

## **Chapter One**

### **1.1 Introduction:**

Spleen is a reticulo-endothelial and lymphoid organ and sometimes works as hemopoietic organ. Spleen is never palpable till it is enlarged two-three times of its own size. There are many modes of investigation to identify the enlarged spleen plane radiograph, sonography, computed tomography, MRI and radionuclide scan. Out of these modalities sonography and computed tomography are most reliable for intra-abdominal organs (Adel Asghar et al 2011).

Various studies were done by sonography to study the linear dimension of spleen – length, width, and thickness .dimensions determined by 2-D ultrasound are limited predominantly by the variable, irregular contour of spleen but also by the difficulty in completely scanning the entire organ or visualizing complete contours as because of the presence of overlying structures such as bone, bowel gas or kidney, CT imaging is more accurate than ultrasonography because this drawback is not seen with computed tomography (Lamb PM et all 2002).

### **1. 2Problem of study:**

There is no stander measurement of spleen volume for Sudanese using to diagnosis spleen abnormality.

### **1.3 Objective of the study:**

#### **1.3.1General objective:**

To measure the spleen volume for Sudanese using computed tomography.

### **1.3.2 Specific objective:**

1. To determine the correlation of spleen volume with body weight and height.
2. To determine the correlation of spleen volume with gender.
3. To determine the correlation of spleen volume with age.

### **1.4 Research Overview:**

Chapter one: Introduction

Chapter two: Theoretical background and previous studies.

Chapter three: Materials and Method

Chapter four: Results

Chapter five: discussion, conclusion, recommendations and  
References

**References:**

**Appendices:**

## **Chapter Two**

### **Theoretical Background and Previous studies**

#### **2.1: Theoretical Background:**

##### **2.1.1Anatomy of the Spleen:**

The spleen starts to develop in the fourth week of gestation as a mesenchymal condensation in the dorsal mesogastrium of the lesser sac. In the following weeks these early mesenchymal cells differentiate to a vascular lymphatic pedicle that eventually forms the spleen. Smaller condensations that develop near the hilum of the spleen form accessory spleens. When the embryo is about 10 cm in length the dorsal mesogastrium can be divided into a posterior part and an anterior part. The posterior part, from the posterior abdominal wall to the spleen, is eventually invaded by the pancreatic bud, which grows as far as the hilum and later fuses with the peritoneum of the posterior abdominal wall ventral to the left kidney to the splenorenal ligament. In this dorsal structure the splenic artery and vein develop. The anterior part of the dorsal mesogastrium develops into the gastrosplenic ligament and contains the short gastric vessels. It is now clear that the spleen is of mesenchymal origin and does not originate from the embryonic endodermal gut.

The splenic condensation forms a trabecular structure resulting in a mesh and ending up in the connective supportive structure of the spleen. The isolated free cells in this network differentiate into hematopoietic cells in the next months of gestation. Other cells derived from the sinusoids of the splenic artery specialize to participate in the reticulo endothelial system (Mollit DL et al 2000).

The spleen is located in the left hypochondria between the fundus of the stomach and the diaphragm, behind the maxillary line opposite the 9th, 10th, and 11th ribs. Its long axis lies parallel to the long axis of the 10th rib. It moves a bit in living during respiration (fig 2.1) (Vishram. S 2014).

The spleen is a wedge-shaped soft organ with purple color. The size of the spleen roughly corresponds to the first of the subject.

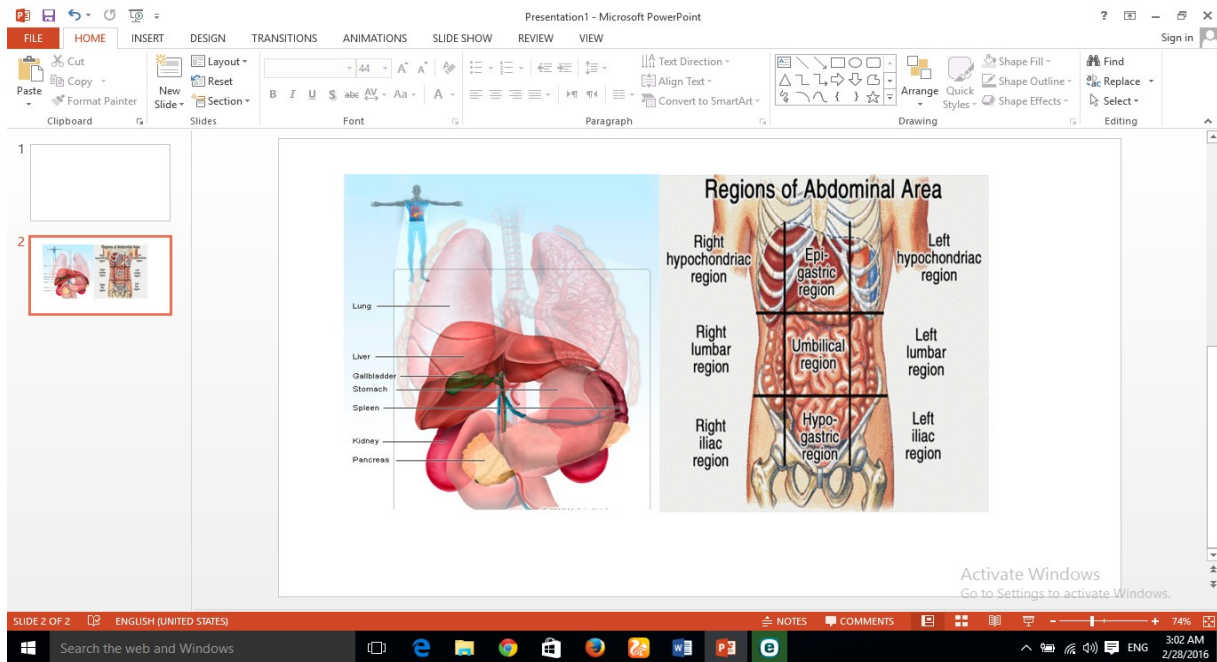
Normal Measurements of the spleen are 1 inch Thickness, 3 inches width, 5 inches Length and about 7 oz Weight .The spleen is marked on the surface on the left side of the back of the trunk. Its long axis corresponds to that of the 10th rib. Its upper border corresponds to the upper border of the 9th rib, and its lower border corresponds to the lower border of the 11th rib. Its medial end lies about 5 cm from the posterior midline of the body at the level of spine of T10 vertebra and lateral end at the mid axillary line (Fig. 2.2) (Richard s 2012).

The features of the spleen are External features two ends (anterior and posterior) the anterior end (lateral end/lower pole) is broad and is more like a border. It is directed downward, forward, and to the left. It is related to the left colic flexure in front and

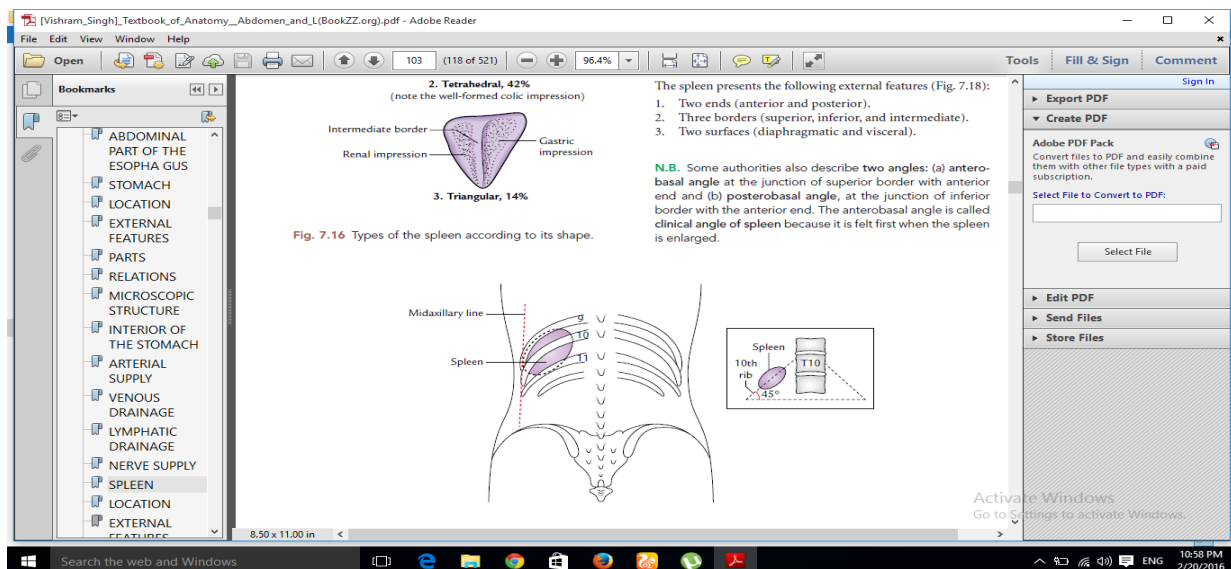
phrenic colic ligament below. The posterior end (medial end/upper pole) is blunt and rounded. It is directed upward, backward, and medially towards the vertebral column. It is related to the upper pole of the left kidney (Vishram. S 2014).

Three borders (superior, inferior, and intermediate).The superior border of the spleen is thin and convex. It separates the visceral surface (gastric impression) from the diaphragmatic surface. It characteristically presents one or two notches near its anterior end. These notches indicate that the spleen develops by the fusion of separate masses of lymphoid tissue (lobulated development).The inferior border of the spleen separates the visceral surface (renal impression) from the diaphragmatic surface. It is rounded and corresponds to the lower border of the 11th rib. The intermediate border is rounded and separates the gastric impression from the renal impression on the visceral surface (Vishram. S 2014).

Concave and irregular. It presents four impressions: gastric, renal, colic, and pancreatic. The gastric impression is produced by the fundus of the stomach. It is the



**Fig (2.1) shows spleen is location in the abdominal cavity**



**Fig (2.2) shows the relation of the spleen with the ribs**

Largest impression and lies between the superior and intermediate borders. The hilum of spleen is located in the lower part of this impression. The renal impression is produced by the left kidney and lies below and behind the gastric impression between the intermediate and inferior borders. The colic impression is produced by the left colic flexure. It is triangular in shape and situated in front of the lateral end. The pancreatic impression (occasional) is produced by the tail of the pancreas. It is located between the hilum and the colic impression (Vishram. S 2014).

### **2.1.1.2 Relation of spleen:**

The Peritoneal Relations spleen is completely enclosed in the peritoneum except at its hilum, from where two peritoneal folds extend one to the stomach and one to the left kidney, called gastrosplenic and lienorenal ligaments, respectively (Fig.2.4). Gastrosplenic ligament extends from the hilum of the spleen to the upper one-third of the greater curvature of the stomach. It contains short gastric vessels (Ashwin P 2014).

Lien renal ligament extends from the hilum of the spleen to the anterior surface of the left kidney. It contains the Tail of the pancreas, splenic vessels, and pancreatic splenic lymph nodes. The visceral surface of the spleens related to the following viscera Fundus of the stomach, anterior surface of the left kidney, Left colic flexure and Tail of pancreas (fig2.5) (Ashwin P 2014).

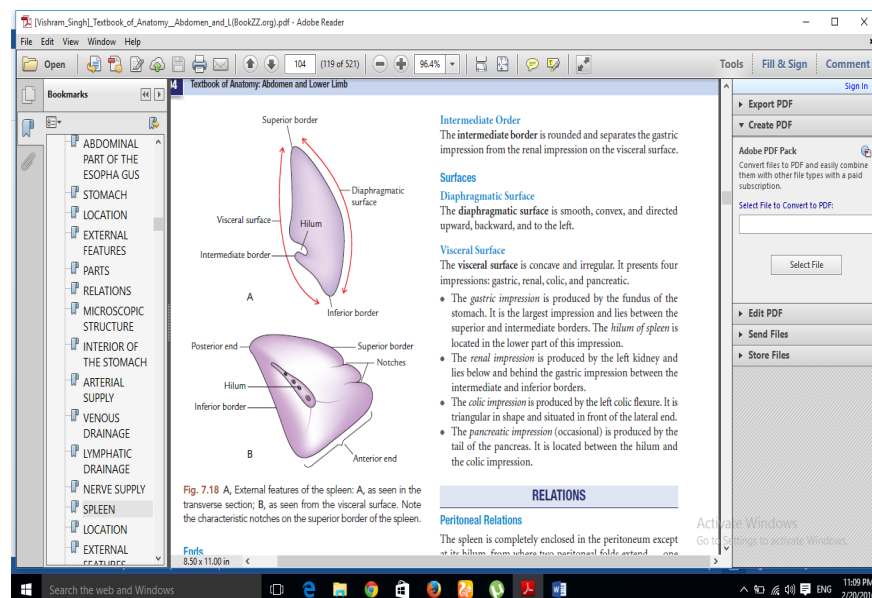
These viscera produce impressions on this surface. The diaphragmatic surface of the spleens related to the diaphragm,

which separates it from the costophrenic recess of the pleura, lung, and 9 to 11 ribs (Figs 2.6 and 2.7).

### 2.1.1.3 Blood supply:

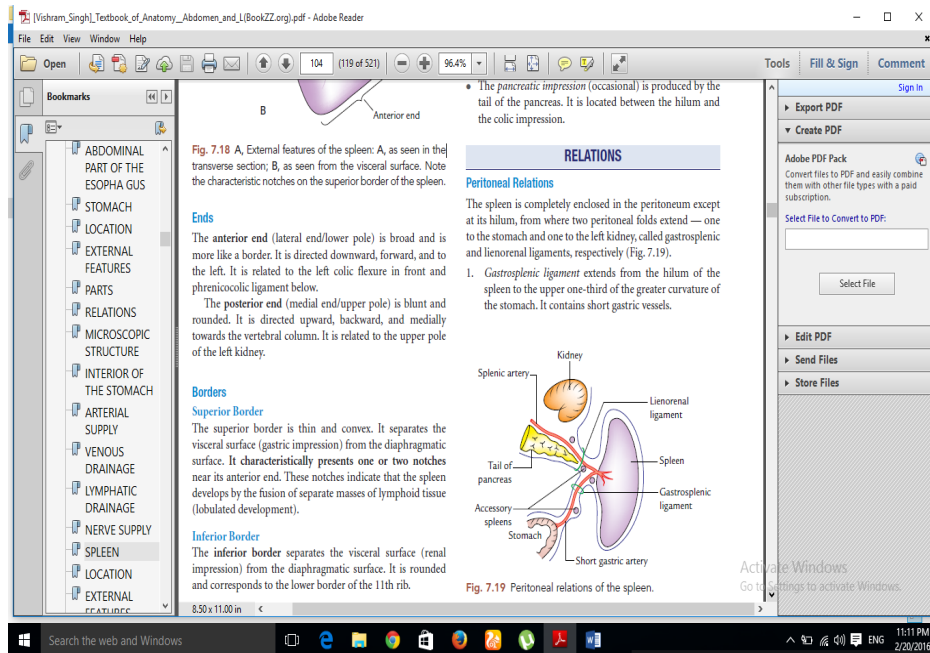
The blood supply of the spleen is splenic artery is, along with the gastric and common hepatic arteries, one of the three main branches of the celiac artery. The celiac artery branches from the abdominal aorta, the largest artery in the abdomen.

The splenic artery is responsible for supplying oxygenated blood to the spleen, but also has several branches that deliver blood to the stomach and pancreas. The

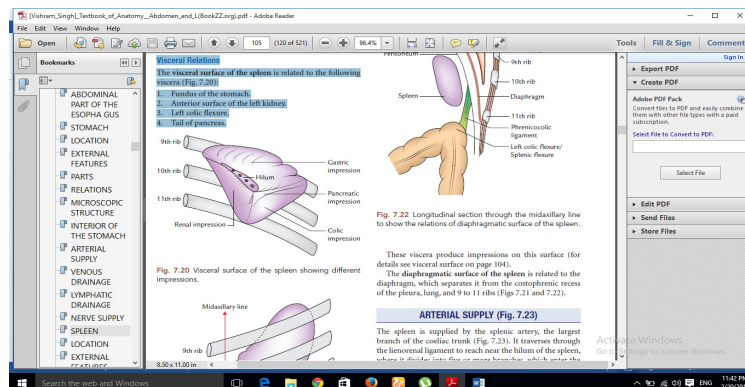


**Fig (2.3): A, External features of the spleen: A, as seen in the transverse section; B, as seen from the visceral surface.**

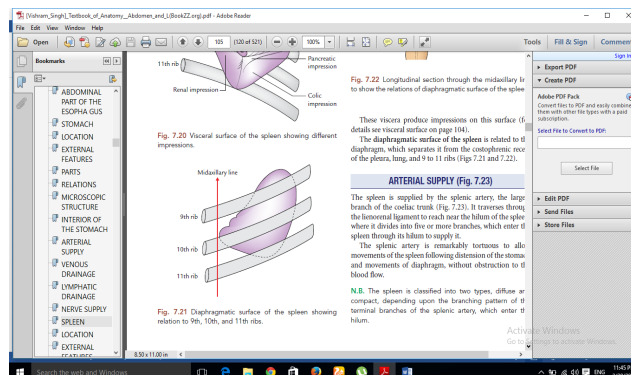




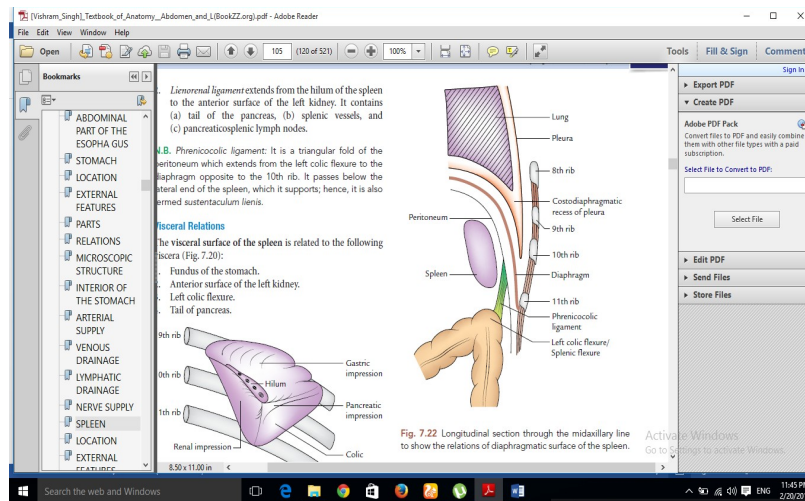
**Fig (2.4): peritoneal relations of the spleen.**



**Fig (2.5): Visceral surface of the Spleen showing different impressions.**



**Fig (2.6): Diaphragmatic surface of the Spleen showing relation to 9<sup>th</sup>, 10<sup>th</sup>, and 11<sup>th</sup> ribs.**



**Fig (2.7): longitudinal section through the mid axillary line to show the relation of diaphragmatic surface of the spleen.**

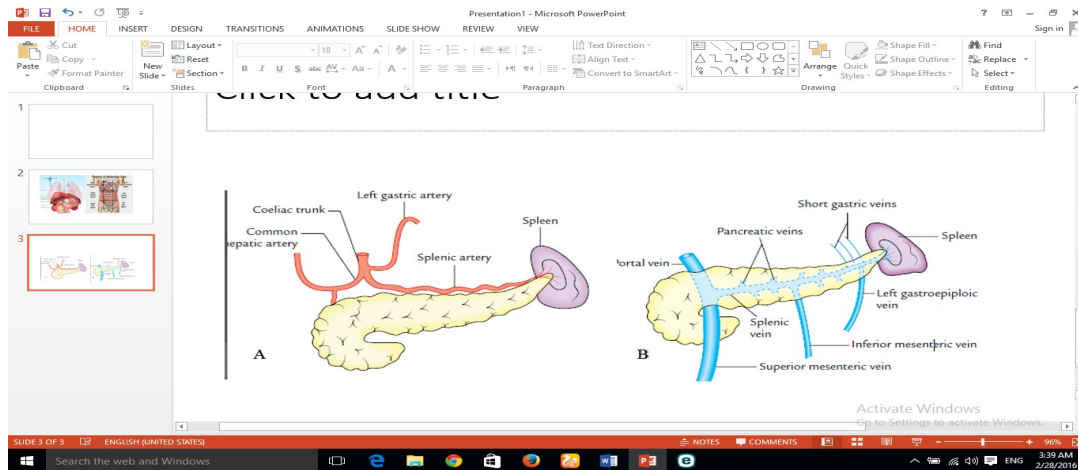
Branches of the splenic artery are the short gastric, the left gastroepiploic, the posterior gastric, and the branches to the pancreas. The short gastric arteries consist of five to seven small branches that run along the greater curvature of the stomach. The left gastroepiploic artery is the largest branch of the splenic artery and runs toward the interior of the stomach through the greater omentum, a large membrane that hangs down from the stomach. The branches to the pancreas consist of numerous, small, blood vessels that run behind the upper border of the pancreas, supplying it with blood (Healthline Media 2016). The venous blood from the spleen is drained by the splenic vein, which is formed at the hilum by the union of five or more tributaries which emerge from the splenic substance. The splenic vein runs a straight course from left to right behind the body of pancreas. Behind the neck of pancreas it joins the superior mesenteric vein

to form the portal vein its tributaries are: Short gastric veins, Left gastroepiploic vein, pancreatic veins and Inferior mesenteric vein(Fig.2.8B)(Healthline2016).

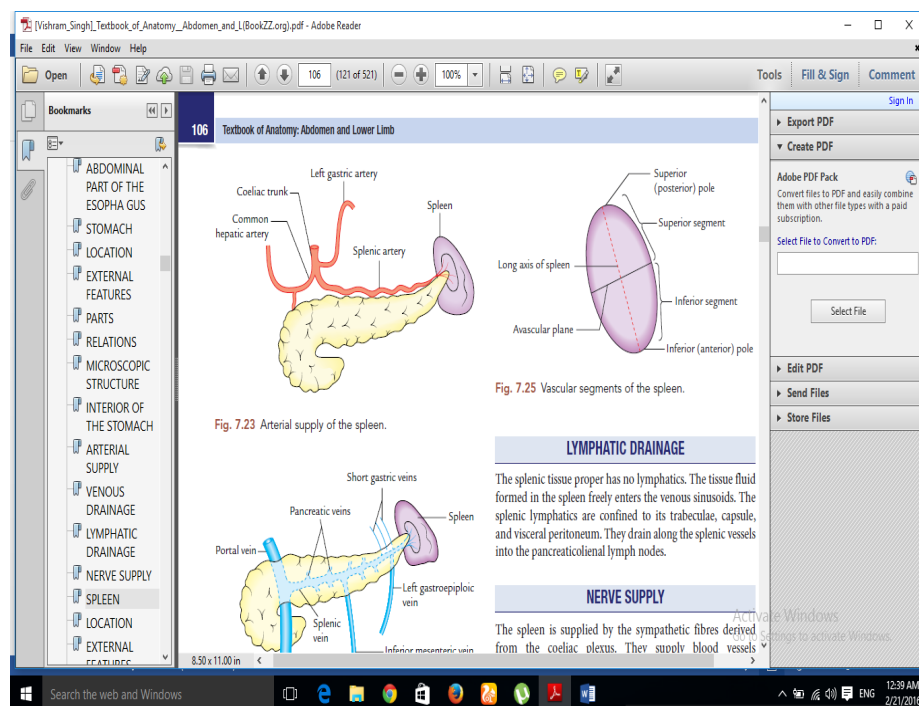
The splenic tissue proper has no lymphatic's the tissue fluid formed in the spleen freely enters the venous sinusoids. The splenic lymphatics are confined to its trabecular, capsule, and visceral peritoneum. They drain along the splenic vessels into the pancreaticolienal lymph nodes (Vishram. S 2014).

The spleen is supplied by the sympathetic fibers derived from the coeliac plexus. They supply blood vessels (vasomotor) and smooth muscle fibers present in the trabecular and capsule (Vishram. S 2014).

The splenic artery within the spleen usually gives two branches superior and inferior. These branches usually do not anastomose and each branch supplies its own territory (segment). Thus, an avascular zone exists between these two territories. Thus, the spleen presents two segments, superior and inferior, separated by an avascular plane passing perpendicular to the long axis of the spleen (Fig. 2.9). The Knowledge of



**Fig (2.8): A. Shows the Arterial supply of the spleen, B. venous drainage of the spleen.**



**Fig (2.9): vascular segment of the spleen**

These vascular segments is essential for segmental resection of the spleen to preserve the splenic tissue if required (Vishram. s 2014).

## 2.1.2 Physiology of Spleen:

The spleen has multiple functions, some of which remain poorly understood. Its most important functions are its ability to act as a blood filter and its role in the immunologic process of the body (Genevieve C 2015).

1. Filtering functions. Splenic blood flow is approximately 350 L/day of blood most blood elements pass through rapidly and uneventfully. A. Removal of old or abnormal red blood cells the spleen removes about 20 mL/day of aged or abnormal red blood cells. The Cells that have immunoglobulin G (IgG) on their surfaces are removed by monocytes in the spleen. This removal of cells may be the mechanism of increased cell destruction in some diseases, such as idiopathic thrombocytopenic Purport and autoimmune haemolytic anaemia. Removal of abnormal white blood cells, normal and abnormal platelets, and cellular debris.

2. Immunologic functions opsonic production. The entire reticuloendothelial system is capable of removing well-opsonized bacteria from the circulation, but the spleen, with its highly efficient filtering mechanism, is particularly suited to removing poorly opsonized or encapsulated pathogens (Genevieve C 2015).Antibody synthesis. This synthesis occurs mainly in the white pulp, where soluble antigens stimulate the production of immunoglobulin M (IgM).Protection from infection. It is well established that splenectomy leaves some patients more susceptible to infection(GenevieveC2015).

3. Storage functions. Approximately one third of the body's platelets are stored in the spleen. In some pathologic states, the percentage is increased (Genevieve C 2015).

## **2.1.3 Pathology of the spleen:**

### **2.1.3.1 Congenital Malformations:**

**Accessory spleen:** A section of spleen with attached pancreas and omentum. In the mass of tissue arising from the hilum, there is a small nodule (approximately 2 cm) of dark red purple tissue. This is an accessory spleen. (Malley 2013).

**Intrapancreatic spleen:** Is a rare finding associated with embryologic abnormality. Small fragments of spleen tissue are entrapped within a portion, usually distal, of the pancreas although these can vary in size, they are usually quite small. (Malley 2013).

**Polysplenia:** In this case, the primordial separate lobes of splenic tissue do not fuse to make a single unified organ. Rather, they are partly fused or remain separated by fibrous bands (Malley 2013).

### **2.1.3.2 Primary benign splenic neoplasms:**

**Hemangioma:** Hemangioma is the most common benign neoplasm of spleen and most splenic hemangiomas are found incidentally on imaging. (Wijaya et al 2001). **Lymphangioma:** Splenic lymphangiomas are rare, benign, slow-growing neoplasms usually seen in childhood. Similar to hemangioma. (Wijaya et al 2001). **Hamartoma:** Splenic hamartoma is a rare benign lesion composed of malformed splenic red pulp elements without

organized lymphoid follicles, the exact cause of which is uncertain. (Yu RS et al 2004).

**Littoral cell angioma:**Littoral cell angioma is a rare vascular tumor arising from the littoral cell, which lines the sinuses of splenic red pulp. (Levy AD et al 2004).

**Inflammatory pseudo tumor:**Splenic inflammatory pseudo tumor is a rare benign lesion of uncertain cause, likely resulting from an unusual inflammatory reparative response to injury such as infection (Levy AD et al 2004).

### **Uncommon primary splenic neoplasms:**

Primary mesenchyme tumors such as lipoma, angiomyolipoma, fibroma, fibrosarcoma, leiomyosarcoma and malignant fibrous histiocytoma have been reported to occur in the splenic parenchyma but are quite rare (Warshauer DM, et al

### **2.1.3.3 Primary malignant neoplasms of the spleen:**

**Lymphoma:**Primary involvement of the spleen by lymphoma is much less common than secondary involvement, accounting for less than 1% of all lymphomas Primary splenic lymphoma usually represents non-Hodgkin lymphoma of B cell origin. Secondary involvement of the spleen is much more common and is seen in association with enlarged lymph nodes in the rest of abdomen (Levy AD et al 2004).

**Angiosarcoma:**Although rare, angiosarcoma is the most common primary non-hematopoietic malignant tumor of the spleen (Lucey BC et al 2000).

#### **2.1.3.4 Metastatic lesions:**

Splenic involvement by metastasis is relatively uncommon and is thought to be secondary to lack of afferent lymphatics. Hematogeneous spread is considered the most probable route of spread resulting in splenic metastases. Tumors that most commonly metastasize to the spleen include melanoma, and tumors of the breast, lung, ovary, colon, stomach and pancreas, most metastases to the spleen are seen as solitary or multiple masses and diffuse infiltration is a rare phenomenon (Lam KY et al 2000).

#### **2.1.3.5 Traumatic:**

Rupture of the spleen can often be managed non-operatively. Splenectomy is reserved for those patients who are unstable or who have additional, massive injuries (Genevieve C 2015).

#### **2.1.4 Principles of Computed tomography (CT):**

Computed tomography (CT) was first introduced as a clinical tool in 1971 when Drs. Godfrey Hounsfield and James Ambrose successfully diagnosed a brain tumor in a 41-year-old woman. In its most basic form, a rotating X-ray beam emits ionizing radiation of a defined thickness, which is used to irradiate the patient from numerous projections. Detectors located on the other side of the patient, opposite the source of the beam, register the amount of radiation that has penetrated through the patient. By calculating these values for numerous projections, a two-dimensional image of



a specified thickness is generated. These images possess contrast resolution that is far superior to conventional radiography, demonstrating the ability to distinguish substances of only slightly different densities. Once such a 2-D image is acquired, the patient is advanced through the CT gantry for a predefined distance, and then the process is repeated. This is known as “step-and-shoot” technology (G. Bongartz et al .2004).

#### **2.1.4.1 Spiral CT imaging:**

Method of CT imaging was allowing for uninterrupted scanning during continuous patient advancement through the gantry, thus describing a spiral or helical pattern of data acquisition .With the introduction of spiral CT came the need to start thinking differently (G. Bongartz et al .2004).

#### **2.1.4.2 Generation OF CT:**

**First Generation:** The CT scanners (early 1970s) have single detector and the combination of both translate and rotate motions, scan times were very long: of the order of a few minutes (fig 2:10) (Greg 2001).

**Second Generation:** The Second generation CT scanners (fig2:11) were developed to decrease scan times. They had a narrow fan-beam of x-rays and a small number of detectors. Multiple projections were acquired simultaneously (one per detector) during each translation and therefore the number of translations required was reduced accordingly (Greg 2001).

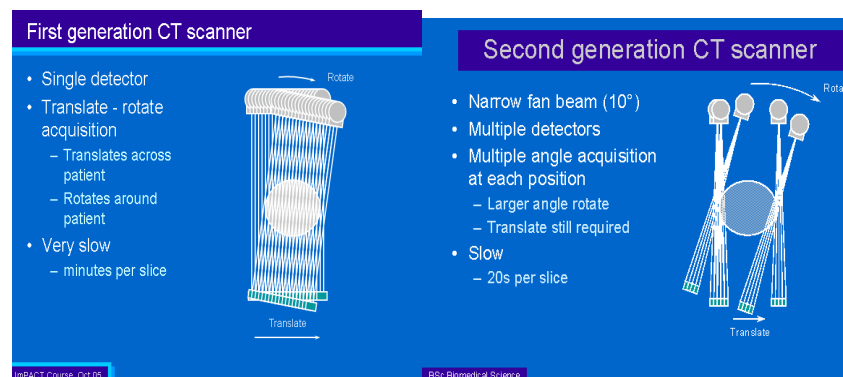
**Third Generation:** The Third generation is that shown in (fig2:12), i.e. the fan beam of x-rays is wide enough to cover the full width of the patient and therefore no translation motion is required. The x-

ray tube and detector arc rotate only. The arc of detectors may contain up to 1000 individual detectors (Greg 2001).

**Fourth Generation:** The Fourth generation scanners the detectors form a complete ring around the patient and only the x-ray tube has to rotate. These scanners may use up to nearly 5000 individual detectors. A fourth generation CT scanner is depicted in (fig 2:13) (Greg 2001)

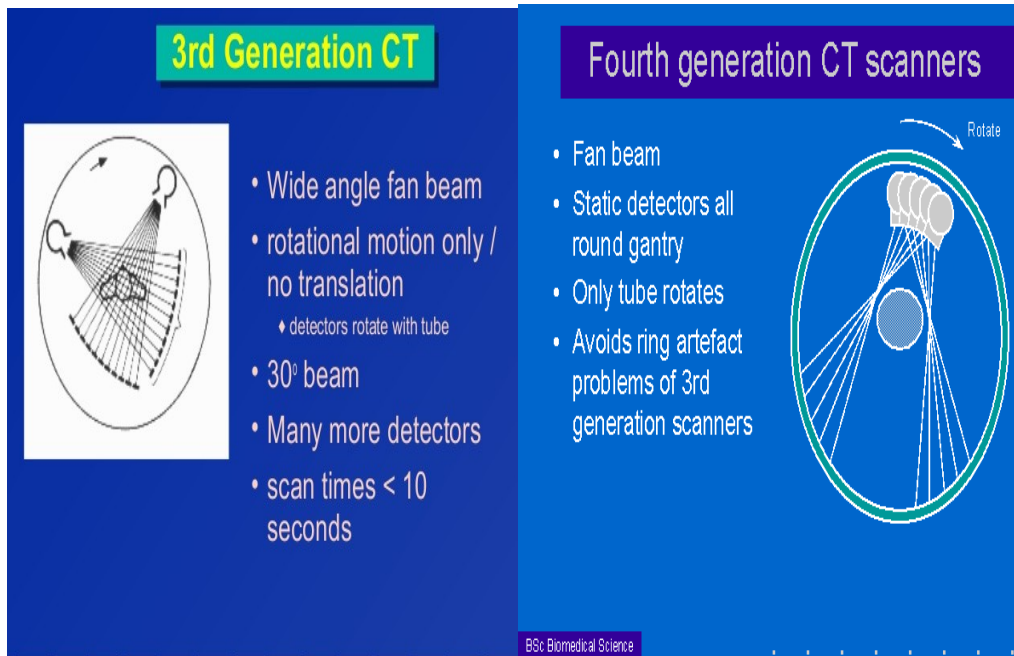
**Fifth Generation:** The fifth generation of CT scanners has eliminated all mechanical motion by using an x-ray tube with an anode that forms a circular arc of about  $210^\circ$  around the patient. The scanning motion is achieved by using magnetic fields to sweep the electron beam along the anode. This scanner can acquire a complete set of projection data in as little as 50 MS and is designed specifically for cardiac imaging (fig 2:14) (Greg 2001).

**Helical CT:** The conventional way in which CT is used is to keep the patient stationary during the scanning process. Scanning is then halted while the patient is positioned, using a motorized table-top, for the next scan (Greg 2001).

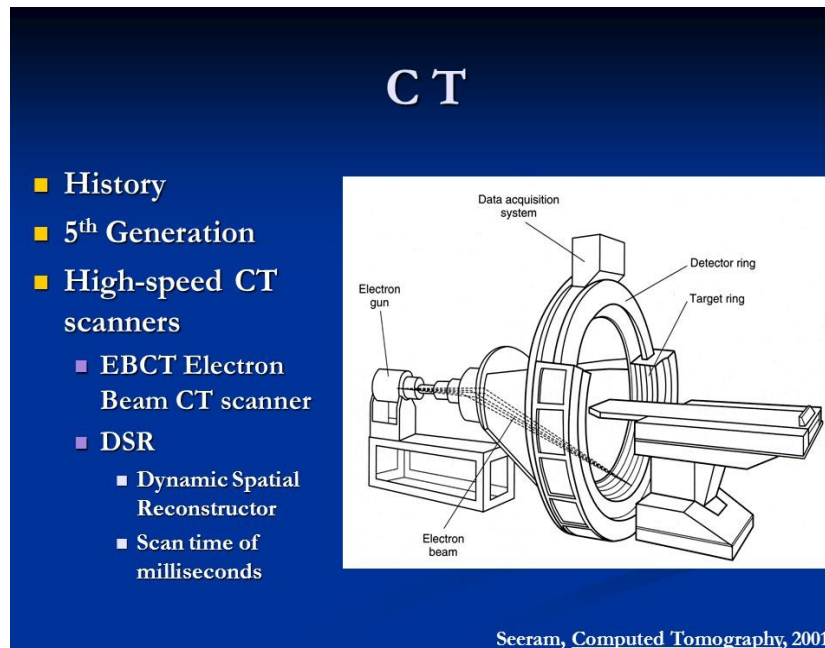


**Fig (2:10) Shows First generation second generation**

**Fig (2:11) Shows**



**Fig (2:12) Shows third generation Fig (2:13) Shows fourth generation**



**Fig (2:14) Shows fifth generation**

## **2.1.5 Technique of abdomen and spleen:**

### **2.1.5.1 Patient's preparation:**

For adequate examination of the abdomen and pelvis by CT, sometimes we need to opacity the gastrointestinal tract by an orally administered contrast material (gastrographin 38%). (D Karthikeyan 2005).

The contrast material is diluted by water to a concentration of 2-4% and taken orally by the patient at intervals to opacity the GI tract from the stomach to the anus. The amount of contrast material and the intervals of intake are subject to great variations.

Patient should be fasting 4-6 hours before the examination. Patients indicated for IV contrast injection are injected with 4-5 ampules (20 ml each) as a bolus just before

The start of examination, flow rate 1.5-2 ml/sec, scan delay 75-80 sec.

Non contrast scans should be obtained before contrast Injection when examining specific organs such as the liver, spleen, kidney and urinary bladder (D Karthikeyan 2005).

### **2.1.5.2 Patient position:**

Patient in supine position, feet first on scanner table, the arms are raised and placed behind the patients head, out of scan plane. Median sagittal plane is perpendicular to the center of the table top and the coronal plane is parallel to it. The scanner table height is adjusted to ensure that the coronal plane alignment light is at the level of the mid-axillary line (M .Mahfouz 2007). A Tomogram is

obtained to include the diaphragm and pubis, the scans are performed during normal inspiration Gantry angle zero, for general abdomen 10 mm slice thickness and 10 mm table increments are selected through the entire abdomen for the spleen use less slice thickness 5 mm 5 mm table increments. In the multidetector CT (MDCT) facilities we may obtain reconstructed images in the sagittal and coronal planes which are very helpful in the diagnosis especially in cases of spleen pathology (M. Mahfouz 2007).

#### **2.1.6 Measurement of spleen:**

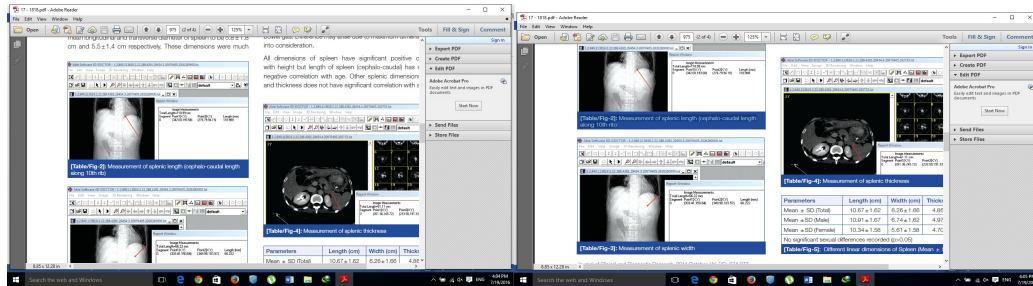
CT-scan DICOM images of each patient were observed in Able- 3D-doctor software. Spleen was identified in each cross section and longitudinal section of CT-scan images. The length of spleen was recorded in longitudinal section along 10th rib in cephalocaudal direction (Fig2:15A). Width of spleen was also recorded in longitudinal direction (Fig2:15B) and thickness measured in cross-section image (Fig2:16). All dimensions were recorded maximum appreciated in sections for better accuracy.

#### **2.1.7 Calculation of spleen volume method:**

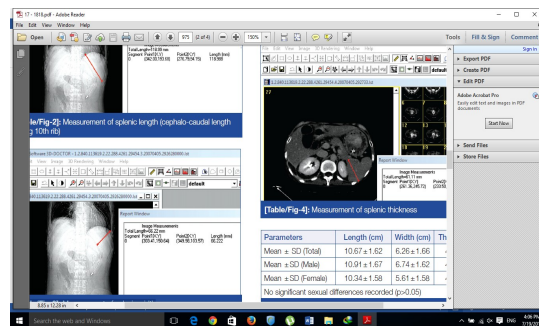
The CT volumes, means and ranges of calculated volumes, and SDs using ellipsoid methodology. The ellipsoid formulas were then adjusted for bias such that  $CT\ volume = (0.524 \times W \times T \times L)$  (Ellen M. 2003)

A

B



**(Fig2:15) Shows A-Measurement of splenic length (cephalo-caudal length Along 10th rib) and B- Measurement of splenic width**



**(Fig2:16) Shows Measurement of splenic thickness**

## 2.2 Previous Studies:

Sitthipong Srisajjakul In 2011 was measured the width (W), length (L), thickness (T) and splenic volume from 426 patients who underwent CT for various indications. The relationship between splenic volume and age, gender and body habitus were also examined. And he found the average splenic volume was  $124.1 \pm 51.8 \text{ cm}^3$ . Adel Asghar *et al*/ In 2011 measured splenic volume using volumetric software in north Indian adult population and

found it out to be  $192 \pm 54.91 \text{ cm}^3$  in males,  $118.39 \pm 47.7 \text{ cm}^3$  in females and over all  $161.57 \pm 90.2 \text{ cm}^3$ . Researcher found the splenic size in males to be  $196.95 \pm 46.81 \text{ cm}^3$  and in females to be  $121.45 \pm 26.97 \text{ cm}^3$ . They found a significant difference in two sexes.

Mustapha *et al*/ In 2010 measurement of spleen for adult African people by ultrasonography and found out the mean splenic volume to be  $120 \text{ cm}^3$ . Harris *et al*/In 2010 measure of splenic volume using volumetric software in 230 patients who underwent CT scan for various reasons. They reported splenic volume in Japanese people to be  $127 \pm 62.9 \text{ cm}^3$  in all subjects.

Loftus *et al*/ In 2009 calculated splenic volume by water displacement and reported

Normal size to be  $110 \pm 70 \text{ cm}^3$ .

## **Chapter three**

### **Materials and methods**

#### **3.1 Materials:**

### 3.1.1 Subject:

This study intended to measure spleen in normal adult Sudanese population.

The data used in this study was collected from two hospitals in Khartoum state:

Alzytoun Specialist Hospital, Royal Scan Diagnostic Center.

The data collected from October 2015 to January 2016.

CT scans of 110patients (55 male and 55 female) are used to measure the volume of spleen. The age of patients ranged from 20 to 80 years.

### 3.1.2 CT Machine:

Two CT machines were used to collect data during this study. This machines are installed in two radiological departments.

Hospital	Manufactu re	Model	Instillati on	Detector type
Al-zaytouna Hospital	Toshiba	Aquilion 64	2010	64 Rows
RoyalScan Diagnostic Center	Toshiba	Aquilion 64	2012	64 Rows



## 3.2 Methods:

### 3.2.1 Technique used:

	<b>Al-Zytouna hospital</b>	<b>Royal scan center</b>
<b>Scouts</b>	AP and lateral	AP and lateral
<b>Scan type</b>	Helical	Helical
<b>Start location</b>	above to the diaphragm	above to the diaphragm
<b>End location</b>	below symphysis pubis	below symphysis pubis
<b>Breath-hold</b>	Inspiration	Inspiration
<b>Reconstruction</b>	Slice Thickness and Interval 5 mm/5 mm	Slice Thickness and Interval 5 mm/5 mm
<b>KVp</b>	120	120
<b>Mas</b>	≥230	≥200
<b>I.V. contrast</b>	3.5 - 4 ml/sec, 100-150 ml	4 - 4.5 ml/sec, 100-150 ml
<b>Scan delay</b>	1. non-contrast 2. Arterial 20 sec. 3. Portal 20 sec. 4.delay after 5 min	1. non-contrast 2. Arterial 25 sec. 3. Portal 25 sec. 4. delay after 5 min

### **3.2.2 Measurement:**

CT-scan DICOM images of each patient were observed in Radiant DICOM Viewer software. Spleen was identified in each cross section and longitudinal section of CT-scan images. The length of spleen was recorded in longitudinal coronal section along 10th rib from superior border of the spleen (appendix A.1). Width of spleen was also recorded in coronal section from the hilum of the spleen to the lateral border of spleen (appendix A.2) and thickness measured in axial section (appendix A.3). All dimensions were recorded maximum appreciated in sections for better accuracy. The splenic volume calculated by multiplying the splenic width, thickness and length and then by multiplying in 0.52.

### **3.2.3 Data Collection and analysis:**

Data were collected using a sheet for all patients in order to maintain consistency of the information from display (appendix B). A data collection sheet was designed to obtain patient gender, age, spleen length, spleen thickness, spleen width, spleen volume, patient Weight, and height was calculated. Microsoft excel for analysis.

## Chapter Four Results

### 4.1 Results:

Table (4.1) demonstrate the distribution of the gender:

<b><i>gender</i></b>	<b><i>Frequencies</i></b>	<b><i>Percentage</i></b>
<b><i>Male</i></b>	<b><i>55</i></b>	<b><i>50%</i></b>
<b><i>Female</i></b>	<b><i>55</i></b>	<b><i>50%</i></b>
<b><i>Total</i></b>	<b><i>110</i></b>	<b><i>100%</i></b>

**Fig (4.1) shows the distribution of the gender**

Table (4.2) demonstrate relation between age groups and spleen volume in males:

<b><i>Age Group\year</i></b>	<b><i>Frequencies</i></b>	<b><i>Percentage</i></b>	<b><i>Spleen Volume\cm<sup>3</sup></i></b>
<b><i>20-40</i></b>	<b><i>20</i></b>	<b><i>36%</i></b>	<b><i>197.1</i></b>
<b><i>41-60</i></b>	<b><i>22</i></b>	<b><i>40%</i></b>	<b><i>197.5</i></b>
<b><i>61-80</i></b>	<b><i>13</i></b>	<b><i>24%</i></b>	<b><i>152.6</i></b>

**Fig (4.2A) Shows relation between age groups and spleen volume in males.**

**Fig (4.2B) shows correlation between age groups and spleen volume in males**

Table (4.3) demonstrate relation between age groups and spleen volume in females:

<b>Age Groups\year</b>	<b>Frequencies</b>	<b>Percentage</b>	<b>Spleen Volume\cm<sup>3</sup></b>
<b>20-40</b>	<b>23</b>	<b>42%</b>	<b>168.4</b>
<b>41-60</b>	<b>22</b>	<b>40%</b>	<b>172.4</b>
<b>61-80</b>	<b>10</b>	<b>18%</b>	<b>104.8</b>

**Fig (4.3A) Shows relation between age groups and spleen volume in females.**

**Fig (4.3B) shows correlation between age groups and spleen volume in females**

Table (4.4) demonstrate relation between body height group and spleen volume in males:

<b>Body height\cm</b>	<b>Frequencies</b>	<b>Percentage</b>	<b>spleen volume\cm<sup>3</sup></b>
<b>140-150</b>	<b>6</b>	<b>11%</b>	<b>263</b>
<b>151-160</b>	<b>20</b>	<b>36%</b>	<b>222.1</b>
<b>161-170</b>	<b>14</b>	<b>26%</b>	<b>151.5</b>
<b>171-180</b>	<b>10</b>	<b>18%</b>	<b>186.9</b>
<b>181-190</b>	<b>5</b>	<b>9%</b>	<b>231.8</b>

**Fig (4.4A) shows relation between body height and spleen volume in males**

**Fig (4.4B) shows correlation between body height and spleen volume in males**

Table (4.5) demonstrate relation between body height group and spleen volume in females:

<b>Body height \ cm</b>	<b>Frequencies</b>	<b>Percentage</b>	<b>Spleenvolume \cm<sup>3</sup></b>
<b>140-150</b>	<b>7</b>	<b>13%</b>	<b>123.4</b>
<b>151-160</b>	<b>13</b>	<b>24%</b>	<b>131.6</b>
<b>161-170</b>	<b>20</b>	<b>36%</b>	<b>173.1</b>

<b>171-180</b>	<b>10</b>	<b>18%</b>	<b>165.5</b>
<b>181-190</b>	<b>5</b>	<b>9%</b>	<b>320.9</b>

**Fig (4.5A) shows relation between body height and spleen volume in females**

**Fig (4.5B) shows correlation between body height and spleen volume in females**

Table (4.6) demonstrate relation between body weight group and spleen volume in males:

<b><i>Body weight\kg</i></b>	<b><i>Frequencies</i></b>	<b><i>Percentage</i></b>	<b><i>spleen volume /cm<sup>3</sup></i></b>
<b>40-65</b>	<b>11</b>	<b>20%</b>	<b>203.9</b>
<b>66-90</b>	<b>39</b>	<b>71%</b>	<b>210.32</b>
<b>91-120</b>	<b>5</b>	<b>9%</b>	<b>242.2</b>

**Fig (4.6A) shows relation between body weight and spleen volume in males**

**Fig (4.6B) shows correlation between body weight and spleen volume in males**

Table (4.7) demonstrate relation between body weight group and spleen volume in females:

<b><i>Body weight/kg</i></b>	<b><i>Frequencies</i></b>	<b><i>Percentage</i></b>	<b><i>spleen volume\cm<sup>3</sup></i></b>
<b>40-65</b>	<b>12</b>	<b>22%</b>	<b>147.2</b>
<b>66-90</b>	<b>36</b>	<b>65%</b>	<b>164.3</b>
<b>91-120</b>	<b>7</b>	<b>13%</b>	<b>182.1</b>

**Fig (4.7A) shows relation between body weight and spleen volume in females**

**Fig (4.7B) shows correlation between body weight and spleen volume in females**

Table (4.8) demonstrate the mean of the spleen volume for males and females adult Sudanese population:

<b>Spleen volume in males\cm<sup>3</sup></b>	<b>Spleen volume in females\cm<sup>3</sup></b>	<b>Mean Volume \cm<sup>3</sup></b>
<b>182.4±25.8 cm<sup>3</sup></b>	<b>148.5±37.9 cm<sup>3</sup></b>	<b>165.45±23 cm<sup>3</sup></b>

**Figure (4.8) showed the mean of the spleen volume for males and females adult Sudanese population and mean of spleen in Sudanese population**

## **Chapter five**

### **Discussion, conclusion and recommendation**

#### **5.1 Discussion:**

In this study the age and gender related random sample of 110 patients including 55 males and 55 females from 20 years to 80 years and this showed in table and figure (4.1).

Table and figure (4.2) showed the relation between the splenic volume with age group in males and Table and figure (4.3) in females and the results showed significant difference in two genders (males 168.3, 172.3 and 104 cm<sup>3</sup>) and females (197.1, 197.4 and 152.6 cm<sup>3</sup>). Also the result showed that the splenic volume in both genders are a slow increase up to the 60 years and then rapidly decrease after age of 61 years. This results was similar to the finding of (Adel Asghar *et al*) In table and figure (4.4)

showed the relation between body heights and the splenic volume in males, the result showed that there is increase in splenic volume ( $263 \text{ cm}^3$ ) up to the height of 150 cm followed by a mild decrease ( $222$  and  $151 \text{ cm}^3$ ) up to 170 cm and then rapid increase ( $186$  and  $231 \text{ cm}^3$ ) after height 171 cm.

In table and figure (4.5) showed the relation between the splenic volume and body height in females, the results showed that increase in the splenic volume ( $123$ ,  $131$  and  $173 \text{ cm}^3$ ) up to the height of 170 cm followed by a mild decrease ( $165 \text{ cm}^3$ ) up to the height of 180 cm and then rapidly increase ( $320 \text{ cm}^3$ ) after the height of 181 cm.

Table and Figure (4.6) shows the relation between splenic volume and body weight in males, the result showed that there is proportional relation between spleen volume and body weight, Increase body weight lead to increase spleen volume.

Table and Figure (4.7) showed the relation between splenic volume and body weight in females the result showed that there is proportional relation between spleen volume and body weight, Increase body weight lead to increase spleen volume.

Table and figure (4.8) showed mean spleen volume in males and females in adult Sudanese population and the result showed that in males the mean of spleen volume are  $182.4 \pm 25.8 \text{ cm}^3$  and in females  $148.5 \pm 37.9 \text{ cm}^3$  and over all  $165.46 \pm 34.4 \text{ cm}^3$  In the present study, it was observed that the splenic volume of male higher than that of female. This may be due to the difference in height, weight and genetic factors. This results was near to the finding of (Adel Asghar et al ) and

significant difference with (Mustapha et al,) harries et al and loftus et al.

## **5.2 Conclusion:**

The volume of the spleen was measure with help of CT in 55 males and 55 female's subject. The basis of the above study, the following conclusion were drown.

In female there is no relation between splenic volumes with the age, Spleen volume, have direct relation with body weight and Volume of the spleen increase with increase the body height. In male there is no relation between spleen volumes with age, and there is no relation between spleen volumes with height and there is a relation between body weight and the spleen volume.

The results showed significant difference in two genders, the spleen volume in males higher than spleen volume females and this may due to genetic factor or other reasons. The results



showed the mean splenic volume for Sudanese population are  $165.45 \pm 23$ .

### **5.3 Recommendations:**

The study recommended to:

- Recommend to measure the spleen volume by using CT machine with 128 slice and more.
- Recommend the radiologist and physician to use the splenic volume in diagnosis the splenic abnormalities.
- Further studies in measuring spleen with larger sample of population.
- Further imaging modalities like Ultrasound and MRI should be used for measuring the spleen volume.

## References:

Adil Asghar et al., Morphometric Study of Spleen in North Indian Adult Population 2011.

D Karthikeyan Step by Step CT Scan (A Practical Guide for Residents and Technologists) First Edition : **2005** ISBN 81-8061-480-8

Elaine N. 2010. Marieb Human Anatomy & Physiology.

Freedman, D., Ogden, C., Berenson, G., & Horlick, M. (2005). Body mass index and body fatness in childhood. *Current Opinion in Clinical Nutrition and Metabolic Care*, 8, 618-623.

G. Bongartz, S.J. Golding, A.G. Jurik, M. Leonardi, E. van Persijn van Meerten, R. Rodríguez,

K. Schneider, A. Calzado, J. Geleijns, K.A. Jessen, W. Panzer, P. C. Shrimpton, G. Tosi .2004 .European Guidelines for Multislice Computed Tomography Funded by the European Commission Contract number FIGM-CT2000-20078-CT-TIP.

[Genevieve Canas](#)Published on 1. März 2015Published in:  
[Wissenschaft](#)

<http://www.healthline.com/health/advertise-with-us>

Kalender, W.A. 2005 .Computed tomography: fundamentals, system technology, image quality, applications. Chichester : Wiley.

Lam KY, Tang V. Metastatic tumors to the spleen: a 25-year clinicopathologic study. Arch Pathol Lab Med. 2000;124:526-30. [[PubMed](#)]

Lamb PM, Lund A., Kanagasabay RR, Martin A, webb JA and Reznick RH et al.: Spleen size: How well do linear ultrasound measurements correlate with three dimension CT volume assessments? Br J Radiol. (2002); 75:573-77.

Lee SH. Fine-needle aspiration cytology of splenic hamartoma. Diagn Cytopathol. 2003;28:82-5. [doi:10.1002/dc.10230](#). PMID: 12561026. [[PubMed](#)]

Levy AD, Abbott RM, Abbondanzo SL. Littoral cell angioma of the spleen: CT features with clinicopathologic comparison. Radiology. 2004;230:485-90. [doi:10.1148/radiol.2302030196](#). PMID:14752189. [[PubMed](#)]

Lucey BC, Boland GW, Maher MM, Hahn PF, Gervais DA, Mueller PR. Percutaneous nonvascular splenic intervention: a 10-year review. AJR Am J Roentgenol. 2002;179:1591-6. [[PubMed](#)]

Malley, Atlas of Spleen Pathology, Atlas of Anatomic Pathology, 11 DOI 10.1007/978-1-4614-4672-9\_2, © Springer Science+Business Media New York 2013

Mollitt DL, Dokler ML 2000. Spleen. In KT Oldham, PM Colombani, RP Foglia (eds), Surgery of Infants and Children: Scientific Principles and Practice. Lippincott-Raven, Publishers, Philadelphia, New York, p. 1425-1436.

M .Mahfouz abdominal imaging 2007.

Vishram Singh TEXTBOOK OF ANATOMY ABDOMEN AND LOWER LIMB Received royalty from Lippincott Williams & Wilkins for other 2014.

Warshauer DM, Hall HL. Solitary splenic lesions. Semin Ultrasound CT MR. 2006;27:370-88. [doi:10.1053/j.sult.2006.06.003](https://doi.org/10.1053/j.sult.2006.06.003). [PubMed]

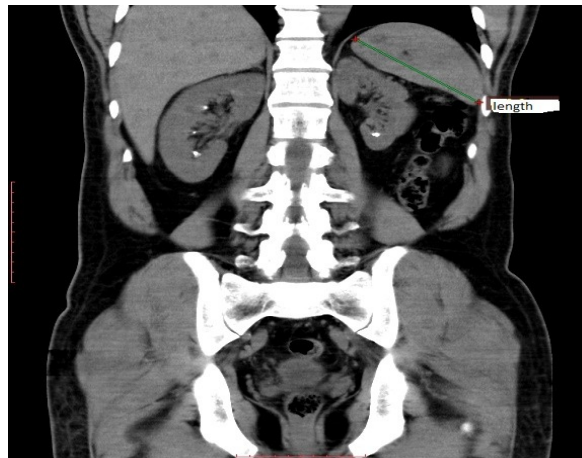
Warshauer DM. Splenic sarcoidosis. Semin Ultrasound CT MR. 2007;28:21-7. [doi:10.1053/j.sult.2006.10.004](https://doi.org/10.1053/j.sult.2006.10.004). [PubMed]

Wijaya J, Kapoor R, Roach P. Tc-99m-labeled RBC scintigraphy and splenic hemangioma. Clin Nucl Med. 2001;26:1022-3. [doi:10.1097/00003072-200112000-00006](https://doi.org/10.1097/00003072-200112000-00006). PMID:11711705. [PubMed]

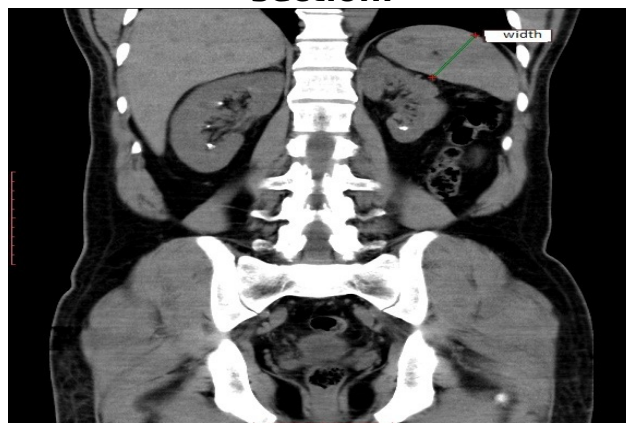
Yu RS, Zhang SZ, Hua JM. Imaging findings of splenic hamartoma. World J Gastroenterol. 2004;10:2613-15. [[PMC free article](#)] [PubMed]

Ellen M. Estimating Splenic Volume: Sonographic Measurements Correlated with Helical CT Determination 2003

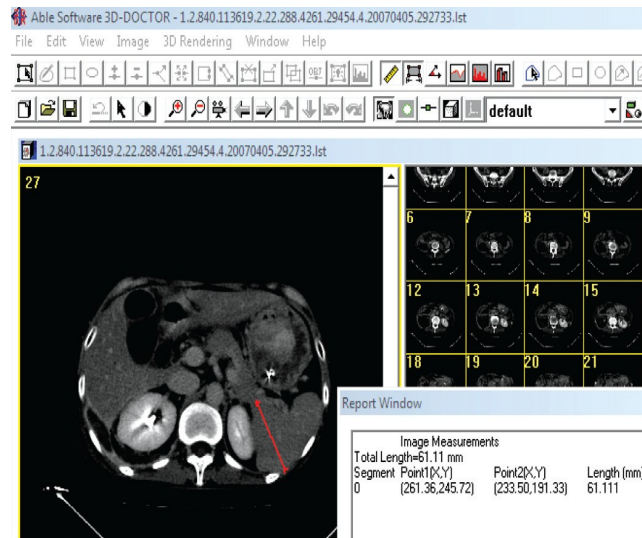
## **Appendices A:**



**Appendix (A1) shows the Measurement of splenic length in coronal section.**



**Appendix (A2) shows the Measurement of splenic width in coronal section.**



**Appendix (A3) shows the thickness measured in axial section.**  
**Appendix B:**

### Data Sheet Collecting

age	gender	Body height	Body weight	Spleen length	Spleen width	Spleen thickness	volume
-----	--------	-------------	-------------	---------------	--------------	------------------	--------

