



**The Association of Placenta Previa with Cesarean Delivery Using
Ultrasound**

**علاقة المشيمة المتقدمة مع الولادة القيصرية باستخدام التصوير
بالموجات فوق الصوتية**

**A thesis Submitted for Partial Fulfillment of Requirement of Master Degree in
Medical Diagnostic Ultrasound**

By:

Awdia Mohamed Ahmed Frah

Supervisor:

Dr: Asma Ibrahim Ahmed Elamin

January 2016

Dedication

This research is dedicated to my parents Mohammed & Fatima, and my husband Esam those who were encouraged me to enjoy the intellectual challenge of Radiology and the love of making a difference in patients' lives.

Acknowledgements

My deepest appreciation and sincerest gratitude:

To my supervisor **Dr. Asma Ibrahim Ahmed Alamin** who have provided me with a wealth of professional joy.

To all the staff in the Turkish hospital, ultrasound department, personally to Sonologist: the director of the department for his permission & unsparing help provided by him, also to **Dr. Yasir**(Sonologist& Radiologist), for their extensive & continuous teaching. Their help and never-ending support made this work possible .I cannot thank them enough for their efforts on this project.

CONTENTS

Subject	Page No.
Dedication	I
Acknowledgements	II
Contents	III
Abbreviations	IV
Abstract	V
Abstract Arabic	VI
List of tables	42-47
List of figures	41-46
CHAPTER ONE	
1.1Introduction	1
1.2The Problem of the study	3
1.3Research Objectives	3
1.4Theses Overview	4
CHAPTER TWO	
2-1 Literature Review	
2.1 Anatomy	5
2.2Physiology	11
2.3Pathology	13
2.4 Previous studies	37

CHAPTER THREE	
3-1 Materials & Tools	
3-2 Methods	40
3-3 Inclusion Criteria	41
3-4 Exclusion Criteria	41
3-5 Ultrasound Technique Of placenta previa	41
3-6 Statistics	42
CHAPTER FOUR	
Results	43-47
CHATER FIVE	
5-1 Discussion	48
5-2 Conclusion	51
5-3 Recommendations	52
5-4 References	53
Appendices	56

Abbreviations

AFV	amniotic fluid volume
APH	ante partum hemorrhage
CS	cesarean section
CD	Color Doppler
D&C	Dilation and curettage
EVS	endovaginal ultrasound
FMC	focal myomertial contraction
HCG	human chorionic gonadotropin
HCS	human chorionic somatomammotropin
IUGR	intrauterine growth restriction
GA	gestation age
LMP	last menstrual period
MA	maternal age
PD	Power Doppler
PP	placenta previa
PROM	premature rupture of membrane

RDS	Respiratory distress syndrome
SCH	sub chorionic hematoma
TAS	transabdominal scan
TPS	transperineal scan

ABSTRACT

This is a descriptive cross-sectional study conducted in Turkish hospital, Khartoum city. The duration of study was 5 months from first January 2016 to May 2016. The main aim was to identify the association of placenta previa with number of previous cesarean section done in pregnant women.

In antenatal clinic as per protocol 50 pregnant women were scanned in their second and third trimester for fetal wellbeing and placental localization after taking a detailed obstetrical history and clinical examination. All women with or without symptoms of placenta previa showing placental implantation in lower uterine segment on ultrasound scan were documented. After completion of the 5 months of data regarding the detailed obstetrical and surgical history were recorded in a questionnaire and analyzed using Statistical package for social sciences Software.

The study found that 31 women were diagnosed as cases of placenta previa. The overall incidence of placenta previa was found to be 62%. Out of these 31 women 15(30%) were have major degree placenta previa .also in the patient who have 1-2 previous Caesarean section(42.3%) were have placenta previa , in those have 3-4 Caesarean section (85.6%) were have placenta previa and in the patient were have 4-5previous Caesarean section (66.7)were have placenta previa.

It was clearly evident from the study that placenta previa is associated with previous cesarean section. Placenta previa was highly significantly associated with increased number of previous cesarean section ($P = 0.000 < 0.05$).

The study concludes that ultrasound is best modalities to diagnosis placenta previa.

ملخص البحث

هذه دراسته وصفية اجريت في المستشفى التركي الخرطوم السودان في الفترة ما بين يناير 2016 الي مايو 2016 الاهداف الاساسيه من هذه الدراسة هي معرفه علاقته المشيمه المتقدمه مع عدد العمليات القيصرية في النساء الحوامل .

في عياده متابعه الحوامل اختير عدد 50 حاله من النساء الحوامل في الثالث والثاني و الثالث من الحمل وبعد عمل الموجات فوق الصوتيه لتاكيد سلامه الجنين و المشيمه و بعد اخذ تاريخ مفصل عن الولادات السابقه و الكشف السريري علي كل النساء الحوامل سوء كان لديهم اعراض مشيمه متقدمه ام لا و لديهن مشيمه متقدمه بعد عمل الموجات فوق الصوتيه ادرجت في البحث بعد اكمال فتره خمس شهور من جمع المعلومات المفصله عن تاريخ الولادات و العمليات الجراحيه السابقه في الاستبيان و تم التحليل بواسطه البرنامج التحليلات الاحصائيه للعلوم الانسانيه .

و تم التوصل الي ان 31 من النساء الحوامل لديهن مشيمه متقدمه بنسبه مؤويه (62%) . و من 31 حاله 15 (30%) لديهن مشيمه متقدمه كلي .

في الحالات اللاتي لديهن 1-2 عمليه قصيريه سابقه (42.3%) لديهن مشيمه متقدمه اما اللاتي لديهن 3-4 عمليات قصيريه (85.6%) لديهن مشيمه متقدمه و اللاتي لديهن 5-6 (66.7%) لديهن مشيمه متقدمه .

و من خلال هذه النتائج يتضح ان هناك علاقه وثيقه بين المشيمه المتقدمه والعمليات القصيريه السابقه.

.ويتضح ايضا ان الموجات فوق الصوتيه من الفحوصات المهمه لتشخيص المشيمه المتقدمه

1.

Chapter One

1.1: Introduction:

When placenta is partly or completely implanted in lower segment, it is called placenta praevia. Placenta is temporary organ that joins the mother and fetus, transferring oxygen and nutrients from mother to the fetus and permitting the release of carbon dioxide and waste products from fetus. (James. 2001).

The risk of having placenta praevia is increased with high gravidity, high parity, and previous caesarean sections. It is associated with antepartum, intrapartum, postpartum complication as well as the risks of massive blood transfusions, septicaemia and hysterectomy. The neonatal complication due to placenta praevia includes preterm birth, low apgar score, RDS, anaemia, neonatal death. (Invest 1999)

This study was done to look for risk factor for placenta praevia particularly, the increasing frequency of placenta praevia in patients with multiple caesarean sections. Early diagnosis of placenta praevia, identification of risk factor such as previous caesarean section, D&C, smoking, multiparty, malpresentation, expectant management and adequate availability of blood may help in better outcome by reducing the fetomaternal complications. Therefore the aim of this study to assess the relationship between previous cesarean section and subsequent development of placenta previa. Several studies, based on ultrasonography findings, have shown that the incidence of

placenta previa is about 3% to 5% in a normal obstetric population during midtrimester.(ActaScand 1981).

However, this frequency falls dramatically to almost 0.3% to 0.7% among term pregnancies as a result of the so-called placental migration.” (Nasreen 2003)

Almost four decades ago Bender first observed an increased frequency of placenta previa among women with uterine scarring (because of cesarean delivery or abortions) in prior pregnancies. (GynecolObstet 1986)

Recently, few studies have explored this association and have unequivocally observed increased risks of placenta previa among women with a history of cesarean delivery. An association between placenta previa and prior cesarean delivery is biologically plausible. Damage to the endometrial and myometrial uterine lining (during cesarean delivery) can predispose to a low implantation of the placenta in the uterus. Likewise, curettage of the uterus during a spontaneous or induced abortion may significantly damage the endometrium and uterine cavity so as to increase the risk for placenta previa. Unfortunately, we were unable to evaluate the association between curettage and subsequent development of placenta previa because of insufficient information from published studies.

(Br J ObstetGyneco2006).

1.2 The problem of the study:

Placenta previa is a frequent complaint in the casualty of obstetrics and gynecology, many tools of investigations are used to find out the right diagnosis. This includes clinical examination, ultrasonography and different types of other radiological modalities. By conducting this research, the researcher wants to know the best way to reach the diagnosis and to help the health workers in the treatment of placenta previa in patients with previous history of caesarean sections.

1.3 Research objectives:

1.3.1 General objective:

To confirm the association of placenta previa in patients with previous history of caesarean sections.

1.3.2 Specific objectives:

- o To determine the incidence of placenta previa in the time of scanning based on the number of caesarean deliveries.
- o To correlate the association of the placenta previa with parity.
- o To assess the association of placenta previa with maternal age.

- o To reduce complication of placenta previa by early detection by using ultrasound.
- o Good counseling to the patients and training labor room staff to reduce primary Cesarean section.
- o To Determine the prevalence of placenta previa for care planners to identify resources needed for obstetrics and gynecology services in the community.

1.4 Overview of the study:

This study consist of five chapter

Chapter one: contains introduction, problem and objectives (general & specific).

Chapter two: contains:

Literature review & Previous Studies.

Chapter three: contains the Material & Methods

Chapter four: Results

Chapter five: contains the Discussion, Conclusion, Recommendations, References and Appendices.

Chapter Two

Literature review

2.1: placenta anatomy

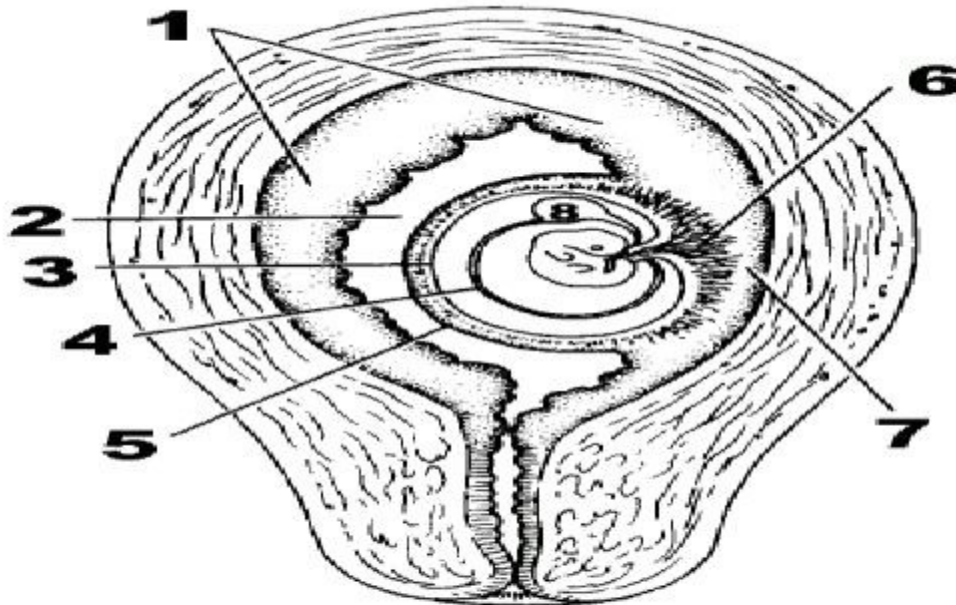
2.1.1Development:

The placenta and fetus both arise from the same single cell - the zygote, which is the fertilized ovum; hence, the placenta and the umbilical cord and the blood flowing in them are of embryonic or fetal origin.(Plascencia, et 1998)

After the blastocyst attaches to the endometrial surface, it begins the process of implantation. In the early stages of implantation, the trophoblast begins to differentiate into two cell layers - the outer syncytiotrophoblast and the inner cytotrophoblast. As the trophoblast invades the decidua, it breaks down decidual blood vessels and creates a network of blood-filled spaces known as lacunae; the lacunar network evolves into the intervillous spaces of the mature placenta.(Moore KL1988)

It is interesting to note that in the trophoblast's invasion of the decidua it normally penetrates just so far and then stops, probably as a result of limits imposed by the decidua rather than by the trophoblast itself (in a tubal pregnancy, trophoblast is

not under any local control and invades freely all the tissue layers of the tube (mucosa, muscle, serosa). As the syncytiotrophoblast becomes embedded in the decidua, the inner cytotrophoblast proliferates forming a complicated system of tiny projections that push into the syncytiotrophoblast and the lacunae. The cytotrophoblastic projections, called the primary chorionic villi, eventually become branched and vascularized by fetal blood vessels originating from the arteries in the umbilical cord. Initially, the entire surface of the developing gestational sac is covered with chorionic villi. As the chorionic sac grows, the villi underneath the decidua capsularis are compressed and their blood supply reduced; subsequently, these villi degenerate, resulting in an avillous portion of the chorionic sac known as the smooth chorion or chorion laeve. Meanwhile, the chorionic villi associated with the deeper decidua basalis proliferate, branch profusely and hypertrophy to form the chorion frondosum or villous chorion (future placenta). (Moore KL 1988)

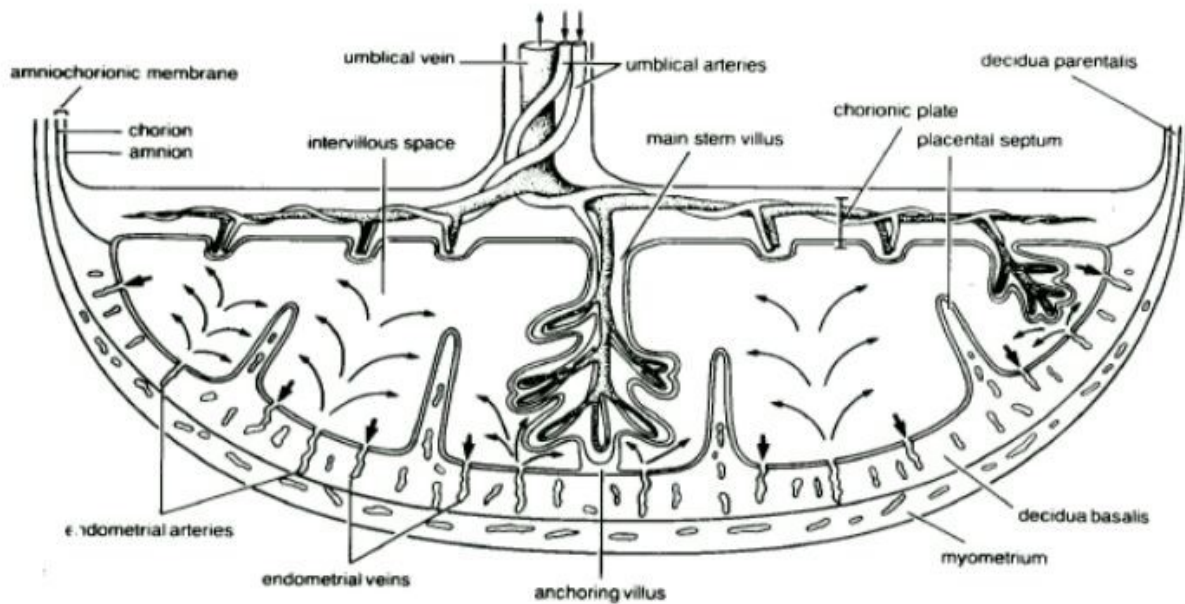


Relationship of the Gestational Sac and Surrounding Decidua. 1-decidua parietalis or vera, 2-uterine cavity, 3-chorion laeve, 4-amnion, 5-decidua capsularis, 6-chorion frondosum, 7-decidua basalis, 8-yolk

Fig2.1: Relationship of the Gestational sac and surrounding deciduas(Moore KL1988)

2.1.2: Structure:

The placenta has two functional components: 1) a fetal portion that develops from the chorion, and 2) a maternal portion formed by the deciduas.



(fig2.2): Fetal and maternal circulation(Moore KL1988).

The fetal component of the placenta consists of the chorionic plate and the chorionic villi that arise from it and project into the intervillous spaces. The maternal component of the placenta is formed by the decidua basalis. This comprises all the endometrium beneath the fetal component of the placenta, except the deepest part, which is called the decidua plate. This layer remains after parturition and is involved in the regeneration of the endometrium during the subsequent menstrual cycle.

The placenta is usually round or discoid. As the villi invade the decidua basalis they leave several wedge-shaped areas of decidual tissue called placental septa. The placental septa compartmentalize the placenta into 15 to 20 segments known as cotyledons. The decidual septa do not completely extend to the chorionic plate, thus allowing maternal blood in adjacent cotyledons to freely communicate.

Certain large branches of chorionic villi (called anchoring villi) arise from the chorionic plate and pass through the intervillous space to attach firmly to the decidua basalis. In addition to anchoring the chorionic plate to the decidua basalis, the anchoring villi give origin to smaller branches called free or floating villi because they float in the blood-filled intervillous spaces). (Devin D 2005).

2.1.3:Placental Maternal-Fetal Circulation:

Maternal blood propelled under maternal blood pressure and heart rate enters the intervillous spaces of the placenta via numerous spiral arterioles and to the maternal circulation via the basal veins. Oxygenated and nutrient-rich fetal blood passes from the fetal capillary bed in the villi to an enlarging system of veins that eventually converge to form a single umbilical vein in the umbilical cord. In the fetal abdomen, the umbilical vein courses cranially towards the liver where it joins the portal sinus (umbilical portion of the left portal vein) to supply the liver. Most of the fetal blood bypasses the liver via the ductus venosus which originates at the portal sinus and terminates in the inferior vena cava or left hepatic vein.

Deoxygenated blood returns from the fetus to the placenta via two umbilical arteries which originate at the right and left internal iliac arteries in the fetal pelvis. The two umbilical arteries divide into numerous radiating branches as the cord inserts in the placenta. Fetal and maternal bloods do not normally come into direct contact. CD/PD are helpful technologies to demonstrate the normal and deranged anatomic vascular relationships of the maternal and fetal circulations. (Moore KL 1988).

2.1.4: Location:

Placental location is described with respect to its relative position on the uterine wall and its relationship to the internal os. The placenta may be described as

predominantly anterior, posterior, fundal, right or left lateral. A placenta that is distant from the internal os may be described as being in a normal location, central, or non previa. A low-lying placenta describes a placenta which appears to extend into the lower uterine segment and is within 1-2 cm of the internal os. A placenta previa describes a placenta which appears to partly or completely cover the internal os. Documentation should include an image showing placental location and the relationship to the internal os.(Devin D 2005).

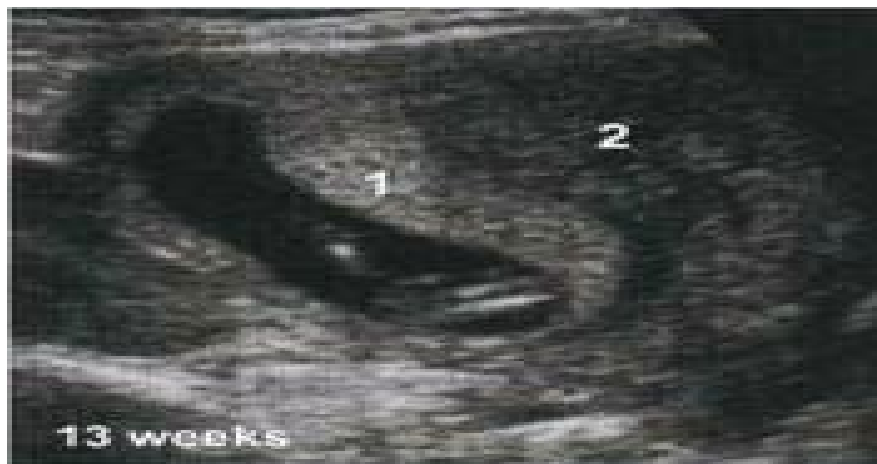

Fig2. 3 Normal Early Placenta

Longitudinal TAS image of the uterus (bladder is empty) shows a normal anterior placenta (1) and a retroplacental FMC (2) (Devin D 2005).

2.1.5 Cord Insertion: The placental cord insertion site should be sought and documented. According to the literature, the placental cord insertion site may be visualized with real-time ultrasound between 50-60% of pregnancies in routine clinical practice and over 95% of cases with colour Doppler. Not surprisingly, the placental cord insertion site is most difficult to assess when the placenta is posterior and in the presence of oligohydramnios. The umbilical cord normally

inserts near the center of the placenta. A cord which appears to insert near the edge of the placenta is called a marginal insertion or battledore placenta and is generally thought to be of no concern. A cord which fails to reach the placenta and inserts in the membranes is known as a velamentous insertion and may complicate the pregnancy especially if the intramembranous umbilical vessels are close to or cross the internal os (a condition known as vasa previa). (Devin D 2005).

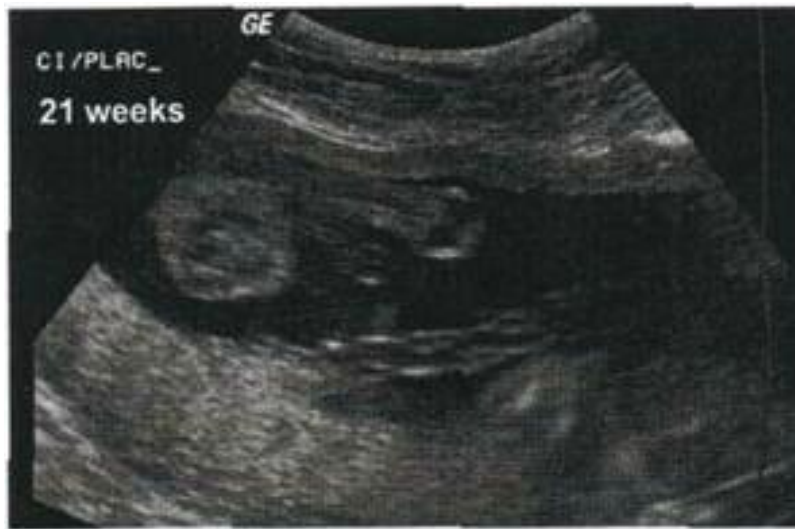

Fig: 2.4 Normal Cord

Insertion Sonogram of the uterus shows a posterior placenta with a central umbilical cord insertion. (Devin D 2005).

2.2: Physiology

2.2.1: Function:

In order to grow and to differentiate into the various tissues that form the placenta, the placenta must be able to metabolize raw materials from the maternal blood pumped into the intervillous spaces. The metabolism of protein in the placenta is largely governed by the demands of fetal and placental growth. No other organ carries out the synthesis of such a diverse group of proteins for such a wide range of purposes. The vast quantities of structural proteins that will be incorporated into proliferating fetal and placental tissues must be derived from maternal sources. Little of the raw material in the massive flow from the mother, however, is in the precise forms required for the different stages of fetal and placental development. Hence, in addition to the placenta's prefabrication of specific proteins for its own purposes it must sort through the available supply, matching the quality and quantity of the material available to the current fetal demand. (Moore KL, 1988).

The production of hormones to regulate the activities of pregnancy is one of the most interesting special functions of the placenta. It is the placenta that bears this responsibility and not the mother or the fetus. From the first days after fertilization, the cells of the trophoblast and their successors in the placenta manufacture a large variety of hormones. The first to be manufactured in appreciable amounts is human chorionic gonadotropin (hCG). As pregnancy proceeds, large amounts of progesterone are synthesized in the placenta. In addition to sustaining the necessary decidual reaction of pregnancy, this hormone serves as a raw material for the production of placental estrogen which in turn act on many organs and tissues of both the mother and fetus. (Moore KL, 1988)

Large amounts of progesterone are produced during the first months of pregnancy by the corpus luteum but the placenta takes over this activity after the third month of pregnancy. The processes influenced by estrogen and progesterone include the synthesis of protein and the metabolism of cholesterol, the functioning of specific organs such as the maternal uterus and breast and the regulation of many

aspects of fetal development. Another hormone produced by the placenta is human chorionic

somatomammotropin (hCS) or human placental lactogen. HCS can be detected in maternal serum as early as the sixth week of pregnancy. It rises steadily during the first Functional Representation of the Placenta Featuring Fetal and Maternal Circulation. (Moore KL, 1988).

In the second trimesters with little variation. HCS has several important physiologic effects on the mother and is referred to as the "growth hormone" of the second half of pregnancy because it promotes good fetal growth by ensuring a good supply of energy to the mother. Maternal HCS serum measurements have been used as a test to measure placental function however it lacks sensitivity and specificity to be of clinical value.. (Devin D 2005).

Among the physiological processes in pregnancy that call for particular precise coordination are those concerned with protecting the embryo from immunological rejection by maternal tissue. One of the many mechanisms that seem to play a part in this task is the non-specific suppression of lymphocytes, the cells that would normally mediate the rejection of a foreign tissue to the host tissue. Another highly specific immunological function of the placenta is to supply the fetus at the end of pregnancy with maternal antibodies of the type known as immunoglobulins. These antibodies summarize the mother's experience of and resistance to various infections and provide the newborn infant with a ready-made prophylaxis against infection until its own immune system can begin to function. (Devin D 2005)

2.3: Pathology

2.3.1: Placental Infarcts:

Small placental infarcts are common and of no clinical significance. Large infarcts (e.g. greater than 10% of the placental volume) are most commonly associated with maternal hypertensive disease and may cause IUGR, fetal hypoxia and fetal demise. Fresh placental infarcts appear as non-specific anechoic spaces in the placenta and are undistinguishable from other anechoic placental lesions. Aging or healing infarcts appear as hyperechoic lesions (more echogenic than the surrounding placental tissue) and may become calcified. (Shaheen F 2003).

2.3.2: Placental Size and Growth:

There is less emphasis nowadays in measurements of the placenta largely because the information is of limited diagnostic value. Thus, the placenta is not routinely measured. The most popular measurement is placental thickness (data on placental area, volume, and weight estimates have all been studied and reported in the literature).

As a guideline, placental thickness should be measured if the placenta appears to be either thick or thin. Placental thickness measurements should be made near the mid portion or center of the placenta with one caliper placed at the amniochorionic surface (chorionic plate) and the second caliper placed at the basal surface perpendicular to the amniochorionic surface. The measurement should exclude retroplacental veins, myometrium, fibroids, and contractions of the uterus that might incorrectly increase the measurement. In a normal pregnancy, placental

Thickness increases with gestational age. As a rule of thumb, the mean thickness of the placenta in millimeters is roughly equal to the gestational age in weeks (e.g. @ 20 weeks, mean placental thickness is 20 mm; @ 28 weeks, mean placental thickness is 28 mm; and @ 36 weeks, mean placental thickness is 36 mm). (Shaheen F 2003)

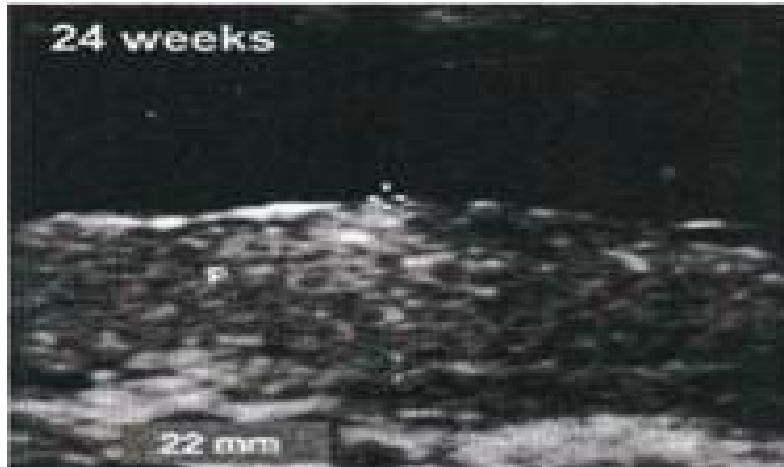

Fig2.5 Placental Thickness Measurement

*Representative image of the posterior placenta shows caliper placement for placental thickness measurement. One caliper is positioned on the amniotic surface of the placenta and the other is positioned at the boundary between the placental tissue and the hypoechoic basal vessels***(Shaheen F 2003).**

False thickening of the placenta may be seen with placental abruption if the retroplacental hematoma has the same echogenicity (isoechoic) as the normal placental tissue. Colour Doppler may be helpful in distinguishing true placental thickening from pseudothickening. With true placental thickening, the normal intraplacental vascular network should be seen from the chorionic to basal surface; with abruption and a retroplacental hematoma, colour will be seen in the placental tissue and be lacking in the hematoma. **(Shaheen F 2003).**

A placental thickness greater than 4 cm is considered abnormal at any gestational age. Less than 2.5 cm at or greater than 35 weeks is considered too thin. The four conditions most commonly associated with placental thickening are:

- a) Diabetes mellitus, especially gestational diabetes.
- b) immune and non-immune fetal hydrops.
- c) Fetal infections (e.g. cytomegalovirus)
- d) Chromosomal abnormalities, especially triploidy

Small or thin placentas are most commonly associated with maternal hypertensive disease, severe IUGR, and severe diabetes mellitus. (Rarely, a thin placenta may be due to a membranous placenta (placenta membranacea or diffusa) which is a thin, poorly functional placenta that covers the entire surface of the chorionic sac. The placenta may also appear unusually thin with severe polyhydramnios as it is stretched over a large surface area of the uterine wall.(Shaheen F 2003).

2.3.3: Placental Tumours:

All primary and secondary tumours of the placenta are rare. The most common tumour of the placenta by far is chorioangioma. Other primary tumours of the placenta include teratoma and choriocarcinoma. Choriocarcinoma is most likely to develop secondary to hydatidiform mole. Melanoma is reported to be the most common tumour to metastasize to the placenta(Devin D 2005).

2.3.4:Developmental Variations:

Variations in the configuration of the placenta is very uncommon however the sonographer should be aware of the most common variants and understand their clinical significance. Only the most commonly encountered forms (succenturiate lobe and placenta circumvallate) will be considered in detail. Other less frequent forms include placenta annularis, placenta membranacea, fenestrate placenta, and placenta spuria.(Devin D 2005).

2.3.4.1 Succenturiate Lobe:

A succenturiate lobe or succenturiate placenta is defined as one or more accessory lobes connected to the main body of the placenta by velamentous connection of the umbilical vessels(vessels traversing the membranes). The pathogenesis of succenturiate lobe is uncertain but it is likely due to a failure of the normal chorionic villi associated with part of the decidua capsularis to atrophy.

Succenturiate placenta has a reported incidence of about 2.5 per 1,000 deliveries. Potential associated symptoms and complications include antepartum hemorrhage (if the velamentous vessels rupture before delivery), vasa previa (velamentous vessels cross the internal os), postpartum hemorrhage and infection (due to retention of the accessory lobe), and perinatal morbidity and mortality (fetal anemia and shock due to rupture of velamentous vessels). (Devin D 2005).

A succenturiate lobe appears as a smaller mass of placental tissue at variable distance from the main placental body (typically very close). The diagnosis can be made accurately when the connecting velamentous vessels are seen between the two islands of placental tissue. Colour Doppler is very helpful to localize the connecting vessels which will show typical fetal umbilical flow. Focal myometrial contractions (FMC) and subchorionic hematomas (SCH) have sonographic characteristics that may mimic a succenturiate placenta with SCH being more

Challenging to distinguish SCH will lack connecting vessels and changes appearance over the course of serial studies. A FMC is a transient event which changes appearance Placenta Membranacea.

Colour Doppler should demonstrate normal intraplacental flow in the succenturiate lobe (colour flow similar to the main placental body) whereas SCH will lack normal colour flow signals (Devin D 2005).

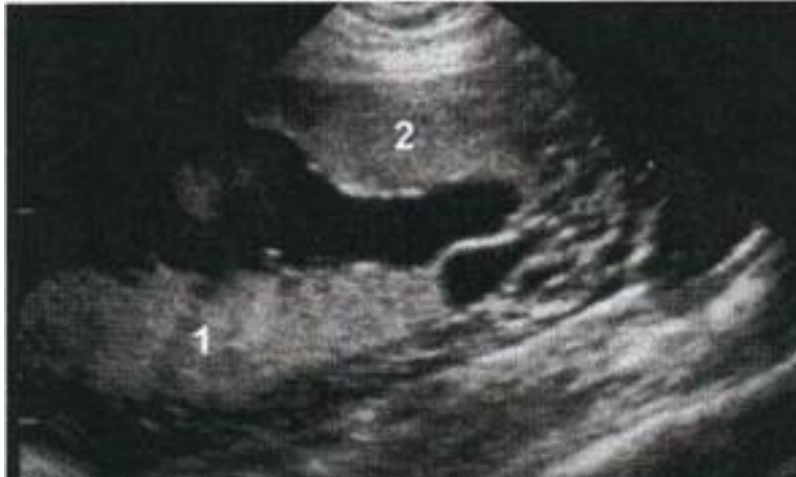

Fig: 2.6 Succenturiate Lobe

Transverse TAS image of the uterus shows a main placental lobe posteriorly (1) and a smaller lobe anteriorly (2). There are numerous vascular channels between the the two lobes(Devin D 2005).

2.3.4.2 :Placenta Membranacea:

Also known as placenta diffusa. Classically, this term describes a thin membranous placenta covering the entire or greater part of the chorioamniotic membrane. The essential feature of the anomaly is that all or most of the chorioamniotic membranes are covered on their outer (endometrial) aspect by functioning chorionic villi. Exceptionally, there may be a focal thickening to form a placental disc, but more commonly the gestational sac is diffusely covered by villous tissue, albeit of varying thickness.(Devin D 2005).

In nearly all instances there is recurrent vaginal bleeding in the late first and second trimesters the consequence of which is either spontaneous abortion or premature labor. The bleeding is due to the fact that the placenta membranacea must also, of necessity, be placenta previa. Fetal survival is usually hampered by prematurity and IUGR. (Devin D 2005).

Antenatal diagnosis of this condition is exceedingly rare but the routine and extensive use of ultrasound in obstetrics will undoubtedly result in more cases being diagnosed prenatally. A review of the ultrasound literature reveals three reported cases since 1976. The diagnosis is established by noting placenta surrounding the entire gestational sac or uterine cavity.

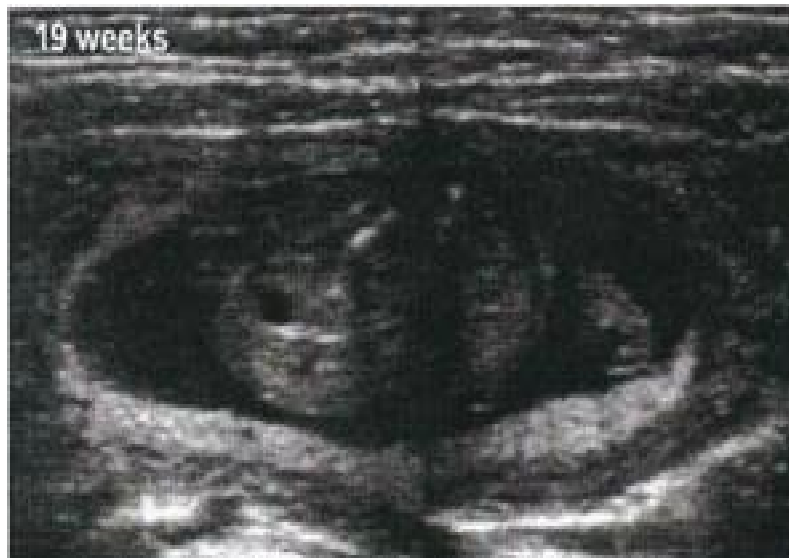

Fig:2.7PlacentaMembranacea

Transverse TAS image of the uterus at 19 weeks gestation shows a thin posterior placenta that covers 60 - 60% of the perimeter of the uterus. (Devin D 2005).

2.3.4.3: Placenta Annularis:

Defines a ring-shaped placenta which surrounds the gestational sac. This type of placenta is considered by some investigators to be a variant of placenta membranacea. It is associated with an increased risk of ante- and postpartum bleeding and IUGR (Devin D 2005).

Placenta Extrachorialis or extrachorial placenta is a placenta in which the membranes and decidua have an abnormal relationship to the amniochorionic

surface of the placenta (resulting in a chorionic surface that is smaller than the basal surface).(Devin D 2005).

2.3.4.4: Placenta circummarginate represents a minor degree of this abnormality and is not of clinical significance (asymptomatic and very unlikely to be recognized with prenatal ultrasound)(Devin D 2005).

2.3.4.5: Placenta circumvallate results in significant raising and folding of the membranes at the edge of the placenta forming a raised ring of tissue. Placenta circumvallate is usually asymptomatic however it may be associated with antepartum hemorrhage (APH) and premature labour. Placenta circumvallate appears as a placenta with a peripheral echogenic Fenestrate Placentaband of tissue near the amniochorionic surface of the placenta representing the abnormally raised and folded amniochorionic membrane.(Devin D 2005).

2.3.4.6: Fenestrate Placenta:

This is an exceptionally rare variant of placental development in which the central portion of a discoidal placenta fails to develop creating a large gap.

Does not appearance to be of significance.

2.3.5: Abnormal Placental Attachment:

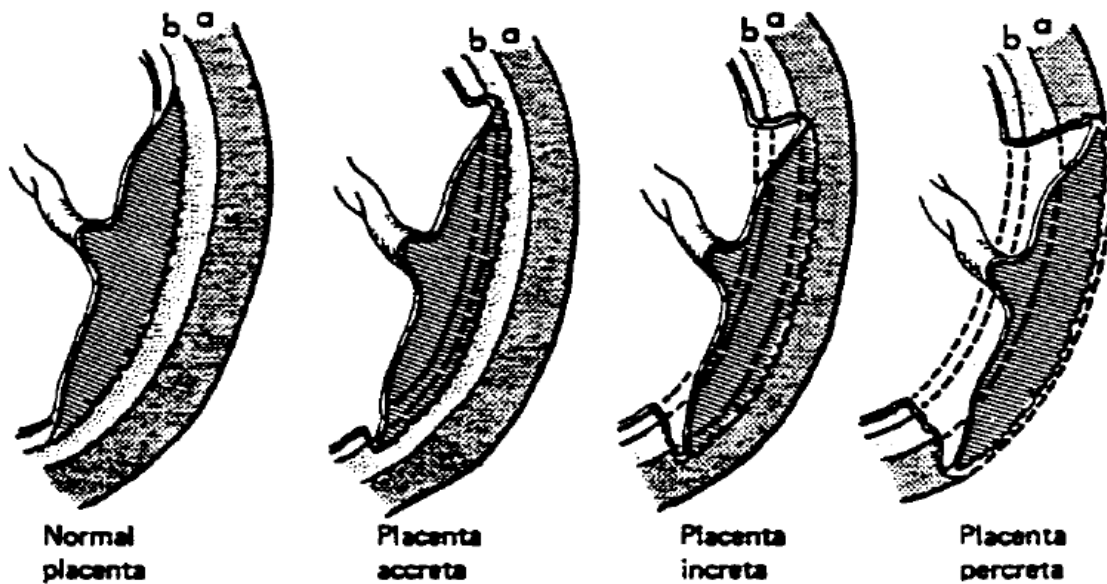
The normal placenta should attach to the decidua basalis and not invade the underlying myometrium. Abnormal placental attachment to the myometrium is a significant maternal risk. This condition varies in severity depending on the degree of invasiveness in the myometrium. Three grades are described based on the depth of penetration of placental tissue:

Placenta accreta: villi invade decidua but not the myometrium

Placenta increta: villi invade myometrium but not the serosa

Placenta percreta: villi invade myometrium and the serosa and can also invade local tissues like the bladder wall.

The true incidence of this condition is unknown and difficult to ascertain. The average incidence is reported to be about 1 in 7,000 pregnancies, with placenta accrete accounting for approximately 60% of cases. Most cases in the ultrasound literature are based on placenta accreta with very few cases describing the sonographic findings associated with placenta increta or percreta. Our discussion with therefore focus on the clinical and sonographic features of placenta accreta. (Devin D 2005).



Abnormal Placental Attachment. a-myometrium, b-decidua basalis.

Fig: 2.8 abnormal placental attachments.(Devin D 2005).

The most important predisposing risk factor for placenta accreta is previous uterine surgery resulting in focal damage to the endometrium and uterine scarring, most notably C-S delivery. Other significant risk factors include advanced maternal age, increasing parity, previous endometritis or history of Asherman's syndrome, and submucous myomas.

Patients are either asymptomatic or may present with antepartum bleeding. In one published series, 5 of 11 patients (45%) had elevated maternal serum alpha-fetoprotein. (Devin D 2005).

Placenta accreta is usually discovered at the time of delivery and may be associated with lack of normal progress during labor (Devin D 2005).

2.3.6: Placenta Previa:

Placenta previa describes a placenta that partially or completely covers the internal os. Three degrees of placenta previa are generally described:

2.3.6.1: Complete or Total Previa

The internal os is completely covered by the placenta. Complete placenta previa may be either symmetric or asymmetric.

A symmetric placenta previa is indicated when the central portion of the placenta is over the os and equal portions of the placenta appears to be attached to the anterior and posterior walls of the lower uterine segment. With asymmetric, complete placenta previa, the placenta is predominantly anterior or posterior in relation to the internal os.(Devin D 2005).

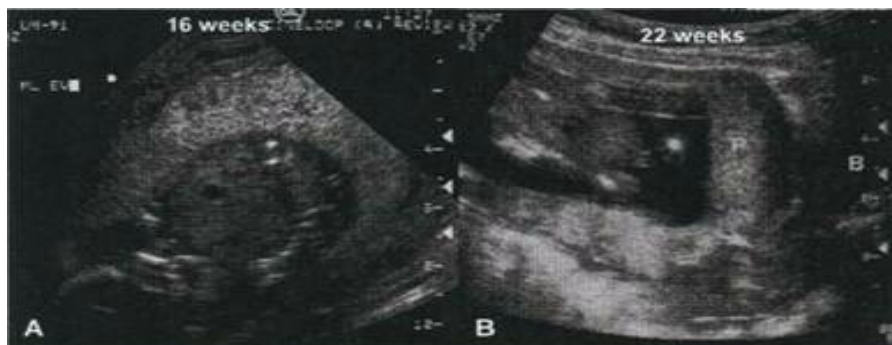

Fig: 2. 9 Central Complete Placenta Previa

A) *Midline EVS image at 14 weeks. B) Midline B) TAS image at 22 weeks. The arrow indicates the approximate location of the internal os*(**Devin D 2005**).

2.3.6.2: Marginal Previa:

The internal os is only partially covered by placenta.

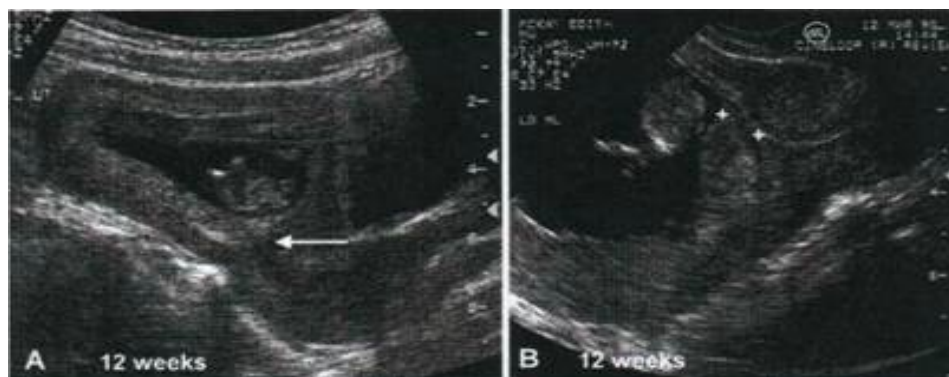


Fig: 2.10 Posterior Marginal Placenta Previa

A) *Midline TAS image with a partially distended bladder shows a posterior placenta that is overlying the area of the internal os. B) Midline EVS image shows the placenta covering the os by a distance of 0 mm. Follow up at 32 weeks showed complete resolution* (**Devin D 2005**).

2.3.6.3: Low-Lying Placenta;

The placenta is close to the edge of the internal os but does not extend over it. Lowlying placentas generally convert to higher positions by 34 weeks gestation. The incidence of placenta previa at the time of delivery is reported to be about 1%. Three factors which increase the relative risk of placenta previa are advanced maternal age, parity, and smoking. Multiparous women are twice as likely to have placenta previa as women delivering for the first time.

A possible reason for this association is endometrial scarring which occurs with increasing age or repeated pregnancies. The scarring is thought to cause inadequate placental blood supply, for which the placenta compensates by becoming thinner and occupying a greater surface area of the endometrium.(Devin D 2005).

A consequence of greater placental surface area attachment is an increased chance for encroachment over the internal os.

The majority of patients with placenta previa present with painless vaginal bleeding near the end of the second trimester or early in the third trimester (antepartum hemorrhaging or APH) however placenta previa may remain asymptomatic until the onset of labour.(Devin D 2005).

The clinical course and management of placenta previa depends on several factors including the onset and severity of APH, the maturity of the fetus, and the degree of placenta previa.

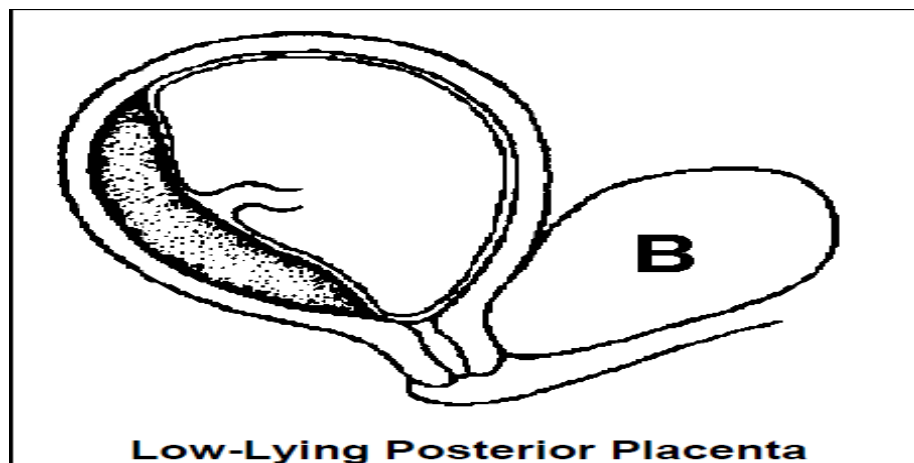


Fig: 2.11 low-lying posterior placenta.(Devin D 2005).

2.4: Ultrasound:

Ultrasound is the imaging modality of choice for the prenatal diagnosis of placenta previa however the sonographer must be aware of technical limitations and common interpretation pitfalls leading to false positive and false negative diagnosis.

The false negative rate for the detection of placenta previa is very low (ultrasound misses the diagnosis of placenta previa), and makes ultrasound a good screening tool to rule out the diagnosis.

The most significant factors contributing to a relatively high false positive rate (ultrasound falsely indicates the diagnosis of placenta previa) include distortion of the lower segment by an overdistended bladder and focal myometrial contractions(Devin D 2005).

Bladder distention Pushes the anterior wall of the uterus posteriorly towards the posterior wall with the net effect of bringing an anterior lower segment placenta artificially closer to the cervix and also compressing the anterior and posterior lower segment walls together and masking the true location of the internal os. For these reasons, when evaluating a placenta that reaches the lower segment of the uterus and appears to be low-lying or previa, the sonographer should re-evaluate the patient after she has voided (postvoid scans). In the majority of cases, the postvoid study will resolve the situation, with most placentas changing in appearance from previa or lowlying to normal (cases that remain suspicious should

be evaluated with endovaginal (EVS) or transperineal (TPS) techniques).(Devin D 2005).

2.4.1: Focal myometrial contractions:

(FMC) can occur at anytime and in any part of the uterus, including the lower segment. The placenta - internal os relationship should not be assessed in the presence of a FMC on the placental wall or lower uterine segment.

Simultaneous contraction of the anterior and posterior lower segment walls (referred to as circumferential or symmetric lower uterine segment contractions) is a little more problematic since it may be more difficult to recognize by the inexperienced sonographer. Keep in mind that the true length of the cervix (internal to external os) should measure approximately 3 cm. If the cervix appears to be significantly longer than 3 cm, the sonographer should question the true location of the internal os since both bladder filling and lower segment contractions can artificially distort the location of the internal os. Less commonly, the presence of a fibroid or subchorionic hematoma in the lower segment may also make it difficult to assess for placenta previa.(Devin D 2005).

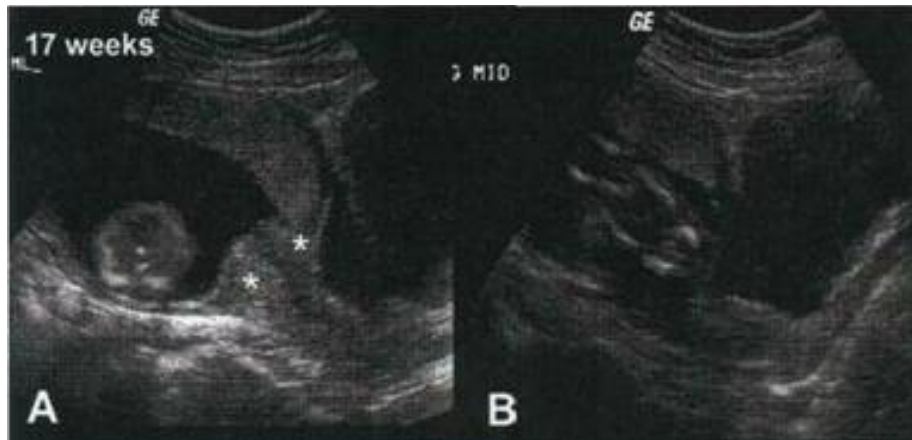

Fig: 2.12 Focal Myometrial Contraction

A) Longitudinal scan of the uterus shows an anterior placenta and a symmetric FMC (*) of the lower uterine segment. B) Same view after dissipation of the contraction. (Devin D 2005).

2.4.2: placental migration or placental retraction

The placenta does not truly migrate; the apparent upward movement of the placenta is due to the development of the lower uterine segment. At 16 weeks gestation, the placenta occupies approximately one-half of the internal surface area of the uterus; however, because the placenta grows more slowly than the uterus, at term it occupies only one-quarter to one-third of the uterine surface area.

The majority of apparent placenta previa and low-lying placentas diagnosed with ultrasound in the first and second trimester will resolve. *Are their reliable sonographic criteria that will reliably predict those placenta previa that will persist and those that will resolve?* Some authors showed that a placenta which overlapped the internal os by 15 mm or more (evaluated with EVS at 18-23 weeks' gestation) was more likely to remain previa at term. The placenta that overlapped the internal

os by 25 mm or more at 20-23 weeks' gestation was incompatible with a vaginal delivery. (JMCarneet al2001)

They initially performed TAS and followed with EVS if the diagnosis was uncertain. They observed that using EVS at 20-23 weeks' gestation to predict persistence of placenta previa to term has a low false-positive rate compared to using it at earlier stages of pregnancy. it show that the incidence of major complications is higher in women with a thick placental.

He defined a "thin" placental edge as measuring less than 1 cm in thickness and or presenting an angle of less than 45 degrees. The thin-edge group had a significantly higher vaginal delivery rate, while the thick-edge group required more frequently emergency delivery by C-section, peripartum hemorrhage, placenta accreta, and preterm delivery. the rate of placental migration was a factor in predicting outcome. (CieminskiA2005)

In his study, EVS was performed at 4-week intervals in women who had been noted at 26 weeks' gestation to have a placenta lying within 3 cm of the internal cervical os, and the rate of placental migration was assessed.

They showed that the mean rate of placental migration in women who were to later require a C-section for related complications (bleeding and malpresentation) was 0.3 mm/wee, while the mean rate of migration in women who had a vaginal delivery or C-sectionfor other indications was 5.4 mm/week. They also made two other important observations: 1) when the placental edge was initially 20 mm or more from the internal os, migration occurred in all cases, and no C-sections were necessary for placenta previa;2) when the placenta overlapped the internal os by 20 mm or more at 26 weeks, all the women required C-section. Further studies are required to verify these reports however it may be possible in the future to predict in the second trimester whichplacentas will be previa at term and which will not. It

may be possible to determine in the second trimester who will need a further sonogram and who will not. (CieminskiA 2005)

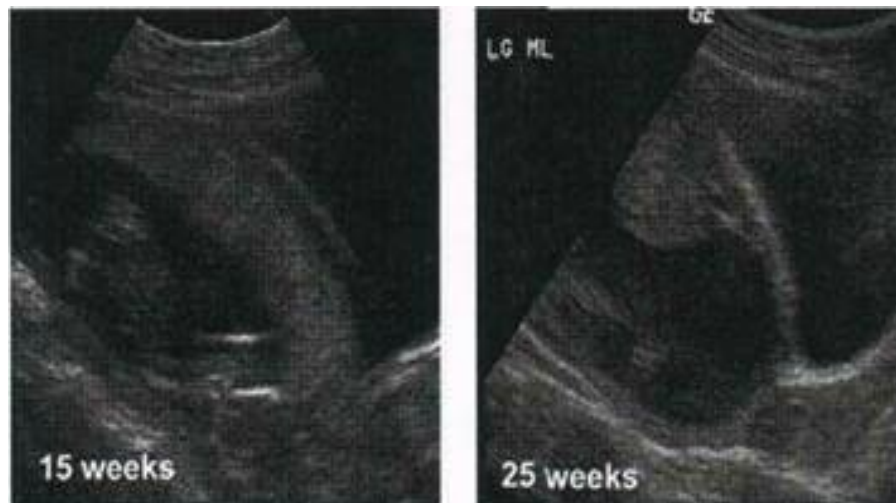

Fig: 2.13Migration

Midline image of the uterus at 15 and 25 weeks gestation shows an upward change in the cervical edge of the placenta.. (CieminskiA 2005)

Complete placenta previa is generally not difficult to diagnose in the second or third trimester with conventional TAS. Partial placenta previas or low-lying placentas are sometimes difficult to diagnose with TAS, especially in the third trimester, largely because the fetus interferes with visualization of the posterior placenta and the internal os region.. (CieminskiA 2005)

When TAS evaluation is non diagnostic, EVS or TPS should be performed. The use of EVS has not been shown to lead to an increase in vaginal bleeding however many investigators prefer the less invasive TPS approach.

The EVS probe should always be carefully and gently introduced in the vagina with the sonographer observing the insertion on the screen with real-time; the tip of the probe should be placed 3 to 4 cm from the external os. The general sentiment is that an EV study does not pose the same threat as a blinded digital examination

which results in direct palpation and manipulation of the cervix. In this circumstance, EVS should be done by a qualified physician in a hospital setting. It is much easier to evaluate a low-lying anterior placenta extending down into the lower uterine segment than a posterior or lateral placenta which may be masked by fetal parts. A posterior placenta will displace the fetal head or buttocks anteriorly and may interfere with descent. In this situation, if the cervical margin of the placenta cannot be adequately visualized with TAS, EVS or TPS should be performed especially if the patient presents with antepartum bleeding..(Devin D 2005).

Ultrasound Evaluationevaluation of the placenta should be a routine part of every second and thirdtrimester ultrasound study as indicated in the American Institute of Ultrasound in Medicine Antepartum Obstetrical Ultrasound Examination Guidelines ("The placentallocation, appearance, and its relationship to the internal cervical os should be recorded").(Carne JM2001).

2.4.3: Technique:

In general, there are no special equipment or transducer considerations (the equipment and transducer deemed most appropriate for the obstetrical ultrasound study may be used). If the system has electronic beam focusing, the focal zone should be adjusted to optimally visualize the placenta.(Carne JM2001).

A posterior placenta is more difficult to visualize in its entirety due to attenuation and shadowing from the overlying fetus. If indicated, positioning the patient in a left or right posterior oblique position may be helpful in better visualizing a posterior placenta.(Carne JM2001).

For the standard transabdominal study (TAS), the bladder should be adequately distended to optimize visualization of the cervix and lower uterine segment and to

show the relationship of the placenta to the internal os. Overdistention of the bladder distorts the appearance of the cervix and lower uterine segment and may lead to the false positive diagnosis of placenta previa. Endovaginal (EVS) or transperineal (TPS) techniques should be performed whenever TAS does not adequately show the relationship of the placenta to the internal os (e.g. due to attenuation by fetal parts or the patient presents with an empty bladder) and there is a high index of suspicion of placenta previa (e.g. patient presents with third trimester bleeding).(Devin D 2005).

Routine evaluation of the placenta with colour Doppler is now favoured to rapidly find the placental cord insertion site and to detect vascular abnormalities in the placenta and the retroplacental uterine wall. This is especially important if the placenta is anterior and appears to be low-lying or previa since the risk of placenta accreta is highest in this situation. An important view is the median lower segment and cervix image which may identify vasa previa associated with velamentous insertion of the cord or succenturiate lobe. Pulsed Doppler spectral waveform analysis of the placenta may be helpful to characterize flow in masses or abnormal appearing vessels.(Devin D 2005).

2.4.4: Echo Texture:

The normal placenta appears as a sonographically uniform structure with mid amplitude echoes (in contrast, the adjacent uterine wall (decidua and myometrium) appear less echogenic or hypoechoic). In the third trimester, the placenta generally appears less homogeneous and may have small anechoic or hypoechoic areas of different pathological etiologies. Calcium deposits are seen in the majority of placentas in the third trimester and appear as high amplitude (white) linear echoes. The fetal or amniochorionic surface of the placenta (generally referred to by authors as the chorionic plate) forms a strong interface with the amniotic fluid.

This surface is very angle dependent (specular reflector) and appears as a bright (white) echo when the sound beam strikes at normal incidence (perpendicular to the interface).(Devin D 2005).

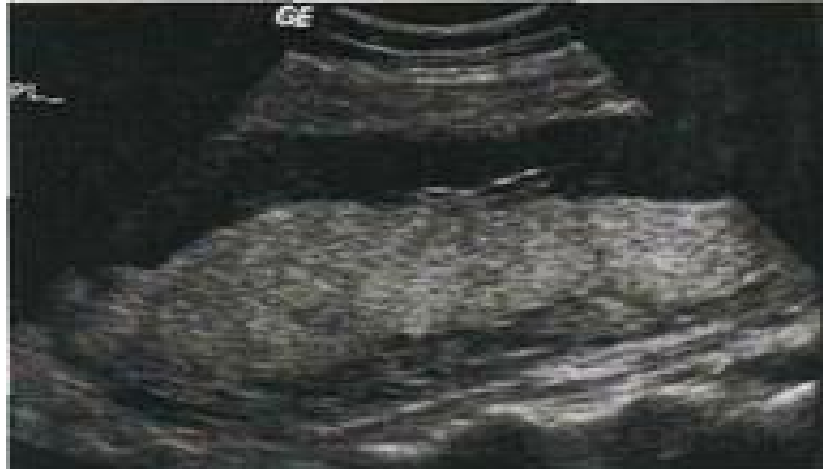

Fig2 -14 Posterior Placenta

Transverse TAS image of a posterior placenta shows the normal hypo echoic uterine wall behind the placenta..(Devin D 2005).

2.4.5: Retroplacental Uterine Wall:

The retroplacental uterine wall consists of the richly vascular myometrium and decidua basalis. These tissues are distinctly hypoechoic in comparison to the placenta. After 18 weeks gestation, the normal anterior retroplacental uterine wall (sometimes referred to as the subplacental complex or the retroplacental space) has an average thickness of 9.5 mm. The sonographic diagnosis of placental accreta depends on this normal hypoechoic zone being invaded by more echogenic villi and appearing thinner or not seen. The endometrial veins in the decidua basalis may be quite dilated and appear as irregular, tubular spaces especially when the placenta is posterior (probably due to diminished venous drainage when the patient is supine and the weight of the uterus on the posterior uterine wall impedes venous flow). Other retroplacental abnormalities include hematomas associated with

abruption of the placenta and fibroids which must be distinguished from focal myometrial contractions.(Devin D 2005).

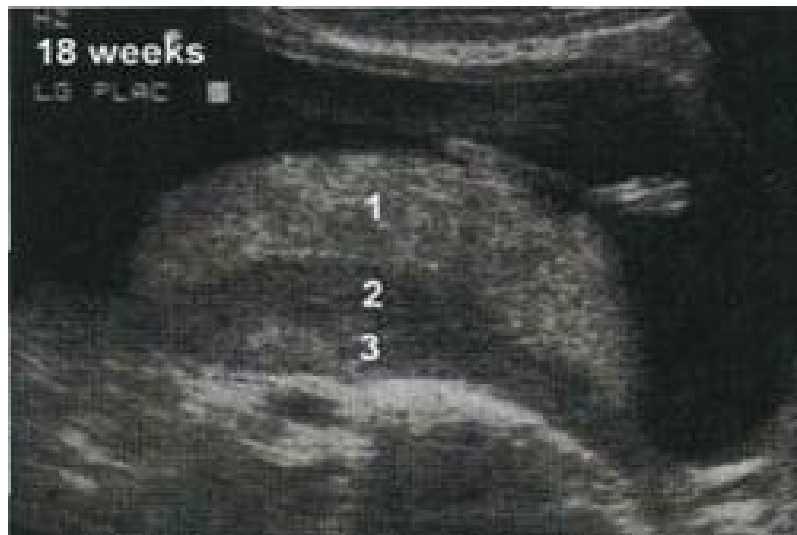

Fig2.15Retro placental Complex

Sagittal TAS image of a posterior placenta (1) shows a prominent retroplacental complex and the "end" of a FMC (3).. (Devin D 2005).

2.4.6: Placental Grading:

Calcium deposition in the placenta is a normal process of placental aging or maturation which occurs at different rates in normal pregnancies. Sonographically, macroscopic areas of placental calcifications appear as hyper echoic (white) echo densities in different areas of the placenta, with larger areas of calcification exhibiting shadowing. Calcium is deposited primarily along the basal surface and placental septa. Macroscopic and sonographic evidence of placental calcification is not evident until the third trimester. More than 50% of placentas show some sonographic evidence of calcification after 33 weeks' gestation however about 20% of normal term placentas have no macroscopic or sonographic evidence of calcification. Previously, investigators found it useful to assign placentas a numerical grade (0 to 3) based on the degree of calcification however such grading

Schemes have proven to be of limited value in clinical practice in predicting fetal maturity, fetal well being, or perinatal outcome. Although of limited clinical value, I recommend you learn the basic facts about placental grade, especially the features of a grade 3 placenta and the significance of early or premature appearance. (Devin D 2005).

These placentas show an irregular amniochorionic surface (chorionic plate) with calcification extending along the cotyledenal division from the chorionic plate to the basal surface. The grade 3 placenta may also have larger areas of calcification that produce shadowing and the placental parenchyma may contain hypoechoic or anechoic areas.(Devin D 2005).

Grade 3 placentas are the most heavily calcified and are not seen before 36 weeks gestation in normal pregnancies. Only about 15% of normal term pregnancies are grade 3 placentas. A greater percentage of Grade 3 placentas are seen with increasing gestational age in pregnancies >36 weeks however a grade 3 placenta does not predict fetal lung maturity. The appearance of a Grade 3 placenta before 36 weeks gestation should raise concern for later development of IUGR, maternal hypertension and fetal distress (these conditions have been associated with premature placental senescence characterized by heavy placental calcification). . (Devin D 2005).

Anechoic and Hypoechoic Placental Lesions Small, anechoic and hypoechoic lesions are commonly seen in the placenta, especially in the 3rd trimester. These anechoic and hypoechoic placental lesions have been referred to by different authors as “sonolucencies”, “lucencies”, and “holes”. Although sonographically alike, these lesions represent different pathologies including subchorionic fibrin deposits, intervillous thrombosis, perivillous fibrin deposition, fresh infarcts, subchorionic maternal venous lakes, and septal cysts. These lesions may be round, ovoid, or linear and are typically less than 2 cm in diameter. Occasionally, sludge-

like blood flow can be seen in some lesions (e.g. subchorionic venous lakes) on real-time imaging and Doppler.

The only significant fact pertaining to these placental lesions is that they may be associated with elevated maternal serum alpha-fetoprotein values and an otherwise normal fetus. If the fetus appears structurally normal, the placenta should be evaluated carefully for evidence of placental bleeding, masses and these lesions. . (Devin D 2005).

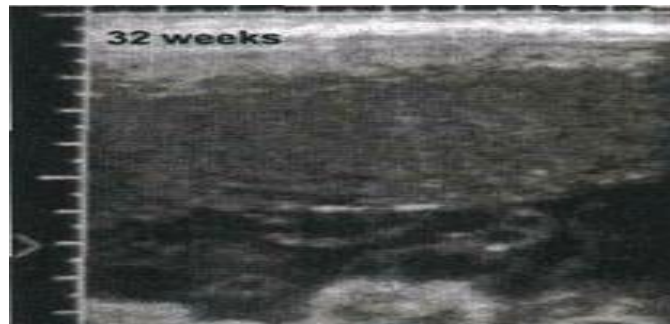

Fig2.16 Grade 0 Placenta

Linear array image of an anterior placenta at 32 weeks gestation shows no evidence of placental calcification. . (Devin D 2005).

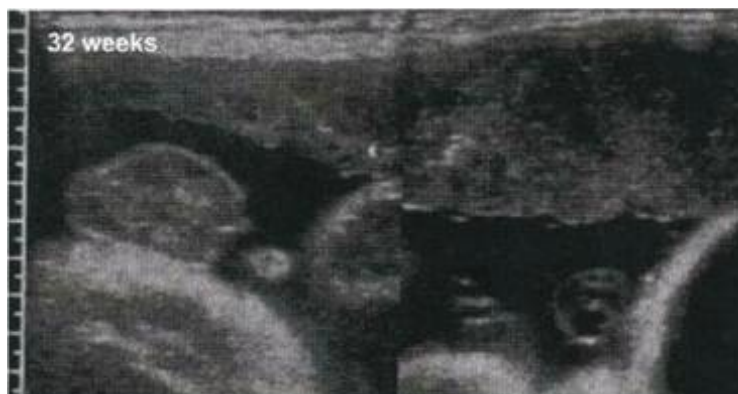

Fig2.17 Grade 1 Placenta

Axial section of the uterus shows an anterior placenta at 32 weeks gestation with evidence of parenchymal calcification but no evidence of basal calcification (maternal surface of the placenta). (Devin D 2005).

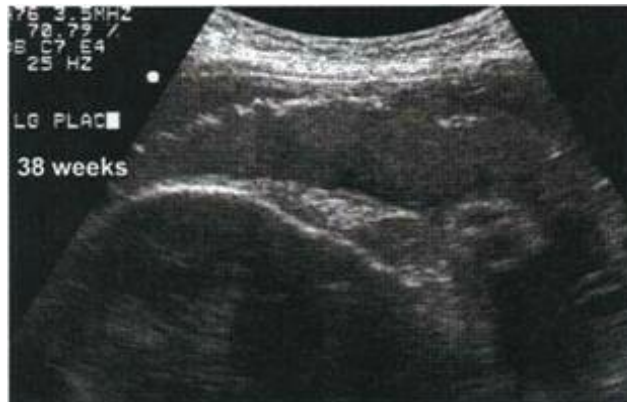

Fig2.18 Grade 2 Placenta

Anterior placenta at 38 weeks gestation shows calcification of the basal surface of the placenta consistent with a grade 2 classification. (Devin D 2005).

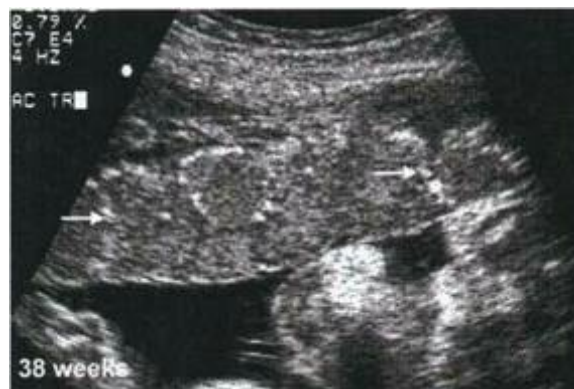

Fig2.19 Grade 3 Placenta

TAS image of an anterior placenta shows calcification of the placenta extending from the maternal to fetal surface, (arrows). (Devin D 2005).

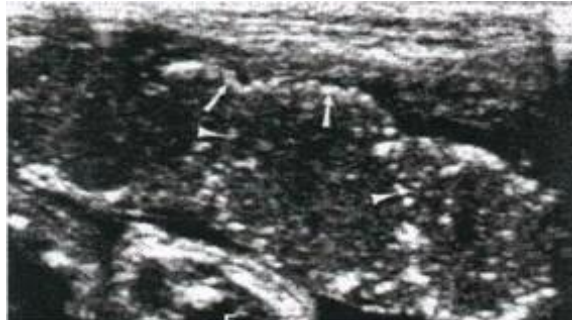

Fig2.20 Grade 3 Placenta

Representative TAS image of the placenta at 39 weeks gestation shows calcification of the placenta extending from the maternal to fetal surface and defining the cotyledon.(Devin D 2005).

2.4.7:Ultrasound/Doppler

Prenatal sonographic diagnosis of placenta accreta is usually in the late second or third trimester based on the appearance of the placental interface with the anterior uterine wall and distended bladder. In patients with previous C-S delivery, a low-lying gestational sac on a scan at 10 weeks or earlier suggests the possibility of placenta accreta. A low position of the gestational sac can occur in other clinical situations including abortion in progress, cervical pregnancy, and normal pregnancy..(Devin D 2005).

Placenta AccretaMost cases of placenta accreta are associated with an anterior low-lying placenta or anterior placenta previa. The characteristic sonographic and Doppler features include:

- Loss or notable thinning of the normal hypoechoicmyometrial layer beneath the placenta

- Large placental vascular spaces - The retroplacentaldecidual veins may be markedly enlarged and appear as irregular anechoic pockets. On CD, the enlarged veins may exhibit unusually intense or turbulent blood flow indicating abnormal Uteroplacental lacunar flow.
- Loss of the hyperechoic uterine serosa-bladder interface
- extrauterine or intravesical masses representing hematoma formation.(Devin D 2005).

Scanning Flag should be highly suspicious of placenta accreta in patients with an anterior placenta extending into the lower segment (low-lying or previa) especially in patient with previous C-S delivery.(Devin D 2005).

2.5 Previous Study

Study 1;

Association of placenta previa with repeat cesarean section in Sudan and Saudi Arabia2014-2015 done by;

Abdelraheem Met al (2016) the total number of deliveries in hospitals at Omdurman city in Sudan duringthestudy period was 200 pregnant women. Out of them 87(43.5%)delivered vaginally, 66 (33.0%(delivered by CSsubdivided into four groups, one CS 22(11%), two CS 29(14.5%) three CS 13(6.5%) more than three CS 2(1%)and 47(23.5%) were prime gravida, compare with 200 pregnant

women in hospitals at Najran city in KSA 108 (54%) delivered vaginally, 64 (32.0%) delivered by CS, one CS 26 (13%), two CS 23 (11.5%) three CS .

The prevalence of PP in this study increased with increasing number of previous CS, and was associated with adverse feto-maternal outcome. This study provides a reason to reduce elective CS and encouraging vaginal birth after CS (VBAC). To enhance patient safety, it is important that the delivery performed in an operating room by an experienced obstetric team that includes an obstetric surgeon, with other surgical specialists, such as urologists, general surgeons, and gynecologic oncologists, available if necessary.

Improved outcomes have been demonstrated when women with PP give birth in specialized tertiary centers. 12 (6%) more or than three CS 3 (1.5%) and 28 (14%) were prime gravid

Study2; Placenta previa is a common obstetrical problem associated with considerable maternal & fetal morbidity and mortality. Done by; Sitana Alamin Butran Abdalla - Sudan University M.Sc degree 2013.

From the total of 48 pregnancies with history of cesarean section, 12 pregnancies (25%) had one cesarean section, 14 pregnancies (29.2%) had two cesarean section, 10 pregnancies (20.8%) had three cesarean section, 10 pregnancies (20.8%) had four cesarean section, and 2 pregnancies (4.2%) had five cesarean section. The percentage of the placenta previa associated with the number of cesarean section was 0%, 78%, 100%, 70% and 50% respectively

Conclusion:

In conclusion, this study demonstrates an elevated risk for placenta previa among women with prior cesarean delivery. Moreover, this risk increases dramatically with increasing number of prior cesarean deliveries and maternal age. This study provides yet another reason for reducing the primary cesarean delivery rate and for advocating vaginal birth for women with prior cesarean delivery.

Early diagnosis of placenta praevia, and identification of risk factor such as previous caesarean section, may help in better outcome by reducing the fetomaternal complications.

Study3

Frequency of Placenta Previa and Maternal Morbidity Associated with Previous Cesarean Delivery*Done by:

Nankali N et al (2014)

Results:

Among 2696 Women, 98 cases had P.P (3.63%). The mean age was 30 years, 76.5% (75 cases) had gravidity 2 and 3 and 87.8% (86 cases) had parity 1 - 3. Anterior location of placenta was 44.9% while posterior was 55.1%. 48% were complete P.P, 32.7% low lying P.P, 13.3% marginal P.P, and 6% Partial P.P. 26.5% of

patients had history of abortion. 55.1% of patients had male fetus. There was an increase in frequency of placenta previa with just one previous C-section (74.5%). Frequency of accreta P.P 32% (n = 7), increta (14.3%, n = 3) and percreta 28% (n = 6). Among those who underwent emergency hysterectomy (21 cases) 23.8% cases had no abnormal placentation. 30.6% of newborns had birth weight < 2500 g. Conclusion: we concluded that patients with history of one previous cesarean delivery had more Placenta previa and need to hysterectomy were more than those with history of 2 and 3 previous cesarean delivery.

Conclusion

Findings of this study showed that frequency of placenta previa was 3.63% among patients with history of previous C-cesarean delivery. 74.5% of patients with placenta previa had history of one previous C-section and the rate of the need for hysterectomy in these patients was 47.6%. The most common type of abnormal placentation was accreta, percreta and increta respectively.

Chapter Three

Materials and Methods

3.1 :Materials:

3.1.1:Machine used Ultrasound machines with transducer frequency 3.5 MHz, our examinations were done by:

MINDRAY ultrasound machine. Model DP 2200. 2008 – 05 made in Germany with convex transducer 3.5 MHz.

FUKUDA 4100 ultrasound machine made in Japan .1995 with Convex transducer 3.5 MHz.

coupling gel and TV card with 16 bit to capture the ultrasound image using the personal computer.

3.2: Methods:

This is a descriptive cross-sectional study conducted at the department of obstetrics and gynecology in Turkish hospital, Khartoum city. It was conducted during the period from January 2016 to May 2016.

In the antenatal clinic as per protocol 50 pregnant women were selected for the study. The inclusion criterion was a pregnant lady in their second and third trimester of pregnancy. The doctor and staff nurse on duty were trained to enter the data in a questionnaire. Then ultrasound scan was done for all selected women for foetal wellbeing and placental localization. All women with or without symptoms of PP showing placental implantation in lower uterine segment on ultrasound were documented. Then women with PP were further examined for their detailed obstetrical history- especially the history of previous CS, parity and - maternal age and socioeconomic status. After completion of the 5 months, data regarding the detailed obstetrical and surgical history were recorded in a questionnaire and analyzed using SPSS software.

3.3: Sample Characteristics

In the antenatal clinic 50 pregnant women in their second and third trimester of pregnancy were selected for the study all women were have previous CS. 32 patients were have placenta previa .

3.4: The inclusion criterion:

Any pregnant patients with history of cesarean section attending the hospital in that period.

3.5: The exclusion criteria:

- Placental abruption.
- Multiple gestations.

3.6: Ethical consideration

.A written permission is issued and taken from the hospital director; also anyone in the study signed an agreement to be one of the study objects after had been told about what should be done for her.

To collect the suitable data for the study; personal information from any patient is written in the data collection sheet as well as the results .This includes the following: General information, Clinical information and Ultrasound findings. See the append

3.7: Ultrasound technique of the placenta previa:

The examination begins with the patient in the supine position. Scans are performed in the sagittal and transverse planes from the anterior approach using the bladder as acoustic window. In general, there are no special equipment or transducer considerations (the equipment and transducer deemed most appropriate for the obstetrical ultrasound study may be used). If the system has electronic beam focusing, the focal zone should be adjusted to optimally visualize the placenta.

A posterior placenta is more difficult to visualize in its entirety due to attenuation and shadowing from the overlying fetus. If indicated, positioning the patient in a left or right posterior oblique position may be helpful in better visualizing a posterior placenta.

For the standard transabdominal study (TAS), the bladder should be adequately distended to optimize visualization of the cervix and lower uterine segment and to show the relationship of the placenta to the internal os. Overdistention of the

bladder distorts the appearance of the cervix and lower uterine segment and may lead to the false positive diagnosis of placenta previa. Endovaginal (EVS) or transperineal (TPS) techniques should be performed whenever TAS does not adequately show the relationship of the placenta to the internal os (e.g. due to attenuation by fetal parts or the patient presents with an empty bladder) and there is a high index of suspicion of placenta previa (e.g. patient presents with third trimester bleeding).

Routine evaluation of the placenta with colour Doppler is now favoured to rapidly find the placental cord insertion site and to detect vascular abnormalities in the placenta and the retroplacental uterine wall.

3.8: statistics:

Finally these data was tabulated, described, represented and analyzed using SPSS version 16 ,putting in mind that the p value is significant less than 0.05 using the chisquare test to know the significance & correlation coefficient between two suitable variables . The results of this analysis put in a scientific frames and facts from which the medical decision and recommendations is created.

Chapter four

Results

Table 4-1 shows the distribution of the maternal age and gestational age.

maternal age/ gestational age

	N	Minimum	Maximum	Mean	Std. Deviation
Age	50	23	45	33.54	5.167
GA	50	24	41	32.40	4.540

Table 4-2 represent the distribution of the Number of C.S

	Frequency	Percent
1-2	26	52.0
3-4	21	42.0
4-5	3	6.0
Total	50	100.0

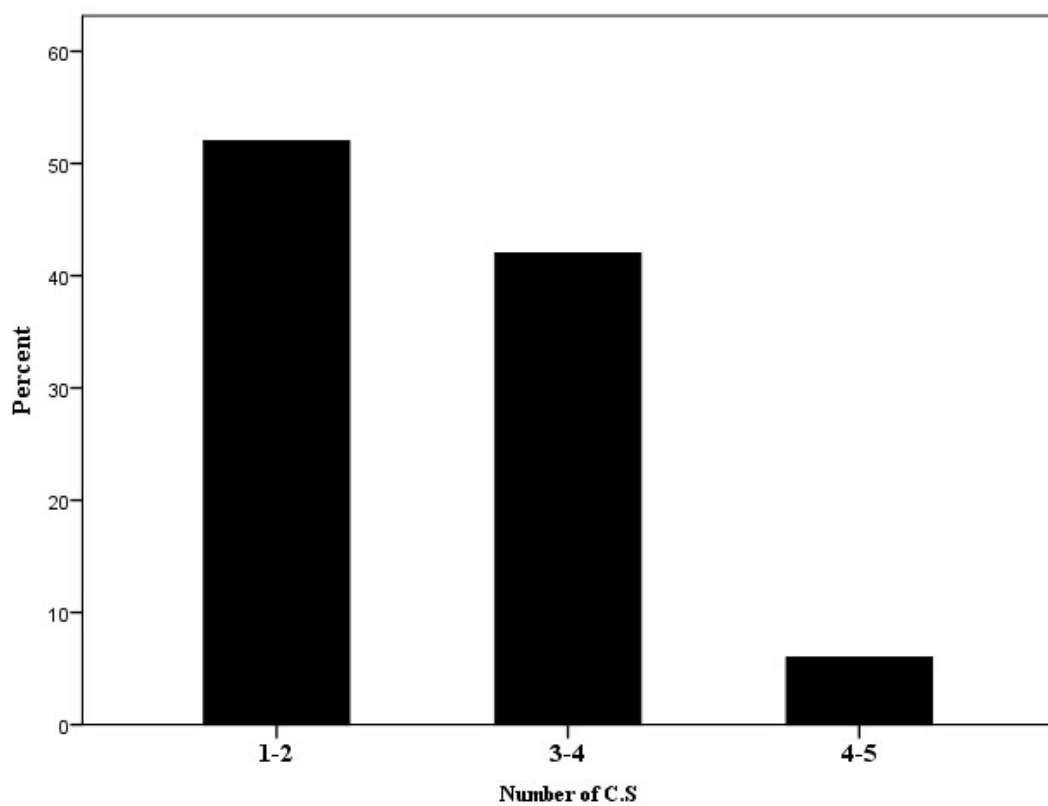


Figure (4-1) shows the distribution of Number of CS.

Table 4-3 shows the distribution of Placenta Location

Placenta Location		
	Frequency	Percent
Upper Placenta	19	38.0
Minor Degree Placenta Previa	16	32.0
Major Degree Placenta Previa	15	30.0
Total	50	100.0

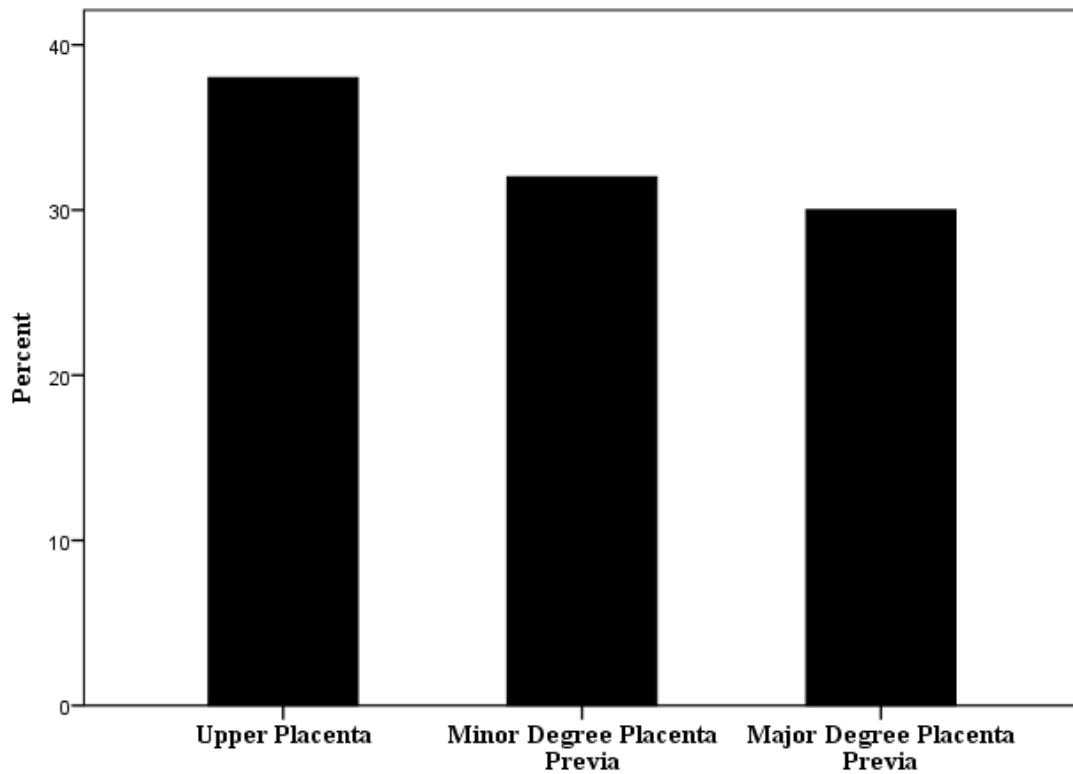


Figure 4-2 shows the **distribution of Placenta Location**.

Table 4-4 shows the distribution of Parity
Parity

	Frequency	Percent
1 - 2	9	18.0
3 - 4	15	30.0
5 - 6	19	38.0
7 - 8	5	10.0
9 -10	2	4.0
Total	50	100.0

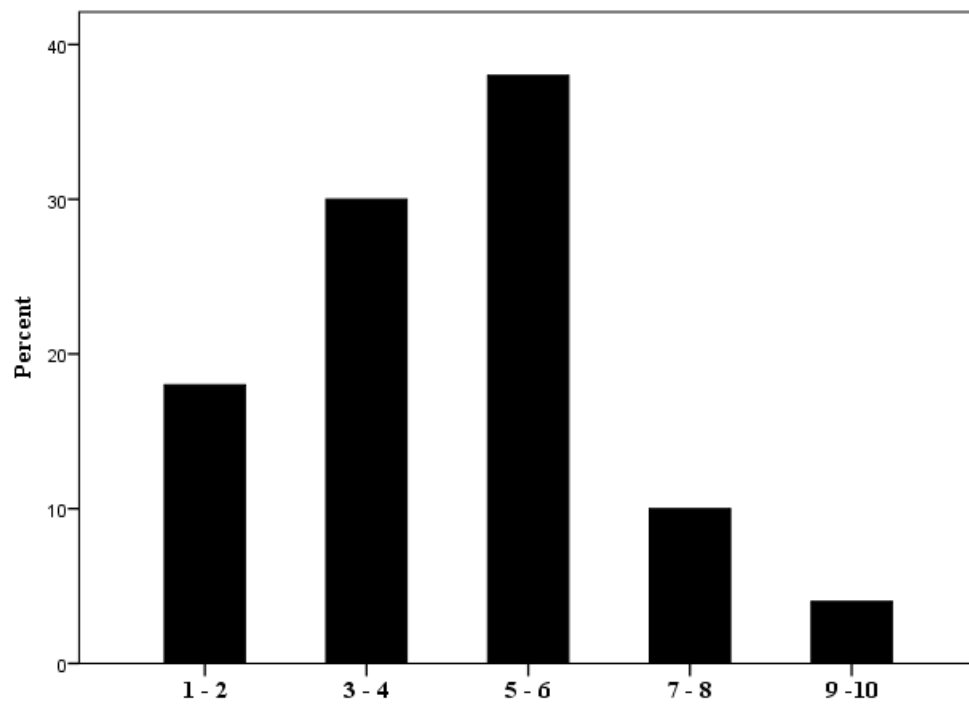


Figure 4-3 shows the distribution of Parity.

**Table 4-5 shows the distribution Of Number of C.S * Placenta Location
Cross tabulation.**

			Placenta Location			Total
			Upper Placenta	Minor Degree Placenta Previa	Major Degree Placenta Previa	
Number of C.S	1-2	Count % within Number of C.S	15 57.7%	6 23.1%	5 19.2%	26 100.0%
	3-4	Count % within Number of C.S	3 14.3%	10 47.6%	8 38.1%	21 100.0%
	4-5	Count % within Number of C.S	1 33.3%	0 .0%	2 66.7%	3 100.0%
Total		Count % within Number of C.S	19 38.0%	16 32.0%	15 30.0%	50 100.0%

Table 4-6 shows the distribution of Parity * Placenta Location Crosstabulation

			Placenta Location			Total
			Upper Placenta	Minor Degree Placenta Previa	Major Degree Placenta Previa	
Parity	1 - 2	Count	9	0	0	9
		% within Parity	100.0%	.0%	.0%	100.0%
	3 - 4	Count	4	2	9	15
		% within Parity	26.7%	13.3%	60.0%	100.0%
	5 - 6	Count	6	8	5	19
		% within Parity	31.6%	42.1%	26.3%	100.0%
	7 - 8	Count	0	4	1	5
		% within Parity	.0%	80.0%	20.0%	100.0%
	9 - 10	Count	0	2	0	2
		% within Parity	.0%	100.0%	.0%	100.0%
Total		Count	19	16	15	50
		% within Parity	38.0%	32.0%	30.0%	100.0%

Chapter Five

5.1 Discussion:

Placenta previa is a common obstetrical problem associated with considerable maternal & fetal morbidity and mortality.

This study has been conducted in Turkish hospital, Khartoum city to study the placenta previa using ultrasound , from the first January 2016 to May 2016. Fifty patients (n=50) were selected to be the sample unit in this study. Table (4-1) shows the majority of the patients in this study aged between 23-45years, and the gestational age between 24- 41 weeks.

The table number (4-2) shows the distribution of number of CS among the studied patients, and it indicates that (52%) of the patients had 1-2 CS, (42%) had 3-4 CS, while only (6%) had 5-6CS.

Table number (4-3) shows the distribution of placental location (38%) of selected patient had upper placenta, (32%) had minor degree placenta preiva and fortunately only (15%) had major degree placenta preiva.

Table 4-4 shows the distribution of Parity, (18%) of patient included in the study were Para 1-2, (30%) were Para 3-4, (38%) were Para 5-6, (10%) were Para 7-8 and (2%) were Para 9-10.

Table 4-5 shows the distribution Of Number of C.S placenta location Cross tabulation. in the total of 26 (100%) patient which represent 1-2 previous CS 15 (57.7%) have upper placenta, 6 patient (23.1%) have minor degree placenta preiva and 5 patient (19.2%) have major degree placenta preiva. Also 21 (100%) patient who have 3-4 previous CS 3 patient (14.3%) have upper placenta 10 patient (47.6%) have minor degree placenta preiva and 8 patient (38.1%) have major degree placenta preiva. In spite of this in patient have 4-5 3 (100%) previous CS 1 (33.3%) have upper placenta and 2 patient (66.7%) have major degree placenta preiva.

Table 4-6 shows the distribution of Parity * Placenta Location Cross tabulation. 9 patients who have Para 1-2 all of them have upper placenta, in total of 15 patient who is Para 3-4 4 patient (26.7%) have upper placenta 2 patient (13.3%) have minor degree placenta preiva and 9 patient (60%) have major degree placenta preiva, in patient Para 5-6 total of 19 patient 6 (31.6%) have upper placenta 8 patient (42.1%) have minor degree placenta preiva and 5 patient (26.3) have major degree placenta preiva, there is 5 patient were Para 7-8 4 patient (80%) have minor degree placenta preiva and 1 (20%) patient have major degree placenta preiva and all of only 2 patient who were Para 9-10 have minor degree placenta preiva.

In brief in the total of the studied patients ($n = 50$), there is Linear equation show that there is increase incidence of placenta previa as the number of cesarean section increased.

This study showed that, the overall incidence of placenta praevia among patients seen in Turkish hospital, Khartoum city is (62%), it is high among patients with scared uterus. From the findings of this study, showed a significantly high association between placenta previa and multiple cesarean section, similar studies done by Singh and et al (1981) and Gilliam and et al (2001) reported there is an association between previous caesarean sections and subsequent development of placenta previa and showed increase in the frequency of placenta previa with increasing number of cesarean section. I yoke et al (2014) argued that women who have one previous caesarean

section face a markedly increased risk of repeat caesarean section similar to our finding which recorded multiple placenta previa resulting to mode caesarean section deliveries from one to more than it. In the previous study from Sudan and Saudi Arabia of 400 deliveries 125 women had placenta previa the percentage of placenta previa which were embedded increased from 10.25% in women with no previous cesarean section, to 14.5% in women who had two or more caesareans the same findings of the percentage of placenta previa which were increased from 4.1% in women with no previous section, to 60% in women who had three or more caesarean section was reported by Saki et al (1998) in their study that done in Saudi Arabia and Ziadeh (1998) from Jordan. Current study showed relation between the placenta previa after one caesarean section and risk of placenta previa increased with repeat caesarean section disagreed with Adeela et al (2012) who recorded the previous one caesarean section did not increase the frequency of placenta previa. Increasing number of scars, was associated with placenta previa.

The incidence of placenta previa was significantly higher than the incidence of normal placenta location which confirm the association of previous cesarean section with placenta previa. . There is strong association between maternal age and the incidence of placenta previa in which the incidence increase as maternal age increased.

From the statistical study and analysis that done , it was found that there is a relationship between previous number of caesarean section and parity , from one side ; and from the placenta preiva on other side ,this done by using χ^2 test put in mind that the errorif less than 0.05 is significance .

5.2 Conclusion:

This study concludes that there is an elevated risk for placenta previa among women with prior cesarean delivery. Moreover, this risk increases dramatically with increasing number of prior cesarean deliveries and maternal age. This study provides yet another reason for reducing the primary cesarean delivery rate and for advocating vaginal birth for women with prior cesarean delivery.

Early diagnosis of placenta praevia, and identification of risk factor such as previous caesarean section and good maternal counseling, may help in better outcome by reducing the fetomaternal complications.

5.3 Recommendation:

The prevalence of placenta previa in this study increased with increasing number of previous caesarean section, and was associated with adverse fetomaternal outcome. From This study I recommended that:

- Reduce primary elective caesarean section.
- Encouraging vaginal birth after caesarean section (VBAC).
- It is important that the delivery performed in an operating room by an experienced obstetric team that includes an obstetric surgeon, with other surgical specialists, such as urologists, general surgeons, and gynecologic oncologists, available if necessary to enhance patient safety.

- To Improved outcomes the patient with placenta previa should h give birth in specialized tertiary centers
- In next study I recommended to increase sample size to increase chance for study more patients.

5.4 References:

Singh PM, Rodrigues C, Guota AN.(1981) Placenta previa and previous cesarean section. *ActaObstetGynaecolScand*; 292:371-2.

Abdelraheem M 1, Qurashi M Ali 2, Kamaleldin B(2016) 3 Association of placenta previa with repeat cesarean section inSudan and Saudi Arabia2014-2015 *Journal of Medical and Dental Science Research Volume 3~ Issue 2pp: 07-11*

AbuHija AT, ElJallad F, Ziadeh S. (1999) Placenta praevia, effect of age, gravidity, parity and previous caesareansection. *GynecolObstet Invest*; 47: 6-8.

Adeela Bashir, HumairaNazJadoon, Aziz-un-NisaAbbasi. (2012) Frequency of Placenta Previa in Women with History of PreviousCaesarean and Normal

Bender S. (1954) Placenta previa and previous lower segment cesarean section. SurgGynecolObstet; 98:625-7.

Brenner WE, Edelman DA, Hendricks CH. (1978) Characteristics of patients with placenta praevia and results of "Expectant management". Am J ObstetGynecol; 132: 180-9.

Carne JM, VandeHof MC, Dodds L, Armson BA, Liston R.(2001) Maternal complication with placenta praevia. Am J Perinatal; 17: 101-5.

Cieminski A, Dlugolecki F. (2005); Relationship between placenta previa and maternal age, parity and prior caesarean deliveries. Ginekol Pol 76(4):284-

Cunningham, G, Leveno, KL, Bloom, SL, Hauth, JC, Gilstrap III, LC and Wenstrom, KD. (2005) Williams Obstetrics. 22nd Edition, McGraw-Hill, New York.

Devin Dean (2005). Ultrasonography Of abdomen and superficial scanning .Part1. Module the Berwin institute of diagnostic medical ultrasound; Lunenburg Canada: P. 11-13.

Gilliam M, Rosenberg AF (2002). The likelihood of placenta previa with greater number of cesarean deliveries and higher parity. ObstetGynecol; 99:976-80

Hendricks MS, Chow YH, Bhagavath B, Singh K (1999) .Previous cesarean sections and abortions as risk factors for developing placenta previa. J ObstetGynecol Res ; 25:137-42.

Hossain GA, Islam SM, Mahmood S, Chakraborty RK, Akhter N, Sultana S (2004). Placenta previa and its relation with maternal age, gravidity and cesarean section. Mymensingh Med J; 13:143-8.

James D (2001). Bleeding in pregnancy. In: Johnson M, Chang A, Neilson J, editor.

Moore KL, (1988) the Developing Human: Clinically Oriented Embryology, 4th Ed., and W.B. Saunders Co.).

Nasreen F. Incidence, causes and outcome of placenta previa. JPostgrad Med Inst (2003); 17:99-104.

Nisenblat V, Barak S, Griness OB, Degani S, Ohel G, Gonen R.(2006) Maternal Complications Associated With Multiple Caesarean Deliveries. ObstetGynecol; 108:21-26.

Plascencia, JL, Ochoa, FI, Zuniga, MA and Karchmer, S. (1995) [Placenta Praevia/Accreta and Previous Cesarean Section. Experience of Five Years at the Mexico National Institute of Perinatology]. Ginecología y Obstetricia de México, 63, 337-340

Shaheen F (2003). Placenta praevia 2 year analysis. Pak JMed Res; 42: 58-60.

Turnbull's (2001) Obstetrics.3rd ed. Edinburgh: Harcourt publishers Ltd; 2001:211-28.

Ultrasonography in early pregnancy. ActaObstetGynecolScand 1981; 60:265-8.

Vaginal Deliveries. J Ayub Med Coll Abbottabad; 24(3-4)

Varma TR (1981) the implication of low implantation of the placenta detected by

Zaki M et al. (1998) Risk factors and morbidity in patients with placenta previaaccreta compared to placenta previa non-accreta, ActaObGynScand, (1998), 77; p391-4.

APPENDIXS APPENDIX 1

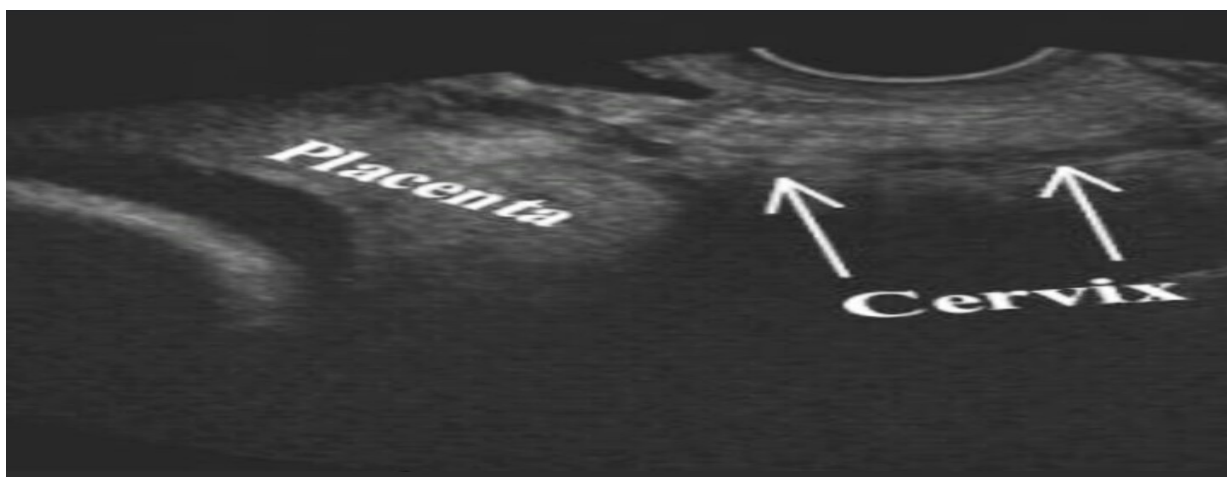


Image 1: 33 year's female patient, gestational age 38weekes major degree placenta previa

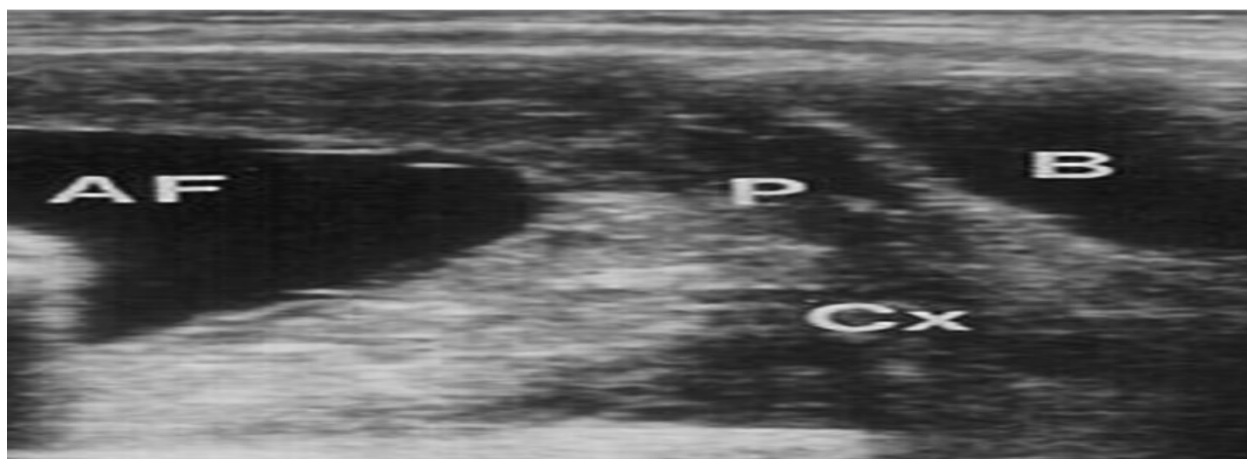


image2: 37years GA 35weeks major degree placenta preiva

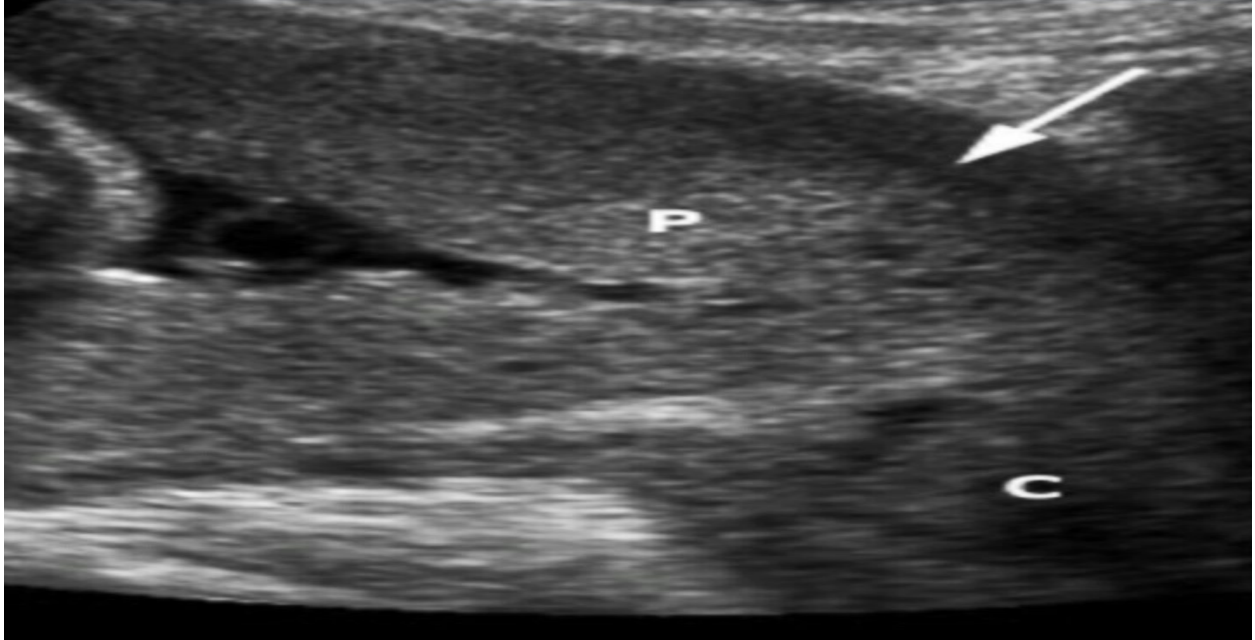

Image3: 39years GA 38weekes placenta preiva major degree



Image 4:28years 33GA minor degree placenta preiva

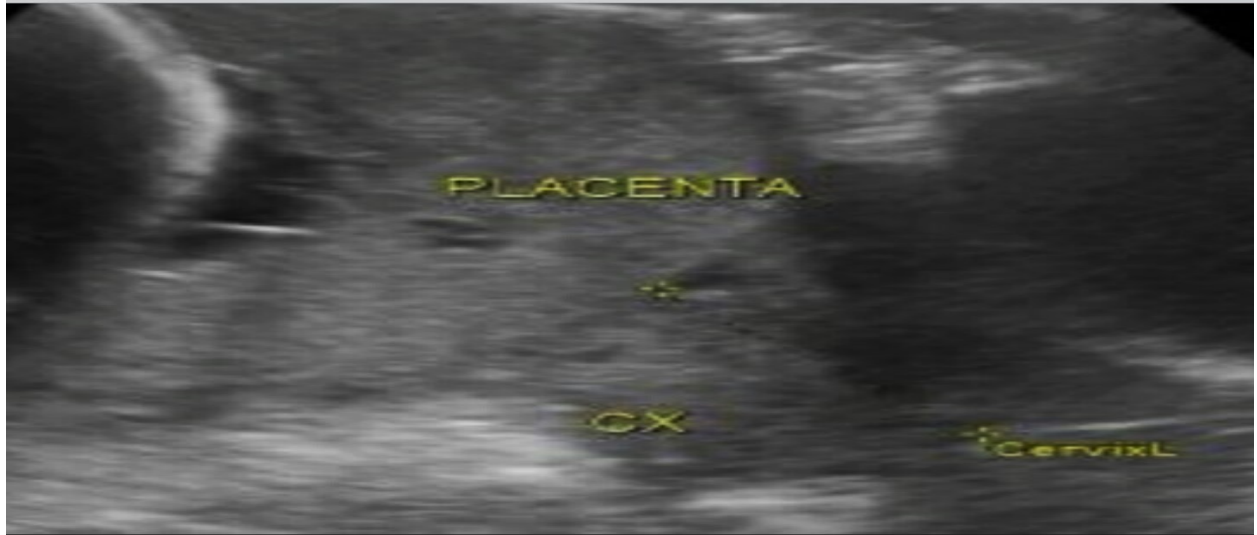


Image5: 32years old 29 weeks GA major degree placenta preiva

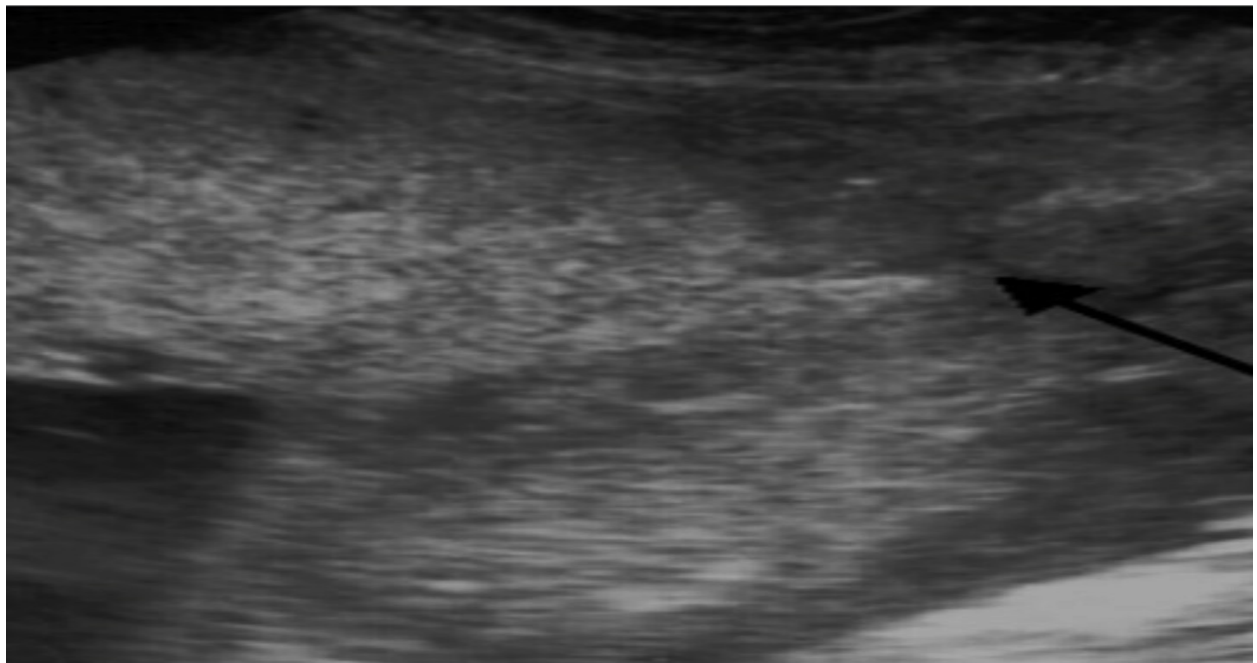

Image6: 40years 36 GA major degree placenta preiva

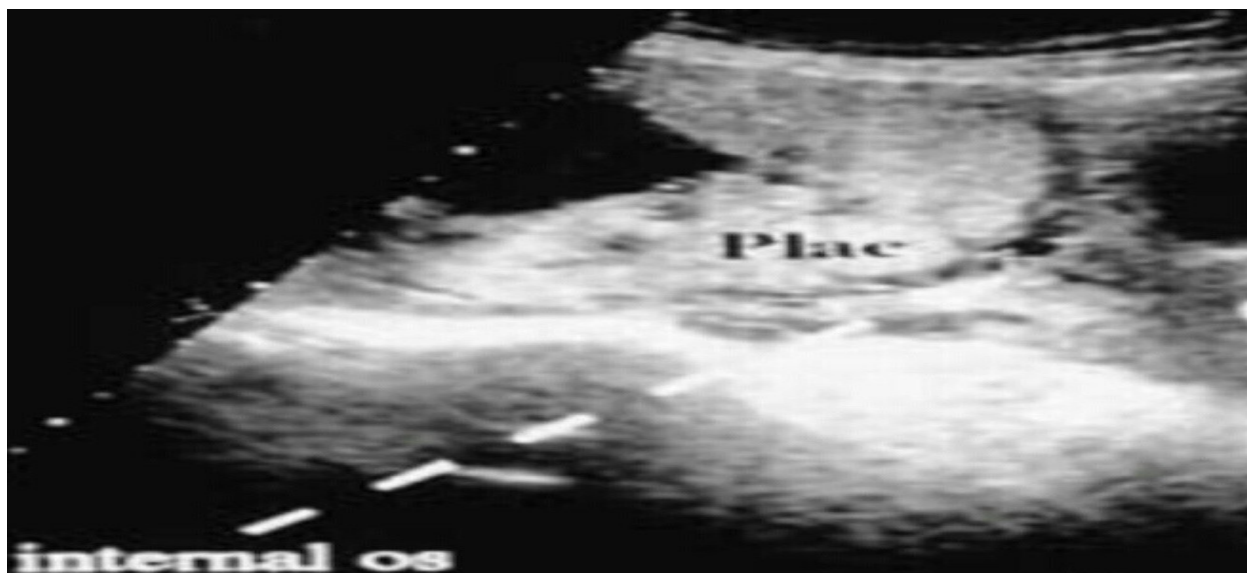

Image7: 42years 36weeks GA major degree placenta preiva

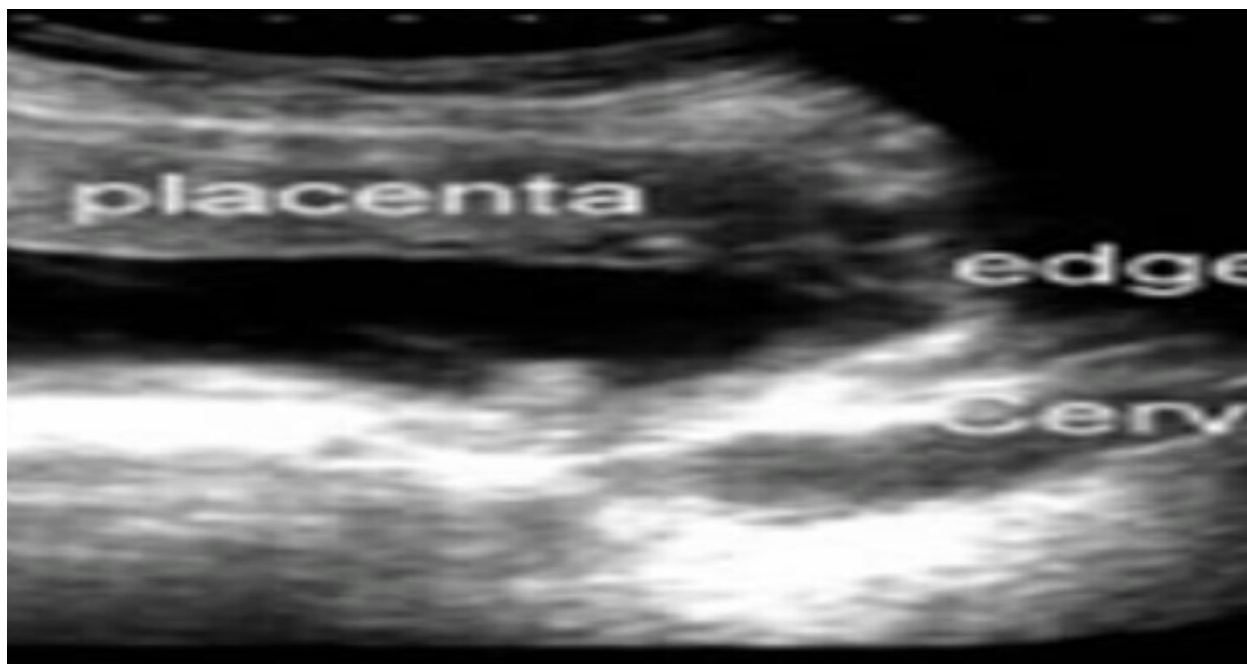

Image8: 35years GA 30 GA week's minor degree placenta preiva

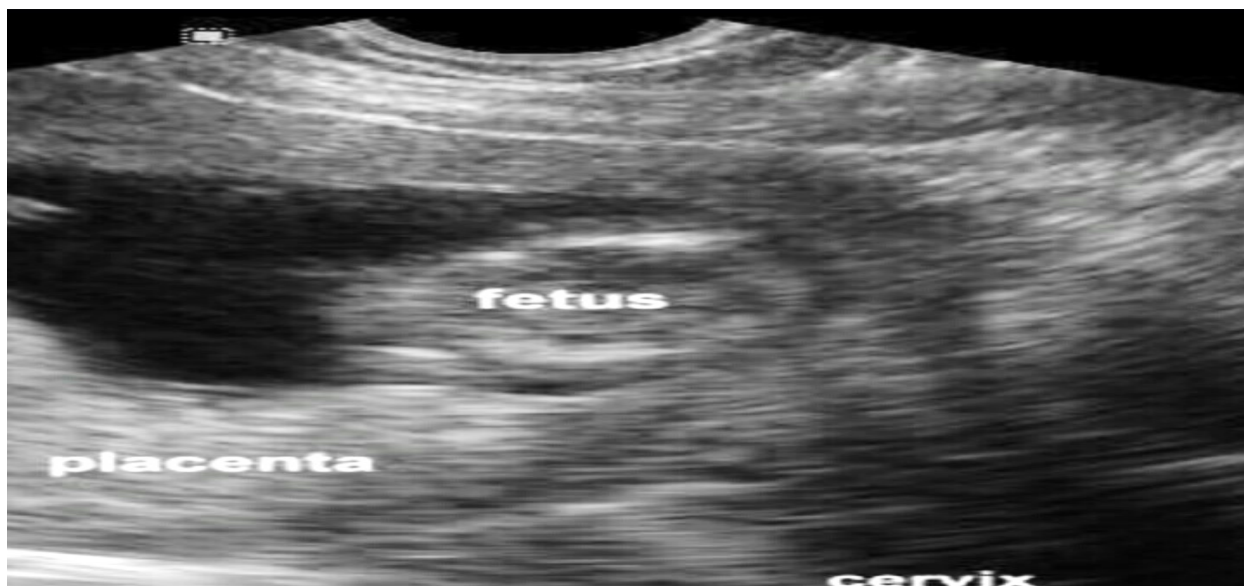

Image9:32 yeas old 28 weeksGA minor degree placenta previa

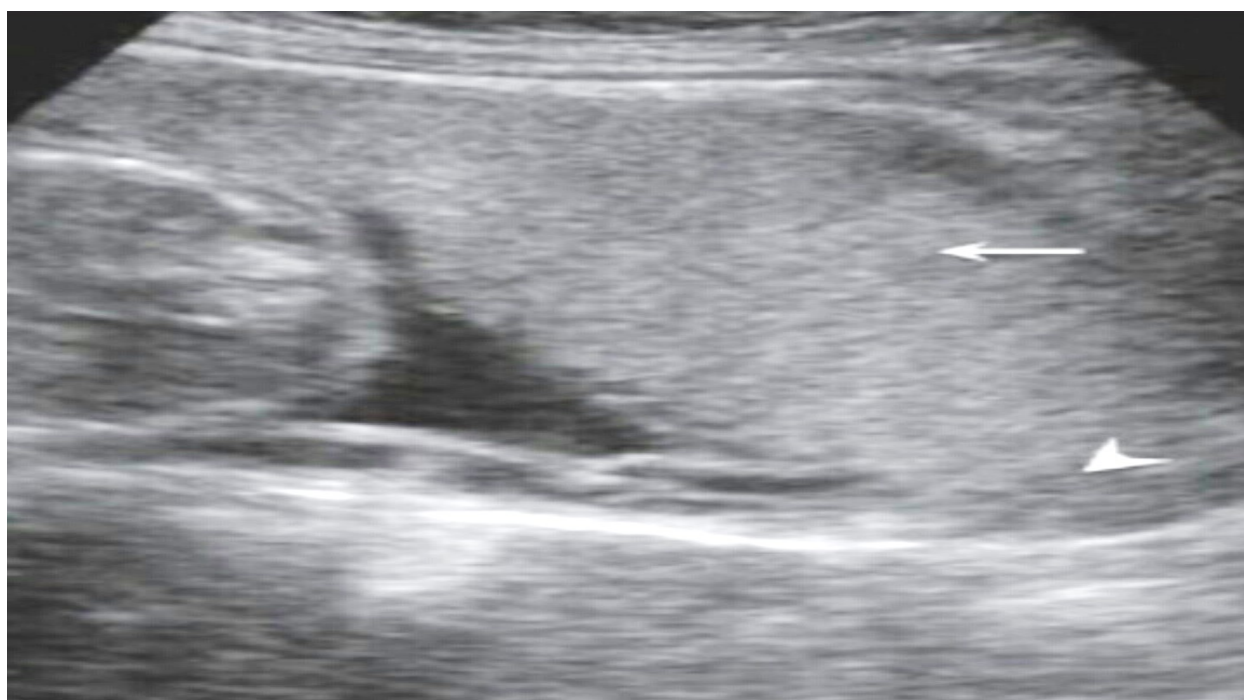

Image10:35 years old 33 weeks GA major degree placenta previa

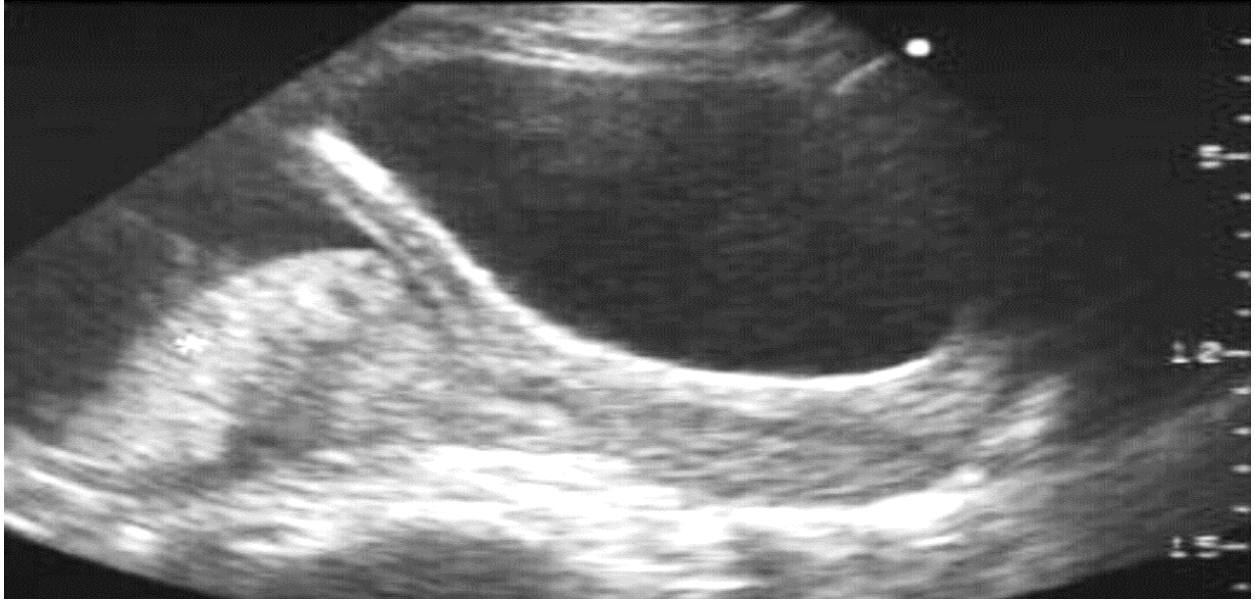


Image11:28 years old 34 weeks GA show placenta previa due to over distended urinary bladder

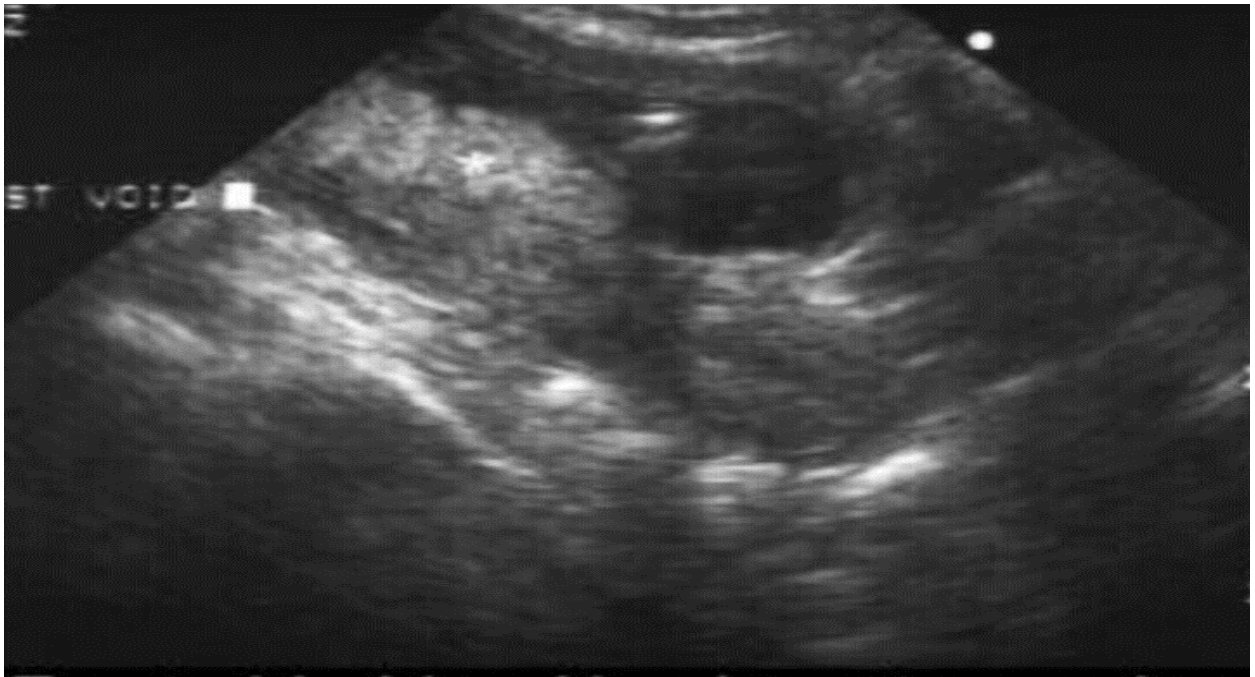

Image12:the same image 11 after evacuation of urinary bladder show upper placenta

Data collecting sheet:

ID ().

-Age:.....

-Parity:.....

-Number of cesarean sections:

.....

_GA:.....

-Placenta location:

.....

