

CHAPTER ONE

INTRODUCTION

Breast cancer is a malignant tumor of breast tissue suspected by clinical findings such as a breast lump, breast thickening, or skin change, or changes on mammography (Julie, *et al.* 2000).

Breast cancer is by far the most common female malignancy diagnosed and the most frequent cause of cancer death among women worldwide (Yuhua, *et al.* 2015).

The global burden of breast cancer in women, measured by incidence or mortality, is substantial and rising in several countries worldwide an estimated 1.4 million women were diagnosed with breast cancer in 2008 and about 458,400 women died from the disease that same year. Breast cancer incidence rates tend to be higher among more affluent women, both within countries and internationally (Steven and Yasmin, 2013).

In 2009 the first National Population-based Cancer Registry (NCR) was established in Sudan, the first data from the(NCR) for Khartoum State for the period 2009–2010, found 6771 new cancer cases were registered of those, 3646 (53.8%) cases were in women and 3125 (46.2%) were in men (Intisar, *et al.* 2014).

The risk factors of breast cancer included previous breast cancer, at-risk lesions such as atypical ductal hyperplasia, lobular carcinoma in situ, lobular hyperplasia and sclerosing adenosis, increased breast density, childlessness, early menarche, postmenopausal obesity, exogenous hormone use, family history, dietary factors and alcohol (Robert, *et al.* 2007).

Methods of diagnosis of breast cancer are mammography, magnetic resonance imaging (MRI), breast biopsy (the only definitive method for

diagnosing), immunohistochemistry (IHC), and serum tumor biomarker. The main types of treatment for breast cancer are surgery, radiation therapy (RT), chemotherapy (CT), endocrine (hormone) therapy (ET), and targeted therapy (Mohamed, *et al.* 2015).

The p63 is a member of the p53 tumor-suppressor gene family with structural homology to p53, but one that, from a functional point of view shows both similarities and differences from p53(Chan, *et al.* 2005).

P63 is expressed in stratified epithelial and in basal cells of the prostate and salivary glands. In mammary epithelium p63 has been shown to be expressed only in the myoepithelial layer . Previous studies found that in all cases, p63 expression was nuclear in normal breast tissue present in the examined sections consistent intense staining of nuclei of normal myoepithelial cells of breast lobules and ducts was noted. In all benign lesions, p63 immunoreactivity was noted in the myoepithelial cell layer surrounding the epithelial structures staining intensity was comparable to that normal breast tissue (Stefanou, *et al.* 2004).

1.2Rationale:

Breast cancer is by far the most common female malignancy diagnosed and the most frequent cause of cancer death among women worldwide (Yuhua, *et al.* 2015).P63 might distinguish between invasive ductal carcinoma and in situ ductal carcinoma and some questionable ductal hyperplasia lesion leading to correct therapy.

1.3Objectives:

1.3.1General objective:

To study the role of p63 in differentiation between benign and malignant breast tumors.

1.3.2Specific objectives:

1. To detect the expression of p63 in breast tissue by using immunohistochemical methods.
- 2 .To correlate between p63 expression and histopathological subtype.

CHAPTER TWO

2. Literature review:

2.1 Scientific background:

Breast cancer is a disease in which breast cells proliferate abnormally the diagnosis of breast cancer is established histologically, breast cancer may present as a breast lump, thickening, or skin change, non-palpable cancers may be detected by mammography. A biopsy is necessary to confirm the diagnosis and determine the type of cancer present, when breast cancer cells metastasize from the original tumor and enter the blood stream or lymphatic system they can form secondary tumors in other parts of the body (Julie, *et al.* 2000).

Breast cancer is one of the most common malignancies that affect women worldwide, and its morbidity has been increasing every year, more attention has been directed towards breast cancer prevention (Man, *et al.* 2015), despite advances in diagnosis, the prognosis of breast cancer is unfavorable due to its metastatic nature (Yuhua, *et al.* 2015).

2.2 Histology of breast:

The breast is a bilateral organ that in the female undergoes dramatic changes in size, shape, and function in association with infantile growth, puberty, pregnancy, lactation, and postmenopausal regression, the development of the human breast is progressive process initiated during embryonic life (Jose and Irma, 2014). In the adult breast, two major cell types can be detected the myoepithelial and the luminal secretory mammary cells (Maha, *et al.* 2007).

2.3 Disorder of breast (malignant):

2.3.1 Carcinoma in situ:

2.3.1.1 Ductal carcinoma in situ (DCIS):

DCIS is a malignant clonal proliferation of epithelial cells limited to ducts and lobules by the basement membrane, divided into two major

architectural subtypes comedo and non comedo (Robbins and Cotran, 2015).

2.3.1.2 Paget disease:

Paget's disease is a weeping, crusted, eczematous lesion of the nipple caused by in situ breast carcinoma cells permeating the squamous epithelium more extensive lesions may involve the areola and surrounding skin (Noel, *et al.*2009).

2.3.1.3 Lobular carcinoma in situ (LCIS):

LCIS is a clonal proliferation of cells within ducts and lobules that grow in a discohesive fashion, usually due to an acquired loss of the tumor suppressive adhesion protein E-cadherin (Robbins and Cotran, 2015).

2.3.2 Invasive carcinoma:

2.3.2.1 Invasive lobular carcinoma:

The classic type of invasive lobular carcinoma is a well-recognized breast lesion other forms of this tumor (Noel, *et al.*2009).

2.3.2.2 Medullary carcinoma:

Medullary carcinoma is defined in the WHO classification of breast tumors as a well circumscribed carcinoma composed of poorly differentiated cells with scant stroma and prominent lymphoid infiltration (Noel, *et al.*2009).

2.3.2.3 Mucinous (colloid) carcinoma:

It is a rare breast cancer formed by the mucus producing cancer cells. Women with mucinous carcinoma have a better prognosis than women with more common types of invasive carcinoma (Ganesh, *et al.* 2010).

2.3.2.4 Tubular carcinoma:

They are special types of invasive breast cancer, tubular carcinomas account for around 2% of breast cancer diagnosis (Ganesh, *et al.* 2010).

2.3.2.5Papillary carcinoma:

As the name implies produces true papillae, fronds of fibro vascular tissue lined by tumor cells (Robbins and Cotran, 2015).

2.3.2.6Secretory (juvenile) carcinoma:

This rare form of breast carcinomas seen primarily in children, but it can also occur in adults (Juan and Lauren, 2011)

Breast cancer histologies are important from the management view point because they determine response to therapy and have impact on survival, especially the aggressive tumor types, like undifferentiated carcinoma (Muhammad, *et al.* 2009).

2.4 Epidemiology:

In the United States, breast cancer accounts for more cancer deaths in women than any site other than lung cancer, breast cancer is the most commonly diagnosed invasive cancer in the United States for women of all racial and ethnic groups (Steven and Yasmin, 2013).

In Africa there is a controversy regarding breast cancer incidence in premenopausal women having the worst prognosis, and further studies and information are needed for better understand the pattern of this tumor in Africa, the black women have high mortality even in developed countries as North America (Maria, 2011).

According to the published data, cancer is increasing in the Sudan. Although the exact reason behind this increase is not known, it partially could be attributed to exposures to common and local carcinogens (tobacco and toombak dipping) and to adoption of lifestyles seen in the developed countries. Breast cancer continues to be the most common cancer among women in Sudan (Elamin, *et al.* 2015).

In 2009, the first National Population-based Cancer Registry (NCR) was established in Sudan, the most commonly diagnosed cancer among women was breast followed by leukemia, cervix, and ovary, and among

men it was prostate cancer followed by leukemia, lymphoma, oral, colorectal, and liver (Intisar, *et al.* 2014).

2.5 Risk factors:

These risk factors included, previous breast cancer, at-risk lesions such as atypical ductal hyperplasia, lobular carcinoma in situ, lobular hyperplasia and sclerosing adenosis, increased breast density, childlessness, early menarche, postmenopausal obesity, exogenous hormone use, dietary factors and alcohol (Robert, *et al.* 2007).

2.5.1 Germ line mutations:

Approximately 5% to 10% of breast cancers occur in persons with germ line mutations in tumor suppressor genes (Robbins and Cotran, 2015).

2.5.2 Race/ethnicity:

In the United States, Hispanic ethnicity and black race have been associated with later stage at breast cancer diagnosis compared with white women. Black women tend to have more aggressive breast cancers (Steven and Yasmin, 2013).

2.5.3 Age:

They are found that incidence increased after age 30, in the age group between 34 and 44 years, a risk of breast cancer was associated only with a family history of breast cancer (Laamiri, *et al.* 2015).

2.5.4 First degree relatives with breast cancer:

Women who have one first degree relative with breast cancer have about two-fold increased risk of developing breast cancer about 20 % of breast cancer patients have a family history of the disease in a first degree relative (Steven and Yasmin, 2013).

2.5.5 Estrogen exposure:

The risks were greater among users of estrogen – progesterone than estrogen-only formulations and if hormonal therapy started at around the time of menopause than later (Valerie, *et al.* 2011).

2.5.6 Mammographic density (MD):

It is one of the strongest risk factors for breast cancer women in highest quartile of MD have four to six times increased risk of breast cancer compared with those in the lowest quartile (Kimberly, *et al.* 2013).

2.5.7 The risk of histological types of breast cancer:

The different etiology of disease according to histological type, lobular tumors have shown an association with age at first birth, increasing parity may be associated with an increased risk of medullary tumors (Grethe, *et al.* 2010).

2.6 Diagnosis and treatment of breast cancer:

2.6.1 Diagnosis of breast cancer

2.6.2 Mammography:

Mammography has radically changed the diagnostic approach to breast cancer. Extremely small tumors (1–2 mm) can be detected with this technique, which relies primarily on the presence of calcification (Juan and Lauren, 2011).

2.6.3 Magnetic resonance imaging (MRI):

It is a powerful imaging tool produces high-resolution images without requiring the application of harmful radiation (Mohamed, *et al.* 2015).

2.6.4 Molecular breast imaging (MBI):

MBI uses a radioactive tracer that lights up cancer tissues of the breast, visualized by a nuclear medicine scanner (Mohamed, *et al.* 2015).

2.6.5 Breast biopsy:

The only definitive method for diagnosing breast cancer is with a breast biopsy, there are several different types of breast biopsies.

2.6.5.1 Needle biopsy:

Two types of needle biopsies are used to diagnose breast cancer, fine needle aspiration cytology (FNAC) and core needle biopsy (CNB) (Mohamed, *et al.* 2015).

2.6.6 Immunohistochemistry (IHC).

IHC is a technique that uses antibodies as a tool to detect protein expression monoclonal or polyclonal antibodies complementary to the antigen of interest are labeled with a marker either visible by light microscopy or fluorescence (Mohamed, *et al.* 2015).

2.6.7Treatment:

The therapy of breast carcinoma includes surgery, radiation therapy, hormonal therapy, chemotherapy, and target therapy, depending on the type and extent of the disease. Surgical therapy, traditionally synonymous with Halsted's radical mastectomy, chemotherapy has had a significant impact on the survival of patients with metastatic breast carcinoma, hormone therapy, tamoxifen has emerged as the most important drug in the past 20 years, to the point of becoming the endocrine treatment of choice for all stages of estrogen receptor positive breast cancer (Juan and Lauren, 2011).

2.7 P63:

The vast majority of human cancers arise from epithelial tissues its dysregulation can impair the normal architecture or behavior of the mammary epithelium, leading to cancer development (Rachel, *et al.* 2012). In the majority of cases, diagnoses of benign and malignant epithelial lesions of the breast are achievable using hematoxylin and eosin (H & E) during the last few decades, immunohistochemistry (IHC) has become an integral part of pathology its provide useful and sometimes vital information (Laila and Marilin, 2015).

The p63 is a member of the p53 tumor-suppressor gene family with structural homology to p53 (Chan, *et al.* 2005),p63and p73are rarely mutated or deleted in cancers, so p63 or p73 is a tumor suppressor gene or an oncogene has been a matter of debate(Kazushi and Elizabeth, 2014).P63 is essential for epithelial cell survival and may function as an

oncogene. P63 was expressed in the nuclei of myoepithelial and basal duct cells (Hadi, *et al.* 2003), also observed that the expression was restricted to epithelial cells of stratified epithelia, and subpopulation of basal cells in glandular structures of prostate and breast, found that p63 is expressed predominantly in basal cell and squamous cell carcinomas, as well as transitional cell carcinomas, but not in adenocarcinomas, including those of breast and prostate (Charles, *et al.* 2002).

The markers of myoepithelial cells and basal cells are extremely useful in diagnostic surgical pathology, particularly when examining difficult breast biopsies, can greatly assist in the distinction of carcinoma from benign mimics of malignancy (Rodney, 2001).

The myoepithelial layer destruction is considered a differential diagnosis parameter of in situ from invasive lesions in human breast cancer (Erika, *et al.* 2012), p63 is often used as a sensitive marker to identify myoepithelial cells particularly, it can be used to discriminate between invasive ductal carcinoma and sclerosing adenosis or to identify myoepithelial cells in papillary neoplasm (Sang, *et al.* 2014).

2.8 Previous studies:

Previous study found that their findings suggest that p63 is a sensitive and specific myoepithelial marker, and may be included in immunohistochemical panels aiming to identify myoepithelial cells in problematic breast lesions. Regarding papillary neoplasms, it is possible that tumor cells acquire and exhibit at least in part myoepithelial differentiation program, p63 has been investigated for its usefulness in aiding the diagnosis of a multitude of histological entities, utilizing its role as a myoepithelial marker in the breast to differentiate invasive from non-invasive malignancies (Stefanou, *et al.* 2004).

In other previous study found that all of the different categories of metaplastic carcinomas showed similar clinico-pathological features

(Patient age, tumor size, nuclear grade, mitotic activity, lymph node status and hormonal receptor status). For metaplastic carcinoma with epithelial component only, p63 was only expressed in the squamous cell component, but not the adenocarcinoma component. Eight of the 10 tumors were positive for p63. Using p63 for diagnosis of metaplastic carcinoma gives a sensitivity of 65%, a specificity of 96%, a positive predictive value of 96%, and a negative predictive value of 66% and an accuracy of 78%. P63 may be used as an adjunct marker in the diagnosis of metaplastic carcinoma (Gary, *et al.* 2006).

Other previous study also found that in normal appearing breast tissue p63 expression was detected in all myoepithelial nuclei of the duct system, but no immunoreactivity was observed in cytoplasm. These cells were seen as a continuous layer lining the epithelial side of basement membrane and luminal cells were consistently negative, all invasive ductal carcinoma cases completely lacked p63, positive cell lining a few scattered residual myoepithelial cell from normal breast or carcinoma in situ mixed in the area of invasive cancer result in p63 positive nuclear expression but no partial ductal structures were recognized. The result suggest an association between loss of p63 expression and progression of breast ductal carcinoma (Xiaojuan, *et al.* 2002).

Other previous study found that p63 was expressed only in poorly differentiated ductal carcinomas (11.76% of cases).

Expression of p63 correlated with pathologic staging, tumor size, histologic grading, nodal metastasis, and estrogen receptor negativity. P63 was expressed high-grade invasive carcinomas, this may be useful in distinguish invasive from in situ lesions when they are very high grade, p63 by itself is an indicator of aggressiveness of breast carcinoma.

P63 was totally negative in medullary carcinomas, and grade I and II invasive ductal carcinomas, being seen only in grade III ductal

carcinomas, positive cells were detected in grade III suggesting that these cells originate from a primary progenitor cell that underwent divergent differentiation to ductal and myoepithelial cells during clonal expansion. p63 is a specific myoepithelial cell marker in normal breast tissue and is expressed in a minority of breast carcinomas, in normal breast tissue and fibroadenomas, p63 stained the nucleus of a single continuous layer of cells surrounding the ductal and alveolar epithelium the literature strongly suggests that p63 is necessary for normal development of epithelial organs being a marker of reserve cells the major histologic criterion for the diagnosis of invasive carcinoma in breast tissue is the lack of myoepithelial cells (Alfredo, *et al.* 2003).

Other previous study found p63 was expressed in the peripheral rim of The myoepithelial cell layer in ADH and DCIS with occasional gaps in DCIS. It was positive and stained occasional malignant cells in 3/30 (10%) of IDC cases. It is concluded from this study that p63 is specific and valuable in differentiating myoepithelial cells and is more specific and valuable than other myoepithelial markers, as ASMA and can differentiate between ADH, DCIS, IDC as it stains peripheral myoepithelial cells in ADH and DCIS with gaps in the latter and does not stain any neoplastic cells. In IDC, it is positive in malignant cells in a minority of cases which may indicate basal/stem cell/myoepithelial cell origin of breast carcinoma (Maha, *et al.* 2007).

CHAPTER THREE

MATERIALS AND METHODS

3.1 Materials:

Archived breast tissue blocks were obtained from breast tissue were used in this study.

3.2 Methods:

3.2.1 Study design:

This is a descriptive retrospective study aimed to study role of p63 tumor marker in breast tissue using immunohistochemical method.

3.2.2 Study samples:

Forty tissue blocks were obtained from breast tissue, thirty samples were previously diagnosed as malignant breast tissue and ten samples were diagnosed as benign cell. Patient's identification data were obtained from patient's files.

3.2.3 Study area:

This study held in Radiation and Isotope Center at Khartoum (RICK) and Khartoum Teaching Hospital during period from February to July 2016.

3.2.4 Sample processing:

3.2.4.1 Immunohistochemical staining:

The section of (3 μ m) thickness were obtained from formalin-fixed, paraffin-embedded tissue was cut by using a rotary microtome and mounted into salinized slides (Thermo). Following deparaffinization in xylene, slides were rehydrated through a graded series of alcohol (100%, 90%, 70%, and 50%) and were placed in distilled water. Samples were steamed for antigen retrieval for P63 using water bath (PT LINK) for thirty minutes at 95c, and then washed in phosphate buffer saline (PH 7.4) for five minutes. Then sections were circulated by Dako pen,

endogenous peroxidase activity was blocked with 3% hydrogen peroxide and methanol for 10 min, and then slides were incubated with 150 µl of primary antibody (P63 monoclonal mouse antihuman) for 20 min at room temperature in a moisture chamber. After washing with PBS for 3 min, binding of antibodies will be detected by incubating for 20 minutes with dextran labeled polymer (Thermo -ultra vision). Finally, the sections washed in three changes of PBS, followed by adding 3, 3 diaminobenzidine tetra hydrochloride (DAB) as a chromogen to produce the characteristic brown stain for the visualization of the antibody/enzyme complex for up to 5 min. Slides was counter stained with Mayer's haematoxylin for one minutes then washed and blued in running tap water then dehydrated through ascending concentration of ethanol then cleared in xylene and mounted in DPX mountant (Jonh and Marilyn, 2005).

3.2.5Result interpretation:

All quality control measures were adopted, positive and negative slides were used during immunohistochemical staining.

Detection of more than 5 cells with brown nucleus per one field considered as positive result.

3.2.6Data analysis:

Data analysis was done using SPSS11.5 computer program. Frequencies mean and chi-square test values were calculated.

3.2.7 Ethical consideration:

Sample collected after taking ethical acceptance from hospital administration.

CHAPTER FOUR

4. RESULT

The study includes forty samples, 30 (75%) samples of them were malignant and ≤ 10 (25%) samples of them were benign as indicated in table(4.1).

The age of study population range between 15 and 80 with mean age of 41 years.

Most patient were less than 40 years 22 (55%) and the remain are 18 (45%) older than 40 years indicated in table (4.2).

The histological subtype includes 27 (67.5) invasive ductal carcinoma, 2 (5%) medullary carcinoma, 1 (2.5%) papillary carcinoma, 6 (15%) fibro adenoma and 4 (10%) fibrocystic change.

The grade of study population include 7 (23.3%) grade I , 11 (36.7%) grade II, 10 (33.3%) grade III and 2 (6.7%) not graded as included in table (4.3).

P63 expression showed positive result among benign breast tumors in 9/10 (22.5%) samples , while in malignant breast tumors gave positive expression in 6/30(15%) samples.

They are strong significant between histological diagnosis and p63 expression ($P.v = 0.000$) as indicate in table (4.4).

Table 4.1: Distribution of histopathological diagnosis:

Histopathological diagnosis		Frequency	Percent%
Malignant	Invasive ductal carcinoma	27	67.5%
	Medularly carcinoma	2	5%
	Papillary carcinoma	1	2.5%
Benign	Fibro adenoma	6	15%
	Fibrocystic change	4	10%
Total		40	100%

Table 4.2: Distribution of age of study population:

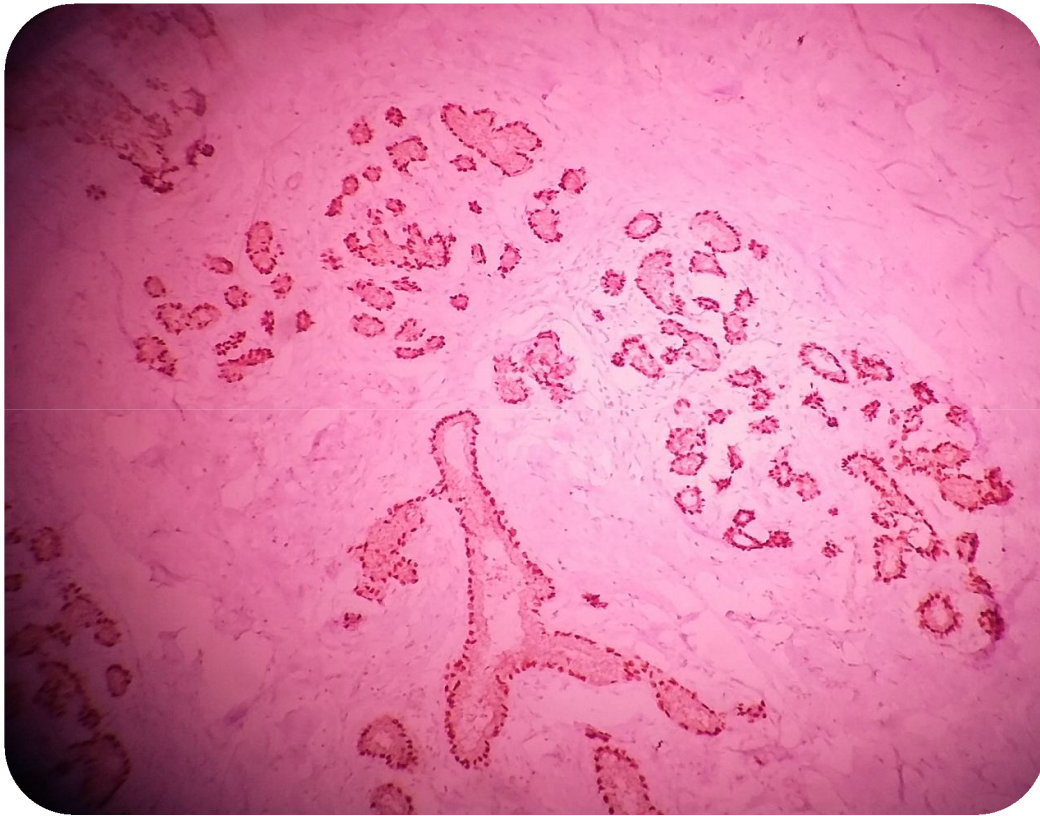
Age group	Frequency	Percent%
≤ 40	22	55%
≥ 40	18	45%
Total	40	100%

Table 4.3: The frequency of a tumor grading:

Grade	Frequency	Percent%
Grade I	7	23.3%
Grade II	11	36.7%
Grade III	10	33.3%
Not graded	2	6.7%
Total	30	100%

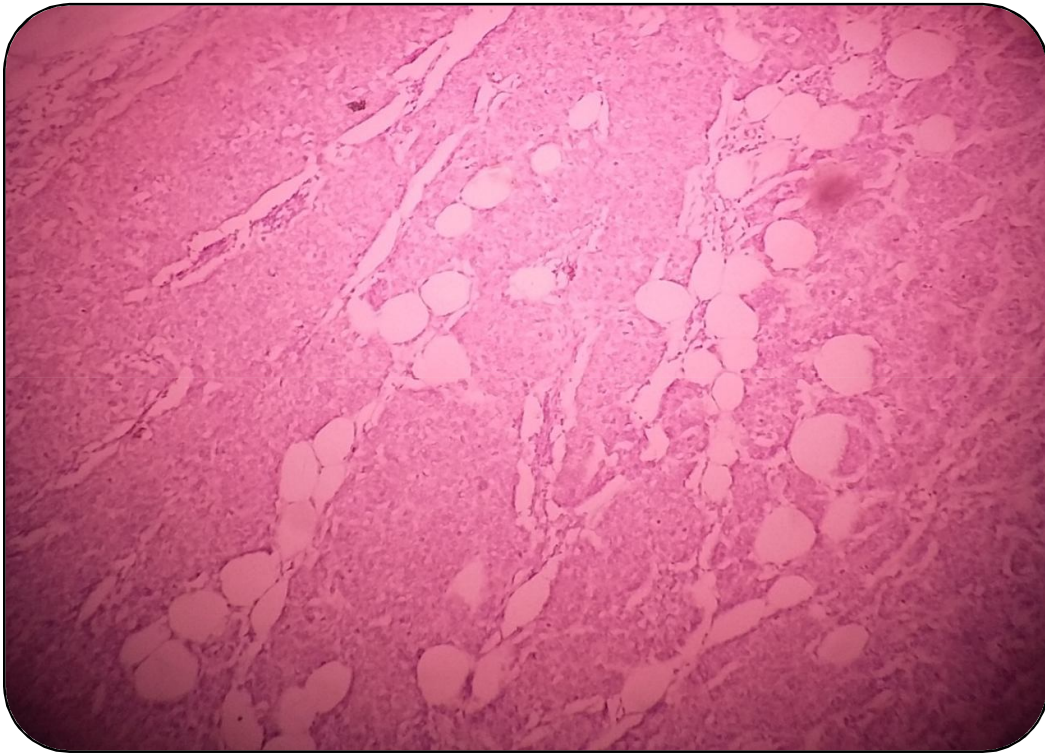
Table 4.4: Relation between the tumor histopathological subtype and P63 expression:

Histopathological diagnosis	P63		Total	P.value
	Positive (N(%))	Negative (N(%))		
Malignant	6 (15%)	24 (60%)	30(75%)	0.000
Benign	9 (22.5%)	1 (2.5%)	10(25%)	
Total	15 (37.5%)	25 (62.5%)	40(100%)	



Microphotography (4.1):

Benign breast tissue showed nuclear positive expression of P63(40X).



Microphotography (4.2):

Malignant breast tissue showed nuclear negative expression P63 (40X).

CHAPTER FIVE

5. DISCUSSION

In this study forty samples were investigated by immunohistochemical stain, 30 of them were malignant breast cancer and the remaining 10 samples were benign.

The age of study population range from 15 to 80 years, with mean age of 41 years. Most patients were aggregating in less than 40 years group representative (55%), indicate that women less than 40 years are more affected with breast cancer in Sudan. This is attributed to estrogen hormone, most incidence rate of breast cancer was in young .

This result is agree with Andrew, *et al.* (2015) who reported that younger women with higher recurrence rate. This effect is most pronounced in women <35 years old, also agree with Intisar, *et al.* (2014) who reported that the higher incidence rate of breast cancer in women aged 25-64 years. This finding also agree with Duada, *et al.* (2011) who that reported breast cancer in females around the mean of 44years.

The diagnosis of study population includes invasive ductal carcinoma most patients were diagnosis with invasive ductal carcinoma 27(67.5) this result is agree with Muhammad, *et al.* (2009) who reported that most common histologies include infiltrating ductal carcinoma counting for more than two-third of cases, also agree with Duada,*et al.* (2011) who reported the most common histopathological type of breast cancer found is invasive ductal carcinoma accounting for 78.8% of cases.

P63 immunostaining has strong association with negative expression with malignant condition (60%) compared to benign (2.5%) with (P=0.000) which suggest that their expression in benign tissue more than malignant and it is sensitive myoepthelial marker, this result is agree with Stefanou, *et al.* (2004),which their findings suggest that p63 is a sensitive and

specific myoepithelial marker and may be include in immunohistochemical panel, also agree with Alfredo, *et al.* (2003) who reported that p63 is a specific myoepithelial cell marker in normal breast tissue and fibroadenomas stained the nucleus of a single continuous layer of cells surrounding the ductal and alveolar.

P63 immunestaining negative in (55%) invasive ductal carcinoma and positive in (12.5%) in grade II and his is due to present of residual of benign cell in invasion area and this result disagree with Alfredo, *et al.* (2003) who reported that p63 was totally negative in medullary carcinomas, and grade I and II invasive ductal carcinomas, being seen only in grade III ductal carcinomas, suggesting that these cells originate from a primary progenitor cell .

CHAPTER SIX

CONCLUSION AND RECOMMENATIONS

6.1CONCLUSION:

From this study we conclude that:-

- The age of the female breast cancer in Sudan is commonly less than 40 years.
- Most histological type of breast cancer is invasive ductal carcinoma.
- Grade of breast cancer found mostly in high grade (II, III).
- P63has intense nuclear expression in myoepthelial cell, positive high expression in benign condition of breast tissue and negative in malignant.

6.2Recommendations:

From this study we recommended that:-

- Further research should be done on expression of p63 in breast tumors tissue with large sample size.
- P63 should be used in panel of myoepthelial marker to help in differentiation between benign and malignant breast tumors.

REFERENCES

Alfredo, R.S., Leandra, N.Z., Sérgio, B.G., Sérgio, Z., (2003). The Relationship between P63 and P53 Expression in Normal and Neoplastic Breast Tissue. *Arch Pathol Lab Med.* **127**:336–340.

Andrew, M.G., James, A.L.B., Carmel, M., Ray, M., Michael, J.K., (2015). Effects of Age on the Detection and Management of Breast Cancer. *Cancers.* **7**: 908-929.

Chan, P., Young, H.O., (2005). Expression of p63 in Reactive Hyperplasia and Malignant Lymphomas. *J Korean Med Sci.* **20**: 8-752.

Charles, J.D.C., Marshall, J.U., Irina, B., Marija, D., Cyrus, V.H., Julie, T.F., Kamal, P., Axel, H., Carlos, C.C., (2002). P63 Expression Profiles in Human Normal and Tumor Tissues. *Clinical Cancer Research.* **8**: 494–501.

Dauda, A.M., Misauno, M.A., EO, O., (2011). Histopathological Types of Breast Cancer in Gombe, North Eastern Nigeria: A Seven-Year Review. *African Journal of Reproductive Health.* **15** (1): 107-109.

Elamin, A., Muntaser, E.I., Dafalla, A., Kamal Eldin, H.M., Sulma, I.M., (2015). Cancer in Sudan burden, distribution, and trends breast, gynecological, and prostate cancers. *Cancer Medicine* **4**(3):447–456.

Erika, M.T., Marcela, M.M.P.R., Georgia, M.M., Mirela, T.C., Renée, L. A., Noeme, S.R., (2012). Immunohistochemical Expression

of p53 and p63 in Adenomas and Carcinomas of Canine Mammary Glands. *Open Journal of Veterinary Medicine*. **2**: 21-24.

Ganesh, N.S., Rahul, D., Jyotsana, S., Piush, S., Sharma, K.K., (2010). Various type and management of breast cancer: an overview. *J Adv Pharm Technol Res*. **1** (2):126-1096.

Gary, M.T., Puay, H., Benjaporn, C., Thomas, C.P., Philip, C.W.L., Alexk, H.T., Fiona, C.L.W., Anthony, W.I.L., (2006). P63 is useful in the diagnosis of mammary metaplastic carcinomas. *Pathology*. **38**(1): 16-20.

Grethe, A., Ivar, H., Steinar, T., (2010) . Histological type and grade of breast cancer tumors by parity, age at birth, and time since birth: a register based study in Norway. *BMC Cancer*. **10**: 226.

Hadi, B., Adriana, H.L., Jacques, C.B., Pierre, J.F., (2003). P63 Is Expressed in Basal and Myoepithelial Cells of Human Normal and Tumor Salivary Gland Tissues. *J Histochem Cytochem*. **51**:133–139.

Intisar, E.S., Hsin, W., Kamal, H.M., Sulma, I.M., (2014). Cancer incidence in Khartoum Sudan: first results from the Cancer Registry (2009-2010). *Cancer Medicine* **3**(4): 1075–1084.

Jonh, D.B., Marilyn, G., (2005). Theory and practical of histological techniques. 5th ed, New York, Elsevier: 452-453.

Jose, R., Irma, H.R., (2014). Histological Evaluation of the Normal Breast, Techniques and Methodological Approaches in Breast Cancer Research. New York, Springer Science Business: 287.

Juan, R., Lauren, V.A., (2011). Surgical pathology 10th ed, vol 1 New York, Elsevier: 1660-1712.

Julie, B.C., Judith, H., Ephrat, L.L., Mary, D., Wylie, B., (2000). Breast Cancer Genetics - An Overview. *Gene Clinics* **4** (3):1-12.

Kazushi, I., Elizabeth, A.F., (2014). Alterations of p63 and p73 in Human Cancers. USA, Springer Science Business Media Dordrecht. 17-34.

Kimberly, A .B., Rulla, M.T., Christopher, G.S., Matthew, R.J., Shane, V.P., Daniel, V., Aaron, N., Fergus, C., John , S.B.F., Yunn, Y.C., Lin, M., Andrew, H.B., Steven, R.C., Karla, K., Celine, M.V., (2013). Mammographic density and risk of breast cancer by age and tumor characteristics. *Breast Cancer Research*. **15**: (R104) 2-13.

Laamiri, F., Abdellatif, B., Nadia, H., Samir, A., Mustapha, M., Barkat, A., (2015). Risk Factors for Breast Cancer of Different Age Groups: Moroccan Data. *Open Journal of Obstetrics and Gynecology*. **5**: 79-87.

Laila, K., Marilin, R., (2015). Use of Immunohistochemical Stains in Epithelial Lesions of the Breast. *Cancer Control*. **22**(2):220-224.

Maha, M.S., Safinazh, E., Emanm, E.S., (2007). P63 and Cytokeratin8/18 Expression in Breast, Atypical Ductal Hyperplasia, Ductal Carcinoma in Situ and Invasive Duct Carcinoma. *Journal of the Egyptian Nat Cancer Inst*. **19** (3): 202-210.

Man, F., Chang, F., Zhigang, Y., Qinye, F., Zhongbing, M., Feng, W., Fei, W., Lixiang, Y., (2015). Histopathological alterations during

breast carcinogenesis in a rat model induced by 7,12-Dimethylbenz (a) anthracene and estrogen-progestogen combinations. *Int J Clin Exp Med*. **8**(1):346-357.

Maria, P. C., (2011). Breast cancer in the world: Incidence and mortality. *Salud Publica Mex*. **53** (5):372-384.

Mohamed, N., Fatema, E., Nada, A., Kamilia, A., Satyanarayana, G., Hussaini, S.S.Q., (2015). Breast Cancer: Conventional Diagnosis and Treatment Modalities and Recent Patents and Technologies. *Breast Cancer: Basic and Clinical Research*: **9** (S2):17–34.

Muhammad, K.S., Farhat, A.K., Imran, K.I.A., Gokul, K., (2009). Age Specific Histologic Types of Carcinoma Breast in Malaysians. *Journal of the College of Physicians and Surgeons Pakistan*. **19** (3): 201-202.

Noel, W., Richard, J.C., Saul, S., Lawrence, M.W., (2009). Modern surgical pathology, 2nd ed.vol 1. NEW York. Elsevier: 549-620.

Rachel, L.D., Jamie, L.B., Hannes, V., Sylvain, B., Alexander, D.B., Mina, J., Laura, D.A., (2012). Deficiency of the p53/p63 target Perp alters mammary gland homeostasis and promotes cancer. *Breast Cancer Research*. **14**: R65:2-14

Robert, W., Peter, D., Wasan, A., (2007). Risk factors for breast cancer in women. *New Zealand Health Technology Assessment report (NZHTA)* .**10**(2) III.

Robbins and Cotran (2015). Pathologic basis of disease, 9th ed. Canada. Saunders Elsevier: 1043-1071.

Rodney, T.M., (2001) . Focus on Immunohistochemistry p63. *ProPath Immunohistochemistry Laboratory*.

Sang, K.K., Woo, H.J., Ja, S.K., (2014). P40 (Δ Np63) expression in breast disease and its correlation with p63 immunohistochemistry. *Int J Clin Exp Pathol*. **7**(3):1032-1041.

Stefanou, D., Batistatou, A., Nonni, A., Arkoumani, E., Agnantis, N.J., (2004). P63 expression in benign and malignant breast lesions. *Histol Histopathol* .**19**: 465-471.

Steven, S.C., Yasmin, C., (2013). Epidemiology of Breast Cancer in Women. Breast Cancer Metastasis and Drug Resistance. New York Springer Science Business Media. 22-30.

Valerie, B., Gillian, R., Diana, B., Jane, G., (2011). Breast Cancer Risk in Relation to the Interval Between Menopause and Starting Hormone Therapy. *J Natl Cancer Inst*. **103** (4):296–305.

Xiaojuan, W., Ichimori, W.T., Misa, N., Yasushi, N., Misako, S., Takeo, S., Kennichi, K., (2002). P63 expression in normal hyperplastic and malignant breast tissue. *Breast cancer*. **9** (3): 216-219

Yuhua, L., Liliang, L., June, L., Xin, H., Beixu, L., Aimin, X., Yiwen, S., Jieqing, J., Mingchang, Z., Jianhui, X., Ziqin, Z., (2015). Deregulation of RGS17 Expression Promotes Breast Cancer Progression. *Journal of Cancer*. **6**(8): 767-775.

APPENDICIES

Appendix 1:

Materials and instruments used for processing and staining of the specimens

Disposable gloves.

Rotary microtome.

Microtome knives.

Salinized slides (Thermo)

Cover glasses.

Dry oven.

Water bath (PTLINK).

Coplin jars.

Humidity chamber.

Ethanol(100%,90%,70%,50%).

Xylene.

Mayer's haematoxylin.

Citrate buffer (PH 6.8).

Phosphate buffer (PH 7.4).

Primary antibody (P63).

Secondary antibody.

Substrate-Chromogen.