

Chapter One

1.1 prelude:

The upper surface of a typical cervical vertebral body is concave from side to side and convex in an anterior posterior direction . The upper projection of the lateral superior surface is known as the uncus and articulates with the vertebral body above at the uncovertebral joint of Luschka. The pedicle is attached below the uncovertebral joint on the body of the vertebra. Thus an intervertebral foramen is bounded in front by both vertebral bodies, the uncovertebral joint, and the lateraldisc. Posteriorly the foramen is bounded by the facet joint . Root compression may occur secondary to osteophyte formation arising from the uncovertebral joint medial to the root or the facet joint lateral to the root. These bony abnormalities are particularly well seen on computed tomography (CT) . A lateral disc prolapse may also compress the root. The laminae enclose a relatively large spinal canal which is triangular in cross section and nicely defined on axial MRI . Cord compression may occur anteriorly, secondary to midline disc prolapse, osteophyte or more rarely ossified posterior longitudinal ligament. The cord may be compressed posteriorly by a hypertrophied ligamentum flavum .(Malcolm, G.P. ,2002).

Cervical degenerative disease is common and it is often difficult to distinguish pathological changes from the normal aging process. Neck, shoulder, and brachial pain is frequently

encountered and the majority of patients presenting with these symptoms do not need consideration for surgery. Patients and doctors may feel that there is “something” that should be done although, in fact, this is rarely the case. MRI scans may well reinforce this delusion by demonstrating Abnormalities

In the first two decades of life few changes occur within the spine, but from the third decade onwards degeneration is apparent. This tends to start at the level of the disc and is most common at C5/C6 and C6/C7. The majority of individuals over 50 years have radiological evidence of degenerative disease, but only a small proportion will have neurological symptoms or signs.) Malcolm, G.P. ,2002(. Intervertebral disc herniation is also known as herniated nucleus pulposus (HNP). The intervertebral discs make up approximately one-fourth of the cervical spine’s height. Over time the water content within the nucleus pulposus of the disc decreases from approximately 90% at birth to 70% by age 70 (Naderi, Benzel, & Resnick, 1999). The diminished water content, along with changes due to the effects of proteoglycan, collagen, keratin sulfate, and chondroitin sulfate, results in degeneration. Spinal cord compression resulting from a central disc herniation can present in varying degrees of symptomatology. Most cervical HNPs occur at C5–C6, or C6–C7 levels. (Jodi Boling, MSN RNCNS CNRN et al ,2007).

Cervical spondylosis describes a non-specific degenerative process of the spine, which may result in varying degrees of stenosis of both the central spinal canal and root canals.

Malcolm, G.P. (2002). Spondylosis is generally defined as age- and use-related degenerative changes of the spine. This diagnosis includes degenerative disc disease and the progressive changes that occur as a result of disc degeneration, such as osteophyte formation, ligamentous hypertrophy, and facet hypertrophy. As the degenerative cascade continues, changes in normal spinal curvature occur. Disc degeneration leads to loss of disc height, more so anteriorly in the cervical spine. (Jodi Boling, MSN RNCNS CNRN et al, 2007).

Cervical Spondylotic Myelopathy Is defined as spinal cord dysfunction accompanying typical age-related degeneration of the cervical spine. Jodi Boling, MSN RNCNS CNRN et al (2007). Also defined Chronic disc degeneration with osteophytes is the most common cause of spinal cord compression in patients over 55 years of age. (Malcolm, G.P. ,2002)

Cervical stenosis, classified as either congenital or acquired, is a result of either being born with a narrow spinal canal or developing a narrow spinal canal as a result of degenerative changes. Cervical Stenosis An important feature of disc degeneration is the reaction that the bone undergoes. Because the normal relationships of the bones are lost, there is a condition of instability. This refers to one vertebra moving in an abnormal manner in relation to the next vertebra. To attempt to stabilize this excess motion, bone grows outward. These outward growths are called osteophytes. (Ali Hassan A. Ali^{1,2}, Mohammad Aslam Siddiqui, et al, 2014).

The most common levels of disc herniation are C5/C6 and C6/C7 leading to compression of the C6 and C7 roots, respectively. Plain cervical x ray will often show evidence of degenerative changes with abnormalities being most prominent at C5/C6 and C6/C7 levels. Loss of disc height and formation of prominent osteophytes is a common finding in older patients and provides limited useful information for patient management.(Malcolm, G.P. ,2002).

Only MRI is capable of detecting the physiological degenerative change of nucleus pulposus ,by alteration in disc space MRI signal intensity. The MRI can diagnose cord cavitation and increased signal intensity by Ct cannot do. Evaluation of disc abnormalities in cervical region is also well done with MRI it is added advantage of demonstrating any internal physiological degenerative change of disc space than CT.MRI superior to Ct in the diagnosis and characterization of disc herniation . Manifested by loss of normal high MRI disc space signal intensity at one or more cervical interspace level. (Stephen M. foreman and Arthur C.croft ,2001).

1-2Problem of Study:

The degenerative changes produced similar symptoms and sings as other pathology , find some difficult measure in older patients and may be in some younger patient ,all study are diagnosis by radiologist to determine the degenerative changes.

1-3Objectives:

1-3-1 General objective:

To Evaluation Of Age -Related Changes In Cervical Spine with Age In Khartoum state Adult Population using MRI Image.

1.3.2 Specific Objectives:

- To measure the height of intervertebral disc and body in sagittal cervical MRI .
- To measure the diameter of cervical body and spinal canal in sagittal cervical MRI .
- To determine the relation between these variable and cervical degenerative changes by using MRI.

1-4 Significances of the study:

This study will enhance the measurement changes in cervical spine with Age by using MRI .so as to be use full in different purpose and diagnose. Although there is a lot of modalities that can detected degenerative changes like CT,X-RAY but not give clear detail of change than MRI therefore studying of measurement changes in cervical spine with Age by use MRI.

1-5 Overview of the study:

The study will fall into five chapters, Chapter one consists of introduction that about the cervical anatomy and degenerative change, objectives, significant of the study and the overview of the study. Chapter two includes the literature review, Chapter three detailed the material and methods, Chapter four includes the presentation of the results, and finally chapter five include the discussions, conclusion, recommendation and summary.

Chapter Two

Literature Review

2-1 Anatomy:

2-1-1 Anatomical description for vertebra:

The vertebral column has 33 vertebrae - 7 cervical, 12 thoracic, 5 lumbar, 5 sacral (fused) and 4 coccygeal (fused) vertebrae. The spine of the fetus is flexed in a smooth C shape. This is referred to as the 'primary curvature' and is retained in the adult in the thoracic and sacrococcygeal areas. Secondary extension results in lordosis - known as the 'secondary curvature' of the cervical and lumbar spine.

A typical vertebra has a vertebral body anteriorly and a neural arch posteriorly. The neural arch consists of pedicles laterally and

of laminae posteriorly. The pedicles are notched superiorly and inferiorly so that adjoining pedicles are separated by an intervertebral foramen, which transmits the segmental nerves. There are 31 segmental spinal nerves - 8 cervical, 12 thoracic, 5 lumbar, 5 sacral and 1 coccygeal . The first seven cervical nerves emerge above the correspondingly named vertebra; the others emerge below

A transverse process arises at the junction of the pedicle and the lamina and extends laterally on each side. The laminae fuse posteriorly as the spinous process. Articular processes project superiorly and inferiorly from each lamina. Articular facets on these processes face posteriorly on the superior facet and anteriorly on the inferior facet. The part of the lamina between the superior and inferior articular facets on each side is called the pars interarticularis. (Stephanie Ryan, et al ,2004).

The cervical vertebrae most distinctive feature is the presence of the foramen transversarium in the transverse process. This transmits the vertebral artery (except C7) and its accompanying veins and sympathetic nerves,(stephanie Ryan,etal,2004). (Fig. 2. 1)

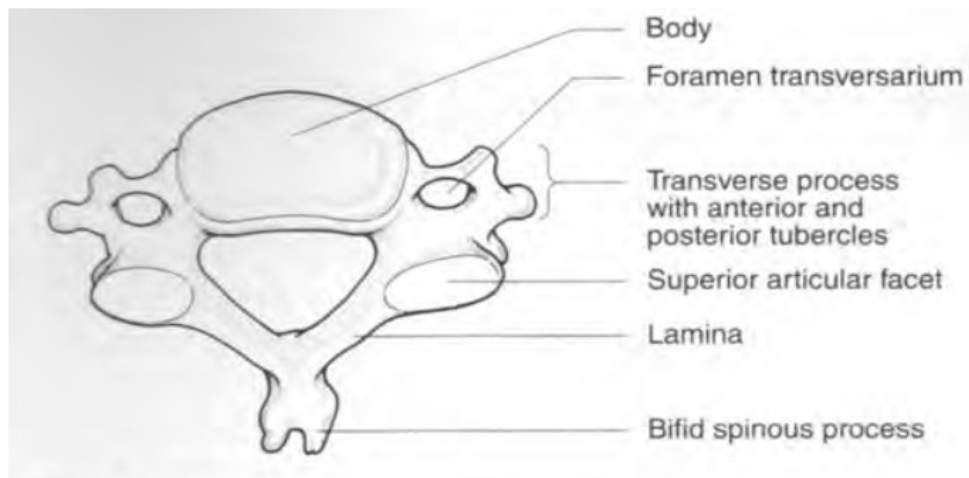


Fig.(2-1) cervical vertebra. (Stephanie Ryan,etal,2004).

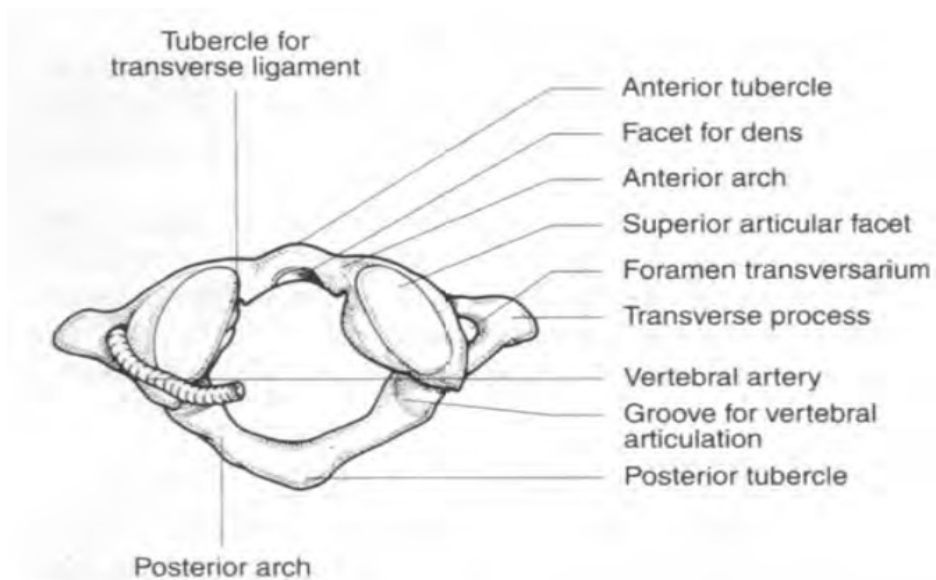
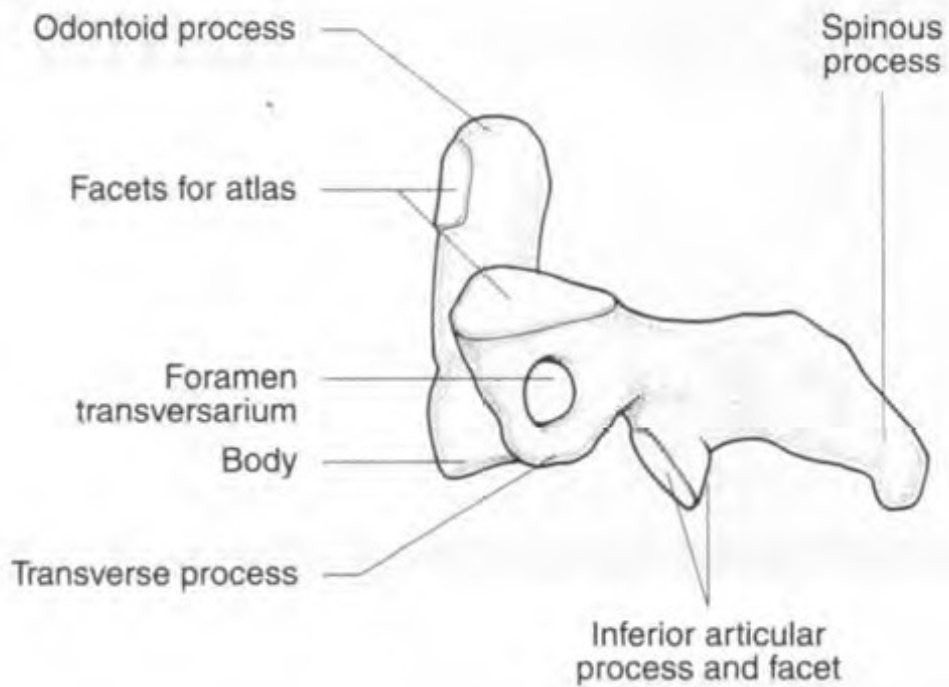


Fig.(2-2) The atlas: Superior View. Stephanie Ryan,etal(2004).

A



B

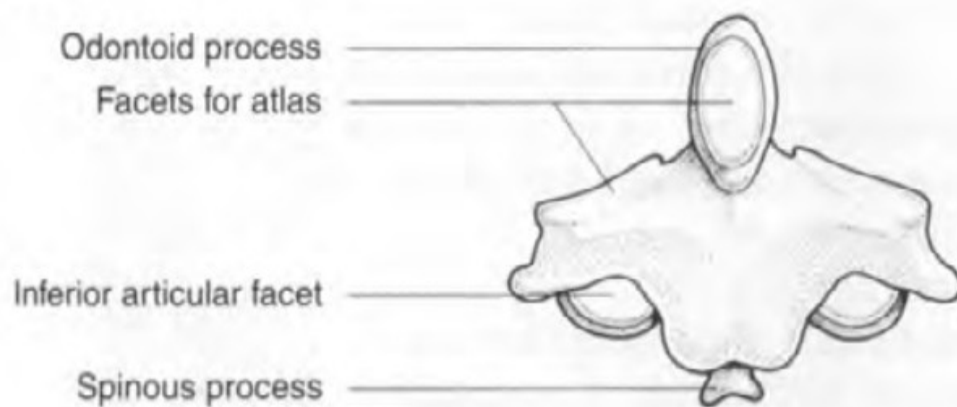


Fig.(2-3) The axis:(A) lateral view (B) anterior view. (Stephanie Ryan,etal,2004).

Small lips are seen on the posterolateral side of the superior surface of the C3-C7 vertebral bodies, with corresponding bevels on the inferior surface. Small joints, called neurocentral joints (of Luschka) or uncovertebral joints, are formed between adjacent cervical vertebral bodies at these sites. These are not true synovial joints although often called so, but are due to degenerative changes in the disc. The cervical vertebral canal is triangular in cross-section. The spinous processes are small and bifid, whereas the articular facets are relatively horizontal. (Stephanie Ryan , et al ,2004).

The atlas has no body as it is fused with that of the axis to become the odontoid process. A lateral mass on each side has a superior articular facet for articulation, with the occipital condyles in the atlanto-occipital joint, also an inferior articular facet for articulation with the axis in the atlantoaxial joint. The anterior arch of the atlas has a tubercle on its anterior surface and a facet posteriorly for articulation with the odontoid process. The posterior arch is grooved behind the lateral mass by the vertebral artery as it ascends into the foramen magnum. (Fig. 2.2)

The odontoid process, which represents the body of the atlas, bears no weight. Like the atlas, the axis has a large lateral mass on each side that transmits the weight of the skull to the vertebral bodies of the remainder of the spinal cord. Sloping articular facets on each side of the dens are for articulation in the atlantoaxial joint. (Fig. 2. 3)

Vertebra prominens - C7 name is derived from its long, easily felt, non-bifid spine. Its foramen transversarium is small or absent and usually transmits only vertebral veins.(Stephanie Ryan,etal,2004).

2-1-2 Joints Of The Vertebral Column:

Although the movement between individual vertebrae is small, the additive effect of this is great, allowing significant movement of the vertebral column. Maximum movement is at the atlanto-occipital and atlantoaxial joints and at the cervicothoracic and thoracolumbar junctions. The joints between the vertebral bodies at the intervertebral discs are secondary cartilaginous joints. The surface of the vertebral bodies in contact with the disc is coated with hyaline cartilage. Small synovial joints between vertebral bodies, called neurocentral joints, occur in the cervical spine as already described. Facet joints occur between the articular processes of the neural arches of the vertebrae. These are synovial joints with a simple capsule attached just beyond the margins of the articular surface. The capsules are looser in the cervical spine than in the thoracic or lumbar spine. The atlanto-occipital joint, between the occipital condyle on each side of the foramen magnum and the superior articular surface of the atlas, is a synovial joint. A fibrous capsule surrounds the synovial membrane and is thickened posteriorly and laterally. In addition, the joint is strengthened by the anterior atlanto-occipital membrane (from the anterior margin of the foramen magnum to the anterior arch of the atlas) and by the posterior atlanto-

occipital membrane (from the posterior margin of the foramen magnum to the posterior arch of the atlas). These joints act as a single joint and allow flexion and extension (nodding of the head) and some lateral motion.(Stephanie Ryan,etal,2004).

Three joints make up the atlantoaxial joint: A small synovial joint between the anterior surface of the dens and the posterior aspect of the anterior arch of the atlas; and A synovial joint between each lateral mass of the atlas and of the axis. These joints are strengthened by: The membrana tectoria, which is an upward continuation of the posterior longitudinal ligament from the axis to the anterior margin of the foramen magnum; The cruciform ligament, which has a transverse band attached to the atlas and a vertical band anterior to the membrana tectoria from the posterior aspect of the body of the axis to the margin of the foramen magnum; and The apical and alar ligaments join the tip of the dens to the margin of the foramen magnum. The atlantoaxial joint allows rotation about a vertical axis of the head and atlas on the axis.(Stephanie Ryan,etal,2004).

2-1-3 Ligament Of The Vertebral Column:

The anterior longitudinal ligament extends from the basilar part of the occipital bone along the anterior surface of the vertebral bodies and intervertebral discs as far as the upper sacrum. It is firmly attached to the discs and less firmly to the anterior surface of the vertebral bodies. The posterior longitudinal ligament passes along the posterior surface of the vertebral bodies from the body of the axis to the sacrum. It is firmly attached to the intervertebral

discs but separated from the posterior surface of the vertebral bodies by the emerging basivertebral veins. The posterior longitudinal ligament continues superiorly as the membrana tectoria from the posterior aspect of the body of the axis to the anterior margin of the foramen magnum. The supraspinous ligament is attached to the tips of the spinous processes from the seventh cervical vertebra to the sacrum. Above level C7 it is represented by the ligamentum nuchae, which is a fibrous septum lying in the midline sagittal plane that extends from the spines of the cervical vertebrae to the external occipital protuberance and the external occipital crest. Adjoining laminae are connected by ligamenta flava, which pass from the anterior surface of one lamina to the posterior surface of the lamina below. The yellow colour that gives them their name is due to their significant content of elastic tissue. They are the only markedly elastic ligament in man, and can stretch on flexion without forming folds on extension that could impinge on dura. Relatively weak ligaments connect adjacent transverse processes - the intertransverse ligaments - and adjacent. (Stephanie Ryan, et al, (2004).

2-1-4 The Intervertebral Disc:

The vertebral bodies are joined by fibrocartilaginous discs, which are adherent to thin cartilaginous plates on the vertebral bodies

above and below them. The discs are wedge-shaped in the cervical and lumbar regions and consequently contribute to lordosis in these regions; however, in the thoracic region they are flat. The intervertebral discs contribute one-fifth of the total height of the vertebral column.

Each disc has a central nucleus pulposus, which is gelatinous in the young subject and becomes more fibrous with age. This is surrounded by an annulus fibrosus of tough fibrous tissue. The annulus is relatively thin posteriorly and this is the usual site of rupture in the degenerate disc. (Stephanie Ryan,etal,2004).

2-1-5 Blood Supply Of The Vertebral Column:

The vertebral bodies and associated structures are supplied by the ascending cervical artery and intercostal and lumbar segmental arteries. Venous drainage of the vertebral bodies is by a pair of basivertebral veins that emerge from the posterior surface of the body to drain to the internal vertebral venous plexus, which in turn drains to the segmental veins. These large valveless veins allow reflux of blood draining from other viscera into the vertebral bodies and are a potential route of spread of disease - particularly malignancy - into the vertebral bodies. (Stephanie Ryan ,et al,2004).

2-1-6 The Spinal Cord:

The spinal cord extends from the medulla oblongata at the foramen magnum to the conus medullaris distally. It extends the

entire length of the vertebral canal in a 3-month-old fetus but, because of greater growth in length of the vertebral column than in the spinal cord, the conus lies at the level of the L3 vertebra at birth and at the lower limit of L1 or upper limit of L2 at the age of 20. The conus may lie even higher in the flexed position that may be used during myelography. Beyond the conus medullaris a prolongation of pia mater extends as a thin cord - the filum terminale. This is attached to the posterior aspect of the first coccygeal segment. From the spinal cord, 31 segmental nerves arise on each side - 8 cervical, 12 thoracic, 5 lumbar, 5 sacral and 1 coccygeal. Although there is no trace of segmentation on the surface of the cord, the part of the spinal cord from which a pair of spinal nerves arises is called a spinal segment. Each spinal nerve arises from a series of rootlets which fuse to form a dorsal root, with a dorsal root ganglion that carries sensory nerves and a ventral root with motor and autonomic nerves. The dorsal and ventral roots unite at the intervertebral foramen to form the spinal nerve. Spinal nerves C1-C7 exit above the pedicles of the corresponding vertebrae and all other spinal nerves exit below the pedicles of the corresponding vertebrae. Thus the C8 nerve passes under the pedicle of C7 (there is no C8 vertebra) and the L5 nerve passes under the pedicle of the L5 vertebra. Having left the vertebral canal, the spinal nerves divide into dorsal and ventral rami, each of which carry motor and sensory nerves. Owing to the difference in length between the spinal cord and the vertebral canal, the spinal segment from which a nerve arises is

separated from the correspondingly named vertebra and the exit foramen. Thus cord segments in the lower cervical spine are one level above the exit foramina, those in the lower thorax two levels above, and those in the lumbar spine three levels above their exit Foramina. Similarly, expansions in the diameter of the spinal cord due to the brachial plexus (C5-T1) and the lumbosacral plexus (L2-S3) cause expansion of vertebral interpedicular distances at higher levels - C4-T2, maximal at C6 for the brachial plexus, and T9-L1/2 (the conus) for the lumbar plexus. Nerve roots take an increasingly greater downward course from cord to exit foramen in the cervical, thoracic and lumbar spinal cord. The lumbar, sacral and coccygeal roots that exit below the conus at L1/2 are contained within the dura as far as its lower limit at S2 and are called the cauda equine. (Stephanie Ryan,etal,2004).

2-2Physiology:

The cervical spine functions to provide mobility and stability to the head while connecting it to the relatively immobile thoracic spine.

The movement of nodding the head takes place predominantly through flexion and extension at the joint between the atlas and the occipital bone, the atlanto-occipital joint. However, the cervical spine is comparatively mobile, and some component of this movement is due to flexion and extension of the vertebral column itself.

The movement rotating the head left and right happens almost entirely at the joint between the atlas and the axis, the atlanto-axial joint. A small amount of rotation of the vertebral column itself contributes to the movement.(http://www.physio-pedia.com/Cervical_Vertebrae).

2-3 Pathology:

Degenerative Cervical Spine Disorders :

Cervical degenerative disease is common and it is often difficult to distinguish pathological changes from the normal aging process. Neck, shoulder, and brachial pain is frequently encountered and the majority of patients presenting with these symptoms do not need consideration for surgery. Patients and doctors may feel that there is “something” that should be done although, in fact, this is rarely the case. MRI scans may well reinforce this delusion by demonstrating Abnormalities. (Malcolm, G.P. ,2002).

Intervertebral disc herniation is also known as herniated nucleus pulposus (HNP). The intervertebral discs make up approximately one-fourth of the cervical spine’s height. Over time the water content within the nucleus pulposus of the disc decreases from approximately 90% at birth to 70% by age 70 (Naderi, Benzal, & Resnick, 1999). The diminished water content, along with changes due to the effects of proteoglycan, collagen, keratin sulfate, and chondroitin sulfate, results in degeneration. Spinal cord compression resulting from a central disc herniation can present in varying degrees of symptomatology. Most cervical HNPs occur

at C5-C6, or C6-C7 levels.(Jodi Boling, MSN RNCNS CNRN et al , 2007).

Cervical spondylosis describes a non-specific degenerative process of the spine, which may result in varying degrees of stenosis of both the central spinal canal and root canals. Malcolm, G.P. (2002).Spondylosis is generally defined as age- and use-related degenerative changes of the spine. This diagnosis includes degenerative disc disease and the progressive changes that occur as a result of disc degeneration, such as osteophyte formation, ligamentous hypertrophy, and facet hypertrophy. As the degenerative cascade continues, changes in normal spinal curvature occur. Disc degeneration leads to loss of disc height, more so anteriorly in the cervical spine.

Cervical Spondylotic Myelopathy Is defined as spinal cord dysfunction accompanying typical age-related degeneration of the cervical spine. Jodi Boling, MSN RNCNS CNRN et al (2007). also defined Chronic disc degeneration with osteophytes is the most common cause of spinal cord compression in patients over 55 years of age.(Malcolm, G.P. ,2002).

Cervical stenosis , classified as either congenital or acquired, is a result of either being born with a narrow spinal canal or developing a narrow spinal canal as a result of degenerative changes. Jodi Boling, MSN RNCNS CNRN et al (2007). Cervical Stenosis An important feature of disc degeneration is the reaction that the bone undergoes. Because the normal relationships of the bones are lost, there is a condition of instability. This refers to one

vertebra moving in an abnormal manner in relation to the next vertebra. To attempt to stabilize this excess motion, bone grows outward. These outward growths are called osteophytes.(Ali Hassan A. Ali^{1,2}, Mohammad Aslam Siddiqui, et al ,2014).

Inflammatory Cervical Spine Disease: Rheumatoid Arthritis- Ankylosing Spondylitis.

Neoplastic Cervical Spine Disease : Metastatic- Primary.

Deformity of the Cervical Spine : This can be caused by a number of conditions, such as congenital anomalies, surgery, osteoporosis, tumor, or inflammatory or degenerative processes. The most common cervical spine deformity is kyphosis.

Infection : Pyogenic Vertebral Body and Disc Infections- Epidural Spinal Abscess.(Jodi Boling, MSN RNCNS CNRN et al , 2007).

2-4 Development of cervical spine :

At birth, the atlas is composed of two bony segments . Between one and two years of age, the cartilaginous anterior arch develops one to several centers of ossification , and by three – four years of age, the anterior arch can be identified as a separate unit of the atlas . The anterior arch closes around the fifth or sixth year of age, and the posterior arch fuses completely by four to five years . The atlas becomes close to its final adult size around age six .

At birth ,the axis (C2) , four separate bones represent the axis: the dens, the centrum, and two longer bones that will eventually

form the neural arch . Around two years of age, the ossiculum terminale, the small portion of bone that becomes the superior most portion of the apex of the dens, begins to ossify and is completely fused to the dens around ten to twelve years of age . Complete fusion for the intradental synchondrosis and posterior synchondrosis occurs around three to four years of age . Also, between third and fifth years of age, the transverse foramina are fully formed on the axis . The complete fusion of the axis occurs around the ages of four to six years, though in some individuals, the odontoid never completely fuses with the rest of the axis. The inferior surface of the centrum fuses completely with the epiphyseal plate around nineteen to twenty years of age.

At birth, each cervical vertebra is represented by two neural arches and one centrum. The neural arches fuse with the centrum proceeding from C3 caudally between the ages of four and six years . Epiphyses appear on the inferior and superior parts of the cervical bodies around 17 years of age, and they completely fuse around 25 years of age.(April. K. Smith ,2010).

2-5 MRI :

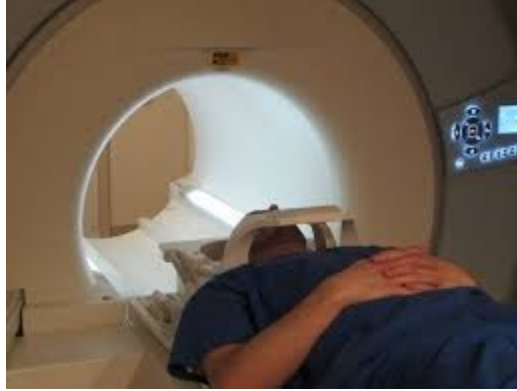


Figure (2-4) MRI machine .

Magnetic resonance imaging (MRI) is a medical imaging procedure that uses strong magnetic fields and radio waves to produce cross-sectional images of organs and internal structures in the body. Because the signal detected by an MRI machine varies depending on the water content and local magnetic properties of a particular area of the body, different tissues or substances can be distinguished from one another in the study image. MRI can give different information about structures in the body than can be obtained using a standard x-ray, ultrasound, or computed tomography (CT) exam. For example, an MRI exam of a joint can provide detailed images of ligaments and cartilage, which are not visible using other study types. In some cases, a magnetically active material (called a contrast agent) is used to show internal structures or abnormalities more clearly. (<http://www.fda.gov/RadiationEmittingProducts/RadiationEmittingProductsandProcedures/MedicalImaging/ucm200086.htm>).

Many MR systems are commercially available, each possessing different features and capabilities that are often difficult to evaluate and compare objectively. Many of these features are based on the operating software provided by the manufacturer, but certain hardware components are common to all systems. The major components are the computer and image processing systems, a magnet system, a gradient system, a radiofrequency system, and a data acquisition system .(MARK A.BROWN,RICHARD C.SEMELKA,1955).

In most MRI devices, an electric current is passed through coiled wires to create a temporary magnetic field around a patient's body. (In open-MRI devices, permanent magnets are used.) Radio waves are sent from and received by a transmitter/receiver in the machine, and these signals are used to produce digital images of the area of interest. Using MRI scans, physicians can diagnose or monitor treatments for a variety of medical conditions, including: Abnormalities of the brain and spinal cord, Tumors, cysts, and other abnormalities in various parts of the body, Injuries or abnormalities of the joints ,Certain types of heart problems, Diseases of the liver and other abdominal organs, Causes of pelvic pain in women (e.g. fibroids, endometriosis), Suspected uterine abnormalities in women undergoing evaluation for infertility . MRI does not use ionizing radiation (high-energy radiation that can potentially cause damage to DNA, like the x-rays used CT scans).There are no known harmful side-effects associated with temporary exposure to the strong magnetic field

used by MRI scanners. However, there are important safety concerns to consider before performing or undergoing an MRI scan: The magnet may cause pacemakers, artificial limbs, and other implanted medical devices that contain metal to malfunction or heat up during the exam, Any loose metal object may cause damage or injury if it gets pulled toward the magnet, If a contrast agent is used, there is a slight risk of an allergic reaction. MRI contrast agents can cause problems in patients with significant kidney disease, Dyes from tattoos or tattooed eyeliner can cause skin or eye irritation, Medication patches can cause a skin burn, The wire leads used to monitor an electrocardiogram (ECG) trace or respiration during a scan must be placed carefully to avoid causing a skin burn and Prolonged exposure to radio waves during the scan could lead to slight warming of the body.

(<http://www.fda.gov/RadiationEmittingProducts/RadiationEmittingProductsandProcedures/MedicalImaging/ucm200086.htm>)

MRI is widely used now to visualize the spinal column and its contents. T1- and T2-weighted images give information about morphology and integrity of discs and vertebrae, the intervertebral foramina and facet joints, and an outline of the spinal cord. The vertebrae have a low-signal outer rim surrounding the high-signal cancellous bone. The basivertebral veins are seen in the posterior midline of the vertebral body. (Malcolm, G.P., 2002). Only MRI is capable of detecting the physiological degenerative change of nucleus pulposus, by

alteration in disc space mri signal intensity. The mri can diagnose cord cavitation and increased signal intensity by Ct cannot do. Evaluation of disc abnormalities in cervical region is also well done with mri it is added advantage of demonstrating any internal physiological degenerative change of disc space than CT. MRI superior to Ct in the diagnosis and characterization of disc herniation. Manifested by loss of normal high MRI disc space signal intensity at one or more cervical interspace level. (Stephen M. Foreman and Arthur C. Croft, 2001).

2-5-1 Neck MRI Technique:

Common indications: Cervical myelopathy, cervical radiculopathy, cervical cord compression or trauma, assessment of extent of spinal infection or tumour, diagnosis of Chiari malformation and cervical syrinx, MS plaques within the cord. (Catherine Westbrook, 2008).

Equipment: Posterior cervical neck coil/volume neck coil/multi-coil array spinal coil, immobilization pads and straps, Pegating if required, Ear plugs. (Catherine Westbrook, 2008).

Patient Positioning: The patient lies supine on the examination couch with the neck coil placed under or around the cervical region. Coils are often moulded to fit the back of the head and neck so that the patient is automatically centred to the coil. If a flat coil is used, placing supporting pads under the shoulders flattens the curve of the cervical spine so that it is in closer proximity to the coil. The coil should extend from the base of the skull to the sternoclavicular joints in order to include the whole of

the cervical spine . The patient is positioned so that the longitudinal alignment light lies in the midline, and the horizontal alignment light passes through the level of the hyoid bone (this can usually be felt above the thyroid cartilage/Adam's apple). The patient's head is immobilized with foam pads and retention straps. Positioning leads are attached if required. (Catherine Westbrook,2008).

2-5-1-1Suggested protocol:

Sagittal/coronal SE/FSE T1 or coherent GRE T2*:

Acts as a localizer if three-plane localization is unavailable. The coronal or sagittal planes may be used.

Coronal localizer: Medium slices/gap are prescribed relative to the vertical alignment light, from the posterior aspect of the spinous processes to the anterior border of the vertebral bodies. The area from the base of the skull to the second thoracic vertebra is included in the image.

P 20 mm

to A 30 mm

Sagittal localizer: Medium slice thickness/gap are prescribed on either side of the longitudinal alignment light, from the left to the right lateral borders of the vertebral bodies. The

area from the base of the skull to the second thoracic vertebra is included in the image.

L 7 mm to R

7 mm

Sagittal SE/FSE T1 (Figure 2.5):

Thin slices/gap are prescribed on either side of the longitudinal alignment light, from the left to the right lateral borders of the vertebral bodies (unless the paravertebral areas are required). The area from the base of the skull to the second thoracic vertebra is included in the image.

L 22 mm to

R mm

Sagittal SE/FSE T2 or coherent GRE T2* (Figure 2.6):

Slice prescription as for Sagittal T1.

Axial/oblique SE/FSE T1/T2 or coherent GRE T2* (Figure 2.9):

Thin slices/gap are angled so that they are parallel to the disc space or perpendicular to the lesion under examination (Figures 2.7 and 2.8). For disc disease, three or four slices per level usually suffice. For larger lesions such as tumour or syrinx, thicker slices covering the lesion and a small area above and below may be necessary.(Catherine Westbook,2008).

2-5-1-2Additional sequences:

Sagittal/axial oblique SE/FSE T1:

Slice prescription as for Axial/oblique T2* with contrast enhancement for tumours.

Sagittal SE/FSE T2 or STIR:

Slice prescription as for Sagittal T2*. An alternative to coherent GRE T2*.

3D coherent/incoherent (spoiled) GRE T2*/T1:

Thin slices and a few or medium number of slice locations are prescribed through the ROI. If PD or T2* weighting is desired, then a coherent or steady-state sequence is utilized. If T1 weighting is required an incoherent or spoiled sequence is necessary. These sequences may be acquired in any plane but, if reformatting is required, isotropic datasets must be acquired.

Sagittal SE/FSE T1 or fast incoherent (spoiled) GRE T1/PD:

Slice prescription as for Sagittal T1, T2 and T2*, except neck in flexion and extension to correlate the potential relevance of spondylotic changes to signs and symptoms.

3D balanced gradient echo (BGRE) (Figure 2.10):

The contrast characteristics of a BGRE sequence provide for high signal from CSF (high T2 / T1 ratio) and thus produces images with high contrast between CSF and nerve roots. It is important to remember that because these images are not true T2 weighted, subtle cord lesions such as MS plaques may not be seen. As such they are typically utilized when

imaging a patient for radiculopathy (disk disease) rather than myelopathy (cord lesions). (Catherine Westbrook,2008).

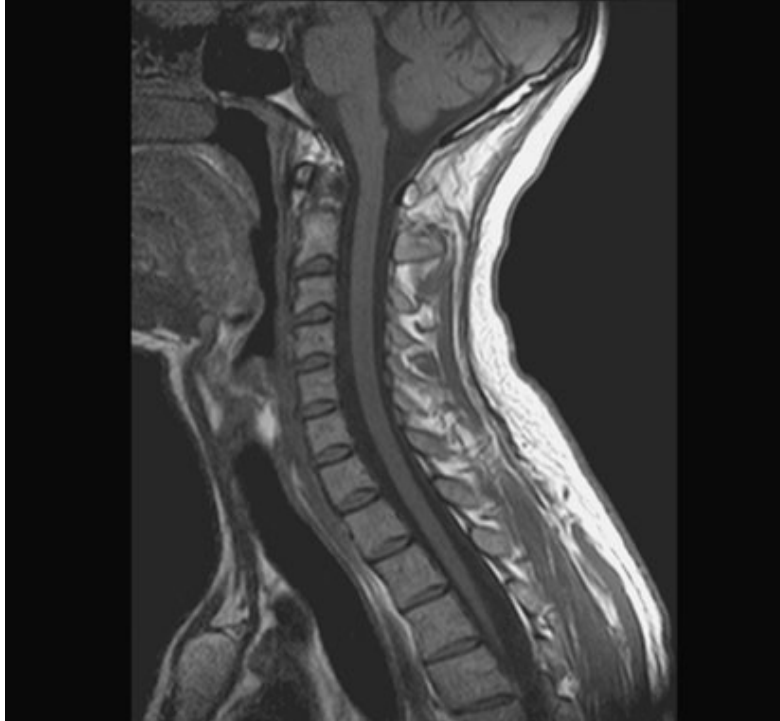


Figure 2.5 Sagittal SE T1 weighted midline image through the cervical spine. (Catherine Westbrook,2008).

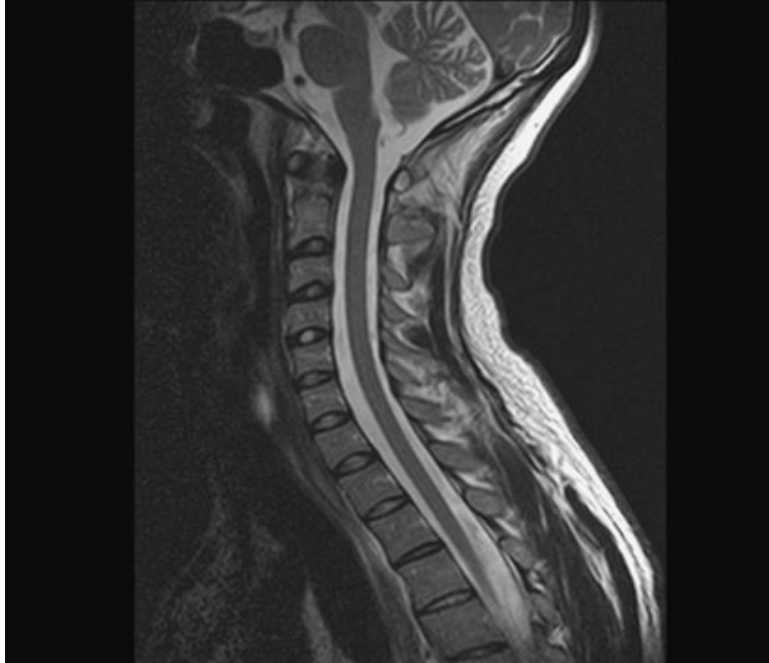


Figure 2.6 Sagittal FSE T2weighted midline image through the cervical cord. (Catherine Westbrook,2008).

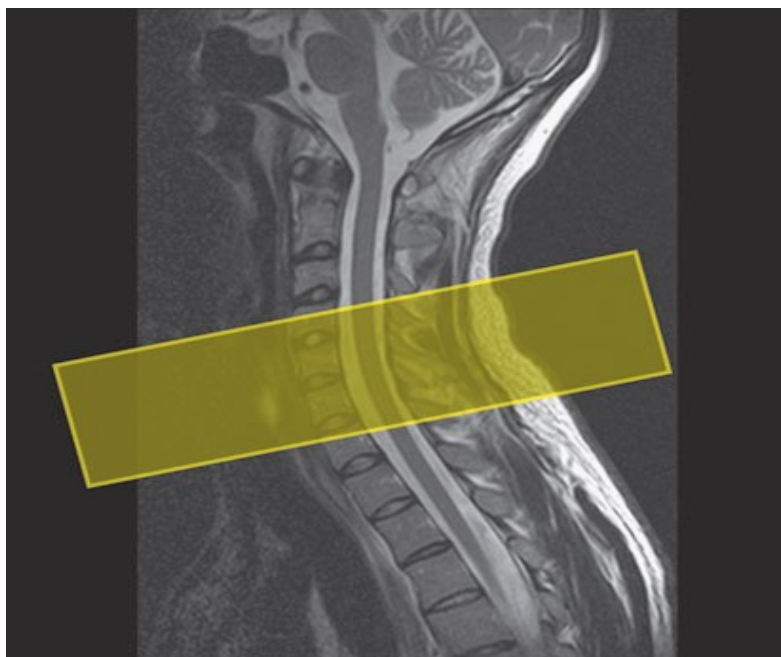


Figure 2.7 Sagittal FSE T2 weighted image showing slice prescription boundaries and orientation for axial imaging of the cervical cord.(Catherine Westbook,2008).

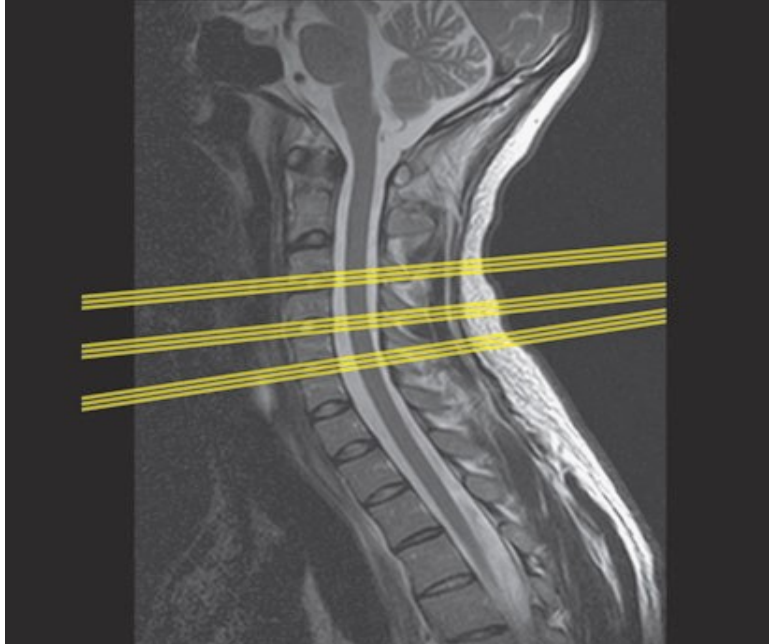


Figure 2.8 Sagittal coherent GRE T2* weighted image of the cervical spine show in axial/oblique slice positions parallel to each disc space. (Catherine Westbook,2008).

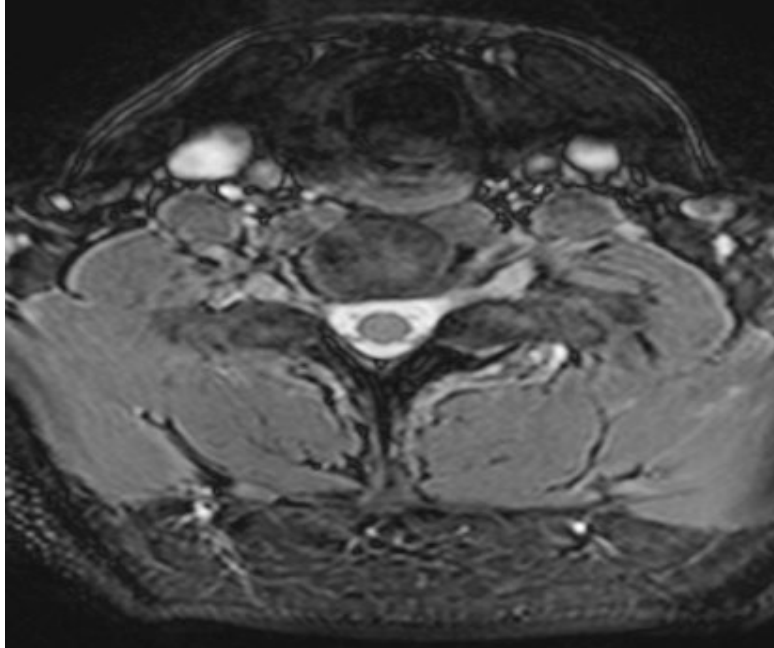


Figure 2.9 Axial/oblique coherent GRE T2* weighted image through the cervical cord. (Catherine Westbrook,2008).

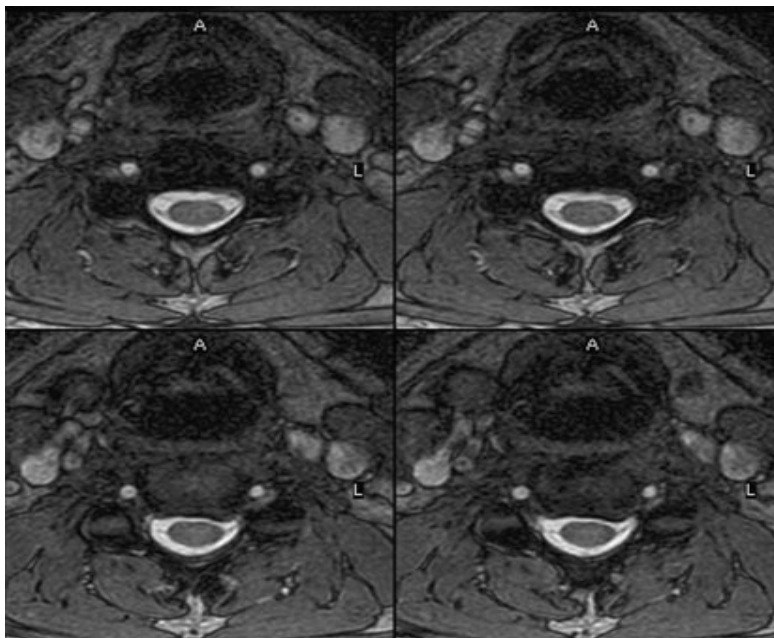


Figure 2.10 Axial balanced GRE through the cervical spine. (Catherine Westbrook,2008).

2-5-1-3 Image optimization:

Technical issues: The SNR in this region is mainly dependent on the quality of the coil. Posterior neck coils give adequate signal for the cervical spine and cord, but signal usually falls off at the anterior part of the neck, so they are not recommended for imaging structures such as the thyroid or larynx. In addition, flare from the posterior skin surface can be troublesome in sagittal T1 imaging, where the large fat pad situated at the back of the neck returns a high signal. Volume coils produce even distribution of signal, but the SNR in the cord is sometimes reduced compared with a posterior neck coil. Multi-coil array combinations commonly produce optimum SNR, and may be used with a large FOV to include the thoracic spine. This strategy is important when pathology extends from the cervical to the thoracic areas of the cord, e.g. syrinx. Spatial resolution is also important, especially in axial/oblique imaging, as the nerve roots in the cervical region are notoriously difficult to visualize. Thin slices with a small gap and relatively fine matrices are employed to maintain spatial resolution. Ideally 3D imaging is used as this allow very thin slices with no gap and the volume may be viewed in any plane. Multiple NEX/NSA are also advisable if the inherent SNR is poor. Therefore, unless FSE is utilized, scan times are often of several minutes duration. Fortunately, rectangular/asymmetric FOV is used very effectively in sagittal imaging as the cervical spine fits into a rectangle with its longitudinal axis running S to I. This facilitates the acquisition of fine matrices in short scan times. With a

reduced FOV in the phase direction, aliasing may be a problem. In sagittal imaging, this artefact originates from the chin and the back of the head wrapping into the FOV. Increasing the size of the overall FOV or utilizing oversampling (if available) may eliminate or reduce this artefact. In addition, spatial presaturation pulses brought into the FOV to nullify signal coming from these structures are effective .

The multiple 180° RF pulses used in FSE sequences cause lengthening of the T2 decay time of fat so that the signal intensity of fat on T2 weighted FSE images is higher than in CSE. This sometimes makes the detection of marrow abnormalities difficult. Therefore, when imaging the vertebral bodies for metastatic disease, a STIR sequence should be utilized.(Catherine Westbrook,2008).

Artefact problems: The cervical area is often plagued with artefact. Not only does aliasing from structures outside the FOV obscure the image, but the periodic, pulsatile, motion of CSF within the spinal canal produces phase ghosting. The speed of flow is usually quite rapid in the cervical region, and therefore conventional flow-reducing measures, such as spatial presaturation and GMN, are less effective than in the lumbar region where CSF flow is slower. On T1 weighted images, spatial presaturation pulses placed S and I to the FOV are usually sufficient. However, on T2 weighted sequences flow artefact is commonly troublesome. In addition, selecting an S-I phase direction along with oversampling can also reduce CSF flow

artifact in sagittal imaging . As FSE sometimes demonstrates more flow artefact than CSE, it is usually not utilized in the cervical spine. This is especially true on T2 weighted images where flow artefact can totally degrade the image. However, in cases where there is severe pathology such as a disc protrusion, FSE often produces images that demonstrate acceptable levels of artefact. This may be because the protruding disc locally slows down the CSF flow. In practice, it is probably worth trying FSE on the T2 images, and only if the artefact is intolerable, repeat the scan using coherent GRE. However, FSE is not commonly recommended in axial/oblique imaging because of flow-related problems. When using coherent GRE T2* sequences, GMN should be implemented as this not only increases the signal from CSF, but also reduces artefact from CSF flowing down the canal within the slice. In addition the use of balanced GRE reduces flow artefact due to the implementation of balancing gradients . This rapid sequence also works well in 3D imaging as a large volume may be acquired in a short scan time. However the conspicuity of nerve roots in the exit foramina may reduce when using a GRE sequence due to the magnetic susceptibility effects. Pe gating minimizes artefact even further but, as the scan time is dependent on the patient's heart rate, it is sometimes rather time-consuming. The implementation of Pe gating is therefore best reserved for cases of severe flow artefact that cannot be reduced to tolerable levels by other measures.

Multiple NEX/NSA reduce artefact from signal averaging, but result in an increase in the scan time. Nevertheless their implementation is often necessary, especially where the SNR is poor, and flow artefact severe. Swallowing during data acquisition is a common source of artifact Spatial presaturation pulses placed over the throat largely eliminate this, but care must be taken not to nullify signal from important anatomy. Another problem in the cervical region is truncation artefact (or Gibbs artefact) that produces a thin line of low signal in the cord and mimics a syrinx. Truncation artefact is reduced by selecting a higher phase matrix. (Catherine Westbrook,2008) .

Patient considerations: Some patients have difficulty placing their neck over the posterior neck coil, especially in cases of fixed deformity. It is important that the neck is as close to the coil as possible to achieve maximum SNR. Placing pads under the patient's shoulders flattens the spine, and therefore positions the back of the neck nearer to the coil. Patients with cervical cord trauma, cord compression, or tumours are often severely disabled. The magnetic safety of any stabilization devices should be established before the examination. Great care must be taken when transferring these patients on to the examination couch, and they should be moved as little as possible . Due to excessively loud gradient noise associated with some sequences, ear plugs must always be provided to prevent hearing impairment. (Catherine Westbrook,2008) .

Contrast usage: Contrast is not routinely given for disc disease. However, in cases of leptomeningeal spread of certain tumours such as medulloblastoma, contrast is invaluable. Other cord lesions such as ependymomas and pinealoblastomas also enhance well with contrast, as do infectious processes and active MS plaques. Bony tumours, especially those that return a low signal on T1 weighted images, enhance with contrast but this often increases their signal intensity so that they are isointense with the surrounding vertebra. Under these circumstances, chemical/spectral presaturation or the Dixon technique should be implemented to reduce the signal from fatty marrow in the vertebral bodies. Inversion recovery sequences that suppress fat (STIR) should not be used in conjunction with contrast, as their inverting pulses may nullify the signal from the tumour that, as a result of contrast enhancement, now has a similar T1 recovery time to fat. (Catherine Westbrook,2008) .

2-6 Previous Studies:

Morio Matsumoto,et al(2012).The Purpose of this study To investigate the frequency of tandem lumbar and cervical intervertebral disc degeneration in asymptomatic subjects. evaluated magnetic resonance imaging (MRI) results from 94 volunteers (48 men and 46 women; mean age 48 years) for age-related intervertebral disc degeneration in the lumbar and cervical spine.the Results MRI indicated degenerative changes in the lumbar spine in 79 subjects (84 %), with decreased disc signal

intensity in 74.5 %, posterior disc protrusion in 78.7 %, anterior compression of the dura in 81.9 %, disc space narrowing in 21.3 %, and spinal canal stenosis in 12.8 %. These findings were more common in older subjects at caudal levels. MRI showed degenerative changes in both the lumbar and cervical spine in 78.7 % of the volunteers. Finally Degenerative findings in both the lumbar and cervical spine, suggesting tandem disc degeneration, was common in asymptomatic subjects. These results provide normative data for evaluating patients with degenerative lumbar and cervical disc diseases.(Morio Matsumoto,et al,2012) .

Another study by W. Brinjikji et al (2014). Degenerative changes are commonly found in spine imaging but often occur in pain-free individuals as well as those with back pain. We sought to estimate the prevalence, by age, of common degenerative spine conditions by performing a systematic review studying the prevalence of spine degeneration on imaging in asymptomatic individuals. selected age groupings by decade (20, 30, 40, 50, 60, 70, 80 years), determining age-specific prevalence estimates. For each imaging finding , we fit a generalized linear mixed-effects model for the age-specific prevalence estimate clustering in the study, adjusting for the midpoint of the reported age interval .the results Thirty-three articles reporting imaging findings for 3110 asymptomatic individuals met our study inclusion criteria. The prevalence of disk degeneration in asymptomatic individuals increased from 37% of 20-year-old individuals to 96% of 80-year-old individuals. Disk bulge prevalence increased from 30% of

those 20 years of age to 84% of those 80 years of age. Disk protrusion prevalence increased from 29% of those 20 years of age to 43% of those 80 years of age. The prevalence of annular fissure increased from 19% of those 20 years of age to 29% of those 80 years of age. finally Imaging findings of spine degeneration are present in high proportions of asymptomatic individuals, increasing with age . Many imaging-based degenerative features are likely part of normal aging and unassociated with pain. These imaging findings must be interpreted in the context of the patient's clinical condition.(W. Brinjikji et al ,2014) .

Another study by Ali Hassan A. Ali¹,et al (2014) , Aim of this work is to evaluate the frequency of age related degeneration in cervical spine in Saudi adult asymptomatic subjects using CT scan images. Methods: In this study, 105 cases of symptomless adults ranging between 18 - 90 years of age were included. The cases were classified into 3 groups; adult group (18 - 35 years old), middle age group (36 - 55 years old) and old age group (56 - 90years old). Their CT scans were performed in the department of radiology, King Khalid Hospital, AlKharj and studied for any age related changes. The Results in first age group category included 35cases; 20 had normal and 15 degenerative changes. The second category included 35 cases; 3 had normal and 32 degenerative changes. The third category included 35 cases. Single had normal and 34 degenerative changes. Finally Asymptomatic degenerative changes are common in the cervical

spine after 30 years of age in Saudi adult asymptomatic subjects.(Ali Hassan A. Ali¹,et al ,2014).

Another study by Kyung Hyun Kim,etal,(2013) All structures of the spine, including the spinal canal, change continuously with age. The purpose of this study was to determine how the spinal canal of the lumbar spine changes with age. The L4/5 is the most common site of spinal stenosis and has the largest flexion-extension motion, whereas the T5/6 has the least motion. Therefore, we measured the spinal canal diameter and vertebral body height at T5, T6, L4, and L5 with age. This was a retrospective study of aged 40 to 77 years. We reviewed whole spine sagittal MRIs of 370 patients with lumbar spinal stenosis (LSS) (Group 2) and 166 herniated cervical disc (HCD) (Group 1). Each group was divided into four age groups, and demographic parameters (age, gender, height, weight, BMI), the mid-spinal canal diameter, and mid-vertebrae height at T5, T6, L4, L5 were compared. Within- and between-group comparisons were made to evaluate changes by age and correlations were carried out to evaluate the relationships between all parameters. The Results of this study Height, weight, and all radiologic parameters were significantly lower in Group 2 than Group 1. Group 1 did not show any differences, when based on age, but in Group 2, height, weight, and T6, L4, and L5 height were significantly decreased in patients in their 70's than patients in their 40's, except for spinal canal diameter. Age was associated with all parameters except spinal canal diameter. Finally Vertebral height decreased with age,

but spinal canal diameter did not change in patients with either LSS or HCD. Mid-spinal canal diameter was not affected by aging(13) Kyung Hyun Kim,etal,(2013). M Ishikawa1,et al (2003), The aim of this study To elucidate the age-related changes of the cervical spinal cord and the cervical spinal canal and the relationship between the spinal cord and the spinal canal in asymptomatic subjects using MRI and radiography Setting in Tokyo, Japan.Uses The transverse area of the cervical spinal cord and the ratio of the anteroposterior diameter to the transverse diameter (RAPT) were investigated, using MRI in 229 asymptomatic subjects. The sagittal spinal canal diameter and anteroposterior diameter of the cervical vertebral body were also measured on plain lateral radiographs. The canal body ratio (CBR), which was defined as the diameter of the spinal canal divided by that of the vertebral body, was calculated. Results The transverse spinal cord area correlated negatively with age. RAPT did not correlate with age. The CBR correlated negatively with age. The correlation between spinal cord area and CBR was significant but weak and the correlation between RAPT and CBR was not significant. Finally The transverse area of the cervical spinal cord measured by MRI decreased with age, while RAPT remained unchanged. The bony spinal canal became narrower with age. The spinal cord area and the shapes of the spinal cord were independent from the spinal canal diameter in asymptomatic subjects. These facts should be considered when

evaluating radiological findings in patients with cervical spinal disorders.(M Ishikawa¹,et al ,2003) .

Another study by Matsumoto,et al)1997(, this studied degenerative changes in the cervical intervertebral discs of 497 asymptomatic subjects by MRI and evaluated disc degeneration by loss of signal intensity, posterior and anterior disc protrusion, narrowing of the disc space and foraminal stenosis. In each subject, five disc levels from C2-C3 to C6-C7 were evaluated. The frequency of all degenerative findings increased linearly with age. Disc degeneration was the most common observation, being present in 17% of discs of men and 12% of those of women in their twenties, and 86% and 89% of discs of both men and women over 60 years of age. We found significant differences in frequency between genders for posterior disc protrusion and foraminal stenosis. The former, with demonstrable compression of the spinal cord, was observed in 7.6% of subjects, mostly over 50 years of age. The results should be taken into account when interpreting the MRI findings in patients with symptomatic disorders of the cervical spine.(Matsumoto M, Fujimura Y, etal,1997).

And Frode Kolstad ,etal,(2005), this Descriptive study comparing MRI classifications with measurements from radiographs. The aims is Define the relationship between MRI classified cervical disc degeneration and objectively measured disc height. and Assess the level of inter- and intra-observer errors using MRI in defining cervical disc degeneration. Cervical spine degeneration

has been defined radiologically by loss of disc height, decreased disc and bone marrow signal intensity and disc protrusion/herniation on MRI. The intra- and inter-observer error using MRI in defining cervical degeneration influences data interpretation. Few previous studies have addressed this source of error. The relation and time sequence between cervical disc degeneration classified by MRI and cervical disc height decrease measured from radiographs is unclear. The MRI classification of degeneration was based on nucleus signal, prolaps identification and bone marrow signal. Two neuro-radiologists evaluated the MR-images independently in a blinded fashion. The radiographic disc height measurements were done by a new computer-assisted method compensating for image distortion and permitting comparison with normal level-, age- and gender-appropriate disc height. Finally Progressing disc degeneration classified from MRI is on average significantly associated with a decrease of disc height as measured from radiographs. Within each MRI defined category of degeneration measured disc heights, however, scatter in a wide range. and The inter-observer agreement between two neuro-radiologists in both defining degeneration and disc height by MRI was only moderate. Studies addressing questions related to cervical disc degeneration should take this into consideration. (Frode Kolstad ,etal, 2005).

Chapter Three

Materials and methods

This study is a retrospective study, carried out to measure certain structure in Cervical Spine using MRI Image, as well as to Evaluation Of Age - Related Changes In Cervical Spine In Khartoum state Adult population using MRI .

3-1Materials:

3-1-1 the patients:

263 adult patients their age ranged from 20 to 90 with mean age of 47years used in this study.

Children, pregnancies women & patients come with abnormal Cervical (trauma, tumor, fracture) were excluded from this study.

Pregnancies were contraindicated to MRI. Children were excluded because MRI for them faced many problems, one of important problem is that images prone to motion artifacts which treated either by repeated the exam or used fast protocols which differ from protocols used in the study .Patients with abnormal cervical are contraindicated because the measure of structure is not accurate.

All patients were informed and agreed that the information from their exam will be used in this study.

3-1-2 the machine:

Material used in this study was, MRI machine General Electric MR Scanner with Field Strength 1.5 Tesla , 8Chanal Coil

3-2Methods:

3-2-1 duration and place of study:

This study was conducted in Khartoum state in Modern Medical Center, during the period of 2015. 263 patients with normal cervical spine were studied for measure cervical spine changes.

3-2-2 positioning technique used in this study:

Cervical MRI Technique: The patient lies supine on the examination couch with the neck coil placed under or around the cervical region. Coils are often moulded to fit the back of the head and neck so that the patient is automatically centred to the coil. If a flat coil is used, placing supporting pads under the shoulders flattens the curve of the cervical spine so that it is in closer proximity to the coil. The coil should extend from the base of the skull to the sternoclavicular joints in order to include the whole of the cervical spine. The patient is positioned so that the longitudinal alignment light lies in the midline, and the horizontal alignment light passes through the level of the hyoid bone (this can usually be felt above the thyroid cartilage/Adam's apple). The patient's head is immobilized with foam pads and retention straps. Pe gating leads are attached if require. (Catherine Westbook ,2008).

3-2-3 (Measurements):

Certain Structure were traced and measured using computer, the measurements were obtained in millimeters:

The height of intervertebral disc C₅/C₆ and body of cervical spine C₆ were measured from mid line in sagittal T₂ cervical spine MRI, also the diameter of cervical body and spinal canal from mid line at level of C₆ in sagittal T₂ cervical spine MRI and determine the relation between these variable and cervical spine degenerative changes using MRI

3-2-4 data analysis:

The data were analyzed using mean value and the standard deviation, as well as the *p*-value to detect the degree of significance using SPSS(Social program for statistical analyses) .

Chapter Four

Results

This study includes 263 cervical MRI that were used to collect the data by measuring 5 variables in sagittal cervical spine MRI(1- height of disc c₅/c₆, 2- height of body c₆ ,3- diameter of body c₆, 4- diameter of canal at level of c₆, 5-Torg ratio). The results included the mean and standard deviation of the variables as well as relationship between many structure. The results of the std error mean was also been presented.

Table(4-1) showed statistical values of vertebral measurement data for 263 cervical MRI.

Variables	Min	Max	Mean	Std. Deviation
Age	21.0	85.0	47.34	14.58
Height of disc	1.11	8.50	6.19	1.08
Height of body	5.82	15.92	9.43	1.40
Diameter of body	10.30	22.54	14.96	1.90
Diameter of canal	5.92	17.84	11.79	1.75
Torg ratio	26.26	158.58	80.56	17.92

Table (4-2) Showed mean and std of Torg ratio in each age classes.

Age group	Mean	Std
20-29	89.62	17.36
30-39	85.5	16.27
40-49	79.52	17.24
50-59	79.91	19.89
Over 60	73.706	17.18

Table (4-3) a frequency table Show the frequency distribution and percent of 263 patient age.

Age group	Frequency	Percent
20-29	28	10.6
30-39	61	23.2
40-49	61	23.2
50-59	51	19.4
60-69	34	12.9
70-79	26	9.9
80-89	2	.8
Total	263	100.0

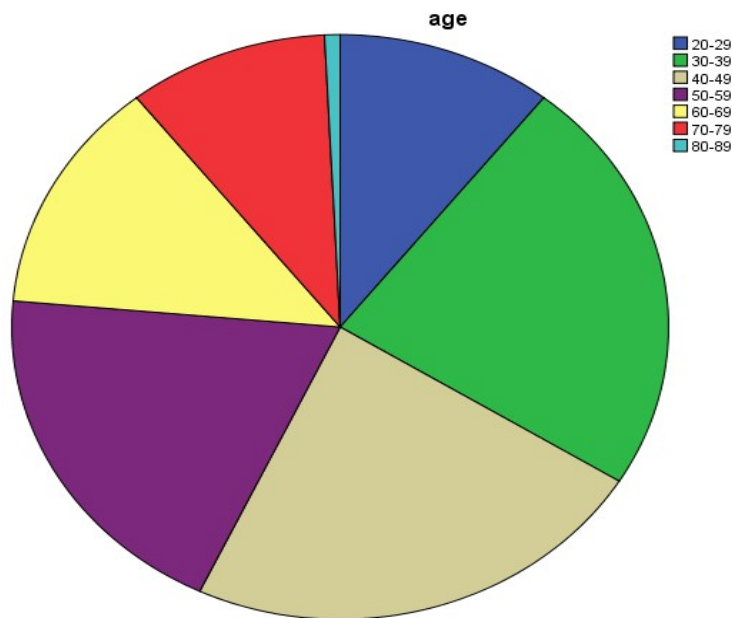


Figure (4.1): Pie Chart Show the proportion or percent of each age class

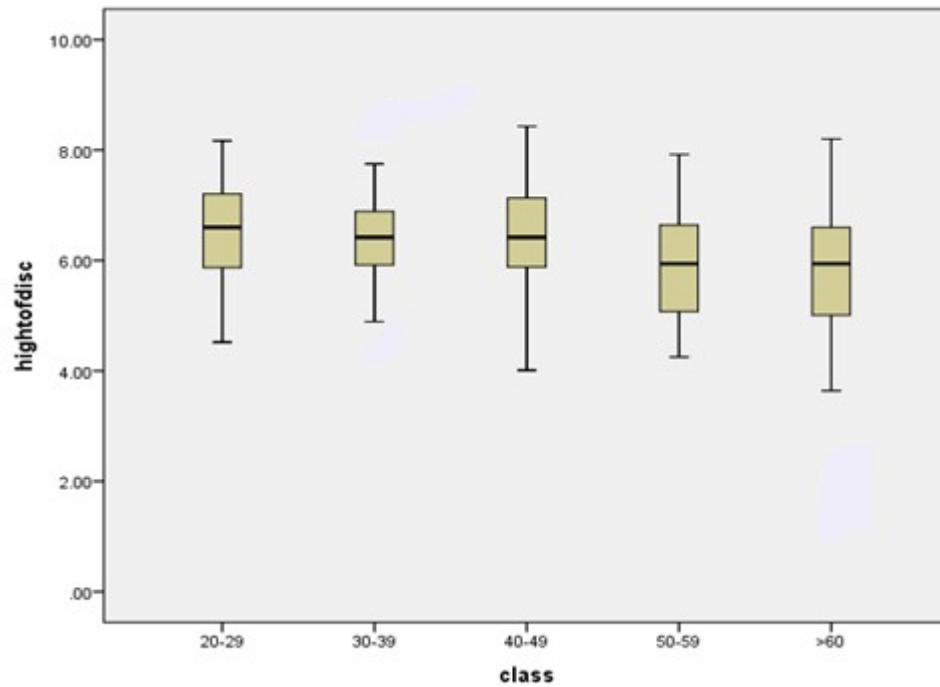


Fig.(4-2) simple box-plot demonstrate the age classes and the hieght of disc at any class.

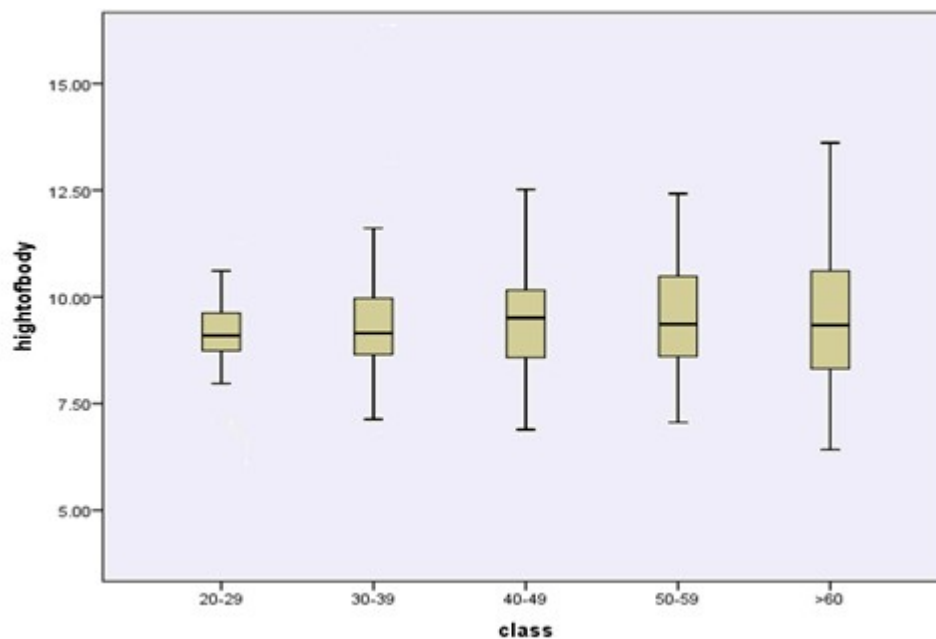


Fig.(4-3) simple box-plot demonstrate the age class and the height of body at any class.

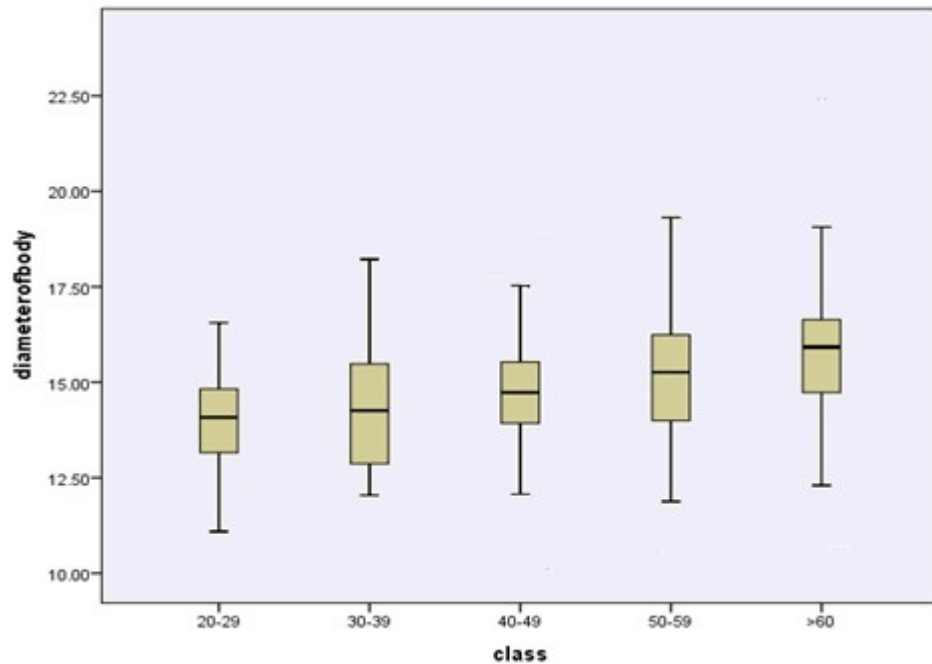


Fig.(4-4) simple box-plot demonstrate the age classes and the diameter of body at any class.

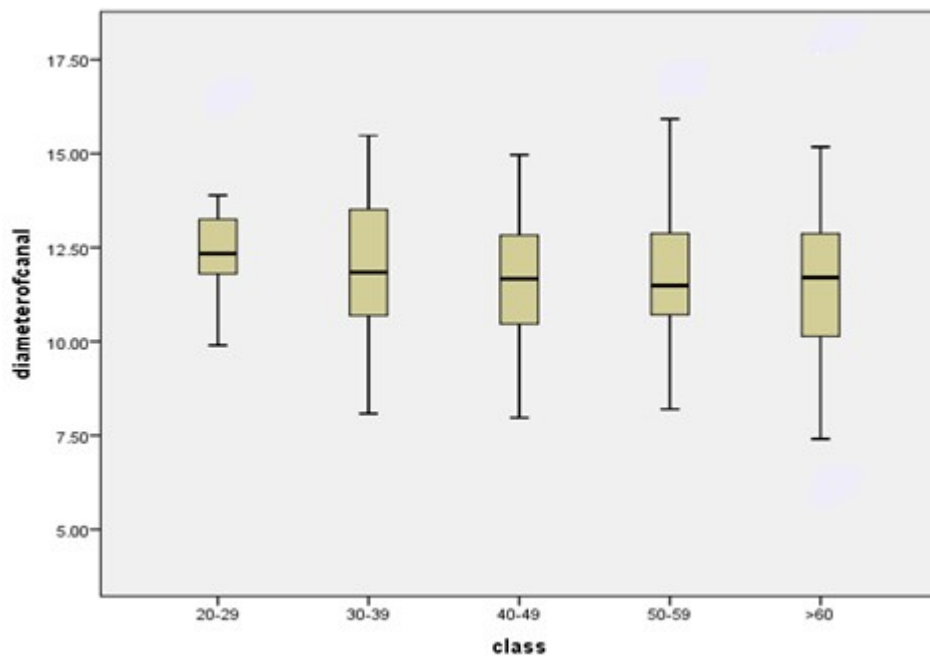


Fig.(4-5) Showed simple box-plot demonstrate age classes and the diameter of canal at any class.

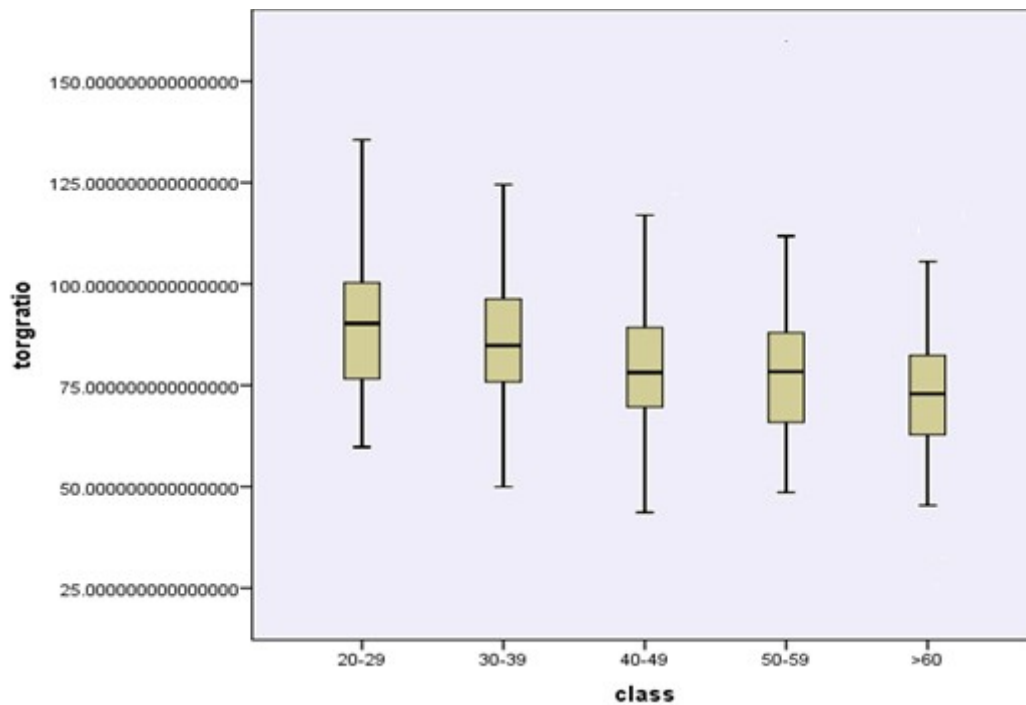


Fig.(4-6) simple box-plot demonstrate the age classes and the torg ratio at any class.

Table (4-4) ANOVA Test show differences test in mean of these measured values with each Age class ,Confidence level of 95% ,
 $p= 0.05$

ANOVA

		Sum of Squares	Df	Mean Square	F	Sig.
Height of disc	Between Groups	26.099	4	6.525	6.080	.000
	Within Groups	276.857	25	1.073		
	Total	302.956	29			
Height of body	Between Groups	8.809	4	2.202	1.131	.342
	Within Groups	502.547	25	1.948		
	Total	511.357	29			
Diameter of body	Between Groups	117.913	4	29.478	9.207	.000
	Within Groups	826.009	25	3.202		
	Total	943.922	29			
Diameter of canal	Between Groups	21.604	4	5.401	1.780	.133
	Within Groups	782.807	25	3.034		
	Total	804.412	29			
Torg ratio	Between Groups	6964.784	4	1741.196	5.822	.000
	Within Groups	77161.373	25	299.075		
	Total	84126.157	29			

Table (4-5):Correlation between five variable

		Diameter of body	Diameter of canal	Age	Heigh t of disc	Height of body	Torg ratio
Diamet er of body	Pearson	1	-.303**	.372**	-.032	.251	-.762**
	Correlation Sig. (2- tailed)		.000	.000	.607	.000	.000
	N	263	263	263	263	263	263
Diamet er of canal	Pearson	-.303**	1	-.134*	.124*	-.003**	.824
	Correlation Sig. (2- tailed)	.000		.030	.044	.958	.000
	N	263	263	263	263	263	263
Age	Pearson	.372**	-.134*	1	-.283*	.095**	-.291*
	Correlation Sig. (2- tailed)	.000	.030		* .000	.123	.000
	N	263	263	263	263	263	263
Height of disc	Pearson	-.032	.124*	-.283*	1	-.155	.062*
	Correlation Sig. (2- tailed)	.607	.044	* .000		.012	.317
	N	263	263	263	263	263	263
Height of body	Pearson	.251**	-.003	.095	-.155*	1**	-.125
	Correlation Sig. (2- tailed)	.000	.958	.123	.012		.043
	N	263	263	263	263	263	263
Torg ratio	Pearson	-.762**	.824**	-.291*	.062	-.125**	1**
	Correlation Sig. (2- tailed)	.000	.000	* .000	.317	.043	
	N	263	263	263	263	263	263

Chapter Five

Discussion, Conclusion and Recommendations

5-1 Discussion:

This study was conducted To measure cervical spine changes and data were collected from the Modern Medical Center during 2015 year for 263patient with normal MRI cervical spine scan.

The measurements of variables were done by computer and was measured in (mm) to find out the suitable method to measure changes in cervical spine with age.

These variables measure were Age ,Height of disc ,Height of body ,Diameter of body ,Diameter of canal and Torg ratio. The mean \pm STD value was (47.34 ± 14.58) , (6.19 ± 1.08) , (9.43 ± 1.40) , (14.96 ± 1.90) , (11.79 ± 1.75) , (80.56 ± 17.92) respecitly .and these values were compared To normal value according Kyung Hyun Kim, et al ,(2013) and Morio Matsumoto , et al (2012) ,and we noted that Torg ratio(=diameter of canal /diameter of body) was higher value in Table (4-1) when Torg ratio $<.80$ were widely accepted as indicative of cervical spinal stenosis (NiKi Matveeva, et al 2013) this result may explain spinal canal stenosis due to changes mostly in older age over 60. (73.706 ± 17.18) show in Table (4-2).

The changes in the aging usually occur in movable structures and bony vertebrae also change significantly , usually decreasing in height and broadening and vertebrae body was posteriorly wedging with age, and this study were grouped the population

Age into five class and in this study showed most Age frequency was 30-39 (61patient ,23.2%) with same result for 40-49 (61 patient , 23.2%) as in Table(4-3) figure(4-1) .

The most effect age group was over 60 showed decrease in height of disc and Torg ratio and increase in diameter of body of cervical spine this result similar many studies such as study were done by (Morio Matsumoto,et al,2012) and (W. Brinjikji et al , 2014).

A significant are way ANOVA Test was performed to Test the differences in mean of these measured values with each Age class ,Confidence level of 95% , $p= 0.05$

The result showed that A significant difference was noted between (Height of Disc -Age) ,(Diameter of Body -Age) at ($P=0.000$) respectily that due to degenerative change in cervical spine in Table(4-4).

The Diameter of Body have indirect relationship with Diameter of Canal which decreased By 0.303 for every one MM increate diameter of body .at $P=0.000$.this results may explain By If the narrow spinal canal in degenerative LSS is associated with aging, degenerative LSS is degenerative disease. However, if the narrow spinal canal in degenerative LSS is not associated with aging, it appears to be logical to change the definition of degenerative LSS which reflects the genetic cause (Kyung Hyun Kim ,et al ,(2013)). As so on diameter of canal narrow due to degenerative changes of body cervical spine that effect by aging. In Table(4-5).

The Diameter of Body has indirect relationship with Height of Disc which decreased By 0.032 for every one MM increase Diameter of body .And The Height of Disc has indirect relationship with height of body which decreased By 0.155 for every one mm increase height of body .this result explain narrow of disc space due to Age .in Table (4-5).

5-2 Conclusion

This study aimed to measurement of cervical spine to evaluate cervical spine changes with Age By MRI. The data were collected from 263 Cervical spine MRI scanned with General electric MR scanner, strength 1.5 Tesla. This study tested in modern medical center(Khartoum, Sudan) during period of 2015 year. The collect data analysis by Microsoft Excel and SPSS program version.

Measure five variables (Height of disc ,Height of body ,Diameter of body ,Diameter of canal and Torg ratio) The mean \pm STD value was (47.34 \pm 14.58), (6.19 \pm 1.08),(9.43 \pm 1.40),(14.96 \pm 1.90), (11.79 \pm 1.75),(80.56 \pm 17.92) respecitly.

The most effect age group was over 60 showed decrease in height of disc and Torg ratio and increase in diameter of body of cervical spine.

This study fined there are significant indirect relationship between these variable The spinal canal decreased by 0.303 for every one MM increate diameter of body, Height of disc decreased by 0.032-0.155 for every one mm increate Diameter of body, height of body respectively.

Therefore conclusion of this study The degenerative change of cervical spine related to age and especially in older patient .

5-3 Recommendations:

- ✓ Take measurement only on T2 Sagittal cervical MRI Although T2 sagittal images provide fundamental information for assessing cervical disc degeneration, the lack of T2 axial images might limit the diagnostic accuracy of the MR images in detecting degenerative changes. Especially, diagnosis of spinal canal stenosis could have been made better on axial images than on sagittal images.
- ✓ Method measurement of canal the best measure from the midpoint between the vertebral body's superior and inferior endplates to the spinolaminar line we measure the C.S.F column to avoid damage of bone with age.
- ✓ Use other variables like weight and length of patients to accurate measure changes in cervical spine .

References:

Ali Hassan A. Ali,et al(2014), Evaluation of Age Related Changes in Cervical Spine in Saudi Arabian Adult ,Population: Using CT Scan Images, Forensic Medicine and Anatomy Research, 2014, 2, 28-36

April. K. Smith ,2010 , Aging of the lumbar vertebrae using known age and sex sample , Georgia state university scholar work @ Georgia state university ,page 3-5

Catherine Westbrook ,(2008)Handbook of MRI Technique, 3rd edition, Part2,140-149

Frode Kolstad ,etal,in 2005, Degeneration and height of cervical discs classified from MRI compared with precise height measurements from radiographs, Aug 30th, 2005//Vol. 55 Iss. 3//pgs. 415-420

<http://www.fda.gov/RadiationEmittingProducts/RadiationEmittingProductsandProcedures/MedicalImaging/ucm200086.htm>

http://www.physio-pedia.com/Cervical_Vertebrae

Jodi Boling,MSN RNCNS CNRN,etal 2007,Cervical Spine Surgery AGuide to preoperative and postoperative patient care, AANN American Association of Neuroscience Nurses 4700W.LAKE avenue Glen view ,IL 60025 -1485 888/557-2266,Page 12-18

Kyung Hyun Kim, et al,(2013) , Changes in Spinal Canal Diameter and Vertebral Body Height with Age , Yonsei Med J 54(6):1498-1504

M Ishikawa1,etal, Changes of cervical spinal cord and cervical spinal canal with age in asymptomatic subjects, Spinal Cord (2003) 41, 159 ± 163

Malcolm, G.P. (2002) Surgical Disorders of the Cervicalspine: Presentation and Management of Common Disorders,*Journal of Neurology, Neurosurgery & Psychiatry*, **73**, i34-i41

Matsumoto M ,Okada E,etal,2013,Tandem age-related Lumber and Cervical intervertebral disc change in asympomatic subject,Eur Spine J(2013) 22:708-713

MARK A.BROWN,RICHARDC.SEMELKA,1955,MRI Basic principles and Application,3rd edition,Chapter 14,202

Stephanie Ryan,etal,2004,Anatomy for Diagnostic Imaging,The Spinal Colum,2ndedition,Chapter3,85-95

Stephen M.foreman and Arthur C.croft ,Whiplash injuries:The cervical Acceleration/Deceleration syndrom ,third edition,USA, 2001,265

W.Brinji,etal,2014,Systematic Literature Review of Imaging Features of spinal Degeneration in Asymtomatic Population, November 27, 2014 as 10.3174/ajnr.A4173

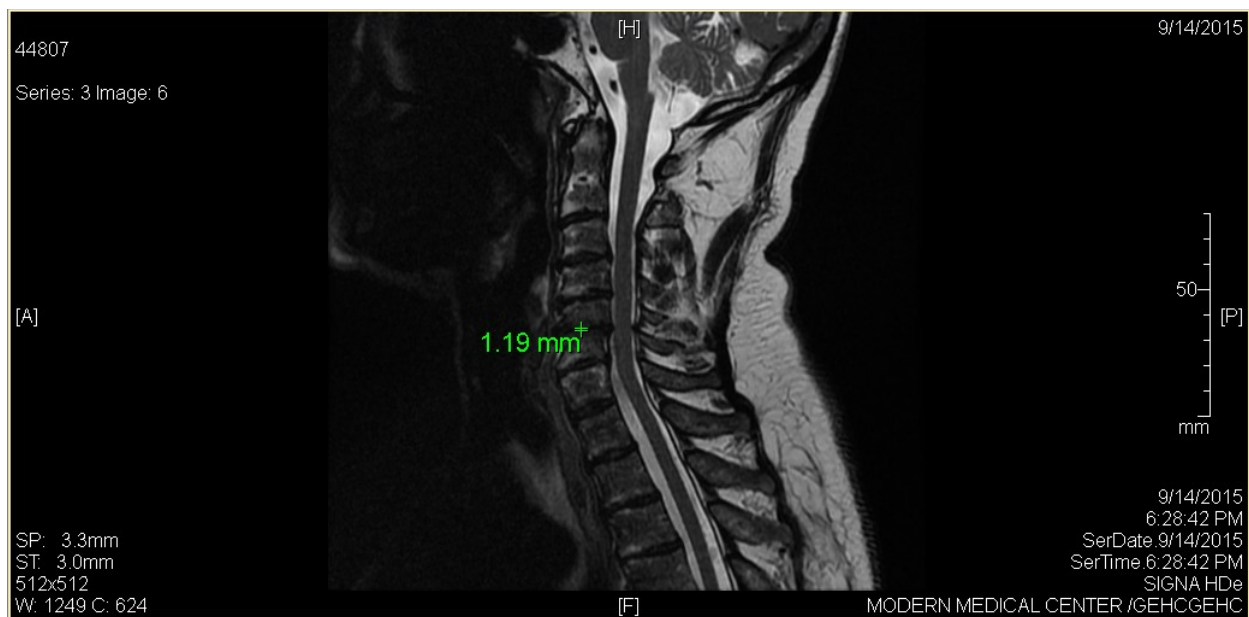
Matsumoto M, Fujimura Y,etal,1997,MRI of cervical intervertebral discs in asymtomatic subjects,J Bone Joint Surge[Br]1998;80:B:19-24

Appendices

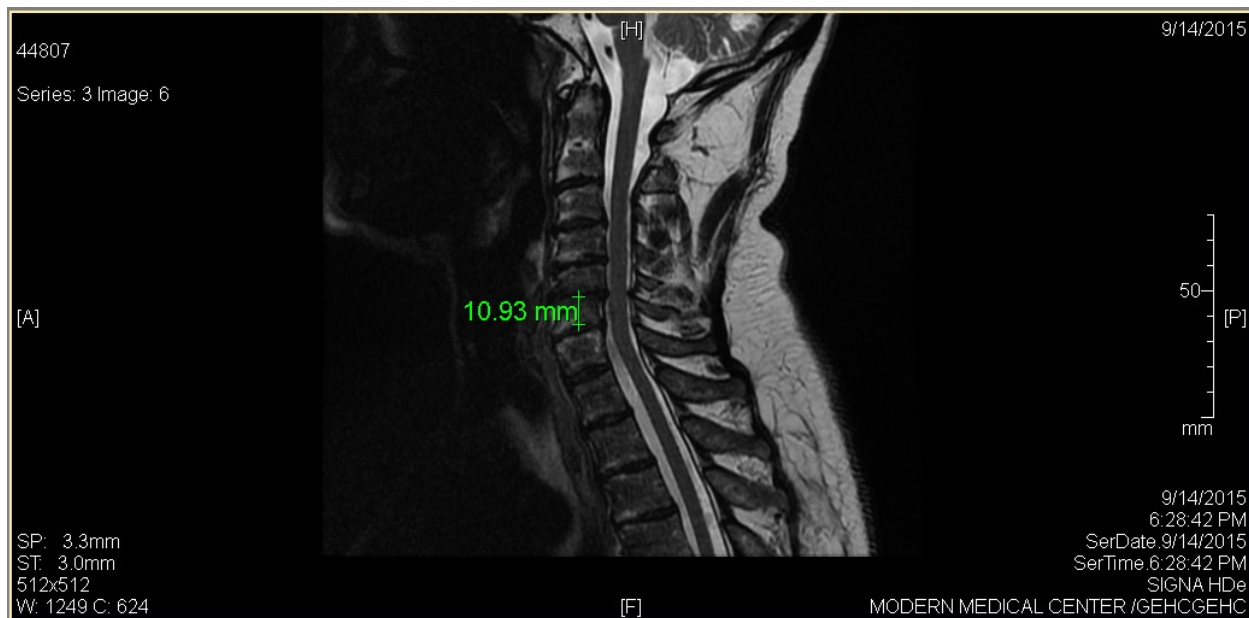
Appendix 1 : Show data sheet

Pt No	Gende r	Age	Height of disc	Height of body	Diamet er of body	Diamet er of canal	Torg ratio
--------------	--------------------	------------	---------------------------	-------------------------------	----------------------------------	-----------------------------------	-----------------------

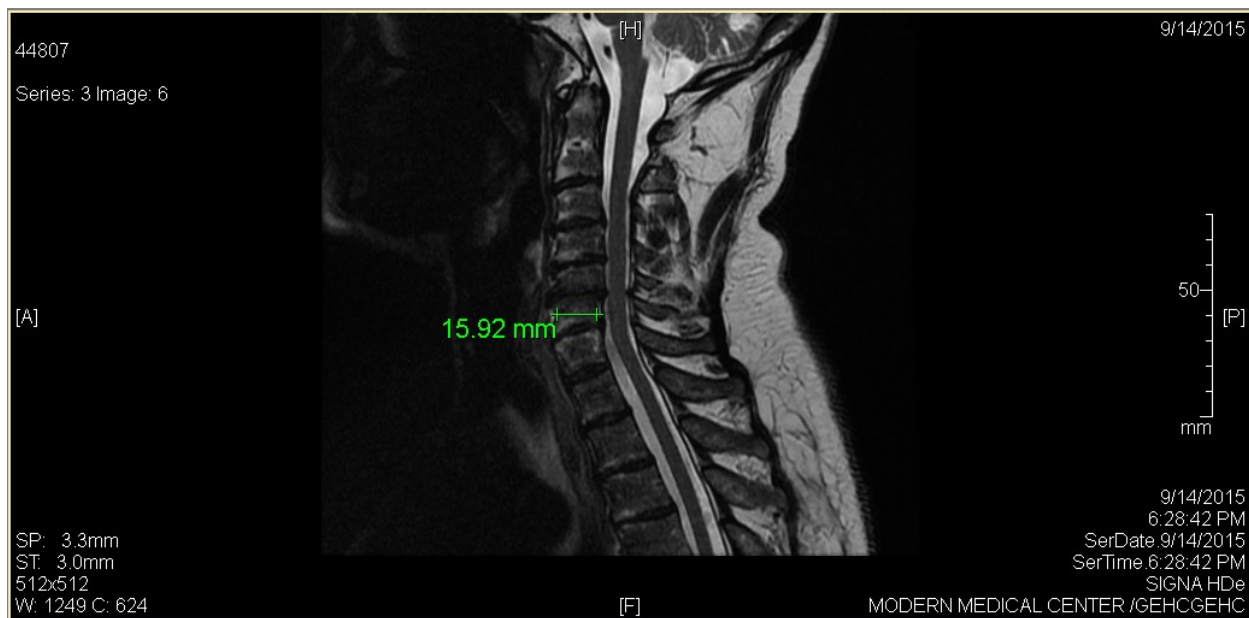Appendix 2 : Sagittal MRI Show measure of cervical spine disc



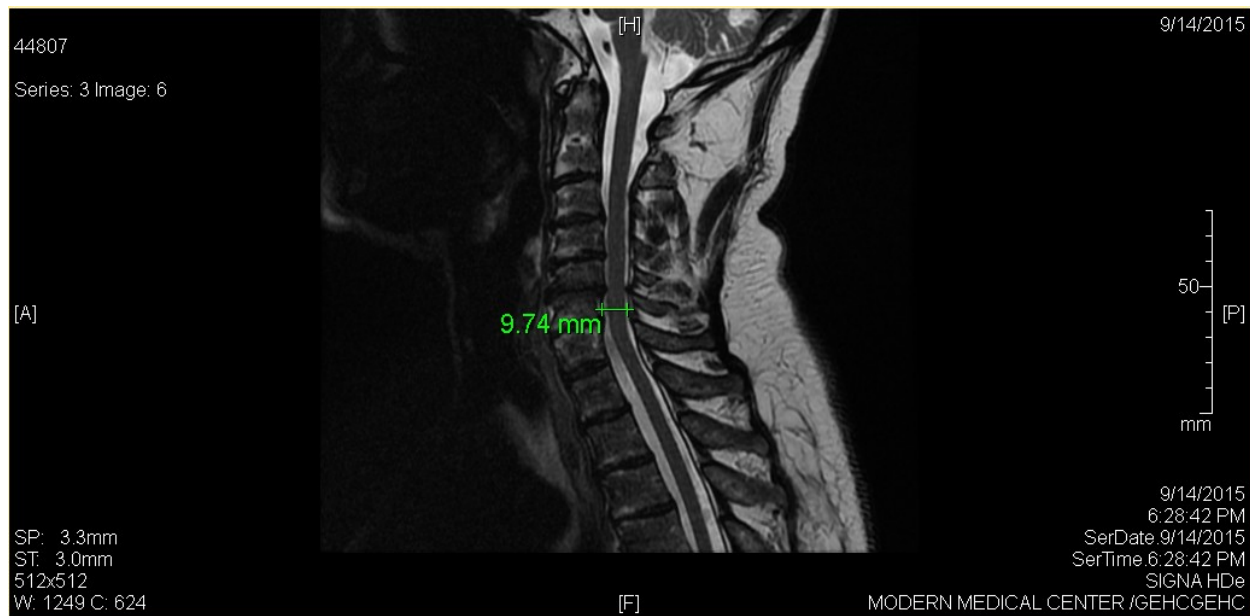
Appendix 3: Sagittal MRI Show measure height of cervical spine body



Appendix 4: Sagittal MRI Show measure diameter of cervical spine body



Appendix 5: Sagittal MRI Show measure spinal canal of cervical spine



Appendix 6: Report of Cervical MRI

Patient.....	ID	44807	Age	65
Date 2015/09/14				
Ref by				

MRI OF CERVICAL SPINE +CONTRAST

Procedure :T1_{wt}, T2_{wt}, in sagittal & Axial T2 cuts + Myelography .

Findings :

- Normal alignment of the cervical spine without subluxation .
- Multilevel disc degeneration with small posterior disc herniation and marginal osteophytes ,indenting the thecal sac & encroaching into neural foraminae bilaterally .
- Normal dimensions and signal intensity of the cervical cord without myelomalacia ,syrinx formation or intra- medullary mass lesion .
- The spinal canal dimensions are within normal limits .
- Advanced degenerative spondylitic changes of the cervical vertebrae .
- Normal atlanto-axial articulations.
- Normal cervico-medullary junction .
- Normal paravertebral soft tissue structures are noted .
- No pathological enhancement detected a fter gadolinium administration .

Impression :

- Multilevel degenerative small posterior disc herniation .
- Advanced cervical spondy losis.