

Chapter One

1.1 Introduction

Diagnostic ultrasound had been used in obstetric nearly 30 years

Although generally consider safe. There is continuing study and research to confirm this. It's a very important technique for examining pregnant women and can be used when clinically indicated at any time during pregnancy, (palmer 1995)

Prediction of gestational age (GA) based on sonographic fetal parameters is perhaps the cornerstone in modern obstetrics and continues to remain an important component in the management of pregnancies with fetuses who have growth disturbances. The cerebellar diameter (CD) serves as a reliable predictor of GA in the fetus and is a standard against which aberrations in other fetal parameters can be compared, especially when the GA cannot be determined by the date of the last menstrual period or an early pregnancy scan, (Hata 1989 and Reece 1987)

There is study evidence an association between the dimensions of the fetal cerebellum, especially the CD and GA, Furthermore, it has been shown that there is a close relationship between CD and GA (correlation coefficient (r) = 0.94 and $p < 0.001$), with CD increases linearly from 15 to 40 weeks. Therefore, based on our findings and taking into account the present state of the art on this issue, the CD fetal ultrasound could be a predictive biometric parameter of GA in the last two trimesters of a pregnancy. The present data offer the normal range of cerebral measurements throughout gestation. These values may allow intrauterine assessment of the development of the cerebellum as well as the posterior fossa. (Mustafa et al 2013)

The cerebellum on ultrasound is s dumb-bell-shaped and consist of two circular hemispheres and separated centerally by the more Hyperechoic triangular shaped vermis. The CD ahs been used as one of the parameters in estimating fetal gestational age in second trimester ; it has been shown that the CD in millimeters is numerically equivalent to number of

weeks of gestation of the pregnancy in second trimester.
(Choudleing and Thilaganathan 2004)

But as any anatomical structures in the body, many diseases can alter the normal anatomical configuration of the cerebellum make it difficult to use it for CD measurement and thus estimating the fetal age.

1.2 Problem of the study:

In addition to traditional biometry including biparietal diameter (BPD), head circumference (HC), abdominal circumference (AC) and femur length (FL), the accuracy of GA estimation of GA using this parameter in late trimester all the time was low, however the accuracy of some of these parameters is affected by growth abnormalities. Cerebellar diameter (CD) is emerging as a new non-traditional sonographic parameter and is claimed to be more accurate in certain situations like extremes of growth abnormalities and variations of fetal head shape such as dolicocephaly and brachycephaly.

There for finding Sudanese index will facilitate the use of Cerebellar diameter (CD) as routine parameter for GA estimation.

1.3.1 Objectives

The general objective is to estimate the gestational age using cerebellar diameter by ultrasound in Sudanese pregnant ladies to overcome limitation of other parameter using to estimate the gestational age.

1.3.2 Specific objective to:

Measure cerebellar diameter (CD) in second and ➤
.third trimester

Correlate between cerebellar diameter (CD) and gestational age (G.A) using last menstrual period (LMP).

Estimate gestational age (G.A) by cerebellar ➤
.(diameter (CD

Estimate gestational age (G.A) by cerebellar ➤
.(diameter (CD) and biparietal diameter (BPD

Find significant difference between (GA) using ➤
cerebellum diameter (CD) and last menstrual period
(LMP), cerebellum diameter (CD) and biparietal
diameter (BPD), cerebellum diameter (CD) and femur
length (FL)

Find the relation between cerebellum diameter ➤
(CD) and biparietal diameter (BPD)

1.4 Significant of the study

This study will highlight the application of cerebellum diameter as one of the crucial factor in gestational age estimation for Sudanese pregnant lady. And hence it will provide a Sudanese index that can be incorporated in an indigenous equation, which will fit their ethnic diversity.

1.5 Overview of the study

This study is concerned with estimation of gestational age using cerebellar diameter by ultrasound in Sudanese pregnant ladies, it falls into five chapters. Chapter one is an introduction, which include problem of the study, statement of the objective and Significant of the study Chapter two

include comprehensive scholarly literature review and anatomical background concerning the previous studies. Chapter three deals with the methodology, where it provides an outline of material and methods used to acquire the data in this study as well as the method of analysis approach. While the results were present in chapter four, and finally Chapter five include discussion of the results, conclusion and recommendation followed by references and appendices.

Chapter two

Literature review

2.1 anatomy of the Cerebellar

The cerebellum develops from the alar plates of the metencephalon. The dorso lateral part of the alar plates bends medially to form the right and left “rhombic lips” which will form the cerebellum.

The rhombic lip have two parts, an intra-ventricular part which projects partly into the lumen of 4th ventricle and an extra-ventricular part which projects above the attachment of the roof plate

Immediately below the mesencephalon the two rhombic lips approach each other in the midline, become compressed and form a “cerebellar plate”.

When the embryo is 12 week old, the cerebellum plate differentiates into a small median part called the “vermis” and two lateral expansions called the “cerebellar hemisphere”. A deep fissure soon arises and separates a part of the cerebellar called the flocculo-nodular lobe from the remaining part of the cerebellar, (Rumack 2011)

Flocculo-nodular lobe is the most primitive part of the cerebellar and is connected with the vestibular system. As development proceeds, many other fissures appear give the cerebellum it’s adult appearance (El-Rakhawy 2000)

2.1.1 Cerebellum

The cerebellum lies within the posterior cranial fossa beneath the tentorium cerebelli. It is situated posterior to the pons and the medulla oblongata. It consists of two hemispheres connected by a median portion, the vermis. The cerebellum is connected to the midbrain by the superior cerebellar peduncles, to the pons by the middle cerebellar peduncles, and to the medulla by the inferior cerebellar peduncle. (Snell 2007)

The surface layer of each cerebellar hemisphere, called the cortex, is composed of gray matter. The cerebellar cortex is thrown into folds, or folia, separated by closely set transverse fissures. Certain masses of gray matter are found in the interior of the cerebellum, embedded in the white matter; the largest of these is known as the dentate nucleus, (Rumack 2011)

The cerebellum plays an important role in the control of muscle tone and the coordination of muscle movement on the same side of the body, (Rumack 2011)

2.1.2 Fetal head Shapes

The shape and echogenicity of the fetal skull or calvarium may be abnormal and provide clues for the diagnosis of central nervous system and skeletal anomalies, and syndromes. The normal skull produces a high amplitude echo which is very echogenic compared to the brain. Diminished echogenicity of the fetal skull is most commonly seen with osteogenesis imperfecta and hypophosphatasia respectively (Nahum 2000).

Abnormal skull mineralization should be suspected if the falx cerebri appears to be as or more echogenic than the skull. Poor or absent calvarial ossification is also associated with “superb” imaging of brain anatomy due to lower sound attenuation and fewer bone-related artifacts which normally hamper good visualization of the brain nearest the transducer. The sonographer should be alerted to a mineralization abnormality if the brain is seen with unusual clarity. Other findings associated with poor mineralization of the skull include increased compressibility of the fetal head and increased acoustic transmission. Normal skull sutures can be seen as short breaks in the skull echo. The coronal suture is routinely seen in the

BPD image between the temporal and frontal bones. The general shape of the normal fetal head in the axial plane in the 2nd/3rd trimester should appear smooth and oval (BPD/HC image). In the 1st trimester (10-14 weeks LMP), the head appears more spherical than oval since brain development and growth has not yet influenced the shape of the head. Abnormalities in the shape of the fetal head are associated with different conditions and can be very helpful in searching for anomalies, including syndromes. The following list describes the most common abnormalities in fetal head shape described in the sonographic literature.(Rumack 2011, Danhnert 200 and Patterson 1985)

Dolicocephaly - describes a fetal head with a relatively narrow biparietal diameter (BPD) and a long occipitofrontal diameter (OFD). Most commonly associated with oligohydramnios.

Brachycephaly - describes a fetal head which is rounder than usual. Most commonly seen with multiple pregnancy (due to intrauterine crowding), and can be a late feature associated with trisomy 21 (Down's syndrome).

Lemon Sign - describes a fetal head with bilateral denting of the frontal bones. Most commonly associated with spina bifida.

Cloverleaf-shaped Skull - describes a trilobed appearance of the head that is believed to occur as a result of premature closure of the coronal, lambdoidal, and squamosal sutures. It is most commonly associated with thanatophoric dysplasia and homozygous achondroplasia, both lethal skeletal limb reduction syndromes.

Strawberry-Shaped Skull - describes a fetal head with a normal BPD and a narrow frontal diameter. Similar to the lemon sign except that there is no obvious concavity to the frontal bones. Most commonly associated with trisomy 18.

Spalding's sign - describes a flattened and misshapen fetal head with overlapping of cranial bones. Associated with fetal demise (Figure 2-2 and 2-3)

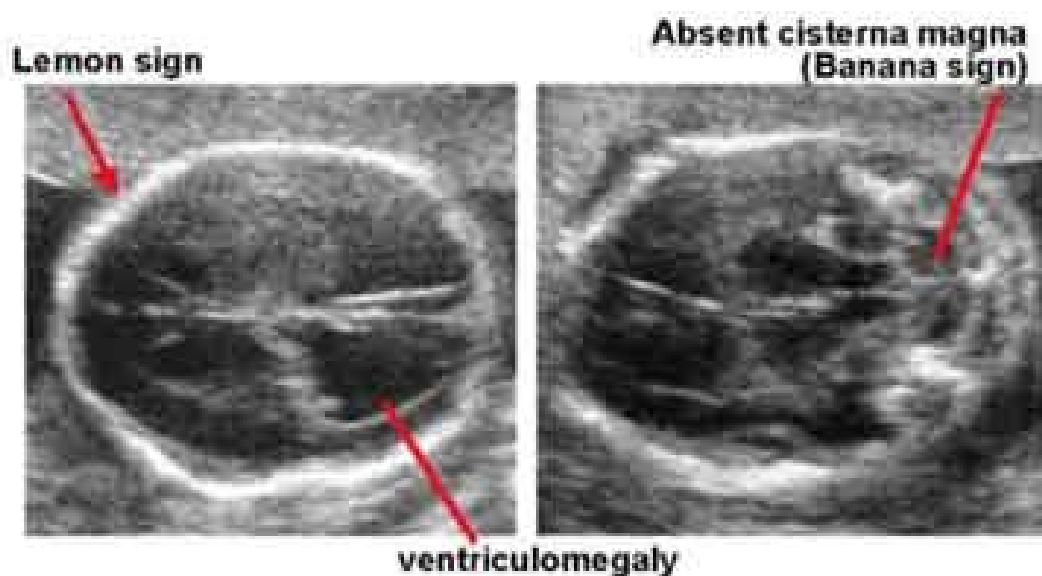


Figure 2-2 Strawberry-Shaped Skull

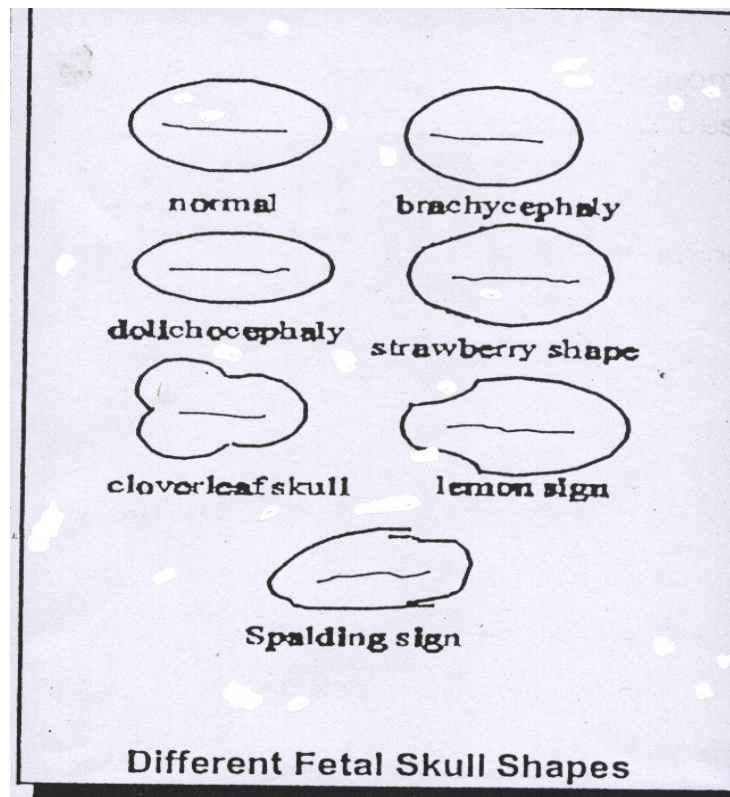


Figure 2-3 Different fetal skull shape

2.1.3 Fetal Scalp

The fetal scalp is normally very thin and barely noticed (scalp thickness is normally <3 mm). In the late third trimester, fetal hair may be seen as short, stringy echoes arising from the scalp. Scalp edema is a manifestation of fetal hydrops and is seen as scalp thickening (scalp thickness more than 3mm) (Chudleigh 2004).

2.1.4 Anomalies of the Fetal Head

Neural Tube Defects

The embryonic brain and spinal cord develop from the neural tube. Anomalous development of the neural tube results in neural tube defects (NTD's) of varying degrees and significance. NTD's may be either open or closed. An open defect indicates the neural tissue (brain or spinal cord) is not covered by the normal integuments or covering tissue layers such as skin and subcutaneous fat. Cranial NTD's include anencephaly, anencephalocele, and cranial meningocele. Spinal NTD's include spina bifida, spinal meningocele, and meningomyelocele. Open NTD's are usually associated with elevated maternal serum and amniotic fluid alpha-fetoprotein concentrations. NTD's are among the most common of all congenital anomalies. The incidence of NTD's varies significantly with geography and has been estimated to be as high as 16 per 10,000births.

(Kazan 2007 and Rumack 2011).

Anencephaly

Anencephaly is defined as absence of the cranial vault and higher brain (cerebrum). Absence of the cranial vault with a variable amount of disorganized brain tissue is defined as acrania. With advancing gestational

age, acrania is associated with progressive degeneration of the fetal brain such that acrania progresses to anencephaly, namely the acrania-anencephaly sequence. Although anencephaly technically means absence of the brain, functioning neural tissue (brain stem and portions of the midbrain) is usually present and the majority of fetuses grows and is born alive. Anencephaly is the most common anomaly of the neural tube and results from failure of the neural tube to completely close at its cephalic end. Closure of the neural tube occurs between the second and third weeks of embryonic development thus the prenatal diagnosis of anencephaly can be made in the first trimester with good equipment and technique. The highest risk factor is a history of previous anencephalic fetus with the recurrence rate estimated to be about 4% and rising to 10% after two successive affected fetuses (Figure 2-4).

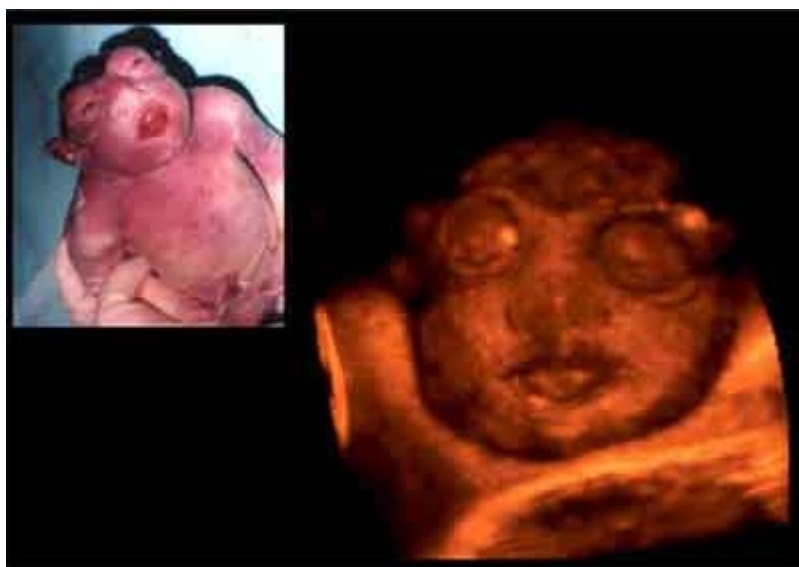

Figure 2-4 Acrania, an encephalocele

Although the cranium is absent with anencephaly and acrania, the base of the skull and orbits are normally present. About one-half or 50% of affected fetuses also have rachischisis (extensive spina bifida) (this finding does not alter the prognosis or management). After 20 to 24 weeks of gestation, polyhydramnios is associated with about one-half of cases (probably due to a decreased ability of affected fetuses to swallow amniotic fluid). The ultrasound diagnosis of acrania and anencephaly can be made reliably by 14 weeks gestation with standard TAS technique, and as early as 10 weeks gestation with EVS providing a specific search is made for the sonographic features for this condition .Acrania is characterized on ultrasound by absence of the normal cranial vault with disorganized (dysmorphic) brain tissue above the orbits which is usually best demonstrated in a coronal view of the fetal head. An interesting and highly specific appearance of acrania at the end of the first trimester is the “Mickey Mouse” sign representing a coronal view of the dysmorphic fetal brain and face. Another characteristic feature of acrania or anencephaly is bulging eyes (exophthalmos). This sonographic feature has been dubbed the "frog face” or “eyeglass” sign. Failure to identify normal cranial morphology and brain tissue above the orbits is the most reliable sonographic feature of anencephaly. The CRL measurement in

anencephalic fetuses may be normal or small-for-dates depending on the status of the cerebral brain tissue. In one group of anencephalic fetuses the mean fetal CRL was significantly reduced but it was below the 5th percentile of the normal range in only one-quarter of the cases. A frequent, indirect sign of acrania-anencephaly sequence is echogenic amniotic fluid in the first trimester. Amniotic fluid at this stage of pregnancy is normally clear or echo free at normal gain settings. Eight of nine cases in the series by Cafici had some degree of amniotic fluid echogenicity. It is hypothesized the amniotic fluid echoes are the result of exfoliating fetal neural debris from the exposed and mechanically traumatized fetal brain and associated bleeding (proven in some cases by aspiration of neural cells and red blood cells by amniocentesis). Variability in the degree of echogenicity of the amniotic fluid is related to gestational age at diagnosis or a more rapid turnover of the amniotic fluid. Sonographers should be heightened of the possibility of acrania anencephaly sequence if the amniotic fluid appears echogenic in relation to the fluid in the chorionic cavity especially in view of increased use of first-trimester nuchal translucency screening (Kazan 2007 and Rumack 2011).

Cephalocele

Cephalocele is a developmental defect in the cranium (skull) resulting in an extracranial mass consisting of variable elements. If the cephalocele contains only protruding meninges and CSF, it is called a cranial meningocele; if the cephalocele also contains brain tissue, it is called an encephalocele or meningoencephalocele. Most cephaloceles are covered by normal scalp tissues and do not cause maternal alpha-fetoprotein concentrations to be abnormally elevated. Cephaloceles are the least common form of open NTD's. Most cephaloceles are midline (symmetric), with the majority occurring in the occipital region (~3/4 or 75% of cases). These lesions may be isolated or featured with other anomalies in syndromes, most notably amniotic band syndrome (ABS), limb-body-wall complex (LBWC), and Meckel-Gruber syndrome. Cephaloceles associated with ABS and LBWC are typically multiple and in an asymmetric or lateral location such as the parietal or temporal region of the head. Sonographically, a cephalocele appears as an extracranial mass of variable dimension and sonographic appearance (cystic, complex, or solid mass) associated with a definitive skull defect. Identification of a skull defect is the predominant distinguishing feature between cephalocele and other cranial masses such as cystic hygroma, teratoma, and other lesions. Other sonographic findings may include the "lemon sign" of the frontal bones in

the BPD image and ventriculomegaly (obstructive hydrocephalus) (Kazan 2007 and Rumack 2011).

Choroids Plexus Cysts (CPC)

CPCs arise from neuroepithelial folds in the choroid plexus, with the atrial region of the lateral ventricle being the most common site. CPCs are typically unilateral, spherical, anechoic, and relatively small (range 1 to 20 mm, with most cysts being less than 5 mm). CPCs are infrequently multiple, bilateral, or odd-shaped. Most CPCs are seen between the 18th and 24th weeks of gestation, with the majority regressing and disappearing spontaneously. The majority of CPCs are isolated findings in otherwise normal fetuses; however, they may be associated with other structural anomalies and aneuploidy. The most common chromosome abnormality associated with CPCs is trisomy 18. There does not appear to be any statistical differences between the association of isolated fetal choroid plexus cysts and the sex of the fetus. The clinical management of isolated CPCs in low-risk women remains somewhat controversial. Some investigators have dismissed the isolated CPCs as a normal variant that usually resolves by the 3rd trimester, whereas others have quoted a significantly increased risk of aneuploidy for all cysts, even if isolated or transient. The sonographic detection of CPCs depends on the size of the

cyst, gestational age, and background heterogeneity of the CP, transducer and equipment resolution capabilities. As shown by Turner et al, the background echo texture of CP is more heterogeneous in younger fetuses and small anechoic areas are normal features of developing CP). Consequently, these small anechoic areas in the CP may be falsely mistaken for small CPCs. Based on their interesting experiment with embedded prototype cysts of different sizes at different gestational ages, Turner advocates “that cysts must be at least 2.5 mm in the screening period of 13 to 21 weeks’ gestation to be reproducibly and accurately detected and at least 2 mm from 22 to 38 weeks’ gestation. It is important to recognize that there is a lower limit of size below which the diagnosis of a CP cyst should not be made, and the possibility of a false diagnosis due to the background heterogeneity is great. We think that, hence tenets should guide the development of diagnostic criteria, help standardize the literature, and, it hoped, reduce the number of false-positive diagnoses and unwarranted amniocenteses, which generate needless anxiety in prospective parents(Kazan 2007 and Rumack 2011)

Cerebral Ventriculomegaly and Hydrocephalus

Cerebral ventriculomegaly refers to dilatation of the cerebral ventricles without defining the cause. The fetal head may be normal, enlarged, or even

small-for-gestational age depending on the underlying cause and the time of the diagnosis during the pregnancy. Fetal head size is therefore not crucial for the diagnosis of cerebral ventriculomegaly. Hydrocephalus (hydrocephaly) is ventriculomegaly most commonly associated with increased intracranial pressure and is usually due to a lesion causing obstruction of the CSF pathway. Fetal hydrocephalus is characterized in the third trimester by macrocephaly and brain atrophy. The most common causes of fetal ventriculomegaly include Arnold-Chiari malformation, open neural tube defects, congenital aqueductal stenosis, and Dandy- Walker malformation. The prognosis depends on the severity, underlying cause, and the association with other anomalies. In the majority of cases ventriculomegaly is bilateral and symmetric. Asymmetric bilateral and/or unilateral ventriculomegaly are very uncommon. As an isolated finding, fetuses with unilateral cerebral ventriculomegaly generally have a good developmental outcome. Fetuses with unilateral ventriculomegaly have a better prognosis than those with bilateral ventriculomegaly suggesting that both ventricles should be evaluated in every fetus. The underlying cause of fetal ventriculomegaly determines the components of the ventricular system that enlarge. For example, with Arnold-Chiari malformation, the 4th, 3rd, and both lateral ventricles are dilated, and with aqueductal stenosis, the 3rd

ventricle and both lateral ventricles are dilated whereas the 4th ventricle is normal is normal since the obstruction is proximal.

Anatomic appearance and several measurements have been described to assess ventricular size including the transverse atrial diameter, combined anterior horn diameter, and the lateral ventricle-to-hemisphere ratio. The atrial measurement is currently the best indicator of ventriculomegaly and will be the only measurement technique considered here (Kazan 2007 and Rumack 2011).

2.2. Previous study

There same studies reveal an association between the dimensions of the fetal cerebellum, especially the TCD and GA is a close relationship between TCD and GA (correlation coefficient $(r) = 0.94$ and $p < 0.001$), with TCD increases linearly from 15 to 40 weeks. Therefore, based on our findings and taking into account the present state of the art on this issue, the TCD fetal ultrasound could be a predictive biometric parameter of GA in the last two trimesters of a pregnancy. The present data offer the normal range of cerebral measurements throughout gestation. These values may allow intrauterine assessment of the development of the cerebellum as well as the posterior fossa (Mustafa et al 2013)

An accurate assessment of gestational age is fundamental in managing both low and high risk pregnancies. In particular, uncertain gestational age has been associated with adverse pregnancy outcomes including low birth weight, spontaneous preterm delivery and perinatal mortality, independent of

maternal characteristics. Making appropriate management decisions and delivering optimal obstetric care necessitates accurate appraisal of gestational age. For example, proper diagnosis and management of preterm labor and post-term pregnancy requires an accurate estimation of fetal age. Many pregnancies considered to be preterm or postterm are wrongly classified. Unnecessary testing such as fetal monitoring and unwarranted interventions including induction for supposed postterm pregnancies may lead to an increased risk of maternal and neonatal morbidity. In addition, pregnancies erroneously thought to be preterm may be subject to avoidable and expensive hospitalization stays as well as excessive and potentially dangerous medication use including tocolytic therapy. In one study by Kramer et al that assessed over 11,000 pregnant women who underwent early ultrasound, one-fourth of all infants who would be classified as premature and one-eighth of all infants who would be classified as post term by menstrual history alone would be misdiagnosed. Accurate pregnancy dating may also assist obstetricians in appropriately counseling women who are at imminent risk of a preterm delivery about likely neonatal outcomes. Precise knowledge of gestational age is also essential in the evaluation of fetal growth and the detection of intrauterine growth restriction. During the third trimester, fundal height assessment may be helpful in determining appropriate fetal growth by comparing the measurement to a known

gestational age. In addition, dating a pregnancy is imperative for scheduling invasive diagnostic tests such as chorionic villus sampling or amniocentesis, as appropriate timing can influence the safety of the procedure. Certainty of gestational age is also important in the interpretation of biochemical serum screening test results and may help avoid undue parental anxiety from miscarriages and superfluous invasive procedures, which may increase the risk of pregnancy loss. Assessment of gestational age is also crucial for counseling patients regarding the option of pregnancy termination (Hall 1985).

Other methods used to assess gestational age have included uterine size assessment, time at quickening and fundal height measurements. However, these clinical methods are often suboptimal. Robinson noted that uterine size determination by bimanual examination produced incorrect assessments by more than two weeks in over 30% of patients. Similarly, fundal height estimation does not provide a reliable guide to predicting gestational age. Beazly et al found up to eight weeks variation in gestational age for any particular fundal height measurement during the second and third trimesters. Quickening, or initial perception of fetal movement can vary greatly among women. While these modalities may be useful adjuncts, they are unreliable as the sole tool for the precise dating of a pregnancy (Salomon et al 2010).

In recent years, ultrasound assessment of gestational age has become an integral part of obstetric practice. Correspondingly, prediction of gestational age is a central element of obstetric ultrasonography. Fetal biometry has been used to predict gestational age since the time of A-mode ultrasound. Currently, the sonographic estimation is derived from calculations based on fetal measurements and serves as an indirect indicator of gestational age. Over the past three decades, numerous equations regarding the relationship between fetal biometric parameters and gestational age have been described and have proven early antenatal ultrasound to be an objective and accurate means of establishing gestational age (Kalish et al 202 and Kurtz et al 1996).

Although routine ultrasonography at 18–20 weeks gestation is controversial, it is practiced by many obstetricians in the United States. In addition to screening for fetal anomalies, sonographic gestational age assessment may be of clinical value in that it has been shown to decrease the incidence of post term as well as preterm diagnoses and thus the administration of tocolytics. In addition, uncertain gestational age has been associated with higher perinatal mortality rates and an increase of low birth weight and spontaneous preterm delivery (Ewigman 1993).

While ultrasound has proven to be useful in the assessment of gestational age in the first and second trimesters, accuracy in the third trimester is not as reliable. Biologic variation can be a major factor that affects accuracy in gestational age prediction, and this variability greatly increases with advancing pregnancy. Doubilet and Benson evaluated late third trimester ultrasound examinations of women who had also received a first trimester exam and found the disparity in gestational age assessments to be three weeks or greater. Thus, third trimester sonographic estimates of gestational age should be used with caution, if at all. Recent advances in ultrasound image quality and the wide availability of accurate biometric formulas have greatly improved physicians' ability to calculate gestational age. However, properly dating a pregnancy sonographically still depends on adherence to good ultrasound technique. Obtaining a clear and precise image of each biometric indicator is essential. Errors in estimation may arise from technical difficulties including obtaining the proper axis for measurement, movement of the mother or fetus, machine sensitivity settings or caliper placement. If a certain biometric indicator is not well visualized or is difficult to measure, it is better to use an alternative indicator rather than include a suboptimal measurement. In addition, it is helpful to obtain several measurements of each indicator and use an average to ensure a more precise calculation of fetal age (Filly and Hadlock 2000).

Chapter three

Material and method

3.1 Study design:

This is analytical study, compare estimation of gestation age by CD and last menstrual period (LMP).

3-2 Study population:

The targets populations of this study are all pregnant ladies attending for fallow up (ultrasound exam) in second and third trimester singleton pregnancy without head abnormality.

Exclusion criteria

Smokers (motivation of teratogenic effect to fetuses).

Diabetes mellitus (as it change growth).

Clinical complications in the current pregnancy such as arterial hypertension (change of fetus growth retardation).

3-3 Study area and duration:

This study will be achieved in Omdurman delivery hospital and was conducted from July 2015 to December 2015

3.4 Sample size and type

The data of this study was collected from 50 pregnant lady in second and third trimester selected conveniently

3-5 Material:

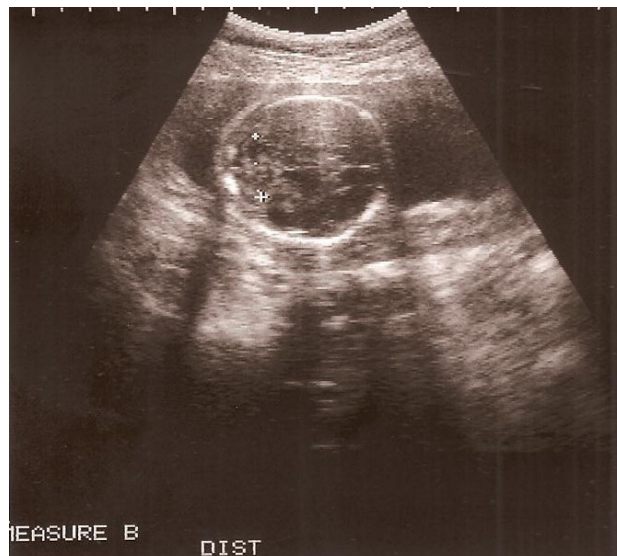Ultrasound examinations were performed on the high-resolution Phillips ultrasound medical system, ultrasound unit equipped with a 3.5 MHz convex probe.

3-6 Method of data:

The GA assessment was based on an early pregnancy scan (second and third trimesters) or by certain dates (date of last menstrual period) if no antenatal scan was available. Dates were considered certain if it was recorded as such in the maternal notes. Fetal CD was measured using the method described by Goldestein et al. to locate the cerebellum in the posterior fossa by means of rotation of the transducer to approximately 30°

from the plane that identifies the thalamus, the cavity of the septum pellucidum, third ventricle and cistern magna, positioning the calipers on the outer margins of the cerebellar hemispheres. (Mustafa et al 2013)

A single CD measurement was used for each fetus studied. The measurement of CD was obtained by placing electronic calipers at the outer margins of the cerebellum. The landmarks of the thalami, cavum, septum pellucidum and third ventricle were identified thereby slightly rotating the transducer below the thalamic plane. The posterior fossa is revealed with the characteristic butterfly like appearance of cerebellum. In all cases cerebellum was seen as two lobules on either side of the midline in the posterior cranial fossa. CD measurement was taken in the coronal plane.



Sonogram of the posterior fossa demonstrating the measurement of the cerebellar diameter

3-7 Variable of data collection:

The data was collected by the following:

- (Last menstrual period (LMP •
- Date of exam •
- (Cerebellum diameter (CD •
- (Biparietal diameter (BPD •
- (Femur length (FL •

3-7-1 Data analysis:

The data was analyzed by using SPSS & Excel package version 17 for quantitative data to find out indicators aimed by this study. Correlations between fetal CD and GA were determined for the whole sample.

Chapter Four

Results

Table 4-1 shows the Mean and SD

Measuring variable	Mean \pm SD
Age	25.98 \pm 4.58
cerebellum diameter	3.20 \pm 0.88
biparietal diameter	6.85 \pm 1.60
femur length	5.26 \pm 1.56
AG- biparietal diameter	27.77 \pm 6.30
AG- femur length	27.62 \pm 6.36
AG- last menstrual period	26.37 \pm 6.33
AG-cerebellum diameter	26.47 \pm 5.46

Table 4-2 shows Pearson Correlation

	Pearson Correlation	Sig. (2-tailed)
BPD&CD	.911**	.000
FL&CD	.897**	.000
GA&CD	.923**	.000
GA&CD	.923**	.000
GA&CD	.858**	.000

The significant at $P = 0.05$ with $r=0.9$ with $p \leq 0.001$

Table 4-3 shows paired samples test

		T	Sig. (2-tailed)
Pair 1	GA_LMP - GA_CD	-.22 5	.823
Pair 2	GA_BPD - GA_LMP	4.10 5	.000
Pair 3	GA_FL - GA_LMP	3.57 5	.001

Figure 4-1 sector plot demonstrate the relationship between GA-LMP and CD with a trend line depict linear association, direct linear relationship

Figure 4-2 sector plot demonstrate the relationship between GA-LMP and FL with a trend line depict linear association, direct linear relationship

Figure 4-3 sector plot demonstrate the relationship between GA-LMP and BPD with a trend line depict linear association, direct linear relationship

Figure 4-4 sector plot demonstrate the relationship between GA-CD and LMP with a trend line depict linear association, direct linear relationship

Figure 4-5 sector plot demonstrate the relationship between GA-FL and LMP with a trend line depict linear association, direct linear relationship

Figure 4-6 sector plot demonstrate the relationship between GA-BPD and LMP with a trend line depict linear association, direct linear relationship

Figure 4-7 sector plot demonstrate the relationship between GA-LMP and CD in 2nd trimester with a trend line depict linear association, direct linear relationship

Figure 4-8 sector plot demonstrate the relationship between GA- LMP and CD in 3rd trimester with a trend line depict linear association, direct linear relationship

Chapter five

5.1 Discussion

The main objective of this study was to estimate the gestational age using the cerebellum diameter in the second and third trimester using the known last menstrual period as a reference in estimating the accurate GA.

The age of the maternal included in this study range from 17-39 years old with the mean age of 25.98 ± 4.58 years (Table ~~and~~ 4-1), with parity range from 1 to 8. The mean value of the cerebellar diameter was 3.20 ± 0.88 cm and the BPD was 6.85 ± 1.60 cm and FL was 5.26 ± 1.56 cm.

This study showed that, there is strong ~~correlation and seen when using paired sample~~significant correlation ~~method~~ between the expected gestational age of last menstrual period -LMP and cerebellar diameter in which ~~r=~~is equal to -0.921, (Table 4-2), ~~additionally in addition to that~~ the paired t-test show insignificant difference between the GA-LMP and CD at $p = 0.05$ (Table 4-3). ~~Similarly t-theis~~ study ~~also~~ showed a significant correlation between the GA-LMP and GA-BPD, ~~between GA-LMP and GA-FL, and between the GA-LMP an and~~ GA-CD which was .927, .925, and .858 respectively (Table 4-2). ~~From t~~ This result ~~it is obvious~~indicates that the strongest correlation is between the GA-LMP and gestational age can be estimated using GA-CD with a correlation almost similar to the classic parameter (BPD and FL) with GA-LMP. Also CD parameter correlated with BPD and FL and showed strong correlation which is equal to 0.897 and

0.923 respectively; this means cerebellar diameter is a direct related parameter as the classic one.

—
-

The ~~study show~~study shows that, that, there is a direct linear ~~relation~~association between the gestational age of last menstrual period ~~and~~versus cerebellar diameter, ~~estimation of GA by~~ BPD and femur length. In this relation the GA increases by 6.2 weeks/cm, 3.60 weeks/cm and 3.5 weeks/cm respectively (Figure 4-1 to 4-3). The ~~study show~~study also shows that, that, there is a direct linear ~~relation~~association between the gestational age of last menstrual period ~~and~~versus cerebellar diameter in second and third trimesters~~estimation of GA by~~. In this relation the gestational age increases by 5.238 weeks/cm, 4.789 weeks/cm respectively (Figure 4-7 to 4-8). Measurement can be used for significant improvement in the accuracy of gestational age estimation in growth restricted fetuses.

5.2 Conclusion

The age of the maternal included in this study range from 17-39 years old with the mean age of 25.98 ± 4.58 years (Table ~~and~~ 4-1), with parity range from 1 to 8. The mean value of the cerebellar diameter was 3.20 ± 0.88 cm and the BPD was 6.85 ± 1.60 cm and FL was 5.26 ± 1.56 cm.

The gestational age increases by 5.238 weeks/cm, 4.789 weeks/cm respectively. Measurement can be used for significant improvement in the accuracy of gestational age estimation in growth restricted fetuses. The results of this study showed that CD can be used in linear equation and exponential one to estimate the gestational age with a predicting power

In conclusion CD can be used safely to predict the GA, but consideration of cephalic index is important to avoid over or under estimation of gestational age.

5.3 Recommendations

- To create CD chart for Sudanese fetus, a large sample of population should be recruited for the study and is performed to be more than 500 .graved women with singleton pregnancy in 2nd and 3rd trimesters
- Also further study can be done to find the accuracy of the head measurements together and separate in the second trimester then third .trimester to compare the accuracy in each trimester
- An ultrasound machine with high spatial resolution is highly recommended to carry out such large study so as to minimize the inaccuracy in putting the calibers in the outer margins of the cerebellum in obtaining the CD
- CD should be programmed in all ultrasound machines to have a good .benchmark for comparison
- Further study to show the sonographic diagnosis of intrauterine growth retardation (IUGR) by fetal cerebellum diameter (CD) to .abdomen circumference (AC) ratio is recommended

5.4 References

Campbell S, Warsof SL, Little D, Cooper DJ. Routine ultrasound screening for the prediction of gestational age. *Obstet Gynecol* 1985; 65:613–20

Choudleing T, andthilaganathan B. 2004. obstetric ultrasound how, why, and when, 3rd edition, Elsevier, Churchill livingstone

Chudleigh T, Thilaganathan B. 2004. Obstetric Ultrasound, Elsevier Churchill Livingstone, Edinburgh London

EA. Reece, I. Goldstein, G.Pilu, et al. Foetal cerebellar growth unaffected by intrauterine growth retardation: A new parameter for prenatal diagnosis. *Am J ObstetGynecol*, Volume157:632-38, 1987.

El- Rakhawy, M.T,2000. Lllustrative emberyology: normal and abnormal human development. 1st ed. Printed and published in Egypt. P 86-94

Ewigman BG, Crane JP, Frigoletto FD, LeFevre ML, Bain RP, McNellis D. Effect of prenatal ultrasound screening on perinatal outcome. *N Engl J Med* 1993; 329:821–27

Filly RA, Hadlock FP. Sonographic determination of menstrual age. In Callen PW (Ed). *Ultrasonography in Obstetrics and Gynecology*. Philadelphia: WB Saunders, 2000.

Hall MH, Carr-Hill RA. The significance of uncertain gestation for obstetric outcome. *Br J Obstet Gynaecol* 1985; 92:452–60

K. Hata, T. Hata, D. Senoh, et al. Ultrasonographic measurement of the foetal transverse cerebellum in utero. *GynecolObstet Invest*, Volume 28:111-12, 1989.

Kazan TJF and Levine D. 2007. Imaging of Fetal Tumors. *Ultrasound Clin*, 245-263

Manual of diagnostic ultrasound, P.E.S palmer, Geneva -1995, page 224

Mustafa. z, Omer A. MageedA, Alsafi A.Abdulla, Fetal Transverse Cerebellar Diameter Measurement for Prediction of Gestational Age in Pregnant Sudanese Ladies,2013,volum 3: 89-93

Nahum G. Detecting and managing fetal macrosomia. *Contemporary obstetrics and gynecology* 2000,6:89-119

recherd s. snell, clinical anatomy by regions, 8th edition, R.R. Donnelley & Sonsâe Willard, USA 2007 : 690

Rumack CM, Wilson SR, Charboneau JW and Levine D. 2011. Diagnostic ultrasound, 4th edition, Mosby, Inc., an affiliate of Elsevier Inc, USA

Salomon LJ., Alfirevic Z., Berghella V., Bilardo C., Hernandez-Andrade E., Johnsen SL., Kalache K., Leung KY., Malinger G., Munoz H., Prefumo F., Toi A. and Lee W. 2010. Practice guidelines for performance of the routine mid-trimester fetal ultrasound scan. Published by John Wiley & Sons, Ltd

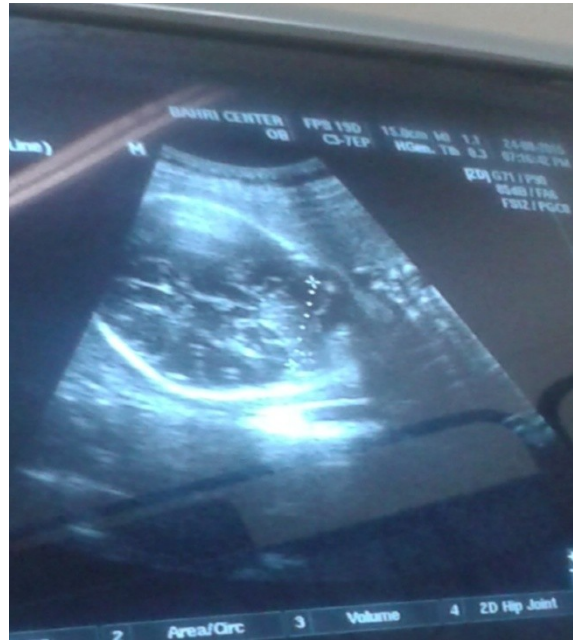Appendix A

Master data sheet

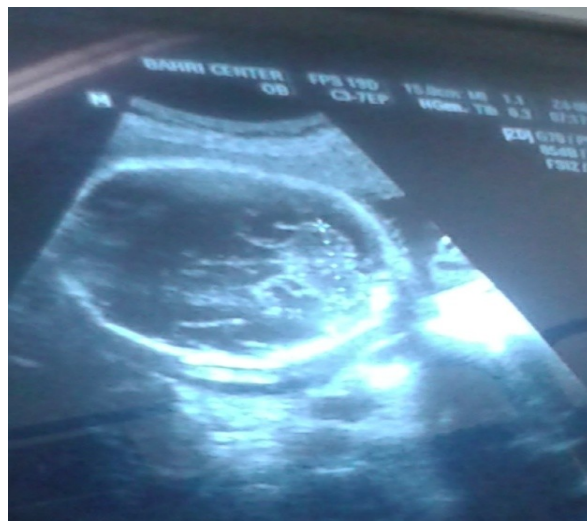No	exam date	AGE (year)	Parity	LMP	CD (cm)	BPD (cm)	FL (cm)	GA by BPD	GA by FL
----	-----------	---------------	--------	-----	------------	-------------	------------	-----------	----------

Appendix (B)

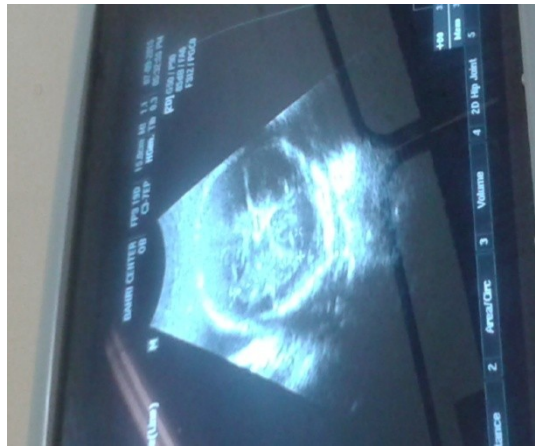Ultrasound Images



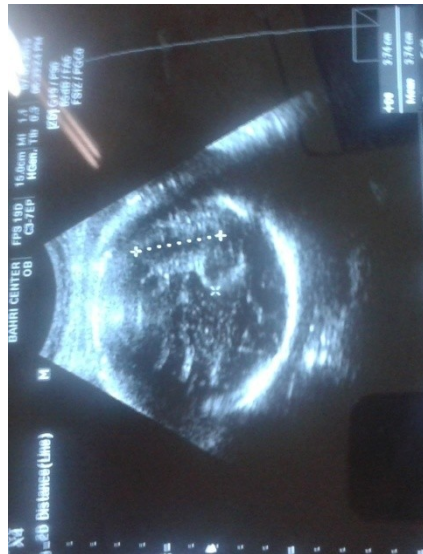Ultrasound image of fetus in 31week and 6 days of gestation, cerebellar diameter 3,75



Ultrasound image of fetus in 26week and 5days of gestation, cerebellar diameter 3,54



Ultrasound image of fetus in 25Week and 3Days of gestation, cerebellar diameter 3,2



Ultrasound image of fetus in 20weak of gestation, cerebellar diameter 2,0

