

# Chapter one

## **Diagnosis of Female Pelvic Pain in Non Pregnant Women using Ultrasound:**

### **1-1 Introduction**

Ultrasound is one of the most important and useful diagnostic tool in the field of modern medicine. Being noninvasive, safe and without hazards of radiation, it has gained wide acceptability, as an integral part of basic investigative procedures. The convenience, high portability, rapidity, and accuracy are few of the advantages of ultrasound over the other procedures. In the last two decades, ultrasound has become an essential diagnostic imaging modality in the field of gynecologic & obstetric and is being extensively used for evaluation of causes of pelvic pain. Ultrasound frequently is the first imaging test performed when pelvic pain is intense enough or of a long-term duration to warrant medical evaluation. The results of this procedure therefore, play a pivotal role in directing the patient to surgical or medical consultation or just watchful waiting. Therefore, it is important for sonographer to be aware of the differential causes of pelvic pain and how ultrasound may be utilized in making the diagnosis **Kuligowska, K.(2005).**

A correct diagnosis at an earlier, less complicated stage could possibly save the patient from a catastrophic outcome. Thus the sonographer is a personnel that are involved in the evaluation should have a firm understanding of the general symptomatology behind the various etiologies of pelvic pain. Initially, the most important aspect of the evaluation is taking the patient's history. This will help guide and focus the procedure that might be utilized in making the diagnosis. Supplying this information to the pelvic ultrasound will usually examine a number of anatomic structure (Rochelle 1988)

### **1-2 Problem of Study :-**

Pelvic contain sensitive and important organs that most of diagnosis was done using ionizing radiation which can affect these organs .

The aim of the study was to assess the validity of ultrasound in the prediction of pelvic pathology in patients with pelvic pain related to clinically suspected The goal of imaging is to make the most accurate diagnosis using the least amount of radiation.

### **1-3 objectives:**

#### **1-3-1 General Objective :-**

Is to assess the validity of ultrasound in prediction of pathology in non pregnant female come with pelvic pain .

#### **1-3-2 Specific objective:-**

To describe the differential diagnosis for a female patient that presents with pelvic pain.

To classified the types of pelvic pain using ultrasound.

To discuss some of the “pitfalls” that can be encountered when evaluating patients who present with pelvic pain.

4. To show the accuracy, sensitivity and specificity of u/s

### **1-4 Significant of study:-**

Ultrasound plays a very important role in the evaluation of patients with acute and chronic pelvic pain. It allows identification of ovarian torsion and has both diagnostic and therapeutic capabilities in patients with pelvic inflammatory disease through guidance of abscess drainage via the transvaginal route. In suspected ectopic pregnancy.

### **1-5- Overview of the study:-**

This study contain of five chapters, chapter one introduction, objectives, problems of the study, significant of the study, methodology and over view of the study:

Chapter two, literature reviews and previous study.

Chapter three, materials and method.

Chapter four results.

Chapter five discussions, recommendations and conclusion.

# **Chapter Two**

## **Literature review and previous studies**

### **2-1 Anatomy:**

A thorough understanding of pelvic anatomy is essential for clinical practice. Not only does it facilitate an understanding of the ultrasound, , and establishes a background to the understanding of gynecological pathology, Congenital abnormalities, a clear understanding of the pelvic anatomy is crucial for the diagnosis of female pelvic diseases, using ultrasound (Kuligowska, K.(2005) .

#### **2-1-1 The vagina:-**

The vagina is a muscular tube, approximately 8cm long, which extends up and back from the vulva to surround the cervix of the uterus. Blood supply is via the vaginal artery and the vaginal branch of the uterine artery. The vaginal veins form a plexus that drains to the internal iliac veins. Lymphatic vessels from the upper two-thirds drain to the internal and external iliac nodes and from the lower third to the inguinal nodes(Kuligowska, K.(2005) .

#### **2-1-2 The cervix :-**

The cervix connects the uterus and vagina, and projects into the upper vagina. The cervix is about 2.5 cm long; the shorter part of it, which lies above the fornices, is termed the supravaginal part. The endocervical canal is fusiform in shape between the external and internal os. The body of the uterus is usually angled forward in relation to the cervix (anteflexion), while the uterus and cervix as a whole lean forward from the upper vagina (anteversion) (Zafer 2011).

#### **2-1-3 The uterus :-**

The uterus is a pear-shaped muscular organ, approximately 8 cm long, 5cm across and 3cm thick. It has a fundus, body and cervix. The Fallopian tubes enter each superior lateral angle (the cornu). The cavity of the uterus is communicates with the

cervical canal via the internal os, and the cervical canal opens into the vagina via the external os. Peritoneum covers the entire uterus except below the level of the internal os anteriorly, where it is reflected on to the bladder, and laterally between the layers of the broad ligament. The thick smooth muscle Myometrium is related directly to the endometrium with no intervening submucosa. The endometrium is continuous with the mucous membrane of the uterine tubes and the endocervix. The wall has three layers: the endometrium (innermost); the Myometrium; and the peritoneum (outermost) Kuligowska, K.(2005) .

### **2-1-3-1 Endometrium**

The endometrium is the epithelial lining of the cavity. The surface consists of a single layer of columnar ciliated cells, with invaginations forming uterine mucus-secreting glands within a cellular stroma. It undergoes cyclical changes in both the glands and stroma, leading to shedding and renewal about every 28 days. There are two layers – a superficial functional layer which is shed monthly, and a basal layer which is not shed, and from which the new functional layer is regenerated. The epithelium of the functional layer shows active proliferative changes after a menstrual period until ovulation occurs, when the endometrial glands undergo secretory changes. Permanent destruction of the basal layer will result in amenorrhoea. This fact forms the basis for ablative techniques for the treatment of menorrhagiab (Kuligowska, K.(2005) .

### **2-1-3-2 Myometrium**

The smooth muscle fibers of the uterine wall do not form distinct layers. While the outermost fibers are predominantly longitudinal, continuous with the musculature of the uterine tubes above and the vaginal wall below, the main thickness of the uterine wall is formed from a mesh of criss-crossing spiral strands. The individual muscle cells contain filaments of actin and myosin, which interact to generate contractions (Greege 2002).

### **2-1-3-3 Peritoneum**

The posterior surface of the uterus is completely covered by peritoneum, which passes down over the posterior fornix of the vagina into the pouch of Douglas. Anteriorly the peritoneum is reflected off the uterus at a much higher level onto the superior surface of the bladder(Kuligowska, K.(2005) .

### **2-1-4 The uterine tubes:-**

Each Fallopian tube is about 10 cm long and lies in the free edge of the broad ligament, extending out from the uterine cornua to form a funnel-shaped lateral part, the infundibulum, which extends beyond the broad ligament and overhangs the ovary with its finger-like fimbriae. Arterial supply is from the ovarian and uterine arteries and there is corresponding venous drainage. Lymphatic drainage is chiefly to para-aortic lymph nodes(Kuligowska, K.(2005) .

### **2-1-5 The ovaries :-**

These paired almond-shaped reproductive and endocrine organs lie in the ovarian fossae, situated in the lateral pelvic sidewalls. Their size and appearance varies with age. Normal adult dimensions are 3x15x2 cm with a weight of 2-8 g and each ovary contains a few mature follicles, 70 000 immature follicles, and postovulatory corpora lutea and corpora albicantia (scarred areas marking the site of previously ruptured follicles). After the menopause, the ovary atrophies. The ovary is attached to the back of the broad ligament by the mesovarium. It is attached to the infundibulum of the Fallopian tube as described above. That part of the broad ligament lateral to the mesovarium running to the lateral pelvic wall is known as the suspensory ligament of the ovary and within it run the ovarian vessels and lymphatics. Inferiorly lies the levator ani muscle (**Kuligowska, K.(2005)** 2-1-

### **4Anatomy of the lower urinary tract**

The descending ureters are narrow thick-walled muscular tubes which cross into the pelvis close to the bifurcation of the common iliac arteries. They lie

immediately under the peritoneum of the pelvic sidewall, behind the lateral attachment of the broad ligaments. and enter the bladder base obliquely at the upper angles of the trigone **(Kuligowska, K.(2005)).**

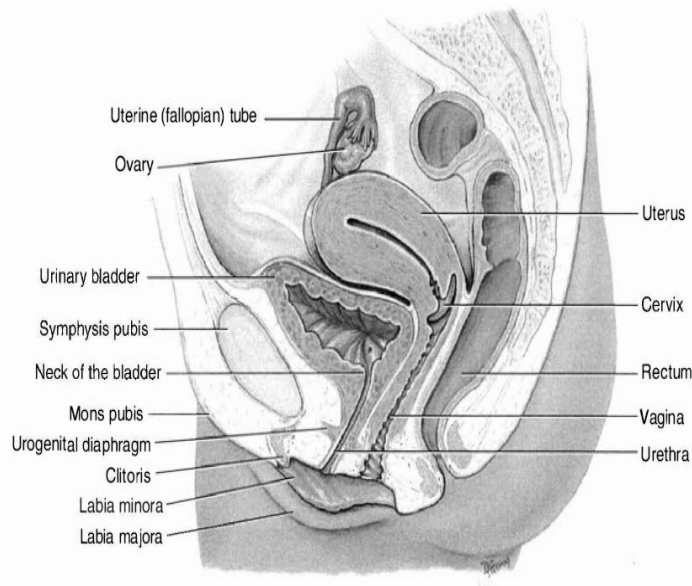
#### **2-1-4-1 The bladder:-**

It has the shape of a tetrahedron when empty, it contain a volume of half a litre or more, The bladder is covered with peritoneum on its superior surface only. The peritoneum is reflected onto the anterior abdominal wall at a varying level, dependent on the degree of bladder filling. The oblique passage of the terminal part of each ureters through the bladder wall creates a one-way valve, which normally prevents urinary backflow from the bladder. This protects the kidneys from ascending infection. The triangular area within the bladder base defined by the two ureteric orifices and the internal urethral orifice is termed the trigone **(Kuligowska, K.(2005)).**

#### **2-1-4-2 The urethra:-**

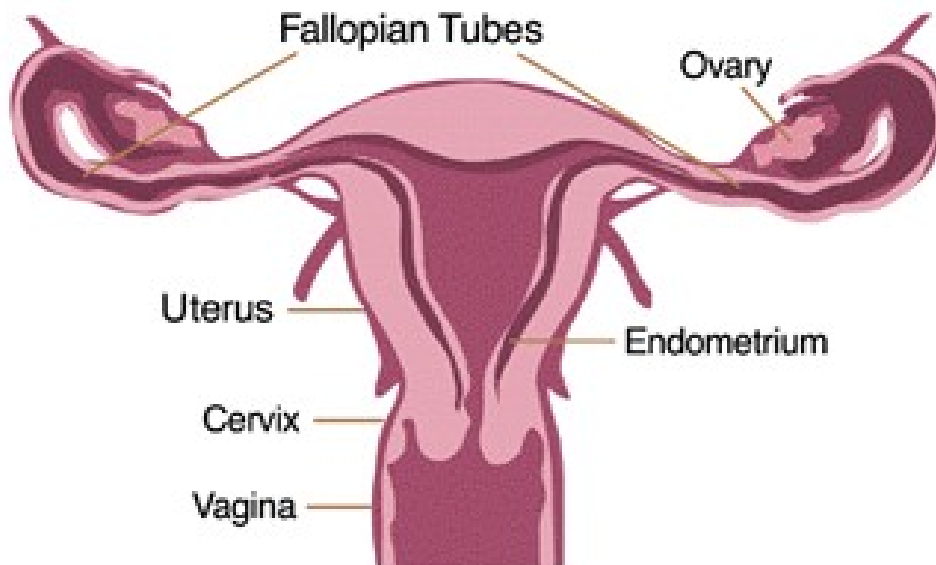
The female urethra is about 4 cm long. Below the bladder neck it is embedded in the anterior vaginal wall, and the smooth muscle layers of the two structures intermingle **(Golden 1996) .**

The pelvic region also holds several digestive organs. These include the large intestine and small intestine. Both are vital to digesting food and expelling solid waste. The large intestine ends in the rear of the pelvis at the anus, a sphincter muscle that controls the disposal of solid waste. The intestines are supported by a series of muscles known as the pelvic floor. These muscles also help the anus function as well as help push a baby through the vaginal opening during childbirth **(Golden 1996).**



**Figure 8.39**  
Lateral view of female pelvis.

**Figure (2-1) shows Crosssections anatomy of the female pelvic (Golden 1996)**



**Figure 2-2 shows the female reproductive system AP view (Golden 1996).**



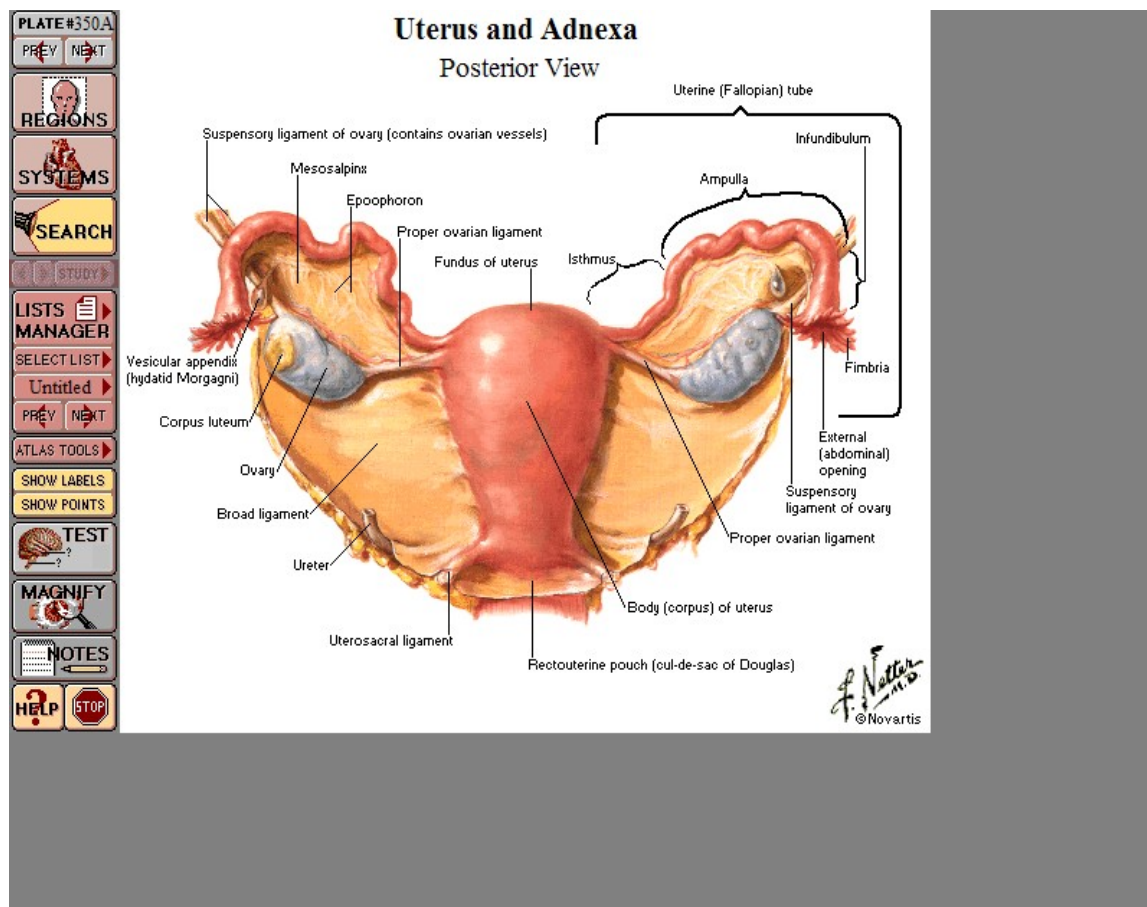


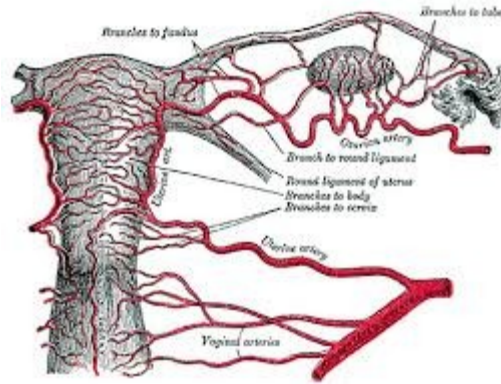
Figure 2-3 shows the posterior view of female reproductive system (Golden 1996).

## 2-2: Physiology:

### 2-2-1 Blood Supply:-

Arterial supply is by the ovarian artery, which arises from the aorta. Venous drainage into the ovarian veins, which drain into the IVC on the right and the renal vein on the left. Lymph drainage is along the ovarian vessels to pre aortic lymph nodes at the level of the first and second lumbar vertebra. The main arterial supply

of the uterus is the uterine artery, which passes to the uterus in the base of the broad ligament, crossing above the ureters. The artery anastomoses with the ovarian artery. The vein accompanies the artery and drains into the internal iliac vein. Lymphatic vessels drain to internal and external iliac lymph nodes and para-aortic nodes (Huderist 2011)



**Figure 2-4 shows the blood supply to the pelvic organs**

### **2-2-2 Muscles of the pelvis :-**

The major muscles include the paired psoas and iliac muscles,. within the true pelvis, the pair forms muscles, covered by parietal fascia, The lateral wall of the pelvis is formed by the obturator internus muscle, (Huderist 2011)

### **2-2-3 Uterine ligaments and supports include:-**

The levator ani muscles; the transverse cervical, pub cervical, and uterosacral ligaments, the broad and round ligaments. The broad ligaments are formed by anterior and posterior reflections of peritoneum passing over the Fallopian tubes. They enclose the parametrial connective tissue in addition to the round ligaments,

uterine vessels, and accompanying lymph channels and ovarian ligaments laterally. The uterus is supplied by sympathetic and parasympathetic nerves (Huderist 2011)

## **2-3 Pathology:**

### **2-3-1 Congenital abnormalities of the uterus :-**

Most of the female genital tract develops from the two paramesonephric (Müllerian) ducts, the caudal portions of which approximate in the midline and fuse to form the uterus, cervix, and upper part of the vagina. The upper divergent portions of the ducts form the uterine tubes. Congenital abnormality can result from, failure of or incomplete fusion, failure of canalization, asymmetrical mal development (Huderist 2011) .

### **2-3-2 Gynecologic causes of pelvic pain :-**

it include ,adenomyosis ,degenerative fibroid ,ectopic pregnancy ,Endometritis ,endometriosis ,pelvic inflammatory disease ,rupture ovarian cyst ,tubo-ovarian cyst ,displaced IUCD , (Huderist 2011) .

#### **2-3-2-1 Endometritis:-**

Which is inflammation of endometrium , endometriosis which is an inflammatory disorder where patches of endometrium-like tissue (the inner lining of the mammalian uterus) grow as lesions abnormally-located outside the uterine cavity **(Huderist 2011).**

#### **2-3-2-2 Fibroids**

**Fibroids** are muscular tumors within the uterus. Intramural fibroids are especially common, and can range in size from a few millimeters to the size of a grapefruit. Subserosal fibroids affect the outer lining of the uterus. They may begin as intramural fibroids—of the middle, muscular layer of the uterus—that grow into the outer wall, pushing on it, or they may originate in the outer wall. Some Subserosal fibroids grow off of the uterus kind of like a dog ear. These are called

pedunculated fibroids. Fibroids that either push on the endometrium—the inner lining of the uterus—or originate from the endometrium are called submucosal fibroids. Any type of fibroid may cause cramping, especially during menstruation. Fibroids that grow within, push on, or even lightly touch the endometrium may cause bleeding, from light spotting in between periods to long, heavy periods. Women who have a uterus that tips backwards—a normal positional variant—may experience lower back pain with fibroids (**Salveson 1995**).

### 2-3-2-3 Polyps:

Polyps are growths within the endometrium. These are often attached to a stalk that is filled with blood vessels. This can often be seen using ultrasound Doppler, a technology that shows the movement of blood cells. Since polyps are within the endometrium, they often cause unusual bleeding—sometimes light and spotty, sometimes heavy and clotty. Polyps may be cancerous, so an endometrial biopsy and a hysterosonogram may be done. A sample of endometrial tissue is taken during the biopsy and sent to a lab to test for cancer cells (**Salveson 1995**).

### 2-3-2-4 Adenomyosis:-

It is the growth of basal layer of the endometrium down into the myometrium. Endometrial stroma, glands are found well in the myometrium between the muscle bundles. The uterine wall often becomes thickened and the uterus is enlarged. Because they are derived from the stratum basalis of the endometrium, they do not undergo cyclical bleeding. Nevertheless, adenomyosis may produce menorrhagia, dysmenorrhea, and pelvic pain before the onset of menstruation (**Salveson 1995**).

### 2-3-2-5 Endometriosis :-

It is characterized by endometrial glands and stroma in a location outside the endomyometrium. It may present as a pelvic mass filled with degenerating blood. Manifestations depend on the distribution of the lesions. Extensive scarring of the

oviducts and ovaries produces discomfort in the lower abdominal quadrants, and eventually causes sterility. Pain on defecation reflects rectal wall involvement, and dyspareunia (painful intercourse) and dysuria reflect involvement of the uterine and bladder serosa, respectively. Almost in all cases, there is severe dysmenorrhea and pelvic pain as a result of intrapelvic bleeding and periuterine adhesions (Hudriska 2011)

#### **2-3-2-6 Fallopian Tubes:-**

Salpingitis is the most common disease of the fallopian tubes, almost always as a component of pelvic inflammatory disease. It is almost always microbial in origin. Salpingitis increases risk of tubal ectopic pregnancy. All forms of Salpingitis may produce fever, lower abdominal or pelvic pain, and pelvic masses. They may result in tubo-ovarian abscess, or tubo-ovarian complex. And damage or obstruction of the tubal lumina may produce permanent sterility pyosalpinx, hydrosalpinx (Salveson 1995). .

#### **2-3-3 Pelvic inflammatory disease (PID):-**

Pelvic inflammatory disease (PID) occurs when an infection spreads from the vagina to the cervix, the endometrium (lining of the uterus) and the fallopian tubes.. PID can lead to scarring of the fallopian tubes and infertility. It can also occur after a ruptured (burst) appendix or a bowel infection (Salveson 1995). .

#### **2-3-4 Non-gynecologic causes of pelvic pain:**

Common gastrointestinal and genitourinary causes where Sonographic plays a role, Appendicitis, Urethral calculi Inflammatory bowel disease. Most common GI cause of pelvic pain in women. Diffuse or periumbilical pain that migrates to the right lower quadrant. Hyper echoic foci adjacent to the wall are commonly demonstrated. A gynecological condition characterized by the presence of ectopic endometrial glands and hyperplastic stroma in the myometrium. Commonly incorrectly labeled as fibroids. Usually in the older reproductive age group.

Uterine tenderness, Dysmenorrhea, Menorrhagia. Abnormal myometrium\_Hypoechoic areas corresponding to smooth muscle hyperplasia, Echogenic heterotypic endometrial tissue (**Salveson 1995**). .

#### **2-3-4-1 Pelvic congestion syndrome :-**

- Chronic pelvic pain that is associated with dilatation of pelvic veins (i.e. pelvic varices) and reduced venous return., dull chronic pain exacerbated by prolonged standing and relieved by lying down and elevating the legs., pelvic congestion Sonographic shows the presence of tortuous and dilated pelvic venous plexuses, dilated arcuate veins crossing the uterine Myometrium ,pelvic congestion, Sonographic signs, dilatation of the left ovarian vein with reversed caudal flow, polycystic-like changes of the ovary, and variable spectral Doppler waveforms in the veins during the Valsalva maneuver (**Salveson 1995**).

#### **2-3-4-2 Chronic pelvic pain:**

Disabling condition which may have more than one cause and Gyn, GI, GU and MSK abnormalities involved. Other causes of chronic pelvic pain Intrauterine contraceptive devices which is easily visualized by transvaginal Sonographic due to their increased echogenicity and marked attenuation of the sound beam, abnormal position may cause chronic pain ,TVS with 3D reconstructions in the coronal plane can confirm the position of the entire IUD in the uterus ,when abnormally located, may show that part of the IUD is imbedded in the Myometrium (**Huderist 2011**)

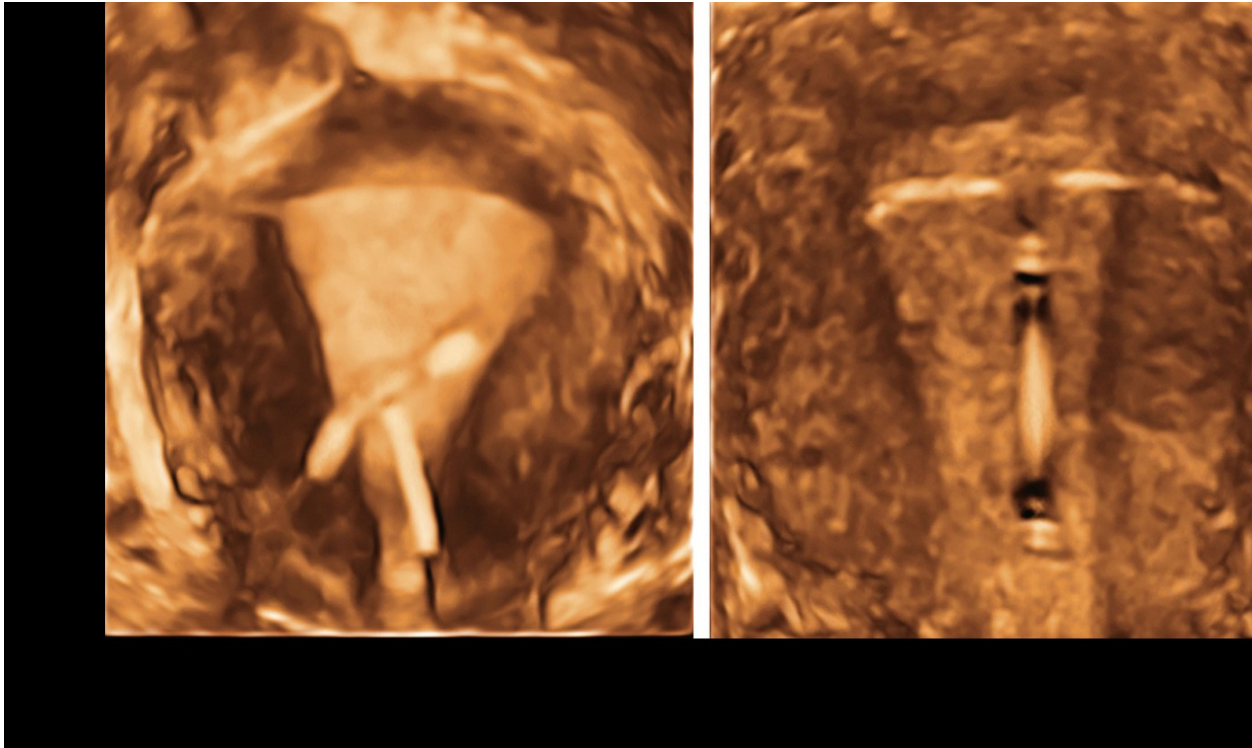


Figure 2-5 shows Three-dimensional reconstructed coronal view of uterus that contains a Paragard intrauterine device (IUD). (Salveson 1995).

## **2-4 Imaging Modalities used in pelvic:**

### **2-4-1 Histro salping raphy (HSG):-**

X-ray assessment of the uterus and the fallopian tubes by injecting a contrast material into these structures, indication is primary and secondary infertility,

recurrent miscarriages following tubal surgery, detect congenital anomalies, to know condition of tubes, its site block, hydrosalpings0 and to localize misplaced IUCD ( **Cronin 2002**)

Figure 2-6 shows hysterosalpingography ( Cronin 2002)

#### **2-4-2 Digital subtraction angiography:**

Angiogram via a right common femoral artery puncture of the left internal artery confirmed the presence of a large fistulous communication between the left uterine artery and a branch of the left internal iliac vein. Superselective catheterization of the left uterine artery was performed using a which were passed coaxially through the 4-French Cobra catheter (for better assessment of the location and size of the fistula) ( **Cronin 2002**)

#### **2-4-3 MRI of the pelvis**

was performed on a 1.5T system with a phased array coil (Achieva; Philips, Best, The Netherlands). In order to characterize this pelvic lesion, we applied the following imaging sequences:



axial T1 weighted (repetition time/echo time (TR/TE), 550/8 ms) fast spin-echo imaging; sagittal and axial T2 weighted (TR/TE, 3700/90 ms) fast spin-echo imaging; (3) three dimensional dynamic enhanced spoiled dual gradient echo fat-suppressed MR images following 0.1 mmol kg<sup>-1</sup> of gadopentetate dimeglumine (Magnevist; Berlex MR angiography (Gd-MRA), maximum intensity projection and multiplanar reconstructions of the subtracted datasets in post-embolisation follow-up. There were large conglomerate tortuous vessels within the left hemipelvis associated with an arteriovenous communication between the branches (probably uterine) of the left internal iliac artery and vein (Figure 1a,b). No dilatation of the left ovarian vein was identified, suggesting venous reflux as a cause of the pelvic congestion syndrome **(Cronin 2002)** .

#### **2-6 Trans abdominal ultrasound and MRI Coronal cut show appendicitis**

Serves an important role in patients with non localizing symptoms, an indeterminate US evaluation, or in patients who require a wider search beyond the field of view available with US. In addition, the widespread availability of and familiarity with CT have helped to expand its role in the emergency evaluation of the female patient with acute pelvic pain. Magnetic resonance imaging (MRI) is an extremely useful second-line modality for problem solving after US or CT has been performed Clinicians should be knowledgeable about available imaging modalities **(Kim SH,2004)**

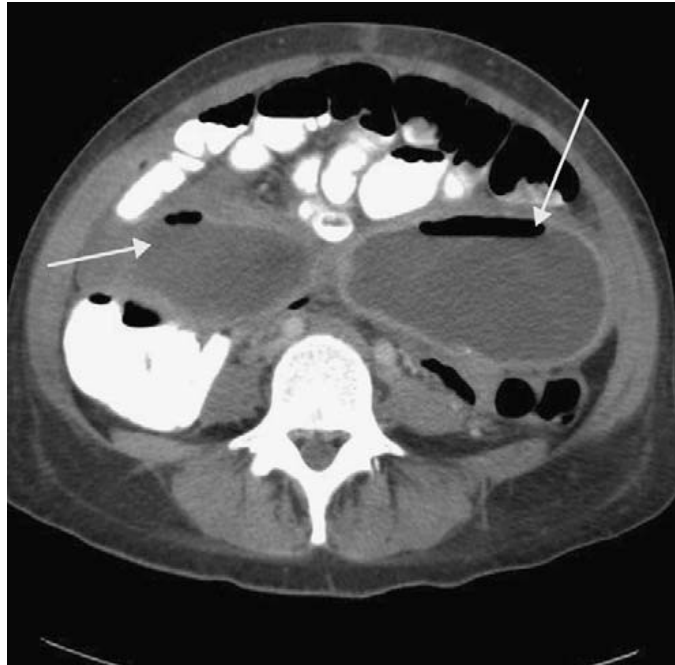
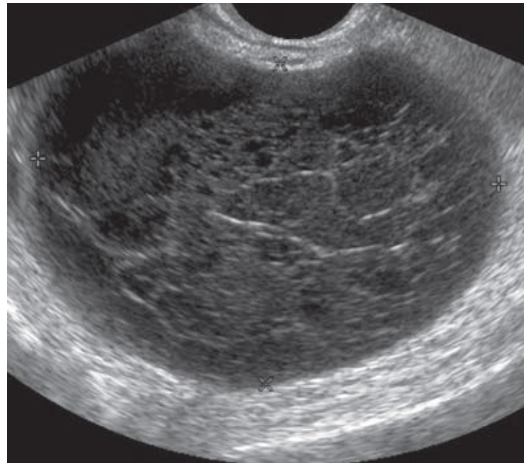


Figure 2-7 shows:.. Enhanced computed tomography shows bilateral, gas-containing, tubo ovarian abscesses (arrows). ( Kim SH,2004)

#### 2-3-6-8 Ultrasound (US):

Ultrasound frequently is the first imaging test performed when pelvic pain is intense enough or of a long-term duration to warrant medical evaluation. The results of this procedure therefore, play a pivotal role in directing the patient to surgical or medical consultation or just watchful waiting. Therefore, it is important for sonographer to be aware of the differential causes of pelvic pain and how ultrasound may be utilized in making the diagnosis. A correct diagnosis at an earlier, less complicated stage could possibly save the patient from a catastrophic outcome. Thus the sonographer that are involved in the evaluation should have a firm understanding of the general symptomatology behind the various etiologies of pelvic pain ( **Kim SH,2004**)

Figure 2-8  
ovarian cyst.



Hemorrhagic  
Transverse

transvaginal US image of the adnexa shows a complex hemorrhagic cyst with the characteristic echogenic pattern of fibrin strands that form as blood clots and retracts **(Kim SH,2004)**

▪

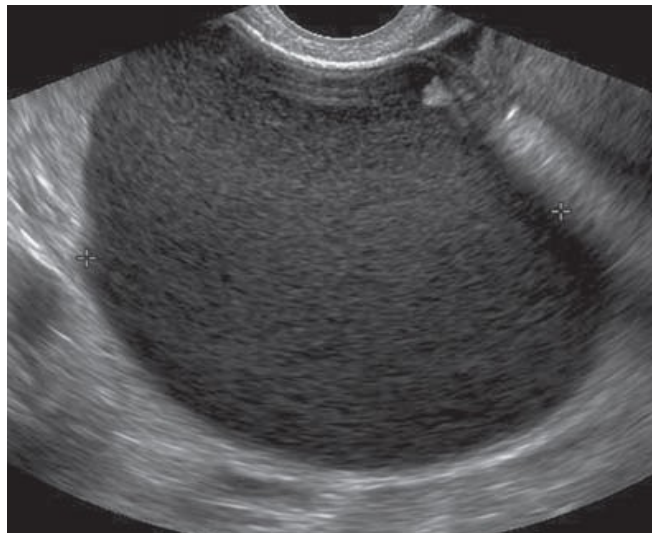


Figure 2-9 shows Endometrium. Longitudinal transvaginal US image of the adnexa well-defined, complex cystic mass with low-level internal echoes ( Kim SH,2004)

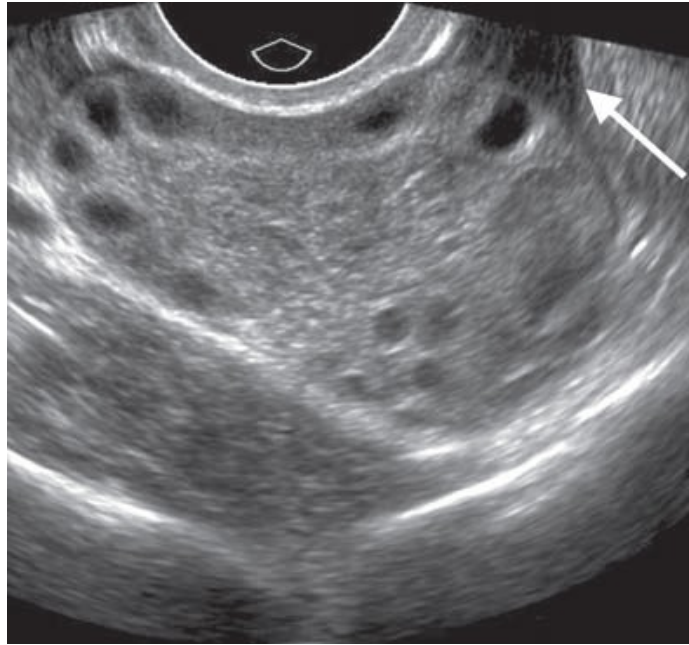


Figure 2-10 shows adnexal torsion. Longitudinal transvaginal US image shows an enlarged ovary ( ( Kim SH,2004)

#### **2-4-1Guide line of the Female Pelvis ultrasound :-**

Abnormalities of the uterus should be documented, the myometrium and cervix should be evaluated for contour changes, echogenicity, masses, and cysts, masses that may require follow up or intervention should be measured in at least two dimensions. The size and location of clinically relevant fibroids should be documented, the endometrium should be analyzed for thickness, focal abnormalities, echogenicity, and the presence of fluid or masses in the cavity. The thickest part of the endometrium should be measured perpendicular to its longitudinal plane in the anteroposterior diameter from echogenic to echogenic border. The adjacent hypo echoic myometrium and fluid in the cavity should be excluded, assessment of the endometrium should allow for variations expected with phases of the menstrual cycle and with hormonal supplementation. It should be reported if the endometrium is not adequately seen in its entirety or is poorly

defined, If the patient has an intrauterine contraceptive device, its location should be documented. (**Ultrasound of the Female Pelvis -2014 [www.aium.org](http://www.aium.org)**)

### **2-5-2 Pelvic US Technique:**

Gynecological Sonographic always requires an acoustic window provided by a full bladder. This will also displace bowel loops with their gas content. Filling should be adequate. An over distended bladder will compress the uterus and adnexa and result in distortion of its normal anatomy. Adequate is learned by experience, but generally the bladder is over distended if the posterior wall is not impressed by the normal anteverted uterus. The patient may be scanned in the upright position or advised to partially empty the bladder. Inadequate filling allows some bowel loops to cast their posterior shadowing and obscure the uterine fundus. With the patient in supine position, the transverse diameter of the bladder may not allow clear simultaneous visualization of the adnexa. Diagonal scan with one side of the patient raised may be attempted. ((gynecological US is incomplete without a urinary-system survey to exclude unilateral or bilateral hydronephrosis or hydroureters.) ( Kim SH,2004)

The scan used are two types, Transabdominal scan & Transvaginal scan, and transducer used are Multifrequency, Curvilinear Transabdominal Probe with a frequency of 3.5 - 5 MHz, Multifrequency Transvaginal Probe with a frequency of 7 - 9 MHz The pelvic organs are routinely visualized by 2 approaches, Transabdominal (TA) and Transvaginal (TV). The standard examination should start with the trans-abdominal approach followed by the trans-vaginal if indicated. If the transabdominal scan is completely normal or a well defined abnormality is detected no further study is usually necessary. Patient in a supine position with reverse Trendelenberg with transvaginal scanning Transabdominal versus Transvaginal\_Scanning ( Kim SH,2004)

#### **2-5-2-1 Complimentary Techniques**

The transabdominal approach offers a far wider Field of View allowing visualization of the entire pelvis and abdomen offering a global overview. Transabdominal Pelvic Scanning, Transabdominal pelvic scanning should be performed with a distended bladder provides an acoustic window, and displaces small bowel away from the pelvic viscera. Partially retroflexed the normally antverted uterus to maintain the endometrial echo at a more perpendicular angle to the beam improving definition of the endometrium and any contents, serves as a reference standard for evaluating cystic structures, uterus and adnexae should be imaged in both the sagittal and transverse Planes• The long axis of the uterus is identified by the endometrial stripe and may require an oblique angulations to visualize the entire uterus and cervix. The adnexae may be imaged by scanning directly over the a adnexae Obliquely from the contra lateral side using the bladder as an acoustic window. Ovaries identified medial and anterior to iliac vessels. Causes of pelvic pain may be divided in tow group gynecological and non gynecological cause ( Kim SH,2004).

#### **2-5-2-2 3D \ 4D Ultrasound:-**

Most ultrasounds are routinely performed using conventional 2 dimensional (2D) scanning. This is where the ultrasound beam scans through a thin slice of the body, and shows the image on a screen in 2 dimensions only. The image usually appears grey on the ultrasound screen, although the sonographer may sometimes change the colour of the picture. This type of ultrasound provides most of the clinically relevant information to the doctor. With 3D ultrasound, a series of thin 2D slices is digitally reconstructed to give more life-like images. With 4D ultrasound, the added dimension is time, so that the 3D images appear to be moving in real time.

The 3D/4D image usually appears a golden colour on the ultrasound screen, as this colour is easy for patients to look at and highlights features on the baby. 3D/4D ultrasound uses the same ultrasound beams as the conventional 2D ultrasound, with extra processing performed by the ultrasound machine computer. 3D/4D ultrasound is just as safe as conventional 2D scanning, with no evidence that it harms. There is a diagnostic role for 3D/4D ultrasound in pelvic scans, although the conventional 2D ultrasound still provides most of the information . A conventional 2D ultrasound of the pelvis will always be performed initially, with 3D images added as needed. 3D/4D images can obtain views of the pelvis that are not seen on the conventional 2D ultrasound. 2D ultrasound can obtain longitudinal and transverse views of the uterus. 3D ultrasound adds in the coronal view (or C-plane) of the uterus, enabling us to get an image of the uterus which is “front on”.3D/4D ultrasound may help in the diagnosis and assessment of pelvic conditions, including, Congenital uterine abnormalities. (for example, bicornuate uterus), location of endometrial polyps, location of submucous fibroids and assessment of any intramural component, location of an intrauterine contraceptive device (IUCD), especially if the IUCD is abnormally located (for example, penetrating into the wall of the uterus) ( **Kim SH,2004**).

### **2-5-2-3 Saline Sono Histogram**

Saline sonohysterogram is a simple outpatient ultrasound procedure designed to help the doctor look at the endometrial cavity (the inside part of the uterus) and the endometrium (the lining of the endometrial cavity). the doctor may request this test for a number of reasons, including, looking for a lesion in the endometrium, such as a polyp. The saline sonohysterogram will help confirm or exclude the presence of an endometrial polyp or submucous fibroid, investigation of postmenopausal bleeding, especially if the endometrium is not well seen on a regular pelvic ultrasound, or if the endometrium appears thicker than expected, assessing the

shape of the endometrial cavity. The saline sonohysterogram evaluates the contour of the endometrial cavity, detecting conditions such as a uterine septum or bicornuate uterus .3D/4D imaging of the uterus during the sonohysterogram is particularly useful for the assessment of congenital uterine anomalies. This information may be used to investigate problems like recurrent miscarriages or infertility ( **Kim SH,2004**)

### **2-5-2-3-1Patient preparation**

It is important that you are sure the patient not pregnant, the best time to perform a saline sonohysterogram is just after your period has finished, approximately day 7 to day 10 of a regular 28-day (monthly) menstrual cycle (the first day of your period is counted as day 1), the menstrual cycle is shorter than 28 days (for example, you usually only have 21 days between periods), you will need to have the test earlier in the cycle and your menstrual cycle is longer than 28 days, but still regular (for example, you usually have 35 days between periods), you may be able to have the test later in the cycle if that is more convenient ( **Kim SH,2004**) .

The vaginal speculum gently inserted into the vagina to visualize the cervix. The cervix is then cleansed with antiseptic solution, to decrease the risk of infection. A thin flexible catheter is inserted through the opening of the cervix, so that the catheter lies within the endometrial cavity. Inserting this intrauterine catheter does not usually cause discomfort. The vaginal speculum is then removed, with the catheter remaining inside. Next, the transvaginal ultrasound (internal scan through the vagina) is used to image the uterus. A small amount of sterile saline (approximately 10ml) is introduced into the endometrial cavity through the catheter. This saline distends the endometrial cavity, allowing better assessment of the contour and shape of the endometrium. The transvaginal ultrasound and catheter are removed at the end of the test It is a safe and well-tolerated procedure for the assessment of the endometrial cavity (**Kim SH,2004**).



Hysterosalpingo-contrast-Sonographic (usually shortened to HyCoSy) is a simple and well-tolerated outpatient ultrasound procedure used to assess the patency of the fallopian tubes, as well as detect abnormalities of the uterus and endometrium. The test requires the use of a contrast agent to visualize the patency of the fallopian tubes. (an agitated saline / air mixture Or use of a non-iodinated contrast agent called Foam. If Foam is used, the test is then referred to as a HyCoSy procedure. The HyCoSy procedure is a safe and reliable alternative to the conventional hysterosalpingogram (HSG) which uses X-rays. No radiation or iodinated contrast material is used for a HyCoSy test The Investigation of infertility is the main reason for a woman to be referred for a HyCoSy procedure, occluded (blocked) fallopian tubes are a common cause of infertility **(Kim SH,2004)**.

Even if the fallopian tube is blocked, it may still be difficult to see on regular ultrasound unless it is also filled with fluid (forming what is known as a hydrosalpinx). This is why a special test using a contrast agent such as Exam Foam is useful, as it helps the doctor to visualize the fallopian tubes and assess whether they are patent (working). The HyCoSy procedure allows integrated assessment of the fallopian tubes, the uterus and endometrial cavity, and the pelvis. The initial part of the HyCoSy procedure uses saline (like a saline sonohysterogram) to assess the endometrial cavity for pathology. The sonographer will be looking for problems such as endometrial polyps, submucous fibroids and congenital uterine abnormalities (such as uterine septum) **(Kim SH,2004)**.

#### **2-5-2-3-2 Technique:**

The vaginal speculum gently inserted into the vagina to visualize the cervix. The cervix is then cleansed with antiseptic solution to decrease the risk of infection. A thin flexible balloon catheter is inserted through the opening of the cervix, so that the catheter lies within the endometrial cavity. Inserting this intrauterine catheter does not usually cause discomfort. A tiny balloon at the tip of the catheter is slowly

inflated with saline – this is necessary to stop fluid leaking back out through the cervix during the test. Inflating this tiny balloon can cause some discomfort. The vaginal speculum is then removed, with the catheter remaining inside the uterus. Next, the transvaginal ultrasound (internal scan through the vagina) is used to image the uterus. Initially, a small amount of sterile saline is introduced into the endometrial cavity through the catheter, as occurs with a saline sonohysterogram. This saline distends the endometrial cavity, allowing assessment of the contour and shape of the cavity. The doctor will be looking for such problems as endometrial polyps, submucous fibroids and congenital uterine abnormalities (such as uterine septum). ( **Kim SH,2004**).

Next, a small amount of a contrast agent (either agitated saline /air mixture, or Exam Foam) will be introduced through the catheter. The doctor will be looking at both fallopian tubes, to see if the tubes are patent. If the contrast can be seen flowing through each tube, and spilling out the end of the tube into the area around the ovaries, the tubes are patent. The transvaginal ultrasound and catheter are removed at the end of the test. HyCoSy is a safe and well-tolerated procedure for the assessment of tubal patency (**Kim SH,2004**).

#### **2-5-2-2-4 Advantages of HyCoSy compared to HSG include:**

HyCoSy does not use radiation or ionizing contrast material, many women find HyCoSy less painful than HSG, small lesions in the endometrial cavity such as polyps may be better demonstrated with HyCoSy, HyCoSy can assess submucous fibroids protruding into the endometrial cavity for intramural components thus assisting plans for surgical removal, congenital uterine abnormalities may be better assessed with HyCoSy as the external contour of the uterus is viewed on ultrasound but not on X-ray. This can help define the exact type of congenital uterine abnormality, permanent tubal occlusion, secondary to an underlying problem such as pelvic adhesions. Technical factors may hinder visibility during

the ultrasound, such as uterine fibroids, size of the patient abdomen, and bowel in the pelvis (Kim SH,2004).

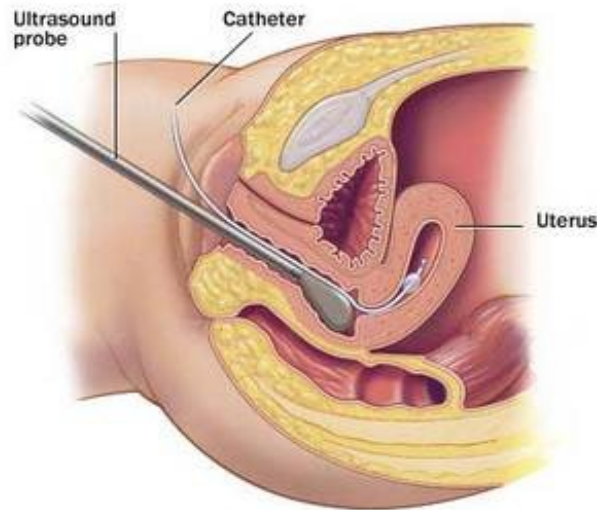


Figure 2-  
HYCOSY is  
laparoscopy  
2-5-2-2-

#### advantages and

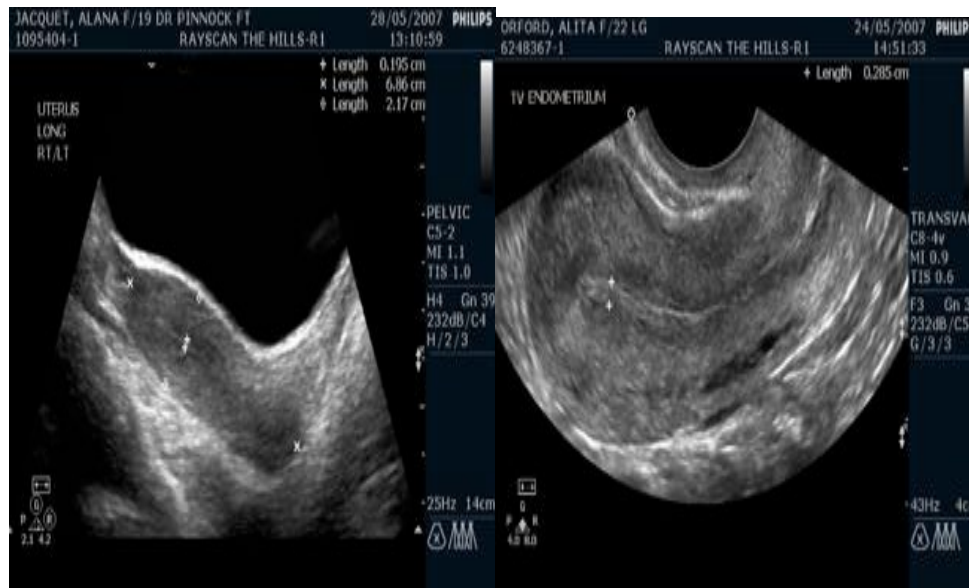
© Mayo Foundation for Medical Education and Research. All rights reserved.

11shows the  
done such as  
( Kim SH,2004).

#### 5Different

#### limitations:

Both techniques mean that the pelvic examination frequently employs both to gain maximum information. The limitations of transabdominal ultrasound includes, examining patients with empty urinary bladders, the examination of the obese patient, and the evaluation of the retroverted uterus, and often less than optimal characterisation of adnexal masses. Transvaginal sonography allows the use of higher frequency transducers producing much better resolution, the limitation of transvaginal ultrasound is that the Field of View is limited ( Kim SH,2004).



TA

TV

2-12Trans vaginal and trans abdominal ( Kim SH,2004).

## 2-5-3 Ultrasound finding of causes of pelvic pain

### 2-5-3-1 Sonographic features of appendicitis:-

Blind ended thick walled, tubular non compressible, peristaltic structure, at least 3 mm single wall thickness, appendicolith highly specific, surrounding echogenic fat, increased color Doppler vascularity within wall ( Kim SH,2004) .

### 2-5-3-1 Adenomyosis :-

Is defined by the presence of ectopic endometrial glands and stroma within the myometrium. The presence of ectopic endometrial glands and stroma induces a hypertrophic and hyper-plastic reaction in the surrounding myometrium tissue. Uterine enlargement, heterogeneous echo texture, cystic anechoic spaces or lakes in the Myometrium, sub endometrial echogenic linear striations, uterine wall thickening, obscure endometrial/myometrium border, thickening of the transition zone, and tenderness ( Kim SH,2004).

### 2-5-3-2 Leiomyomas :-

Well circumscribed, Hypo -iso hyperechogenicity, Peripheral vessels, Shadowing, non tender unless get degenerative, Often calcified, Usually multiple, Location : intramural, submucosal & Subserosal ( Kim SH,2004).

### **2-5-3-3 Endometritis :-**

Thick endometrium with high echogenicity, acoustic enhancement, fluid and gas. It is an inflammatory disorder where patches of endometrium-like tissue grow as lesions abnormally-located outside the uterine cavity. The tissue is thought to originate from endometrial fragments shed at menses, Women with endometriosis often complain of chronic, pelvic pain and infertility. Is defined as the presence of endometrial glands and stroma outside the uterine cavity. Direct extension of endometrial tissue along the round ligament is a possible pathogenesis of inguinal endometriosis( Kim SH,2004).

### **2-5-3-3-1 Sonographic features of endometriomas :-**

Single or multiple thick walled cystic masses with diffuse low level homogeneous echoes. Hyper echoic foci adjacent to the wall are commonly demonstrated. Hydrosalpinx and pyosalpinx can usually be readily distinguished from pelvic veins and bowel by visualizing the color flow within the patent blood vessels and peristalsis within the bowel. Imaging findings in TOAs may be nonspecific and must be distinguished from endometriomas, ectopic pregnancies, hemorrhagic cysts, ovarian tumors, and abscesses from adjacent organs. The Sonographic features of inguinal endometriosis are variable. The presence of solid masses, cystic masses, and combined cystic and solid masses has been described.:- the Sonographic features of inguinal endometriosis may be variable, a cystic appearance is not rare. Endometriosis should be included in the differential

diagnosis when a unilocular or multilocular cystic mass in patients with painful inguinal swelling is encountered on Sonographic ( Kim SH,2004).

#### **2-5-3-5 Sonographic appearance Hemorrhagic functional cyst**

A diffuse pattern of low level echoes, Internal echoes and septations, Leakage of hemorrhagic fluid with associated, peritoneal irritation is common, more commonly associated with an endometriomas, hemorrhagic functional cyst( Kim SH,2004).

#### **2-5-3-6 Ovarian Torsion**

Sonographic findings of ovarian torsion the completely torsed ovary is enlarged and appears edematous, affected ovary may show a heterogeneous echo texture affected ovary may show small spherical cystic areas towards the periphery associated intraperitoneal fluid may be seen, in cases of partial torsion, the ovary may be normal in size and show normal intra-ovarian flow, but the echo texture is usually heterogeneous. In cases of isolated tubal torsion, the affected fallopian tube is distended and appears as a cystic pelvic mass with normal ovarian flow enlarged ovary or ovarian complex, irregular internal texture suggesting, hemorrhage and edema, and peripherally placed follicles( Kim SH,2004)

#### **2-5-3-6-1Doppler evaluation of ovarian torsion :-**

Lack of arterial and venous signal, should enable confident diagnosis

False positive diagnoses may be obtained, depth of penetration greater than beam capabilities and improper Doppler or grayscale settings (ie. PRF setting)

#### **2-5-3-7 Intrauterine contraceptive devices :-**

Easily visualized by transvaginal Sonographic due to their increased echogenicity and marked attenuation of the sound beam, abnormal position may cause chronic

pain when abnormally located, may show that part of the IUD is imbedded in the myometrium

### **2-5-3-8 Common gastrointestinal and genitourinary causes of pelvic pain where ultrasound plays a role :-**

Appendicitis is most common GI cause of pelvic pain in women, diffuse or periumbilical pain that migrates to the right lower quadrant (**Zafar N 2011**)

### **2-5-4 Ultrasonic Safety**

The question of whether diagnostic ultrasound can have harmful effects has been the subject of many papers and discussions since it was first introduced. Traditionally, the view has been that ultrasound hazards can arise through three mechanisms, cavitations, heating and micro streaming. Currently, most emphasis is being place on the thermal effects of ultrasound and the possibility of ultrasound induced thermal damage. Unfortunately, it is extremely difficult to predict the temperature rise which a given ultrasound beam will produce in a given volume of tissue and the knowledge that vasodilatation will generally occur in most heated living systems confounds the calculation still further. It is likely that the temperature rise will be related not to the total output power from the transducer but rather to the way in which the output is distributed in time and space. Thus the Spatial Peak Temporal Average Intensity (ISPTA) is often used as a general indicator of the heating potential of a given beam (**Zafar N 2011**) .

An important statement from the American Institute for Ultrasound in Medicine and Biology [1](#) suggests that if the ISPTA does not exceed  $100\text{m W cm}^{-2}$  then this should be considered unequivocally safe. This condition is satisfied by almost all machines when operating in normal imaging mode. However, when pulsed Doppler or CF Doppler is used, it is common to find ISPTA well in excess of this. An additional consideration arises from the possibility of heating directly from the probe itself. In pulsed Doppler mode the transducer, which has been optimized to

produce the short imaging pulses, is required to generate and receive longer pulses. Its efficiency for this purpose is relatively low. The loss of energy due to inefficiency manifests itself as heat in the probe itself and there is evidence that left unattended in worst case conditions, some probes can reach up to 60°C.

Most of the vast bulk of epidemiological evidence supports the assertion that no one anywhere has ever been shown to have been damaged by the ultrasonic energy from a diagnostic machine. The epidemiological evidence relating to the safety of ultrasound in obstetric applications has recently been reviewed.

Studies have been conducted relating to possible associations of ultrasonic exposure of the fetus with childhood malignancies, neurological maldevelopment, left-handedness and low birthweight. It seems clear that most of the work supports the notion of there being no association of these outcomes with ultrasound exposure. However, they conclude that on some issues, such as the incidence of left-handedness and low birth weight, no firm conclusions can yet be drawn and hence the recent trend has been towards somewhat more guarded statements than in the past. There is no direct evidence that these effects are harmful but nonetheless it should be noted that the general consensus is that the developing embryo is most at risk, and that this risk is maximized when the embryo is imaged transvaginal using pulsed Doppler. In fact, the European Federation of Societies for Ultrasound in Medicine and Biology (EFSUMB) has issued (**Zafar N 2011**)



## **2-5 Previous studies :-**

**Zafar N 2011** Ultrasound has been proven to be useful in detecting any underlying pelvic pathology. Lee *et al.* concluded that identification of the twisted vascular pedicle through ultrasonography is suggestive of ovarian torsion, and color Doppler Sonographic could be helpful in pre-dicting the viability of adnexal structures by depicting blood flow within the twisted vascular pedicle. Gray- scale findings typically include asymmetric enlargement, a solid heterogeneous appearance, and peripheral cystic areas; detected by Doppler Sonographic is highly predictive of adnexal torsion and is therefore useful in the diagnosis of ovarian torsion; however, the detection of normal flow does not necessarily exclude ovarian torsion. Thus, our results are similar to those of international studies. \_USG is a valued tool for clinically suspected appendicitis and it enhances the diagnostic accuracy in cases with pain in the RIF and \_reduces the number of negative appendicectomies. \_Of the 58 cases of appendicitis, pain in abdomen and vomiting were the predominant clinical symptoms, but they are not specific for acute appendicitis.

Tenderness in RIF was present in almost all cases. Rebound tenderness, guarding and Rovsing's sign if present, are more specific for acute appendicitis. These findings tallied with the findings of the study by Acute appendicitis is the most common

acute abdominal condition, necessitating emergency surgery. When the clinical signs and the symptoms are combined with USG findings, the diagnostic accuracy is significantly high. USG helps in diagnosing other causes of RIF pain which helps in excluding appendicular pathology. The overall specificity of abdominal USG in the diagnosis of acute appendicitis was 88.09% and sensitivity was 91.37%. It should be emphasized that USG does not replace clinical diagnosis, but is a useful adjunct in the diagnosis of acute appendicitis. We recommend USG as a valuable tool in diagnosing acute appendicitis in spite of sophisticated investigations like CT abdomen and laparoscopy; thus, reducing the cost of treatment and preventing negative laparotomies.

**George MJ, 2002** study shown that pre-operative transvaginal ultrasound examination can be used to diagnose pelvic endometriosis and to assess its severity. The total number of endometriosis lesions found at laparoscopy has statistically significant positive effect on the accuracy of ultrasound diagnosis of deeply infiltrating lesions. The sensitivity of the ultrasound diagnosis was significantly affected by the location of the endometriotic lesions but the specificity remained high throughout. We have shown for the first time that ultrasound enables detection and assessment of severity of adhesions affecting the ovaries and pouch of Douglas.

The accuracy of TVS was highest in the diagnosis of ovarian adhesions, pouch of Douglas obliteration and bladder lesions. The accuracy for these features was similar to the accuracy for ovarian endometriomas which were previously thought of as the only feature of pelvic endometriosis which it is possible to diagnose on ultrasound. Previous studies have stated that left sided endometriomas are more common than right but there was no statistically significant difference in our data

set. Our study has also shown that only 26.9% of women with focal endometriosis will have disease in only one location and therefore in all cases the examiner should perform a detailed search for lesions in other typical locations. Our study showed a high specificity of the diagnosis of rectovaginal disease and a lower sensitivity. This agrees with the results of a recent review by Hudelist encompassing 10 studies on the diagnostic accuracy of TVS for intestinal endometriosis. He found sensitivities ranging from 67- 98% and specificities of 92-100%. The effect of the number of lesions on the sensitivity of ultrasound diagnosis of specific endometriotic lesions in different locations has not been assessed before. Our data shows that the accuracy of the diagnosis of individual specific lesions increases with their absolute number up to a maximum of three lesions. With increasing number of lesions above that level the sensitivity declines. A possible reason for this could be that in more severe disease the adhesions tend to obscure other small lesions further away from the ultrasound probe. There is also a possibility of operator bias as in women with evidence of severe disease documentation of the presence of small lesions such as those located at utero-sacral ligaments becomes less clinically relevant. Our study could be criticised for not more accurately differentiating between DIE of the rectum and sigmoid or between rectovaginal and vaginal disease. We could also be criticised for including subjective assessments such as ovarian and pouch of Douglas mobility which cannot be recorded with ease. However we diagnosed ovarian and pouch of Douglas disease with greater accuracy than other features of endometriosis which indicates that subjective assessment is accurate enough to be used in routine practice. Reproducibility of these findings however needs to be externally validated before we can reach a consensus about the value of subjective assessment for the diagnosis of ovarian and pouch of Douglas adhesions. Scanning for endometriosis is difficult and we believe that the use of palpation is of critical

importance to achieve good diagnostic accuracy. Gynaecologists use palpation routinely as part of pelvic examination and they can incorporate it more easily into ultrasound examination than sonographers or radiologists. For this reason it remains to be seen whether these results can be extrapolated to units with different levels of experience and expertise.

**Salveson KA 1995** Our study has shown that the specificity of the ultrasound diagnosis of pelvic endometriosis lesions is high with low false positive rates. The negative diagnostic rate was less high especially in the diagnosis of bowel, rectovaginal, uterosacral ligament, pelvic side wall and uterosacral ligament lesions. Therefore women with significant symptoms and a negative diagnosis still require further investigation. The accuracy of ultrasound diagnosis is significantly affected by the location and number of endometriosis lesions.

**Tarjan Z., et al 1994** their study conclude that US advantage of over CT is that it allows precise correlation of the US findings with the area of maximum tenderness or with a palpable mass with. Another advantage of US is its mobility and flexibility: It can be done in the Emergency Ward, High Care Units and the Operating Room, and with the present generation of small, battery-assisted, hand-held units, in fact anywhere. Furthermore, in case of intra peritoneal fluid, US guided puncture is a safe and rapid way to determine if the fluid is blood, pus, bile, amylase, gastric contents, etc. US examination allows a natural and direct form of communication with the patient. Information provided by the patient may lead to a specific search for a US finding, while, vice versa, certain US findings may lead to a specific question to the patient. In 24% 12 cases of our patients with findings of appendicitis, pain in the pelvic and lower abdomen, vomiting and tenderness in RIF were the predominant clinical symptoms, was present in almost all cases in our study, USG helps in diagnosing other causes of RIF pain which helps in . excluding appendicular pathology

**Lee et al 2011** Ultrasound has been proven to be useful in detecting any underlying pelvic pathology.. [21] concluded that identification of the twisted vascular pedicle through ultrasonography is suggestive of ovarian torsion, and color Doppler sonography could be helpful in pre-dicting the viability of adnexal structures by depicting blood flow within the twisted vascular pedicle. Gray- scale findings typically include asymmetric enlargement, a solid heterogeneous appearance, and peripheral cystic areas; detected by Doppler sonography is highly predictive of adnexal torsion and is therefore useful in the diagnosis of ovarian torsion; however, the detection of normal flow does not necessarily exclude ovarian torsion. Thus, our results are similar to those of international studies.

## **Chapter Three**

### **Material and Method**

This study was conducted in the period June 2014-May 2015 .the aim of the study is to assess the role of ultrasound in diagnosis of female pelvic pain at kalba hospital UAE ,Sharjah district and to get an idea of common findings in female pelvic pain.

#### **3-1 Materials:**

##### **3-1-1Sampling:-**

50 female patient, Non pregnant females aged between (5-50 years).

##### **3-1-2 Excluding criteria :-** All pregnant female

**Including Criteria:** Female non pregnant

##### **3-1-3 Tools &equipments:-**

Ultrasound system General Electric, Siemens, (acuson 500) C6-2 curvilinear, C10-5 transverse, (sonoline) EC9-4 ,C5-2, VF 13-5 With transabdominal & transvaginal probes with Doppler and & 3D fascilities . Ultrasound gel makes probe movement easy and more close contact probe-skin.

Adequate documentation is essential for high-quality patient care. There should be a permanent record of the ultrasound examination and its

Transducer a 3.5 MHz transducer for adults, a 5 MHz transducer for children or thin adults.

##### **3-1-3 Area of study:**

A retrospective observation study was conducted at kalba hospital –United Arab Emirates (UAE) - radiology department .

.The Data collected in the tabulated database sheet and analyses

The patients are seen in A/E department and gyne OPD

#### **3-2 Method:**

### **3-2-1 Technique**

#### **3-2-1-1 Preparation**

The bladder must be full, give 4 or 5 glasses of fluid and examine after one hour (do not allow the patient to micturate).

#### **3-2-1-2 Position of the patient:**

The patient lie supine but may need to be rotated obliquely. The patient relaxed, lying comfortably and breathing quietly. Lubricate the lower abdomen with coupling agent. Hair anywhere on the abdomen will trap air bubbles so apply coupling agent generously.

#### **3-2-1-3 Scanning technique:**

Start with transverse scans from the pubic symphysis upwards to the umbilicus. Follow with longitudinal scans, moving from one side of the lower abdomen to the other. These scans usually be sufficient, see the position of the lateral and anterior walls of the bladder and patients turned 30-45° to see an area more clearly. Any area that appears abnormal viewed in several projections. After scanning, the patient empty bladder and then rescanned.

#### **3-2-4 Image interpretations:**

Interpretation. Images fall appropriate areas, both normal and abnormal, should be recorded. Variations from normal size should be accompanied by measurements. Images should be labeled with the patient identification, facility identification, examination date, and side (right or left) of the anatomic Ultrasound printer using thermal paper, CD, DVD & PAC5 Thermal paper. CD or DVD

## Chapter four

### Results

This study was carried out on 50 patients complaining of pelvic pain were examined with the following results according to the age, marital status, complains and ultrasound finding:.

**Table {4-1} frequency distributions of age group**

Age	Frequency
0-10	1
11-20	5
21-30	20
31-40	16
41-50	6
51-	2
TOTAL	50

**graph {4-1} frequency distributions of age group**

**Table {4-2 } show frequency distribution of marital status**

Marital	Frequency
single	12
married	38
total	50



graph {4-2 } show frequency distribution of marital status

**Table {4-3} shows the etiology frequency :-**

Etiology	Frequency
Gyne	28
Git	14
Ut	6
Others	2
Total	50

graph {4-3} shows the etiology frequency

**Table {4-4} show the site gyne cause :-**

Site	Frequency
Myometrium	9
Endometrium	1

Ovaries	16
Peritoneum	2
Total	28

**graph {4-4} show the site gyne cause**

**Table{4-5} shows the area of pain**

Pain site	frequency	Percentage%
Site of gyne etio	28	56
GIT	14	28
UT	06	12
Others	02	04
Total	50	100

**Figure{4-5} shows the area of pain**

**Table{4-6} shows the area of pain according to site**

Gyno				GIT	UT				Others			p.pain
Ov	myo	endo	pret	apped	cysti	u-lith	Ly-N	herni	type			
16	09	01	02	14	3	3	01	01	50			
32%	18%	02%	04%	28%	06%	06%	02%	02%	100%			

**Figure {4-6} shows the area of pain**

## **Chapter five**

### **Discussion, Conclusion and recommendations**

#### **5-1 Discussion:-**

From the collective findings of this study that the more affected ages between 21-30 year with distribution of 38 married (76%) and 12 single (24%) the etiology frequency show that the gynecological pain 28 patients percentage (56%) and their distributions: ovarian cyst 16 patients percentage (32%), Myometrium 8 patients percentage (18%), endometrium 01 patients percentage (02%), peritoneum 02 percentage (04%), from site point of view in gyne we found that the ovaries is more affected part than ,Myometrium and the tubes. the majority of patients come with pelvic and lower abdomen pain.

GIT abnormalities 14 patients percentage (28%) and distributions: appendicitis 14 patients percentage (28%).

UT 6 patients percentage (28%) and distributions: cystitis 3 patients percentage (06%), utilities 3 patients percentage (06%). And others abnormalities other like inguinal hernia ,enlarged lymph node is less presentation 2 patients percentage (04%), These findings tallied with the findings of the study by Rosemary Kozar et al [2014)

## **5 -2 Conclusions :-**

Ultrasound availability, relatively low cost, and absence of ionizing radiation or need to contrast material, US has maintained an important role in evaluation of pelvic pain even during recent diffusion of MDCT. Awareness of normal and pathological Sonographic appearance of pelvic and attention to technique will enable the sonologist to make optimal use of this imaging modality.

Pelvic pain may vary organic or functional .multiple organ systems can contribute to pelvic pain, and the gastrointestinal, genitourinary and peritoneum, all must be considered in patients who come with this symptom.

The diagnostic accuracy of appendicitis (the most common acute abdominal condition ) is significantly high.

The accuracy of TVS was highest in the diagnosis types of ovarian cysts, adenoidal lesions pouch of Douglas free fluid and bladder lesions.

Adenomyosis is less finding in female .

From the collective findings of this study, and considering its limitations in terms of sample size, it is concluded that the definitive diagnosis of pelvic pain in non pregnant female remains challenging. Both clinical and sonographical evaluation of acute pelvic pain should be considered for the diagnosis of pelvic pain. The diagnosis cannot be exclusively based on ultrasound only, on the presence or absence of color flow Doppler, or even on the morphological findings. Therefore, surgical intervention is recommended in suspicions of a nonviable ovary in order to decrease the morbidity

## **5-3 Recommendations**

- 1-The study recommend that US as a valuable tool in diagnosing acute appendicitis in spite of sophisticated investigations.
- 2-Ultrasound must be done as the first modalities to detect the causes of female pelvic pain.
- 3-Transvaginal ultrasound is best in gynecological pain
- 4-Further studies with more sample
- 5- In all emergency hospital there must be qualified ultrasound machine with new accessories and Doppler facilities.

## **Reference :-**

1. Salveson KA, Eik-Ness (SH 1995) A review of epidemiological studies of human exposure to ultrasound. Ultrasound Obstet Gynecol, , 6: 293-298.
2. , Trondheim, European J (1995) European Federation of Societies for Ultrasound in Medicine and Biology (EFSUMB) 1995 Clinical Safety Statement 1994f Ultrasound, 2: 77
3. Goldstein SR, (1996) Report for cleaning and preparation of endocavitary ultrasound transducers between patients. Ultrasound Obstet Gynecol; AIUM, , 7:

92-94 . Ultrasound Obstet Gynecol; AIUM, 7-8 Pre-operative assessment of bladder endometriosis. appendicitis. Orv. Hetil . 1995; 136:713-7.

4-Bazot M, Thomassin I, Hourani R, Cortez A, Darai EBJOG. (2006) Mar; 10 Transvaginal sonography vs. clinical examination in the preoperative diagnosis of deep infiltrating endometriosis. ;24:1575–1589113(3):251-6. [[PubMed](#)] [[Ref list](#)] Chapron C, Pietin-Vialle C, Borghese B, Davy C, Foulot H, Chopin N

5-Cronin P, McPherson SJ, Meaney JF, Mavor A. (2002) Venouscovered stent: successful occlusion of a symptomatic internal iliac arteriovenous fistula. Cardiovasc Intervent Radiol;25:323-5.

6- Fedele L, Bianchi S, Raffaelli R, Portuese A Fertil Steril. (1985) CT and MR imaging findings. Radiographics. Department of Radiology and Radiological SciencesDepartment of Radiology and Radiological Sciences Diagnostic Aid in Appendicitis. Indian J Evaluation of Ultrasonography as a useful Mar; 43(3):351-2. [[PubMed](#)] [[Ref list](#)]Fertil Steril. 2009 Aug; 92(2):453-7. [[PubMed](#)] [[Ref list](#)] Fertil Steril. 2010 Jul; 94(2):742-6. [[PubMed](#)] [[Ref list](#)]

7- George MJ, Siba PP, Charan PK, Rao RRM.- 1995 12- Associated ovarian endometrioma is a marker for greater severity of deeply infiltrating endometriosis. Gynecol, , 6: 293-298.

8-Hudelist G, Ballard K, English J, Wright J, Banerjee S, Mastoroudes H, Thomas A, Singer CF, Keckstein J Hudelist G, English J, Thomas AE, Tinelli A, Singer CF, 1997 Dec; 12(12):2649-53. Journal of Clinical and Diagnostic Research. 2009 Oct ;(3):1731-1736

9-Kim SH, Kim SH, Yang DM, et al. 2002, Diagnosis of pelvic adhesions in patients with endometrioma: the role of transvaginal ultrasonography 2: 7715-

- 10-Okaro E, Condous G, Khalid A, Timmerman D, Ameye L, Huffel SV, Bourne TRochelle F. Andreotti M.D. FACR, FSRU, FAIUMRochelle F. Andreotti M.D. FACR, FSRU, FAIUM Suppl.Suppl. Surg.; 64: 436 – 9.
- 11-Tarjan Z., Mako E., Winternitz T., et al. (2002) The value of ultrasonic diagnosis in acuteUltrasound Obstet Gynecol. 2004 Aug; 24(2):180-5 Ultrasound Obstet Gynecol. 2011 Apr; 37(4):480-7.
- 12- Zafar N, Kupesic Plavsic S. (2012)Role of Ultrasound in the Evaluation of Acute Pelvic Pain in Nonpregnant Reproductive Age Patients. Donald School J Ultrasound Obstet Gynecol;6(2):207-217.
- .
- 13-. Jain KA. (2002) Sonographic spectrum of hemorrhagic ovarian cysts. J Ultrasound Med;21:879–886.
14. Borders RJ, Breiman RS, Yeh BM, Qayyum A, Coakley FV. (2007) Computed tomography of corpus luteal cysts. J Comput Assist Tomogr 2004;28:340–342. Peri N, Graham D, Levine D. Imaging of intrauterine contraceptive devices. J Ultrasound Med;26:1389–1401.
- 15-Rochelle F. Andreotti M.D. FACR, FSRU, FAIUM (1988) Department of Radiology and Radiological Sciences Vanderbilt University Medical Center [www.aium.org](http://www.aium.org). American Institute for Ultrasound in Medicine (AIUM) Bioeffects considerations for the safety of diagnostic ultrasound. J Ultrasound Med 16.
16. Salveson KA, Eik-Ness SH 1995 A review of epidemiological studies of human exposure to ultrasound. Ultrasound Obstet Gynecol, , 6: 293-298.

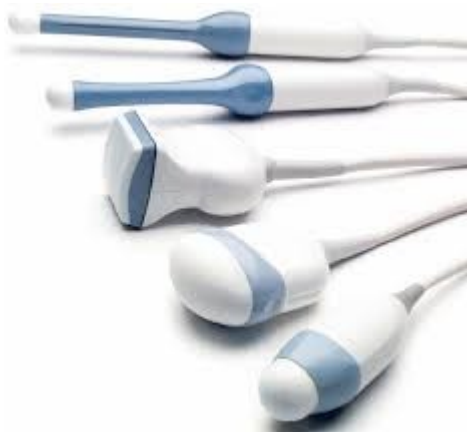- 17- European Federation of Societies for Ultrasound in Medicine and Biology (EFSUMB) 1995 Clinical Safety Statement 1994, Trondheim, European J of Ultrasound, 2: 77
- 18- Goldstein SR, (1996) Report for cleaning and preparation of endocavitary ultrasound transducers between patients. Ultrasound Obstet Gynecol; AIUM, 7: 92-94 .old version
19. American Institute for Ultrasound in Medicine (AIUM) 1988 Bioeffects considerations for the safety of diagnostic ultrasound. J Ultrasound Med 7 Suppl.
20. Salveson KA, Eik-Ness SH 1995 Is ultrasound unsound? A review of epidemiological studies of human exposure to ultrasound. Ultrasound Obstet Gynecol, , 6: 293-298.
21. European Federation of Societies for Ultrasound in Medicine and Biology (EFSUMB) 1995 Clinical Safety Statement 1994, Trondheim, European J of Ultrasound, 2: 77
22. Goldstein SR, 1996 Report for cleaning and preparation of endocavitary ultrasound transducers between patients. Ultrasound Obstet Gynecol; AIUM, , 7: 92-94 .old version

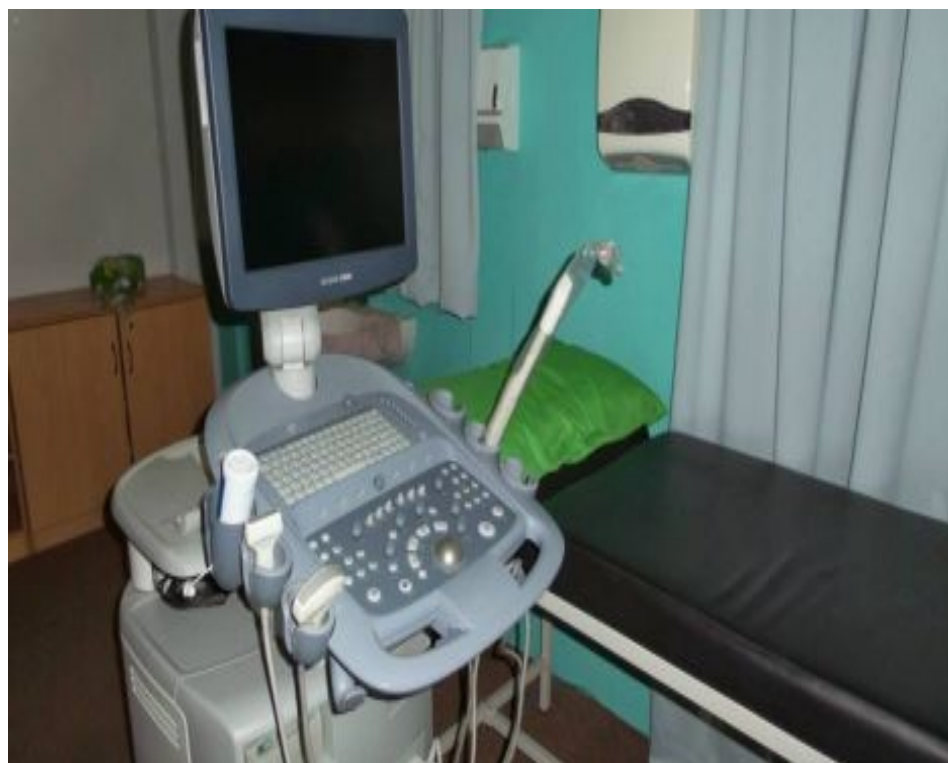

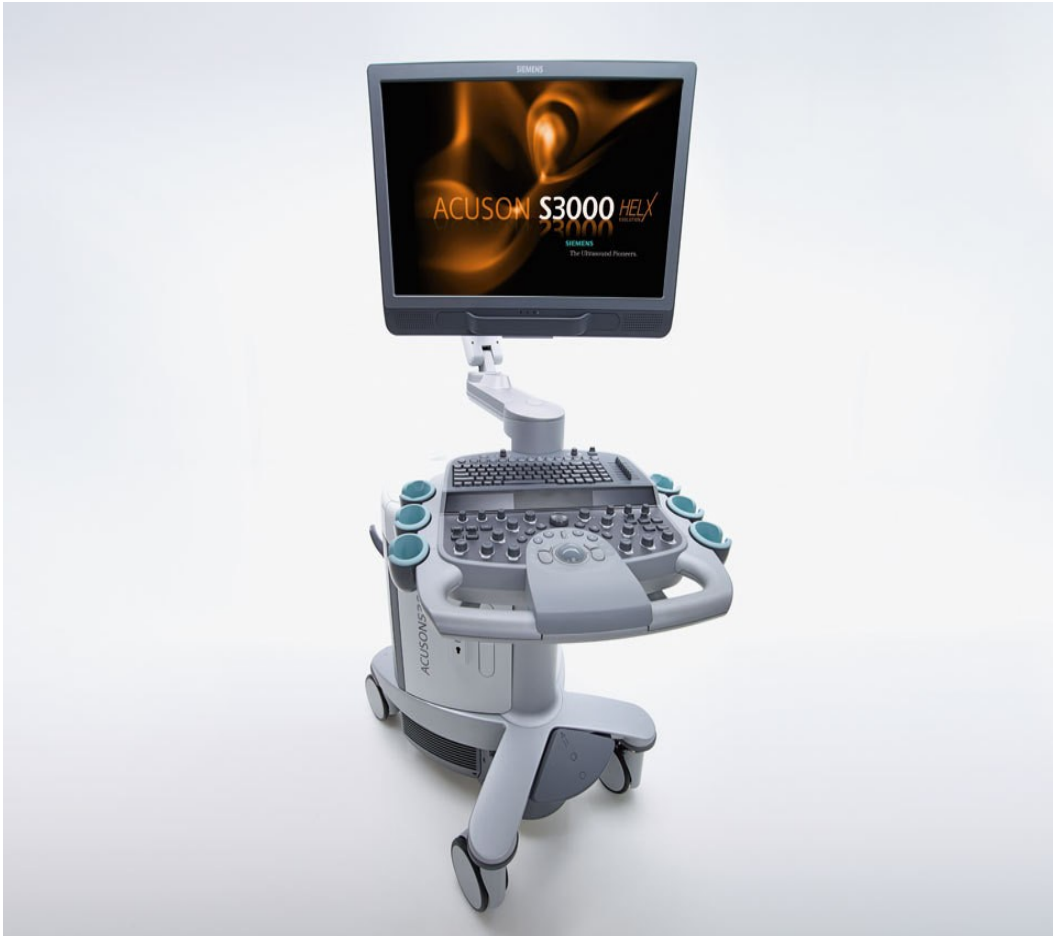# Appendix

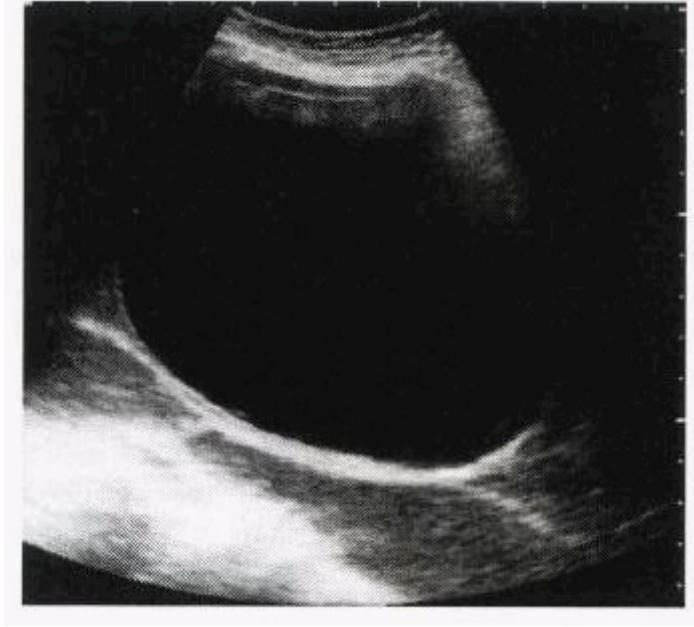No.	Age	Marital status	Finding
1	48	Married	appendicitis
2	33	Married	Appendicitis
3	23	Married	Appendicitis
4	47	Married	F.cyst
5	36	Married	Haemo.cyst
6	5	Single	Cystitis
7	30	Married	Lt .o.cyst
8	24	Married	P.o.cyst
9	28	Married	P.O.CYST
10	11	Single	Appendicitis
11	23	Married	HHAGE CYST
12	29	Single	Dermoid Cyst
13	35	Single	Multiple uterine fibroid
14	49	Married	Adenomyosis
15	22	Single	Free fluid PID
16	28	Married	Rupture appendicitis
17	46	Married	Uterine fibroid
18	17	Single	P.O.Cyst
19	38	Married	Cystitis FF =PID
20	25	Single	Appendicitis
21	32	Married	Subserous fibroid
22	22	Married	Subserous fibroid -lt haemorrhagic cyst

23	26	Married	Appendicitis
24	31	Married	Lt ovarian cyst
25	14	Single	Appendicitis
26	50	Married	Multiple uterine fibroid
28	44	Married	Rt.o.cyst
29	26	Single	Dermoid cyst
29	24	Single	Appendicitis
30	24	Married	Rupture O. cyst
31	36	Married	Dermoid cyst
32	20	Married	PID
33	38	Married	TORSION OF OVARIAN CYST
34	30	Married	Rupture ovarian cyst
35	32	Married	Hemorrhagic ovarian cyst
36	22	Married	Acute appendicitis
37	37	Married	Uretrolithiasis
38	22	Married	Acute cystitis
39	39	Married	Cholelithiasis
40	40	Married	Bowel hernia
41	36	Married	Rt VUJ stone
42	43	Married	O cyst with septations
43	22	Married	Uterine posterior wall fibroid
45	18	Single	Rt o cyst with internal echoes
46	21	Single	Appendicitis
47	26	Married	Appendicitis
48	38	Married	Fibroid with calcification
49	32	Married	Appendicitis
50	37	Married	Hemorrhagic cyst



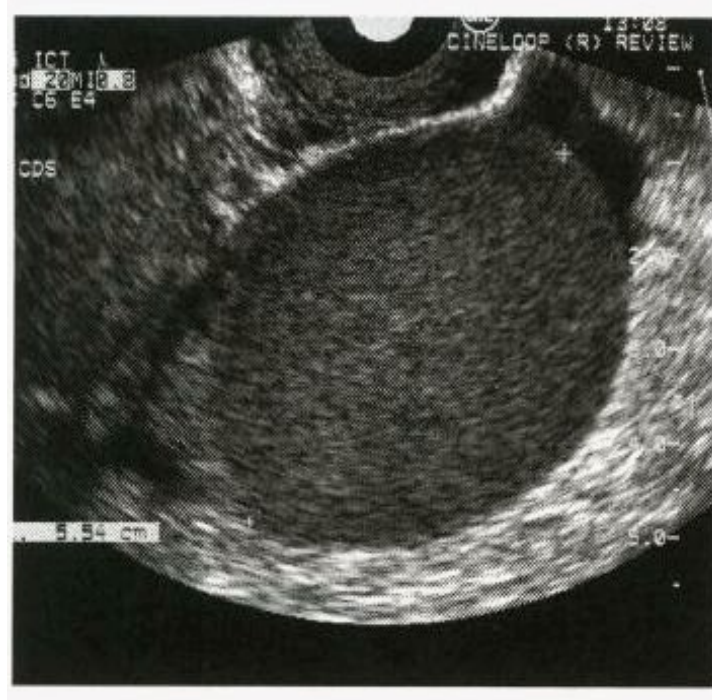



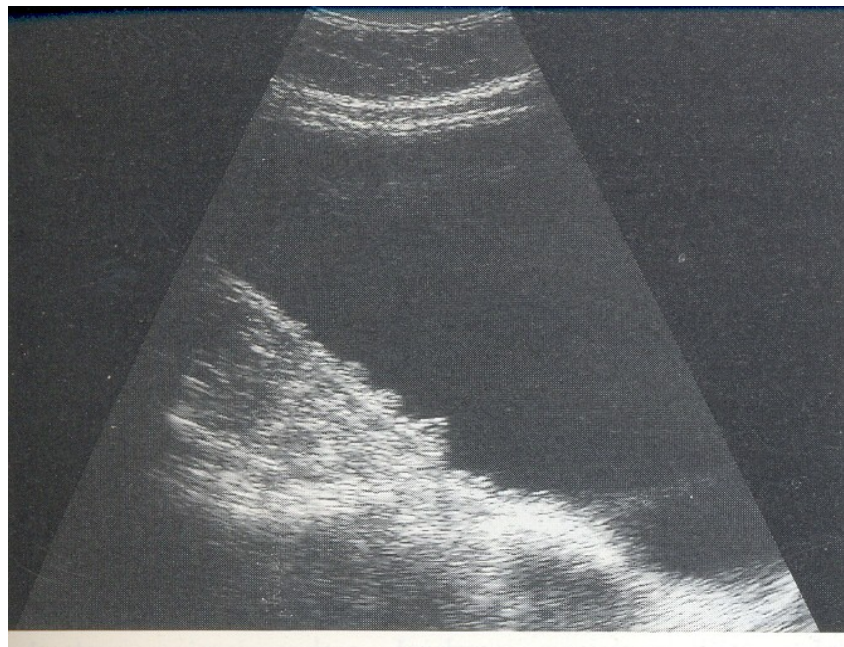


**35 years old female patients complain of pelvic pain, ultrasound image diagnosis big cyst**





25 years old female the diagnosis that is complex cyst



26 years old female patient complain of abdominal pain with heamaturia the  
Ultrasound diagnosis is cystitis











