

## **CHAPTER ONE**

### **1.1 Introduction:**

Hematouria is defined as the presence of red blood cells in the urine. It can be characterized as either "gross" (visible to the naked eye) or "microscopic" (visible only under the microscope). Microscopic hematouria is an incidental finding often discovered on urine tests as part of a routine medical evaluation.

Hematouria can originate from any site along the urinary tract, including the kidneys, ureters, bladder, prostate and urethra. It is estimated that hematouria occurs in 2.5 to 21 percent of the population. In many patients no specific cause is found; however, hematuria may be a marker for infection, stone disease or urinary tract cancer. Risk factors for significant underlying disease include: smoking, radiation, overuse of some pain medicines and exposure to certain chemicals. (Simon Steddon, 2014).

A urinalysis is a test that is used to detect the presence of harmful chemicals or substances in urine. A urinalysis is able to detect substances, such as blood, crystals, glucose, as well as pus cells. Sometimes, Presence of pus cells in urine is definite indication of some types of infection. Pus is a whitish or yellowish or slightly green substance which is thick like glue. Pus urine signifies that the body is fighting an infection in the lower or upper urinary tract. Pus contains dead skin cells, bacteria, and white blood cells. The medical term of the pus in urine condition is known as pyuria and is a common symptom of various medical conditions. the most common reason for pyuria is existence of urinary tract infection. Women are more prone to urinary tract infections. The urinary tract infections are caused by bacteria entering the urinary tract. The infection can occur at any part of the tract, and commonly infections at lower portion such as urethra and urinary bladder. (Louis 2005).

Ultrasound is one of the most used imagistic examinations in nephrology. In order to establish a precise diagnosis in acute or chronic kidney disease.

Renal ultrasonography has become the standard imaging modality in the investigation of kidneys because it offers excellent anatomic detail, requires no special preparation of patients .it is readily available and does not expose the patient to radiation or contrast agents.

Ultrasonography is used to determine the site and size of the kidney and to detect focal lesions, the presence of reno-parenchymatous disease, however most glomerular diseases cannot be further sub classified. Exceptions are primarily endovascular disorders like hypertensive nephrosclerosis, diabetic nephropathy or renal vasculitis which can be suspected if the intra renal resistance index value is increased (Radermacher, (2003).

In this study we use the ultrasound to study sonographic finding in the kidneys of patients with uncountable pus and RBCs in urine.

## **1.2Statement of the problem**

Renal failure is now days are a day talk because of its effects on families and patients, and many cases discovered every day. a lot of cases can avoid that by simple urine test and abdominal ultrasound, some of causes of renal failure can be manifested by puss cell and heamtouria and confirmed by bedside abdominal ultrasound, early discover and treatment of those causes save the kidney and patients life. This lead to reduce cost of treatment of end stage kidney disease by minimizes the number of patients on dialysis and transplantation..

## **1.3Objectives:**

### **1.3.1General objective:**

To study the kidneys in patient with uncountable pus and RBCs in urine using ultrasound.

### **1.3.2 Specific objective:**

To measure renal volume.

To diagnose possible causes of haematuria i.e. stone, masses, and infection.

Detection of associated obstructive changes.

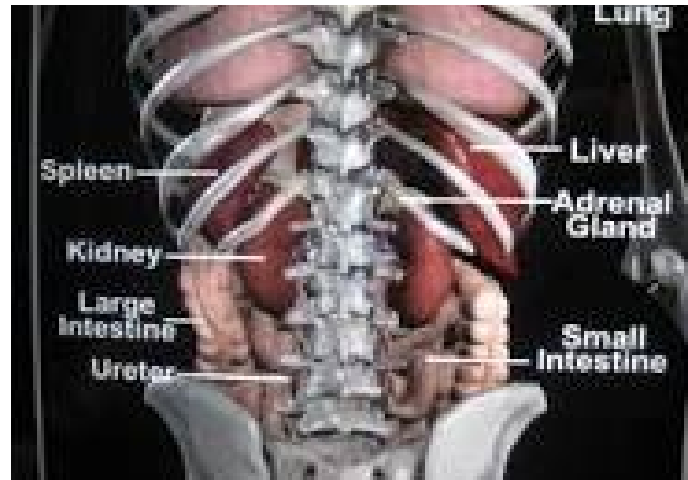
## **CHAPTER TWO**

### **Literature Review**

#### **2-1: Renal anatomy**

##### **2.1.1 Gross anatomy**

The two kidneys are located in the upper abdominal cavity on either side of the vertebral column, behind the peritoneum (retroperitoneal). (Fig.2-1) They extend from the level of 12<sup>th</sup> thoracic vertebra to the 3<sup>rd</sup> lumbar vertebra receiving some protection from the lower rib cage. The right kidney is usually slightly lower than left, probably because of the considerable space occupied by the liver (Ross and Willson, 2009). The left kidney is usually a little longer and narrower and near to the median plane. The long axis of each kidney is directed downward and laterally. The upper pole of the left kidney may overlie the eleventh rib in a radiograph, that of the right kidney seldom ascend so high, though it must be remembered that each kidney moves in vertical range of almost 1 inch during full respiratory excursion of the diaphragm. (R.J.Last, 1984).

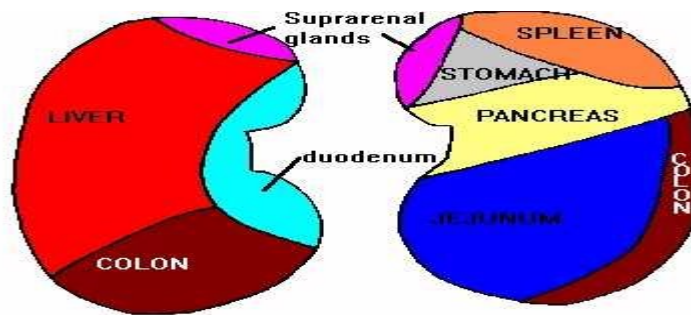


**Figure 2.1 position of the kidney**

[www.netterimages.com](http://www.netterimages.com)

### **2.1.2 Relation of the kidneys**

As the kidneys lie on either side of the vertebral column, each is associated with a different group of structure. Right kidney is related Superiorly to the right adrenal gland, anteriorly to the right lobe of the liver, duodenum and the hepatic flexure of the colon, and posteriorly to the diaphragm, and muscles of posterior abdominal wall. The left kidney is related Superiorly to the left adrenal gland, anteriorly to the spleen, stomach, pancreas, jejunum, and splenic flexure of the colon, and posteriorly to the diaphragm and muscles of the posterior abdominal wall ( Figure 2-2 ). ( Ross and Wilson, 2006).

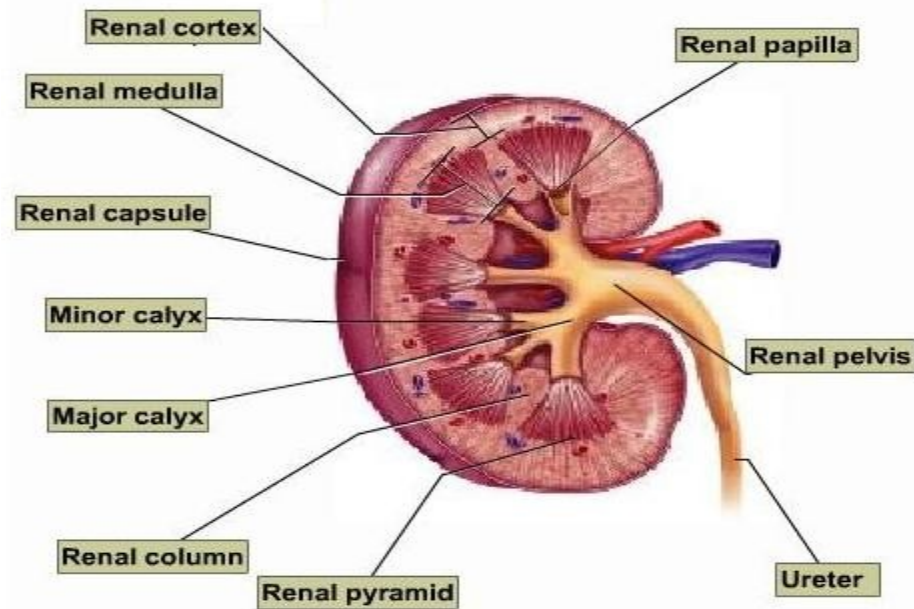


**Figure 2-2:** Relations of the kidneys  
[www.urologyhealth.com](http://www.urologyhealth.com)

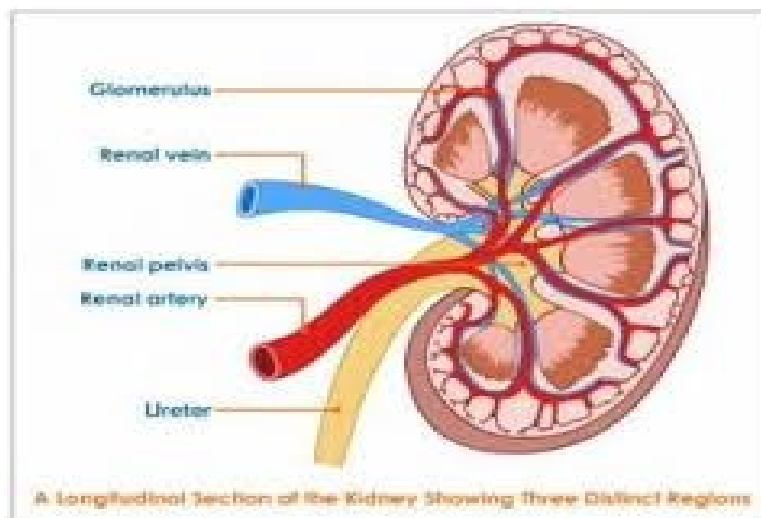
### 2.1.3 Gross Structure of kidneys

There are three areas of tissue that can be distinguished when a longitudinal section of the kidney is viewed with the naked eye.

- Fibrous capsule, surrounding the kidney.
  - The cortex, a reddish-brown layer of tissue immediately below the capsule and outside the pyramid.
- Medulla, the innermost layer, consisting of pale conical-shaped striation, the renal pyramids. (Ross and Wilson, 2006).
- The renal pelvis is a funnel shaped structure that acts as receptor for urine formed by the kidney; it has a number of distal branches called calyces, each of which surrounds the apex of a renal pyramids. Urine formed in the kidney passes through a papilla at the apex of a pyramid into a minor calyx, then into a major calyx, then cells in the walls of the calyces propels urine through the pelvis and ureter to the bladder. This is an intrinsic property of the smooth muscle, and is not under nerve the ureter. The walls of the pelvis contain smooth muscle and are lined with transitional epithelium. Peristalsis of the smooth muscle originating in pacemaker control. (Figure 2-3).
- The hilum is the concave medial border of the kidney where the renal blood and lymph-vessels, the ureter and nerves enter (figure 2-4). The hilum of the right lies just below, and of the left just above transpyloric plane about 2 inches from the midline. (Figure 2-4). (R.J.Last, 1984).



**Figure (2-3) gross structure of the kidney**  
[www.infovisual.info](http://www.infovisual.info)



**Figure (2-4) Hilum of the kidney** ( [www.pixgood.com](http://www.pixgood.com) )

#### **2.1.4 Microscopic structure of the kidney**

The kidney is composed of about 1 million functional units, the nephron, and a smaller number of collecting ducts. . It is in the nephron, with their associated blood vessels, that urine is formed.

The collecting ducts transport urine through the pyramids to the renal pelvis, giving them their striped appearance. The tubules are supported by a small amount of connective tissue, containing blood vessels, nerves, nerves and lymph vessels. Each nephron has two major portions: a renal corpuscle and a renal tubule. Each of these major parts has further subdivisions, which are shown with their blood vessels. (Ross and Wilson 2009).

Renal corpuscle consists of a glomerulus surrounded by a Bowman's capsule. The glomerulus is a capillary network that arises from an afferent arteriole and empties into an efferent arteriole. The diameter of the efferent arteriole is smaller than that of the afferent arteriole, which helps maintain a fairly high blood pressure in the glomerulus. (Figure 2-5). ([Valeriec.scanlon, 2007](#)).

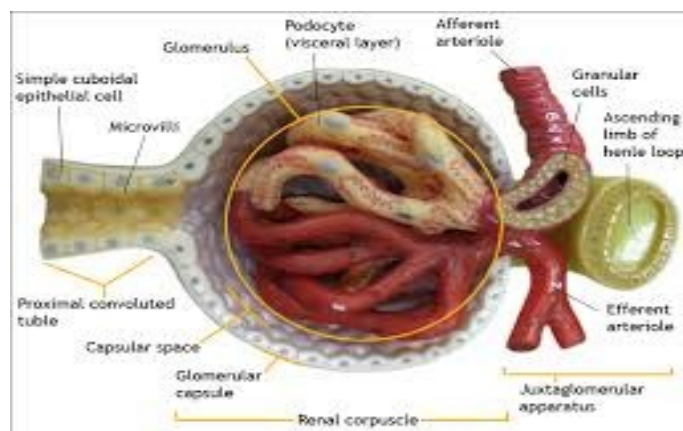


Figure (2.5) renal corpuscle

([www.vestudent-microbiologymaniac.com](http://www.vestudent-microbiologymaniac.com))

Bowman's capsule (glomerular capsule) is the expanded end of a renal tubule; it encloses the glomerulus. The inner layer of Bowman's capsule is made of podocytes; the name means "foot cells," and the "feet" of the podocytes are on the surface of the glomerular capillaries. The arrangement of podocytes creates pores, spaces between adjacent "feet," which make this layer very permeable. The outer layer of Bowman's capsule has no pores and is not permeable. The space between the inner and

outer layers of Bowman's capsule contains renal filtrate, the fluid that is formed from the blood in the glomerulus and will eventually become urine.

### **2.1.5 Tubular components of the nephron**

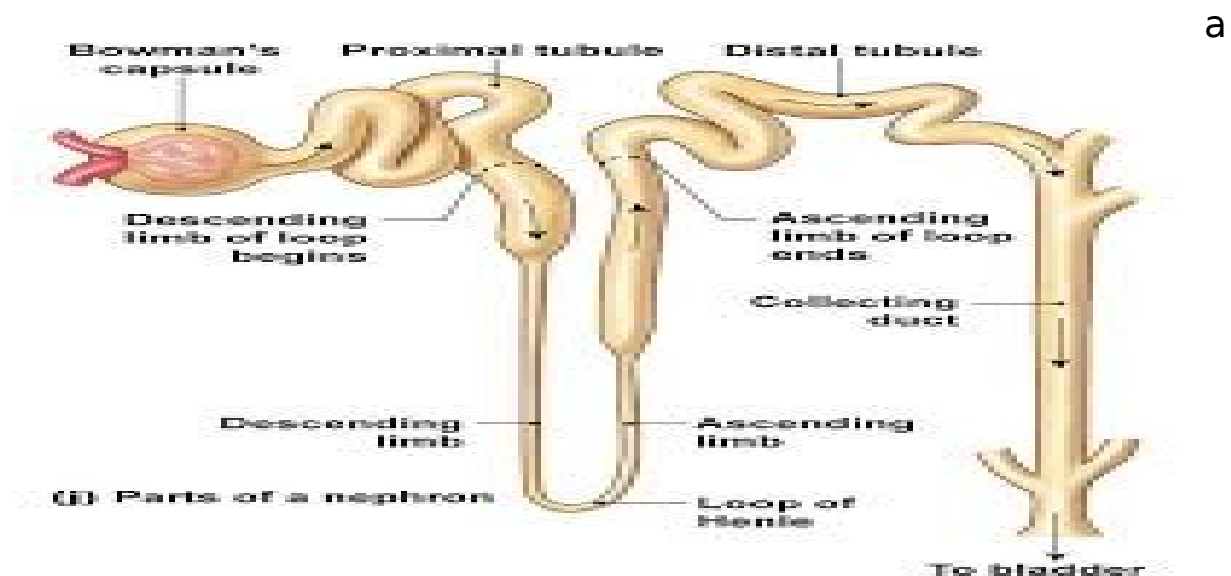
The nephron tubule is divided into four segments: a highly coiled segment called the proximal convoluted tubule, which drain the Bowman's capsule ; a thin, looped structure called the loop of Henle; a distal coiled portion called the distal convoluted tubules; and the final segment called the collecting tubules, which join several tubules to collect the urine filtrate. The filtrate passes through each of these

segments before reaching the pelvis of the kidney. Nephrons can be roughly

grouped into two categories. About 85% of the nephrons originate in the superficial part of the cortex and are called cortical nephrons; they have short, thick loops of Henle that penetrate only a short distance into the medulla. The remaining 15% are called juxtamedullary nephrons. They originate deeper in the cortex and have longer and thinner loops of Henle that penetrate the entire length of the medulla. The juxtamedullary nephrons are largely concerned with urine concentration. The proximal tubule is highly coiled structure that dips toward the renal pelvis to become the descending limb of the loop of Henle. The ascending loop of Henle return to the region of the renal corpuscle, where it becomes the distal tubule. The distal convoluted tubule which begins at the juxtamedullary complex is divided into two segments: the diluting segment and the late distal tubule. The late distal tubule fuse with the collecting tubule. Like the distal tubules, the collecting duct is divided into two segments: the cortical collecting tubule and the inner medullary collecting tubule. Throughout its course, the nephron is composed of a single layer of epithelial cells resting on a basement membrane . The structure of the epithelial cells varies with tubular function. The cells of the proximal tubule have a fine villous structure that



increase the surface area for reabsorption; they are also rich in mitochondria, which support active transport processes. The epithelial layer of the thin segment loop of Henle has few mitochondria, indicating minimal metabolic activity and active reabsorptive function. All parts of the renal tubule are surrounded by peritubular capillaries, which arise from the efferent arteriole. The peritubular capillaries will receive the materials reabsorbed by the renal tubules. (Figure 2-6). The proximal tubule is highly coiled structure that dips toward the renal pelvis to become the descending limb of the loop of Henle. The ascending loop of Henle return to the region of the renal corpuscle, where it becomes the distal tubule. The distal convoluted tubule which begins at the juxtamedullary complex is divided into two segments: the diluting segment and the late distal tubule. The late distal tubule fuse with the collecting tubule. Like the distal tubules, the collecting duct is divided into two segments: the cortical collecting tubule and the inner medullary collecting tubule. Throughout its course, the nephron is composed of a single layer of epithelial cells resting on



basement membrane .

Figure (2.6) demonstrate renal tubules ([www.studyblue.com](http://www.studyblue.com))

The structure of the epithelial cells varies with tubular function. The cells of the proximal tubule have a fine villous structure that increase the surface area for reabsorption; they are also rich in mitochondria, which support active transport processes. The epithelial layer of the thin segment loop of Henle has few mitochondria, indicating minimal metabolic activity and active reabsorptive function. All parts of the renal tubule are surrounded by peritubular capillaries, which arise from the efferent arteriole. The peritubular capillaries will receive the materials reabsorbed by the renal tubules. (Figure 2-6).

### **2.1.6 Vascular anatomy of the kidneys**

The renal arteries are branches of the abdominal aorta that are located just below the level of the superior mesenteric artery. Oxygenated blood travels through the renal arteries, which enter the renal hilum, and then into the segmental branches and subsequently into the interlobar arteries, which can be noted traveling between the renal pyramids (Fig. 7-1). The interlobar arteries branch into the much smaller arcuate arteries at the base of the pyramids. The arcuate arteries then branch into the interlobular arteries, and into the afferent arterioles, which carry blood into the glomerulus for filtration. The renal veins exit the kidneys at their respective renal hilums and connect to the lateral aspects of the inferior vena cava. The left renal vein has to travel across the abdomen, between the superior mesenteric artery and abdominal aorta, and is therefore longer than the right renal vein. The right renal artery travels posterior to the inferior vena cava. It is longer than the left renal artery. (Figure 2-7). (Steven M. Penny, 2011).

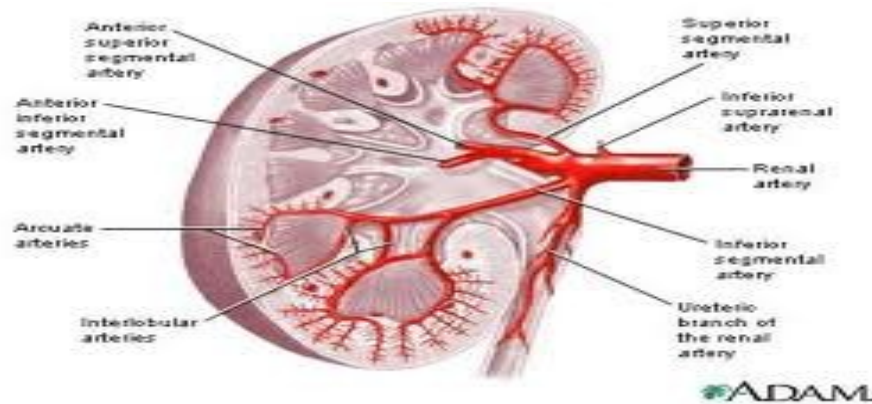


Figure (2-7 )vasculature of the kidney ( [www.Heath.allrefer.com](http://www.Heath.allrefer.com))

## 2-2 physiology of the kidney

### 2-2-1 Multiple functions of the kidney

- Excretion of metabolic waste products and foreign chemicals
- Regulation of water and electrolyte balances
- Regulation of body fluid osmolality and electrolyte concentrations
- Regulation of arterial pressure
- Regulation of acid-base balance
- Secretion, metabolism, and excretion of hormones
- Gluconeogenesis

- Excretion of Metabolic Waste Products, Foreign Chemicals, Drugs, and Hormone Metabolites. The kidneys are the primary means for eliminating waste products of metabolism that are no longer needed by the body. These products include *urea* (from the metabolism of amino acids), *creatinine* (from muscle creatinine), *uric acid* (from nucleic acids), *end products of hemoglobin breakdown* (such as bilirubin), and *metabolites of various hormones*. These waste products must be eliminated from the body as rapidly as they are produced. The kidneys also eliminate most toxins and other foreign substances that are either produced by the body or ingested, such as pesticides, drugs, and food additives.

-Regulation of Water and Electrolyte Balances. For maintenance of homeostasis, excretion of water and electrolytes must precisely match intake. If intake exceeds excretion, the amount of that

substance in the body will increase. If intake is less than excretion, the amount of that substance in the body will decrease. Intake of water and many electrolytes is governed mainly by a person's eating and drinking habits, requiring the kidneys to adjust their excretion rates to match the intake of various substances. Figure 26-1 shows the response of the kidneys to a sudden 10-fold increase in sodium intake from a low level of 30 mEq/day to a high level of 300 mEq/day. Within 2 to 3 days after raising the sodium intake, renal excretion also increases to about 300 mEq/day, so that a balance between intake and output is re-established. However, during the 2 to 3 days of renal adaptation to the high sodium intake, there is a modest accumulation of sodium that raises extracellular fluid volume slightly and triggers hormonal changes and other compensatory responses that signal the kidneys to increase their sodium excretion. The capacity of the kidneys to alter sodium excretion in response to changes in sodium intake is enormous. Experimental studies have shown that in many people, sodium intake can be increased to 1500 mEq/day (more than 10 times normal) or decreased to 10 mEq/day (less than one tenth normal) with relatively small changes in extracellular fluid volume or plasma sodium concentration. This is also true for water and for most other electrolytes, such as chloride, potassium, calcium, hydrogen, magnesium, and phosphate ions. In the next few chapters, we discuss the specific mechanisms that permit the kidneys to perform these amazing feats of homeostasis.

-Regulation of Arterial Pressure. The kidneys play a dominant role in long-term regulation of arterial pressure by excreting variable amounts of sodium and water. The kidneys also contribute to short-term arterial pressure regulation by secreting vasoactive factors or substances, such as *renin*, that lead to the formation of vasoactive products.

-Regulation of Acid-Base Balance. The kidneys contribute to acid-base regulation, along with the lungs and body fluid buffers, by excreting acids and by regulating the body fluid buffer stores. The kidneys are the only means of eliminating from the body certain types of acids, such as sulfuric acid and phosphoric acid, generated by the metabolism of proteins.

-Regulation of Erythrocyte Production. The kidneys secrete *erythropoietin*, which stimulates the production of red blood cells. One important stimulus for erythropoietin secretion by the kidneys is *hypoxia*. The kidneys normally account for almost all the erythropoietin secreted into the circulation. In people with severe kidney disease or who have had their kidneys removed and have been placed on hemodialysis, severe anemia develops as a result of decreased erythropoietin production.

-Regulation of 1,25-Dihydroxyvitamin D<sub>3</sub> Production. The kidneys produce the active form of vitamin D, 1,25- dihydroxyvitamin D<sub>3</sub> (*calcitriol*), by hydroxylating this vitamin at the “number 1” position. Calcitriol is essential for normal calcium deposition in bone and calcium reabsorption by the gastrointestinal tract. Calcitriol plays an important role in calcium and phosphate regulation.

-Glucose Synthesis. The kidneys synthesize glucose from amino acids and other precursors during prolonged fasting, a process referred to as *gluconeogenesis*. The kidneys’ capacity to add glucose to the blood during prolonged periods of fasting rivals that of the liver. With chronic kidney disease or acute failure of the kidneys, these homeostatic functions are disrupted, and severe abnormalities of body fluid volumes and composition rapidly occur. With complete renal failure, enough potassium, acids, fluid, and other substances accumulate in the body to cause death within a few days, unless clinical interventions such as hemodialysis are initiated to restore, at least partially, the body fluid and electrolyte balance. ([Arthur. C. Guyton, 2006](#)).

## **2-2-2Main function of the kidneys**

## Formation of the urine

The kidneys form urine which passes through the ureters to the bladder for storage prior to excretion. The composition of the urine reflects exchange of substances between the nephron and the blood in the renal capillaries. Waste products of protein metabolism are excreted, electrolyte levels are controlled and pH (acid-base balance) is maintained by excretion of hydrogen ions.

There are three mechanisms involved in the formation of urine:

- Glomerular Filtration
- Selective reabsorption
- Secretion

- Glomerular filtration

This takes place through the semi permeable walls of the glomerulus and glomerular capsule. Water and other small molecules pass through, although some are reabsorbed later. Blood cells, plasma proteins and other large molecules are too large to filter through and therefore remain in the capillaries. The filtrate in the glomerulus is very similar in composition to plasma with the important exception of plasma proteins. (Ross and Wilson, 2009).

The movement of fluid through the glomerular capillaries is determined by the same factors (i.e., capillary pressure, colloidal osmotic pressure, and capillary permeability) that affect fluid movement through other capillaries in the body.

About 125 ml of filtrate is formed each minute, this is called glomerular filtration rate (GFR). This rate can vary from a few milliliters per minute to as high as 200 ml/minute.

The location of the glomerulus between two arterioles allows for maintenance of a high-pressure filtration system. The capillary filtration pressure (about 60 mmHg) in the glomerulus is about two to three times higher than that of other capillary beds in the body. The filtration pressure and GFR are regulated by the

constriction and relaxation of the afferent and efferent arterioles. Constriction of the efferent arteriole increase resistance to outflow from the glomeruli and increase the glomerular pressure and GFR. Constriction of the afferent arteriole cause a reduction in the renal blood flow, glomerular filtration pressure, and GFR.

The afferent and the efferent arterioles are innervated by the sympathetic nervous

System . During period of strong sympathetic stimulation such as occurs during

Shock , renal blood flow and the glomerular filtration pressure can be markedly

Decrease and urine out put can fall almost to zero.

- Tubular reabsorbtion and secretion

From Bowman's capsule, the glomerular filtrate moves into the tubular segment of the nephron. In it is movement though the lumen of tubular segments, the glomerular filtrate is changed considerably by the tubular transport of water and solutes. Tubular transport can result in reabsorbtion of substances from the tubular fluid into the blood or secretion of substances into the tubular fluid from the blood. The basic mechanisms of transport across the tubular epithelial cell membrane are similar to those of cell membrane in the body and include active and passive transport mechanism. Water and urea are passively absorbed along concentration gradient .Sodium, potassium, chloride, calcium, and phosphate ions , urate , glucose, and amino acids are reabsorbed using primary or secondary active mechanisms to move across the tubular membrane . Some substances such as hydrogen, potassium, and urate ions are secreted into tubular fluids. Under normal conditions, only about 1 ml of the 125ml of glomerular filtrate that is formed each minute is excreted in the urine. The other 124 ml reabsorbed in the tubules. This means that the average output of urine is about 60ml/hour. Renal tubular cells have two membrane surfaces through which substances must pass as they are reabsorbed from the tubular fluid. The side of the cells that is contact with the tubular lumen and tubular

filtrate is called luminal membrane. the out side membrane that lies adjacent to the interstitial fluid is called the basolateral membrane . in most cases, substances move from the tubular filtrate into the tubular cell along a concentration gradient, but they require facilitated transporter carrier system to move across the basolateral membrane into the interstitial fluid , where they are absorbed into the peritubular capillaries .

With most substances such as glucose and amino acids, transport is linked to sodium reabsorption. This is called a secondary active transport , the energy dependent sodium-potassium ATP- ase pump on the basolateral side of renal tubular cells maintain a low intercellular sodium concentration that facilitates the downhill(i.e., from a higher to lower concentration ) movement of sodium across the luminal membrane. Contratransport uses a carrier system in which the downhill movement of ions substances such as sodium is coupled to uphill movement (i.e., from a lower to higher concentration) of another substance such as glucose or an amino acid. A few substances such as hydrogen are secreted into the tubule using countertransport in which the movement of one substance, such as sodium, enables the movement of a second substance in the opposite direction. Sodium ions are the single most abundant cation in the filtrate. The bulk of energy used by the kidney is for active sodium transport mechanisms that facilitate sodium reabsorption such as glucose and amino acids.

Proximal tubule. About 65% of all reabsorptive and secretory processes that occur in the tubular system take place in the proximal tubule. There is almost complete reabsorption of nutritionally important substance, such as glucose, amino acids, and water soluble vitamins. Electrolytes such as sodium, potassium, chloride, and bicarbonate, are 65% reabsorbed. As these solutes move into the tubular cells, their concentration within tubular lumen decreased, providing a concentration gradient for the osmotic reabsorption of water and urea. The proximal tubule is highly permeable to water , and the osmotic movement of water occurs so rapidly that the concentration



difference of solutes on either side of membrane seldom is more than a few milliosmoles . Many substances such as glucose, are freely filtered in the glomerulus and reabsorbed by energy-dependent contratransport carrier mechanism. The maximum amount of substances that theses transport systems can absorb per unit time is called the transport maximum. The transport maximum is related to the number of carrier proteins that are available for transport and is usually sufficient to ensure that all of filtered substances such as glucose are reabsorbed rather than being eliminated in the urine. The plasma level at which the substance appears in the urine is called the renal threshold. Under some circumstances, the amount of substance filtered in the glomerulus excess the transport maximum , for example when the blood glucose level is elevated in uncontrolled diabetes mellitus, the amount that is filtered in the glomerular often excess the transport maximum ( about 32mg/minute), and glucose spills into the urine.

The loop of Henle .The loop of Henle is divided into three segments: the thin descending segment, the thin ascending segment and, thick ascending segment. Each of these segments has specific structural and functional properties. Fluid that enters the loop of Henle is iso osmotic to plasma, but it becomes hypo-osmotic as it moves through the loop. The thin descending limb is highly permeable to water and moderately permeable to urea, sodium, and other ions. The ascending limb, in contrast to the descending limb, is impermeable to water. As fluid moves down the descending limb, water is reabsorbed until the osmolarity of the tubular fluid reaches equilibrium with the interstitial fluid, which is more hypertonic. In the ascending limb , which is impermeable to water, solutes are reabsorbed, but water cannot follow; as result, the tubular fluid is becomes more and more dilute, often reaching an osmolarity of 100 mOsm/kg of H<sub>2</sub>O as it enters the distal convoluted tubule, compared with the 285 mOsm/kg of H<sub>2</sub>O in plasma. The thick segment of the loop of

Henle begins in the ascending limb where the epithelial cells become thickened. As with the thin ascending limb, this segment is impermeable to water. The thick segment contains a  $\text{Na}^+ - \text{K}^+ - 2\text{Cl}^-$  cotransport system. This system involves the cotransporter of positively charged sodium and positively charged potassium ion accompanied by two negatively charged chloride ions. It is here that the loop diuretics exert their function. The gradient for the operation of this cotransporter system is provided by the basolateral sodium-potassium pump, which maintains a lower intracellular sodium concentration. The repetitive reabsorption of sodium chloride from the thick ascending limb of Henle and continued inflow of new sodium chloride from proximal tubule into the loop of Henle serve to trap solutes in the medullary interstitial, contributing to the high osmolarity in this part of the nephron. About 20 % of 25% of the filtered load of sodium. Potassium and chloride are reabsorbed in the thick loop of Henle. Movement of these ions out of the tubules leads to the development of a transmembrane potential that favors the passive reabsorption of small divalent cations such as calcium and magnesium. Inhibition of sodium transport in the thick loop of Henle by loop diuretics causes an increase in urinary excretion of these divalent ions in addition to sodium and chloride. In about one fifth of the juxtamedullary nephrons, the loop of Henle and special hairpin-shaped capillary called vasa recta descend into the medullary portion of the kidney. A countercurrent mechanism controls water and solutes movement so that water is kept out of the peritubular area and sodium and urea are retained. The term countercurrent refers to a flow of fluid in opposite directions in adjacent structure. There is an exchange of solutes between the adjacent descending and ascending loops of Henle and between the ascending and descending sections of the vasa recta. Because of these exchange processes, a high concentration of the osmolarity active particles ( about 1200 mOsm/kg of  $\text{H}_2\text{O}$  ). Collect in the interstitial of this portion of the kidney. It is here, where the

kidney interstitium surrounds the collecting tubules, that the presence of these osmolarity active particles facilitates the antidiuretic hormone (ADH) - mediated reabsorption of water.

**Distal convoluted tubule.** Like the thick ascending loop of Henle, the distal convoluted tubule is relatively impermeable to water, and reabsorption of sodium chloride from this segment further dilutes the tubular fluid. Sodium reabsorption occurs through a sodium and chloride transport mechanism. About 1% of filtered sodium chloride is reabsorbed in this section of the tubule. Unlike the thick ascending loop of Henle, neither calcium nor magnesium is passively absorbed in this segment of the tubule. Instead, calcium ions are actively reabsorbed in a process that is largely regulated by parathyroid hormone and possibly vitamin D.

The thick ascending loop of Henle, the distal tubule, and collecting duct are often referred to as the diluting segment of the tubule. As solutes are reabsorbed from these segments, the urine becomes more and more dilute, often reaching the osmolar concentration that is equal or less than that of plasma. This allows excretion of free water from the body.

**Late Distal tubule and cortical collecting tubule.** The late distal tubule and the cortical collecting tubule constitute the site where aldosterone exerts its action on sodium and potassium reabsorption. Although responsible for only 2% to 5% of sodium chloride reabsorption, this site is largely responsible for determining the final sodium concentration of the urine, the late distal tubule with the cortical collecting tubule is also the major site for regulation of potassium excretion by the kidney. When the body is confronted with a potassium excess, as occurs with a diet high in potassium content, the amount of potassium secreted at this site may exceed the amount filtered in the glomerulus.

The mechanism for sodium reabsorption and potassium secretion by this section of the kidney is distinct from other tubular segments. This tubular segment is composed of two types of cells, the principal cells and the intercalated cells. The principal cells reabsorb sodium and water from the lumen filtrate and secrete potassium to

the lumen. The intercalated cells reabsorb potassium and secrete hydrogen ions into the lumen. The principle cells use separate channels for transport of sodium and potassium rather than co transport mechanisms. Aldosterone is thought to exert its effect on sodium and potassium excretion by increasing the number of ion channels and the function of the basolateral sodium-potassium pump.

**Medullary collecting duct.** The epithelium of the medullary collecting ducts is well designed to resist extreme changes in the osmotic or pH characteristics of tubular fluid, and in it is here that the urine becomes highly concentrated, highly diluted, highly alkaline, or highly acidic. During periods of water excess or dehydration, the kidneys play a major role in maintaining water balance. ADH exerts its effect in the medullary collecting duct. ADH maintains extracellular volume by returning water to the vascular compartment and leads to the production of concentrated urine by removing water from tubular filtrate. Osmoreceptors in the hypothalamus sense the increase in osmolarity of extracellular fluids and stimulate the release of ADH from the posterior pituitary gland. The permeability of the collecting ducts to water is determined mainly by the concentration of ADH. In exerting its effect, ADH also known as vasopressin, binds to the vasopressin receptors on the blood side of the tubular cells. Binding of ADH to the vasopressin receptors causes insertion of water channels into the cell membrane on the luminal side of the tubular cells, producing a marked increase in water permeability. After the permeability of the collecting tubules has been established, water moves out of the tubular lumen and into the interstitium of the medullary area, where it enters the peritubular capillaries for return to the vascular system. When the effect of the ADH is over, the inserted water channels are removed, the tubular cells lose their water permeability, and the dilute urine is formed. (Bernadette Madara, 2008).

## **2-3 Sonography of the kidneys**

### **2-3-1 renal shape and -position**

The kidneys are located in the retroperitoneum on the iliopsoas muscles. Their longitudinal axes point laterally downward at a divergent angle. They are tilted laterally, and their lower poles are directed forward. (G.schmidt, 2011).

The sonographic appearance of the kidneys differs with age. And multiple variants may be noted with sonography. Neonatal and pediatric kidneys may appear lobulated, have prominent renal pyramids, and/or have subtle sonographic distinctions between the renal cortex and renal sinus. Normal adult kidneys are elliptical in shape in the longitudinal plane and rounded in the transverse plane. (Figure 2-8). ). (Steven M. Penny, 2011).

The normal orientation of the kidneys is such that the upper pole is medial and anterior to the lower pole. The right kidney is 1 to 2 cm inferior in position as compared with the left kidney because of the location of the liver superior to the right kidney.

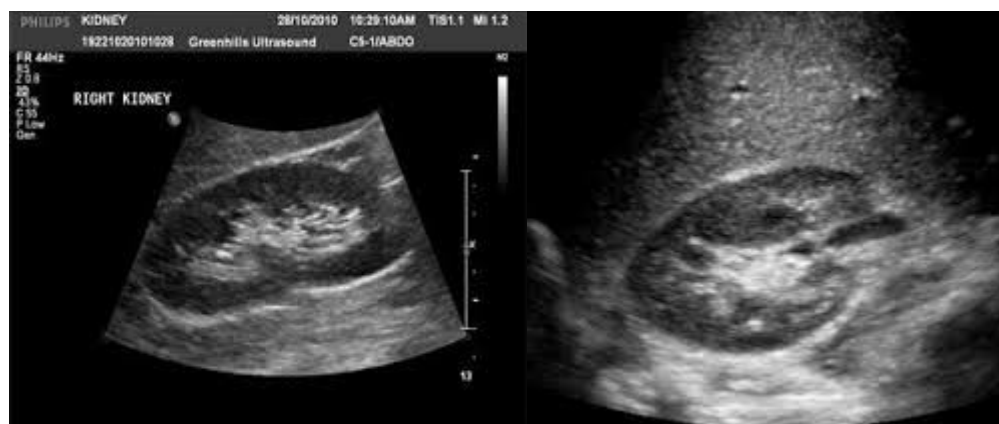

Figure (2-8) longitudinal and transverse views of the normal kidney

( [www.ultrasoundpaedia.com](http://www.ultrasoundpaedia.com))

The liver and hepatic flexure of the colon are situated anterior to the right kidney (figure 2-9) . The spleen lies anterosuperior to the left kidney (figure 2-9) and the rest of the left kidney is related anteriorly with the colon.

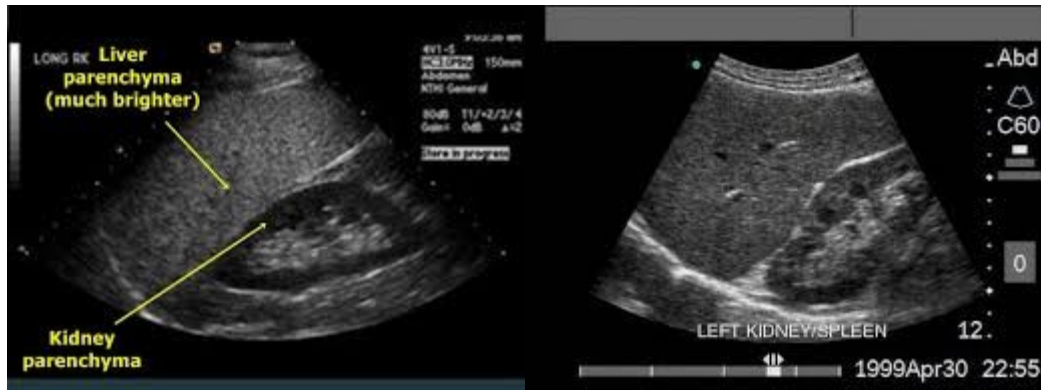


Figure (2-9) , relation of liver to right kidney , and spleen to left kidney

([www.frac.co.uk.com](http://www.frac.co.uk.com))

### 2-3-2 renal surface and capsule

The kidneys are enclosed by an adipose capsule the thickness of which varies with patient's body habitus and age. The capsule is an echogenic white boundary separating the kidney from adjacent structures anteriorly and the musculature posterior. In advanced tissue damage ,such as occurs in cirrhosis , the fat capsule may be confused with the renal tissue itself; however it remain immobile during breathing, That , the missing mobility surrounding during in- and expiration usually allows clear differentiation of fatty tissue and renal parenchyma. Kidneys usually have a smooth surface. As the kidney develops in the fetus from a number of lobes, which fuse. Occasionally the traces of these lobes can be seen on the surface of the kidney, forming *fetal lobulations*); these may persist into adulthood as normal variant. ( figure 2-10).

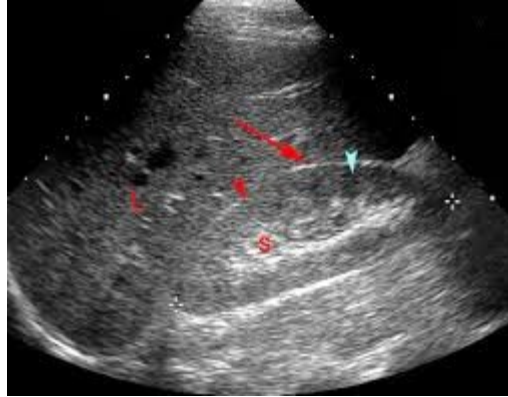


Figure (2-10), sonographic appearance of renal capsule  
[www.ultrasound-images.com](http://www.ultrasound-images.com)

### **2-3-3 renal parenchyma**

An inexperienced investigator should assess the renal parenchyma only in comparison to the adjacent liver and spleen. The normal renal cortical echogenicity in children age 6 and older and in adults should be slightly less echogenic than that of liver and spleen. Normal renal. Cortical echogenicity from birth until 6 months of age is slightly brighter than that of the liver. Increased echogenicity compared to liver and spleen in adults is a sensitive but unspecific sign of renal disease. The normal parenchymal width of 15-25 mm can be measured most reliably from the basis of a medullary pyramid to the kidneys surface. The medullary pyramids are seen as regularly spaced, echo-poor triangular structures between the cortex and the renal sinus. ( figure 2-11). The tiny reflective structures often seen at the margins of the pyramids are echoes from the arcuate arteries which branch around the pyramids. (Barton Dudlick, 2006). Columns of Bertin (column of renals) are extensions of the renal parenchyma in the renal pelvis and hypertrophied columns of Bertini should not be confused with pelvic tumors.

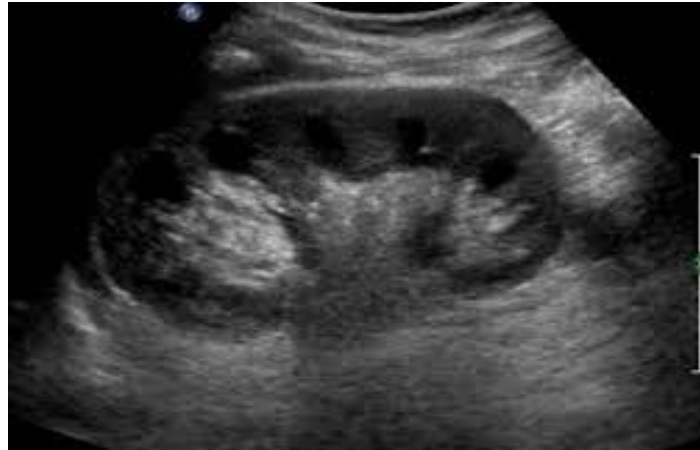

Figure (2-11) , Normal sonographic appearance of renal parenchyma

([www.ultrasoundpaedia.com](http://www.ultrasoundpaedia.com))

### 2-3-4 renal sinus

The central echogenic part of the kidney (sinus) is composed of the pelvis and the calyces, blood and lymphoid vessels and interposed adipose tissue. (Figure 2-11). The normal renal pelvis should not be fluid filled except in pregnant women. Anechoic areas are frequently due to dilated veins as can be easily proven by Color Doppler ultrasound. The ureter is located dorsally to the renal vessels and also should not be visible normally. (Figure ).  
( Giyani S.A (2003).

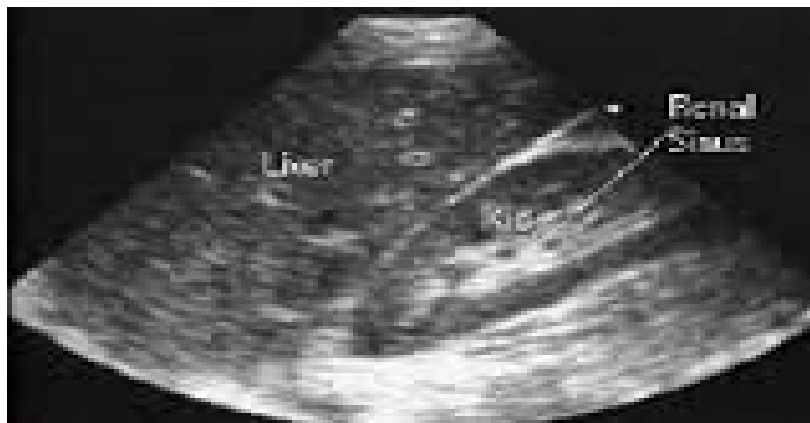

Figure (2-12), sonographic appearance of renal sinus

([www.emedicine.medscape.com](http://www.emedicine.medscape.com))

### 2-3-5 Renal vessels



The renal artery usually branches within the renal sinus or extrarenally in 2 to 3 segmental arteries of first order and these 1st order segmental arteries branch another 2 to 3 times into segmental arteries of 2nd and 3rd order. When entering the renal parenchyma the vessels are called interlobar arteries.( Figure 2-13).

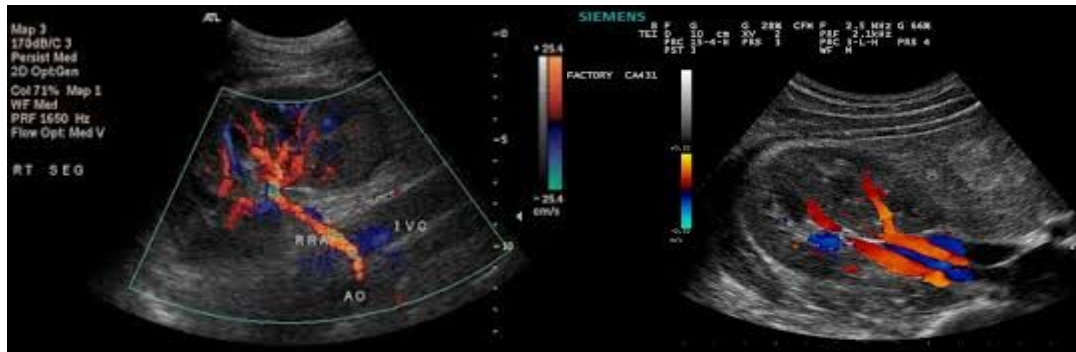


Figure (2-13) Doppler renal vasculature  
([www.Healthcare.sismens.de.com](http://www.Healthcare.sismens.de.com))

### 2-3-6 Normal Renal Measurements:

The size of the kidneys is affected by age, sex (greater in men than in women), and body size; furthermore, the left kidney is slightly larger than the right in most individuals.

The normal adult kidney measures 9 to 12 cm in length, 4 to 5 cm in width, and 2.5 to 3 cm in thickness. A renal length outside the normal range may be an indication of pathological process and measurements should therefore form part of the protocol of renal scanning. A discrepancy of more than 2 cm between the lengths of two kidneys is considered significant and needs further evaluation. ( Jane Bates , 2004).

The measurement of renal volume is a more effective way of assessing the renal size, though measurement of renal length is more practical in regular practice. A better correlation can be found between renal volume and body weight or body surface area.

Renal volume is frequently estimated as length x depth x width (cm) / 2.

The average volume of the right kidney is  $(99.8 \pm 37.2)$  , and for the left kidney is  $(124.4 \pm 41.3)$  , according to the( J.Ayub et al,2011).

The cortical thickness of the kidney is generally taken as the distance between the capsule and the margin of the medullary pyramid. This varies between individuals and within individual kidneys and tends to decrease with age. (Jane Bates , 2004).

Cortical thickness is 11-18 mm in the male and 11-16 mm in the female (Giyani S.A (2003).

### **2-3-7 Age Related Changes In The Adult**

1. “The thickness of the renal parenchyma decreases at about 10% per decade after age 20 years.

2. There is a loss of contrast between the cortex and pyramids as “the normal

Aging process increases cortical and pyramidal echogenicity, but the effect is

More obvious in the pyramids, which gradually fade from view as their

Echogenicity increases.

3. The overall size decreases gradually but is only apparent in the elderly. (Giyani S.A (2003).

## **2.4 Pathology of the kidney:**

### **2-4-1 Renal Infection**

## **2-4-1-1 bacterial infection**

### **Acute Pyelonephritis**

Acute pyelonephritis is a tubointerstitial inflammation of the kidney. Two routes may lead to inflammation: ascending infection (85%; e.g, *Escherichia coli*) (infection begins in the bladder and refluxes up through the ureters and into the kidney) (update). and hematogenous seeding (15% *staphylococcus aureus*) , women age 15-35 years are most often affected.;2% of pregnant women will develop pyelonephritis. Most adult clinically present with flank pain and fever, dysuria, urinary frequency, and can be diagnosed clinically with aid of laboratory studies ( bacteriuria,pyuria, and leukocytosis). (Rumak, 2005).

At ultrasound the majority of kidneys with pyelonephritis appear normal. However, ultrasound findings of pyelonephritis include the following:

If the pyelonephritis is focal, the poorly margined masses may be echogenic, hypoechoic, or mixed echogenicity. Echogenic masses may be the most common appearance of focal

Pyelonephritis.

Sonography, including power Doppler, is less sensitive than CT, magnetic resonance imaging, or technetium-99m single photon emission computer tomography(99mTc- DMSA SPECT) renal cortical scintigraphy to demonstrate changes of acute pyelonephritis . However, ultrasound is more accessible and less expensive and thus an excellent screening modality for monitoring and follow-up of complication. As well as in the assessment of pregnant patients with acute pyelonephritis because of its lack of ionizing radiation.

Complications of acute pyelonephritis include the development of a renal abscess, pyonephrosis, xanthogranulomatous pyelonephritis, emphysematous pyelonephritis, and chronic pyelonephritis. (Barton Dudlick, 2006).

- Clinical findings of acute pyelonephritis
  - Flank pain

- Fever
- Bacteriuria
- Pyuria
- Leukocytosis
- Dysuria
- Urinary frequency
  - Sonographic findings of acute pyelonephritis
- May appear normal
- Renal enlargement
- Decreased echogenicity (secondary to edema) or increased echogenicity (potentially from hemorrhage)
- Focal areas of altered echotexture
- Focal or diffuse absence of color Doppler perfusion corresponding to the swollen inflamed area.
- Compression of the renal sinus (Steven M. Penny, 2011).

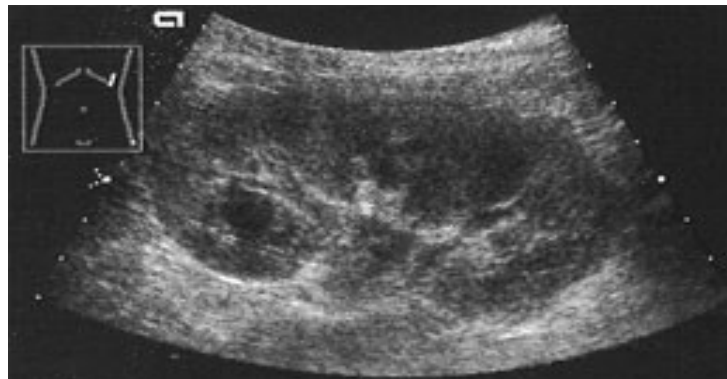

Figure (2-14) Acute pyelonephritis: Large, hypoechoic kidney with an obliterated sinus echo and a rim of fluid in the renal pelvis. (Schmidt, 2011).

### **Pyonephrosis**

Pyonephrosis describes the condition of having pus, also referred to as purulent material, within the collecting system of the kidney. The accumulation of pus is most likely caused by some obstructive process or infection that leads to urinary stasis, as seen in many cases of pyelonephritis. (Steven M. Penny, 2011).

- Clinical findings of pyonephrosis
  - Pyuria
  - Bacteruria
  - Fever
  - Leukocytosis
- Sonographic findings of pyonephrosis
  - Hydronephrosis
  - Pus and debris appear as internal, layering, and low-level echoes within the dilated collecting system. (Steven M. Penny, 2011).

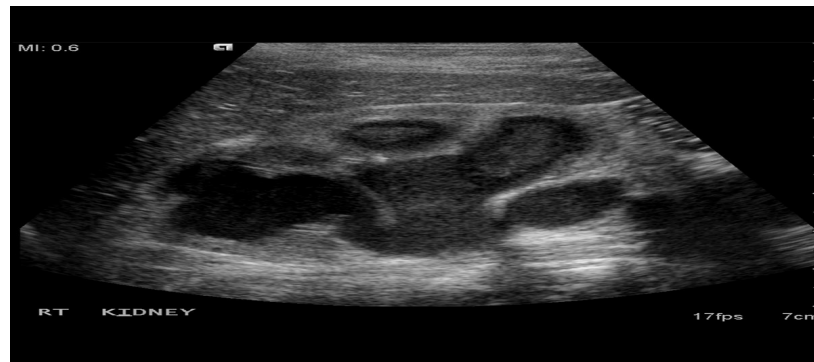


Figure 2.15 Pyonephrosis (<http://www.ajronline.org>)

## **Renal or Perinephric Abscess**

A renal abscess can occur in regions of the kidney affected by pyelonephritis or be located adjacent to the kidney. A perinephric abscess is a collection of purulent material that has leaked through the capsule into the tissue surrounding the kidney.. (Figure 2-16). (Barton Dudlick, 2006).

Clinical findings of a renal or perinephric abscess

- . Symptom of pyelonephritis
- . High fever
- Flank pain
- Leukocytosis

Sonographic Findings Of Renal Or Perinephric Abscess

- . Can appear anechoic, hypoechoic, or complex, depending on its contents

Gas shadows or dirty shadowing may be present within the mass. (Steven M. Penny, 2011).

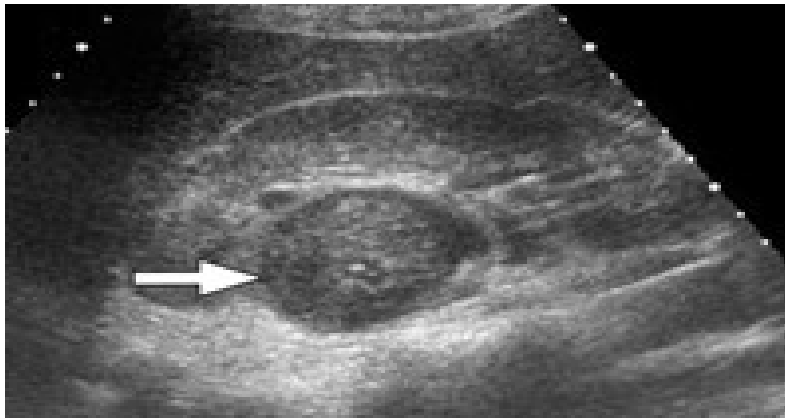


Figure 2.16 renal abscess (<http://www.ajronline.org>)

### **Emphysematous Pyelonephritis**

A rare, and yet life-threatening, complication of pyelonephritis is emphysematous pyelonephritis. Though emphysematous pyelonephritis may be the result of a long-standing urinary tract obstruction, it is found more often in patients who have diabetes mellitus or who are immunocompromised.<sup>4,8</sup> The term emphysematous denotes the formation of air within an organ. Consequently, with emphysematous pyelonephritis, bacterial formation allows gas to accumulate within the renal parenchyma. *Escherichia coli* infection is the most common culprit. artifact . (Barton Dudlick, 2006)

- Clinical Findings of Emphysematous Pyelonephritis
  - . Diabetes mellitus
  - Immunocompromised patient
  - Fever
  - Flank pain
  - Leukocytosis
- Sonographic Findings Of Emphysematous Pyelonephritis
  - . Gas or air within the renal parenchyma
  - . Dirty shadowing (reverberation artifact) coming from the renal parenchyma. (Steven M. Penny, 2011)

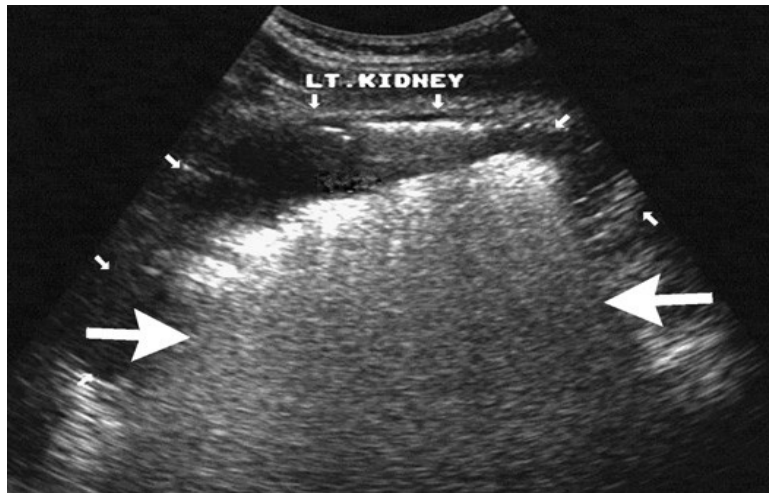


Figure (2-17), emphysematous pyelonephritis  
(.Radiol, (2006).

### **Chronic Pyelonephritis**

Recurrent kidney infections or chronic obstruction may lead to scarring of the calices and renal pelvis. This is referred to as chronic pyelonephritis. Chronic pyelonephritis can lead to xanthogranulomatous pyelonephritis and end-stage renal disease. (figure 2-18). (Steven M. Penny, 2011).

- Clinical Findings Of Chronic Pyelonephritis

- Flank pain
- Bacteruria
- Pyuria
- Leukocytosis
- Dysuria
- Urinary frequency

- Sonographic Findings Of Chronic Pyelonephritis

Small, echogenic kidneys that have lobulated borders. (Steven M. Penny, 2011).

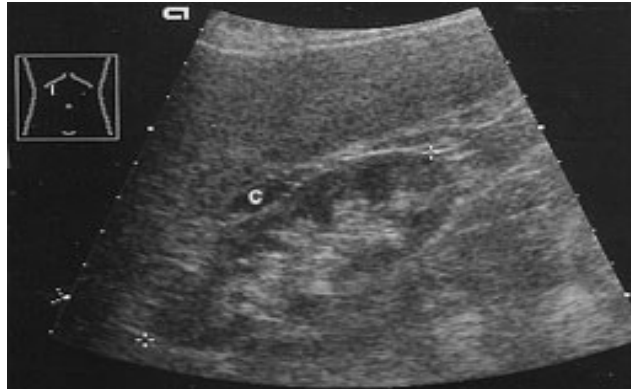

Figure (2-18), chronic pyelonephritis, decreased renal size in pyelonephritis (83.9mm, cursors): Foci of parenchymal thinning due to scarring, producing a wavy surface contour in chronic pyelonephritis. (Schmidt, 2011).

### **2-4-1-2 Renal Fungal Disease**

The most common cause of fungal urinary tract infections is *Candida albicans*, immunocompromised patients are at increased risk for developing a fungal infection within their kidneys. Also, patients with a history of diabetes mellitus, intravenous drug abuse, and infants that have long-standing, indwelling catheters are more likely to suffer from renal fungal disease. (Steven M. Penny, 2011).

- Clinical Findings of Renal Fungal Disease
  - Immunocompromised person
  - Diabetes mellitus, IV drug abuse or long-standing indwelling catheter
  - Infant with an indwelling catheter
  - Flank pain
  - Fever
  - Chills

▪ Sonographic Findings Of Renal Fungal Disease  
Fungal balls appear as hyperechoic, nonshadowing mobile structures within the renal collecting system. (Steven M. Penny, 2011).



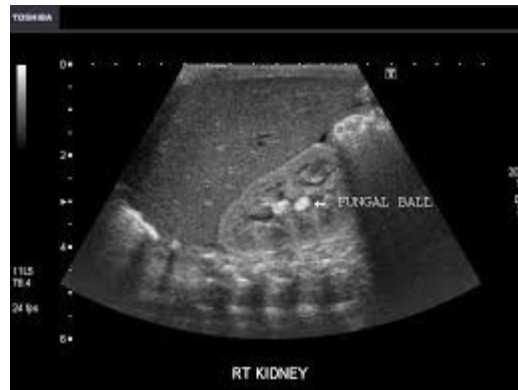

Figure (2-19), fungal ball (www.studyblue.com)

## **2-4 -2 inflammatory conditions**

### **Glomerulonephritis**

Glomerulonephritis can be caused by a distant infection such as a throat infection or an autoimmune reaction. Some conditions, such as lupus, have glomerulonephritis as a characteristic feature. The infection can lead to significant glomerular damage and the kidneys can slowly shut down secondary to diminished filtration capabilities. Patients typically present with smoky urine, fever, proteinuria, hematuria, hypertension, and azotemia.

Glomerulonephritis can be acute or chronic. In the acute stage, the kidney may enlarge and have varying degrees of echogenicity. The renal pyramids may appear more prominent with acute glomerulonephritis. (Figure 2-20). (Steven M. Penny, 2011).

- Clinical Findings of Glomerulonephritis
  - Recent throat infection (acute)
  - Smoky urine
  - Hematuria
  - Proteinuria
  - Fever
  - Hypertension
  - Azotemia
- Sonographic Findings of Acute Glomerulonephritis
  - Enlarged kidney(s) of varying echogenicities

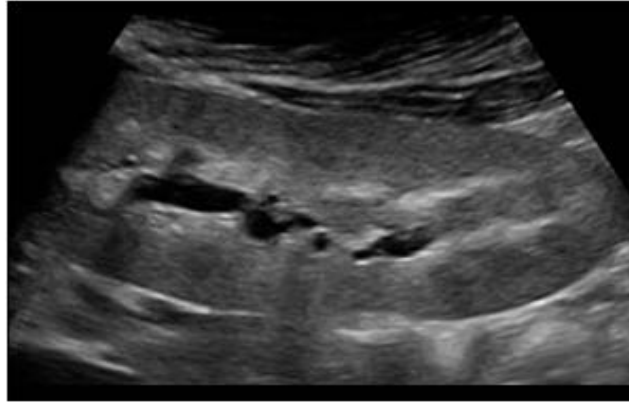


Figure (2-20) acute GN enlarged kidney with increase cortical echogenicity. ([www.toplowridersites.com](http://www.toplowridersites.com)).

**Chronic glomerulonephritis:** the result of a long-standing infection, can lead to end-stage renal disease. (Barton Dudlick, 2006).

#### Sonographic Findings of Chronic Glomerulonephritis

Small, echogenic kidney(s). (Figure 2-21). (Steven M. Penny, 2011).

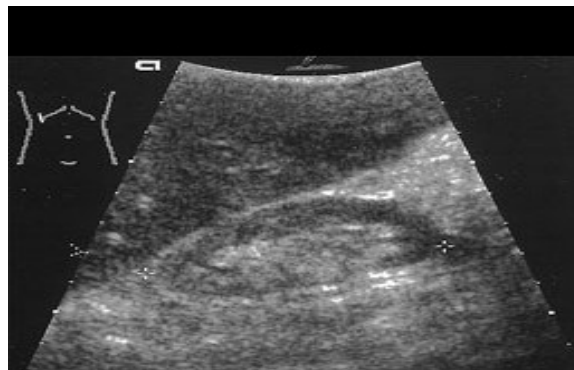


Figure (2-21) , Chronic glomerulonephritis small kidney , with increased echogenicity , and loss of corticomedullary differentiation (Schmidt, 2011) .

#### 2-4-3 Renal stones

Renal calculi are a common finding on ultrasound. They may be an accidental discovery in an asymptomatic patient; alternatively they may be present in patients with acute renal colic and complete or partial obstruction of the ipsilateral renal tract. They

may be the cause of haematuria and can also be associated with urinary tract infections.

The composition of calculi can vary. The common types include:

- Calcium stones are the most common type and are frequently associated with patients who have abnormal calcium metabolism.
- Struvite (triple phosphate) stones have a different composition of salts and are associated with urinary tract infections. They may form large, staghorn calculi.
- Uric acid stones are rare, and tend to be associated with gout.
- Cystine stones are the rarest of all and result from a disorder of amino acid metabolism—cystinuria.

Most renal calculi are calcified foci located in the collecting system of the kidney. Careful scanning with modern equipment can identify over 90% of these.<sup>16</sup> Most stones are highly reflective structures which display distal shadowing. The shadowing may, however, be difficult to demonstrate due to the proximity of hyperechoic sinus echoes distal to the stone, or due to the relatively small size of the stone compared to the beam width.

The identification of reflective foci in the kidney is complicated by the fact that the normal renal sinus echoes are of similar echogenicity. This means that small stones may be missed on ultrasound. Differentiation of stones from sinus fat and reflective vessel walls is dependent upon careful technique and optimal use of the equipment. The operator must adjust the technique to display the distal shadow by using a variety of scanning angles and approaches and by ensuring that the suspected stone lies within the (narrowest) focal zone of the beam. The higher the frequency used, the better the chances of identifying the stone. Clearly the identification of large calculi is normally straightforward; however, for many of the reasons above, identification of small calculi can be difficult, especially in a patient with pain. Ultrasound still has a major role, however, not

just in calculus detection but in identifying the secondary effects, that is, hydronephrosis, and where necessary, guiding renal drainage.

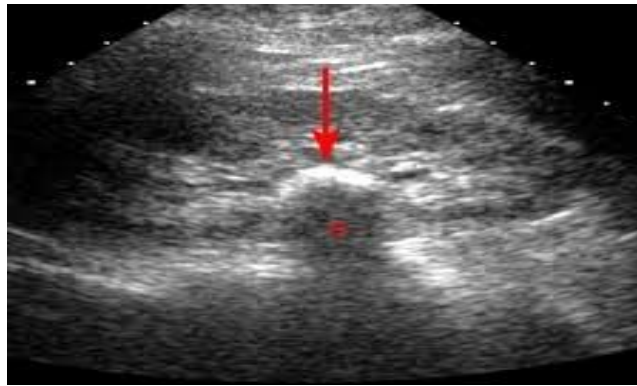


Figure (2-22) renal stones

([www.urologystone.com](http://www.urologystone.com))

#### **2-4-4 Hydronephrosis and Renal Obstruction**

hydronephrosis is dilation of the calices, infundibula, and renal pelvis. Hydronephrosis may also be referred to as pyelocaliectasis, and described more specifically according to which part of the kidney is dilated. (table ) (It may also be described as mild, moderate, and severe or marked. Mild hydronephrosis is noted as distension of the renal pelvis, whereas moderate hydronephrosis is described as further progression of distension into the calices and medullary pyramids. Marked hydronephrosis extends into the cortex and causes severe thinning of the parenchyma. (Jane Bates, 2004).

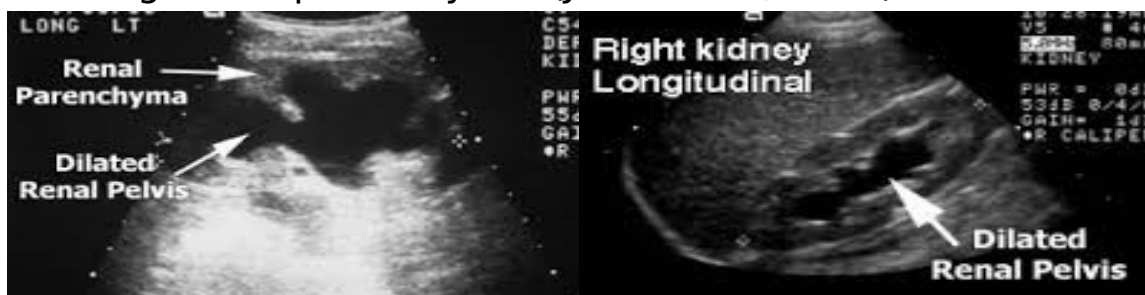


Figure (2-23) Hydronephrosis

([www.meddean.luc.edu.com](http://www.meddean.luc.edu.com))

Irregularities that lead to renal obstruction that are located inside of the urinary tract are called intrinsic causes of hydronephrosis,

and abnormalities that are located outside of the urinary tract that lead to renal obstruction are referred to as extrinsic causes of hydronephrosis ( table 2-2) . (Steven M. Penny, 2011).

Renal obstruction, particularly if long-standing, can irreversibly damage the kidney or kidneys, leading eventually to renal failure. If diagnosed early enough, renal function can be preserved and therefore ultrasound plays a prominent role as one of the first-line investigations in patients with loin pain, renal colic or micturition disorders In the vast majority of cases. (Figure 2-24).

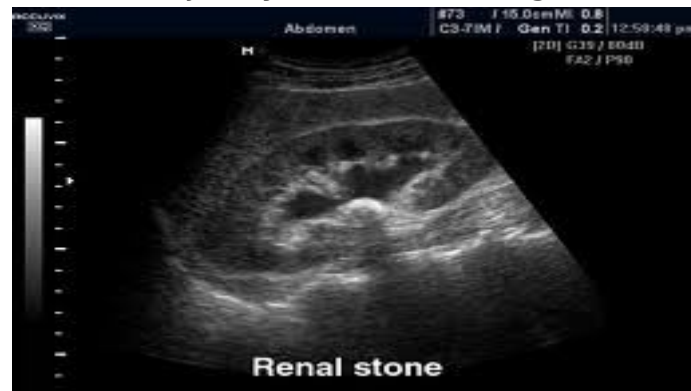

Figure (2-24) obstructing stone

([www.ultrasound-images.com](http://www.ultrasound-images.com))

Table (2-1) causes of hydronephrosis

Intrinsic Causes of Hydronephrosis
<ul style="list-style-type: none"> <li>- Urolithiasis</li> <li>- Congenital abnormality (vesicoureteral reflux, posterior urethral valves, and ureterovesicular junction obstruction)</li> <li>- Hematoma (blood clot)</li> <li>- Neoplasm</li> <li>- Ureteropelvic junction obstruction or ureteral stricture</li> <li>- Ureterocele</li> </ul>
Extrinsic Causes of Hydronephrosis
<p>Benign prostatic hypertrophy</p> <p>Neurogenic bladder</p> <p>Pelvic masses (uterine leiomyoma, ovarian masses.</p> <p>Tubo-ovarian abscess and bowel masses)</p> <p>Pregnancy</p>

## **2-4 -5 Benign Masses of the Kidney**

### **Renal Adenoma**

A renal cell adenoma is a benign mass that appears sonographically similar to its malignant counterpart, the RCC. Clinically, patients are most often asymptomatic, although larger tumors may lead to hematuria . Surgical excision or biopsy is often warranted to differentiate the renal adenoma from RCC. (Barton Dudlick, 2006).

- Clinical Findings of Renal Adenoma
- . Asymptomatic
- . May complain of hematuria
- Sonographic Findings Of Renal Adenoma
- Hyperechoic, vascular mass with internal calcifications
- May produce acoustic shadowing. (Figure 2-25). (Steven M. Penny, 2011).

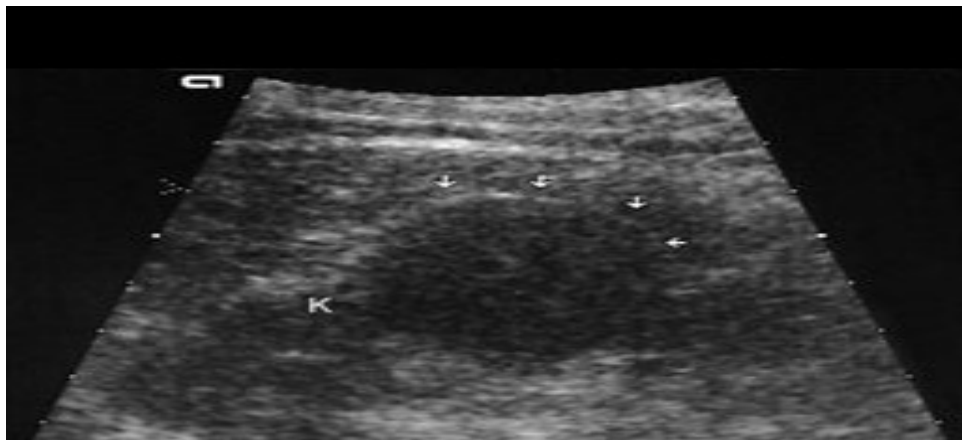


Figure (2-25 ) Renal adenoma. Hypoechoic mass with smooth margins

(Schmidt, 2005)

### **Angiomyolipoma**

The angiomyolipoma is a common benign renal tumor that consists of a network of blood vessels, muscle, and fat. It may

also be referred to as a renal hamartoma. These masses are frequently incidentally encountered and are unilateral and asymptomatic in the general population. However, patients with tuberous sclerosis have a tendency to have multiple and bilateral angiomyolipomas. If symptoms do occur, they will be secondary to hemorrhage within the mass. These symptoms include hematuria, pain, and/or hypertension. Classically, the sonographic appearance of an angiomyolipoma is a solid, echogenic mass. However, depending on the composition of the mass the sonographic appearance may vary. Angiomyolipomas, in 20% to 30% of the cases, will shadow secondary to its high fat component.<sup>11</sup> Because RCC rarely shadows, the acoustic shadowing seen posterior to a hyperechoic mass is helpful, but not always indicative of angiomyolipoma. (Jane Bates, 2004).

- Clinical Findings Of Angiomyolipoma

- Asymptomatic

- Tuberous sclerosis

- Sonographic Findings Of An Angiomyolipoma

- Solid, hyperechoic mass

- May produce acoustic shadowing

- Tend to be multiple and bilateral with tuberous-sclerosis. .

(Steven M. Penny, 2011).

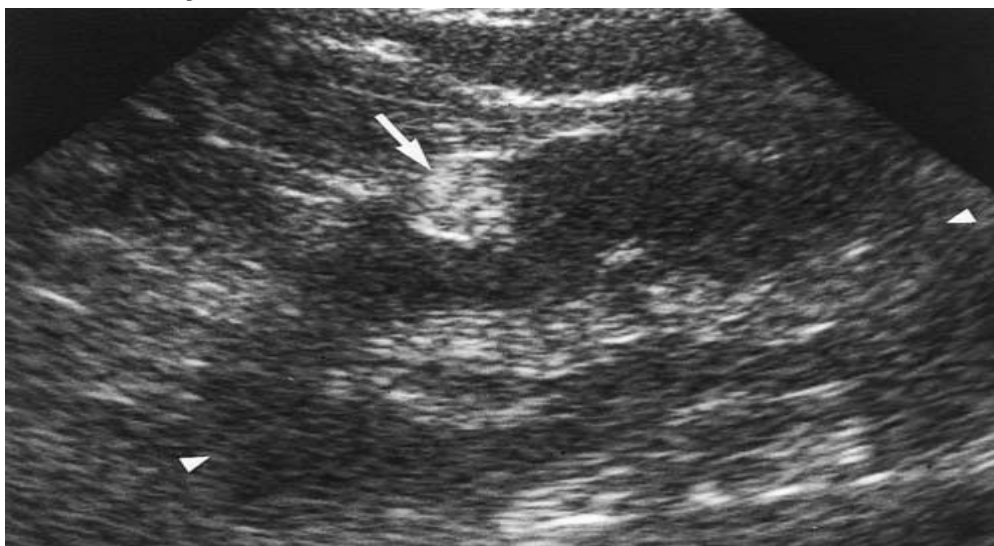

Figure (2-26), angiomyolipoma a small echogenic mass within the renal parenchyma. (Schmidt, 2011).

### **Renal Hemangioma**

Like benign hemangiomas found elsewhere in the body, the renal hemangioma consists of a mass of blood vessels. They are most often asymptomatic and are encountered during the third or fourth decade of life. Again, pain and hematuria may result from hemorrhage within the mass.

- Clinical Findings Of A Renal Hemangioma
  - Asymptomatic
- Sonographic Findings of A Renal Hemangioma
  - Small, hyperechoic mass. (Steven M. Penny, 2011).

### **Renal Lipoma**

A lipoma is a benign fatty tumor. The renal lipoma is most often found in women and they are typically asymptomatic.

- Clinical Findings Of A Renal Lipoma
  - Asymptomatic
- Sonographic Findings Of A Renal Lipoma
  - Well-circumscribed, hyperechoic mass. (Steven M. Penny, 2011).

## **2-4-6 Malignant Renal Masses**

### **Renal Cell Carcinoma**

Renal cell carcinoma (RCC) may also be referred to as a hypernephroma or adenocarcinoma of the kidney. It is a primary form of renal cancer. Smoking, hypertension, obesity, and tuberous sclerosis increased risk for developing RCC. Also, there seems to be a strong association between RCC and von Hippel-Lindau disease.<sup>6,7</sup> Patients who have acquired renal cystic disease from long-term dialysis are especially susceptible to develop RCC. Unfortunately, frequently symptoms manifest late in the disease when the tumor is moderately large. Patients may



present with flank pain, a palpable mass and gross hematuria. They may also suffer from unexplained weight loss and anorexia. The tumor can spread into the renal vein and inferior vena cava. (Figure 2-27). (Barton Dudlick, 2006).

- Clinical Findings of Renal Cell Carcinoma

- Anorexia
- Flank pain
- Gross hematuria
- Hypertension
- Palpable mass
- Weight loss

- Sonographic Findings of Renal Cell Carcinoma

Hypoechoic or isoechoic solid mass on the kidney. (Steven M. Penny, 2011).

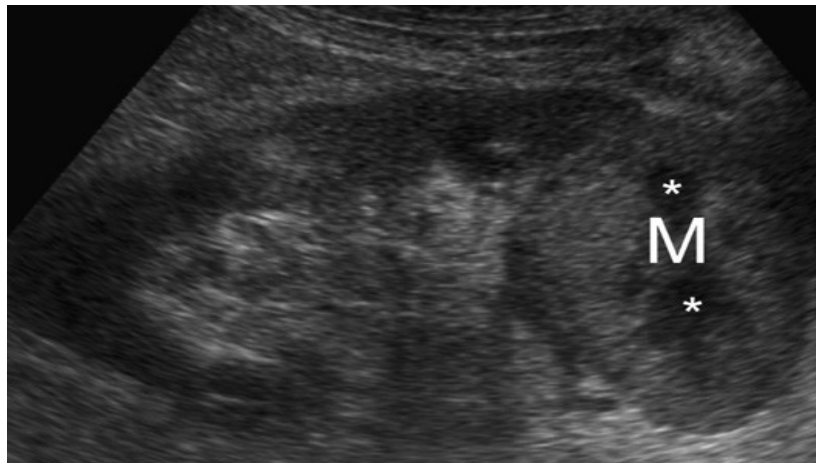


Figure (2-27). RCC. a hyperechoic mass (M) arising from the lower pole with areas of intra tumoral cystic changes. (Barton Dudlick,2006).

### **Transitional Cell Carcinoma of the Kidney**

Transitional cell carcinoma (TCC) of the kidney is a malignant tumor that is most often found in the area of internal pelvis. TCC may also be found within the ureter and urinary bladder. TCC can cause focal dilation of the calices and small lesions can be difficult

to identify with sonography. 8 Larger masses most often appear as hypoechoic or isoechoic masses within the renal sinus.8 Patients may present with hematuria and pain secondary to renal obstruction.

- Clinical Findings Of Transitional Cell Carcinoma
- Hematuria
- Pain secondary to renal obstruction
  - Sonographic Findings Of Transitional Cell Carcinoma Of The Kidney
- Hypoechoic or isoechoic mass within the renal sinus.
- Hydronephrosis may be present. (Steven M. Penny, 2011).

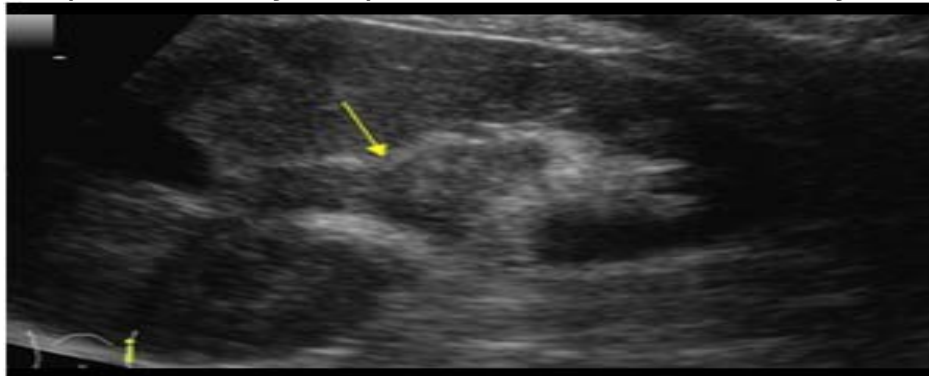


Figure (2.28) transitional cell carcinoma .  
([www.ultrasoundcases.info](http://www.ultrasoundcases.info))

### **Metastases to the Kidney and Other Malignancies**

Metastases to the kidneys are most often from the lungs or breast, with prostate, pancreas, and melanoma occurring less frequently. RCC can also metastasize from the contralateral kidney. (Jane Bates,2004).

- Clinical Findings of Metastases Of The Kidney
- . History of primary cancer (often lung or breast)
- . Hematuria
- . Fever
- . Weight loss
  - Sonographic Findings Of Metastases Of The Kidney
- Bilateral, hypoechoic or hyperechoic masses

-Lymphoma or leukemia can manifest as an enlarged hypoechoic kidney.

## **2-5 Investigation**

### **2-5-1 Urinalysis**

The patients with kidney disease often presents with nonspecific signs and symptoms , that include nausea, anorexia, lethargy, edema, dyspnea, and diminished urine out put. Consequently, the physician must rely on laboratory studies to assist in the evaluation and diagnosis of kidney disease. The urinalysis (UA) is critically important in the diagnosis of renal and urologic diseases (Akin et al., 1987; Kroenke et al., 1986). It is usually abnormal in patients with renal disease.

**visual examination ( appearance)** .The color of the urine should be assessed. The color of normal urine varies from clear (dilute) to yellow (concentrated). Macroscopic (gross) hematuria will make the urine appear red. Smoky red or cola-colored urine suggests glomerulonephritis. Dark yellow to orange urine is typical of bilirubinuria. Cloudy urine suggests pyuria or crystalluria (usually phosphates). Milky urine suggests chyluria (lymphatic/urinary fistula). ([www.labtestonline.org](http://www.labtestonline.org)).

**Chemical examination** To perform the chemical examination, most clinical laboratories use commercially prepared test strips.these are narrow plastic stripes that hold a small squares of paper called test pads, arranged in a row.the test pads have chemicals impregnated into them . when strip is briefly , but completely ,dipped into urine,the test pads absorb the urine and a chemical reaction changes the color of the pads within seconds to minutes. The laboratorian compares the colorchanges for each reaction pad to a color chart provided with the test strips to determine the result for each test. The degree of color change on a test pad also give approximation of the amount of substance present . for example , a slight color change in the test pad for

protein may indicate a small amount of protein present in the urine where as a deep color change may indicate a large amount.

The most frequently performed chemical tests using reagent strips are:

**Specific gravity** .Specific gravity is the weight of urine relative to distilled water and reflects the number and size (weight) of particles in urine. The higher the specific gravity the more solid materials in the urine. The normal range of urine specific gravity is 1.001 (very dilute) to 1.030 (very concentrated).

**PH.** A kidney has important role in maintaining the acid-base balance of the body. Therefore any condition that produce acids or bases in the body such as acidosis or alkalosis, or ingestion of acidic food directly affect urine pH. A urine PH of 4 is strongly acidic, 7 is neutral (neither acidic nor alkaline), and 9 is strongly alkaline.

**Protein** .The protein test reagent is designed to measure the amount of albumen (also known as albumen) in the urine. Normally, there will not be detectable quantities. When urine protein is elevated, the condition known as proteinuria. This can be early sign of kidney disease. Albumin is smaller than most other proteins and is typically the first protein that is seen in the urine when kidney dysfunction begins to develop.

**Glucose** .is normally not present in urine . when the glucose is present the condition called glucosuria. when the blood sugar level is very high , the sugar spills over into the urine. Glucose can also be found in urine when the kidneys are damaged or diseased.

**Ketones.** (Also known as ketone bodies) are not normally found in the urine. A ketone body is a chemical produced when the human body breaks down fat tissue stored around the body for energy. The use of fat instead of sugar by the body is commonly

done following heavy exercise and during long-term exposure to cold. There are also other causes for an increase in fat metabolism, that include, but are not limited to, such things as a shortage of insulin in the bloodstream, a low amount of carbohydrate in the diet (high-protein diets), starvation, dehydration.

**Leuckocyte esterase.** (WBC esterase ) shows leuckocytes in the urine , that WBCs in urine mean UTI is present.

**Nitrites** : bacteria that cause urinary tract infection (UTI ) make an enzymes that changes urinary nitrates to nitrites.  
([www.labtestonline.org](http://www.labtestonline.org)).

**Microscopic examination** Microscopic examination may or may not be performed as part of a routine urinalysis. It will typically be done when there are abnormal finding on the physical or chemical examination. It is performed on urine sediment- urine that has being centrifuged to concentrate the substances in the bottom of tube. The fluid at the top of the tube is then discarded and the drops of fluid remaining are examined under a microscope. Cells, crystals, and other substances are counted and reported either as number observed (per low power field (LPF) or per high power field (HPF).

**White Blood Cells.** Pyuria refers to the presence of abnormal numbers of leukocytes that may appear with infection in either the upper or lower urinary tract or with acute glomerulonephritis. Usually, the WBC's are granulocytes. White cells from the vagina, especially in the presence of vaginal and cervical infections, or the external urethral meatus in men and women may contaminate the urine.If two or more leukocytes per each high power field appear in non-contaminated urine, the specimen is probably abnormal. Leukocytes have lobed nuclei and granular cytoplasm.

**Epithelial Cells.** Renal tubular epithelial cells, usually larger than granulocytes, contain a large round or oval nucleus and normally slough into the urine in small numbers. However, with nephrotic syndrome and in conditions leading to tubular degeneration, the number sloughed is increased.

When lipid uria occurs, these cells contain endogenous fats. When filled with numerous fat droplets, such cells are called oval fat bodies. Oval fat bodies exhibit a "Maltese cross" configuration by polarized light microscopy.

Transitional epithelial cells from the renal pelvis, ureter, or bladder have more regular cell borders, larger nuclei, and smaller overall size than squamous epithelium. Renal tubular epithelial cells are smaller and rounder than transitional epithelium, and their nucleus occupies more of the total cell volume.

Squamous epithelial cells from the skin surface or from the outer urethra can appear in urine. Their significance is that they represent possible contamination of the specimen with skin flora. ([www.mycoclinic.org](http://www.mycoclinic.org))

**Casts.** Urinary casts are formed only in the distal convoluted tubule (DCT) or the collecting duct (distal nephron). The proximal convoluted tubule (PCT) and loop of Henle are not locations for cast formation. Hyaline casts are composed primarily of a mucoprotein (Tamm-Horsfall protein) secreted by tubule cells. The Tamm-Horsfall protein secretion (green dots) is illustrated in the diagram below, forming a hyaline cast in the collecting duct. Even with glomerular injury causing increased glomerular permeability to plasma proteins with resulting proteinuria, most matrix or "glue" that cements urinary casts together is Tamm-Horsfall mucoprotein, although albumin and some globulins are also incorporated. An example of glomerular inflammation with leakage of RBC's to produce a red blood cell cast.

Red blood cells may stick together and form red blood cell casts. Such casts are indicative of glomerulonephritis, with leakage of RBC's from glomeruli, or severe tubular damage

White blood cell casts are most typical for acute pyelonephritis, but they may also be present with glomerulonephritis. Their presence indicates inflammation of the kidney, because such casts will not form except in the kidney.

**Bacteria.** Bacteria are common in urine specimens because of the abundant normal microbial flora of the vagina or external urethral meatus and because of their ability to rapidly multiply in urine standing at room temperature. Therefore, microbial organisms found in all but the most scrupulously collected urines should be interpreted in view of clinical symptoms.

Diagnosis of bacteriuria in a case of suspected urinary tract infection requires culture. A colony count may also be done to see if significant numbers of bacteria are present. Generally, more than 100,000/ml of one organism reflects significant bacteriuria. Multiple organisms reflect contamination. However, the presence of any organism in catheterized or suprapubic tap specimens should be considered significant.

**Yeast** .Yeast cells may be contaminants or represent a true yeast infection. They are often difficult to distinguish from red cells and amorphous crystals but are distinguished by their tendency to bud. Most often they are Candida, which may colonize bladder, urethra, or vagina.

**Crystal's** .Common crystals seen even in healthy patients include calcium oxalate, triple phosphate crystals and amorphous phosphates.  
([www.labtest.online.org](http://www.labtest.online.org) )

## **Red Blood Cells ( hematuria ).**

Can result from bleeding at any site in the urinary tract, from the kidney to the tip of the urethra. Generally, hematuria is defined as the presence of 5 or more red blood cells (RBCs) per high-power field. Hematuria can be either gross (ie, overtly bloody, smoky, or tea-colored urine) or microscopic. It may also be either symptomatic or asymptomatic, either transient or persistent, and either isolated or associated with proteinuria and other urinary abnormalities uses range from to benign to serious. ( [www.medicinehealthy.com](http://www.medicinehealthy.com)).

### **Signs and symptoms**

The first step in the evaluation of hematuria consists of a detailed history and a thorough physical examination. Efforts should be made to distinguish glomerular causes from extraglomerular ones, as follows:

- Passage of clots in urine suggests an extraglomerular cause
- Fever, abdominal pain, dysuria, frequency, and recent enuresis in older children may point to a urinary tract infection as the cause.
- Recent trauma to the abdomen may be indicative of hydronephrosis
- Early-morning periorbital puffiness, weight gain, oliguria, dark-colored urine, and edema or hypertension suggest a glomerular cause
- Hematuria due to glomerular causes is painless
- Recent throat or skin infection may suggest postinfectious glomerulonephritis
- Joint pains, skin rashes, and prolonged fever in adolescents suggest a collagen vascular disorder



- Anemia cannot be accounted for by hematuria alone; in a patient with hematuria and pallor, other conditions should be considered
- Skin rashes and arthritis can occur in Henoch-Schönlein purpura and systemic lupus erythematosus

Information regarding exercise, menstruation, recent bladder catheterization, intake of certain drugs or toxic substances, or passage of a calculus may also assist in the differential diagnosis. ( Simon Steddon and Neil Ashman,2014)

## **Classification**

- Macroscopic versus microscopic

Macroscopic Blood is visible to the naked eye. Gross hematuria startles the patient; and present early. The patient may not recognize blood and report discoloration (pink, smoky, cola, or tea-like)

Macroscopic hematuria always require investigation (presenting complain in 85% of bladder and 40% of renal tumors.

Heavy bleeding with clot formation almost never occurs in glomerular diseases.

Microscopic Blood only visible under high-powered microscopy. Often detected on dipstick examination in an asymptomatic patient.

- Glomerular versus non glomerular

Provide a framework for considering pathology. Both can present with macro- or microscopic bleeding (particularly non-glomerular hematuria).

Always assume bleeding is non-glomerular (particular age more than 40) until investigation proves otherwise. Locally agreed

nephrological and urological referral and management pathways are highly desirable, particularly for microscopic hematuria. . ( Simon Steddon and Neil Ashman,2014)

Table (2-2) important causes of hematuria by age and source

Origin	age less 40
age above 40	
Glomerular	IgA nephropathy Thin basement membrane disease Alports syndrome. Focal GN
Non-glomerular	renal stones
renal stones	
Upper urinary tract	Pyelonephritis
transitional cell carcinoma	
	Polycystic kidney disease      renal cell
carcinoma	
	Medullary spongy kidney
polycystic kidney disease	
	Hypercalciuria
	hyperuricosuria±stones
papillary necrosis	
	renal trauma                      renal
infarction	

stricture	papillary necrosis	ureteral
	ureteral stricture	Renal TB
thrombosis	Sickle cell disease	Renal vein
	Renal infarction	
	Renal TB	
	Renal vein thrombosis	

---

Lower urinary tract	cystitis,prostitis, and urethritis	cystitis,prostitis, and urethritis
	benign bladder,ureteral polyps and tumors	bladder cancer
	bladder cancer	prostate cancer
prostatic hypertrophy		benign
ureteral/bladder cancer	prostate cancer	benign
	urethral stricture	
	schistosoma hematobium	

---

Uncertain source	exercise hematuria
	Unexplained hematuria ( idiopathic)
	Over-anticoagulation
	Factitious hematuria

---

(Simon Steddon and Neil Ashman,2014)

## **2-5-2 Renal Imaging**

### **Conventional Radiology**

X-ray machines have been used to diagnose diseases for about 100 years. X rays of the urinary tract can help highlight a kidney stone or tumor that could be blocking the flow of urine and causing pain. For men, an x ray also shows the size and shape of the prostate—a walnut-shaped gland that surrounds the urethra at the neck of the bladder and supplies fluid that goes into semen. Conventional x rays do involve some exposure to ionizing radiation—radiation that is strong enough to damage some cells. Two common x-ray procedures include the injection of a special dye, called contrast medium, which shows the shape of the urinary tract.

Intravenous pyelogram (IVP). An IVP is an x ray of the urinary tract. Contrast medium is injected into a vein in the person's arm, travels through the body to the kidneys, and makes urine visible on the x ray. The contrast medium also shows any blockage in the urinary tract. The procedure is performed in a health care provider's office, outpatient center, or hospital by an x-ray technician, and the images are interpreted by a radiologist— a doctor who specializes in medical imaging; anesthesia is not needed. An IVP can help locate problems in the kidneys, ureters, or bladder that may be caused by urinary retention or reflux. (Emilio Quaia,2014)

## **CT Scans**

Computerized tomography scans use a combination of x rays and computer technology to create three-dimensional (3-D) images. A CT scan may include the injection of contrast medium. CT scans require the person to lie on a table that slides into a tunnel-shaped device where the x rays are taken. The procedure is performed in an outpatient center or hospital by a specially trained technician, and the images are interpreted by a radiologist; anesthesia is not needed. CT scans can show stones in the urinary tract, obstructions, infections, cysts, tumors, and traumatic injuries. (Emilio Quaia,2014)

## **MRI**

Magnetic resonance imaging is a test that takes pictures of the body's internal organs and soft tissues without using x rays. MRI machines use radio waves and magnets to produce detailed pictures of the body's internal organs and soft tissues. An MRI may include the injection of contrast medium. With most MRI machines, the person lies on a table that slides into a tunnel-shaped device where the images are taken. The device may be open ended or closed at one end; some newer machines are designed to allow the person to lie in a more open space. During an MRI, the person is usually awake but must remain perfectly still while the images are being taken. A sequence of images taken from different angles may be needed to create a detailed picture of the urinary tract. During the sequencing, the person will hear loud, mechanical knocking and humming noises. The procedure is performed in an outpatient center or hospital by a specially trained technician, and the images are interpreted by a radiologist; anesthesia is not needed, though light sedation may be used for people with a fear of confined spaces. (Emilio Quaia,2014)

## **Ultrasonography**

Ultrasound represent a first line imaging technique in the assessment of the kidney , and it present several advantage over the other imaging technique including, low financial cost ,portability ,availability, lack or restrictions in performing frequent serial examination in short intervals, and absence of exposure to radiation or nuclear traces. (Emilio Quaia,2014).

Ultrasound is useful in assessment of renal location, size, and contour. It also can be used to identify the cortex, medulla, renal pyramids, and distended collecting system or ureter. (Simon Steddon and Neil Ashman,2014) .

It may be helpful in detecting cysts, tumor, obstructions, abscesses, fluid collection, or infections of the kidneys, and renal stone. It can be used to examined transplanted kidney, as well as used in ultrasound guided biopsy and percutaneous nephrostomy. ([www.davita.com/kidney-disease.com](http://www.davita.com/kidney-disease.com)).

Doppler ultrasound analysis of renal vessels has to be performed after conventional gray scale ultrasound examination since it allows functional evaluation of the kidneys. . (Emilio Quaia,2014).

## **2-6-Previous study:**

Has been done by M.H. Khadra et al, 2000 , in a total of 1,930 patients e enrolled prospectively in the study at a hematuria clinic their evaluation consisted of basic demographics, history and examination, routine blood tests, urinalysis and cytology . All patients underwent plain abdominal radiography, renal ultrasound, IVP and flexible cystoscopy. Their result showed that total of 1,194 males and 736 females with a mean age of 58 years (range 17 to 96) were included in the study. Overall, 61% of patients had no basis found for hematuria, 12% had bladder cancer, 13% had urinary tract infection and 2% had stones. Kidney and upper tract tumors were noted in 14 patients (0.7%), including 4 who presented with microscopic hematuria.

Study done by PH Ellenbogen ,2011, to determine the reliability of gray scale ultrasound in detecting urinary tract obstruction , aprospective study of 67 patients examined by both excretory urography and ultrasound, result showed that hydronephrosis was correctly diagnosed with ultrasound in 44 of 47 patients kidneys shown to be obstructed on urography .

Other done by (LOUIS J. JR et al, 2005). They used 282 consecutive patients (5days- 6months) old, 96male and 184 females. They underwent radiographic evaluation for febrile UTI between October 1995-2001. All patients evaluated with VCUG and renal ultrasound. They found that of 203 patients with normal VCUG, ultrasound was abnormal in 32 (16%). They concluded that renal ultrasound adds information to the radiologic evaluation of infants after febrile UTI.

## **CHAPTER THREE**

### **Material and Method**

#### **3.1 Subject**

Fifty patients were enrolled in the study, their including and excluding criteria as follows:

##### **3.1.1 Including criteria:**

Patients present with uncountable pus and RBCs in their urinalysis test , male and female over age of 20 years.

##### **3.1.2Excluding criteria**

- 1-Pregnant women
- 2- Patient with congenital malformation
- 2- Diabetic and hypertensive patients.

#### **3-2-Area of study:**

The study conducted in U/S department in a academy hospital, and some private medical centers.

#### **3.3 Data collection:**

1. Questioner including personal data.
2. Laboratory results.
3. Ultrasound finding.

### **3.4 Data analysis:**

Data were analyzed with SPSS (statistical package of the social science).

### **3.5 machines used:**

Shimadzu sdu 450, trans abdominal convex probe 3.5MHz. And thermal Paper Printer was used.

### **3.6 Technique:**

- Investigation protocols:

The following technique was applied to allow visualization of both kidneys and proximal ureters.

- Pt. preparation: None
- Transducer: curved low frequency transducer 3.5MHZ.

Patient positioning: supine left lateral oblique, right lateral decubitus, and Prone position was sometimes applied to thin patients.

Initial approach for Right kidney, longitudinal section pt. supine transducer position directly below the costal margin in the midclavicular line, beams pointing slightly cephalic.

Respiratory maneuver: deep inspiration protrusion of anterior abdominal wall.

Scanning procedure: spread out gel with transducer face. With patient in quite respiration, survey the area. Return to initial scanning position and initiated respiratory maneuver.



Transducer moved smoothly along the costal margin, angling slightly towards the lateral edge of the liver.

Some time respiratory maneuver or pt. position (oblique or decubitus) changed.

Locate the upper pole of the kidneys top look.

Rotate the transducer to join the upper and lower poles. The transducer moved cephalic to caudal to position the kidney in the centre of the screen.

Beam angled slightly from side to side sweeping through the long section of the kidney.

The last step was repeated two or three times, focusing on central collecting system. Image was appeared in longitudinal section and was measured by bipolar distance.

### **Second approach:**

Transverse section: Angulation and position of the transducer in long section. Transducer rotated 90, maintaining angulations.

Scanning procedure:

Transducer swept cephalad and caudal to assess central collecting system

Image was appeared in transverse section of mid portion of kidney.

## **CHAPTER FOUR**

### **RESULT**

Table 4-1: gender distribution

Gender	frequency	percent
Male	22	44%
Female	28	56%
total	50	100%

Figure 4-1 gender frequency distribution

Table 4-2 age distribution

age	20-29	30-39	40-49	>50
frequency	17	19	10	4
percentage	34%	38%	20%	8%

Figure 4-2 age frequency and percentage

Table 4-3 Stone and gender

Stone	Male	Female	total
Frequency	7	4	11
percentage	63.6%	36.4%	100%

Figure 4-3 renal stones and gender

Table 4-4 renal stones and age

Age	20-29	30-39	40-49	<50
Frequency	2	5	4	0
Percentage	18	46	36	0

Figure 4-4 renal stones and age

Table 4-5 renal stones cross tabulation

		Stone_ Lt		Total
		1	2	
Stone_Rt	1	39	5	44
	2	4	2	6
Total		43	7	50

Table (4-6) hydronephrosis

cause	Rt	Lt	Bilatera 	total
Stone	2	1	2	5
Non stone	1	2	1	4
Total	3	3	3	9

Figure (4-5) hydronephrosis.

Table ( 4-7 ) : Right and Left mean kidney volume

Variable	Right Kidney Volume	Left Kidney Volume
Mean	103.9	113.7
STDV	±25.9	±22.1

Table (4-8) volume changes with age in both kidneys

age	RT kidney mean volume	LT kidney mean volume
20-29	127.2	135.1
30-39	103	106.8
40-49	80.6	91.2
>50	82	88.8

Figure (4-6) volume changes with age in both kidneys

**Figure (4-7) : linear relation between volume of the right kidney and age**

**Figure (4-8): linear relation between volume of the left kidney and age**

Table ( 4-9 ) : Right kidney volume **(99.8±37.2)**

volume	Frequency	Percentage
Normal	44	88%
Large	6	12%

Figure ( 4-9 ) : Right kidney volume

Table ( 4- 10) : left kidney volume

volume	Frequency	Percentage
--------	-----------	------------



Normal	47	94%
Large	3	6%

Figure (4- 10): left kidney volume

## **CHAPTER FIVE**

### **5-1 Discussion**

This study had been conducted in the academy hospital on 50 patients presented with uncountable pus and RBCs in their urine. 22 of them are male which is 44%, and 28 are female which is 56%. (Table 4-1),( figure 4-1). This result clarify that women were more affected, and these result was agreed with Rumak who

stated female women aged 15 to 35 are most often affected than male ( *Rumak, , 2011*).

On this study we found that 11 patients with hematuria and pyuria had renal stone which is 22% and 39 patient which is (78%), without stone. (table 4-5), This study in line with finding of M.H. Khadra et al, at 2007, as they mentioned that 61% of patients had no basic cause of hematuria. on the other hand significant difference in respect to renal stone is noted as their study showed only 2% comparing to 22% on this study, this can be explained by that this study looking for hematuria associated with infection, as small mean age of data which was 33 years ,and small sample volume oppose to he looking for only hematuria, 58 years mean age for their study , in this age the masses is a common cause of hematuria., rather than stone and large sample, volume which is 1750 cases , which is more common in younger population. This was consistence with Lemone, who found that most people affected with stone are in young or middle adulthood. (Lemone, etal, 2014).

Regarding the stone the research showed that male are affected than female , as male patients are 7 out of total 11 patients with renal stone which represent 64% , while only other 4 patients are female , which represent 36% (Table 4-3),(figure 4-3). This match with Lemone, etal as they mentioned in their study at 2014 it affect more male (1:10), than female (1:35). (Lemone, etal ,2014) . on the other hand the most affected age group with stone was the group of (30-39) years, it contain 5 patient which is 46% followed by age group (40-49)which contain 4 patients which is 36% while only 2 patient were less than 29 years age which is 18% and patient above 50 years seen (Table 4-4),(figure4-4), this also agreed with Lemone, et al as they stated most people affected are in young or middle adulthood. ). (Lemone, etal, 2014), as well as Ross and Wilson on their study at

2006, mentioned that they are most common in males and after 30 years of age.

In cross relation of right and left renal stones, 39 patients showed no stone in each kidney, and 9 patients showed stone in one kidney 5 detected on the left and 4 in the right kidney. While two patients showed stones on both kidneys (table 4-5) presence of stone either unilateral or bilateral had no effect on cases under study.

Respecting to hydronephrosis the study showed that 9 patients showed hydronephrosis or obstructive changes. This result agree with PH Ellenbogen at 2011, who found that ultrasound detect hydronephrosis in 44 of 46 patients kidneys shown to be obstructed on urography. on the other hand 5 patient with hydronephrosis were be due to stone , 3 of them unilaterally , two on the right , one on the left , and two are bilaterally, and the other 4 ones were due to other causes rather than stone ( table 4-6) (figure4-5). And also agreed with Porth & Matfin, Who were mentioned that calculi in the urinary tract, are the most common cause of upper urinary tact obstruction. (Porth & Matfin, 2009). And also with Lemone etal, at their study in 2014 , as they mentioned that urinary stone may obstruct urine flow at any point of the urinary tract , leading to complication such as hydronephrosis and urinary stasis with subsequent infection. (Lemone, etal, 2014).

The results showed that the mean volume of the Lt kidney was  $140.6 \text{ cm}^3$  which is larger than the Rt one  $103.9 \text{ cm}^3$ . Table (4-7) this also noticed in mean volume in each group which usually in the Lt kidney was larger than the Rt kidney for the same age group . Table (4-8) Figure (4-6).

Also the study showed that, the mean volume of each kidney is decreased dramatically with increasing age except in right kidney of age group above 50 which attributed to the small sample

volume, and presence of hydronephrosis which affect the volume table (4-8) figure (4-6) . This also is shown in the linear relationship which showed that the right kidney volume is decreased by 1.9cm for years , ( figure4-7 ) and the left kidney volume decreased by 1.8cm for years, (figure4-8 ) This is matching with Robert W.Schrier who mentioned that the natural process of aging affect both structure and function of the kidney , that gross kidney weight and mass both decrease as age increase , changes in renal masses may be age-appropriate given that there is parallel decrease in body surface area with aging. And he also state that ultrasound examination of older kidneys reveals a general increase in glomerulosclerosis and tubulointerstitial fibrosis. ( Robert W.Schrier, 2007).

The study showed 9 patients out of 50 which is 18% showed enlarged kidney volume which in right kidney is more than **(99.8±37.2 )** ,and for the kidney is **(124.4±4.3)** according to (j ,Ayub 2005 ) most of enlarged kidneys were observed in younger ages , these renal enlargement is not associated with other sonographic findings (table4-6 ) (figure4-6 ) , (table 4-7 ) (figure 4-7 ) this enlargement could be explained by wide range of inflammatory conditions . and these agree with (LOUIS J. JR et al, 2005) as mentioned that that renal ultrasound adds information to the radiologic evaluation of patients after febrile UTI.

## **5-2 Conclusion**

This study done in academy teaching hospital in 50 patients presented with uncountable pus cells and RBCs in urine .

The goal of this research was to study kidneys volume, and most likely cause of pus sells and RBCs In urine. And their effect on the kidneys using ultrasound imaging.

The result of the study concluded that 11 patients have renal stone, 9 patients have hydronephrosis and 9 patients have enlarged kidney.

Hydronephrosis without intra-renal cause of obstruction , is most likely due to ureteric obstruction , it so difficult to trace ureter using ultrasound .

Ultrasound scanning is very important to diagnose underlying causes of hematuria and pyuria and the complication from that and have a big role in planning of treatment.

### **5-3 Recommendation**

After the enumeration of the results that related to the following thesis, there are some ideas which could help in more proper management and follow up of patient with hematuria and pyuria and better to be recommended as follows:

1. Advice to have ultrasound department in any primary health center as that it be mandatory in renal centers
2. Other investigation beside ultrasound should be used to detect the cause such as conventional xray ,IVP, CT , And MRI may be used for the cause and complication of hematuria and pyuria.
3. Further studies should be done to evaluate the accuracy of ultrasound in detecting the causes as well as complications of hematuria and pyuria, in the kidneys , as well as ureters and bladder.
4. We can use ultrasound guided biopsy to differentiate the wide range on inflammatory conditions, such as glomerulonephritis , nephritic syndrome .

#### **5-4 References:**

Barton Dudlick ,2006, , up date on ultrasound, 4<sup>th</sup> edn, Saunders, london.

Emilio Quaia,2014, Radiological Imaging of the kidney,2<sup>nd</sup> edn,Springers,london.

Guenter Schmidt, 2011, Thiemeclinical companion, ultrasound,Germany,267-270.

Guyton, M., John E. Hall 2006. *Textbook of medical physiology*, philadelphia, Elsevier saunders.

Jane A Bates,2004, Abdominal Ultrasound ,How ,Why, ana When,,2<sup>nd</sup> edn, Churchill livingstone,London,, 166-171.

Lemone et al , 2014 , Medical Nursing Surgery,2<sup>nd</sup> edn,Jones and Bartlett publisher , Canada.

Ross and Wilson, 2006, *anatomy and physiology in heath and illness* ,10<sup>th</sup> edn, An imprint of Elsevier limited , United Kingdom,336-340.

Robert W. Schrier ,2007,Disease Of The Kidneys And Urinary Tract,3<sup>rd</sup> edn, lippincott williamwilkins , United Kingdom.

Rumak et al, 2005, Diagnostic Ultrasound,4<sup>th</sup> edn,Elsevier Mosby,Philadelphia.

R.J.Last,1984,Anatomy Reigonal and Applied,7<sup>th</sup> edn,Longman Singapore Publisher Pte L te Singapore 316-318.

Simon Steddon and Neil Ashman,2014,Oxford Hand Book Of Nephrology and Hypertention,2<sup>nd</sup> edn, Oxford United Press, United kingdom.62-65.

Steven M .Penny,2010, Examination Review of Ultrasound, 2<sup>nd</sup> edn, Williams & Wilkins, Philadelphia.

Valeriec.Scanlon, T. 2007. *Essential of Anatomy and Physiology*, 5<sup>th</sup> edn, philadelphia, F.A.Davis.company.

[www.labtest.online.org](http://www.labtest.online.org).

[www.mycoclinic.org](http://www.mycoclinic.org)

[www.medicinehealthy.com](http://www.medicinehealthy.com)

([www.davita.com/kidney-disease.com](http://www.davita.com/kidney-disease.com)).



## APPENDIX 1

### Master Data Sheet

No	Gend er	Age	kidne y	Volum e	stone	Hyder o
1	1	45	Rt	71	2	1
			Lt	80	1	1

2	1	32	Rt	88	2	1
			Lt	93	1	1
3	2	36	Rt	108	2	2
			Lt	134	1	1
4	1	26	Rt	129	2	1
			Lt	134	1	1
5	2	42	Rt	77	1	1
			Lt	90	2	1
6	1	36	Rt	79	1	1
			Lt	91	2	1
7	1	39	Rt	83	1	1
			Lt	95	2	2
8	1	27	Rt	117	1	1
			Lt	133	2	1
9	2	26	Rt	128	1	1
			Lt	135	2	2
10	1	31	Rt	76	1	2
			Lt	83	1	1
11	1	51	Rt	77	1	2
			Lt	87	1	1
12	1	29	Rt	105	1	1
			Lt	112	1	2
13	1	35	Rt	82	2	2
			Lt	94	2	2
14	2	42	Rt	78	2	2
			Lt	91	2	2
15	2	53	Rt	86	1	2
			Lt	99	1	2
16	2	25	Rt	167	1	1
			Lt	136	1	1
17	2	27	Rt	190	1	1
			Lt	143	1	1
18	2	31	Rt	140	1	1
			Lt	173	1	1
19	2	34	Rt	164	1	1
			Lt	131	1	1
20	2	21	Rt	117	1	1
			Lt	139	1	1
21	2	31	Rt	104	1	1
			Lt	116	1	1
22	1	40	Rt	74	1	1

			Lt	88	1	1
23	1	31	Rt	100	1	1
			Lt	124	1	1
24	2	42	Rt	98	1	1
			Lt	110	1	1
25	1	52	Rt	74	1	1
			Lt	78	1	1
26	2	42	Rt	86	1	1
			Lt	97	1	1
27	1	50	Rt	84	1	1
			Lt	89	1	1
28	1	45	Rt	78	1	1
			Lt	88	1	1
29	2	20	Rt	128	1	1
			Lt	135	1	1
30	2	35	Rt	89	1	1
			Lt	93	1	1
31	2	30	Rt	98	1	1
			Lt	110	1	1
32	2	27	Rt	113	1	1
			Lt	132	1	1
33	2	32	Rt	100	1	1
			Lt	136	1	1
34	2	34	Rt	103	1	1
			Lt	108	1	1
35	2	20	Rt	138	1	1
			Lt	141	1	1
36	2	21	Rt	129	1	1
			Lt	140	1	1
37	2	26	Rt	106	1	1
			Lt	125	1	1
38	2	31	Rt	106	1	1
			Lt	117	1	1
39	1	37	Rt	95	1	1
			Lt	109	1	1
40	2	26	Rt	115	1	1
			Lt	125	1	1
41	2	22	Rt	121	1	1
			Lt	127	1	1
42	1	25	Rt	119	1	1
			Lt	131	1	1

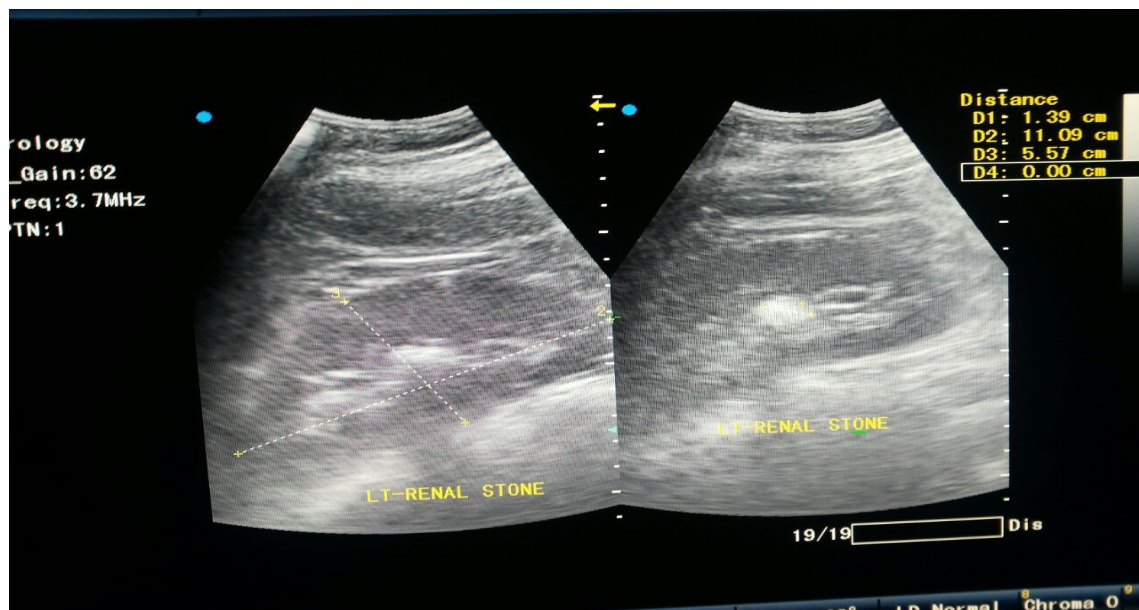
43	1	35	Rt	92	1	1
			Lt	107	1	1
44	1	30	Rt	94	1	1
			Lt	113	1	1
45	1	55	Rt	84	1	1
			Lt	89	1	1
46	1	43	Rt	78	1	1
			Lt	88	1	1
47	2	20	Rt	128	1	1
			Lt	135	1	1
48	1	42	Rt	89	1	1
			Lt	93	1	1
49	2	27	Rt	113	1	1
			Lt	132	1	1
50	2	32	Rt	100	1	1
			Lt	136	1	1

1= male     2= female

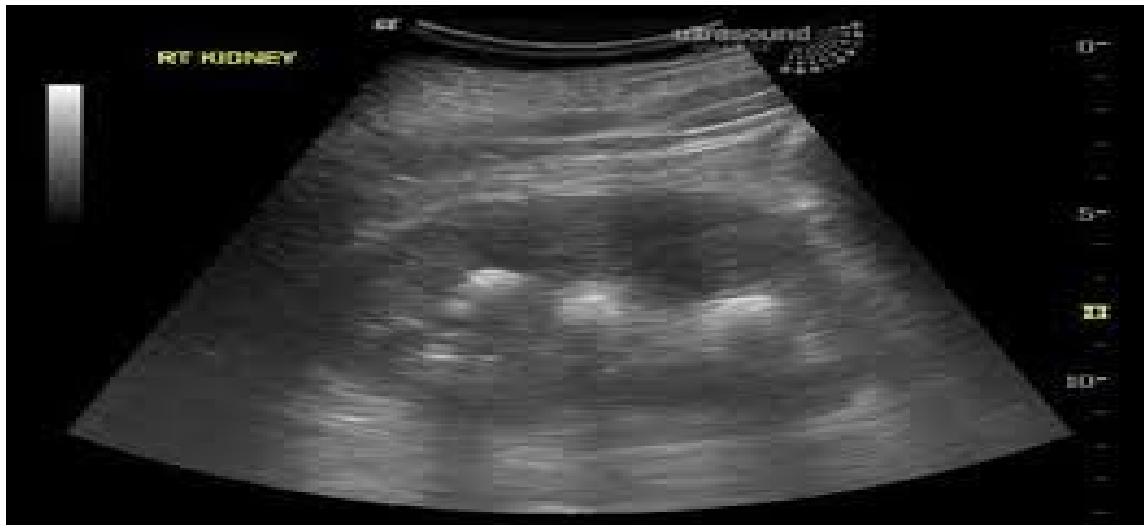1=no stone    2= stone

1= no hydronephrosis    2= hydronephrosis

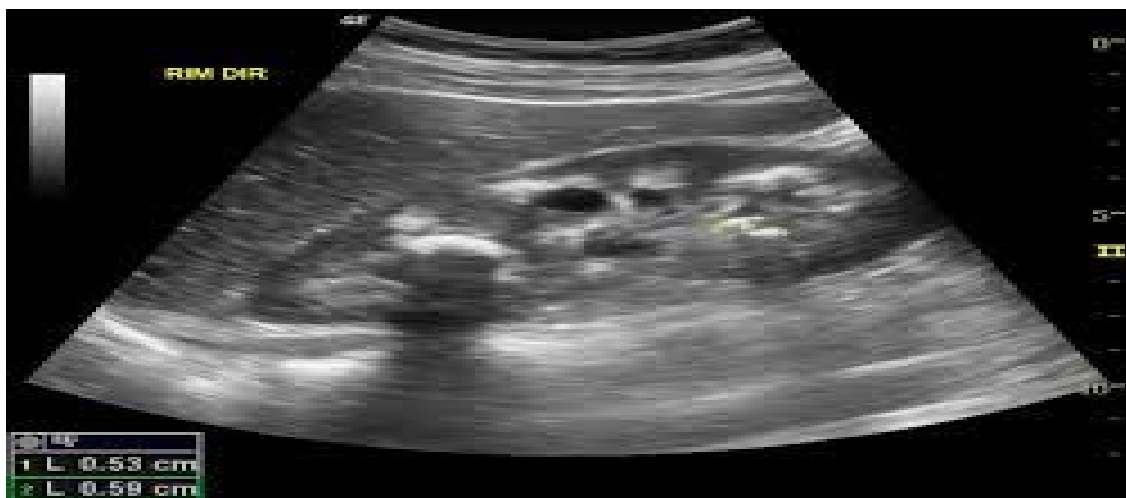## APPENDIX



US image no ( 1 ) , for 32 years old male shows non obstructing right left stone.

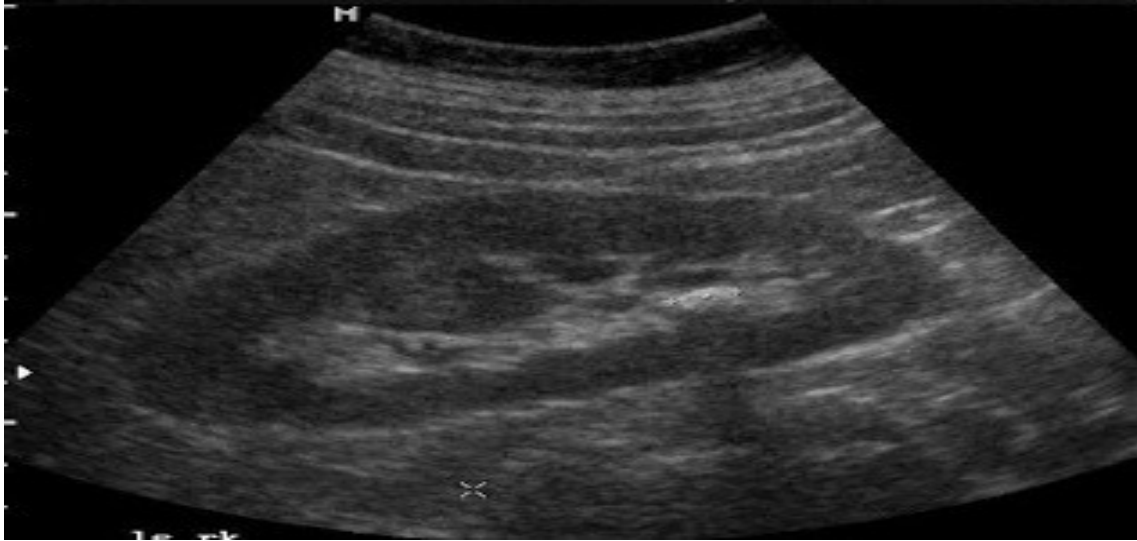

US image no ( 2 ) , for 37 years old female shows multiple right renal stone

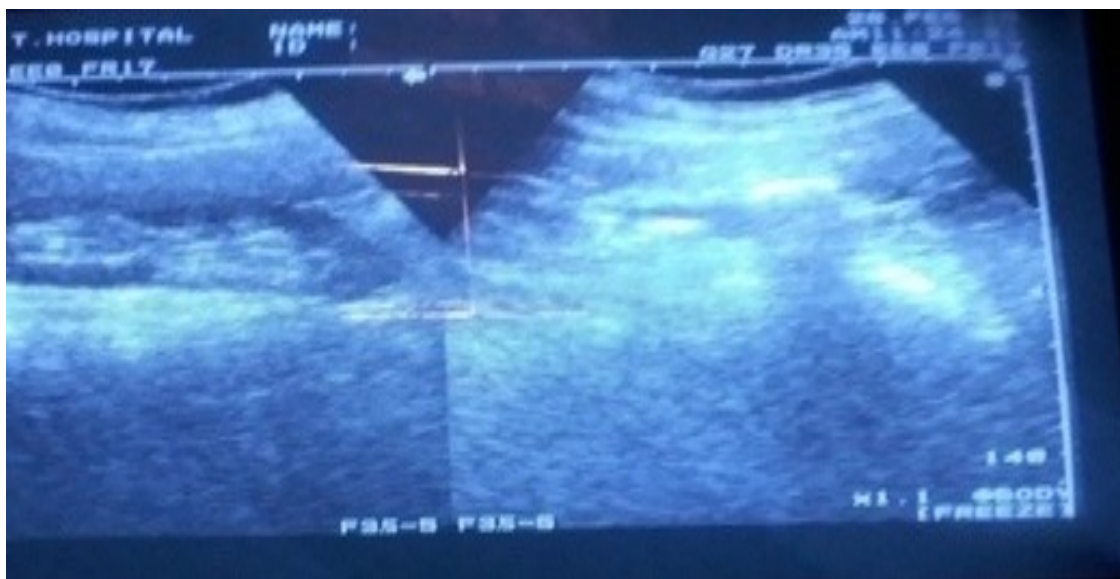

U/S

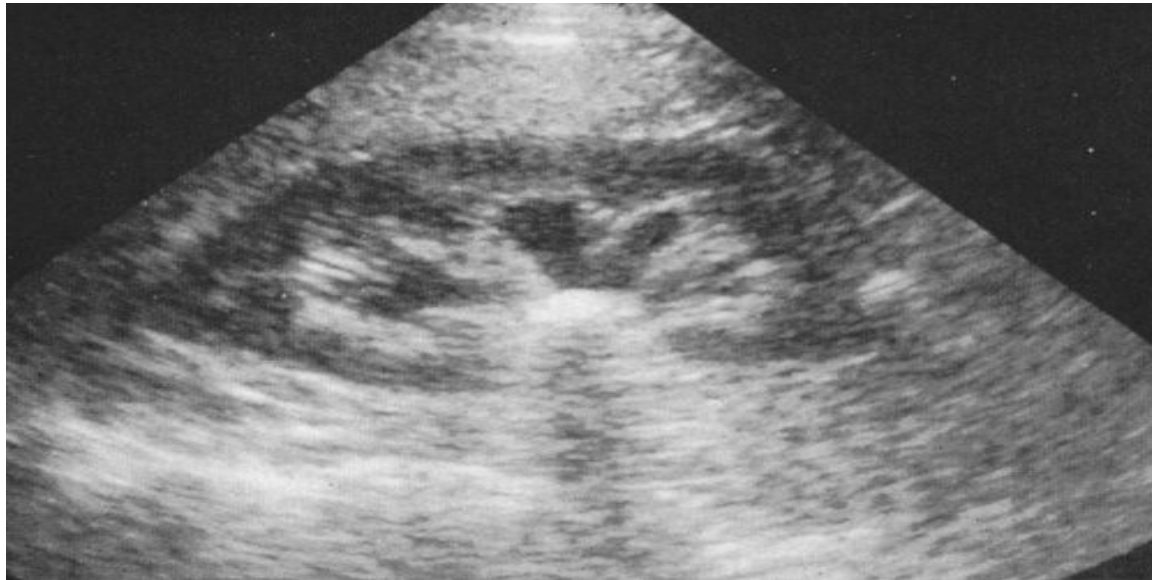image no (3) , for 26 years old female shows right renal stone.



U/S image no (4) , for 35 years old female shows left renal stone.

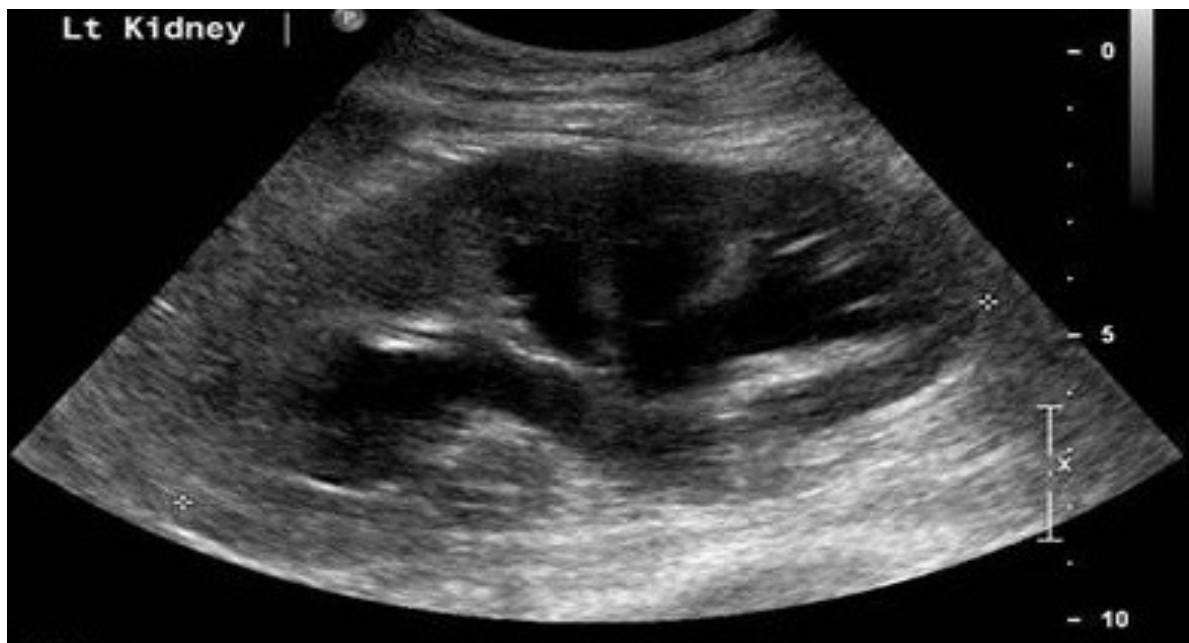

U/S image no (5) , for 42 years old female shows multiple left renal stone with mild hydronephrosis.

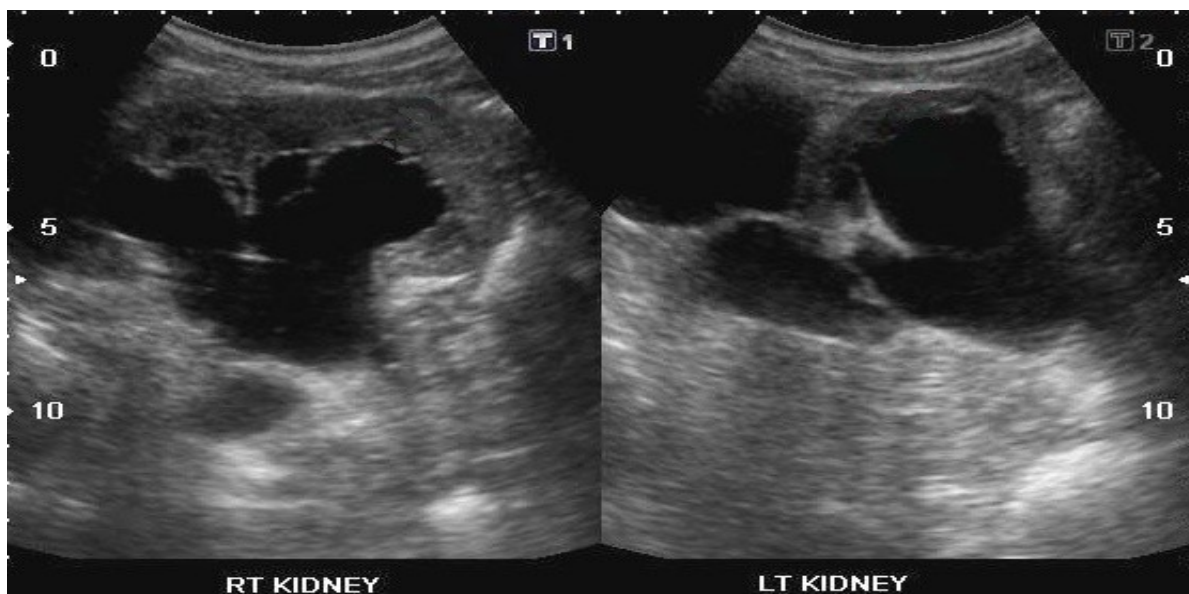


U/S image no (6) , for 36 years old female , shows left renal stone with mild hydronephrosis

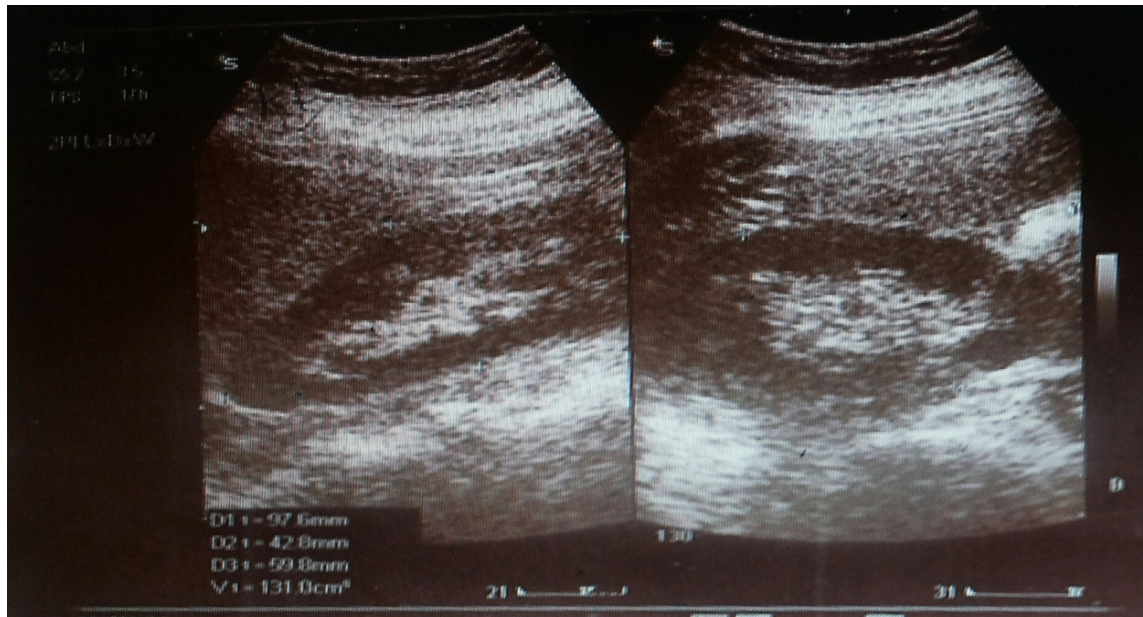




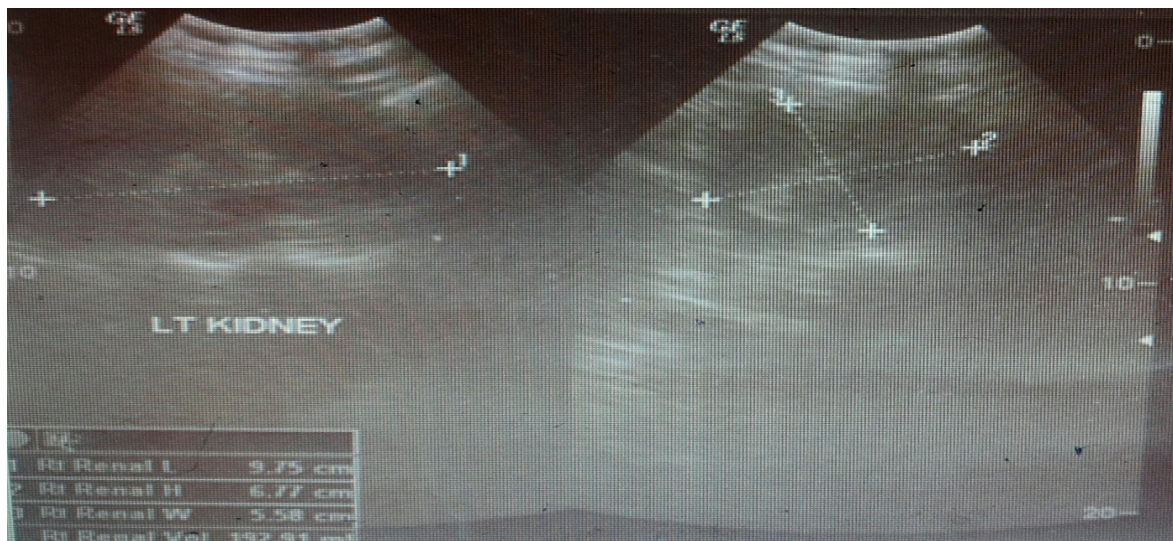U/S image no (7) , for 31 years old male shows moderate hydronephrosis, no intra-renal stone detected.



U/S image no (8) , for 53 years old male shows bilateral moderate to severe hydronephrosis, no intra-renal stone detected.

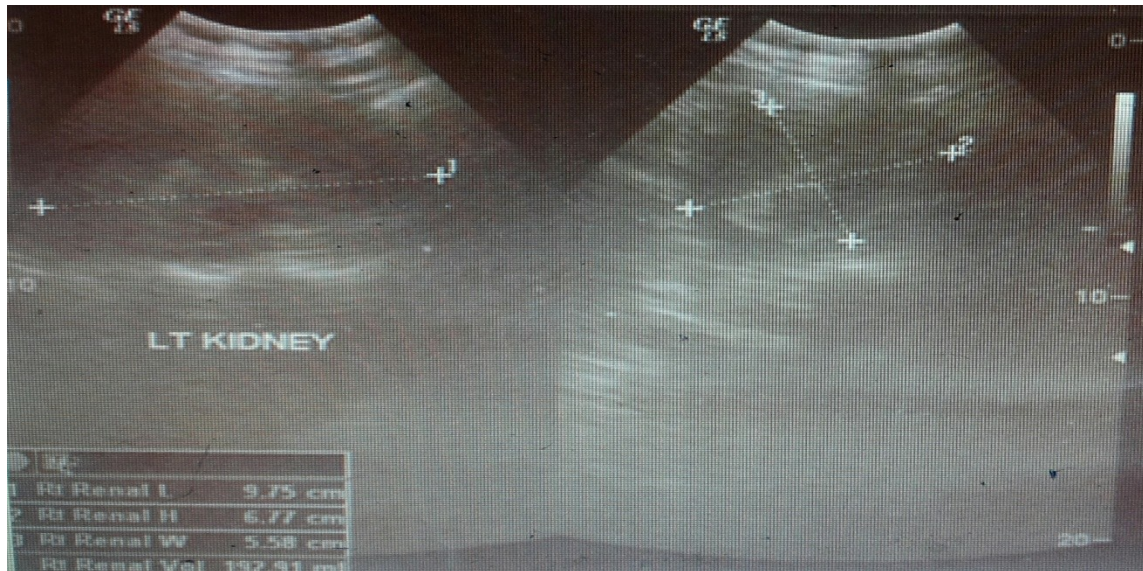


U/S image no (9) , for 30 years old female shows normal right kidney volume measuring (131cc).

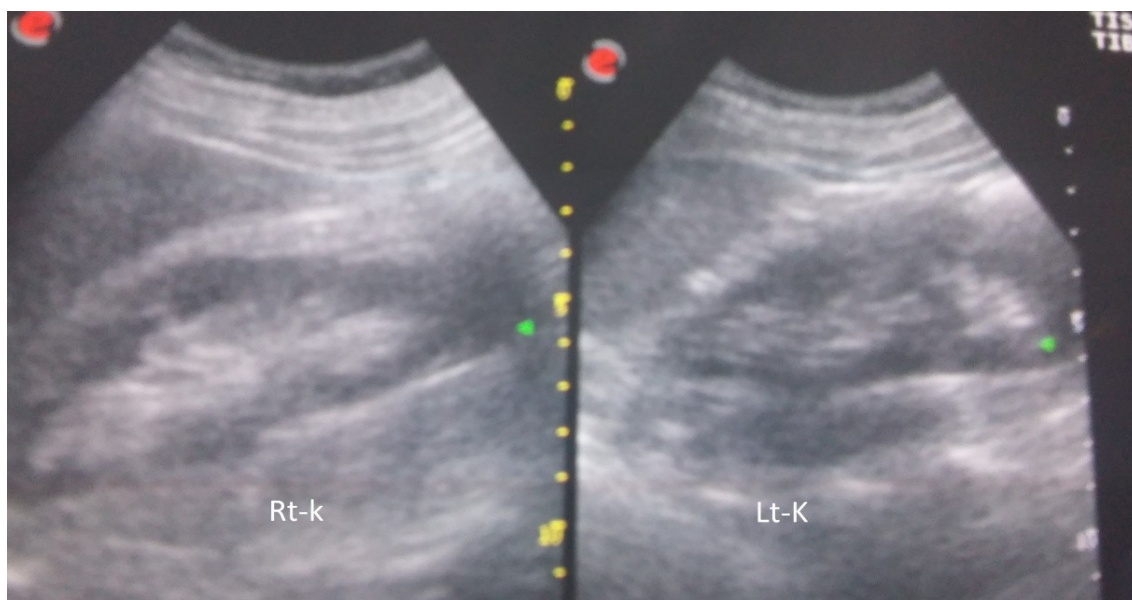


U/S image no (10) , for 25 years old female shows enlarged right kidney measuring (161cc).

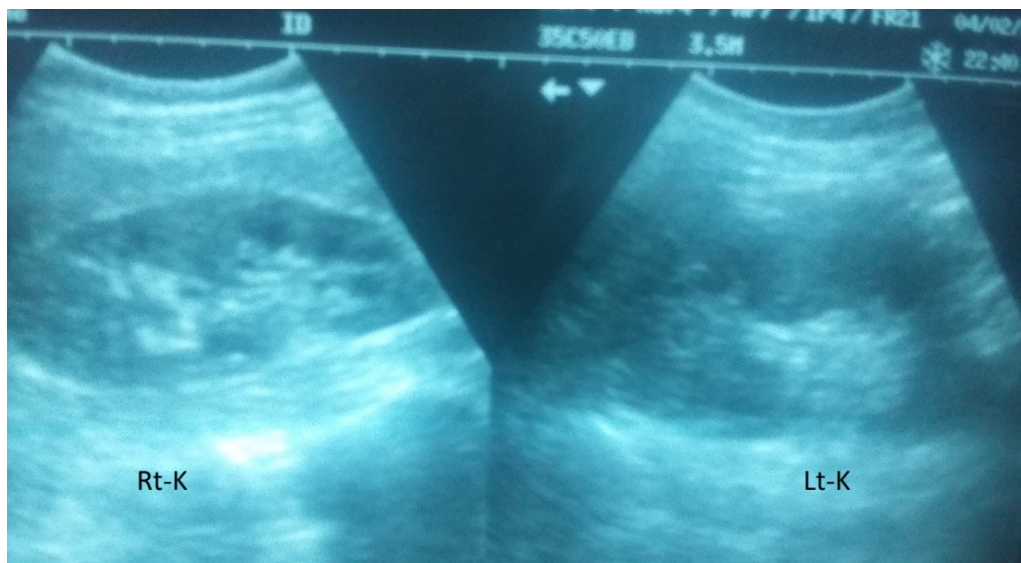




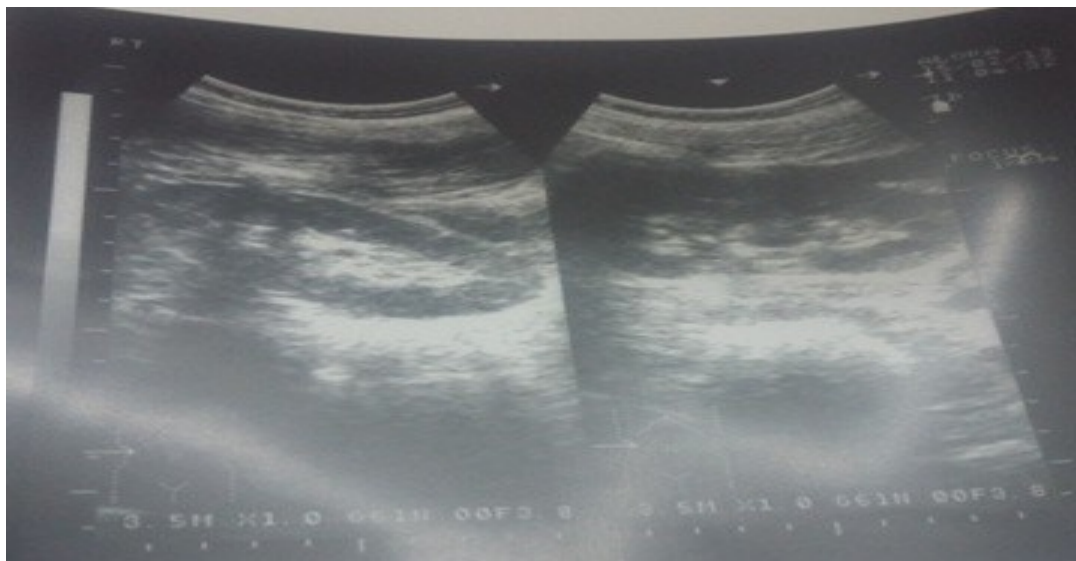U/S image no (11) , for 27 years old female shows enlarged left kidney measuring (192cc).



U/S image no (12) , for 43 years old male shows normal both kidneys.

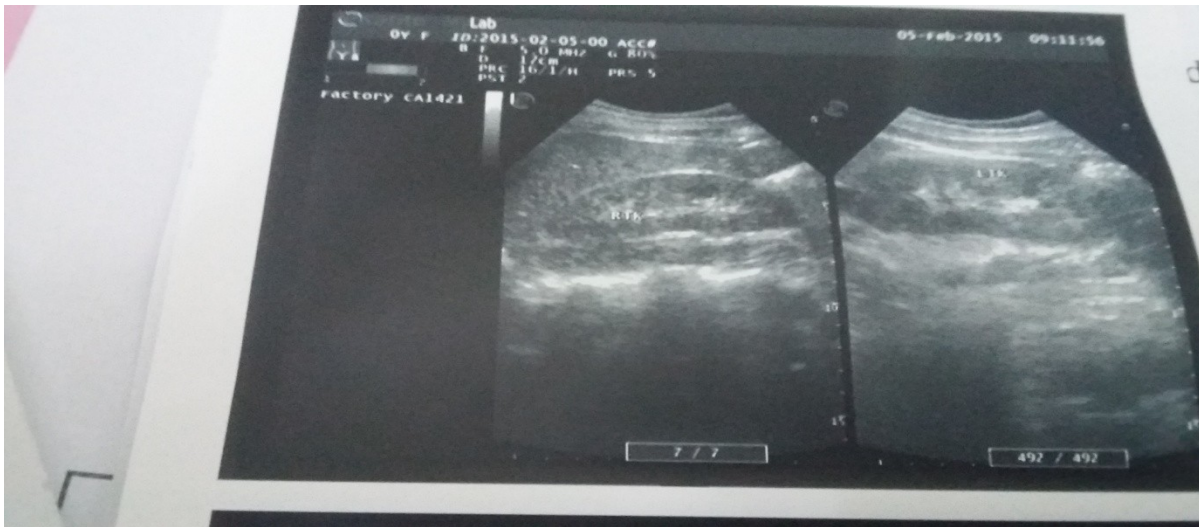


U/S image no (13) , for 20 years old female shows normal both kidneys.

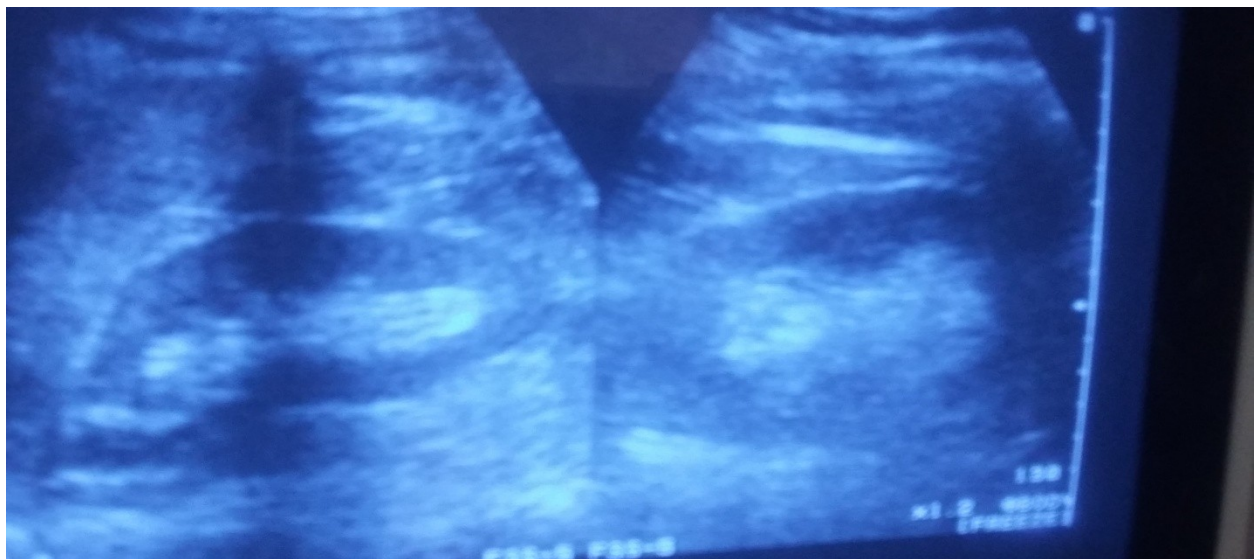


U/S image no (14) , for 27 years old female shows normal both kidneys.





U/S image no (15) , for 35 years old male shows normal both kidneys



U/S image no (16) , for 35 years old male shows normal both kidneys.