

**SUDAN UNIVERSITY OF SCIENCE AND TECHNOLOGY**  
**COLLAGE OF GRADUATE STUDIES**

# **Assessment of Liver Abscess by Using Ultrasound and Ultrasound Guided Drainage**

**تقويمخراج الكبد والتصريف باستخدام امالموجات فوقالصوتية**

A thesis submitted in a partial fulfillment for the requirement of M.Sc.  
Degree in DiagnosticMedical Ultrasound

**By:**  
**Dr. SaydaAbdelgader Mohamed Salih**

**Supervisor:**  
**Dr. El-Safi Ahmed Abdulla**  
**Associate Professor**

**2015**

## DEDICATIONS

---

***TO:***

My honored late Father,

My beloved Mothers,

My darling and supportive auntie,

My dear brothers and sisters,

& my best friends.

## ACKNOWLEDGEMENTS

---

I am indebted to all those who directly or indirectly, have made it for me to write this research.

I would like to express my deep gratitude to Dr. Mohamed Elfadil for his encouraging, supervision, & guidance of this research.

Special thanks for Dr. Alsafifor his good support all the time.

I am especially indebted to Dr. Ahmed Omar & Dr. Alsadiq - the pathologists who helped me and gave me all of the patients' results after aspiration.

My heartily gratitude to my little brother Dr. Ahmed Khalafalla for the computer facilities that he provided.

Finally, special thanks to my family and friends who were of great help during the whole study period

## ABSTRACT

---

A liver abscess is a pus-filled cavity within the liver, usually caused by a biliary tract source, portal venous system, and abdominal trauma.

This is both retrospective and prospective study, facility based-study. Study period conducted from 2008-2013. A total of 54 patients (40 males and 14 females) were studied. Age group was between 1-90 years old. All of them with a known history of liver abscess and were send for aspiration from different hospitals. This study was done assess the role of the ultrasound in diagnosis and treatment of liver abscess.

The procedure is started by normal abdominal ultrasound scan for whole abdomen to determine the exact site, size and echogenicity of the abscess. The machine, the probe, and the whole patient's abdomen were sterilized. 5cc of local anesthesia was injected at the site of procedure. Then, small-sized are totally aspirated to dryness & washed with a few cc of normal saline, without further action. The site is then covered with a plaster, larger sized abscess are drained by inserting by a drainage catheter mostly by Seldinger technique & the catheter is secured in site for about 2 days until the abscess is totally drained & sometimes a saline wash is done through the catheter. Data obtained were analyzed using the statistical package for social sciences (SPSS) version 20 as well as Microsoft Excel 2007.

In summary of the results of this study we showed that the males affected more than females and the right lobe of the liver more than the left lobe. The most typical ultrasound features of the liver abscess are they are usually hypoechoic, well defined and thick walled. Most of the abscesses can be completely aspirated in one session without the need for catheter drainage. After aspiration, mostly, the abscess is yellowish in color and these features are probably of pyogenic liver abscess.



## ملخص الدراسة

خراج الكبد هو عبارة عن تجويف مليء بالصديد داخل الكبد، عادة ما يكون مصدره القناة الصفراوية وجهاز الوريد البابي وإصابات البطن. وتعتبر الموجات الصوتية من أهم وسائل التشخيص لهذا المرض. أجريت هذه الدراسة في عيادة خاصة بشارع الحوادث داخل ولاية الخرطوم على عينة من المرضى تتكون من 54 مريض منهم 40 ذكر و14 أنثى في الفترة ما بين 2008-2013 وتتراوح فئاتهم العمرية بين 1-90 عام، وقد تم إجراء هذه الدراسة لتقييم دور الموجات فوق الصوتية في تشخيص وعلاج خراج الكبد. تبدأ عملية السحب بعمل موجات العادية (B-mode) للبطن لتحديد حجم وموقع الخراج، بعد ذلك يتم تعقيم جهاز الموجات وتعقم بطن المريض بكاملها مع التركيز على مكان الخراج، بعد ذلك يحقن المريض مقدار 5 سنتيمترات مكعبة من المخدر الموضعي ويتم السحب تحت إشراف الموجات الصوتية. تم تحليل جميع المعلومات المدخلة إحصائياً باستخدام الحاسوب بواسطة برنامج الإكسل (Excel) وبرنامج الحزمة الإحصائية للعلوم الاجتماعية (SPSS). وبعد إجراء الدراسة تبين أن الذكور أكثر تعرضاً من الإناث وأن الفص الأيمن أكثر تأثراً من الأيسر. ما يميز شكل للخراج في صورة الموجات فوق الصوتية؛ أنه عبارة عن كيس غامض اللون ذو حدود واضحة وجدار سميك، وبعد عملية السحب يتبين أنه في أغلب الحالات يحتوي على سائل أصفر اللون وبعد تحليله معملياً تظهر النتائج أن الغالبية العظمى من الحالات هي عبارة عن صديد قيحي (pyogenic abscess).

## TABLE OF CONTENTS

---

|                              |      |
|------------------------------|------|
| DEDICATIONS.....             | II   |
| Acknowledgements .....       | III  |
| Abstract.....                | IV   |
| ملخص الدراسة.....            | V    |
| List of tables.....          | VIII |
| List of figures.....         | IX   |
| List of abbreviations.....   | X    |
| Chapter 1.....               | 1    |
| Introduction: .....          | 2    |
| Problem: .....               | 4    |
| Objectives: .....            | 5    |
| Material and methods: .....  | 6    |
| Overview of the study: ..... | 7    |
| Chapter 2:.....              | 8    |
| Liver anatomy.....           | 9    |
| Functions of the liver:..... | 20   |
| Liver Tests.....             | 22   |
| Liver disease: .....         | 24   |
| Liver Abscess .....          | 26   |
| Previous studies:.....       | 35   |
| Chapter 3:.....              | 41   |
| Methodology.....             | 42   |
| Study design:.....           | 42   |
| Study period and area: ..... | 42   |
| Patients:.....               | 42   |
| Machine used:.....           | 42   |
| Other materials needs:.....  | 42   |
| Technique:.....              | 43   |
| Data analysis method: .....  | 43   |
| Chapter 4:.....              | 44   |
| Results:.....                | 45   |
| Chapter 5.....               | 62   |

|                      |    |
|----------------------|----|
| Discussion: .....    | 63 |
| Conclusion:.....     | 65 |
| Recommendations..... | 66 |
| References:.....     | 67 |
| Appendiges.....      | 68 |

## LIST OF TABLES

---

|   |    |
|---|----|
| Table 4-1 Shows gender distribution and percentages .....   | 45 |
| Table 4-2 Shows age distribution and percentages .....  | 46 |
| Table 4-3 Shows group affected lobe site .....  | 47 |
| Table 4-4 Shows type of abscess echogenicity .....  | 48 |
| Table 4-5 Shows the margins of the abscess .....  | 49 |
| Table 4-6 Shows the wall thickness of the abscess .....   | 50 |
| Table 4-7 Shows the amount of abscess that was aspirated .....  | 51 |
| Table 4-8 Shows the color of the abscess after aspiration .....                                       | 52 |
| Table 4-9 Shows the relation between gender and lobe site. ....                                       | 55 |
| Table 4-10 Shows the relation between age and lobe site.....  | 56 |
| Table 4-11 Shows the relation between echogenicity of the abscess and the color of the aspirate ..... | 57 |
| Table 4-12 Shows the relation between the wall of the abscess and aspirate color .....                | 58 |
| Table 4-13 Shows the relation between the margins of the abscess and aspirate color . ....            | 59 |
| Table 4-14 Shows the relation between the margins of the abscess and its echogenicity. ....           | 60 |

## LIST OF FIGURES

---

|   |    |
|---|----|
| Figure 4-1 Scatter plot shows the linear association between the size and volume of the liver abscess with a trend line shows a direct linear proportional relationship. ....             | 53 |
| Figure 4-2 Scatter plot shows the linear association between the volume of the abscess and the age of the patient with a trend line shows a direct linear proportional relationship. .... | 54 |

## LIST OF ABBREVIATIONS

---

|             |                     |
|-------------|---------------------|
| <b>AO:</b>  | Abdominal aorta     |
| <b>CBD:</b> | Common bile duct    |
| <b>CT:</b>  | Computed tomography |
| <b>GB:</b>  | Gall bladder        |
| <b>HA:</b>  | Hepatic artery      |
| <b>HV:</b>  | Hepatic vein        |
| <b>IVC:</b> | Inferior vena cava  |
| <b>NO:</b>  | Number              |
| <b>PV:</b>  | Portal vein         |
| <b>US:</b>  | Ultrasound          |

# CHAPTER 1:

---

Introduction

Problem

Objective

Material and methods

Overview of the study

## INTRODUCTION:

---

A liver abscess is a pus-filled cavity within the liver, usually caused by a biliary tract source, portal venous system, and abdominal trauma. Occasionally, multiple cavities are seen. It is almost uniformly fatal if left untreated. Sudan is one of the endemic areas of liver abscess.

Ultrasound is the most commonly used imaging technique for diagnosis of liver abscess. It offers a high sensitivity and specificity in diagnosis, though it cannot differentiate between the types of abscess. The only methods that give us the definitive diagnosis are the laboratory tests.

There are several types of ultrasound-guided procedures done in the liver; those are:

1. Diagnostic purposes: for solid and cystic lesions, either this lesion is primary or secondary, in this procedure we will use percutaneous ultrasound guided fine needle aspiration.
  2. Diagnostic-therapeutic purposes: for aspiration of cyst or abscess, in this we do a percutaneous drainage.
  3. Therapeutic purposes: for tumor ablation.
- In this research, the author intended to study both diagnostic & diagnostic-therapeutic purposes.
  - Those two procedures are very useful for giving both doctor and patient a full answer about patient condition, also it avoids patient from hazard of general surgery and anesthesia in a much less expensive manner.



- As we know the liver is a vital organ and it has a wide range of functions, also, it supports most of the organs in the body, and the liver is prone to many diseases, so in this study we would concentrate on the liver abscess.

## PROBLEM:

---

In Sudan, liver abscess is relatively common infectious disease, so we need to know the typical characteristics of liver abscess on gray scale. and all those procedures have been newly introduced in the past 2 decades, so in this research we would like to concentrate on ultrasound guided percutaneous drainage of the liver abscess, and to see the usefulness of it in both diagnostic & therapeutic purposes of liver abscess, And assess the complication rate.

## OBJECTIVES:

---

- **General:**

To assess the role of the ultrasound in diagnosis and treatment of liver abscess.

- **Specific:**

1. To determine the accuracy of the ultrasound in diagnosis of the liver abscess.
2. To identify the role of the ultrasound guided percutaneous drainage in both diagnosis and treatment of liver abscess.
3. To evaluate the safety of the ultrasound guided of per cutaneous drainage in the managements of the liver abscess.
4. To determine volume aspirated using the ultrasound size.
5. To investigate the association of age with volume of abscess.

## MATERIAL AND METHODS:

---

- The study was retrospective and prospective views at a private clinic at Khartoum Hospital Street. All patients who came for ultrasound guided liver abscess drainage between 2008-to present were recruited.
- All data collected were tabulated and analyzed using the statistical package for social sciences (SPSS) version 20 as well as Microsoft Excel 2007.

## OVERVIEW OF THE STUDY:

---

This study will help physician, doctors and sonologists know about the characteristics of the liver abscess on gray scale and the usefulness of ultrasound in both diagnosis and treatment of the liver abscess.

- **Chapter 1**: introduction, problem of the study, objectives of the study and overview of the study.
- **Chapter 2**: literature review: (2 parts):
  - Part1: brief anatomy, physiology, pathology of the liver and we will concentrate on liver abscess+ clinical presentations of patient with liver abscess +the procedure and the equipment.
  - Part2: previous studies
- **Chapter 3**: Materials and methods of data collection (methodology)
- **Chapter 4**: Deals with data presentation and results.
- **Chapter 5**: 2 parts:
  - Part 1: Discussion.
  - Part2: Conclusion and recommendations.

# CHAPTER 2:

---

## Literature review

Liver anatomy

Functions of the liver

Liver Tests

Liver disease

Liver Abscess

Previous studies

---

## LIVER ANATOMY

---

The liver is a roughly triangular organ that extends across the entire abdominal cavity just inferior to the diaphragm. Most of the liver's mass is located on the right side of the body where it descends inferiorly toward the right **kidney**. The liver is made of very soft, pinkish-brown tissues encapsulated by a connective tissue capsule. This capsule is further covered and reinforced by the peritoneum of the abdominal cavity, which protects the liver and holds it in place within the abdomen.

The peritoneum connects the liver in 4 locations: the coronary ligament, the left and right triangular ligaments, and the falciform ligament. These connections are not true ligaments in the anatomical sense; rather, they are condensed regions of peritoneal membrane that support the liver.

- The wide CORONARY LIGAMENT connects the central superior portion of the liver to the diaphragm.
- Located on the lateral borders of the left and right lobes, respectively, the LEFT and RIGHT TRIANGULAR LIGAMENTS connect the superior ends of the liver to the diaphragm.
- The FALCIFORM LIGAMENT runs inferiorly from the diaphragm across the anterior edge of the liver to its inferior border. At the inferior end of the liver, the falciform ligament forms the round ligament (ligamentum teres) of the liver and connects the liver to the umbilicus. The round ligament is a remnant of the umbilical vein that carries blood into the body during fetal development.

The liver consists of 4 distinct lobes – the left, right, caudate, and quadrate lobes.

- The left and right lobes are the largest lobes and are separated by the falciform ligament. The **right lobe** is about 5 to 6 times larger than the tapered left lobe.
- The small **caudate lobe** extends from the posterior side of the right lobe and wraps around the inferior vena cava.
- The small **quadrate lobe** is inferior to the caudate lobe and extends from the posterior side of the right lobe and wraps around the gallbladder.

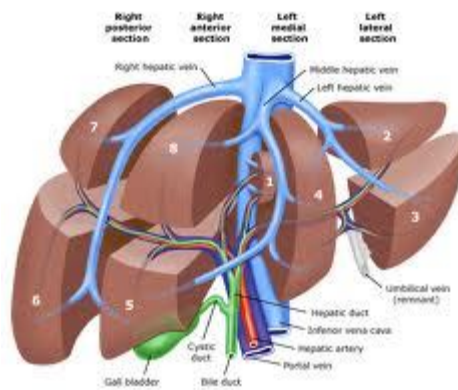


Figure 2.1

## Bile Ducts

The tubes that carry bile through the liver and **gallbladder** are known as bile ducts and form a branched structure known as the biliary tree. Bile produced by liver cells drains into microscopic canals known as bile canaliculi. The countless bile canaliculi join together into many larger bile ducts found throughout the liver.

These bile ducts next join to form the larger left and right **hepatic ducts**, which carry bile from the left and right lobes of the liver. Those two hepatic ducts join to form the common hepatic duct that drains all bile away from the liver. The common hepatic duct finally joins with the cystic duct from the gallbladder to form the **common bile duct**, carrying bile to the duodenum of the small intestine. Most



of the bile produced by the liver is pushed back up the cystic duct by peristalsis to arrive in the gallbladder for storage, until it is needed for digestion.

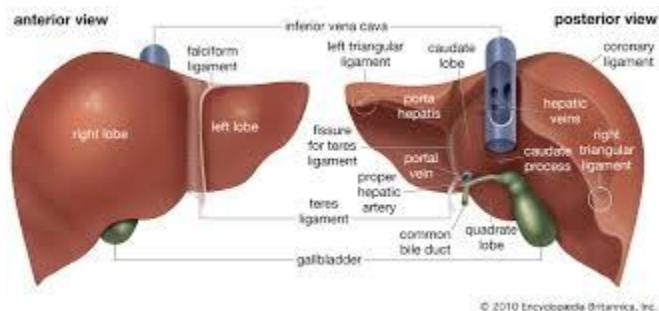


Figure 2.2

## Blood Vessels

The blood supply of the liver is unique among all organs of the body due to the hepatic portal vein system. Blood traveling to the **spleen, stomach, pancreas, gallbladder, and intestines** passes through capillaries in these organs and is collected into the **hepatic portal vein**. The hepatic portal vein then delivers this blood to the tissues of the liver where the contents of the blood are divided up into smaller vessels and processed before being passed on to the rest of the body. Blood leaving the tissues of the liver collects into the **hepatic veins** that lead to the **vena cava** and return to the **heart**. The liver also has its own system of arteries and arterioles that provide oxygenated blood to its tissues just like any other organ.

## Lobules

The internal structure of the liver is made of around 100,000 small hexagonal functional units known as lobules. Each lobule consists of a central vein surrounded by 6 hepatic portal veins and 6 hepatic arteries. These blood vessels are connected by many capillary-like tubes called **sinusoids**, which extend from the portal veins and arteries to meet the central vein like spokes on a wheel.

Each sinusoid passes through liver tissue containing 2 main cell types: Kupffer cells and hepatocytes.

- KUPFFER CELLS are a type of macrophage that capture and break down old, worn out red blood cells passing through the sinusoids.
- HEPATOCYTES are cuboidal epithelial cells that line the sinusoids and make up the majority of cells in the liver. Hepatocytes perform most of the liver's functions – metabolism, storage, digestion, and bile production. Tiny bile collection vessels known as bile canaliculi run parallel to the sinusoids on the other side of the hepatocytes and drain into the bile ducts of the liver

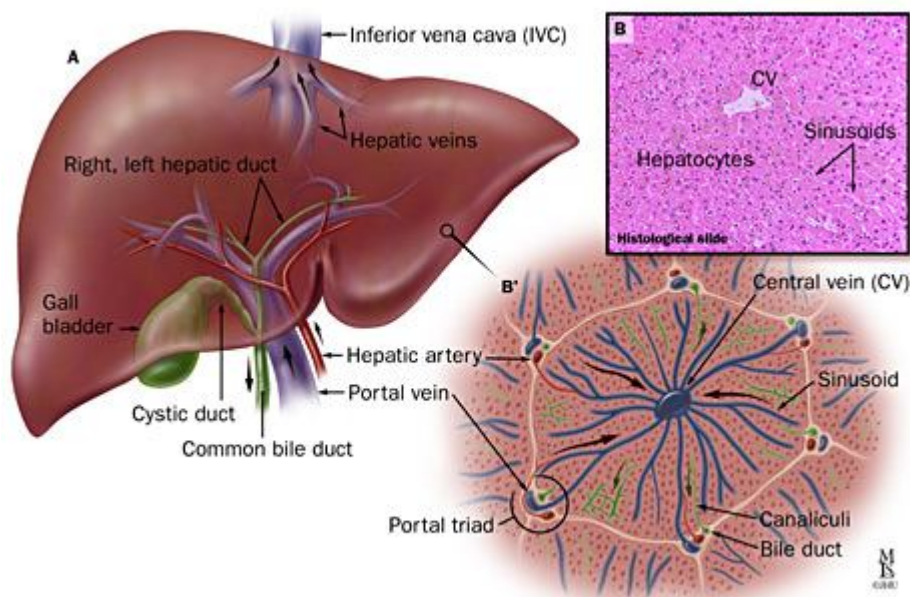


Figure 2.3

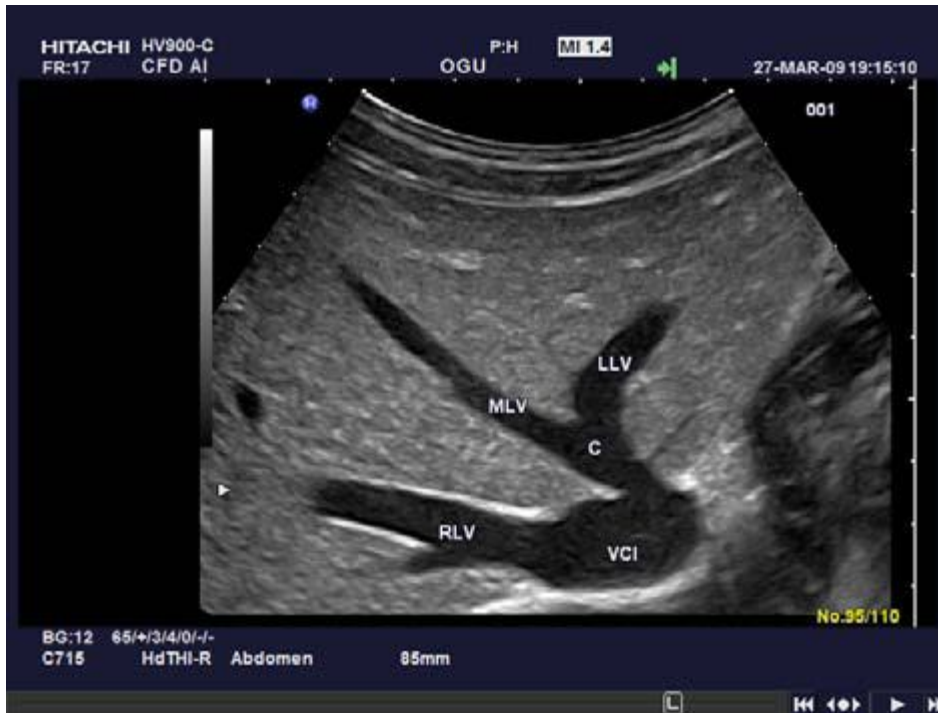### **Normal ultrasound appearance of the liver:**

The liver is a large, pyramidal shaped organ and liver sectional anatomy may be best

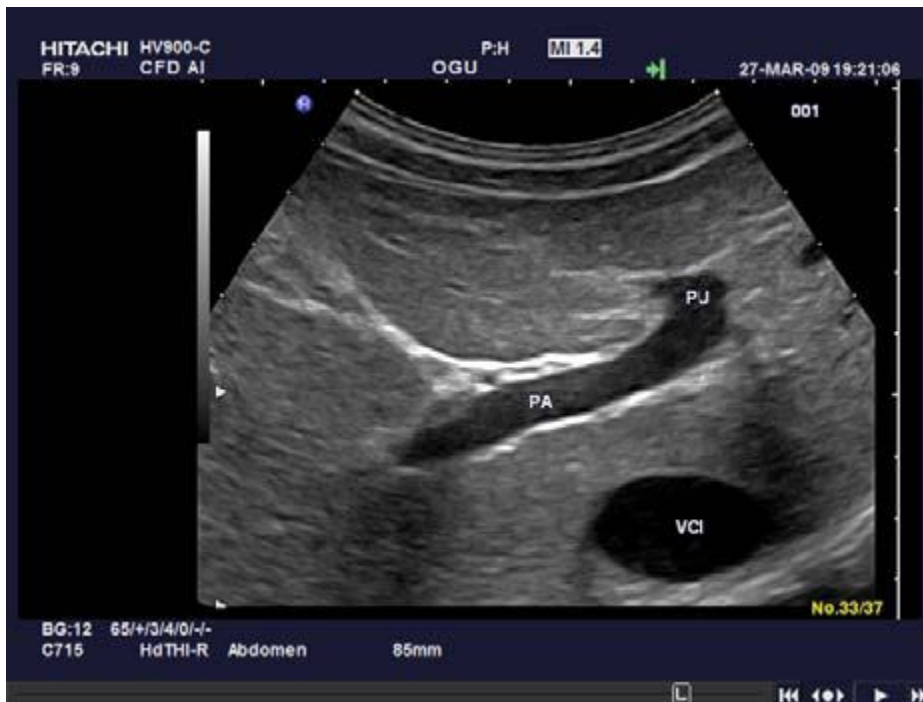described imaged and defined using by real time ultrasound imaging. Conventional real time ultrasound produces images of thin slices of the liver on the screen, and so it is essential that the operator scans the entire organ systematically/ritually, in at least two anatomical planes, to be entirely convinced that the entire volume of the liver tissue and structures has been imaged. The operator must then synthesise this 2 dimensional information in their brain to develop a 3 dimensional map of the individual patient's liver anatomy and pathology. This requires good hand-eye-brain coordination. For orientation, three levels of the central portion of the liver can be differentiated:

- Level of the Confluences of the liver veins [Figure 2.4].
- Level of the Pars umbilicalis of the (left) portal vein branch [Figure 2.5].
- Level of the gall bladder [Figure 2.6].

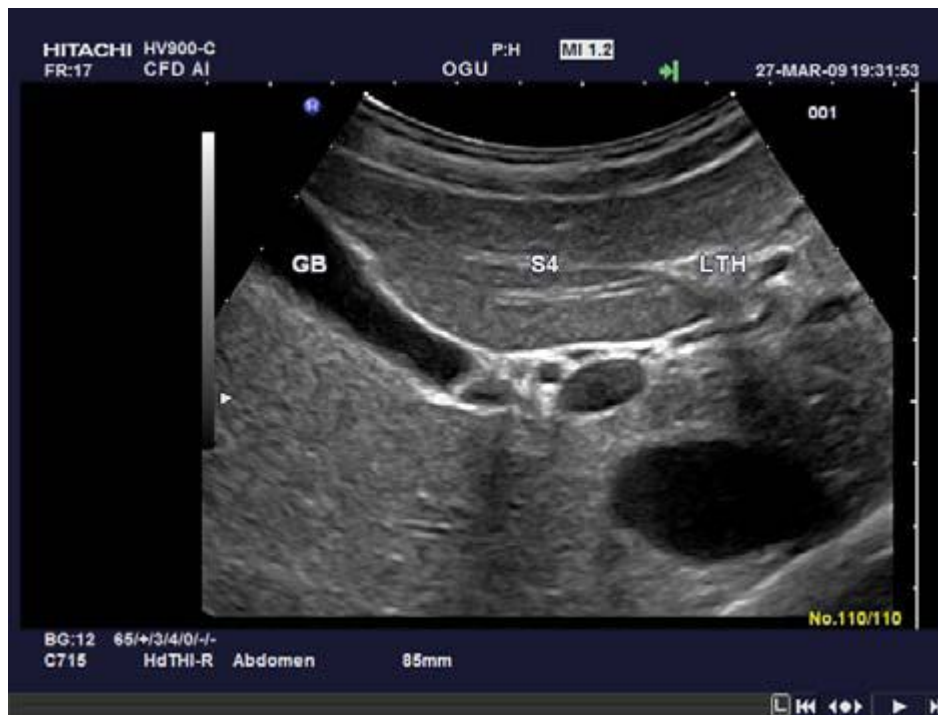**Figure 2.4** Confluences of the liver veins. This “junction” level is the first one in ultrasound examination of the right liver lobe by subcostal scanning sections steeply “looking” upwards, preferably in deep inspiration [video]. VCI: inferior vena cava. LLV: Left liver vein. MLV: Middle liver vein. C: Confluences of the LLV and MLV. RLV: Right liver vein. The RLV often separately joins the inferior vena cava, whereas the LLV and MLV often reveal a common trunk (“C”).



**Figure 2.5** “Pars umbilicalis” of the portal vein – scanning planes display the left and right liver lobes in a more downwards orientated view into the right liver lobe as compared to the level of the confluens of the liver veins. PA: Portal vein. PU: parsumbilicalis of the portal vein. IVC: Inferior vena cava.



**Figure 2.6** Gallbladder level as the most caudate scanning plane. GB: Gallbladder. LTH: Ligamentum teres hepatis. S4: Segment IV of the liver (quadrate lobe).



Analysing the ultrasound examination, these levels mean the access for a number of (more or less) parallel scanning sections, which in their summary in the examiner's brain form a real time three dimensional ("4D") copy of the given patient's individual anatomy and pathology.

Standardised scanning in a ritualized sequence of probe- and patient positions and of scanning planes is mandatory to cover all segments and the complete liver surface.

The patient should be examined from sub- and intercostally in the decubitus position as well in modified slightly oblique positions with the right arm above the head and the right leg stretched during all respiration cycles to identify the best approach and to avoid artifacts caused by the thorax. Examination in the standing position is additionally helpful due to its weight, the liver moves caudally by gravity, and scanning from sub- or intercostal probe positions – according to the individual anatomy - avoids the interposed lung which is mainly true for the right

posterolateral(superficial) parts of the liver using the intercostal approach. Other examination techniques have also been described but are not mentioned here in detail which might be additionally used.

A great number of variants of the normal has to be encountered – e.g. with respect to accessory lobules, vascular branching, shape and configuration.

### ***Examination criteria***

An acronym has shown to be didactically helpful [“SSOTM”]:

- S = size
- S = shape
- O = outline
- T = texture
- M = measurement

### ***Size***

The size of the liver has been measured by many methods, including 3D-reconstructions. Liver size measurement has no impact in daily routine because there is no reliable and reproducible ultrasound method established so far.

### ***Shape***

Normally described as pyramidal.

### ***Outline***

The normal liver surface should be smooth with no lumps protruding or indentations.

The inferior liver border in the normal patient should have an acute angled edge.

Liver surface border delineation and other ultrasound criteria: Other ultrasound criteria are described in the respective chapters.

### ***Texture, echogenicity***

The normal liver parenchyma is of medium homogenous echogenicity, usually slightly darker than the spleen and slightly brighter than the renal cortex

independently of the age except in childhood . It is essential when comparing the liver with the spleen and renal cortex that the comparison is done at the same depth. Liver surface and vessels borders are smooth and vascular architecture with its classic dichotomy in branching is perceived as a harmonic and detailed aspect. The image of the normal parenchyma varies very little among individuals.

### ***Liver veins***

The three liver veins are positioned in between the liver segments. Their course - additionally to the Glisson`s triad - is helpful in defining liver lobes and liver segments. Number and course of liver veins is somewhat variable [Figure 2.11].

### ***Portal vein***

Formed by the confluents of the splenic and superior mesenteric vein, the portal vein can be sonographically displayed using scans more or less perpendicular to the lower costal margin (orientation might be achieved referring from the right shoulder to the umbilicus), preferably in a left decubitus position and in variably deep inspiration.

Intrahepatically, the portal vein bifurcates into a main left and right branch. The first(right) portal vein branch splits into an anterior and into a posterior branch, which itself leads to the segments V – VIII. The latter (left) main portal branch bifurcates into segments II and III and, additionally, into the left medial branches for segments I(caudate lobe), IVa and Ivb [Figure 2.12].

### ***Hepatic artery***

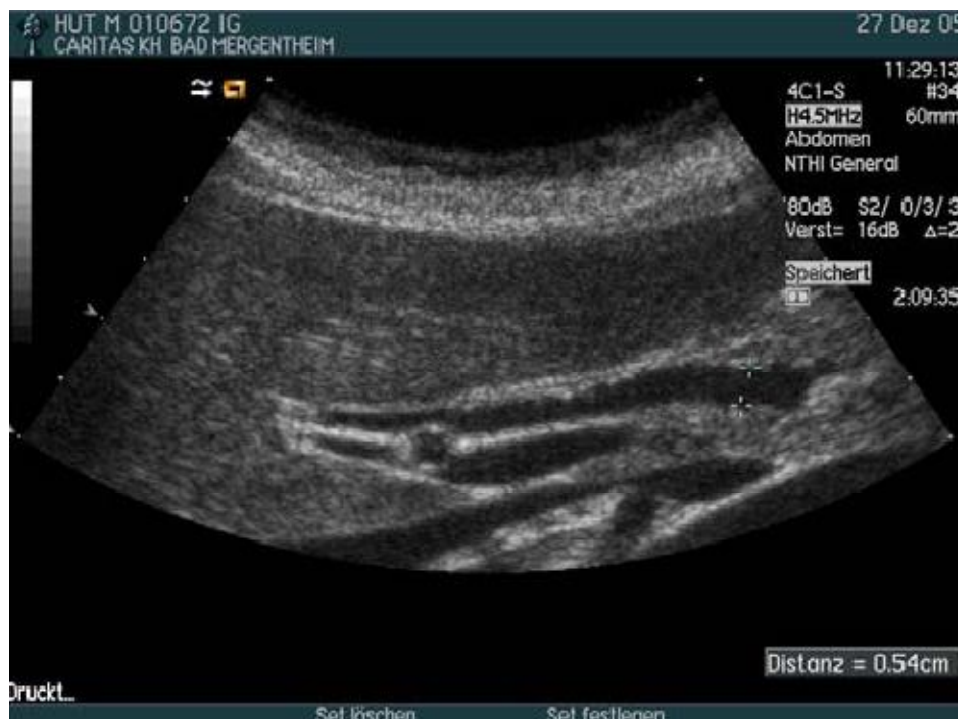The common hepatic artery has its source from the celiac axis, branching into the gastroduodenal artery and into the proper hepatic artery (arteria hepatica propria). Anatomical variations are frequent (in up to 50 %), e.g. the origin of the left proper hepatic artery out of the left gastric artery as well as the variable arterial supply of the liver by superior mesenteric artery branches. The hepatic artery runs with the portal vein, the right main arterial branch frequently meandering around the portal

veinsonographically displayed in short segments medially (or less often laterally) of the portal vein. The normal and pathological flow patterns are described below in the Doppler chapter.

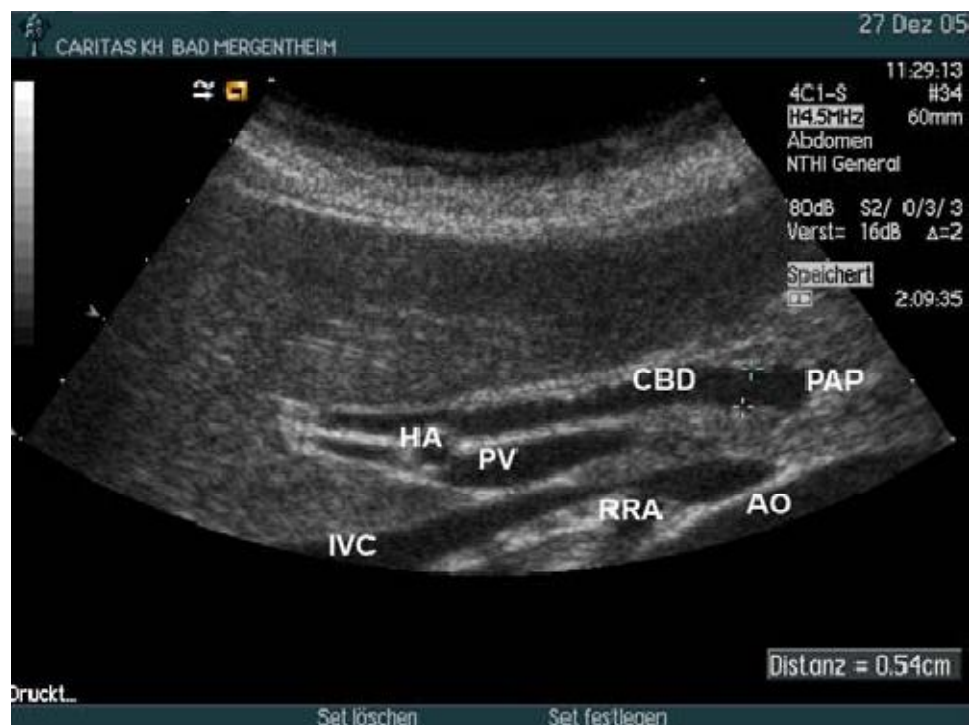
### ***Bile ducts***

Bile ducts accompany the portal vein and hepatic artery branches from the liver hilum into the liver lobules, intrahepatically forming the ductus principalis dexter and the ductus principalis sinister, which join as common bile duct (CBD). The extrahepatic course of the CBD is cranially (pre-pancreatic) often ventral to the portal vein and caudally (intrapancreatic) more dorsolateral. The respective course of the hepatic artery is more variable [Figure 2.7].

**Figure 2.7** Common bile duct (CBD). The CBD, and therefore, the liver hilum, is often best examined in a left lateral decubitus position using a subcostal approach in slight inspiration [video]. In the typical view CBD (in between markers), portal vein (PV), hepatic artery (HA), inferior vena cava (IVC) and right renal artery (RRA) (and sometimes also the aorta [AO]) can be seen; the papilla region (PAP) is indicated.







---

## FUNCTIONS OF THE LIVER:

---

The liver regulates most chemical levels in the blood and excretes a product called bile, which helps carry away waste products from the liver. All the blood leaving the stomach and intestines passes through the liver. The liver processes this blood and breaks down the nutrients and drugs into forms that are easier to use for the rest of the body. More than 500 vital functions have been identified with the liver. Some of the more well-known functions include the following:

- Production of bile, which helps carry away waste and break down fats in the small intestine during digestion
- Production of certain proteins for blood plasma
- Production of cholesterol and special proteins to help carry fats through the body
- Conversion of excess glucose into glycogen for storage (glycogen can later be converted back to glucose for energy)
- Regulation of blood levels of amino acids, which form the building blocks of proteins
- Processing of hemoglobin for use of its iron content (the liver stores iron)
- Conversion of poisonous ammonia to urea (urea is an end product of protein metabolism and is excreted in the urine)
- Clearing the blood of drugs and other poisonous substances
- Regulating blood clotting

Other functions:

- The liver stores a multitude of substances, including glucose (in the form of glycogen), vitamin A (1–2 years' supply), vitamin D (1–4 months' supply), vitamin B12 (1–3 years' supply), vitamin K, iron, and copper.

- The liver is responsible for immunological effects—the reticuloendothelial system of the liver contains many immunologically active cells, acting as a 'sieve' for antigens carried to it via the portal system.
- The liver produces albumin, the major osmolar component of blood serum.
- The liver synthesizes angiotensinogen, a hormone that is responsible for raising the blood pressure when activated by renin, an enzyme that is released when the kidney senses low blood pressure.
- Resisting infections by producing immune factors and removing bacteria from the bloodstream

When the liver has broken down harmful substances, its by-products are excreted into the bile or blood. Bile by-products enter the intestine and ultimately leave the body in the form of feces. Blood by-products are filtered out by the kidneys, and leave the body in the form of urine.

The liver can lose three-quarters of its cells before it stops functioning. In addition, the liver is the only organ in the body that can regenerate itself.

---

## LIVER TESTS

---

### Blood Tests:

- Liver function panel: A liver function panel checks how well the liver is working and consists of many different blood tests.
- ALT (Alanine Aminotransferase): An elevated ALT helps identify liver disease or damage from any number of causes, including hepatitis.
- AST (Aspartate Aminotransferase): Along with an elevated ALT, the AST checks for liver damage.
- Alkaline phosphatase: Alkaline phosphatase is present in bile-secreting cells in the liver; it's also in bones. High levels often mean bile flow out of the liver is blocked.
- Bilirubin: High bilirubin levels suggest a problem with the liver.
- Albumin: As part of total protein levels, albumin helps determine how well the liver is working.
- Ammonia: Ammonia levels in the blood rise when the liver is not functioning properly.
- Hepatitis A tests: If hepatitis A is suspected, the doctor will test liver function as well as antibodies to detect the hepatitis A virus.
- Hepatitis B tests: Your doctor can test antibody levels to determine if you have been infected with the hepatitis B virus.
- Hepatitis C tests: In addition to checking liver function, blood tests can determine if you have been infected with the hepatitis C virus.
- Prothrombin Time (PT): A prothrombin time, or PT, is commonly done to see if someone is taking the correct dose of the blood thinner warfarin (Coumadin). It also checks for blood clotting problems.

- Partial Thromboplastin Time (PTT): A PTT is done to check for blood clotting problems.

#### Imaging Tests:

- Ultrasound: An abdominal ultrasound can test for many liver conditions, including cancer, cirrhosis, or problems from gallstones.
- CT scan (computed tomography): A CT scan of the abdomen gives detailed pictures of the liver and other abdominal organs.
- Liver biopsy: A liver biopsy is most commonly done after another test, such as a blood test or ultrasound, indicates a possible liver problem.
- Liver and spleen scan: This nuclear scan uses radioactive material to help diagnose a number of conditions, including abscesses, tumors, and other liver function problems.

---

## LIVER DISEASE:

---

Liver disease is any disturbance of liver function that causes illness.

There are more than a hundred kinds of liver disease

- Hepatitis, inflammation of the liver, is caused mainly by various viruses (viral hepatitis) but also by some liver toxins (e.g. alcoholic hepatitis), autoimmunity (autoimmune hepatitis) or hereditary conditions.
- Alcoholic liver disease is any hepatic manifestation of alcohol overconsumption, including fatty liver disease, alcoholic hepatitis, and cirrhosis. Analogous terms such as "drug-induced" or "toxic" liver disease are also used to refer to the range of disorders caused by various drugs and environmental chemicals.
- Fatty liver disease (hepatic steatosis) is a reversible condition where large vacuoles of triglyceride fat accumulate in liver cells. Non-alcoholic fatty liver disease is a spectrum of disease associated with obesity and metabolic syndrome, among other causes. Fatty liver may lead to inflammatory disease (i.e. steatohepatitis) and, eventually, cirrhosis.
- Cirrhosis is the formation of fibrous tissue (fibrosis) in the place of liver cells that have died due to a variety of causes, including viral hepatitis, alcohol overconsumption, and other forms of liver toxicity. Cirrhosis causes chronic liver failure.
- Primary liver cancer most commonly manifests as hepatocellular carcinoma and/or cholangiocarcinoma; rarer forms include angiosarcoma and hemangiosarcoma of the liver. (Many liver malignancies are secondary lesions that have metastasized from primary cancers in the gastrointestinal tract and other organs, such as the kidneys, lungs, breast, or prostate.)

- Primary biliary cirrhosis is a serious autoimmune disease of the bile capillaries.
- Primary sclerosing cholangitis is a serious chronic inflammatory disease of the bile duct, which is believed to be autoimmune in origin.
- Budd–Chiari syndrome is the clinical picture caused by occlusion of the hepatic vein, which in some cases may lead to cirrhosis.
- Hereditary diseases that cause damage to the liver include hemochromatosis, involving accumulation of iron in the body, and Wilson's disease, which causes the body to retain copper. Liver damage is also a clinical feature of alpha 1-antitrypsin deficiency and glycogen storage disease type II.
- In transthyretin-related hereditary amyloidosis, the liver produces a mutated transthyretin protein which has severe neurodegenerative and/or cardiopathic effects. Liver transplantation can provide a curative treatment option.
- Gilbert's syndrome, a genetic disorder of bilirubin metabolism found in about 5% of the population, can cause mild jaundice.

There are also many pediatric liver diseases including: biliary atresia, alpha-1 antitrypsin deficiency, Alagille syndrome, and progressive familial intrahepatic cholestasis.

---

## LIVER ABSCESS

---

- A liver abscess is a collection of pus in the liver caused by bacteria, fungi, or parasites. It may occur as a single lesion or as multiple lesions of different sizes. The abscess may contain thick, bad smelling pus or reddish-brown anchovy paste-like fluid with no odor.
- The liver is in the upper right side of the abdomen (stomach). It is located just below the right lung and behind the ribs. The liver does many things to help your body function well. It makes enzymes and bile that help digest food and removes harmful material from the blood. It stores and gives energy when you need it. The liver also cleans foreign things from the body, such as drugs, alcohol, and other chemicals. With treatment and care, your abscess may be cured and serious problems may be prevented.

### Causes of liver abscess

- **Bacteria:** A liver abscess may be caused by different bacteria (germs). The bacteria may be from infections in another part of the body. These may include infections in the abdomen, heart, or mouth. The bacteria may reach the liver through the blood or bile ducts. The bile ducts are tubes where bile passes in and out of the liver. A liver abscess most often comes from infection of the bile ducts caused by gallstones, infections in the intestines, or appendicitis. Bacteria may also enter during a direct trauma to the liver or during procedures involving the liver.
- **Parasite:** An infection by a parasite (bug), most commonly by an ameba, may also cause a liver abscess. This infection, also called amebiasis, is common in



overcrowded areas with poor sanitation. You can get this parasite by eating or drinking contaminated (dirty) food or water.

- **Fungus:** In very few cases, liver abscess may be caused by a fungus or other infectious organism. These are organisms which usually cause problems when the immune system becomes weak. The immune system is the part of your body that fights infection.

### **Risk factors:**

The following conditions and factors may make you more likely to develop a liver abscess:

- **Activity:** Traveling to places where amebiasis is common. Eating foods and drinking liquids that are sold in the street may further increase your risk.
- **Age:** Advanced age, particularly in people older than 70 years old.
- **Health:** Having a long-term disease, such as cancer, diabetes, tuberculosis, or syphilis, or had surgery to remove the spleen. Having a weak immune system, such as organ transplant or AIDS patients. Taking steroids, chemotherapy, or anti-rejection medicines.
- **Lifestyle:** Drinking too much alcohol, too often. Alcohol is found in beer, wine, liquor (such as vodka or whiskey), and other adult drinks.
- **Nutrition:** Being malnourished (having poor nutrition).

### **Signs and symptoms of liver abscess:**

You may have any of the following:

- Abdominal pain, mostly in the upper right part of the abdomen just below the ribs.
- Cough or trouble breathing.
- Feeling more tired and weak than usual.
- Fever and night sweats.
- Losing weight without trying.
- Loss of appetite for food, nausea (upset stomach), or vomiting (throwing up).
- Yellowing of the skin or the whites of the eyes.

### **Diagnosis of liver abscess:**

Your caregiver will take a detailed health history from you, including diseases or procedures you may have had. This also includes information about your past travels or past residences if you just moved in. You may need any of the following tests:

- **Blood tests:** You may need blood taken to give caregivers information about how your body is working. The blood may be taken from your hand, arm, or IV. Complete blood picture (CBC), Liver function test (LFT), Renal function test (RFT), Urine general (UG).
- **Computerized tomography scan:** This is also called a CT scan. A special x-ray machine uses a computer to take pictures of your abdomen, including your liver. You may be given dye through an IV before the pictures are taken so that your organs show clearly. People who are allergic to iodine or shellfish (lobster,

crab, or shrimp) may be allergic to some dyes. Tell your caregiver if you are allergic to shellfish or have other allergies or health problems.

- **Liver scan:** This is a test to look at your liver. You are given a small amount of dye in your IV. Pictures are then taken by a special scanner that can see the dye in your body. The dye soaks up more in abnormal areas of the liver.
- **Magnetic resonance imaging test:** This test is also called an MRI. It uses magnetic waves to look at the liver. You will need to lie still during an MRI. **Never** enter the MRI room with an oxygen tank, watch, or any other metal objects. This can cause serious injury.
- **Ultrasound:** This is a test that uses sound waves to look inside of your body. Pictures are shown on a TV-like screen. Caregivers may do an abdominal ultrasound to see your liver and other organs in the abdomen. A doppler ultrasound study may be done to check for blood flow in your liver. Caregivers may be able to look for clots or other problems in the veins during this test.
- **X-rays:** X-rays of different parts of your body may be taken. These may include your abdomen (stomach) or chest (lungs and heart).

## **Treatment of liver abscess:**

Your liver abscess may be treated with any of the following:

- **Medicines:**
  - **Antibiotics:** This medicine is given to help treat or prevent an infection caused by bacteria.
  - **Antifungal medicine:** This medicine helps kill fungus that can cause illness. like metronidazole

- **Antiparasitic medicine:** This medicine may be given to kill parasites. Parasites are living things that feed or eat off of other living things.
- **Procedures:**
  - **Catheter drainage:** Caregivers make an incision (cut) into your abdomen, over your liver. With an ultrasound or CT as guide, a catheter (tube) is inserted in the cut and into the abscess. Draining the abscess may clean out any pus in your abdomen. The incision will be closed with thread or staples. The catheter may be sutured (sewn) to the skin to prevent it from moving. The catheter may need to be flushed with a saline (salt-water) solution once in a while.
  - **Needle aspiration:** Caregivers may do a needle aspiration to suck the fluid out of the abscess. With an ultrasound or CT as guide, a needle is put through your skin over your liver and into the abscess. The fluid is removed and sent to the lab for tests.
  - **Surgery:** Surgery to open your abdomen may be done if other forms of treatment have failed. It may be done if the abscess is very large or if there are multiple abscesses. Caregivers may also do surgery to look for and correct problems inside your abdomen. This may include removing bile duct stones or cleaning pus if the abscess burst.

**In this study we are dealing with ultrasound guided aspiration of the liver abscess. In Sudan.**

**Ultrasound guided percutaneous drainage** is one form of the imaging guided procedures, allowing minimally invasive treatment of collections that are accessible by ultrasound study.

It has several advantages and disadvantages over CT, which include:

### **Advantages**

- It is a dynamic study, allowing greater precision to control needle insertion.
- It does not expose patient to ionizing radiation.
- It does not require a wider range of staff to undertake compared to CT.

### **Disadvantages**

- Limitation on accessing deep areas, which are not well visualized on ultrasound.
- Vision could be obscured by gases.
- Attenuation of the sound beam on larger patients.

### **Indications**

Indications for percutaneous drainage are broad: essentially any abnormal fluid collection in the patient, which can be accessible. Examples include:

- Complicated diverticular abscess
- Crohn's disease related abscess
- Complicated appendicitis by appendicular abscess
- Localized abscess related to ovary (tuboovarian abscess)
- Abscess collection after surgery
- Hepatic abscess (e.g. amebic or post-operative)
- Renal abscess or retro-peritoneal abscess.
- Splenic abscess
- Failure of medical treatments (common cause in sudan)

## Contraindications

The only common contraindications are:

- abscess is not accessible
- patient has a bleeding tendency

## Procedure

Laboratory parameters for a safe procedure

Interventional procedures like percutaneous drainage require special attention to coagulation indices.

Complete blood count: Platelet  $> 50000/\text{mm}^3$  (Some institutions determine other values between 50000 -100000/ $\text{mm}^3$ )

Coagulation profile: Some studies showed that having a normal INR or prothrombin time is no reassurance that the patient will not bleed after the procedure

- International normalized ratio (INR)  $\leq 1.5$  <sup>1</sup>
- Normal prothrombin time (PT), partial thromboplastin time (PTT)

## Pre-procedure evaluation

Review other diagnostic studies first to clarify the collection that is requested to be drained, as well a ultrasound study should be done prior to decide the access point and checks the collection relationship with adjacent structures. Prefer shortest possible route without traversing other structures

## Technique

Ultrasound guided percutaneous drainage may be performed with a single or multiple stage technique.

In the single stage technique the fluid collection is entered directly with a catheter, typically either 8 or 12F in size for a huge abscess.

We need also canula size 14-20G, and syringe size 20-60CC for a small size abscess.

The multiple step technique utilizes the modified Seldinger technique, whereby the abscess is entered with an introducer needle, through which a stiff wire is passed. The track is then expanded with a dilator or serial dilators, before the catheter is passed over the wire to gain the final position within the abscess. A locking drain is typically used to ensure a secure position. The catheter is then connected to an external drainage bag. That if the abscess is huge.

- But if the abscess is little bit small we can just drain it just through a needles.

## Post-procedure care

The patient's basic observations should be monitored for 4 hours (pulse, BP, SpO2), or as deemed necessary.

The patient should remain in bed for 2 hours. After this mobilization is permissible as it being able to eat and drink.

The entry site should be reviewed on a daily basis. Once the output from the collection ceases, re-imaging should be considered before removing the drainage catheter.

After the drain removed patient should be seen after 1 week for follow up.



---

## PREVIOUS STUDIES:

---

### **Study no. (1):**

Barrio J (2000)

Studied: Pyogenic liver abscesses of bacterial origin. A study of 45 cases.

#### OBJECTIVE:

to determine the clinical, microbiological, diagnostic and therapeutic characteristics of pyogenic liver abscesses of bacterial origin.

#### METHODS:

retrospective analysis of pyogenic liver abscesses diagnosed at the Aránzazu Hospital in San Sebastián (northern Spain) between 1989 and 1998.

#### RESULTS:

we studied 45 patients with pyogenic liver abscesses of bacterial origin (30 men, 15 women, mean age 61 years 11 months). The site of the liver abscess was biliary in 28.9% of the patients, portal in 11.1%, and unknown in 33.3%. Elevated erythrocyte sedimentation rate (95.5%), leukocytosis (86.7%) and fever (82.2%) were the most frequent clinical and laboratory findings. The abscesses were solitary in 55. 5% of the patients. Echography was diagnostic in 68.4% of patients, and computed tomography was diagnostic in 100%. Cultures of pus from the abscess and blood were positive in 77.1% and 50% respectively. Of the abscesses diagnosed as being of bacterial origin, 44.4% involved multiple organisms. *Escherichia coli* and *Streptococcus milleri* were the germs isolated most frequently. Percutaneous drainage was done in 22 patients (48.9%), with satisfactory results in 18. Overall mortality related with abscesses was 15.5%.

## CONCLUSIONS:

the clinical presentation of pyogenic liver abscess did not vary during the study period. Computed tomography is fundamental for diagnosis and treatment.

Percutaneous drainage associated with early antibiotic therapy is the treatment of choice.

## **Study no. (2):**

Cosme A et al (2010)

Studied: Pyogenic versus amoebic liver abscesses. A comparative clinical study in a series of 58 patients.

### OBJECTIVE:

To compare the clinical and epidemiological characteristics of patients with pyogenic liver abscess (PLA) and with amebic liver abscess (AHA) in order to determine the potential factors that may help improve diagnosis and treatment for this disease.

### MATERIAL AND METHOD:

A retrospective study of clinical histories of 45 patients with PLA and 13 with ALA, diagnosed between 1985 and 2005 in Donostia Hospital in San Sebastián.

### RESULTS:

Among the 45 patients with PLA (30 men and 15 women, with a mean age of 61 years and 11 months), more than a half were cholangitic (13 cases) or were of unknown origin (15 cases). In 10 patients, diabetes was considered to be a predisposing condition. Increased ESR ( $> 30$ ), leukocytosis ( $> 12,000$ ), fever and

abdominal pain were observed in 95.5%, 86.7%, 82.8% and 68.9%, respectively. Twenty-five patients had single abscesses. Abscess and blood cultures were positive in 77.1% and 50% of cases, respectively (44.4% with polymicrobial infection). *E. coli* and *S. milleri* were the most commonly found germs. A percutaneous drainage was performed on 22 patients. Mean hospital stay was 27 days, and overall mortality, including that related to concomitant conditions, was 7 of 45 cases. Of the 13 cases of ALA (7 men and 6 women, with mean age of 42.9 years), 2 were locally acquired. Increased AF and GGTP ( $> 2N$ ), fever, leukocytosis and ESR ( $> 30$ ) were observed in 92.3, 77, 70 and 61.5% of cases, respectively. There were single abscesses in 10 patients and all except one were located in the right lobe. The serological test for *E. histolytica* (IFF  $> \text{or} = 1/256$ ) was positive in 100% of cases. A percutaneous drainage was carried out on 6 patients. Mean hospital stay was 18 days and two patients died.

#### CONCLUSIONS:

In our series, the clinical parameters suggesting pyogenic origin were: age 50 or older, male gender, diabetes, moderately elevated bilirubin and transaminases. In amoebic cases the associated features were being aged 45 or younger, diarrhoea, and presence of a single abscess in the right lobe. Parasitism by *E. histolytica* must be considered in the differential diagnosis of liver abscesses, even with no epidemiological clinical history of travel and/or immigration.

#### **Study no.(3):**

Greenstein AJ (2006)

**Studied: Amebic liver abscess: a study of 11 cases compared with a series of 38 patients with pyogenic liver abscess.**

Amebic liver abscess is an uncommon disease in the northern states of North America with 11 cases seen among approximately 500,000 Mount Sinai Hospital admissions over a 16-year period. Five of 11 cases originated in, or had recently visited South America. In three of these, and two patients with concomitant intestinal amebiasis, the diagnosis was suspected on admission. Diagnosis after admission was rapid, mean 5 days, compared with a mean of 13 days in pyogenic liver abscess. There was a higher incidence of male patients, nine males versus two females which was greater than the excess found in our pyogenic abscesses, 22 versus 16. Multiplicity was less common than in pyogenic abscess, 27 versus 50%, respectively. All three patients with multiple abscesses survived with surgical drainage and antibiotic therapy despite numerous complicating factors, including secondary bacterial infection. One patient resolved with drug treatment only; all others were treated with drugs and concomitant drainage; surgical drainage in earlier cases, and percutaneous drainage more recently. There was a single postoperative death. Drug treatment is the first therapeutic modality, and if recovery is delayed more than 2 days percutaneous aspiration should be carried out. This was successful in four cases. Surgery should seldom be required with present methods of accurately localizing amebic liver abscess, but is essential for ruptured abscess with peritonitis, and liver abscess with associated intestinal problems such as toxic megacolon, colonic perforation, or fulminating colitis. There has been a significant reduction in mortality of amebic liver abscess over the past 50 years and particularly within the past decade.

#### **Study no. (4):**

Anderson R et al(1990)

Studied :**Percutaneous management of pyogenic hepatic abscesses**

Twelve patients (9 men, 3 women) with a mean age of 65 (54-78) years, with pyogenic hepatic abscesses were managed by percutaneous drainage between 1979 and 1987. Biliary origin was most common (4 patients), followed by hepatic abscesses as a late postoperative complication (seen in 3 patients) and hepatic abscesses occurring in association with acute appendicitis (2 patients). The origin was unknown in 3 patients. Diagnosis was reached by computed tomography or ultrasonography with a diagnostic delay of in mean 11 days. Seventeen abscesses were found among the 12 patients. The median abscess size (maximal diameter) was 7 (1-12) cm. Nine patients were treated with percutaneous drainage with an indwelling catheter within the abscess cavity for up to 3 weeks, while 3 patients were managed with percutaneous puncture and aspiration alone. The most commonly isolated organism from the drained hepatic abscess was E. coli. The course following percutaneous treatment was uneventful, without mortality and recurrence of the hepatic abscess during follow-up. One patient required surgical drainage of an additional hepatic abscess. Percutaneous drainage of hepatic abscesses, independent of origin, thus seems as a safe and reliable method, which should be considered as the treatment of choice if facilities and knowledge of percutaneous management are provided.

#### **Study no (5):**

Nudnov NV (1999)

## **Studied: Invasive interventions guided by computerized tomography in the diagnosis and treatment of diseases of the internal organs**

Diagnostic punctures under CT guidance were made in 544 patients with diseases of the chest (n = 303), abdomen (n = 149), and retroperitoneal space (n = 92). In 87 patients, diagnostic punctures were combined with therapeutical manipulations and included aspiration and drainage of visceral organ cysts and abscesses. The proposed procedure of diagnostic biopsies under CT guidance could ascertain the morphological nature of a lesion in 90.1% of cases prior to treatment.

Therapeutical aspirations and drainage of visceral cysts and abscesses under CT guidance resulted in their complete recovery in 97.8 and 85.7% of cases, respectively. Diagnostic and therapeutical interventions under CT guidance caused complications in 6.9% of cases. At diagnostic biopsy, pneumothorax is the most frequent complication (5.3%), and lung tissue hemorrhage along the puncture needle passage is the less frequent (1.3%). The use of therapeutical interventions developed complications in 1.1% of cases.

# CHAPTER 3:

---

## Methodolgy

## METHODOLOGY

---

### STUDY DESIGN:

---

This is both retrospective and prospective study, Facility based study.

### STUDY PERIOD AND AREA:

---

Study period conducted from 2008-2013, in Khartoum state hospitals.

### PATIENTS:

---

A total of 54 patients (40 males and 14 females) were studied.

Age group was between 1-90 years old.

All of them with a known history of liver abscess and were send for aspiration from different hospitals.

The patient should take nothing by mouth for 6-8 hours preceding examination. Infants should be given nothing by mouth for about 3 hours prior to examination.

### MACHINE USED:

---

GE logic P5 using curvi- linear (convex) transducers with frequencies between(3-5 MHz)

Aloka ultrasound mashine SSD 3500 using curvi-linear transducer with frequencies (3-5 Hz).

### OTHER MATERIALS NEEDS:

---

- Sterile surgical gloves.
- Drainage set with catheter sizes 8-12F.
- Scalpel size 11.
- Collection bag.
- Cannulasize 14-20 G.
- Syringe 20-60cc for aspiration and 5cc for local anesthesia.
- Localanesthesia (Lidocaine 1-2%).



- Normal saline.
- Antiseptic solution (alcohol and iodine).

The pathologist should attend the procedure.

---

## TECHNIQUE:

---

- The procedure is started by normal abdominal ultrasound scan for whole abdomen to determine the exact site, size and echogenicity of the abscess.
- The machine, probe, and whole patient abdomen are sterilized.
- 5cc of local anesthesia is injected at the site of procedure.
- Then, small-sized are totally aspirated to dryness & washed with a few cc of normal saline, without further action. The site is then covered with a plaster, larger sized abscess are drained by inserting by a drainage catheter mostly by Seldinger technique & the catheter is secured in site for about 2 days until the abscess is totally drained & sometimes a saline wash is done through the catheter

---

## DATA ANALYSIS METHOD:

---

The data were analyzed by using SPSS software for statistical analysis as well as Excel under windows.

# CHAPTER 4:

---

## Results

## RESULTS:

The study included 54 patient aged between 1-90 years old, all were known cases of liver abscesses. The results of both ultrasound and ultrasound-guided aspiration were as follows:

Table 4-1 Shows gender distribution and percentages

| Gender | Frequency | Percent |
|--------|-----------|---------|
| male   | 40        | 74.1    |
| female | 14        | 25.9    |
| Total  | 54        | 100.0   |

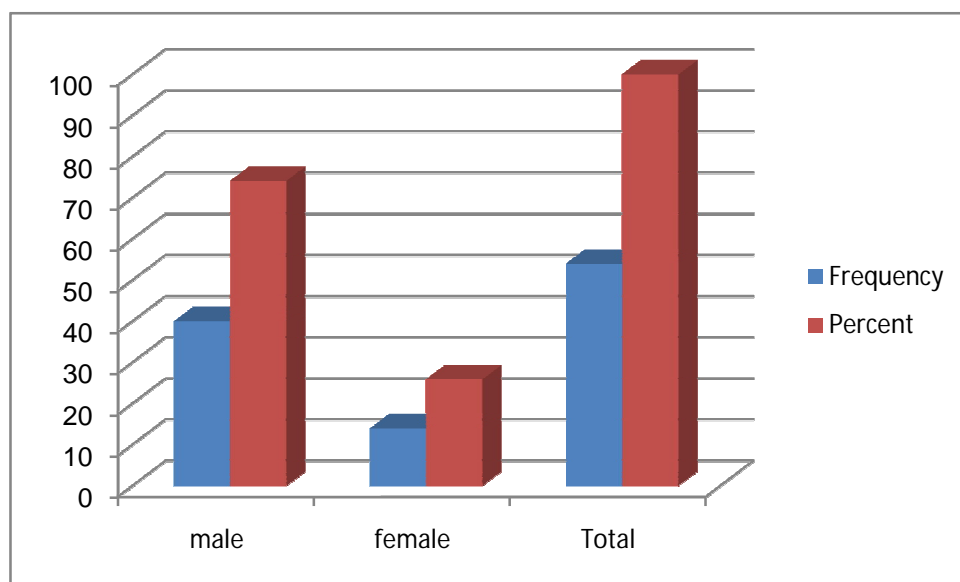


Table 4-2 Shows age distribution and percentages:

| age group | Frequency | Percent |
|-----------|-----------|---------|
| 1-14      | 2         | 3.7     |
| 15-29     | 6         | 11.1    |
| 30-44     | 11        | 20.4    |
| 45-59     | 16        | 29.6    |
| 60-74     | 12        | 22.2    |
| 75-90     | 7         | 13.0    |
| Total     | 54        | 100.0   |

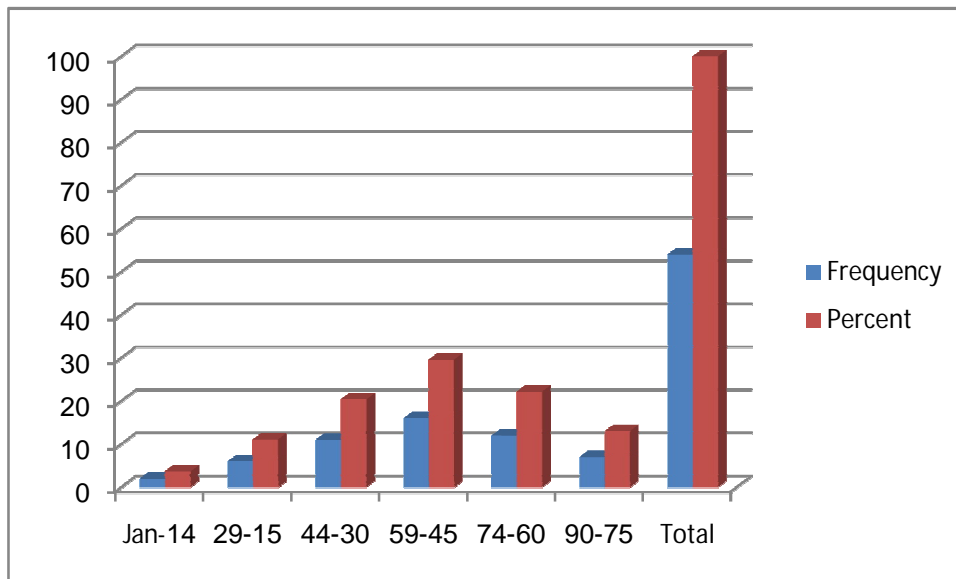


Table 4-3 Shows group affected lobe site:

| Lobe site  | Frequency | Percent |
|------------|-----------|---------|
| Right lobe | 42        | 77.8    |
| Left lobe  | 12        | 22.2    |
| Total      | 54        | 100.0   |

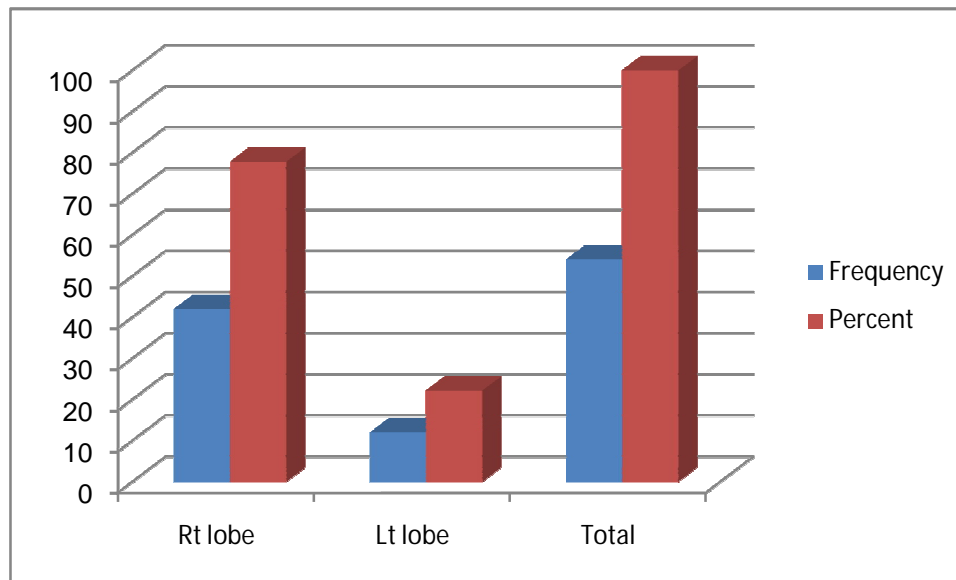


Table 4-4 Shows type of abscess echogenicity:

| Echogenicity  | Frequency | Percent |
|---------------|-----------|---------|
| Hypo-echoic   | 30        | 55.6    |
| Heterogeneous | 24        | 44.4    |
| Total         | 54        | 100.0   |

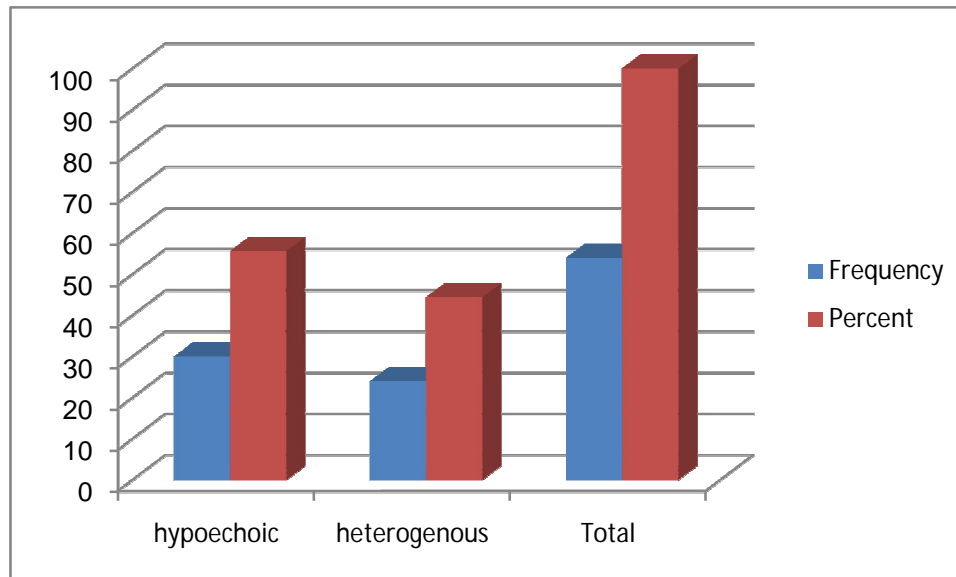


Table 4-5 Shows the margins of the abscess:

| Margins      | Frequency | Percent |
|--------------|-----------|---------|
| well defined | 40        | 74.1    |
| ill defined  | 14        | 25.9    |
| Total        | 54        | 100.0   |

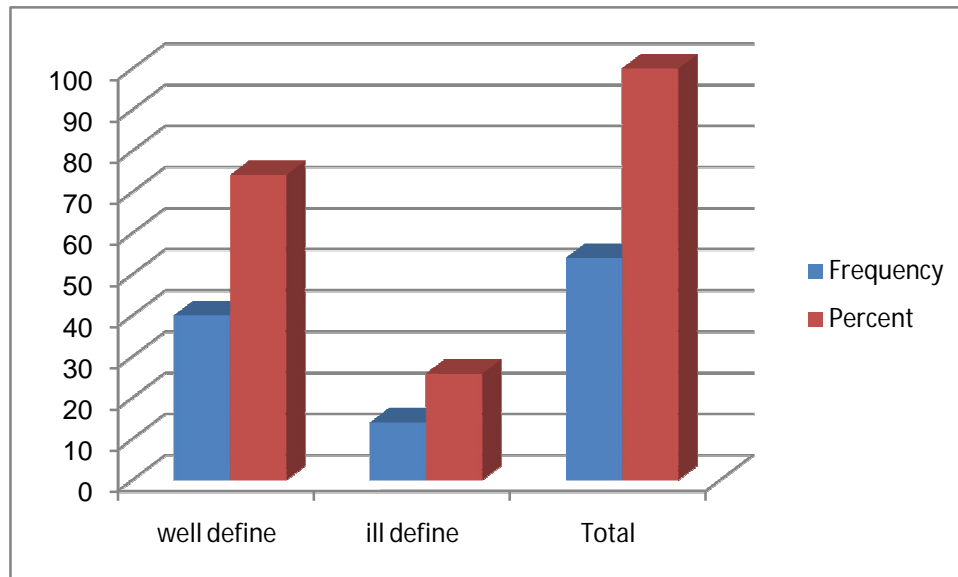


Table 4-6 Shows the wall thickness of the abscess

| wall  | Frequency | Percent |
|-------|-----------|---------|
| thick | 35        | 64.8    |
| thin  | 19        | 35.2    |
| Total | 54        | 100.0   |

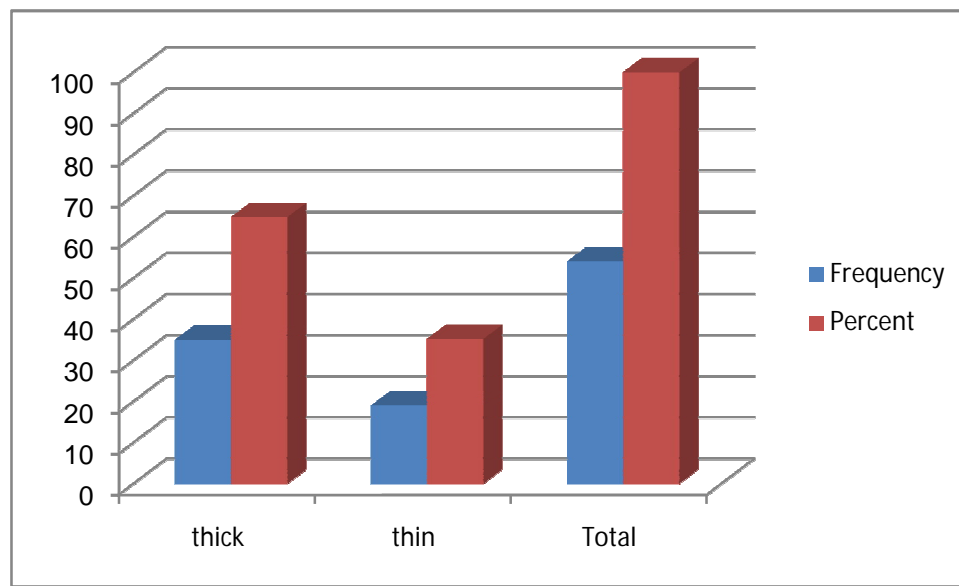




Table 4-7 Shows the amount of abscess that was aspirated:

| Aspiration amount | Frequency | Percent |
|-------------------|-----------|---------|
| wholly            | 46        | 85.2    |
| partially         | 8         | 14.8    |
| Total             | 54        | 100.0   |

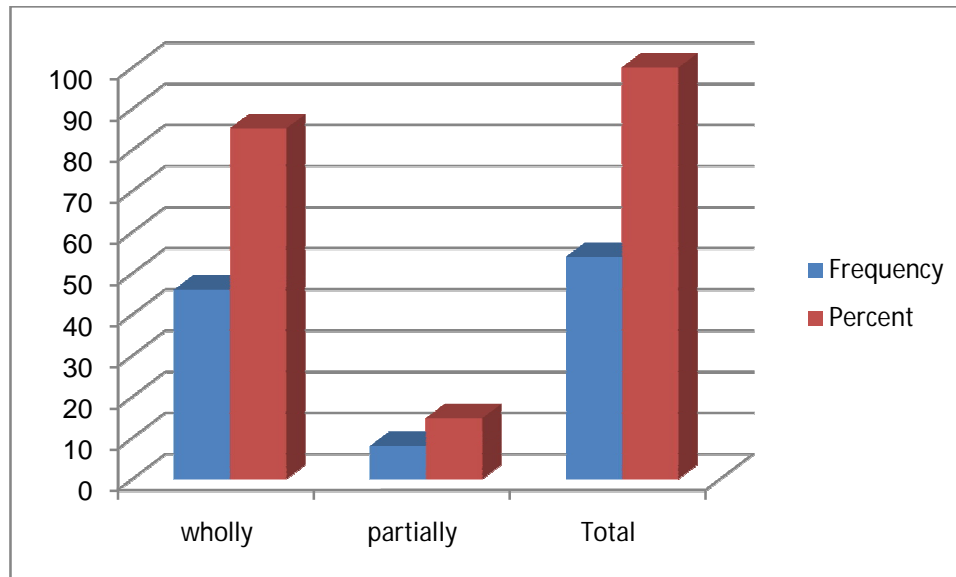
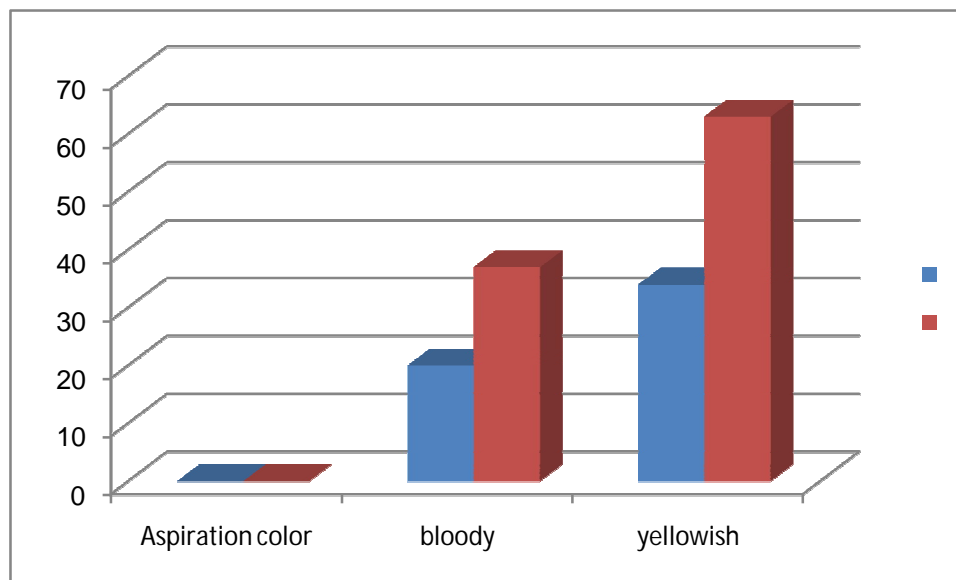


Table 4-8 Shows the color of the abscess after aspiration:

| Aspiration color | Frequency | Percent |
|------------------|-----------|---------|
| bloody           | 20        | 37.0    |
| yellowish        | 34        | 63.0    |
| Total            | 54        | 100.0   |



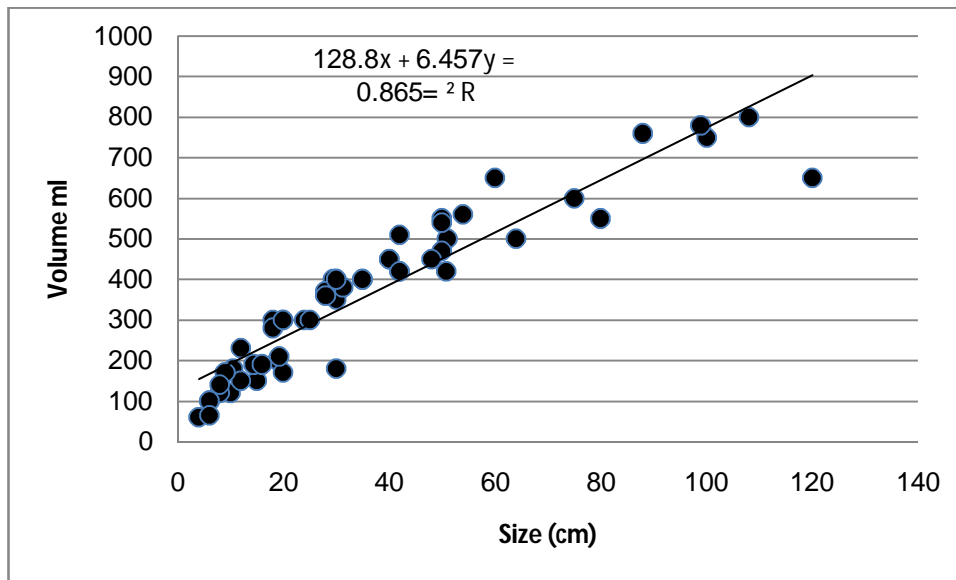


Figure 4-1 Scatter plot shows the linear association between the size and volume of the liver abscess with a trend line shows a direct linear proportional relationship.

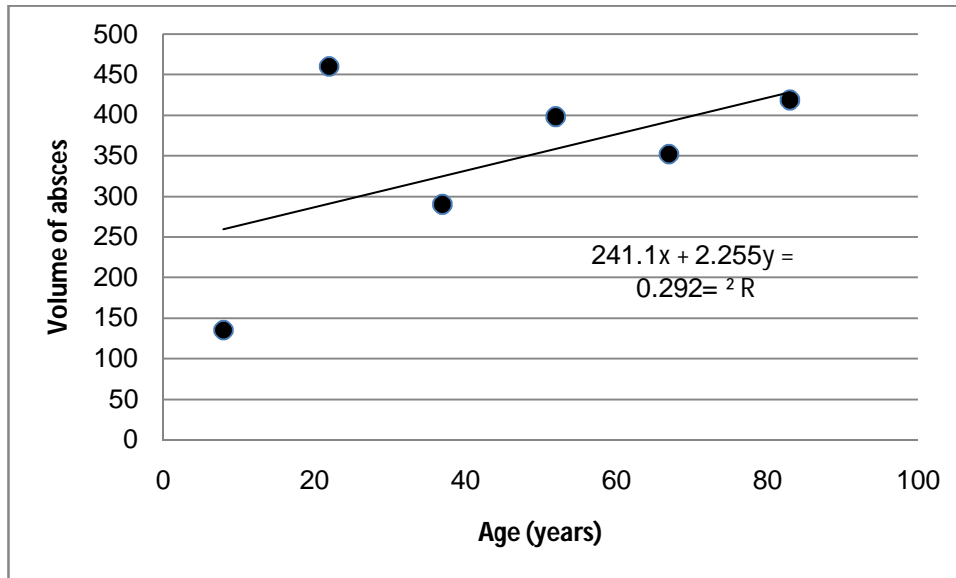


Figure 4-2 Scatter plot shows the linear association between the volume of the abscess and the age of the patient with a trend line shows a direct linear proportional relationship.

Table 4-9 Shows the relation between genders and lobs site.

| gender | Lobe site  |           | Total |
|--------|------------|-----------|-------|
|        | Right lobe | Left lobe |       |
| male   | 31         | 9         | 40    |
| female | 11         | 3         | 14    |
| Total  | 42         | 12        | 54    |

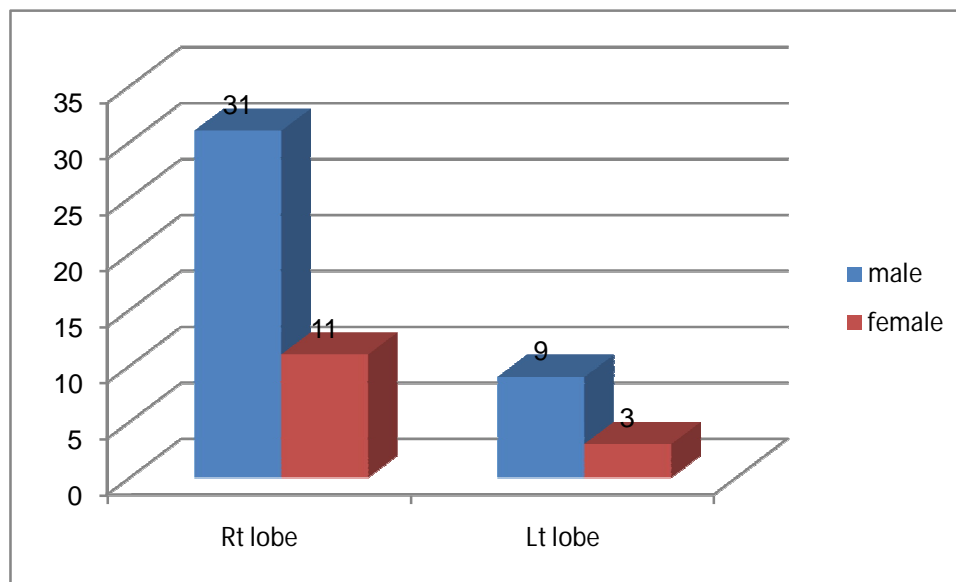


Table 4-10 Shows the relation between age and lobe site.

| Age   | Lobe site  |           | Total |
|-------|------------|-----------|-------|
|       | Right lobe | Left lobe |       |
| 1-14  | 2          | 0         | 2     |
| 15-29 | 6          | 0         | 6     |
| 30-44 | 8          | 3         | 11    |
| 45-59 | 12         | 4         | 16    |
| 60-74 | 9          | 3         | 12    |
| 75-90 | 5          | 2         | 7     |
| Total | 42         | 12        | 54    |

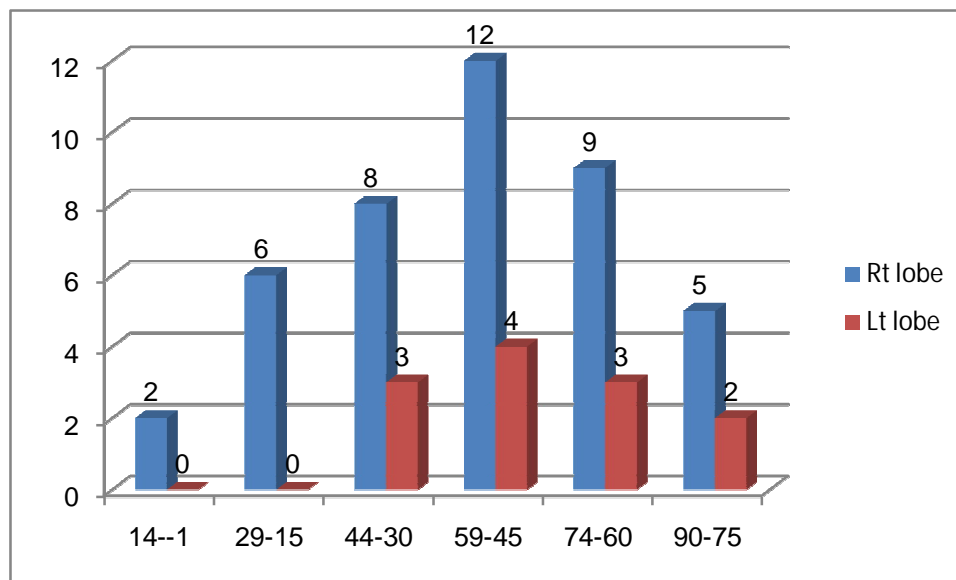


Table 4-11 Shows the relation between echogenicity of the abscess and the color of aspirate.

| echogenicity  | aspiration color |           | Total |
|---------------|------------------|-----------|-------|
|               | bloody           | yellowish |       |
| Hypo-echoic   | 10               | 20        | 30    |
| heterogeneous | 10               | 14        | 24    |
| Total         | 20               | 34        | 54    |

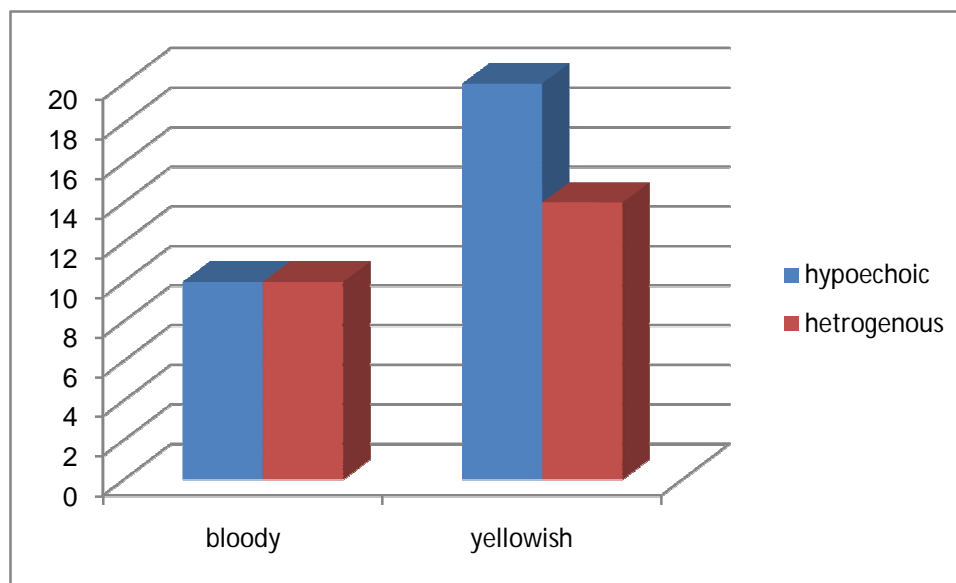


Table 4-12 Shows the relation between the wall of the abscess and the aspirate color.

| wall  | Aspirate color |           | Total |
|-------|----------------|-----------|-------|
|       | bloody         | yellowish |       |
| thick | 15             | 20        | 35    |
| thin  | 5              | 14        | 19    |
| Total | 20             | 34        | 54    |

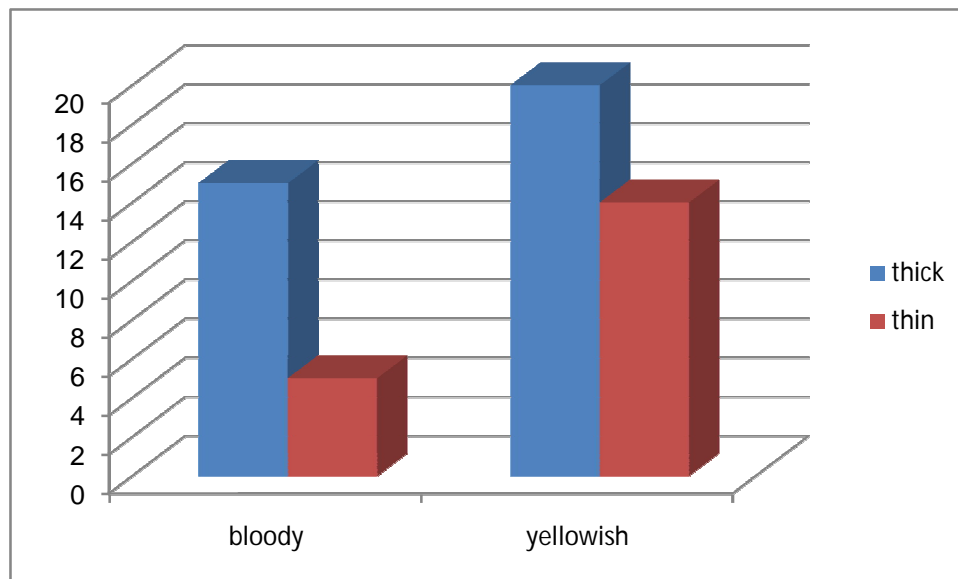




Table 4-13 Shows the relation between the margins of the abscess and the aspirate color.

| margins      | aspirate color |           | Total |
|--------------|----------------|-----------|-------|
|              | bloody         | yellowish |       |
| Well-defined | 13             | 27        | 40    |
| Ill-define   | 7              | 7         | 14    |
| Total        | 20             | 34        | 54    |

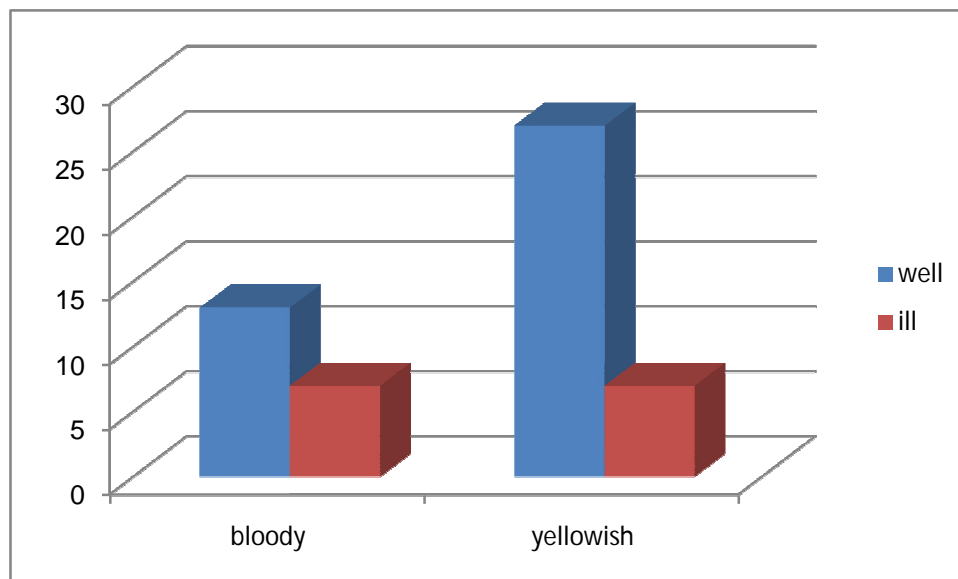
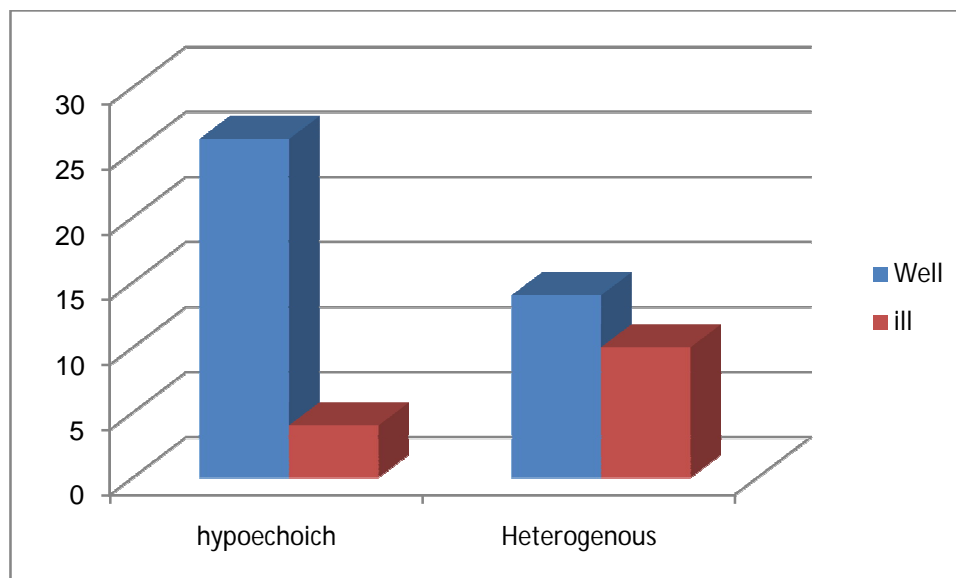


Table 4-14 Shows the relation between the margins of the abscess and its echogenicity.

| margins      | echogenicity |               | Total |
|--------------|--------------|---------------|-------|
|              | Hypo-echoic  | heterogeneous |       |
| Well-defined | 26           | 14            | 40    |
| Ill-defined  | 4            | 10            | 14    |
| Total        | 30           | 24            | 54    |



In summary, the results of this study showed that males were affected more than females and so was the right lobe of the liver, which was more affected than the left one.

The most typical ultrasound features of liver abscess that; it is usually hypo-echoic, well defined and thick-walled. Most of abscesses can be completely aspirated in one session without the need for catheter drainage.

After aspiration, mostly, the abscess is yellowish in color and these features are probably of pyogenic liver abscess. No significant immediate complications noted following any aspiration procedure.

# CHAPTER 5

---

Discussion

Conclusion

Recommendations

## DISCUSSION:

---

The main objective of this study is to assess the role of the ultrasound in diagnosis and treatment of the liver abscess. The study included 54 patients from different region in Sudan.

The study showed that 74.1% of cases were males(40pts.) and 25.9% were females (14pts) this indicates that the male:female ratio is approximately 3:1.(table 4.1).This is most probably due to increased mobility of males and susceptibility to be infected.

The liver abscess affected all age groups, but commonly males between 45-59 yrs (16pt).(Table 5.2).

It affected the right liver lobe 77.8% (42pts) more than the left 22.2 % (12pts). Because the right lobe receives the larger amount of portal circulation.

The ultrasound appearance of the liver abscess were commonly hypoechoic 55.6% (30 pts) because they totally liquified, heterogeneous 44.4% (24 pts) infection state. (table 4.4).usually abscesses have fairly well defined margins 74.1% (40 pts) ill defined are about 25.9% (14pts) (table 4.5).liver abscess also usually thick walled in 64.8% (35pts) and thin walled in 35.2% (19 pts) (table 4.6).

In this study 85.2% (46pts) the whole abscess were aspirated in one session , but about 14.8% (8pts) they needed drainage insertion. Most of the aspirated abscess color was yellowish 63% (34pts), but 37% (20pts) had a bloody colored abscess.

More than 98% (53pts) of the aspirated abscess diagnosed as pyogenic liver abscess (suppurative liver infection), but just one pt .diagnosed as amoebic liver abscess.

Table & figure 4.11: express the relation between echogenicity of the abscess and the color of the aspiration, that most of the hypoechoic(late stage) abscess has yellowish color, and almost all bloody color abscess has a heterogeneous texture.

Table & figure 4.12: show the relation between the wall of the abscess and the aspiration color, which that most of the thick walled abscess had a yellowish color, but the thin walled has a bloody color.

Table & figure 4.13: which describe the relation between margins and color of the aspiration, most of the yellowish abscess colored had a well define margins, and bloody colored had ill define margins.

Table & figure 4.14: show the relation between margins of the abscess and echogenicity, most of well-defined margins has a hypo-echoic texture, but ill define margins has a heterogeneous texture.

All patient doesn't have immediate complication after aspiration like: severe pain, bleeding and hypotension,...etc.

## CONCLUSION:

---

Liver abscess is a serious common infectious liver disease in Sudan, and it is easy to be diagnosed by ultrasound, also it can be completely aspirated and treated by ultrasound-guided drainage.

The study included 54 patient aged between 1-90 years old, all were known cases of liver abscesses.

The main objective of this study was to assess the role of the ultrasound in diagnosis and treatment of liver abscess.

The data were collected using, gender, age, lobe site, abscess size, echogenicity, margins, wall thickness, and color of the abscess after aspiration, amount that was aspirated, type of abscess after aspiration and presence of any immediate complications.

The result of this study showed that the incidence of liver abscess is more among males with middle aged group , while the commonest ultrasound appearance was hypo-echoic, thick walled with well define margins, mostly in the right hepatic lobe. After aspiration, mostly, the abscess is yellowish in color and these features are probably of pyogenic liver abscess. Only one case was diagnosed as amebic liver abscess. No significant immediate complications noted following the aspiration procedures.

## RECOMMENDATIONS

---

Liver abscess is one of the serious diseases in Sudan, so every patient suspected to have liver abscess during clinical examination should be sent for proper investigations especially US because the laboratory is not enough to state the presence of liver abscess and if the diagnosis is confirmed, the patient should be sent for aspiration as soon as possible.

The researcher recommended for more study of the disease and its implication on the other vital organs (like kidneys), and to detect if there is recurrence after complete aspiration or not.



## REFERENCES:

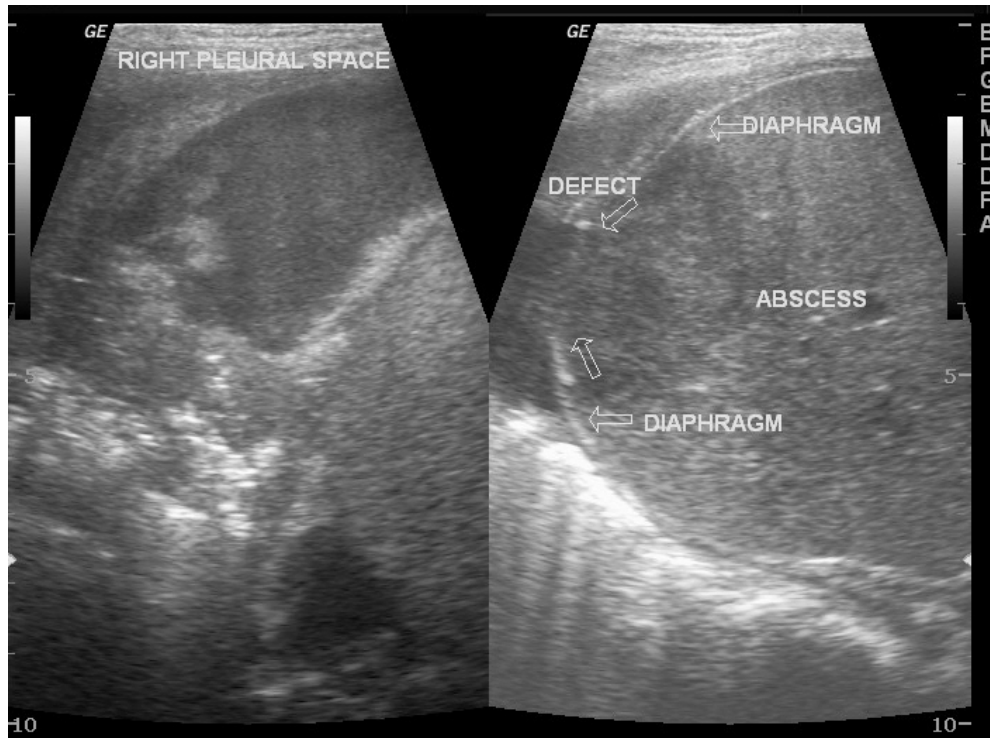
---

1. Ochsner A, DeBakey M, Murray S. Pyogenic Abscess of the Liver II. An Analysis of Forty-Seven Cases with Review of the Literature. AM J SURG. 1938;XL:292-319.
2. Othman N, Mohamed Z, Yahya MM, Meng LV, Huat LB, Noordin R. Entamoebahistolytica antigenic protein detected in pus aspirates from patients with amoebic liver abscess. EXP PARASITOL. 2013May 13.
3. Chen SC, Huang CC, Tsai SJ, et al. Severity of disease as main predictor for mortality in patients with pyogenic liver abscess. AM J SURG. Aug 2009;198(2):164-72.
4. Brisse S, Fevre C, Passet V, et al. Virulent clones of Klebsiellapneumoniae: identification and evolutionary scenario based on genomic and phenotypic characterization. PLOS ONE. 2009;4(3):e4982. [
5. Lin YT, Liu CJ, Chen TJ, Chen TL, Yeh YC, Wu HS, et al. Pyogenic liver abscess as the initial manifestation of underlying hepatocellular carcinoma. AM J MED. Dec 2011;124(12):1158-64.
6. Walker TG. Interventional Procedures. Lippincott Williams & Wilkins. (2012) ISBN:1931884862.
7. Gilmore IT, Burroughs A, Murray-Lyon IM et-al. Indications, methods, and outcomes of percutaneous liver biopsy in England and Wales: an audit by the British Society of Gastroenterology and the Royal College of Physicians of London. Gut. 1995;36 (3): 437-41.

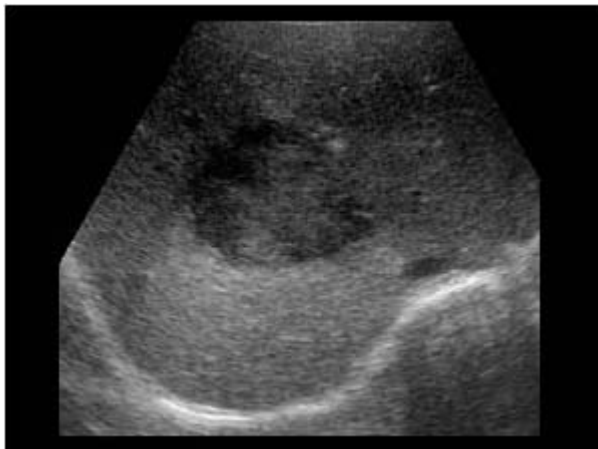
## APPENDIGES

---

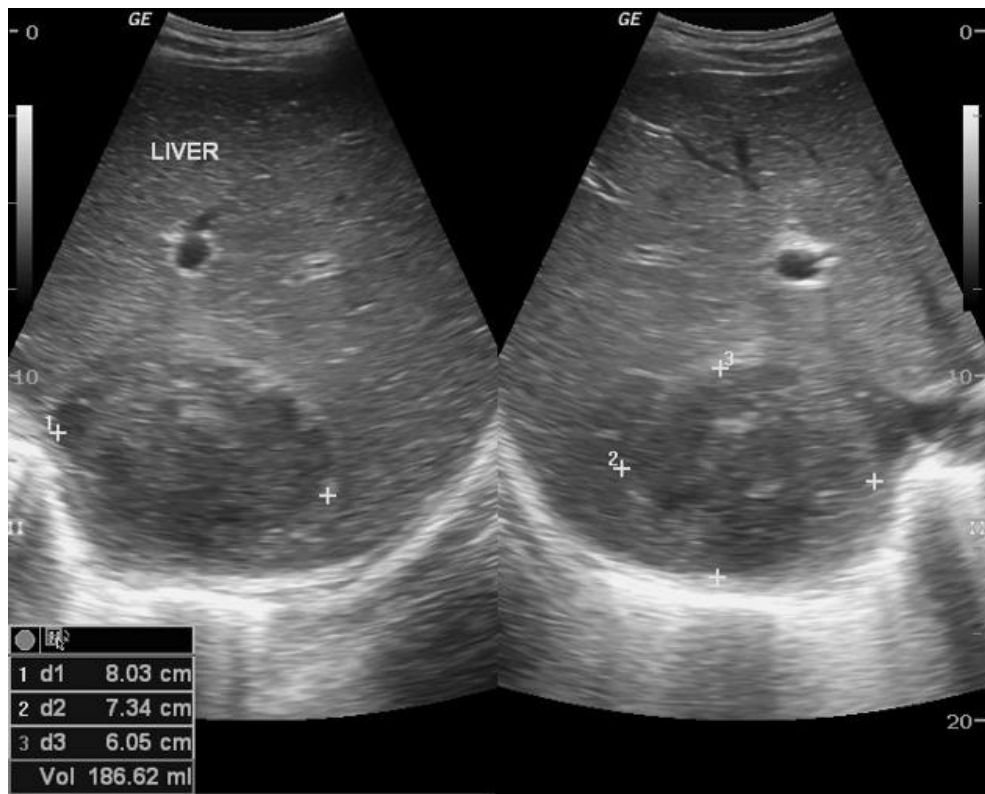
1 ABDOMINAL US SHOWING LIVER ABSCESS



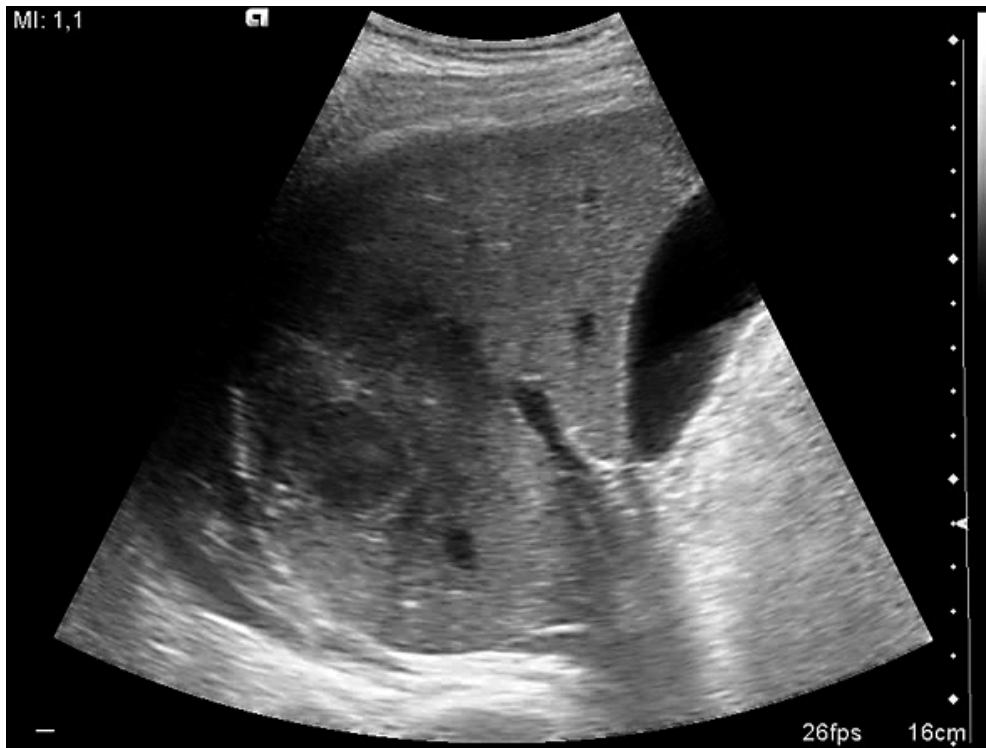2 ABDOMINAL US SHOWING RIGHT LOBED LIVER ABSCESS



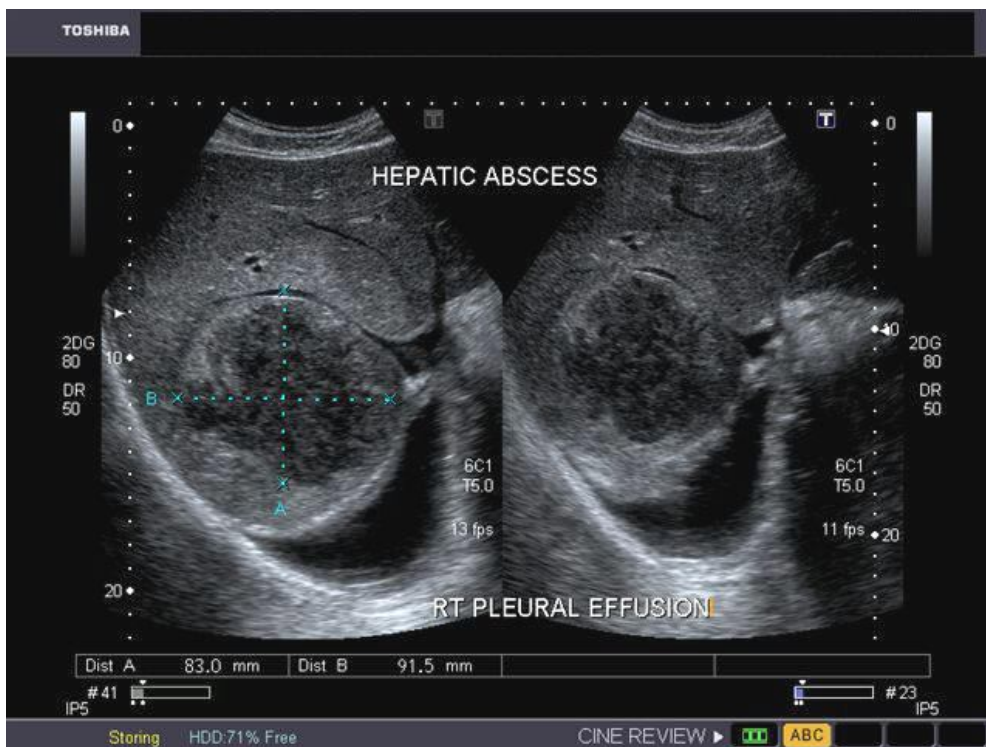
03ABDOMINAL US SHOWING LARGE THICK WALLED AND HETEROGENOUSLY ECHOS LIVER ABSCESS



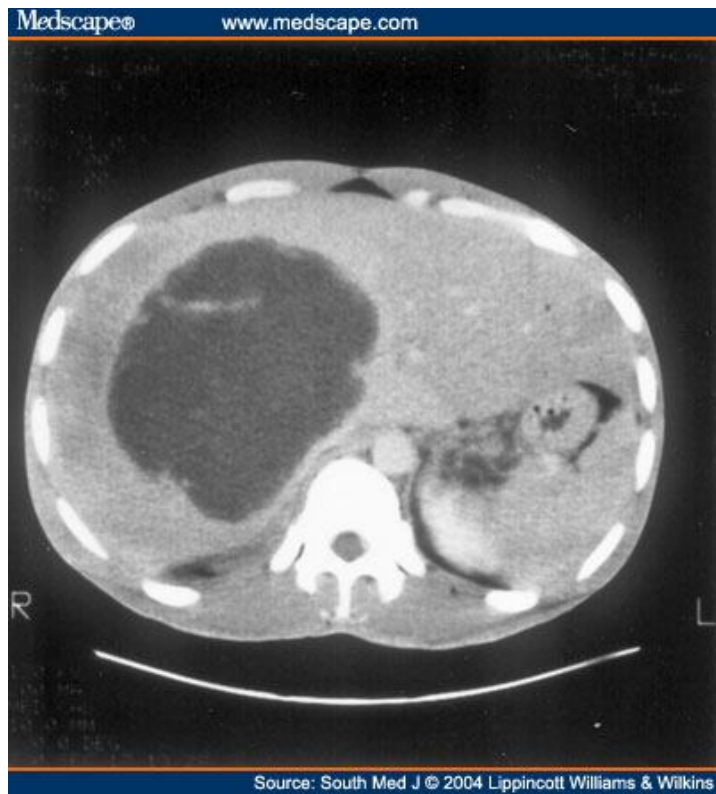04 ABDOMINAL US SHOWING HYPOECHOIC THICK-WALLED LIVER ABSCESS



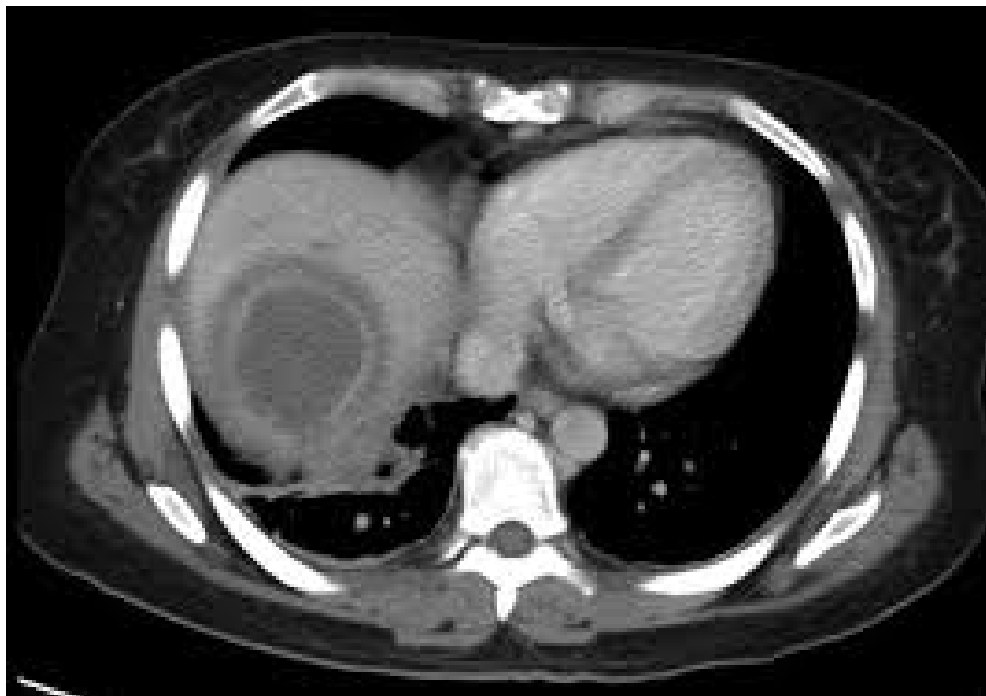
5 ABDOMINAL US SHOWING RIGHT LOBED LIVER ABSCESS WITH RIGHT SIDED PLEURAL EFFUSION



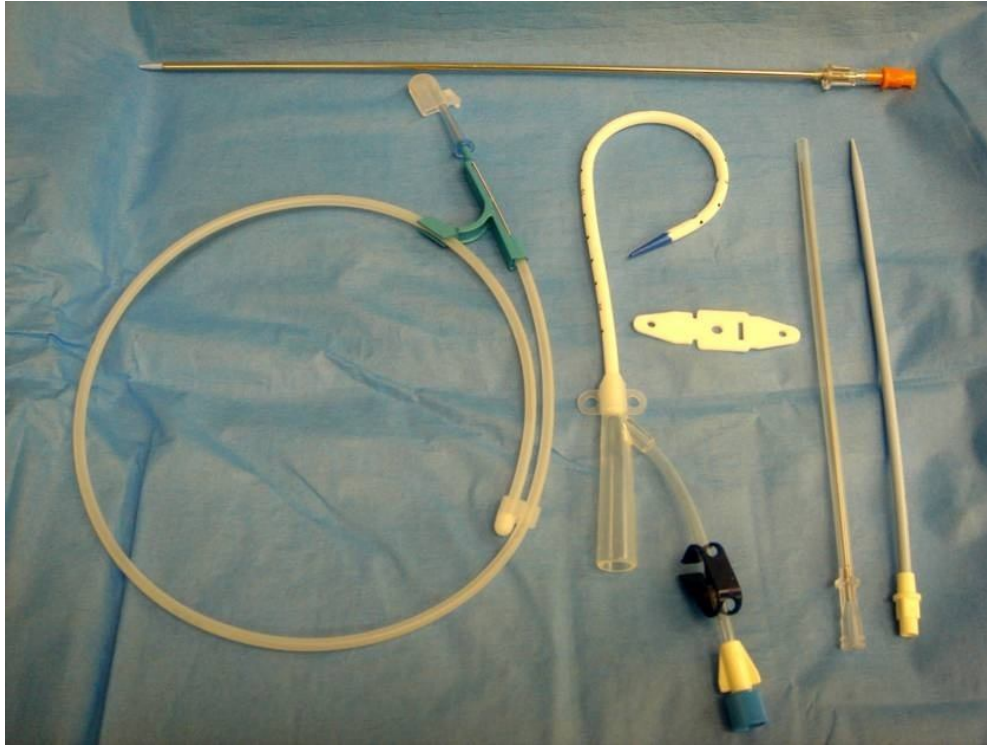06 CT ABDOMEN SHOWING A HUGE LIVER ABSCESS



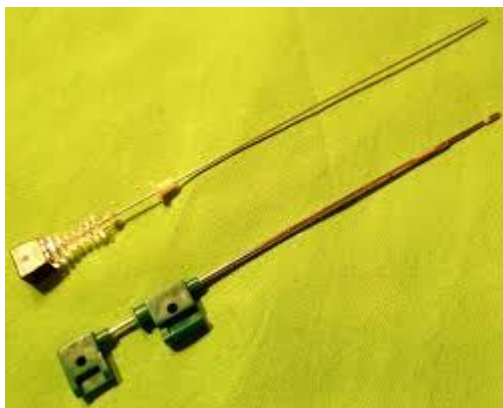07 CT ABDOMEN SHOWING THICK-WALLED LIVER ABSCESS



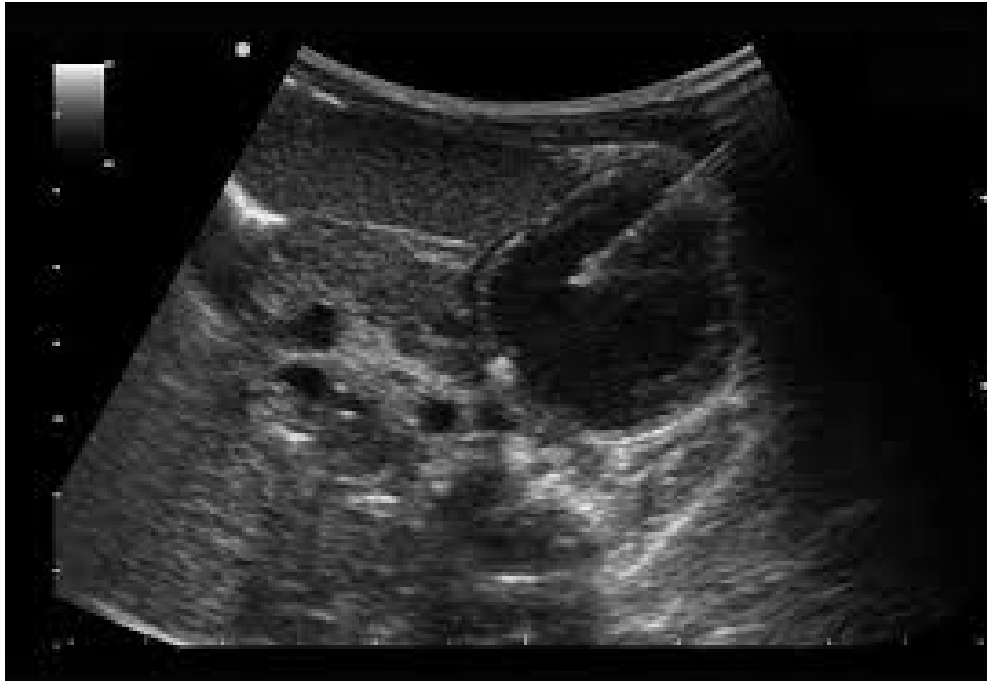08 DRAINAGE SET



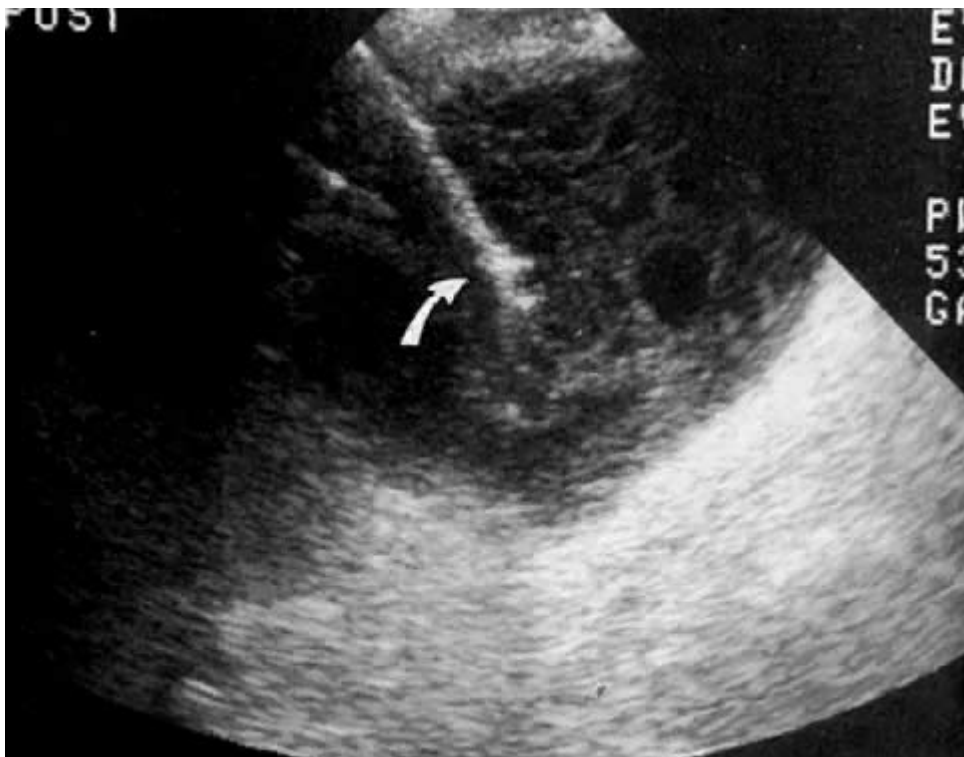
09 DRAINAGE NEEDLE



010 US SHOWING NEEDLE INSIDE AN ABSCESS (REVERBARATION SIGN)

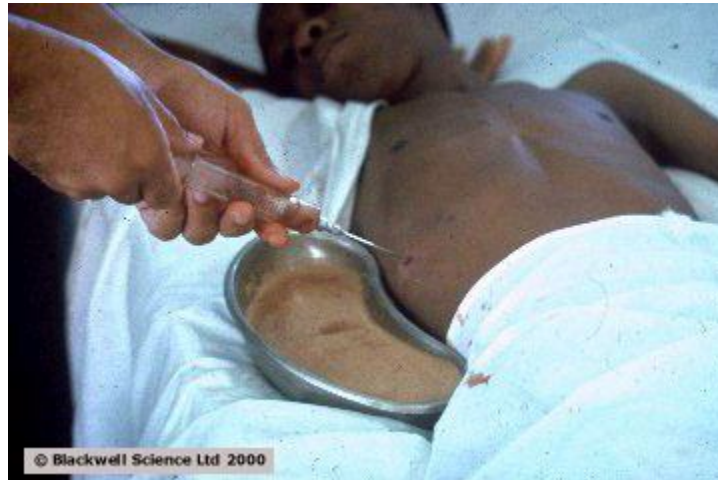

011US SHOWING TIP OF NEEDLE INSIDE AN ABSCESS

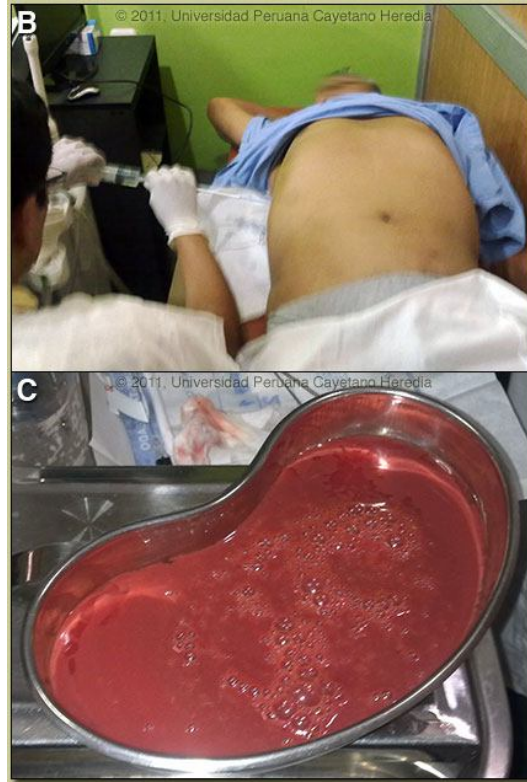



012 PATIENT WITH LIVER ABSCESS DURING ASPIRATION

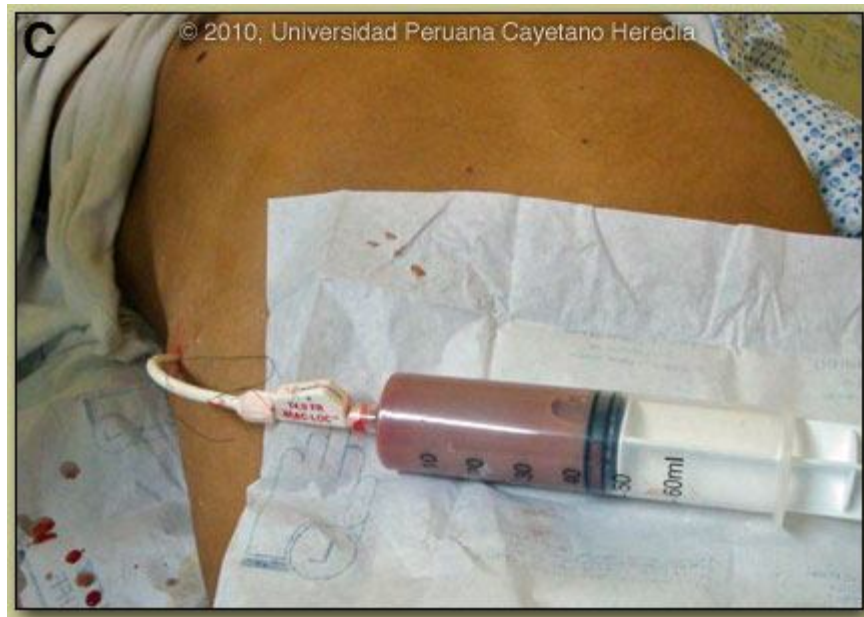

013 REDISH LIVER ABSCESS ASPIRATE





014 SYRINGE ATTACHED TO A DRAINAGE CATHETER



015 YELLOWISH LIVER ABSCESS ASPIRATE

