

Chapter one

1.1 Introduction :

The nasal septum consists of multiple components with various developmental origins and is considered a mosaic structure. Few studies have focused on anatomical relationships among the components of the nasal septum, even though they are essential for clinical assessments of morphological anatomical correlations among components of the nasal septum using computed tomography(CT)of the paranasal sinus .Many patients are somehow confused about what the septum is and what the role of it in the nasal passages. Anatomically, the septum refers to the wall that separates the left and right sides of the nasal passages. there is mucous membrane lining over the entire septum on either side, and the center part is made from bone and cartilage.The role of the septum is essentially similar to lane markers in a busy highway. The septum allows the air that is breathed in through our nostrils to go directly from the tip of the nose into the back of the nose and into the lungs. Without the septum , the air that is breathed in might “get lost” in the nose; the turbulence might interfere with the direct transit of the air directly into the lungs.(Kim J¹, Cho JH, Kim SW, Kim BG 2010)

In an ideal situation , the septum is to be a straight wall that goes in an up and down direction .in reality ,everybody has some degree of deviation of their septum. Sometimes this is due to the way that the nose develops and sometimes it could be due to a previous injury or fracture of the nose. the degree of the deviation of the septum ,as well as the anatomy of the side wall of the nose ,can result in various degrees of blockage of the nasal passages as well as the sinus drainage pathways.

Patient with a deviated nasal septum is considered to have fixed anatomical abnormality that will not respond to any kind of medical therapy for an anatomical blockage. As such, the only remedy is to undergo corrective surgery. It is usually not easy to determine if the patient is suffering from deviation of septum versus other reasons for nasal obstruction by external examination. Examination of the inside of the nasal passages can be done with the help of nasal endoscopy. This is the best determinant to certain of the nasal septum. (www.newyorkentspecialist.com)

1.2 problem of the study :

There are many factors that affect the nasal septum dimensions including normal variations and pathological causes. The ethnicity, gender, race and age can be one of the factors.

No study was done in the open literature related to nasal septum in Sudanese population.

1.3 research objectives :

1.3.1 general objective :

The general objective of this study is to characterize of nasal septum in Sudanese patients using computed tomography.

1.3.2 specific objective :

1. To measure the nasal septum length in Sudanese individuals.
2. To correlate the measurements of normal nasal septum with the age and gender.
3. To determine common variations in Sudanese.
4. To establish an index for normal Sudanese

1.4 significance of study :

This study will profile an index of nasal septum dimensions in Sudanese to show the reasons of nasal septum variation in individuals as well as it will give theoretical bases that can be used to estimate the nasal dimensions which can be used as reference for different individuals; this make the index a dynamic in individuals.

1.5 overview of study :

This study consisted of five chapters. Chapter One dealt with the introduction ,Chapter Two include literatures review and reconstruction, chapter three detailed the materials and methods then chapter four presented the results and chapter five presented the discussion ,conclusion and recommendations.

Chapter Two

literature review

2.1 Theoretical back ground :

2.1.1 Anatomy of the Nasal septum :

The nasal cavity is a potential space situated above the oral cavity and hard palate and below the skull base and intracranial compartment. It is separated in the midline by the nasal septum into a right and left side. The nasal septum is composed of cartilage in its front end and bone towards the back of the nose. There are three contributors to the bony septum: the perpendicular plate of the ethmoid bone, vomer bone, and maxilla bone. The nasal septum is often crooked or off-midline, which can result in narrowing of one or both sides of the nasal cavity. The left and right nasal cavities become continuous in the back of the nose via the opening to the nasopharynx, termed the choana. In this area, the nasal cavity transitions into the nasopharynx. The nasopharynx contains a collection of centrally located lymphoid tissue called the adenoids. The Eustachian tubes each open into the sides of the nasopharynx, thus connecting the middle ear with the upper respiratory tracts. Dysfunction of the Eustachian tubes, from swelling, infection, or changes in altitude, among other things, can lead to transient ear ‘popping’ and ‘plugged’ sensation to ears (Justin H. Turner , 2011)

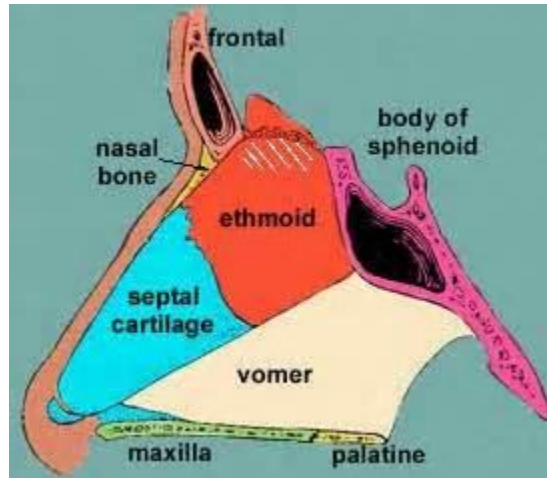
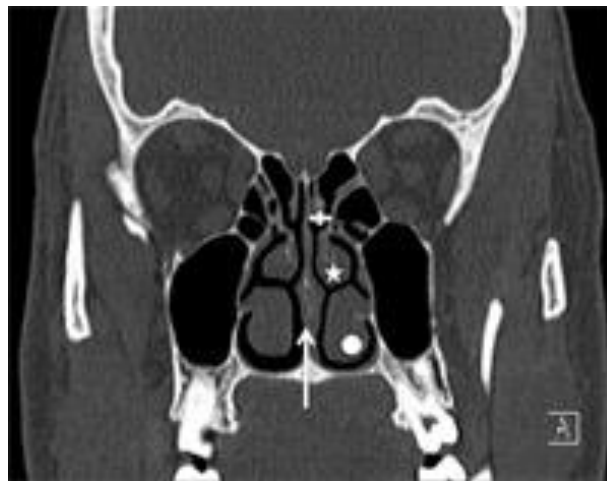

Figure (2.1) shows Nasal cavity (earnoethroatclinic.blogspot.com)

The sidewalls of the nose, or lateral nasal walls, include three structures called turbinates. The turbinates are finger-like projections composed of a bony core and covered with soft tissue and mucosa, and are important because they serve to increase the mucosal surface area of the nasal cavity and regulate nasal airflow. (Justin H. Turner, American Rhinologic Society 2011)

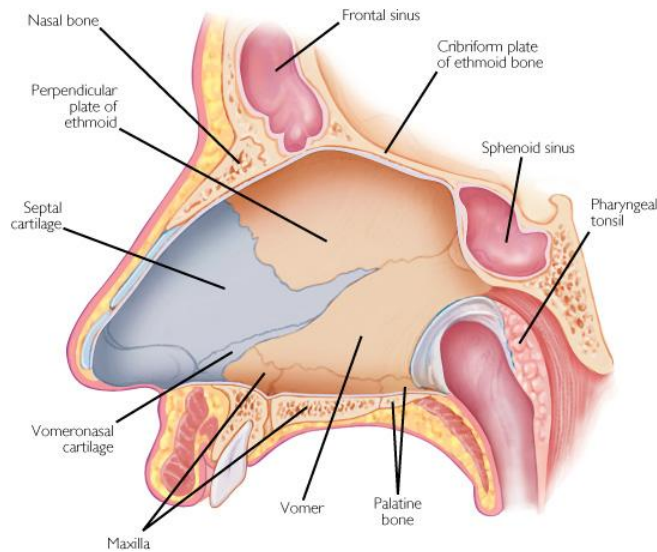


Figure(2.2) shows CT scan coronal section show turbinates (Rakesh Chandra, 2011)

Beneath each turbinate is a cleft, or meatus, named according to the turbinate just above it. The inferior turbinate is the largest of the three paired turbinates, and runs along the entire length of the lateral nasal wall, adjacent

to the nasal floor. The nasolacrimal (tear) duct, which inferior meatus, which explains why crying leads to a rapid onset of nasal discharge. The middle turbinate projects into the central nasal cavity and resides next to the nasal septum. It is attached to the lateral nasal wall posteriorly just above the inferior turbinate but behind the maxillary, or cheek, sinus. Superiorly, it inserts along the lateral nasal wall and skull base. The frontal sinus, maxillary sinus, and anterior ethmoid sinus cells drain beneath the middle turbinate into the middle meatus. Sometimes an ethmoid sinus cell can expand within the normally thin walls of the middle turbinate, and form an enlarged structure termed a concha bullosa.

The superior turbinate is the smallest of the turbinates. It resides just above and behind the middle turbinate, and also attaches to the skull base superiorly and nasal wall laterally. The sphenoid sinus and posterior ethmoid sinus cells drain into spaces between the nasal septum and superior turbinate called the sphenoethmoid



Figure(2.3)shows lateral view of nasal septum(<http://drpaulose.com/surgery/nasal-septal-deviation-how-to-correct-it>)

2.1.1blood supply:

The nasal cavity has a diverse blood supply arising from both the internal and external carotid arteries, which arise from the chest and neck. The anterior and posterior ethmoid arteries provide blood to the nose, and are both terminal branches of the internal carotid artery. They supply the lateral and anterior one-third of the nasal cavity and posterior nasal septum, respectively. The internal maxillary artery arises from the external carotid artery and divides into several branches in the head and neck before entering the nasal cavity. The largest branch is the sphenopalatine artery that enters the nasal cavity through a tunnel located along the lateral nasal wall near the back of the middle turbinate. This artery divides into two or more branches to supply the majority of the lateral nasal wall and nasal septum. The second major branch of the internal maxillary artery is the descending palatine artery, which descends to supply the nasal floor and anterior nasal septum, and eventually the mucosa of the hard palate of the mouth. In addition to this larger vasculature, there is a confluence of the small vessels that supply the

front portion of the nasal septum that is termed Kiesselbach's plexus. This lattice of veins is a common source of nasal bleeding (epistaxis) due to trauma and dry air exposure, and may require medical attention in many cases. . (Justin H. Turner , 2011)

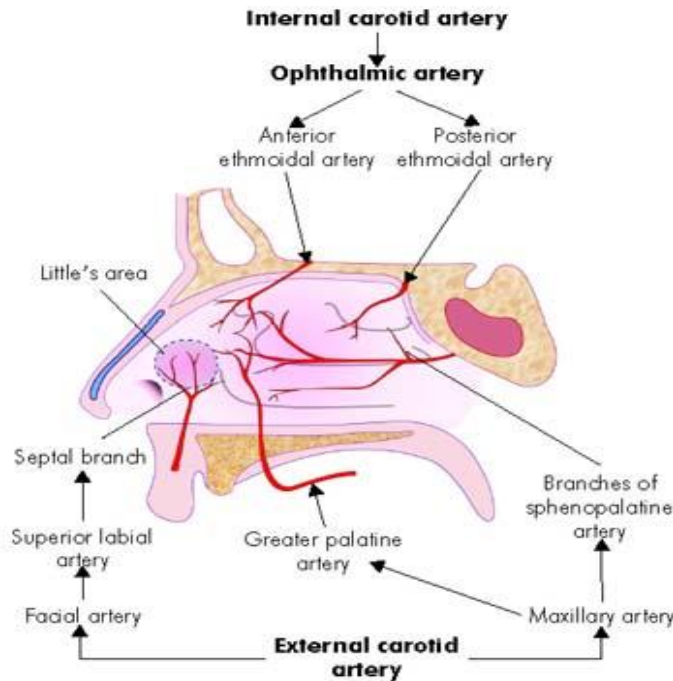


Fig. 33.1 Blood supply of nasal septum.

Figure(2.4)shows Blood supply of nasal septum (medipicz.blogspot.com)

2.1.2 Nerve Supply:

Sensation is provided to the nasal cavity primarily via branches of the trigeminal nerve, one of the twelve cranial nerves arising from the brain into various structures in the head and neck. The ophthalmic division (V1) of the trigeminal nerve gives off the anterior and posterior ethmoidal nerves, which travel along with their counterpart arteries (noted above), to innervate the upper front and upper back portions of the nasal cavity and septum. The maxillary branch (V2) of the trigeminal nerve exits the brain, ultimately dividing into several smaller branches. The largest of these branches is the sphenopalatine nerve, which travels with the corresponding artery and

supplies sensation to the lateral nasal wall and septum. Nasal secretions and mucus production is controlled by autonomic innervation from the brain to the vidian nerve, which then sends special parasympathetic fibers along with branches of the sphenopalatine nerve.

Likewise, blood flow to the nasal cavity and nasal mucosa is controlled largely by opposing sympathetic nerve fibers that also travel along with the sphenopalatine nerve. Changes in the balance of autonomic signals in the nasal cavity result in a rhythmic engorgement of nasal blood vessels to the mucosa and turbinates, and result in fluctuations in left and right nasal congestion that some people experience over a 4-6 hour cycle. This diurnal nasal cycle is normal, but can be a source of concern for some patients that may require evaluation (Jayakar V. Nayak , 2011)

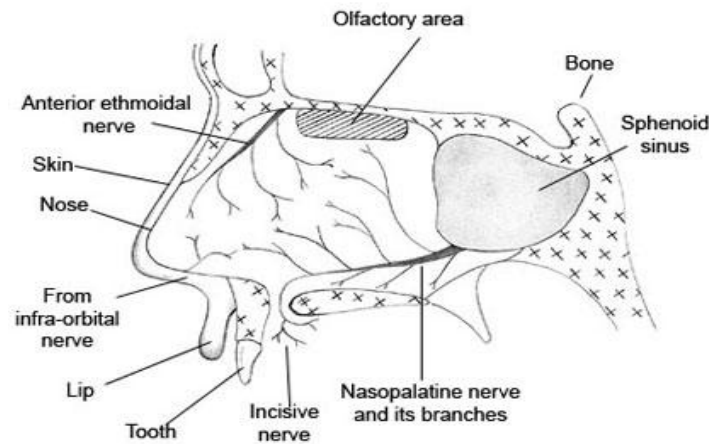
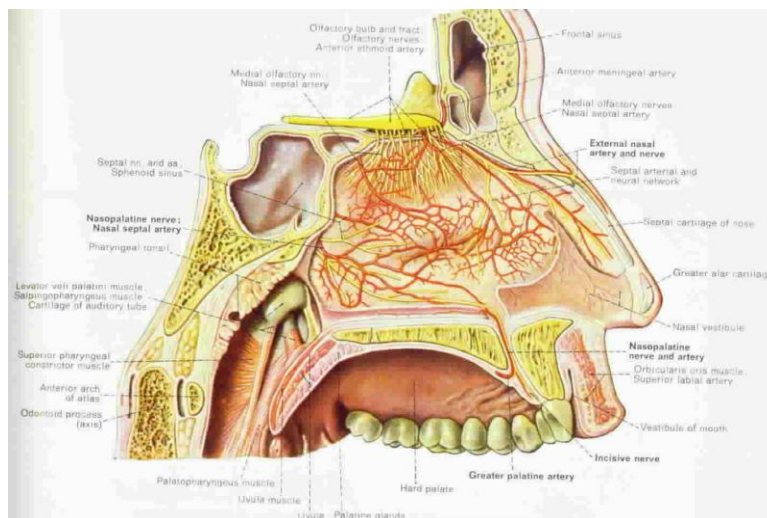


Figure (2.5) shows Nerve supply of the nasal septum(www.rhinobizra.net)

2.2 Physiology :

Nasal Cavity functions are Olfaction, filtration, heating and humidification . The nose has two primary functions. The first is olfaction – the sense of smell. However, the second function is of primary interest to this discussion

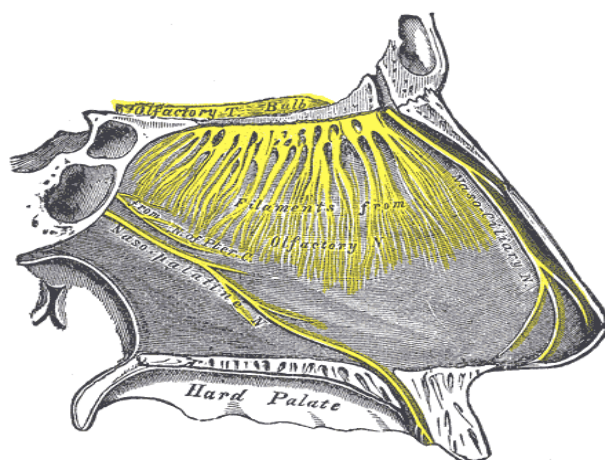
– filtration, heating and humidification of the inhaled air. To accomplish the second task, the nasal cavity contains a convoluted set of passageways called the turbinates on the lateral wall of each nasal cavity (see cross-sectional CT scan of turbinates to right). These turbinates interrupt the flow of air into the nasal passage, forcing it through narrow passages that are covered with moist nasal respiratory mucosa. The total surface area available in the nasal mucosa is estimated to be about 180 cm², of which 10 cm² is olfactory mucosa and 170 cm² is the richly vascularized respiratory mucosa. During the passage across this broad mucosal surface, the air is warmed and humidified by a rich vascular capillary bed that is directly beneath the surface. These capillaries are specifically designed for rapid passage of fluids through the vascular wall and out into the dry air. The amount of blood flow to this area is considerable – it is higher per unit of tissue than the blood flow to the brain, liver or muscle. (Talegaonkar , Indian J Pharm 2004)



Figure(2.6) shows that air is warmed and humidified by a rich vascular capillary (Talegaonkar, J Pharm 2004)

2.2.1 Nose-brain pathway – nasal mucosal absorption of medications directly into the cerebral spinal fluid and brain:

If the nasally administered medication contacts the olfactory mucosa, there is good evidence that suggests molecule transport can occur directly across this tissue and into the cerebral spinal fluid. The olfactory mucosa is located in the upper nasal cavity, just below the cribriform plate of the skull. It contains olfactory cells which traverse the cribriform plate and extend up into the cranial cavity. When medication molecules come in contact with this specialized mucosa they are rapidly transported directly into the brain, skipping the blood-brain barrier, and achieving very rapid cerebrospinal fluid levels (often faster than if the drug is given intravenously). This concept of transfer of molecules from the nose to the brain is referred to as the nose-brain pathway and has implications when centrally acting medications such as sedatives, anti-seizure drugs and opiates are delivered nasally. Multiple authors demonstrate that the nose-brain pathway leads to nearly immediate delivery of some nasal medications to the cerebral spinal fluid, by-passing the blood brain barrier. (Talegaonkar, J Pharm 2004)



Figure(2.7)shows Nose-brain pathway (Talegaonkar, J Pharm 2004)

In summary, the nasal mucosa consists of a highly vascularized surface that easily absorbs many medications directly into the venous circulation. This medication is then transported to the heart and pumped out to the body where it can have its therapeutic effect. Because the absorptive surface is not the intestinal mucosa, the drug never enters the portal circulation and is not subjected to hepatic metabolism – thereby leading to far higher drug levels than oral or rectal medications. In addition, the nose brain pathway across the olfactory mucosal transports some of the nasally delivered medication directly into the CSF and brain – leading to early effects of centrally acting medications.(Westin, 2007)

2.3 pathology :

Nasal septum and its diseases Septal cartilage forms a partition between right and left nasal cavities and provides support to tip and dorsum of cartilagenous part of nose.oSeptal destruction may occur in septal abscess, injuries, tuberculosis, excess removal during SMR leads to depression of lower part of nose and drooping of tip.oSeptal cartilage lies in a groove in the anterior edge of vomer and rests anteriorly on anterior nasal spine.during trauma, it may get dislocated from nasal spine or vomer causing caudal septal deviation and spur respectively (Vinay Bhat ,2012)

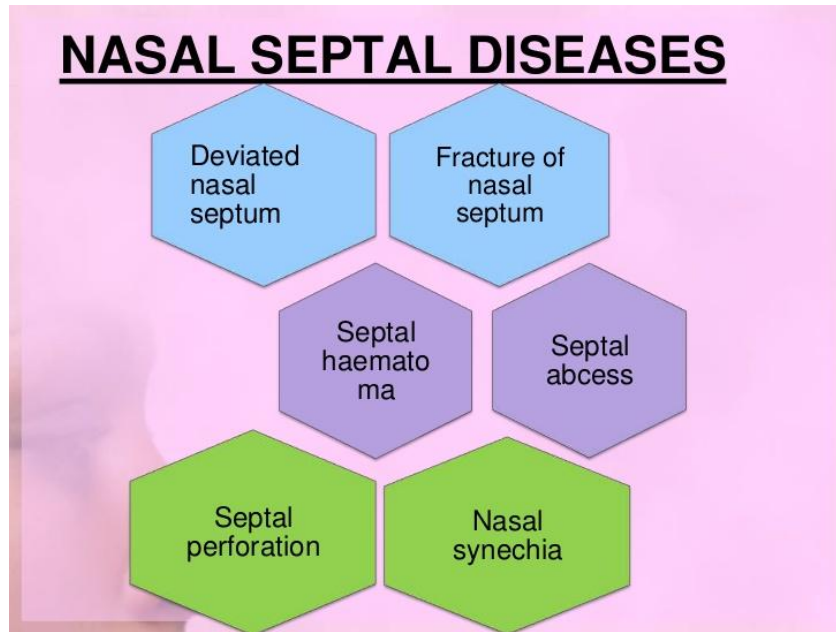


Figure (2.8) shows diagram showing nasal septal diseases (Vishnu Narayanan , 2012)

2.3.1. Fractures of nasal septum:

- Trauma inflicted from front, side or below. the septum may buckle on itself, fracture vertically, horizontally or get crushed.
- fracture of septal cartilage or its dislocation can occur without nasal bones fracture in cases of trauma to lower nose.
- septal injuries with mucosal tears cause profuse epistaxis while with intact mucosa result in septal hematoma.

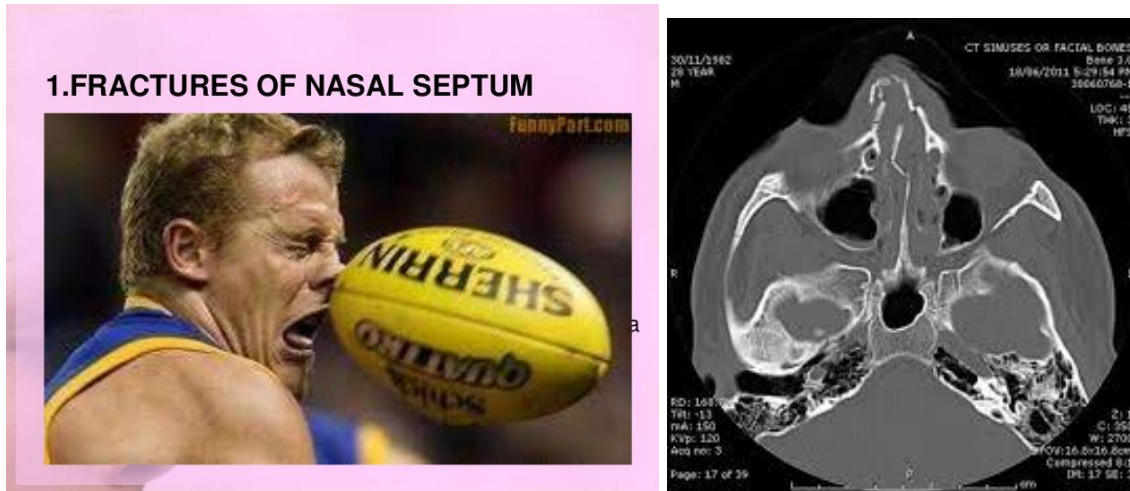


Figure (2.9) shows Fractures of nasal septum (Vishnu Narayanan, 2012)

2.3.1.1 Fractures of nasal septum Types :

1. Jarjaway fracture: result from blow from front. fracture line starts just above the anterior nasal spine and runs horizontally backwards just above the junction of septal cartilage with the vomer.
2. Chevallet fracture: results from blow from below. it runs vertically from anterior nasal spine upwards to the junction of bony and cartilaginous dorsum of nose.

○ Complications Fractures:

- a) deviation of cartilagenous nose.
- b) asymmetry of nasal tip ,columella or nostril.

2.3.2 Deviated Nasal Septum(DNS) :

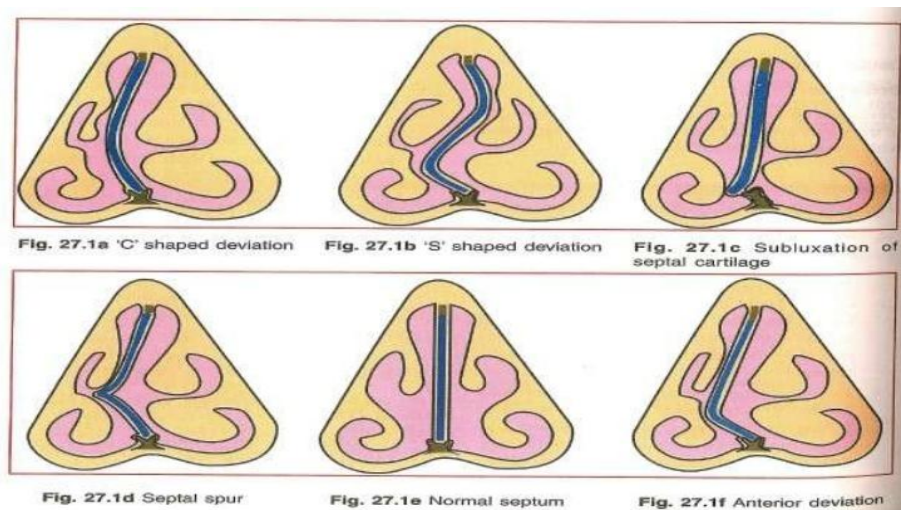
1. Trauma: lateral blow-displacement of septal cartilage from vomer. blow from front-buckling, fracture, duplication of septum with telescoping of fragments.
2. Developmental: the septum should grow at the same rate as that of face. if septum grows at faster rate it becomes buckled. unequal growth

between palate and base of skull may also cause buckling (high arched palate)

3. Congenital: abnormal intrauterine posture cause compressing forces acting on nose and upper jaw.
4. Hereditary
5. Racial: Caucasians are more affected
6. Secondary: to a tumor, mass or poly

2.3.2.1 Deviated Nasal Septum Types:

1. Deviations: upper or lower, anterior or posterior, C shaped, S shaped. nasal cavity on the concave side of the septum will be wider and may show compensatory hypertrophy of turbinates.
2. Anterior Dislocation: seen on tilting the patients head backwards.
3. Spurs: shelf like projection at the junction of bone and cartilage. may predispose for epistaxis and headache.
4. Thickening: it may be due to organized haematoma or over-riding of dislocated septal fragments .(Vinay Bhat ,2012)



Figure(2.10) Deviated nasal septum Types(Vishnu Narayanan in Health & Medicine 2012)

- **Sites of DNS:**

- Cartilagenous/bony/both
- Anterior/posterior
- High/low

- **Types of DNS :**

- Anterior Dislocation
- Septal spur

- **Effects of DNS:**

1. Compensatory hypertrophy of turbinates of opposite side
2. External deformity
3. Impairment of drainage to sinus
4. Secondary atrophic rhinitis

- **Clinical features of DNS:**

- 1 .Nasal obstruction

- Sites :

- 1) Vestibular
- 2) At the nasal valve
- 3) Attic
- 4) Turbinal
- 5) Choanal

- Bilateral/unilateral obstruction

- **Cottle test of DNS :**

Used in nasal obstruction due to abnormality of nasal valve• In this test ,cheek is drawn laterally while patient breathes quietly. If the nasal airway improves on test side ,the test is positive and indicates abnormality of vestibular component of nasal valve

2. Headache

3. Sinusitis

4. Epistaxis

5. Anosmia

6. External Deformity

7. Middle ear Infection

2.3.3 Septal Haematoma:

Collection of blood under the perichondrium or periosteum of nasal septumAetiology

1. nasal trauma

2. septal surgery

3. bleeding disorders

- **Clinical features of Septal Haematoma:**

- Bilateral nasal obstruction and mouth breathing

- Frontal headache

- Sense of pressure over nasal bridge
- Smooth rounded swelling of the septum in both nasal fossae
- Soft and fluctuant mass felt
 - **Complications of Septal Haematoma:**
- Permanently thickened septum
- Septal abscess with necrosis of cartilage and depression of nasal dorsum

2.3.4 Septal Abscess :

- Secondary infection from septal haematoma
- Furuncle of the nose or upper lip
- Acute infection such as typhoid or measles
 - **Clinical feature of Septal Abscess:**
- Severe bilateral nasal obstruction with pain and tenderness over the bridge of nose
- fever with chills and frontal headache
- Skin over the nose -- red and swollen
- smooth bilateral swelling of nasal septum
- Fluctuation elicited
- Septal mucosa – congested
- Submandibular lymph nodes -- enlarged and tender

○ **Complications of Septal Abscess:**

- Depression of the cartilaginous dorsum in the supratip area
- Septal perforation
- Meningitis and cavernous sinus thrombosis

2.3.5.Perforation of Nasal Septum :

1. Traumatic perforation

- Injury to mucosal flaps during SMR
- cauterization of septum with chemicals
- galvanocautery for epistaxis
- Habitual nose- picking

2. Pathologic perforations

- Septal abscess
- Nasal myiasis
- Rhinolith or neglected foreign body
- Chronic granulomatous conditions like Lupus, tuberculosis, leprosy, syphilis
- Wegener's granuloma

3. Drugs and chemicals

- Prolonged use of steroids in nasal allergy
- Cocaine addicts
- Workers in certain occupations. Eg .chromium plating ,dichromate or soda ash manufacture or those exposed to arsenic or its compounds4.Idiopathic

○ **Clinical features of Perforation of Nasal Septum:**

- Small anterior perforation cause whistling sound during inspiration or expiration
- Large perforations develop crusts which obstruct the nose or cause epistaxis when removed

2.3.6 Nasal Synechia :

- Adhesions between septum and lateral wall
- Adhesions between middle turbinate and lateral wall
- Following nasal surgery and nasal packing
- Nasal obstruction
- Sinusitis and headache (Vishnu Narayanan ,2012)

2.3.6 Atrophic Rhinitis:

Type of rhinitis caused by thinning nasal membranes can be caused by aging, sinus surgery and prolonged nasal infection..The following conditions have been cited in various sources as potentially causal risk factors related to Atrophic rhinitis:

- Aging
- Menopause
- Infections

The list of treatments mentioned in various sources for Atrophic rhinitis includes the following. Always seek professional medical advice about any treatment or change in treatment plans.

- Antibiotic ointments
- Estrogens
- Vitamin A
- Vitamin D
- Topical vitamin A
- Topical vitamin D
- Nasal lambswool plug

(http://www.rightdiagnosis.com/n/nose_conditions/intro.htm)

2.3.5 Catarrh and Nasal Congestion:

For most people, colds or flu go away and they feel fine after a few days or so. Some people, however, are left with catarrh - unpleasant nasal congestion with a build-up of mucus, usually in the nose, throat, ears or chest. Catarrh can also be caused by hayfever (allergic rhinitis), other allergies or fleshy swellings in the nose called polyps.

○ Diagnosing catarrh:

Catarrh is difficult for doctors to diagnose as it affects different people in different ways. The Royal College of Surgeons for England/ENT.UK says some people call catarrh the feeling of mucus at the back of their nose. Others say it is a build-up of phlegm in their throat. It may be the need to keep clearing the throat for other people. Other symptoms may include blowing the nose having no effect, throat discomfort, crackling noises in the

ears, constantly feeling like something is stuck in the throat, a persistent cough or feeling sick. Some people may experience facial pain from their blocked nose and sinuses; the senses of smell and taste may also be affected. People who get catarrh may suffer from it for many years (chronic catarrh) and find it gets worse when they have a cold or flu. ENT.UK says patients seem to have one of two types of catarrh:

- Excessive mucus running out of the nose
- Excess mucus they are unable to clear

(Medically Reviewed by Dr Rob Hicks on August 16, 2013)

2.4 Images modalities of nasal septum and Para nasal sinuses :

2.4.1 X ray :

Pathology Demonstrated; Inflammatory conditions and sinus polyps/cysts are shown.

a) Water's view:

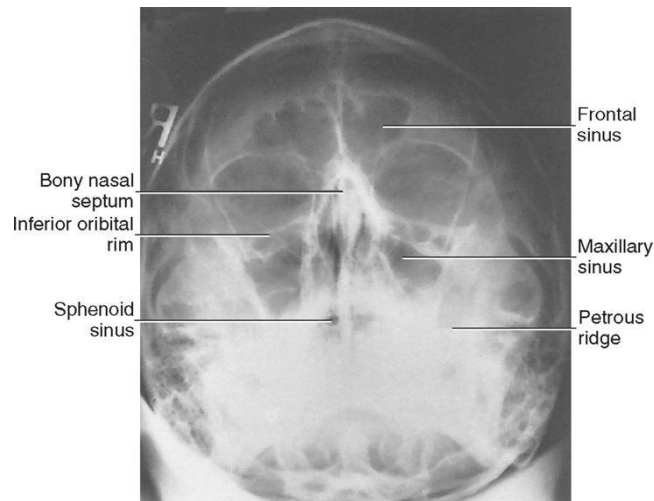
○ Part Position:

- Extend neck, placing chin and nose against table/upright Bucky surface.
- Adjust head until MML is perpendicular to IR; OML will form a 37° angle with the plane of the IR.
- Position the MSP perpendicular to the midline of grid or table/upright Bucky surface.
- Ensure that no rotation or tilt exists.
- Center IR to CR and to acanthion.

○ Central Ray:

- Align a horizontal CR perpendicular to the IR centered to exit at the acanthion.

- Minimum SID is 40 inches (100 cm).



Figure(2.11)Waters view image(Prof. J. Stelmark , 2012)

b) Caldwell view:

○ Part Position:

- Place patient's nose and forehead against upright Bucky or table with neck extended to elevate the OML 15° from horizontal. A radiolucent support between forehead and upright Bucky or table may be used to maintain this position. CR remains horizontal. (alternate method if Bucky can be tilted 15° .)

- Align MSP perpendicular to midline of grid or upright Bucky surface.

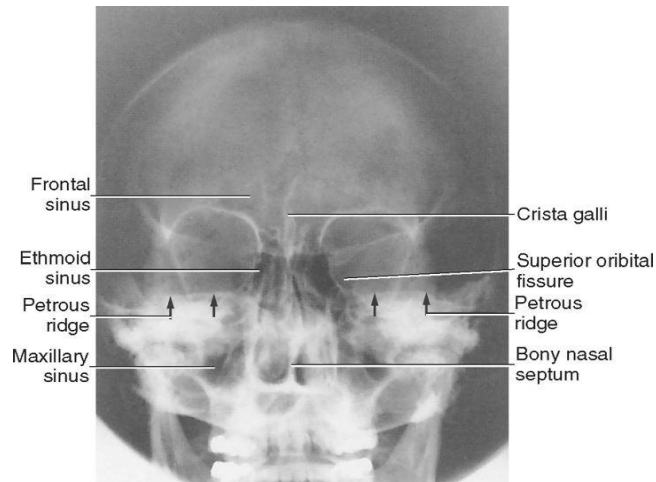
- Center IR to CR and to nasion, ensuring no rotation.

○ Central Ray:

- Align CR horizontal, parallel with the floor.

- Center CR to exit at nasion.

- Minimum SID is 40 inches (100 cm). (Prof. J. Stelmark , 2012)



Figure(2.12)Caldwell view image(Prof. J. Stelmark , 2012)

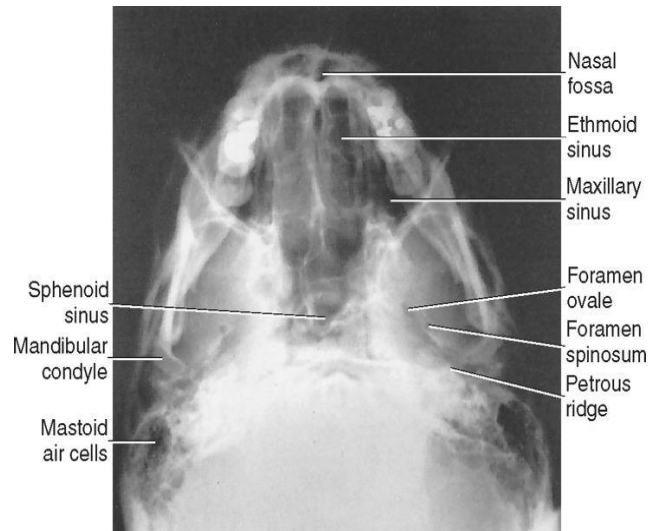
c) Submento vertex view (SMV):

○ Part Position:

- Raise chin, hyperextend neck if possible until IOML is parallel to table/upright Bucky surface.
- Head rests on vertex of skull.
- Align MSP perpendicular to midline of the grid or table/upright Bucky surface; ensure no rotation or tilt.

○ Central Ray:

- CR directed perpendicular to IOML
- CR centered midway between angles of mandible, at a level 1½ to 2 inches (4 to 5 cm) inferior to mandibular symphysis
- CR centered to IR
- Minimum SID of 40 inches (100 cm)



Figure(2.13)Submento vertex view image(Prof. J. Stelmark , 2012)

2.4.2 CT procedure and sections :

CT is currently the modality of choice in the evaluation of the paranasal sinuses and adjacent structures. Its ability to optimally display bone, soft tissue, and air provides an accurate depiction of both the anatomy and the extent of disease in and around the paranasal sinuses. In contrast to standard radiographs, CT clearly shows the fine bony anatomy of the osteomeatal channels.

a course of adequate medical therapy to eliminate or diminish reversible mucosal inflammation. pretreatment with a sympathomimetic nasal spray 15 minutes prior to scanning in order to reduce nasal congestion (mucosal edema) and thus improve the display of the fine bony architecture and any irreversible mucosal disease. The coronal plane best shows the ostiomeatal unit (OMU), shows the relationship of the brain to the ethmoid roof. Coronal plane should be the primary imaging orientation for evaluation of the sinonasal tract in all patients with inflammatory sinus disease who are endoscopic surgical candidates .

2.4.2.1 Coronal section procedure:

- 1) Prone with chin hyper extended
- 2) Gantry angulations- perpendicular to hard palate
- 3) Section thickness-3mm contiguous
- 4) Table increment- 3-4 mm each step
- 5) Kvp-125
- 6) Mas-80
- 7) Hanging head technique
 - **Head hanging method:**

Performed in the prone position, so that any remaining sinus secretions do not obscure the OMU . In patients who cannot tolerate prone positioning (children, patients of advanced age, etc.), the hanging head technique can sometimes be utilized.

In this technique, the patient is placed in the supine position and the neck is maximally extended. A pillow placed under the patient's shoulders facilitates positioning. The CT gantry is then angled to be perpendicular to the hard palate. It is not always possible to obtain true direct coronal images with this technique

2.4.2.2 Axial images :

complement the coronal study, particularly when there is severe disease (opacification) of any of the paranasal sinuses and surgical treatment is contemplated. The axial studies provide the best CT evaluation of the anterior and posterior maxillary sinus walls . Axial images are particularly important in visualizing the frontoethmoid junction and the sphenoethmoid recess. Whenever there is total opacification of the frontal, maxillary, or

sphenoid sinuses, a complete axial and coronal CT examination should be performed. And also, if the patient has a suspected neoplasm, a complete axial and coronal examination need to be performed to provide the most detailed analysis of the sinonasal cavities and the adjacent skull base

Contrast is not required for all cases of CT paranasal sinus. Used in cases such as vascular lesion, malignancy, mass extending intra cranially and for acute infections. (Prasanna Kumaravel , 2014)

2.4.3 MRI :

Is predominantly used for pre and post operative management of naso sinus malignancy The chief disadvantage of MRI is its inability to show the bony details of the sinuses, as both air and bone give no signal (Prasanna Kumaravel in Education 2014)

- **Equipment of MRI brain image:**

- Head Coils:

- Surface coils for brain imaging usually consist of two types:

1. Single-channel transmit/receive coils
2. High-channel phased array coils.

- Immobilization pads and straps

- Ear plugs

- High performance gradients for EPI (Eco planer Imaging), diffusion and perfusion imaging.

- **Patient preparation:**

- Before preparation, complete history should be checked. If indication is unclear, the referring physician should be contacted.
- All metallic objects should be removed from patient body to ensure that artifacts are not created during scanning.
- Disposable ear plugs should be provided to the patient to devoid the patients from repeated noises during scanning.
- The patient should be instructed to avoid coughing, wriggling or producing other large motion during or in between the scans.
- Ensure the IV line prior to the precontrast acquisition preferably with 20 or 22 gauge IV canula.
- Patient who present with claustrophobic features may require sedation with diazepam/ alprazolam/ midazolam.

- **Contrast Media:**

- Gadolinium-based contrast enhancement is useful in brain imaging.
- Physicians often believe that administration of contrast is indicated for all lesions.
- Three conditions must be met in order for contrast enhancement to occur:
 1. An adequate blood supply to the lesion must exist
 2. Blood-brain barrier breakdown must be present
 3. Sufficient extracellular space must be available for the contrast agent to localize after it has leaked out of the vasculature

- In cases in which lesions do not enhance, the lack of enhancement in and of itself provides useful clinical information

- IV Gadolinium: 0.1-0.2 mmol/kg body weight

- given as a bolus at the rate of 1 ml/sec or

- as a slow infusion at the rate of 1 ml/6 sec.

- **Patient Positioning:**

- Supine with head placed within the coil.

- Arms beside the trunk.

- Interpupillary line parallel to the couch and the head should be straight.

- Longitudinal alignment line in the midline.

- Horizontal alignment line through the nasion.

- Straps and foam pads for immobilization. 9/3/2013 10MRI Brain by Sudil

- **Routine Brain Protocol:**

- **Sequences:**

1. Scout : 3 plane localiser

2. T2 FSE in axial plane

3. T2 FLAIR in axial plane

4. T1 SE in sagittal and coronal plane

5. DW EPI based in axial plane

6. Post contrast T1 SE in the axial and coronal plane. (Sudil Paudyal, 2013)

2.5 Previous studies :

Ansu Sam ETAL 2012,had studied the deviated nasal septum in order of 100 consecutive patients to analyze association of septal deviation with external nasal deformity in indian . 66% of the patients with deviated nasal septum were symptomatic while 34% lacked symptoms. they looked at a total of 100 patients in the age group of 16–65. Mean age of the patient was 34.7 years. Maximum number of patients were in the age bracket of 31–40 (34%) followed by 29% in the age group of 21–30 . 63 patients (63%) were males and 37 (37%) were females. Male to female ratio was thus 1.7:1. noted concha bullosa in 18%, accessory ostium in 8% and paradoxical middle turbinate in 6%. Noteworthy finding of their study is 11% of their patients had chronic suppurative otitis media (8% unilateral and 3% bilateral).

AlirezaMohebbi ,ETAL 2012,had studied about An epidemiologic research of factors associated with nasal septum deviation by computed tomography scan. Two trained resident of ENT evaluated sinus CT scans of 463 cases presenting with nasal obstruction or chronic sinusitis symptoms from April 2011 to December 2011. Of 463 cases, 47% had septal deviation. Concha bullosa was seen in 16.8% of the patients in the left side and 27.6% of them in the right side by this study, the relationship between concha bullosa in osteomeatal complex and the severity of sinusitis was not cleared. No relationship between the severity of sinusitis, osteomeatal involvement and the degree of septal deviation..

FatmahBanaz, et al 2014,their studied of Prevalence of deviated nasal septum among adults in Jeddah, Saudi Arabia: Age and gender difference.The study included 378 patients. Their age ranged between 19 and 67 years with a mean of 41.8 ± 12.7 years.Female patients represent 57.4% of the participants. The prevalence of DNS among patients who underwent CT PNS was 88.9%. The prevalence was slightly higher in male compared to female patients (91.9% versus 86.6%). $p=0.106$. Regarding their age, the mean age of patients with no DNS was slightly higher compared to those with DNS (42.9 ± 11.0 versus 41.7 ± 12.9 years) with no significant differences. The bony deviation is the most reported type either unilateral (75.9%) or bilateral (6.6%) followed by cartilaginous deviation either unilateral (54.5%) or bilateral (2.4%) and lastly maxillary crest deviation only unilateral (43.7%). The prevalence of Nasal septal deviation among adult Saudi population is high. The crude and type-specific prevalence were more reported among male patients and the occurrence of the posterior deformities (bony-type) was more reported than cartilaginous type among adult population.

Abhinandan Bhattacharjee, 2005 . A prospective studied of Deviated nasal septum in the newborn—A 1-year .200 newborn babies was done at Silchar Medical College Hospital in indian. The babies aged from 0 to 4 days were taken in the study. In the study, the incidence was found to be 14.5% (29 cases).It was found that high-birth weight babies, delivered by vaginal route (55%), to a primi mother are more likely to have DNS after birth. Moreover, intrauterine malposition particularly breech (45%) and prolonged labour seemed to play a role in newborn DNS. Therefore, a

policy of routine screening in view of early correction is advocated to decrease the morbidity associated with nasal septal deviation in newborns.

Niña Eliza R. Pernia, ETAL (2011). Their studies aimed to measure the dimensions of the nasal septal cartilage in adult Filipino Malay cadavers. Ten preserved adult cadavers dissected within a period from September 2010 to October 2010. The septal cartilages were harvested and the lengths of the cephalic margin, dorsal margin, caudal margin and ventral margin were measured. From these measurements, the total area of the cartilage and the amount of graft material that can be harvested were calculated. The mean length of each margin of the septal cartilage was 25.9mm (cephalic edge), 22.3 mm (dorsal edge), 21.4mm (caudal edge) and 33.1 mm (ventral edge). The area of the septal cartilage had a mean value of 652.5 mm. The amount of septal cartilage which can be harvested had a mean area of 403mm. This study showed a slight decrease in septal cartilage area to 652.5 mm. and in available graft material to 403 mm.

Rarinthorn Samrid, ETAL. Their research of the Nasal Septum in North-East Thai Cadavers. The fifty-four nasal septum's of North-East Thai cadavers (35 males and 19 females), who donated the healthy bodies for anatomy department. This study showed that the average age of the nasal septum analyzed Thai cadavers was 66 years (ranged from 23 to 97 years); there are 67.85 ± 16.12 years in males and 64.31 ± 16.31 years in females. In addition, the total area of the nasal septum in both sexes was $2,180.02 \pm 351.45$ mm. Their study found that the nasal septum areas (both total and individual) of males were significantly larger than those of females.

Chapter Three

Materials and methods

The data used in this disruptive Analytics study were collected from department of radiology ,Ibn Alhaitham center and Roial care hospital. Data of the patients under gone CT examination were taken during August 2014 up to 1 November 2014

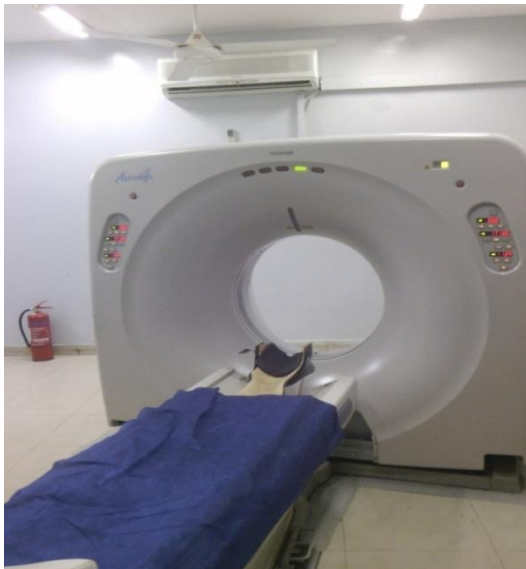3.1 materials:

3.1.1 Patients :

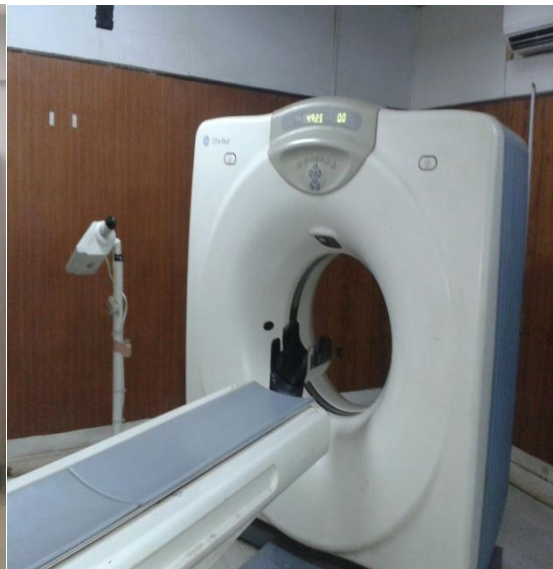80 Sudanese adult patients (40 male –40 female) ,patient age range between (15-80years),underwent computed tomography examination for sinuses .In this range of age the septum completed the process of development.

3.1.2 CT machine characteristics :

In This study use (dual) machine and multi slice CT scanner 64 slice(Toshiba).the gantry and table allows for a 120 cm scan range. It is also equipped with positioning lights .



Figure(3.1)CT Toshiba machine
used in Ibn Alhaytham medical center



Figure(3.2)CT (dual)machine
used in Modern Medical center

3.2 Methods of scanning :

CT scans typically obtained for visualizing the paranasal sinus should include coronal and axial (3-mm) cross sections. Soft tissue and bony windows facilitate evaluation of disease processes and the bony architecture. Proper positioning of the patient's head is important to obtain CT images. We reposed the patient positioned lying flat on the back and pillows may be used to help the patient maintain the correct position and to hold still during the exam.

For axial views, the patient's hard palate is placed perpendicular to the CT scanner table. The images must be captured such that the external auditory canal is in line with the inferior orbital rim. The coronal images are taken so that the gantry is perpendicular to the patient's hard palate. Misalignment or rotation can lead to distortion of the true anatomy on the films.

Next, the table were move quickly through the scanner to determine the correct starting position for the scans. Then, the table were moved slowly through the machine as the actual CT scanning was performed. Depended on the type of CT scan, the machine may make several passes. we asked patient to hold breath during the scanning. Any motion, whether breathing or body movements, can lead to artifacts on the images. This loss of image quality can resemble the blurring seen on a photograph taken of a moving object. When the examination is completed, we asked the patient wait until the we verified that the images are of high enough quality for accurate interpretation. The actual CT scan takes less than a minute and the entire process is usually completed within 10 minutes (A John Vartanian, 2014)

3.3 Methods measurement:

The study took place in Khartoum state with permission from different hospitals and centers ,Ibn Alhaytham medical center and Royal care hospital .the study was conducted during the period from August to November 2014. The data were analyzed using excel program and simple frequency tables . All images of the study are measured and analized of length of nasal septum and RT,LT distance between the septum and medial border of maxillary sinuses in coronal section (figure3.3)

RT,LT distance between the septum and medial border of maxillary sinuses in axial section (figure3.4). all this measurements done and completed by the researcher .

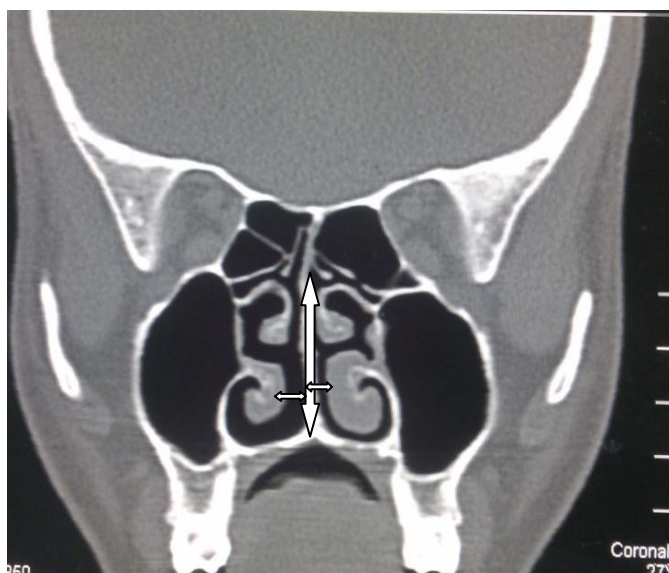


Figure (3.3)Measurement of nasal septum and RT,LT distance between the septum and medial border of maxillary sinuses in coronal section

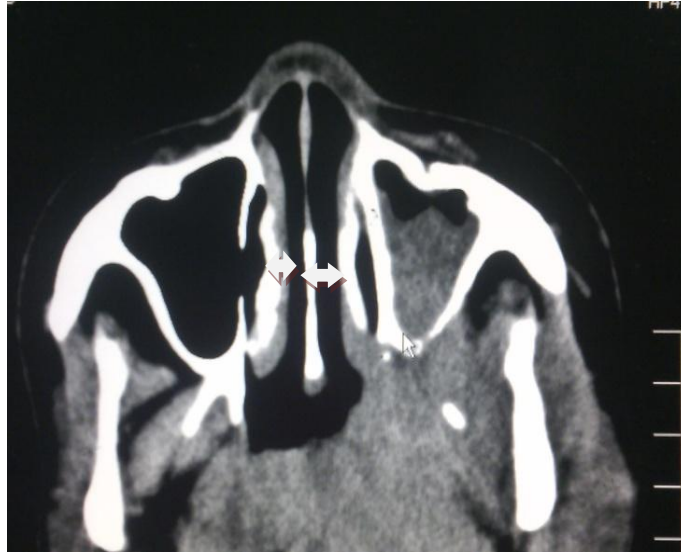

Figure (3.4) Measurement RT,LT distance between the septum and medial border of maxillary sinuses in axial section

Chapter four

Results

The following tables and figures presented the data obtained from 80 patients who were examined for axial and coronal CT brain. The Nasal septum length, The distance from the right nasal septum to right maxillary bone, and the distance from the nasal septum and LT maxillary bone in both coronal and axial cuts were measured. Patient's age and gender have also been registered. The data were analyzed using Excel programme. Frequency tables mean and standard deviations were presented.

Table 4.1 The distribution of the sample according to gender

Gender	Frequency	Percentages
Male	40	50%
Females	40	50%
Total	80	100%

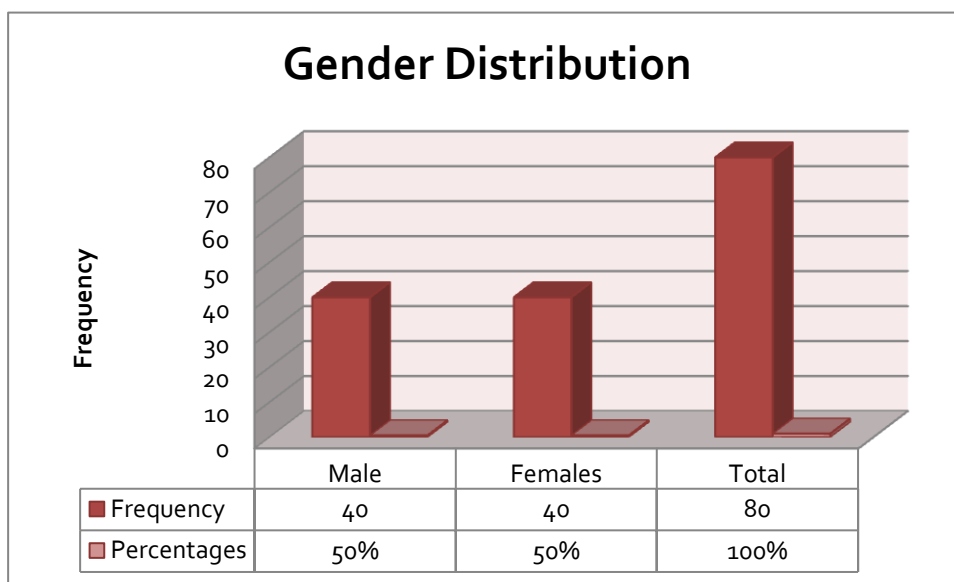


Figure 4.1 Gender distribution and percentages.

Table 4.2 Classification of Sample according to age(frequency and percentages)

Age Classes	Frequency	Percentages%
17-27	22	27.4
28-38	27	33.8
39-49	15	18.8
50-60	12	15.0
61-71	4	5.0
Total	80	100

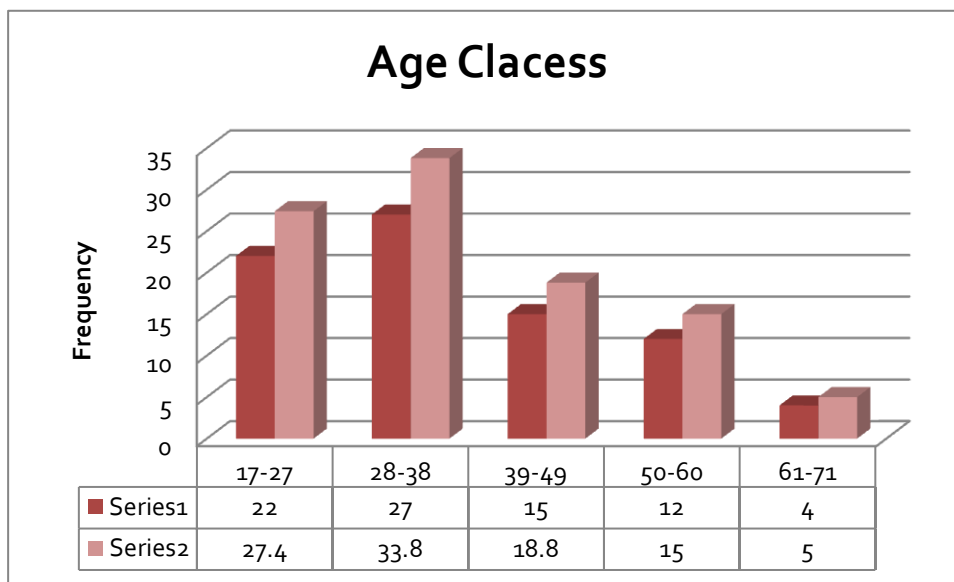


Figure 4.2 Age classes, frequency and percentages.

Table 4.3 Classification of Sample Variables according to gender

gender	Age	SL	C D1(RT)	C D2(LT)	A D1(RT)	A D2(LT)
Females	32.82	27.14	2.70	2.75	2.95	3.08
	±11.9	±1.92	±0.32	±0.37	±0.41	±0.43
Males	41.4	28.35	2.91	2.96	3.26	3.37
	±13.1	±3.37	±0.53	±0.57	±0.63	±0.62
P-Value	0.000	0.024	0.059	0.052	0.058	0.012

*Correlations are significant at p=0.05(There are significant differences between the males and females ages)

*SL cut for nasal septum ,C D1(RT) distance between nasal septum and RT medial border of maxillary sinuses in coronal section , C D1(LT) distance between nasal septum and LT medial border of maxillary sinuses in coronal section, A D1(RT) distance between nasal septum and RT medial border of maxillary sinuses in axial section, A D1(RT) distance between nasal septum and RT medial border of maxillary sinuses in axial section.

Table 4.4 The difference between measurements in both techniques (axial and Coronal),mean and standard deviations

Variable	C D1(RT)	A D1(RT)	C D2(LT)	A D2(LT)
Mean	2.81	3.11	2.86	3.22
STDV	±0.5	±0.6	±0.5	±0.6
P-value	0.057		0.036	

* significant at p=0.05(there are significant difference between the measurements done in axial or coronal)

*SL cut for nasal septum ,C D1(RT) distance between nasal septum and RT medial border of maxillary sinuses in coronal section , C D1(LT) distance between nasal septum and LT medial border of maxillary sinuses in coronal section, A D1(RT) distance between nasal septum and RT medial border of maxillary sinuses in axial section, A D1(RT) distance between nasal septum and RT medial border of maxillary sinuses in axial section.

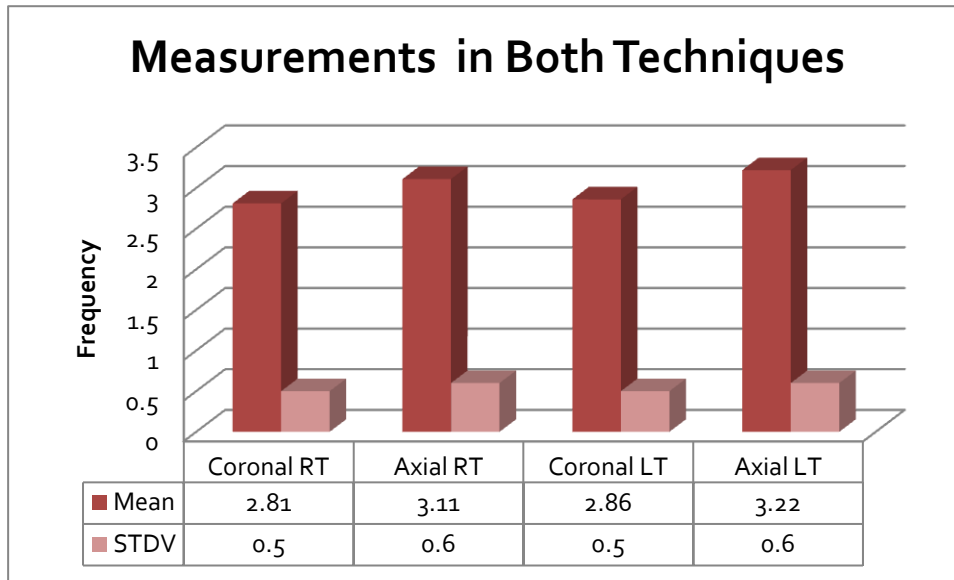


Figure 4.3 The measurements of the variables in both techniques (axial and Coronal)mean and standard deviation

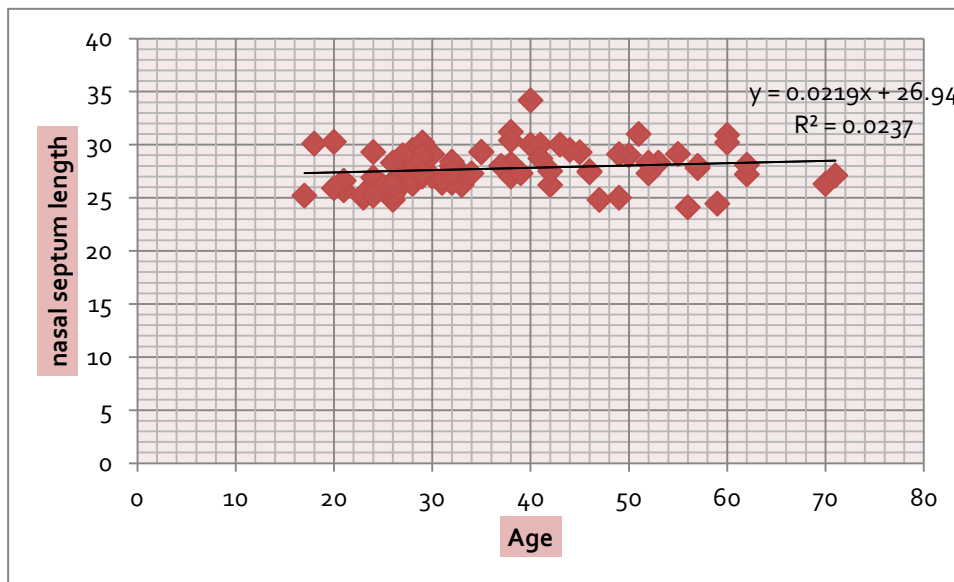


Figure 4.4 A Scatter plot diagramme shows the linear relationship between the age and nasal septum length the equation showed that as the age increase the nasal septum increase by 0.021 starting from 26.9mm/year, $r^2=0.023$

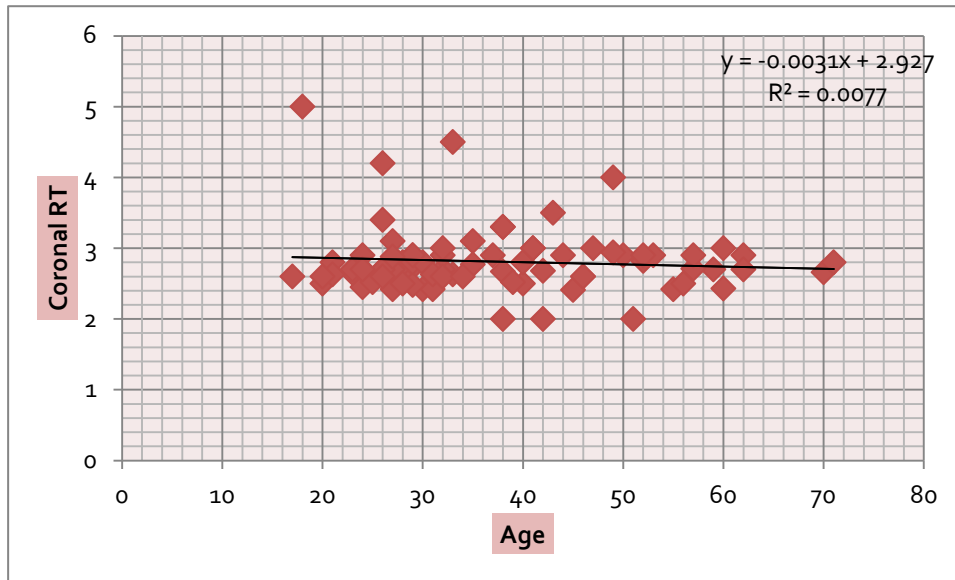


Figure 4.5 A Scatter plot diagramme shows the linear relationship between the age and nasal Coronal RT the equation showed that as the age increase the coronal RT measurementsdecreases by 0.003 starting from 2.9mm/year, $r^2=0.007$

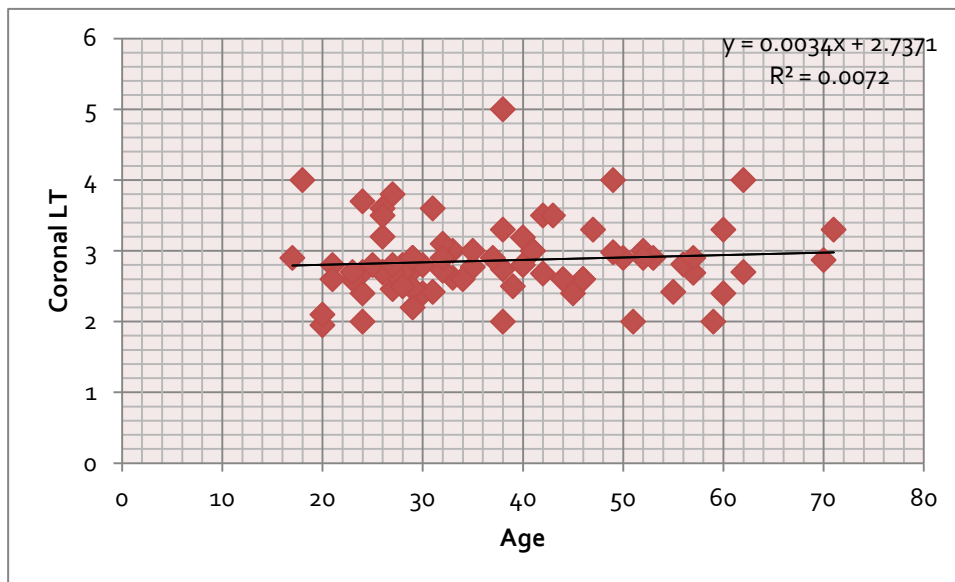


Figure 4.6 A Scatter plot diagramme shows the linear relationship between the age and nasal Coronal LT the equation showed that as the age increase the coronal LT measurementsincreases by 0.003 starting from 2.7mm/year, $r^2=0.007$

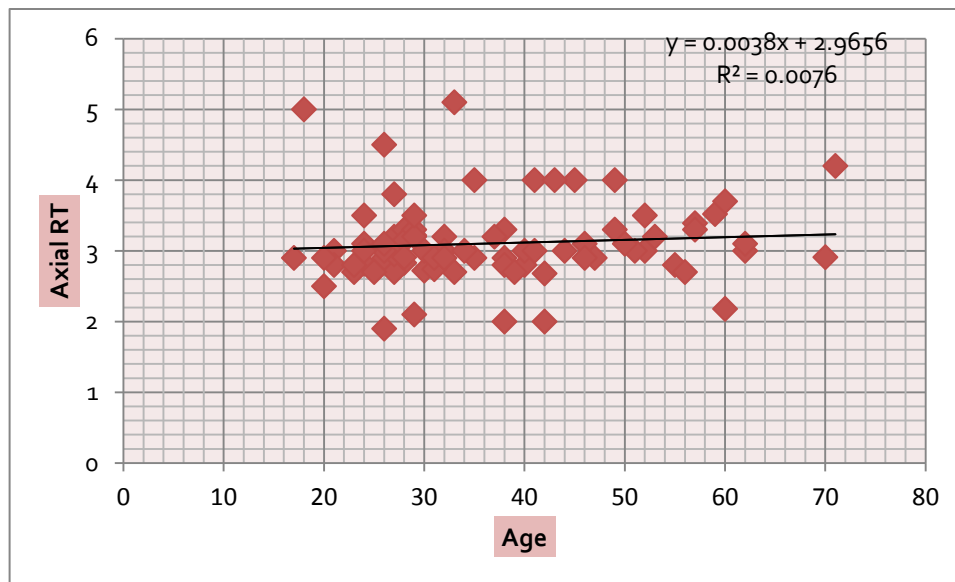

Figure 4.7 A Scatter plot diagramme shows the linear relationship between the age and nasal Axial RT the equation showed that as the age increases the axial RT measurements increases by 0.003 starting from 2.965mm/year, $r^2=0.007$

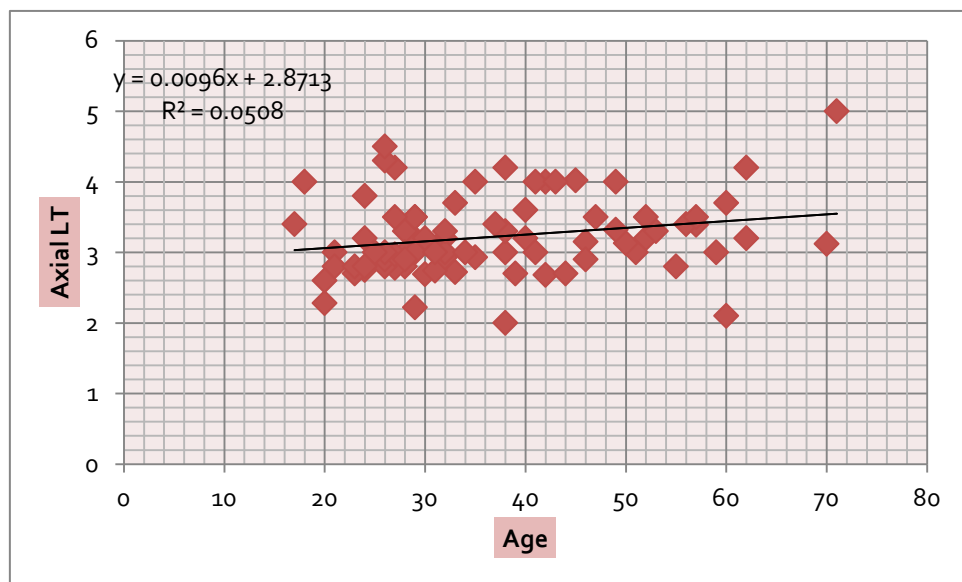


Figure 4.8 A Scatter plot diagramme shows the linear relationship between the age and nasal Axial LT the equation showed that as the age increases the Axial LT measurements increases by 0.009 starting from 2.871mm/year, $r^2=0.0$

Chapter five

Discussion, conclusion, and recommendations

5.1 Discussion :

This study was done for 80 adult Sudanese patient using the CT scan in order to find out an index for nasal septum measurement for Sudanese .in this study , 50% of the patients were males and 50% of the patients were females, the data were collected for patients age between 17-71 years.

The length of nasal septum and distance between nasal septum and RT,LT medial border of maxillary sinuses in axial and coronal section measured in (mm) and were correlated with patients ages and gender.

Maximum age group was age between (28-38) 27(33.8 %). In another study done by Ansu Sam, et al 2012 regarding the measurement of the nasal septum using CT scan. Measurements found that the mean age of the patient was 34.7 years. Maximum number of patients were in the age group of 31–40 (34%)

This study showed that the mean of patient ages was 41.4 ± 13.1 for (males) and 32.82 ± 11.9 for (females). Classification of sample variables according to gender were studied, Correlations are significant at $p=0.05$ (There is a significant difference between the two genders in age and all of the measured variables)as presented in table (4.3)

In Table (4.4)

The difference between measurements in both techniques (axial and Coronal) were evaluated, mean and standard deviations were taken.

Significant difference between the measurements done in axial or coronal was found at $p=0.05$

The relationship between the age and nasal septum length, showed that as the age increase the nasal septum increase by 0.021 starting from 26.9mm/year, $r^2=0.023$,as presented in figure 4.3

The relationship between the age and nasal Coronal RT, showed that as the age increase the coronal RT measurements decreases by 0.003 starting from 2.9mm/year, $r^2=0.007$, as presented in figure 4.4 .

In The relationship between the age and nasal Coronal LT , figure 4.5 showed that as the age increase the coronal LT measurements increases by 0.003 starting from 2.7mm/year, $r^2=0.007$,

In The relationship between the age and nasal Axial RT , figure 4.6 showed that as the age increases the axial RT measurements increases by 0.003 starting from 2.965mm/year, $r^2=0.007$.

The correlation between the age and nasal Axial LT, showed that as the age increases the Axial LT measurements increases by 0.009 starting from 2.871mm/year, $r^2=0.050$,as presented in figure 4.7 .

Our justification about the difference between the measurements done in both techniques is that it may be due to measurements error because the some patients were examined using 2 CT machines ,one is old and another is new multi detector generations and the image quality was poor and the starting point and ending points of measurements were unclear as well as some patients have some sort of changes in the nose but they were not diagnosed as diseased or with deviated nasal septum. therefore the

suggestion to emit these unclear cases is an important issue and these may change the results

5.2 Conclusion :

From these results, the study concluded the following:

- CT sinuses can be used as tool to determine the precise details measurement of nasal septum .
- male has greater measurements than females
- there are linear relationship between the patient age and the selected variables

Sudanese index was developed for nasal septum measurements

5.3 Recommendation:

The researcher recommended that:

- More research should be used a large sample of patient for further assessment.
- Use the most recent CT machine with high quality of images without technical errors
- any doubt about any abnormal cases should be avoided although they were diagnosed as normal in order to avoid the limitations of this study.
- add additional imaging method to confirm the results

Audition of coronal section from axial section .

Categorize of Sudanese according to tribal and increase the number of patients in each group.

Consolidation Usage one device.

Additional tow person for reading.

Reference :

Ansu Sam, Prasad T. Deshmukh 2012 ,Deviated nasal septum with external
nasal deformity in Indian

Alireza Mohebbi , Aslan Ahmadi , Maryam Etemadi 2012,

An epidemiologic study
of factors associated with nasal septum deviation by computed tomography
scan

1. Fatmah Banaz, Talal Alandejani. Saudi Arabia2014

study of Prevalence of deviated nasal septum among adults in Jeddah

2. Abhinandan Bhattacharjee, Indian 2005 . A prospective study of Deviated
nasal septum in the newborn

3. Niña Eliza R. Pernia, MDJoseph Amado C. Galvez, MDFrancisco A.Victoria,
MD (2011)This study aimed to measure the dimensions of the nasal septal
cartilage in adult Filipino Malay cadavers.

4. Justin H. Turner, M.D., Ph.D.(2011), Nasal Anatomy .

5. Karl Edward Swenson (2012) , nasalseptaldeviationin

6. alongitudinal growthsample

7. Dr Rob Hicks on August 16, 2013 ,Medically Reviewed

8. <http://www.radiologyinfo.org/en/info.cfm?pg=sinusct>

9. http://care.americanrhinologic.org/nasal_anatomy

10. http://care.americanrhinologic.org/septoplasty_turbinates?print
11. http://en.wikipedia.org/wiki/Nasal_septum
12. http://www.rightdiagnosis.com/n/nose_conditions/intro.htm
13. <http://www.slideshare.net/drvinaybhat/nasal-septum-and-its-diseases>

The Appendix(A):

Sudan University of Science and Technology

Faculty of Graduation Studies

MSc Diagnostic Radiologic Technology

Research About:

**Characterization of nasal septum in Sudanese patients using
computed tomography**

Data collection sheet (questionnaires)

Pt data :

- Pt number:
- Age:
- Gender:

Male

femal

Dimention of nasal septum :

- SL: mm

***Cronal Section measurement :**

- C D1(RT): mm
- C D1(LT): mm

***Axial Section measurement :**

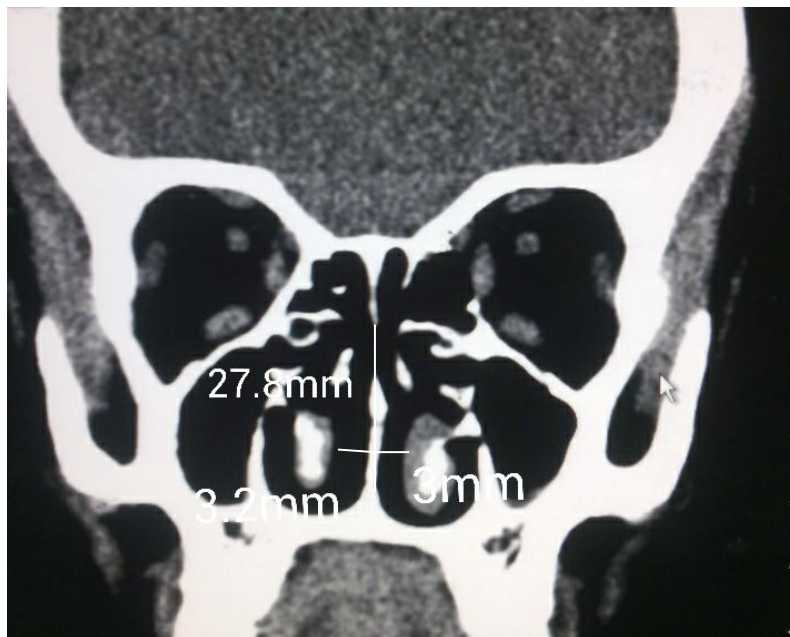
- A D1(RT) : mm

- A D1(LT): mm

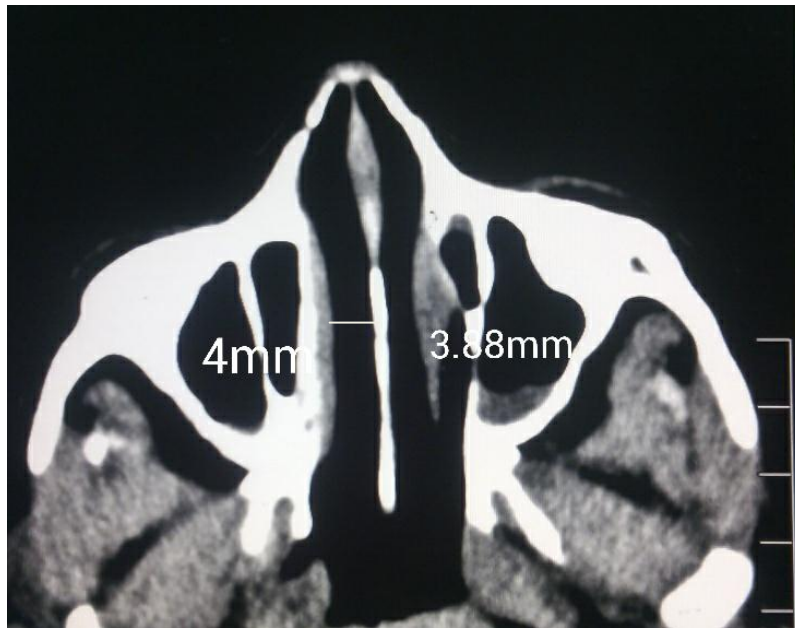
*SL cut for nasal septum ,C D1(RT) distance between nasal septum and RT medial border of maxillary sinuses in coronal section , C D1(LT) distance between nasal septum and LT medial border of maxillary sinuses in coronal section, A D1(RT) distance between nasal septum and RT medial border of maxillary sinuses in axial section, A D1(LT) distance between nasal septum and LT medial border of maxillary sinuses in axial section.

The Appendix(B):

From my measurement



Coronal section of CT sinuses image



Axial section of CT sinuses image

