Sudan University of Science & Technology

Collage of Graduate Studies

Study of Malignant Breast Tumors using Ultrasound

دراسة أورام الثدي الخبيثه باستخدام الموجات فوق الصوتيه

A thesis submitted for partial fulfillment of the requirements for the Msc degree in Medical Ultrasound.

By:

Amjad Abdel hlim Ahmed Abdella

Superviser :

Dr:Alssafi Ahmmed Abdella

2014

الاية

بسم الله الرحمن الرحيم

قال تعالى :

[قُلْ مَن رَّبُّ السَّمَاوَاتِ وَالأَرْضِ قُلِ اللَّهُ قُلْ أَفَاتَّخَذْتُم مِّن دُونِهِ أَوْلِيَاء لاَ يَمْلِكُونَ لِأَنفُسِهِمْ نَفْعًا وَلاَ ضَرًّا قُلْ هَلْ يَسْتَوِي الأَعْمَى وَالْبَصِيرُ أَمْ هَلْ تَسْتَوِي الظُّلُمَاتُ وَالنُّورُ أَمْ جَعَلُواْ لِلَّهِ شُرَكَاء خَلَقُواْ كَخَلْقِهِ فَتَشَابَهَ الْخَلْقُ عَلَيْهِمْ قُلِ اللَّهُ خَالِقُ كُلِّ شَيْءٍ وَهُوَ الْوَاحِدُ الْقَهَّارُ * أَنزَلَ مِنَ السَّمَاء مَاء فَسَالَتْ أَوْدِيَةٌ بِقَدَرِهَا فَاحْتَمَلَ السَّيْلُ زَبَدًا رَّابِيًا وَمِمَّا يُوقِدُونَ عَلَيْهِ فِي النَّارِ ابْتِغَاء حِلْيَةٍ أَوْ مَتَاعٍ زَبَدٌ مِّثْلُهُ كَذَلِكَ يَضْرِبُ اللَّهُ الْحَقَّ وَالْبَاطِلَ فَأَمَّا الزَّبَدُ فَيَذْهَبُ جُفَاء وَأَمَّا مَا يَنفَعُ النَّاسَ فَيَمْكُثُ فِي الأَرْضِ كَذَلِكَ يَضْرِبُ اللَّهُ الأَمْثَالَ]

صدق الله العظيم

سورة الرعد

الايات 16 - 17

Dedication

This work is dedicated with great appreciation and gratitude to

My dear parents, abdel hleim and sittanissa.

All my teachers and mentors, particularl Dr. alsaffi Dr mohammed alfadil,whose magnificent research, and Dr. Ahmed Almusstafa.

Acknowledgement

I am most of all grateful to the God almighty, who made me able to fulfill this master program in spite of all problems and pressures. My supervisor Dr .Alssafi deserves all my gratitude as I could not have made it through without his valuable support. He was always there when I needed help.

I will like to thanks Dr Mustafa Alamen at The(Antalia) center who took time for me and gave me valuable information and was cooperative whenever needed his advice. I would also like to thanks other people that were involved indirectly in providing information related to my thesis .Not least am grateful for support and encouragement from all my teachers specially Dr Mohammed Alfadil , who commented and advised me during my work, Dr A hammed Al musstafa & Dr naagi

Abstract

From February 2014 to November 2014 inclusive, (200) patients presented for breast imaging and of these, (100) formed the study group , All patients in the study group were imaged with breast ultrasound. There was inclusive and exclusive data due to the lack of required information.

The appearance of specific types of breast carcinoma has been studied. Although appearances vary greatly, some patterns are typical,, Mucin-containing carcinomas are often circumscribed but may have irregular margins. These lesions may be either hypoechoic or isoechoic relative to subcutaneous fat.

Statistical measures of accuracy, sensitivity, specificity, positive predictive (PPV) and negative predictive values (NPV) were calculated using 2x2 contingency tables. The ultrasound examinations were performed by Toshiba Xario (Toshiba Corporation, Tokyo, Japan) and sono scape .

The ultrasound scan was performed in a radial pattern, beginning at the periphery of the breast and moving inward. Each quadrant was scanned with overlap at the 12-, 3-, 6- and 9-o'clock positions followed by three scanning in orthogonal planes to complete the assessment. Imaging of each axilla was deemed an essential part of the ultrasound.

Malignant lesions had a mean size of (4.35) mm (SD .37) . most of the patients was from various Sudan states (about 90%), while 10 was from Khartoum city that mean place may considered as risk factor. Age risk factor at the range of classes (40-49).most of the patients was a housekeeper that mean the job is not considered as a risk factor.

The prevalence of cancer in the screened population was 56% of patients. The statistical measures of accurac, sensitivity, specificity, positive predictive (PPV) and negative predictive values (NPV) were calculated. Malignant lesions were detected in each patient group at the rate of 43% 89%, 84%, 87% and 86% respectively.

In this study, breast ultrasound significantly increases the cancer detection rate and should be considered as an important in the patient with positive imaging findings. Ultrasonography has been playing an increasingly important role in the evaluation of breast cancer as well as evaluation of many abnormalities seen on mammograms. US is also useful in the guidance of biopsies and therapeutic procedures.

ملخص الدراسه

الهدف الرئيسي من هذه الدراسه هو تقييم دور الموجات فوق الصوتيه في تصوير أورام الثدي الخبيثه , وفي تقييم الكتل المحسوسه التي لم تتم رؤيتها في صور الأشعه العاديه للثدي , وأيضا لتقييم أمراض الثدي المتوقعه في النساء اللأقل عمرا من 30 عاما.

في الفتره من فبراير(2014) وحتي نوفمبر (2014) كانت هناك (200) حاله قد حضروا لعمل تصوير للثدي , (100) مريض شكلو عينة البحث . كل المرضي قد تم عمل فحص الموجات فوق الصوتيه لهم , كانت هناك بيانات معتمده وبيانات احري مستبعده نتيجه لعدم اكتمال بعض البيانات .

تمت دراسة طريقة ظهور انواع معينه من سرطانات الثدي , وبالرغم من اختلاف طريقة ظهورها الي حد كبير الا ان بعض النماذج تبدو متطابقه , فالتي تحتوي علي الميوسين تكون دائما دائريه مع حواف غير منتظمه , هذه الآفات قد تكون (قليلة الصدي) أو (عديمة الصدي) مفارنة مع نسيج الدهون تحت الجلدي.

القياسات الاحصائيه للدقه , الحساسيه , الخصوصيه , التنبؤيه الايجابيه والتنبؤيه السلبيه قد تم تجميعها . تم عمل فحوصات الموجات فوق الصوتيه بجهازي (توشيبا اوكساريو : مجموعة توشيبا اليابان) وجهاز (سونو اسكيب).

فحص الثدي تم عمله بنموذج متفرق , يبدأ عند أطراف الثدي وينتهي عند المنتصف.كل ربع تم عمله المسح له عند أوضاع الساعه(12,3,6و9), ثم متابعة الفحص بالمسح عند الخط المتعامد ليكتمل عمل الفحص لكل (ابط) حيث يعتبر فحص هذا الجزء جزء مهم من عملية الفحص بالموجات فوق الصوتيه.

نسبة المرضي المصابين فعليا في هذه الدراسه 49% ويعتبراعلي مقارنة بالدراسات المشابهه : سوزان هاميلتون (2010)(44.9%) , كوب, ليثي ونيوهاوس(2002) : (40.6) , روزنبيرج (2006) : (21%) , وبيرج (2008) وهذا يعني تزايد نسبة الاصابه بسرطان الثدي.

معدل أخذ العينات كان 50% (50\100) , منها 50 آفه خبيثه و37 آفه حميده معطية معدل اكتشاف وقدره 48.5% في العينه التي تم فحصها.

الآفات الخبيثه كان لها متوسط حجم يساوي 4.35سم, وانحراف معياري(037). معظم المريضات كن ربات منزل مما يدل علي عم اعتبار المهنه كعامل خطر , الفئه العمريه من (40-49) كانت الفئه الاكثر اصابه .

التحليل الاحصائي للدقه , الحساسيه , الخصوصيه , التنبؤيه الايجابيه والتنبؤئيه السلبيه في كل مجموعة مرضي كانت بمعدل 43% , 89% , 84% , 87% و86% علي التوالى .

في هذه الدراسه معدل اكتشاف المرض بواسطة الموجات فوق الصوتيه زاد الي حد كبير ويجب ان يعتبر هذا جزء طبيعي في عملية التصوير للمرضي الذين تحقق لديهم وجود المرض.

ان الموجات فوق الصوتيه قد لعبت دورا متعاظما في تقييم سرطان الثدي , وتعتبر ايضا مفيده في عملية (توجيه العينات) وفي الأغراض العلاجيه ايضا .

Table of contents

Title	Page No.
الاية	I
Dedication	II
Acknowledgment	III
Abstract(English)	IV
Abstract (Arabic)	VI
Table of Contents	VIII
List of Tables	XII
List of Figure	XIII
List of abbreviation	XIV
Chapter One Introduction	
1.1.Introduction	1
1.2. Statement of the problem	3
1.3. Objectives of the study	3
1.4.Overview of the study	5
1.5.Breast caner overview	5
1.5.1. Signs and symptoms of breast cancer	5
1.5.2.Diagnosis	6
1.5.3 Background	7
1.5.4 Pathophysiology	8
1.5.5 Etiology	10
1.5.6 Age and gender	10

1.5.7 Family history of breast cancer	10
1.5.8 Reproductive factors and steroid hormones	12
1.5.9 Prior breast health history	15
1.5.10 Lifestyle risk factors	16
1.5.11 Obesity	16
1.5.12 Environmental risk factors	17
1.5.13.Age-related demographics	20
1.5.14.Histopathology	21
1.5.14.Grade	21
1.5.15.Stage	21
1.5.16.Receptor status	22
1.5.17.DNA assays	23
1.5.18.Tumor Size and Staging	23
1.6.Where in the body does breast cancer usually spread?	25
Chapter Two **Section one** **Ultrasound characteristic of the lesion**	
2.1. Breast ultrasound (Theoretical Baground)	30
2.2.Malignant breast lesions	32
2.3.Ultrasound characteristic of the lesion	32
2.3.1. Shape and margin of the lesion	37
2.3.2.Width-AP dimension ratio	38
2.3.3 Echogenicity	38
2.3.4.Internal Echo pattern	38

2.3.5.Shadowing	38
2.3.6.Calcifications	38
2.3.7.Duct Extension	39
Section two: **Literature review**	
2.4 Anatomy of the breast	40
2.4.1. Anatomy of the breast Vascular Anatomy and Innervation of the Breast	40
2.4.2. Breast Parenchyma and Support Structures	41
2.4.3. Musculature Related to the Breast	42
2.4.3.1. Pectoralis major	42
2.4.3.2. Seriates anterior	43
2.4.3.3. Rectus abdominis	43
2.4.3.4. External oblique	44
2.4.4 Lymphatic drainage of the breast	44
2.4.5 . Hormones of the breast	46
2.5 Literature studies	47
Chapter three **Material & method**	
3.1: Introduction	50
3.2. The study design & the study duration	50
3.3. The patient population	51
3.4. Ultrasound imaging method	51
3.5.Statistical analysis	52

Chapter four Results	
4.1 Introduction	54
4.2 Lesions classification &types	54
4.3. Patient age	55
4.4.Lesion sizes	56
4.5.lymph node involvement	57
Chapter five Discussion	
Discussion	61
Conclusion	65
Recommendations	66
References	67

List of tables

Table	Page No.
Table 1: IARC and WCRF/AICR Evaluations of Breast Cancer Risk Factors	**18**
Table 2.1 is a summary of those ultrasound characteristics (Stavros et al.(1995).	**31**
Table (3.1) : The contingency table :	**53**
Table (4.1) : Show the type of breast ca & the number of cases for each type :	**54**
Table (4.2) : Patient age:	**55**
Table (4.3): show the size and number of malignant lesions.	**57**
Table (4.4): show the breast cancer type & the number of involved lymph node.	**58**
Table (4.5):show the breast ca type & the number of lymph nodes involved.	**59**

List of Figures

Figure	Page No.
Figure (1.1) : signs & symptoms of breast ca	**5**
Figure (1.2) :Axillary lymph node metastasis of a breast carcinoma with rounded hypoechoic lymph nodes	**26**
Figure (2.1): malignant mass of the breast	**33**
Image (2.2) Anatomy of the breast	**40**
figure (2.3) Female breast, anterior view	**41**
Figure(2.4): Breast Lymph Node	**45**
Figure (4.1) : depicts the relationship between cancer type & the number of cases	**55**
Figure (4.2): a chart represents the percentage of patients age	**56**
Figure (4.3) : represents the percentages of number of malignant lesions & the size of the lesions	**57**

list of abbreviations

ACRIN	American College of Radiology Imaging Network
ACR	American College of Radiology
BPBD	Benign proliferative breast disease
BSA	Breast Screen Aotearoa
DCIS	Ductal carcinoma in situ
FCC	Fibrocystic change
FNA	Fine needle aspiration
FN	False negative
FP	False positive
HRT	Hormone replacement therapy
IDC	Invasive ductal carcinoma
NAD	No abnormality detected
NPV	Negative predictive value
PPV	Positive predictive value
TDLU	Terminal ductal lobular units
TP	True positive
TN	True negative
US	Ultrasound
WHO	World Health Organisation

Chapter One

Introduction

1.1.Introduction:

Breast cancer is among the most common causes of cancer deaths today, coming fifth after lung, stomach, liver and colon cancers. It is the most common cause of cancer death in women. In 2005 alone, 519 000 deaths were recorded due to breast cancer (Medknow Publications). This means that one in every 100 deaths worldwide and almost one in every 15 cancer deaths were due to breast cancer.

Common Malignant lesions discussed include invasive ductal carcinoma (IDC), ductal carcinoma in situ (DCIS), invasive lobular and invasive tubular carcinomas.

Though breast imaging with ultrasound has been established as an adjunct to mammography in recent research, (Kolb et al. 1998; Berg, 2003B; Warner et al).

Its role has been primarily confined to the targeted confirmation of cystic lesions (Cormack & Mendelson, et al 2006),. Its use in then patient with a positive imaging finding has not been as well established.

With the development of ultrasound technology, (Georgian-Smith et al. 2000; & Muradali, 2005), ultrasound is becoming accepted as a tool to differentiate benign from malignant breast lesions (Stavros et al. 1995). Since 2000, there is an emerging body of evidence that suggest the use of breast ultrasound is valid (Kaplan, (2001); Crystal et al. (2004); Wilkinson et al. (2005); & Berg, 2003A & 2008). It seems timely to investigate its role both in the management of patients with symptoms and/or positive findings from mammography and in patients with established risk factors.

For the purpose of this study, the risk factors for breast cancer were an individual's

prior history of breast cancer, an individual's positive status for the BRCA1 or BRCA2 gene, a familial history of breast cancer, or the presence of dense breast tissue.

Women with these risk factors may be excluded from the national screening programme, Breast Screen Aotearoa (BSA). This program was established by the New Zealand government (Ministry of Health, 2007A) to screen women for the early

Detection of curable cancers. imaging for these high risk women is of a very importance of breast ultrasound could be used to achieve satisfactory breast screening Breast cancer is among the most common causes of cancer deaths today , It is the most common cause of cancer death in women .In 2005 alone, 519 000 deaths were recorded due to breast cancer. This means that one in every 100 deaths worldwide and almost one in every 15 cancer deaths were due to breast cancer. Refinement of high-frequency technology, particularly with 7.5–13 MHz probes, has brought out a totally new facet in ultrasound breast imaging. For example:

a. High-density probes provide better lateral resolution.
b. Harmonic imaging leads to improved resolution and reduced reverberation and near-field artifacts. .
c. Real-time compound scanning results in increased tissue contrast resolution.
d. Extended or panoramic views provide a better perspective of the lesion in relation to the rest of the breast.

Harmonic imaging and real-time compounding has been shown to improve image resolution and lesion characterization. More recently, breast ultrasound seems to be quite promising. Initial results indicate that it can improve the specificity and positive predictive value of ultrasound in the characterization of breast masses.

This is exemplified in women with dense breast tissue, where breast ultrasound is useful in detecting small breast cancers that are not detected on mammography.

From January 2014 to August 2014 inclusive, 200 patients presented for breast imaging and of these, 100 formed the study group as they required a breast tissue biopsies due to imaging results. The cancer detection rate was compared among those women with a baseline risk and those who had either an increased risk of breast cancer and / or had dense breast tissue,. All patients in the study group (100) were imaged with breast ultrasound. The statistical measures of accuracy, sensitivity,

specificity, positive predictive (PPV) and negative predictive values (NPV) were calculated using 2x2 contingency table.

These results will investigate The role of breast ultrasound in diagnosis of malignant breast tumors and establish to the role of breast ultrasound in the screening of patient suspected of breast cancer As a safe modality .

1.2. Statement of the problem:

Breast cancer is among the most common causes of cancer deaths today, coming fifth after lung, stomach, liver and colon cancers. It is the most common cause of cancer death in women.In 2005 alone, 519 000 deaths were recorded due to breast cancer. This means that one in every 100 deaths worldwide and almost one in every 15 cancer deaths were due to breast cancer. Appropriate imaging for these high risk women is of obvious importance and perhaps the addition of breast ultrasound could be used to achieve satisfactory breast screening. Refinement of high-frequency technology, particularly with 7.5–13 MHz probes, has brought out a totally new facet in ultrasound breast imaging. For example:

a) High-density probes provide better lateral resolution. .
b) Harmonic imaging leads to improved resolution and reduced reverberation and near-field artifacts. .
c) Real-time compound scanning results in increased tissue contrast resolution.
d) Extended or panoramic views provide a better perspective of the lesion in relation to the rest of the breast.

Harmonic imaging and real-time compounding has been shown to improve image resolution and lesion characterization. More recently, breast ultrasound seems to be quite promising. Initial results indicate that it can improve the specificity and positive predictive value of ultrasound in the characterization of breast masses.

1.3. Objectives of the study:

The main aim of the study is to assess whether breast ultrasound could have a role in the In diagnosis of malignant breast tumors or not?

Additionally, sub-aims were related to:

The role of breast ultrasound in the screening of patient suspected of breast cancer

As a safe modility. evaluate of palpable masses that are mammographically occult , and to evaluate of clinically suspected breast lesions in women younger than 30 years of age to prevent the exposes' to the ionized radiation.

Mammography has long been viewed as the gold standard for breast cancer detection, however there are well documented limitations in the effectiveness of mammography because of its hazard.

Ultrasound (US) is an important adjunct to mammography in breast cancer detection as it increases the rate of detection in dense breasts. Ultrasound also does dynamic analysis of moving structures in breast thus it is used to analyze the functional behavior of breast. In the proposed method, ultrasound images are preprocessed using Gaussian smoothing to remove additive noise and anisotropic diffusion filters to remove multiplicative noise (speckle noise). Active contour method has been used to extract a closed contour of filtered image which is the boundary of the spiculated mass. Spiculations which make breast mass unstructured or irregular are marked by measuring the angle of curvature of each pixel at the boundary of mass. To classify the breast mass as malignant or benign we have used: the structure of mass in accordance with spiculations, elliptical shape of the mass and acoustic shadowing feature which is an important functional feature.

1.4.Overview of the study :

This study falls into 5 chapter, with:

Chapter one (general introduction): introduction, problem of the study, objective and overview of the study.

Chapter two include: Ultrasound characteristic of the lesion, and Literature Review: Anatomy of breast Physiology and Sonographic characteristic of the breast cancer.

Chapter three: Material & Method: Study area & study population, Study design & study duration. Sampling, Data collection, Data analysis and Limitation.

Chapter four: (The Result).

Chapter five include: Discussion, Conclusion and Recommendation.

1.5.Breast caner overview:

1.5.1. Signs and symptoms of breast cancer:

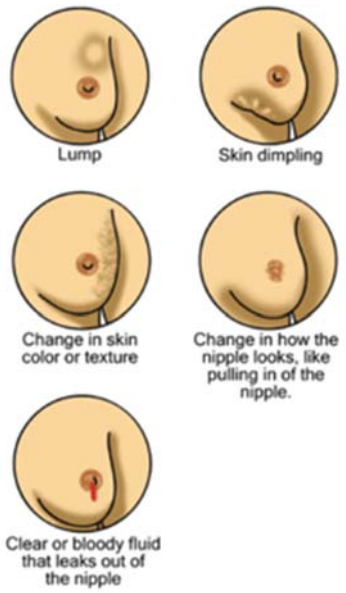

Figure (1.1) : signs & symptoms of breast ca.

Early breast cancers may be asymptomatic, and pain and discomfort are typically not present. If a lump is discovered, the following may indicate the possible presence of breast cancer:

1. Change in breast size or shape
2. Skin dimpling or skin changes
3. Recent nipple inversion or skin change, or nipple abnormalities
4. Single-duct discharge, particularly if blood-stained
5. Axillary lump

1.5.2.Diagnosis

Breast cancer is often first detected as an abnormality on a mammogram before it is felt by the patient or health care provider.

Evaluation of breast cancer includes the following:

1. Clinical examination
2. Imaging
3. Needle biopsy

- *Physical examination*

The following physical findings should raise concern:

1. Lump or contour change
2. Skin tethering
3. Nipple inversion
4. Dilated veins
5. Ulceration
6. Paget disease
7. Edema or peau d'orange

If a palpable lump is found and possesses any of the following features, breast cancer may be present:

1. Hardness
2. Irregularity
3. Focal nodularity
4. Fixation to skin or muscle

- *Screening*

Early detection remains the primary defense in preventing breast cancer. Screening modalities include the following:

a) Breast self-examination
b) Clinical breast examination
c) Mammography
d) Ultrasonography
e) Magnetic resonance imaging

Ultrasonography and MRI are more sensitive than mammography for invasive cancer in nonfatty breasts. Combined mammography, clinical examination, and MRI are more sensitive than any other individual test or combination of tests.

Biopsy

Core biopsy with image guidance is the recommended diagnostic approach for newly diagnosed breast cancers. This is a method for obtaining breast tissue without surgery and can eliminate the need for additional surgeries. Open excisional biopsy is the surgical removal of the entire lump.

1.5.3 Background

Worldwide, breast cancer is the most frequently diagnosed life-threatening cancer in women and the leading cause of cancer death in women (Jemal A, et al 2011). In the United States, breast cancer accounts for 29% of all cancers in women and is second only to lung cancer as

Many early breast carcinomas are asymptomatic; pain or discomfort is not usually a symptom of breast cancer. Breast cancer is often first detected as an abnormality on a mammogram before it is felt by the patient or healthcare provider.

The general approach to evaluation of breast cancer has become formalized as triple assessment: clinical examination, imaging (usually mammography, ultrasonography, or both), and needle biopsy. Increased public awareness and improved screening have led to earlier diagnosis, at stages amenable to complete surgical resection and curative therapies. Improvements in therapy and screening have led to improved survival rates for women diagnosed with breast cancer.

Surgery and radiation therapy, along with adjuvant hormone or chemotherapy when indicated, are now considered primary treatment for breast cancer. For many patients with low-risk early-stage breast cancer, surgery with local radiation is curative.

Adjuvant breast cancer therapies are designed to treat micrometastatic disease or breast cancer cells that have escaped the breast and regional lymph nodes but do not yet have an established identifiable metastasis. Depending on the model of risk reduction, adjuvant therapy has been estimated to be responsible for 35-72% of the decrease in mortality.

Over the past 3 decades, extensive and advocate-driven breast cancer research has led to extraordinary progress in the understanding of the disease. This has resulted in the development of more targeted and less toxic treatments.

1.5.4 Pathophysiology

The current understanding of breast cancer etiopathogenesis is that invasive cancers arise through a series of molecular alterations at the cell level. These alterations result in breast epithelial cells with immortal features and uncontrolled growth.

Genomic profiling has demonstrated the presence of discrete breast tumor subtypes with distinct natural histories and clinical behavior. The exact number of disease subtypes and molecular alterations from which these subtypes arise remains to be fully elucidated, but these generally align with the presence or absence of estrogen receptor (ER), progesterone receptor (PR), and human epidermal growth factor receptor 2 (HER2).

This view of breast cancer--not as a set of stochastic molecular events, but as a limited set of separable diseases of distinct molecular and cellular origins--has altered thinking about breast cancer etiology, type-specific risk factors, and prevention and has had a substantial impact on treatment strategies and breast cancer research.

Evidence from The Cancer Genome Atlas Network (TCGA) confirms the following 4 main breast tumor subtypes, with distinct genetic and epigenetic aberrations:

a. Luminal A
b. Luminal B
c. Basal-like
d. HER2-positiveIntrinsic subtypes of breast cancer.

It is noteworthy that the basal-like breast tumor subgroup shares a number of molecular characteristics common to serous ovarian tumors, including the types and frequencies of genomic mutations. These data support the evidence that some breast cancers share etiologic factors with ovarian cancer. Most compelling are the data showing that patients with basal-type breast cancers show treatment responsiveness similar to that of ovarian cancer patients (Recht A, et al 2001).

The various types of breast cancers are listed below by percentage of cases:

a. Infiltrating ductal carcinoma is the most commonly diagnosed breast tumor and has a tendency to metastasize via lymphatics; this lesion accounts for 75% of breast cancers
b. Over the past 25 years, the incidence of lobular carcinoma in situ (LCIS) has doubled, reaching a current level of 2.8 per 100,000 women; the peak incidence is in women aged 40-50 years
c. Infiltrating lobular carcinoma accounts for fewer than 15% of invasive breast cancers
d. Medullary carcinoma accounts for about 5% of cases and generally occurs in younger women
e. Mucinous (colloid) carcinoma is seen in fewer than 5% of invasive breast cancer cases
f. Tubular carcinoma of the breast accounts for 1-2% of all breast cancers
g. Papillary carcinoma is usually seen in women older than 60 years and accounts for approximately 1-2% of all breast cancers

h. Metaplastic breast cancer accounts for fewer than 1% of breast cancer cases, tends to occur in older women (average age of onset in the sixth decade), and has a higher incidence in blacks
i. Mammary Paget disease accounts for 1-4% of all breast cancers and has a peak incidence in the sixth decade of life (mean age, 57 years)

1.5.5 Etiology

Epidemiologic studies have identified a number of risk factors that are associated with an increased risk of a woman developing breast cancer. Several risk factors have been found to be clinically useful for assessing a patient's risk of breast cancer. Many of these factors form the basis of breast cancer risk assessment tools currently being used in the practice setting.

1.5.6 Age and gender

Increasing age and female sex are established risk factors for breast cancer. Sporadic breast cancer is relatively uncommon among women younger than 40 years but increases significantly thereafter. The effect of age on risk is illustrated in the SEER (Surveillance, Epidemiology and End Results) data, where the incidence of invasive breast cancer for women younger than 50 years is 44.0 per 100,000 as compared with 345 per 100,000 for women aged 50 years or older.

The total and age-specific incidence for breast cancer is bimodal, with the first peak occurring at about 50 years and the second occurring at about 70 years (Jatoi I, et al 2008). This bimodal pattern may reflect the influence of age within the different tumor subtypes; poorly differentiated, high-grade disease tend to occur earlier, whereas hormone-sensitive, slower-growing tumors tend to occur with advancing age.

1.5.7 Family history of breast cancer

A positive family history of breast cancer is the most widely recognized risk factor for breast cancer. The lifetime risk is up to 4 times higher if a mother and sister are affected, and it is about 5 times greater in women who have 2 or more first-degree relatives with breast cancer. The risk is also greater among women with breast cancer in a single first-degree relative, particularly if the relative was diagnosed at an early

age (≤50 years). Despite a history indicating increased risk, many of these families have normal results on genetic testing.

A family history of ovarian cancer in a first-degree relative, especially if the disease occurred at an early age (< 50 years), has been associated with a doubling of breast cancer risk. This often reflects inheritance of a pathogenic mutation in the *BRCA1* or *BRCA2* gene.

The family history characteristics that suggest increased risk of cancer are summarized as follows:

a) Two or more relatives with breast or ovarian cancer

b) Breast cancer occurring in an affected relative younger than 50 years

c) Relatives with both breast cancer and ovarian cancer

d) One or more relatives with 2 cancers (breast and ovarian cancer or 2 independent breast cancers)

e) Male relatives with breast cancer

f) *BRCA1* and *BRCA2* mutations

g) Ataxia telangiectasia heterozygotes (quadrupled risk)

h) Ashkenazi Jewish descent (doubled risk)

A small percentage of patients, usually with a strong family history of other cancers, have cancer syndromes. These include families with a mutation in the *PTEN, TP53, MLH1, MLH2, CDH1,* or *STK11* gene.

To aid in the identification of mutation carriers of *BRCA1/2*, a number of family history–based risk assessment tools have been developed for clinical use, including the following:

a) BRCAPRO

b) Couch

c) Myriad I and II

d) Ontario Family History Assessment Tool (FHAT)

e) Manchester

All of these assessment tools are highly predictive of carrier status and aid in reducing testing costs for the majority of mutation negative families (Parmigiani G, et al 2007). BRCAPRO, the most commonly used model, identifies approximately 50% of mutation-negative families, avoiding unnecessary genetic testing, and fails to screen only about 10% of mutation carriers.

Notably, a significant portion of ovarian cancers not previously considered familial can be attributed to *BRCA1* or *BRCA2* mutations (Pal T, et al 2005). This finding has led to the suggestion that women with nonmucinous invasive ovarian cancers may benefit from genetic testing to determine mutation status independent of a strong history or no history of breast cancer.

The National Institutes of Health (NIH) provides a Cancer Genetics Services Directory. This is a partial listing of professionals who provide services related to cancer genetics, including cancer risk assessment, genetic counseling, and genetic susceptibility testing.

1.5.8 Reproductive factors and steroid hormones

Late age at first pregnancy, nulliparity, early onset of menses, and late age of menopause have all been consistently associated with an increased risk of breast cancer (Deligeoroglou E, et al 2003). Prolonged exposure to elevated levels of sex hormones has long been postulated as a risk factor for developing breast cancer, explaining the association between breast cancer and reproductive behaviors (Hankinson SE, et al 2010).

Clinical trials of secondary prevention in women with breast cancer have demonstrated the protective effect of selective estrogen receptor modulators (SERMs) and aromatase inhibitors on recurrence and the development of contralateral breast cancers (Cuzick J, et al 2011). Use of SERMs in women at increased risk for breast cancer has prevented invasive ER-positive cancers (Vogel VG, et al 2006). These data support estradiol and its receptor as a primary target for risk reduction but do not establish that circulating hormone levels predict increase risk.

A number of epidemiologic and pooled studies support an elevated risk of breast cancer among women with high estradiol levels (Santen RJ, et al 2007). The Endogenous Hormones and Breast Cancer Collaborative Group (EHBCG) reported a relative risk of 2.58 among women in the top quintile of estradiol levels.

Upon thorough review of the collective data, the Breast Cancer Prevention Collaborative Group (BCPCG) prioritized additional factors that might be included in the validation phase of a risk prediction model and gave a high priority score to free plasma estradiol levels (Santen RJ, et al 2007). At present, routine measurement of plasma hormone levels is not recommended in the assessment of breast cancer risk.

One of the most widely studied factors in breast cancer etiology is the use of exogenous hormones in the form of oral contraceptives (OCs) and hormone replacement therapy (HRT) (Garbe E, et al 2004). The overall evidence suggests an approximately 25% greater risk of breast cancer among current users of OCs. The risk appears to decrease with age and time since OC discontinuance. For OC users, risk returns to that of the average population risk about 10 years after cessation.

Data obtained from case-control and prospective cohort settings support an increased risk of breast cancer incidence and mortality with the use of postmenopausal HRT (Reeves GK, et al 2006). Increased risk of breast cancer has been positively associated with length of exposure, with the greatest risk being observed for hormonally responsive lobular, mixed ductal-lobular, and tubular cancers. Risk is greater among women taking combination HRT than among those taking estrogen-only formulations (Schairer C, et al 2000).

In the Women's Health Initiative (WHI) trial, the incidence of invasive breast cancer was 26% higher in women randomly assigned to combination HRT than in those assigned to placebo. In contrast, the use of estrogen (conjugated equine estrogen) alone in women who had undergone hysterectomy was associated with a 23% (but not significant) decrease in breast cancer risk in comparison with placebo at initial reporting.

On extended follow-up (median, 11.8 years), estrogen-only therapy for 5-9 years in women with hysterectomy was associated with a significant 23% reduction in the annual incidence of invasive breast cancer (0.27%; placebo, 0.35%) (Anderson GL, et

al 2012). Fewer women died of breast cancer in the estrogen-only arm. These findings contrast with those reported from large observational case-control and prospective cohort studies, where estrogen alone was associated with increased risk (though the increase was consistently less than that associated with combined HRT use) (Speroff L. 2003).

To aid the medical community in the application of HRT, a number of agencies and groups have published recommendations for HRT use in the treatment of menopause and associated bone loss. At present, HRT is not recommended for prevention of cardiovascular disease or dementia or, more generally, for long-term use to prevent disease.

When prescribing HRT, the clinician should provide a discussion of the most current evidence and an assessment of the potential benefit and harm to the patient. Because of the known risk of endometrial cancer with estrogen-only formulations, the US Food and Drug Administration (FDA) currently advises the use of estrogen-plus-progesterone HRT for the management of menopausal symptoms in women with an intact uterus tailored to the individual patient, at the lowest effective dose for the shortest time needed to abate symptoms.

There are currently no formal guidelines for the use of HRT in women at high risk for breast cancer (ie, women with a family history of breast cancer, a personal history of breast cancer, or benign breast disease). Only a few studies have evaluated the effect of HRT after a diagnosis of breast cancer. The largest of these, the HABITS (Hormonal replacement therapy After Breast cancer—is IT Safe?) study was stopped early because unacceptable rates of breast cancer recurrence and contralateral disease with 2 years of HRT use (hazard ratio, 3.5) (Holmberg L, et al 2004).

In another randomized clinical trial, no increase in the risk of breast cancer recurrences was observed in women at a median follow up of 4.1 years (Loprinzi CL, et al 1994). Use of progesterone-containing HRT was limited by intermittent use, with continuous exposure avoided.

Combination formulations containing estrogen plus progesterone are contraindicated in women with a prior history of invasive disease, a history of ductal or lobular carcinoma in situ, or a strong family history of breast cancer. This recommendation

poses a significant challenge when confronted with a patient suffering severe menopausal symptoms.

Many new treatments for menopausal symptoms have been suggested (eg, clonidine, venlafaxine, gabapentin, and combination venlafaxine plus gabapentin). To date, no randomized clinical trials among women at increased risk of breast cancer or women with a history of breast cancer have assessed the overall efficacy or risks associated with these treatments (Bordeleau L, et al 2007). Use of these agents is controversial and should target the severity of menopausal symptoms.

Other hormone-based approaches (eg, low-dose vaginal estrogen for vaginal and urinary symptoms, including dyspareunia) are generally considered to be safer, particularly in patients receiving SERMs. However, these agents may also carry a slight increased risk, in that they are capable of raising estradiol levels, at least transiently, depending on the dose and frequency of administration. Little evidence supports the benefit of commonly used dietary isoflavones, black cohosh, or vitamin E.

1.5.9 Prior breast health history

A history of breast cancer is associated with a 3- to 4-fold increased risk of a second primary cancer in the contralateral breast (Page DL, et al 2003). The presence of any premalignant ductal carcinoma in situ (DCIS) or LCIS confers an 8- to 10-fold increase in the risk of developing breast cancer in women who harbor untreated preinvasive lesions (Ashbeck EL, et al 2007).

A history of breast biopsy that is positive for hyperplasia, fibroadenoma with complex features, sclerosing adenosis, and solitary papilloma have been associated with a modest (1.5- to 2-fold) increase in breast cancer risk (Ashbeck EL, et al 2007). In contrast, any diagnosis of atypical hyperplasia that is ductal or lobular in nature, especially in a woman under the age of 45 years, carries a 4- to 5-fold increased risk of breast cancer, with the increase rising to 8- to 10-fold among women with multiple foci of atypia or calcifications in the breast (Degnim AC, et al 2007).

Benign breast lesions, including fibrocystic disease such as fibrocystic change without proliferative breast disease or fibroadenoma, have not been associated with increased risk (Dupont WD, et al 1994).

1.5.10 Lifestyle risk factors

The wide variability of breast cancer incidence around the world (eg, the nearly 5-fold difference between Eastern Africa and Western Europe) has long been attributed to differences in dietary intake and reproductive patterns (Holmes MD, et al 2004). In general, rates differ according to the level of industrial development: there are more than 80 cases per 100,000 in developed countries, compared with fewer than 40 per 100,000 in less developed countries.

As with cancers of the colon and prostate, diets that are rich in grains, fruits, and vegetables; low in saturated fats; low in energy (calories); and low in alcohol—the more common pattern in less industrialized countries—are thought to be protective against breast cancer (Holmes MD, et al 2004).

1.5.11 Obesity

Increased risk of postmenopausal breast cancer has been consistently associated with the following:

a) Adult weight gain of 20-25 kg above body weight at age 18 (Han D, et al 2006).
b) Western dietary pattern (high energy content in the form of animal fats and refined carbohydrates)
c) Sedentary lifestyle
d) Regular, moderate consumption of alcohol (3-5 alcoholic beverages per week)

The Western lifestyle (ie, chronic excess energy intake from meat, fat, and carbohydrates and lack of exercise) strongly correlates with development of the following:

a) Obesity, particularly abdominal obesity
b) Chronic hyperinsulinemia
c) Higher production and availability of insulinlike growth factor (IGF)-1
d) Increased levels of endogenous sex hormones through suppression of sex hormone–binding globulin (Lukanova A, et al 2004).

Studies of dietary fat, total energy, and meat intake levels have largely been inconsistent in population studies of adult women with regard to risk of breast cancer. In contrast, epidemiologic studies have more consistently found a positive relation

between breast cancer risk and early-life exposures such as diet, obesity, and body size (including height) (Fuemmeler BF, et al 2009). The mechanism of this relation is unknown.

1.5.12 Environmental risk factors

A number of environmental exposures have been investigated in relation to breast cancer risk in humans, including the following (Gammon MD, et al 2004):

a) Tobacco smoke (both active and passive exposure)
b) Dietary (eg, charred and processed meats)
c) Alcohol consumption
d) Environmental carcinogens (eg, exposure to pesticides, radiation, and environmental and dietary estrogens)

Of these environmental exposures, only high doses of ionizing radiation to the chest area, particularly during puberty, have been unequivocally linked with an increased risk of breast cancer in adulthood (Carmichael A, et al 2003). Because of the strong association between ionizing radiation exposure and breast cancer risk, medical diagnostic procedures are performed in such a way as to minimize exposure to the chest area, particularly during adolescence.

Women with a history of radiation exposure to the chest area should be examined and counseled regarding their risk of breast cancer on the basis of the timing and dose of the previous exposure. A patient treated for Hodgkin lymphoma with Mantel radiation that includes the breasts in the radiation field has a 5-fold higher risk of developing breast cancer. This risk increases markedly for women treated during adolescence (Clemons M, et al 2000); evidence suggests that cumulative risk increases with age as a function of age of exposure and type of therapy (Hill DA, et al 15 Nov).

Current evidence does not support a significant and reproducible link between other environmental exposures and breast cancer risk. Thus, a number of factors remain suspect but unproven.

The International Agency for Research on Cancer (IARC) evaluates evidence on the carcinogenic risk to humans of a number of exposures including tobacco, alcohol, infections, radiation, occupational exposures, and medications.4 The World Cancer

Research Fund/American Institute for Cancer Research (WCRF/AICR) have a conclusions about breast cancer risk factors are shown in **Table (2.1):.**

Increases risk ('sufficient' or 'convincing' evidence)	**May increase risk ('limited' or 'probable' evidence)**	**Decreases risk ('sufficient' or 'convincing' evidence)**	**May decrease risk ('limited' or 'probable' evidence)**
-Alcoholic beverages -Diethylstilbestrol -Oestrogen-progestogen contraceptives -Oestrogen-progestogen menopausal therapy -X radiation and Gamma radiation -Body fatnessa -Adult attained heighta	-Digoxin. -Oestrogen menopausal therapy (hormone replacement. therapy). -Ethylene oxide -Shiftwork. involving circadian disruption. -Tobacco smoking. -Adult attained height. -Greater birth weightb. -Abdominal fatnessa. -Adult weight gaina. -Total dietary fata.	-Breastfeeding	

Table 1: IARC and WCRF/AICR Evaluations of Breast Cancer Risk Factors

Incidence over this period of time varied dramatically by histologic type. Common ductal carcinomas increased modestly from 1987 to 1999, whereas invasive lobular and mixed ductal-lobular carcinomas increased dramatically during this time period (Li CI, et al 2007). For women under the age of 50, breast cancer rates have remained stable since the middle to late 1980s. Rates of DCIS have stabilized since 2000.

Whereas a decline in invasive breast cancer rates was evident as early as 1999, rates decreased dramatically in women aged 50 years or older between 2001 and 2004. During this same period, no significant change was observed in the incidence of ER-negative cancers or cancers in women younger than 50 years. The decline in rates from 2001 to 2004 was greatest between 2002 and 2003 and was limited to non-Hispanic whites (Katalinic A, et al 2008).

The reason for the decline has been extensively debated. Breast cancer rates decreased significantly after the reports from the Million Women Study (Beral V. 2003) and the Women's Health Initiative showing higher numbers of breast cancers in women using combination HRT with estrogen and progestin for menopausal symptoms. The near-immediate decrease in the use of combination HRT for that purpose has been widely accepted as a primary explanation for the decrease in breast cancer rates (Ravdin PM, et al 2007).

However, Jemal and Li argued that the decline in breast cancer incidence started earlier than the reduction in combination HRT use and that the decline is due in part to a "saturation" in mammographic screening mammography that produced a plateau in incidence when such screening stabilized in the late 1990s (Jemal A, et al 2007). Saturation of the population would be predicted to reduce the pool of undiagnosed or prevalent cases.

For women aged 69 years or older, breast cancer rates started to decline as early as 1998, when screening first showed a plateau. This observation is consistent with the prediction that if widespread screening and earlier detection are effective, they should result in a peak incidence among women during the sixth and seventh decades of life, followed by a decline. This is exactly the pattern now being reported for screened populations (Anderson WF, et al 2007).

The second observation noted by Jemal et al was that despite evidence for a plateau effect, screening saturation alone could not explain the dramatic declines or the pattern of decline. The decline in incidence was observed only for ER-positive tumors and not for ER-negative ones; these findings support the competing hypothesis that exposure to HRT as estrogen in combination with synthetic progesterone promoted the growth of undetected tumors.

Under this scenario, withdrawal of combination HRT at the population level may have resulted in regression or a slowing of tumor growth. The latter, it has been argued, would result in a delay in detection. Overall, incidence figures from 2005-2009, for which the most recent data are currently available, suggest that overall new breast cancer case rates have remained fairly stable since the initial drop.

It is notable, however, that the annual percentage change from 2005 to 2009 increased in women aged 65-74 years by 2.7% during this period, rates that parallel 2001 incidence figures for this age group. This rise is occurring in spite of very low use of HRT by this population (. Burger HG, et al 2012) and suggests that the drop in combination HRT use immediately after 2002 may not have resulted in a sustained decrease in new breast cancer cases.

At present, it is unclear whether decreased use of combination HRT has resulted in a sustained reduction in the incidence of breast cancer at the population level or has shifted the age at which preexisting disease would become detectable

1.5.13.Age-related demographics

The incidence rate of breast cancer increases with age, from 1.5 cases per 100,000 in women 20-24 years of age to a peak of 421.3 cases per 100,000 in women 75-79 years of age; 95% of new cases occur in women aged 40 years or older. The median age of women at the time of breast cancer diagnosis is 61 years.

Rates of in situ breast cancer stabilized among women 50 years and older in the late 1990s; this is consistent with the proposed effects of screening saturation. However, the incidence of in situ breast cancer continues to increase in younger women**.**

Breast cancers are classified by several grading systems. Each of these influences the prognosis and can affect treatment response. Description of a breast cancer optimally includes all of these factors.

1.5.14.Histopathology:

Breast cancer is usually classified primarily by its histological appearance. Most breast cancers are derived from the epithelium lining the ducts or lobules, and these cancers are classified as ductal or lobular carcinoma. *Carcinoma in situ* is growth of low grade cancerous or precancerous cells within a particular tissue compartment such as the mammary duct without invasion of the surrounding tissue. In contrast, *invasive carcinoma* does not confine itself to the initial tissue compartment .

1.5.14.Grade:

Grading compares the appearance of the breast cancer cells to the appearance of normal breast tissue. Normal cells in an organ like the breast become differentiated, meaning that they take on specific shapes and forms that reflect their function as part of that organ. Cancerous cells lose that differentiation. In cancer, the cells that would normally line up in an orderly way to make up the milk ducts become disorganized. Cell division becomes uncontrolled. Cell nuclei become less uniform. Pathologists describe cells as well differentiated (low grade), moderately differentiated (intermediate grade), and poorly differentiated (high grade) as the cells progressively lose the features seen in normal breast cells. Poorly differentiated cancers (the ones whose tissue is least like normal breast tissue) have a worse prognosis.

1.5.15.Stage:

Breast cancer staging using the TNM system is based on the size of the tumor (**T**), whether or not the tumor has spread to the lymph nodes (**N**) in the armpits, and whether the tumor has metastasized (**M**) (i.e. spread to a more distant part of the body). Larger size, nodal spread, and metastasis have a larger stage number and a worse prognosis. .

The main stages are:

a) Stage 0 is a pre-cancerous or marker condition, either ductal carcinoma in situ (DCIS) or lobular carcinoma in situ (LCIS).

b) Stages 1–3 are within the breast or regional lymph nodes.

c) Stage 4 is 'metastatic' cancer that has a less favorable prognosis.

Where available, imaging studies may be employed as part of the staging process in select cases to look for signs of metastatic cancer. However, in cases of breast cancer with low risk for metastasis, the risks associated with PET scans, CT scans, or bone scans outweigh the possible benefits, as these procedures expose the patient to a substantial amount of potentially dangerous ionizing radiation.

There are two types of breast cancer staging:

-Pathologic staging

-Clinical staging

-Pathologic staging:

Pathologic staging (the standard way to stage breast cancer) is based on a pathologist's study of the lymph nodes and tumor tissue removed during surgery.

-Clinical staging:

Clinical staging includes results from a health care provider's physical exam and tests like mammography. These may add to the pathologist's findings, when needed.

Although there are a few ways to classify stage, the most widely used is the TNM system (which stands for **t**umor, **n**odes and **m**etastases). TNM takes into account:

-The size of the tumor (T).

-The number and location lymph nodes (N) with cancer.

-Whether or not the cancer has spread to other areas of the body (metastasis) (M).

1.5.16.Receptor status:

Breast cancer cells have receptors on their surface and in their cytoplasm and nucleus. Chemical messengers such as hormones bind to receptors, and this causes changes in the cell. Breast cancer cells may or may not have three important receptors: estrogen receptor (ER), progesterone receptor (PR), and HER2.

ER+ cancer cells (that is, cancer cells that have estrogen receptors) depend on estrogen for their growth, so they can be treated with drugs to block estrogen effects (e.g. tamoxifen), and generally have a better prognosis. Untreated, HER2+ breast cancers are generally more aggressive than HER2- breast cancers, but HER2+ cancer cells respond to drugs such as the monoclonal antibody trastuzumab (in combination with conventional chemotherapy), and this has improved the prognosis significantly (Watson M 2008). Cells that do not have any of these three receptor types (estrogen receptors, progesterone receptors, or HER2) are called triple-negative, although they frequently do express receptors for other hormones, such as androgen receptor and prolactin receptor.

1.5.17.DNA assays :

DNA testing of various types including DNA microarrays have compared normal cells to breast cancer cells. The specific changes in a particular breast cancer can be used to classify the cancer in several ways, and may assist in choosing the most effective treatment for that DNA type.

The 2003 World Health Organization (WHO) classification of tumors of the breast which includes **benign** (harmless) tumors and **malignant** (cancerous) tumors, recommends the following pathological types:

1.5.18.Tumor Size and Staging:

-Tumor size is strongly related to prognosis. In general, the smaller the tumor, the higher the chances are for long-term survival.

-In the TNM staging system, a "T" followed by a number shows the size of the tumor.

-In some cases, the size of the tumor cannot be determined (TX) or a tumor cannot be found (TO). If the diagnosis is carcinoma in situ, this is written as Tis.

Tumor size categories :
TX: Tumor size cannot be assessed
T0: No tumor can be found

Tis: Carcinoma in situ	
	Subcategories of Tis:
	Tis (DCIS): Ductal carcinoma in situ
	Tis (LCIS): Lobular carcinoma in situ
	Tis (Paget): Paget disease of the breast (Paget disease of the nipple) with no DCIS, LCIS or invasive breast cancer
T1: Tumor is 2 cm or smaller	
	Subcategories of T1:
	T1mi: Very small tumor (0.1 cm or smaller)
	T1a: Tumor is larger than 0.1 cm, but no larger than 0.5 cm
	T1b: Tumor is larger than 0.5 cm, but no larger than 1 cm
	T1c: Tumor is larger than 1 cm, but no larger than 2 cm
T2: Tumor is larger than 2 cm, but no larger than 5 cm	
T3: Tumor is larger than 5 cm	
T4: Tumor is any size, but has spread beyond the breast tissue to the chest wall and/or skin	
	Subcategories of T4:
	T4a: Tumor has spread to the chest wall

	T4b: Tumor has spread to the skin, but is not inflammatory breast cancer
	T4c: Tumor has spread to both the chest wall and skin
	T4d: Inflammatory breast cancer
Adapted from National Cancer Institute materials [98].	

- Histological grade

-Histologic grade (G)

-GX : Grade cannot be assessed.

-G1 : Low combined histologic grade (favorable).

-G2 : Intermediate combined histologic grade (moderately favorable).

-G3 : High combined histologic grade (unfavorable).

1.6.Where in the body does breast cancer usually spread?

Lymph nodes: The most common sites for breast cancer to spread Other parts of the body**:**

- **a.** Muscle, fatty tissue and skin.
- **b.** Bones.
- **c.** Bone marrow.
- **d.** Liver **.**
- **e.** Lungs **.**
- **f.** Brain **.**

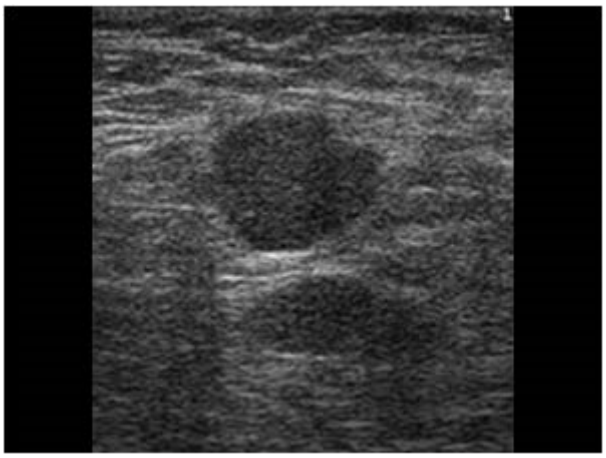

Figure (1.2) :Axillary lymph node metastasis of a breast carcinoma with rounded hypoechoic lymph nodes.

Axillary lymph node status is the single most important prognostic variable in the management of patients with primary breast cancer. Yet, it is not known whether metastasis to the axillary nodes is simply a time-dependent variable or also a marker for a more aggressive tumor phenotype.

cancers have a worse prognosis than node-negative cases (Dent DM, et al 1996). However, the significance of nodal metastasis is poorly understood. Late in the 19th century, Halsted (Halsted WS, et al 1898) proposed that breast cancer spreads first to the axillary lymph nodes and then to distant sites. Thus, nodal metastasis was viewed as an indicator of tumor chronology. The better prognosis of node-negative tumors was attributed to timely resection, before distant metastasis via the axillary lymphatics had occurred (Eggers C, et al 1937).

In more recent years, large randomized trials have shown that neither the extent of the mastectomy nor delay in the treatment of the axilla has any influence on the prognosis of patients with operable breast cancer (Wood WC, 1994). In addition, long-term follow-up of node-negative patients reveals that 30% eventually die of metastatic breast cancer (Bonadonna G, 1992). Thus, the axilla does not seem to serve as a nidus for further spread of the cancer, as postulated by Halsted. Yet, nodal status is still considered an indicator of tumor chronology, and the better prognosis of node-negative patients is generally attributed to lead time bias (Mittra I, et al 1993). However, an alternative possibility may account for the difference in prognosis between node-negative and node-positive patients. Nodal status is perhaps also a

marker of tumor biology, with node-positive tumors having a more aggressive phenotype.

Mueller (Mueller CB, 1988) analyzed the annual rates of death from the National Surgical Adjuvant Breast and Bowel Project 04 study and Connecticut Tumor Registry and found that they were consistently higher for node-positive patients than for node-negative patients. Therefore, he postulated that the two stages of breast cancer represented biologic variants of the same disease. However, his analysis did not account for the confounding effects of other prognostic factors on survival, and the possibility that nodal status was a surrogate for these other variables could not be excluded. Subsequently, Mittra and MacRae (Mittra I, et al 1991) undertook a meta-analysis of published correlations between various prognostic factors in breast cancer and concluded that axillary lymph node status is simply a reflection of the chronologic age of the tumor. Yet, a meta-analysis has pitfalls, many of which were acknowledged by the authors. These include publication bias (journals tend to report only positive findings) and variability in laboratory analysis criteria (for instance, different laboratories adopt different criteria as to what constitutes ER positivity and ER negativity). In order to account for the shortcomings of the two previous studies, we undertook a multivariate analysis using a single, large database. All laboratory data were generated from the same institution, thereby accounting for the possible confounding effects of other prognostic factors on survival and yet eliminating the deficiencies of the meta-analysis.

The clinical history of breast cancer is often marked by four milestones: inception, diagnosis, distant relapse, and death (Bonadonna G, 1992). The time of inception is not known, and therefore the interval between inception and diagnosis is not known and probably highly variable between patients. If the survival advantage of node-negative patients is due to lead time bias, then these patients may seem to do better only because their cancers are diagnosed earlier than in the node-positive group, resulting in a longer follow-up time to death. To reduce the uncertainty associated with lead time bias, we correlated nodal status at initial diagnosis with the interval between two known points in the clinical history of breast cancer: relapse and death. A long interval would suggest a biologically indolent tumor, while a shorter interval

would indicate a more aggressive tumor phenotype. If nodal status is simply a marker of delay in diagnosis, then it should not correlate with outcome after relapse.

The importance of nodal status in predicting outcome after relapse is controversial. Some investigators have reported that nodal status has prognostic importance after relapse (Clark GM, et al 1987). However, others have found no correlation (Williams MR, et al 1986). There were relatively few patients in most of these studies, and the relationship between the number of involved nodes and prognosis after relapse was generally not examined (patients were categorized simply as node-positive or node-negative). More recently, several authors have reviewed the literature on this subject and concluded that nodal status has no value in predicting outcome after relapse and is therefore simply an indicator of tumor chronology (Tubiana-Hulin M, et al 1995). Several years ago, a report from our institution suggested that nodal status does have prognostic importance after relapse (Clark GM, et al 1987). In the present study, we evaluate an expanded cohort of patients from that database and correlate the extent of nodal involvement with outcome after relapse.

Patients with large, hormone receptor–negative or node-positive tumors are often selected to receive adjuvant systemic therapy. Thus, it is not surprising that patients selected for adjuvant systemic therapy have a worse outcome after relapse in the univariate analysis but not the multivariate model, where the effect of these other confounding variables is taken into account. Similarly, the size of the primary tumor correlates with outcome after relapse in the univariate analysis but not the multivariate model. Therefore, one might speculate that tumor size is a surrogate for nodal status. In the multivariate model, only nodal status, site of relapse, and hormone receptor status are independent predictors of outcome after relapse. After these main effects and the interaction between number of nodes involved and DFI are accounted for, nodal status remains a significant predictor of outcome after relapse. Indeed, when compared with node-negative patients, those with four or more involved nodes have a significantly worse outcome after relapse. However, for patients with only one to three involved nodes, the outcome is not significantly different from that of the node-negative patients. Thus, the number of involved nodes (rather than simply the absence or presence of nodal involvement) is a key determinant of prognosis after relapse.

The risk of axillary lymph node metastasis increases as tumor size increases, which suggests that nodal metastasis is indicative of tumor chronology (Tabar L, et al 1985). Yet, our study suggests that nodal status has prognostic importance after relapse, indicating that it is also a marker for tumor phenotype. These findings are not necessarily inconsistent. One might speculate that there is a continuum from slow-growing tumors with late axillary involvement to more aggressive tumors with early metastasis to the axilla (Koscielny S, et al 1989). A 1-cm, node-positive tumor might be chronologically early but biologically more aggressive when compared with a 2-cm, node-negative tumor. Thus, all breast cancers may eventually metastasize to the axillary nodes, with the propensity for early or late metastasis having prognostic importance after relapse. Therefore, nodal status may indicate both tumor chronology and phenotype.

Chapter Two

Section one

(Ultrasound characteristic of the lesion)

2.1. Breast ultrasound (Theoretical Baground) :

Breast ultrasound is an important modality in breast imaging. It is the usual initial breast imaging modality in those less than 30 years of age in many countries.

In assessing for malignancy, is important to remember that one must use most suspicious feature of 3 modalities (pathology, ultrasound, and mammography) to guide management.

-Breast ultrasound is targeted to a clinical problem.
-Reasonable sensitivity but poor specificity.
-May have a place in screening women at high risk or with MMG dense breasts.

2.1.1.Use of breast ultrasound:

1. to evaluate a young (usually under 30 years of age) or pregnant patient .
2. evaluate a palpable lump with negative or equivocal mammographic findings.
3. detect lesions in lower contrast field.
4. can help to distinguish between benign vs malignant characteristics.
5. for guiding biopsy.
6. for evaluation of breast implants for rupture.

-Features that are found NOT to be useful in differentiating malignant from benign lesions:

1- heterogenicity homogenicity of texture.
2- normal enhanced through transmission (i.e. mucinous cancers)
3- being iso-mildly hypoechoic.
4- maximum diameter.

Table 2.1 is a summary of those ultrasound characteristics (Stavros et al.(1995).

Malignant	Benign	Indeterminate
-Spiculation. -Angular margins. -Marked hypoechogenicity. -Posterior shadowing -Calcification. -Duct extension. -Branch pattern. -Microlobulations.	-Absent malignant findings. -Intense hyperechogenicity. -Ellipsoid shape. -Mild hypoechogenicity. -Gentle lobulations. -Thin, echogenic capsule .	-Normal sound transmission. -Isoechogenicity. -Mild hypoechogenicity. -Enhanced transmission. -Heterogenous texture. -Homogeneous texture.

With more accent now being placed on characterising breast density, more authors feel there is a place for screening ultrasound in the dense (> 75%) breast. In Connecticut ultrasound of the dense breast is now mandated and paid for by the state. There is good evidence that in this group of patients the yield of ultrasound in picking up cancers is almost as high as mammography itself in the range of an additional 3-4/1000 cancers found (Berg, ECR, 2013). In the context of screening for breast cancer, ultrasound in capable hands will find low grade DCIS that may not be visible on mammography. "Second look" ultrasound after breast MRI will yield a positive finding in about 56% of cases.

2.2.Malignant breast lesions:

Breast cancers can start in any part of the breast tissue and while most originate in the TDLU's or ducts, some do occur in the breast lobules. Malignant lesions are significantly different in appearance to benign lesions, and distort the normal tissue planes and invade surrounding tissue. A marked increased in vascularity is apparent with colour Doppler and these lesions have the potential to metastasize to distant tissues through lymphatic and vascular channels. Common Malignant lesions discussed in this section include invasive ductal carcinoma (IDC), ductal carcinoma in situ (DCIS), invasive lobular and invasive tubular carcinomas.

2.3.Ultrasound characteristic of the lesion:

Breast lesions at ultrasound have a number of characteristics which allows the classification as either malignant, intermediate or benign. In 1995, A. Thomas Stavros published an important paper in Radiology (Stavros AT, et al 1995) which established the usefulness of various ultrasound features in distinguishing benign from malignant lesions.

Malignant characteristics (with positive predictive values):

1. **Sonographic spiculation:** 87-90% (Stavros AT, et al 1995) : alternate hypo-hyperechoic lines radiating perpendicularly from surface of nodules (If lesion is surrounded by echogenic tissue, you will see hypoechoic strands. If lesion is surrounded by fat, echogenic strands may be seen).
2. **Deeper (taller) than wide**: 74-80% (Paredes ES. Et al 2007): except in certain grade III Invasive ductal carcinomas.
3. **Microlobulations**: 75% : small lobulations 1 - 2 mm on the surface; risk of malignancy rises with increasing numbers.
4. **Thick** Hyperechoic Halo: 74 %
5. **Angular Margins**: 70%
6. **Markedly Hypoechoic nodule:** 70%
7. **Sonographic Shadowing:** 50%

   branching pattern: 30% : multiple projections from the nodule within or around ducts extending away from the nipple, usually seen in larger tumours.

   Punctate Calcifications: 25% : which usually do not shadow.

8. **Duct Extension**: 25% : is seen as projection from a nodule which extends radially within or around a duct towards the nipple.
9. **Shadowing** (. Cardeñosa G. 2003).
10. **Heterogeneous echotexture** (. Cardeñosa G. 2003) .
11. **Compressibility**: in general terms, benign lesions compress with transducer pressure and malignant lesions displace the breast tissue without changing in height. This is the basis for elastography.

These ultrasound images reveal a hypoechoic, poorly defined, irregular mass in the breast. There is also evidence of acoustic shadowing posteriorly. These findings on sonography suggest malignant mass of the breast. Images courtesy of Dr. Nirmali Dutta, UAE.

Figure (2.1): malignant mass of the breast.

-These ultrasound images reveal a hypoechoic, poorly defined, irregular mass in the breast. There is also evidence of acoustic shadowing posteriorly. These findings on sonography suggest malignant mass of the breast. Images courtesy of Dr. Nirmali Dutta, UAE.

The below ultrasound images show a typical proven case of cancer of the left breast. The tumor is seen as a well defined hypoechoic mass with microlobulation or fine irregularities of the margins. In addition, the mass shows multiple echogenic areas along the rim a clear sign of malignancy in breast carcinoma. Images are courtesy of Ravi Kadasne, MD, UAE :

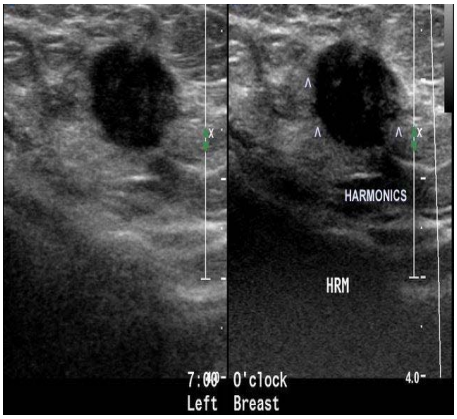

Blew image shows a markedly hypoechoic mass of the right breast, that seems to spread vertically (taller than wide), a sign of malignant nature of the breast tumor. In addition, note the presence of fine irregularities of the margin of the lump. All these sonographic findings are suggestive of a breast carcinoma. This ultrasound image is courtesy of Dr. ravi Kadasne, MD, UAE.

MI: 0.8
SIEMENS
VF10-5 / 'Breast NEW
2D
GEN / 10.00 MHz
47 dB / DR 65
ASC 5 / DTCE M
Map J / RS 3
D=28.6 mm
© www.ultrasound-images.com
40fps
4cm
Fr263

MI: 0.8
SIEMENS
VF10-5 / 'Breast NEW
2D
GEN / 10.00 MHz
50 dB / DR 65
ASC 5 / DTCE M
Map J / RS 3
© www.ultrasound-images.com
40fps
4cm
Fr509

Finding: Solid nodule	Positive predictive value
Spiculation	91.8
Taller than wide	81.2
Angular margins	67.5
Shadowing	64.9
Branching pattern	64.0
Hypoechogenicity	60.1
Calcifications	59.6
Duct extension	50.8
Branching pattern	48.0
Microlobulations	48.2

USG suspicious for malignancy

-Benign characteristics (with negative predictive values):

-Well circumscribed markedly hyperechoic tissue: ~ 100%

-Wider than deep: 99%

-Gently curving smooth lobulations (<3 in a wider than deep nodule, i.e. D/W ratio <1) : 99%

-Thin echogenic pseudocapsule in a wider than deep nodule : 99%. It is best seen on anterior / posterior margins, perpendicular to the beam. It probably represents normal compressed tissue consistent with a non infiltrative process.

2.3. Sonographic Differentiation of solid breast lesions:

Breast sonography is not universally accepted as a screening technique. Differentiating masses as cystic or solid has been accepted as the traditional role of ultra sound in workup of breast masses. Further evolution of solid masses has been advised either by FNAC, large core percutaneous technique or excisional biopsy. Though well tolerated, these techniques do have some risk, induce patient discomfort and increase overall cost of health care. .

With recent advances in technology, new hardware and software improvement and availability of Dynamic high resolution, real time ultrasound attempts are being made to evaluate solid breast masses further and differentiate benign from malignant lesions.

There is an overlap in sonographic findings between benign and malignant solid breast lesions. To be able to characterize all solid breast nodules is impossible. A reasonable goal is to identify subgroup of nodules that has low risk of being malignant so that option of follow up One has to rely upon an array of findings to evaluate solid breast lesions and call it benign or malignant. No characteristics are absolutely specific and it is impossible to distinguish all benign from all solid breast nodules using Sonographic criteria. However Sonographic criteria are :

2.3.1. Shape and margin of the lesion:

The shape of a mass can be described as round, oval, lobulated or irregular. Round and oval shapes are suggestive of benign masses. As long as there are fewer than three lobulations, the chances of malignancy is very less. The presence of greater than three lobulations is an indeterminate feature. Irregular shape is suspicious of malignancy. The margin of the lesion reflects the demarcation of the mass with surrounding tissue. It can be smooth, micro lobulated, irregular or spiculated. Gentle bilobulate or Tri lobulated margins are considered smooth. Presence of 2 or 3 gentle smooth, circumscribed and well-encapsulated lobulation strongly favours a benign etiology over cancer. The presence of many small lobulations, that is microlobulation, on surface of solid breast lesion is suspicious of malignancy. Numerous lobulations give the lesion a pleomorphic shape. Microlobulation are frequently associated with angular margins. All lesions with irregular shape, ill defined margins and / or spiculation irrespective of their internal structure, sound transmission and orientation are suspicious of malignancy. If such a lesion is accompanied by satellite lesions, enlarged lymph nodes, ingrowth into isoechoic lesion and surrounding tissues. Obtuse or acute pointed junctions are formed between the mass and surrounding tissues. Irregular margin or presence of spiculation indicate invasion of lesion into surrounding tissue. Sonographic spiculation consists of alternating hypoechoic and relatively hyperechoic lines radiating out from the nodule.

Only hypoechoic or relativel is characterized malignant. .

2.3.2.Width-AP dimension ratio:

It has been suggested that benign masses tend to grow within the plane of the breast resulting in lesions that are relatively wide in length or width relative to their AP dimension. In contrast, the infiltration of malignant masses presumably allows them to grow perpendicular to the plane of the breast. Simple measurement of the lesion dimension has not proven useful as the sole means of differentiating benign from malignant lesions, but it one of the several discriminating features. Benign lesions, like fibroadenomas, which grow horizontally within tissue planes, have a greater width than AP dimension and are compressible, partially resulting into their oval shape. Most carcinomas traverse surrounding tissue planes, resulting in a more vertical orientation, are firm and much less compressible. In consideration with other criteria, Width to AP ratio greater than 1.4 is suggestive of benign lesion where as 1.4 or less characterized the malignant ones. .

2.3.3.Echogenicity: The lesions can be anechoic, hypoechoic, isoechoic and hyperechoic. An anechoic lesion is a benign cyst, but a complex cyst with thickened wall is suspicious and if there is also presence of intracystic growth it is probably a malignant lesion. To comment on echogenicity of lesion, the surrounding fat lobules should be used as reference level. Markedly hypoechoic lesion with respect to fat is probably malignant. .

2.3.4.Internal Echo pattern:

A lesion can be homogeneous or heterogeneous. Homogeneity or Heterogeneity reflects the diversity of tissue components within the lesion. A heterogeneous lesion has a more chance of being malignant. However both benign as well as malignant lesions.

2.3.5.Shadowing:

Many of the malignant lesions attenuate sound and cause shadowing behind all or part of the mass. It is common with scirrous cancers and less with highly cellular tumors.

2.3.6.Calcifications:

Calcifications seen within such a nodule are more likely to be malignant than benign.

2.3.7.Duct Extension:

Malignant breast nodules sometimes have projections from the surface of the nodule, which extend radially within a duct toward the nipple (duct extension) and/or within ducts away from the nipple (branch pattern). All of these findings suggest that the nodule extends into or along the ductal system. This increases the chance that the nodule is malignant and has components of intraductal cancer.

To conclude, malignant features include an irregular shape; micro lobulated, ill-defined or spiculated margins, AP dimension greater than width; marked hypoechogenicity; attenuating distal echoes and punctate calcifications. Features typical of benignity are homogeneous hyperechogenicity; a thin echogenic capsule; ellipsoid shape and fewer than four lobulations. A lack of all malignant features plus a combination of benign features is required for the mass to be characterized as benign (Zonderland HM, et al 1999).

Section two

(Literature review)

2.4 Anatomy of the breast:

Breast shape varies among patients, but knowing and understanding the anatomy of the breast ensures safe surgical planning. (See the image below.) When the breasts are carefully examined, significant asymmetries are revealed in most patients. Any preexisting asymmetries, spinal curvature, or chest wall deformities must be recognized and demonstrated to the patient, as these may be difficult to correct and can become noticeable in the postoperative period. Preoperative photographs with multiple views are obtained on all patients and maintained as part of the office record (Thorne CH, et al 2007).

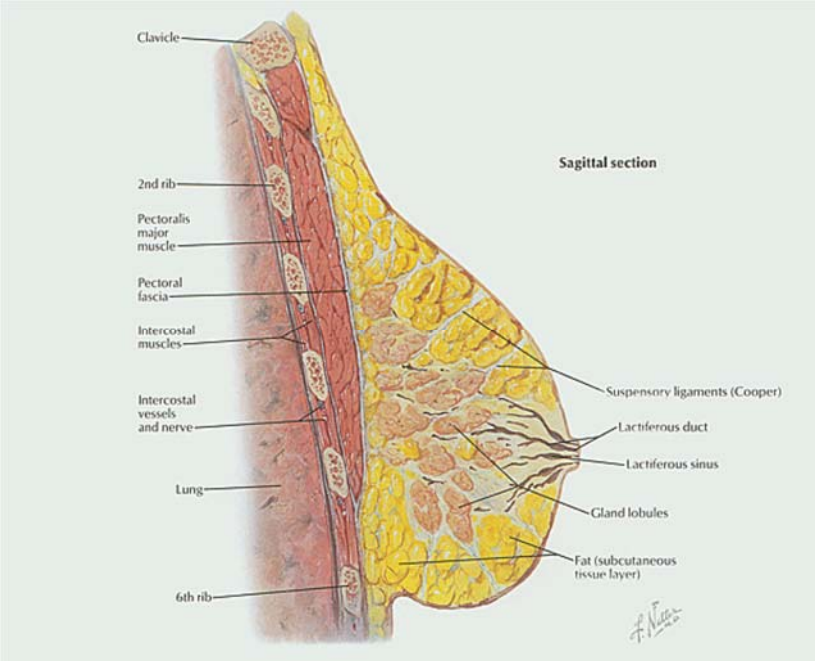

Image (2.2) Anatomy of the breast.

2.4.1. Anatomy of the breast Vascular Anatomy and Innervation of the Breast :

The blood supply to the breast skin depends on the subdermal plexus, which is in communication with deeper underlying vessels supplying the breast parenchyma. The blood supply is derived from the following:

1. -The internal mammary perforators (most notably the second to fifth perforators).
2. -The thoracoacromial artery.
3. -The vessels to serratus anterior.
4. -The lateral thoracic artery.
5. -The terminal branches of the third to eighth intercostal perforators.

The superomedial perforator supply from the internal mammary vessels is particularly robust and accounts for some 60% of the total breast blood supply. This rich blood supply allows for various reduction techniques, ensuring the viability of the skin flaps after surgery (Maxwell GP, et al 2009).

Sensory innervation of the breast is dermatomal in nature. It is mainly derived from the anterolateral and anteromedial branches of thoracic intercostal nerves T3-T5. Supraclavicular nerves from the lower fibers of the cervical plexus also provide innervation to the upper and lateral portions of the breast. Researchers believe sensation to the nipple derives largely from the lateral cutaneous branch of T4.

2.4.2. Breast Parenchyma and Support Structures :

The breast is made up of fatty tissue and glandular, milk-producing tissues. (See the image below.) The ratio of fatty tissue to glandular tissue varies among individuals. In addition, with the onset of menopause (ie, decrease in estrogen levels), the relative amount of fatty tissue increases as the glandular tissue diminishes.

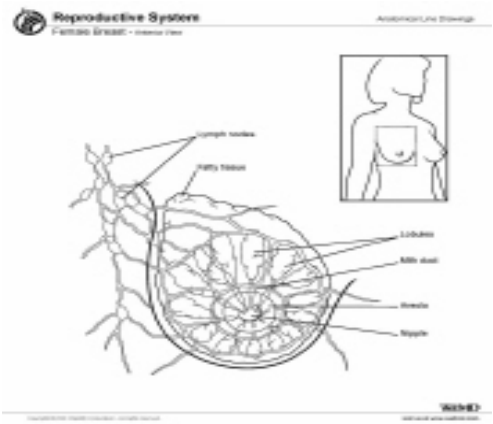

figure (2.3) Female breast, anterior view.

The base of the breast overlies the pectoralis major muscle between the second and sixth ribs in the nonptotic state. The gland is anchored to the pectoralis major fascia by the suspensory ligaments first described by Astley Cooper in 1840. These ligaments run throughout the breast tissue parenchyma from the deep fascia beneath the breast and attach to the dermis of the skin. Since they are not taut, they allow for the natural motion of the breast. These ligaments relax with age and time, eventually resulting in breast ptosis. The lower pole of the breast is fuller than the upper pole. (See the image below.) The tail of Spence extends obliquely up into the medial wall of the axilla (Maxwell GP, et al 2009).

The breast overlies the pectoralis major muscle as well as the uppermost portion of the rectus abdominis muscle inferomedially. The nipple should lie above the inframammary crease and is usually level with the fourth rib and just lateral to the midclavicular line. The average nipple–to–sternal notch measurement in a youthful, well-developed breast is 21-22 cm; an equilateral triangle formed between the nipples and sternal notch measures an average of 21 cm per side (Maxwell GP, et al 2009).

2.4.3. Musculature Related to the Breast :

The breast lies over the musculature that encases the chest wall. The muscles involved include the pectoralis major, serratus anterior, external oblique, and rectus abdominis fascia. The blood supply that provides circulation to these muscles perforates through to the breast parenchyma, thus also supplying blood to the breast. By maintaining continuity with the underlying musculature, the breast tissue remains richly perfused, thus preventing complications from arising from aesthetic or reconstructive surgery that requires the placement of a breast implant.

2.4.3.1. Pectoralis major:

The pectoralis major muscle is a broad muscle that extends from its origin on the medial clavicle and lateral sternum to its insertion on the humerus. The thoracoacromial artery provides its major blood supply, while the intercostal perforators arising from the internal mammary artery provide a segmental blood supply. The medial and lateral anterior thoracic nerves provide innervation for the muscle, entering posteriorly and laterally. The action of the pectoralis major is to flex, adduct, and rotate the arm medially.

The pectoralis major is extremely important in aesthetic and reconstructive breast surgery, since it provides muscle coverage for the breast implant. In reconstructive surgery, the pectoralis major muscle covers the implant, providing a decreased risk of exposure of the implant, since the skin and underlying subcutaneous tissues are often thin following mastectomy. The muscle also provides additional tissue between implant and skin, thus decreasing palpability of the implant.

Often, placement of the implant beneath the muscle causes it to be noticeable when the pectoralis is contracted. In these instances, it may be helpful to release the pectoralis muscle from its inferior and medial attachments to decrease the incidence of noticeable contractions. In addition, with inferior release of the pectoralis muscle, lower positioning of the implant can be achieved, resulting in a more aesthetically pleasing appearance.

2.4.3.2. Seriates anterior :

The serratus anterior muscle is a broad muscle that runs along the anterolateral chest wall. Its origin is the outer surface of the upper borders of the first through eighth ribs, and its insertion is on the deep surface of the scapula. Its vascular supply is derived equally from the lateral thoracic artery and from branches of the thoracodorsal artery. The long thoracic nerve serves to innervate the serratus anterior, which acts to rotate the scapula, raising the point of the shoulder and drawing the scapula forward toward the body. Transection of the long thoracic nerve is carefully avoided during an axillary lymph node dissection, since its loss results in "winging" as the scapula is released from the chest wall and moves upward and outward.

Because the serratus anterior underlies the lateral aspect of the breast, in aesthetic surgery, blunt elevation of the pectoralis major laterally inadvertently elevates a small portion of the serratus muscle. Often the serratus anterior must be elevated sharply to obtain a sufficient muscle layer to provide coverage of the implant.

2.4.3.3. Rectus abdominis :

The rectus abdominis muscle demarcates the inferior border of the breast. It is an elongated muscle that runs from its origin at the crest of the pubis and interpubic ligament to its insertion at the xiphoid process and cartilages of the fifth through seventh ribs. It acts to compress the abdomen and flex the spine. The 7th through

12th intercostal nerves provide sensation to overlying skin and innervate the muscle. Vascularity of the muscle is maintained through a network between the superior and inferior deep epigastric arteries.

When placing an implant for breast reconstruction, in attempting to achieve complete coverage with muscle, the rectus fascia must often be elevated to place the implant sufficiently caudal. This dense, thick fascia is often intimately adherent to the ribs below it. Once the fascia is elevated and released, proper positioning and expansion of the implant can proceed.

2.4.3.4. External oblique :

The external oblique muscle is a broad muscle that runs along the anterolateral abdomen and chest wall. Its origin is from the lower 8 ribs, and its insertion is along the anterior half of the iliac crest and the aponeurosis of the linea alba from the xiphoid to the pubis. It acts to compress the abdomen, flex and laterally rotate the spine, and depress the ribs. The 7th through 12th intercostal nerves serve to innervate the external oblique. A segmental blood supply is maintained through the inferior 8 posterior intercostal arteries.

The external oblique muscle abuts the breast on the inferior lateral aspect. Elevated along with the rectus abdominis fascia to provide inferior coverage of the breast implant during reconstructive surgery, its fascia, like the fascia of the rectus abdominis muscle, must be released adequately to provide for proper placement and expansion of the implant. In aesthetic surgery, placement of the implant inferiorly is usually not below these fascial attachments. If the implant is placed behind the fascia, the implant often "rides too high" and may result in a "double bubble" effect, wherein the breast parenchyma slides over and off the implant.

The arrangement of the chest wall, shoulder bones and muscles, and the upper arm create a small hollow called the armpit. The armpit is the underside of the shoulder joint, and is among the warmest areas of the body. The armpit is also called the axilla.

2.4.4 Lymphatic drainage of the breast

Originate from breast lobules and flow into a sub-areolar plexus, called Sappey’s plexus. From this plexus, lymphatic drainage takes place through three main routes:

axillary or lateral pathway

- fed by Sappey's Plexus, as well as by ducts satellite lymphatics and by most of parenchymal lymphatics.
- this pathway runs around the inferior edge of the pectoralis major and reach the pectoral group of axillary nodes

internal mammary pathway

- originates from both the lateral and medial halves of the breast and passes through the pectoralis major; connections may lead across the median plane and hence to the contralateral breast

retromammary pathway

- comes from the posterior portion of the breast

Lymphatics may reach the sheath of the rectus abdominis and the subperitoneal and subhepatic plexuses.

Usually axillary lymph nodes receive more than 75% of the lymph drained from the breast.

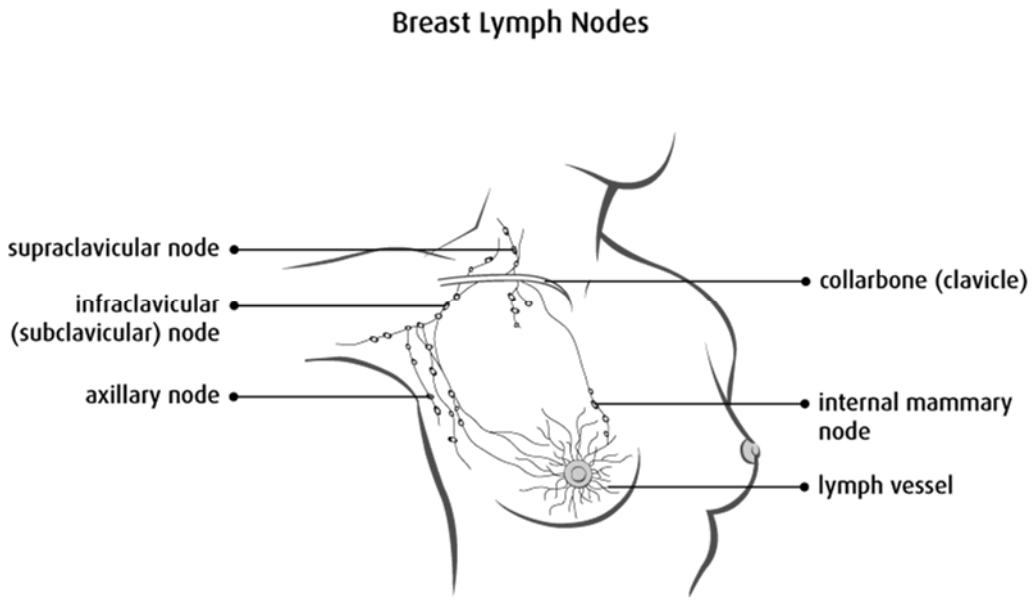

Figure(2.4): Breast Lymph Node.

The breast lymph nodes include:

1. -Supraclavicular Nodes – above the Collarbone.
2. -Infraclavicular (or Subclavicular) Nodes – below the collarbone.
3. -Axillary Nodes – in the Armpit (Axilla).
4. -Internal Mammary Nodes – inside the chest around the Breastbone (Sternum)

2.4.5 . Hormones of the breast:

In order to produce milk, hormones are needed. The two main hormones are prolactin and oxytocin.

Prolactin is produced by the adenohypophysis (anterior pituitary) and released into the circulation. The regulation of prolactin levels in the plasma is controlled by the dopaminergic system. Prolactin acts on the human breast to produce milk. This occurs by binding to mammary epithelial cell receptors, which stimulates synthesis of mRNA of milk proteins (Lawrence, et al 2011). It takes several minutes of the infant sucking at the breast to cause prolactin secretion. Prolactin is also important in inhibiting ovulation.

Oxytocin is produced by the neurohypophysis (posterior pituitary). Suckling at the breast stimulates the neurohypophysis to produce and release oxytocin in an intermittent manner. Oxytocin acts on the breast to produce milk ejection or "milk let down." Oxytocin also causes uterine contractions. Opiates and B endorphins released during stress can block the release of oxytocin (Lawrence, et al 2011 p76-81). Newton showed that women who received a saline injection and were distracted during breastfeeding produced less milk than women who were not distracted or women who received an injection of Pitocin (synthetic oxytocin) prior to distraction and breastfeeding (Newton M, et al 1948). Lack of release of oxytocin inhibits the "milk let down" and the milk cannot be removed from the breast (Neville, et al 2001).

Other hormones necessary for the production of breast milk include: insulin, cortisol, thyroid hormone, parathyroid hormone, parathyroid hormone-related protein, and human growth hormone.

A recently described hormone, Fil (feedback inhibitor of lactation), seems to play an important role in regulation of milk supply. Fil acts locally within each breast. Fil is secreted into breast milk. When the breast is not emptied, Fil remains in contact with the alveolar cells. Fil appears to act on an apical receptor on the alveolar cell. This inhibits secretion of milk constituents. The complete mechanism is not yet understood, however this appears to be the mechanism of decreased milk production due to not emptying the breast. (Wilde, et al 1998 **)**

2.5 Literature studies:

Invasive ductal cancers (IDC) were assessed in a study performed from 1993 - 2002

by Rotstein & Neerhut (2005) where the characteristics of Grade 3 IDC's were evaluated - 87% of those tumours had "a margin with an echogenic rind, microlobulation or angular margins" . Posterior shadowing or enhancement and echogenicity were all assessed but it was the tumour margin that was most telling.

Acoustic shadowing was absent in 70% of the cases. Rotstein & Neerhut comment that these lesions tend to be very cellular and show less distortion of the tissue planes in the breast. Assessment of the interface between the tumour and adjacent breast tissue is essential to determine the extent of the lesion. IDC's of the breast account for a high percentage of breast cancers (Perlmutter, 2008) where the cancer cells form in the lining of the ducts and may penetrate through the ductal wall and invade nearby healthy tissue. Younger women tend to have more aggressive forms of IDC and these appear on the ultrasound image as solid and circumscribed, with pushing margins. They infrequently appear as benign lesions due to their cellular nature and may even enhance, appearing brighter, due to their celluarlity. The slower growing IDC's often shadow in the ultrasound image as they are less cellular, appearing as a "poorly differentiated lesion surrounded by collagenous fibre". Watermann, Tempfer, Hefler & Stickeler (2005) comment that the ultrasound appearance of these cancers vary significantly from an indistinct margin to posterior shadowing.

Ductal carcinoma in situ (DCIS) is described pathologically as a "malignant neoplasm of the breast that is confined to the ducts and lobules, without invasion into them surrounding breast stroma" by Boonjunwetwat, Chyutipraiwan, Sampatanukul & Chatamra (2007). Piccoli (2003) bb describes ultrasound findings of DCIS as a

“micro-lobulated, hypoechoic mass with calcifications and ductal extension”. The dilated ducts may appear as hypoechoic, well-defined, tubular structures, differing from the normal breast parenchyma . DCIS was identified mammographically in 73-98% of cases by the presence of the microcalcifications (Boonjunwetwat et al). Micro-calcifications may appear as hyperechoic foci that have reproducible positions, seen in both transverse and longitudinal images. The micro-calcifications associated with DCIS are always multifocal and have a variable appearance. Micro-calcifications are classified as being linear, granular and of a mixed form, with granular micro-calcifications most commonly associated with DCIS. Hashimoto, Kramer & Picozzi (2001), with a small cohort of patients (18), assessed the ultrasound characteristics of micro-calcifications in patients with biopsy-proven DCIS. These authors reported a 94% sonographic detection rate. Benson et al. (2004) comment that mammography was superior to ultrasound in the detection of DCIS due to the lack of soft tissue changes and the sensitivity for detection of micro-calcifications by mammography.

Invasive lobular cancer was the focus of a study by Selinko, Middleton & Dempsey

(2004). Evaluation of the comparative sensitivity of ultrasound in the detection of these lesions was undertaken with a cohort of 62 patients with pathologically proven invasive lobular cancer. Invasive lobular cancer infiltrates in a diffuse manner with no apparent architectural distortion to the breast tissue – a histological analysis shows an ‘Indian file’ pattern of tumour cell arrangement (Tabar, 2007, p. D-34). On ultrasound lobular carcinomas can be seen as a hypoechoic mass without identifiable margins.

Malignant tumors other than invasive ductal or lobular were less common in this study. Infiltrating tubular carcinoma is slow-growing tumour that infrequently metastasizes. It is defined as having “at least 75% of the tumour composed of tubular structures”. Gunhan-Bilgen (2007) assessed tubular carcinomas in 2872 women, determining it to be seen on mammography as a small, speculated mass, and then on ultrasound as an irregular mass with posterior acoustic shadowing. Tabar (2007) commented that 40% of patients with tubular carcinoma report a “positive family history among first degree relatives” .

Not all lesions fulfill the classic criteria of a given pathology. Ultrasonically the appearance of these lesions is quite different and while much research has been performed, the seminal study by Stavros et al. (1995) is still applicable in the practice of breast imaging today. Appreciating the ultrasonic features of benign, indeterminate and malignant breast lesions is vital if areas of altered echotexture are to be detected. The next section will describe the principal features of these lesions with the characteristics that may be present in the ultrasound image.

Chapter three

Material & method

3.1: Introduction :

The aims of this study was to evaluate and study ultrasound characteristic of the breast ca. the breast ultrasound procedure is commonly performed to determine if an abnormality detected by mammography or a palpable lump is a fluid-filled cyst or a solid tumor (benign or malignant). Breast ultrasound may also be used to identify masses in women whose breast tissue is too dense to be measured accurately by mammography. Breast ultrasound is generally not used as a screening tool for breast cancer detection because it does not always detect some early signs of cancer such as microcalcifications, which are tiny calcium deposits.

Ultrasound may be used in some women who should avoid radiation, such as pregnant women, women younger than 25 years old, women who are breastfeeding, and women with silicone breast implants. The procedure may also be used to guide interventional procedures such as needle localization during breast biopsies and cyst aspiration (removal of fluid from cyst).

3.2. The study design & the study duration:

The study group (100) patients was taken from a screened population (200) patients who presented consecutively for routine annual screening or diagnostic breast imaging at (Antalya medical center) & (RICK :Radiation & Isotope Khartoum Center) . The study period was from Feb. 2014 through to September 2014 .

Individual patient consent was not required for this study and no exclusion criteria were applied to these patients. All relevant study data was accessed and retrieved from two sources: a medical database specific to this radiology practice and from a handwritten record of biopsy data and reports. The handwritten record contained the patient's name, the presumed pathology based on imaging results with the final pathology result following analysis by Antalya medical center lap and RICK lab.

3.3. The patient population:

All patients who presented for examination during the study period belonged to one of following categories:

- patients who were asymptomatic and between biennial breast screening years with BSA, choosing to have more regular imaging. (screening patients).
- patients who were symptomatic and between biennial breast screening years and were now aware of a new breast symptom –(diagnostic patients) Within the practice, there was an awareness that a greater percentage of cancers would be detected in those with risk factors or those who presented for a diagnostic examination.

The range of personal patient information (unique identifier applied) stored in the database included all relevant examination, historical, genetic and pathological detail as listed below:

a. age of patient.

b. type of the malignant lesion.

c. date of examination.

d. age at time of breast tissue biopsy

e. lymph node invasive or not ?

f. measurement/s of the lesion/s.

g. Metastases invasation or not?

3.4. Ultrasound imaging method :

The ultrasound examinations were performed either- there is metastases or not ?

3.4.1.Machine used:

-er on the Toshiba Xario (Toshiba Corporation, Tokyo, Japan) or sonoscape . High resolution 12-14MHz broadband , linear array transducers were used .

3.4.2.Technique used:

The ultrasound scan was performed in a radial pattern, beginning at the periphery of the breast and moving inward. Each quadrant was scanned with overlap at the 12-, 3-, 6- and 9-o'clock positions followed by scanning in orthogonal planes to complete the assessment. Imaging of each axilla was deemed an essential part of the ultrasound examination. Images and measurements were obtained for all solid masses, complex cysts, areas of architectural distortion, acoustic shadowing and dominant simple cysts. For examinations with negative findings, representative images were obtained in each of the four quadrants bilaterally, including the axillae.

Sonographic findings were classified as normal (no simple cysts, ductal ectasia or focal lesions), benign (simple cysts or sonographically benign solid lesions) or indeterminate / suspicious for malignancy.

3.5.Statistical analysis:

The total number of breast biopsies performed and breast cancers detected were

calculated for:

- the total screened population (200).

-Study group (100).

- the patients with malignant breast lesion (50).

Performance characteristics were calculated with the use of (2x2 contingency table) analysis (for each grouping of patients breast ultrasound. The sensitivity, specificity, positive predictive value, negative predictive value and accuracy were calculated by using the true positive, true negative, false positive and false negative results.

True positive breast lesions (TP) were identified as (malignancies with ultrasound imaging), and then proven malignant through the histological analysis of a tissue sample. False positive results (FP) related to lesions that were(suspicious for malignancy on imaging, however were proven benign in histology).

Traditionally, this type of statistical assessment would attribute a true negative (TN) or false negative (FN) result as meaning either an examination where no abnormality was detected on imaging and a biopsy was not performed (TN); or an examination where imaging suggested a benign lesion, though the tissue sample was proven malignant (FN). These standard definitions do not apply to this retrospective study, for there was no possibility for follow-up of the total screened population (200) who were imaged and declared to have no abnormality detected.

value	**Ultrasound** **No**
True positive	50
True negative	37
False positive	7
False negative	6

Table (3.1) : The contingency table :

Chapter four

Results

4.1. Introduction:

Diagnostic implies that the patient or their referrer was concerned about specific breast symptoms including nipple discharge, generalized or localized soreness / tenderness, unexplained redness, lump/s, increasing tenderness, pain, intermittent pain, a change in the size of a lump, change / roughness in the skin surface, dimpling or puckering of the skin or nipple. Screening implies that the patient was asymptomatic, having no specific concerns.

4.2. Lesions classification &types :

The patients with an ultrasound detected lesion were aged 20 – 80 of years, The lesions measured 1 – 10 cm in diameter with a mean size of (4.35),cm (SD 0.37).

These lesions were considered suspicious for malignancy based on the ultrasound appearance and verification with core biopsy was deemed appropriate. Three (3) lesions considered most likely benign in appearance and thought to be fibroadenomas or fibrocystic change but were proven Grade I (1) and II (2) invasive carcinomas, giving a false negative result. Two lesions were false positives; malignancy was suspected and the histology proved the lesions were a lipoma and fibroadenoma. The remaining 50 lesions were proven malignant, giving a true positive result for DCIS (4): 8%,Grade I(3):6%, Grade II(23): 46%, Grade III invasive ductal carcinomas(10):20% ,Infiltrating Lobular Carcinoma(2):4%,Invasive lobular carcinoma**(1)**2%

Ca Types	No. of cases
-DCIS	**4**
-Grade I IDC	**3**
-Grade II IDC	**23**
-Grade III IDC	**10**
-Grade IV IDC	**7**

Table (4.1) : Show the type of breast ca & the number of cases for each type :

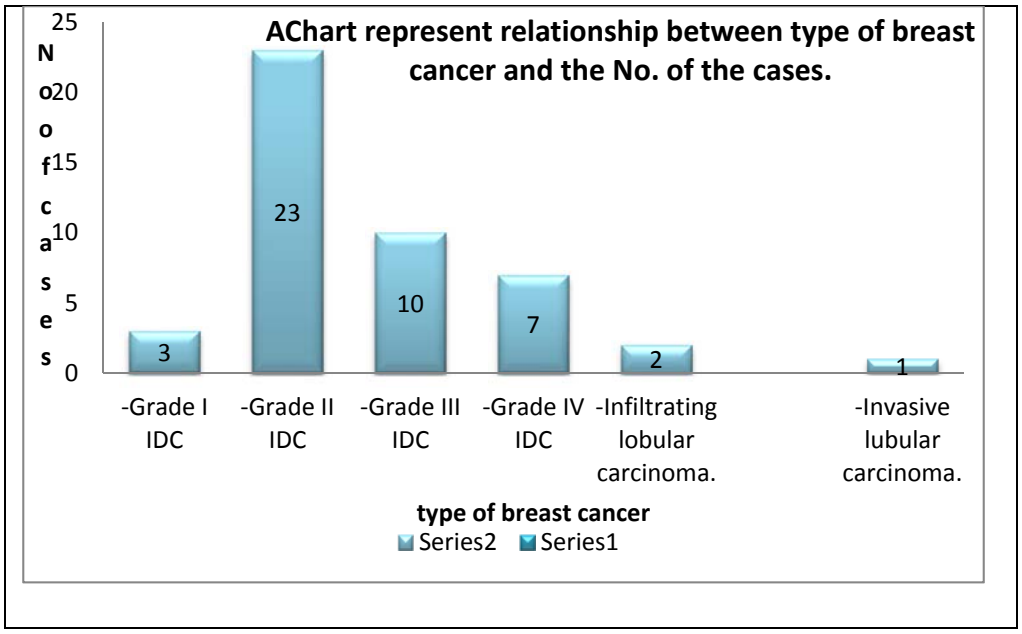

Figure (4.1) : depicts the relationship between cancer type & the number of cases.

4.3. Patient age:

Malignant lesions were histologically proven in 50 of the patient in this study; the patient's age at the time of biopsy was assessed : The median age of these patients was years (SD 0.93), ranging from (20 to 80) years. Table (7)and Figure(9) documents the patient age & the No of patient ,percentage for each range of age .

Patient age	frequency
(20-29)	2
(30—39)	9
(40-49)	19
(50-59)	10
(60-69)	7
(70-80)	2

Table (4.2) : Patient age:

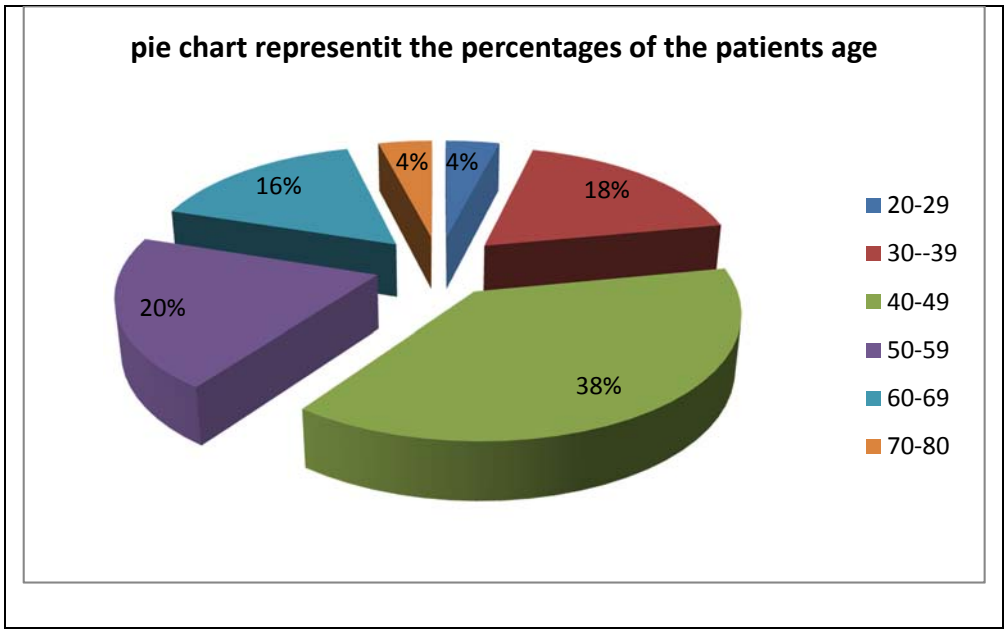

Figure (4.2): a chart represents the percentage of patients age.

4.4.Lesion sizes:

Lesion sizes were measured during the ultrasound scan . Measurements for the lesions ranged from 1 – 10 cm with a mean of 4.35cm (SD 0 .37), and a median of cm. Among the histologically confirmed breast cancers, 18 were < 3cm, 17 were < 5cm and 5 patients were (9-10) cm .

Lesion size	No of malignant lesion
(1-2.9)	18
(3—4.9)	17
(5-6.9)	6
(7-8.9)	4
(9-10)	5

Table (4.3): show the size and number of malignant lesions.

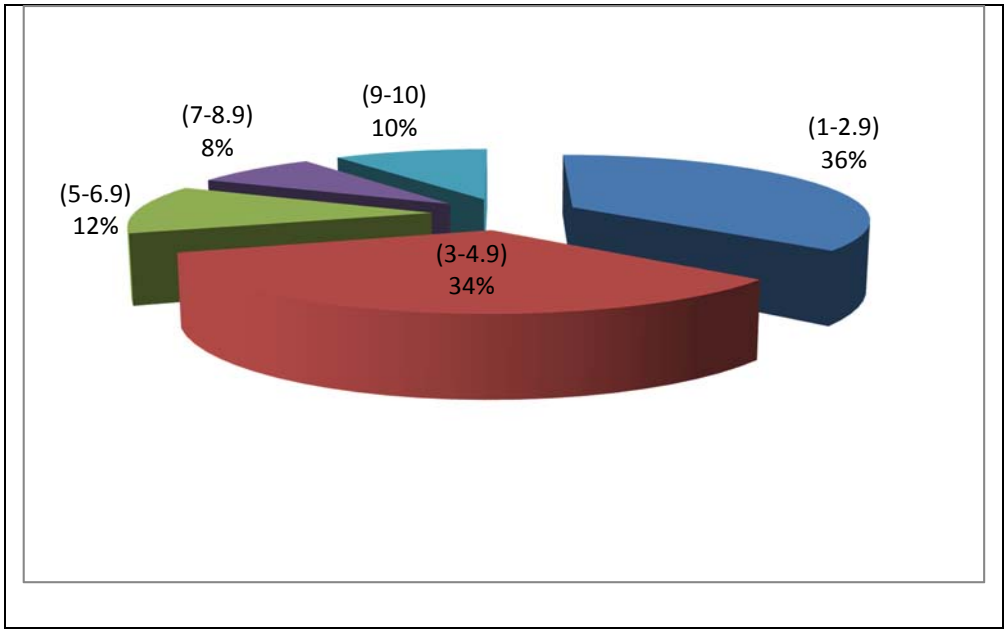

Figure (4.3) : represents the percentages of number of malignant lesions & the size of the lesions :

Information was recorded relative to their appearance in the breast tissue as seen in the ultrasound image. These observations were due to recognition of change that had occurred in the breast tissue relative to prior imaging.

summary of the accuracy, sensitivity, specificity and predictive values , A discussion of all these statistical results can be found in chapter 6.0.

4.5.lymph node involvement:

lymph node involvement in Grade II IDC (12 case) of all the sample , in Grade IDC (13 case) , & in infiltrative DC was (3 case).

pathology	No .of lymph 1n. cases	All the ca cases
DC1S	**0**	**4**
Grade **I** IDC	**0**	**3**
Grade **II** IDC	**12**	**23**
Grade **III** IDC	**10**	**10**
Grade **IV** IDC	**7**	**7**
Infiltrating lobular ca.	**2**	**2**
Invasive lubular ca.	**1**	**1**

Table (4.4): show the breast cancer type & the number of involved lymph node.

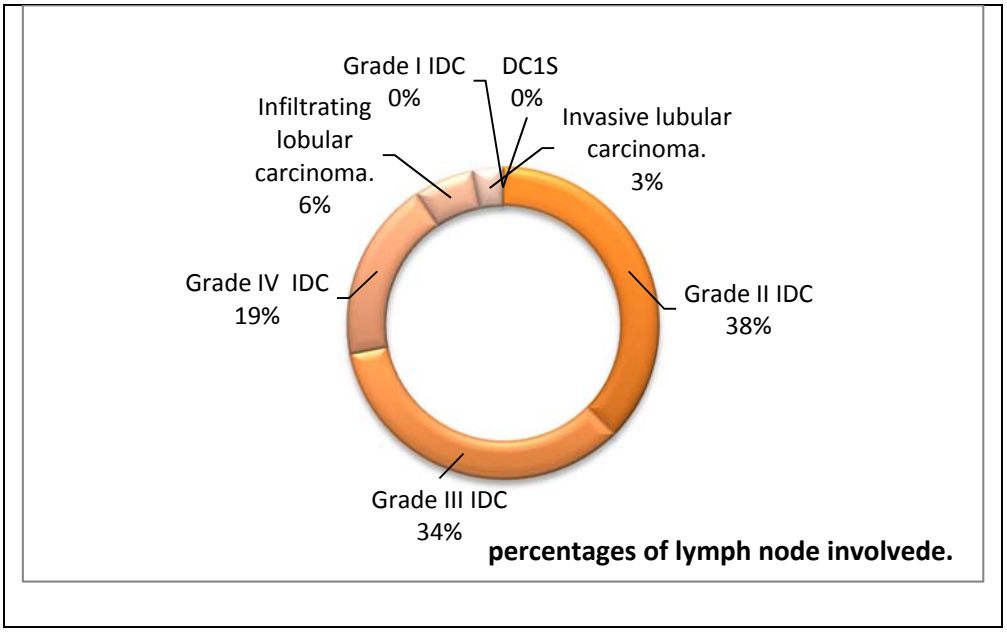

Figure (5.3): show the breast cancer type & the percentages of involved lymph node.

5.5.Metastases involvement :

Metastases spread to the other parts : skeletal , bone , lung ,spine, ribs and brain was high rate in grade IV IDC (70 %) from all cases and (30%) from the Grade III IDC, in infiltrating lubular carcinoma(50%) of all the cases have metastases spread, and all the cases of infiltrating lobular carcinoma have metastases involvement. this is result is also expected because of the high grade of the breast ca.

pathology	No .of cases	All the ca cases
DCIS	0	4
Grade I IDC	0	3
Grade II IDC	1	23
Grade III IDC	3	10
Grade IV IDC	5	7
Infiltrating lobular ca.	1	2
Invasive lobular ca.	1	1

Table (4.5):show the breast ca type & the number of lymph nodes involved.

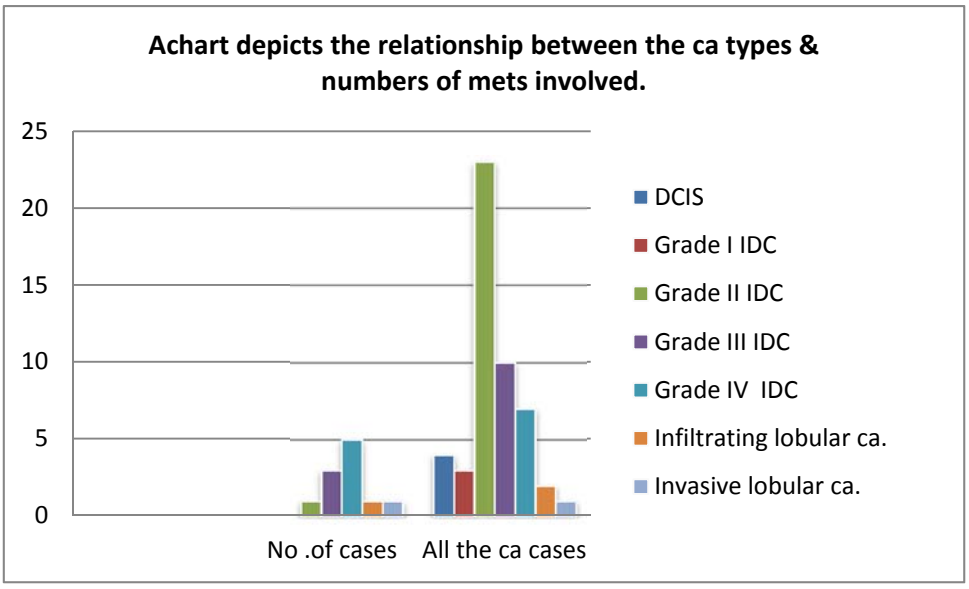

Figure (6.3):show the breast ca type & the number of lymph nodes involved.

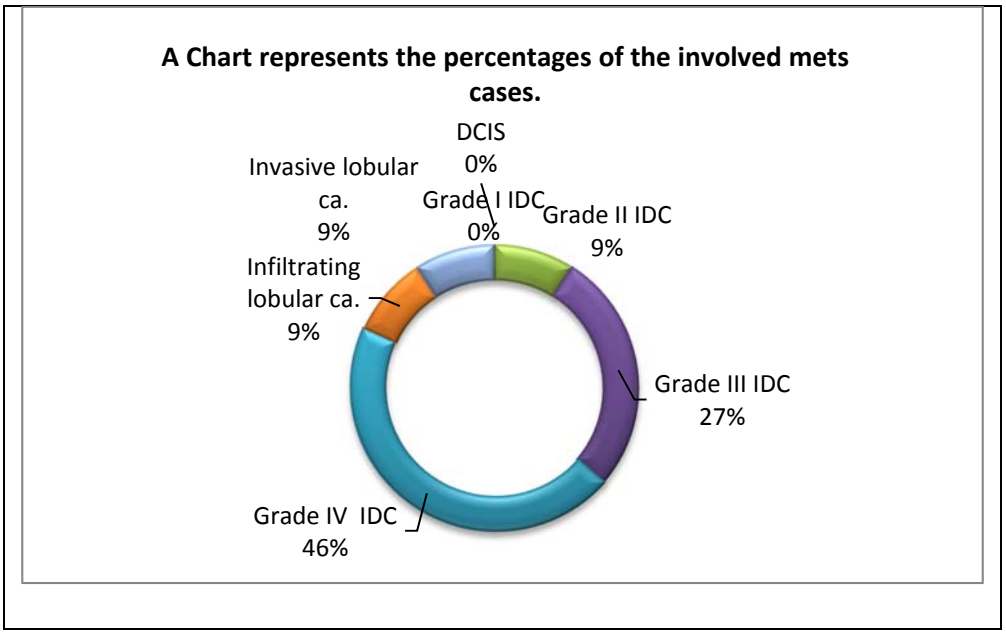

Figure (7.3):show the breast ca type & the percntages of lymph nodes involved.

Chapter five
Discussion

This chapter will discuss the results of breast ultrasound from this study and assess those results with reference to current literature.

Ultrasound uses sound waves to study the breast. Based on the same principle as radar, the sound waves are sent into the body and then reflected back to form an image on a computer screen for analysis , ultrasound is useful in diagnosing cancerous lesions . It is the best test to "rule out" the possibility of a cancer as it can distinguish whether a lump is solid (made of tissue) or a cyst (filled with water). Ultrasound can detect a simple cyst, which is noncancerous, with 100% accuracy and when this is the case, no further tests are required.

Sometimes ultrasound is used to make a highly accurate prediction that a solid lump is cancerous, however, it is generally not used in screening for cancer as it usually cannot detect tiny microcalcifications that indicate early cancer.

Diffuse, rapid spreading malignancies are often known to be subtle in presentation and a skilled eye is necessary to perceive the often subtle changes in breast tissue. These issues, along with the relevant limitations and variables applicable to this study will be addressed in the following pages.

The data for this study was obtained from two sources; a patient database and a handwritten record of biopsy information documented during the study period. The accuracy of the database information was dependent on those who input the data and contained principal data of the patient and their breast imaging history. Some of the cases in this study had incomplete dataset and there is some patients were excluded due to incomplete information.

Types of the common malignant lesions was graded into 5 types these are Grade I invasive ductal carcinomas , Grade II invasive ductal carcinomas , Grade III invasive ductal carcinomas(, infiltrating lubular carcinoma and invasive lobular carcinomas .the most common types was Grade II invasive ductal carcinomas.

These lesions were considered suspicious for malignancy based on the ultrasound appearance and verification with core biopsy was deemed appropriate. Type Grade II IDC was the most common type (23 patients) with percentage of (49%) from all types of breast ca , and then the Grade III IDC (10 patients) , represents(20%) ,this percentage is also rather high comparing with other types.

Malignant lesions were histologically proven in 50 of the patient in this study; the patient's age at the time of biopsy was assessed , ranging from (20 to 80) years. With

Median of (48 years) & (SD of 0.93) that main that the median age of breast ca in sudan is (49 years) and the age is considered a very important risk factor.

Lesion sizes were measured during the ultrasound scan . Measurements for the lesions ranged from (1 – 10) cm with a mean of 4.35,that main the size of tumor of less than 3 cm is the most frequent size (18 lesions), and the size of tumor less than 10 cm is less frequent (5 lesions).

Information was recorded relative to their appearance in the breast tissue as seen in the ultrasound image. These observations were due to recognition of change that had occurred in the breast tissue relative to prior imaging.

lymph node involvement in our study was high in Grade II IDC about 48% of all the Grade II IDC type, and all the cases of Grade III IDC was have lymph node invasive. thus all the cases of infiltrating lubular carcinoma and invasive lobular carcinomas had a lymph node invasation. There was no cases of involvement in Grade I , and this is result is expected because of its low grade.

lymph node involvement in Grade II IDC (12 case) of all the sample , in Grade IDC (13 case) , & in infiltrative DC was (3 case), that main the involvement of lymph node is incrase with the increase of the grade.

This chapter will discuss the results of breast ultrasound from this study and assess those results with reference to current literature. Consideration as to the types of breast lesions detected with breast ultrasound . Diffuse, rapid spreading malignancies are often known to be subtle in presentation and a skilled eye is necessary to perceive the often subtle changes in breast tissue. These issues, along with the relevant

limitations and variables applicable to this study will be addressed in the following pages.

The data for this study was obtained from two sources; a patient database and a handwritten record of biopsy information documented during the study period. The accuracy of the database information was dependent on those who input the data and contained principal data of the patient and their breast imaging history. Some of the cases in this study had a incomplete dataset and there is some of patients were excluded due to incomplete information.

Types of malignant lesions was full in 5 types these are Grade I invasive ductal carcinomas , Grade II invasive ductal carcinomas , Grade III invasive ductal carcinomas(, infiltrating lubular carcinoma and invasive lobular carcinomas .the most common types was Grade II invasive ductal carcinomas.

These lesions were considered suspicious for malignancy based on the ultrasound appearance and verification with core biopsy was deemed appropriate. Type Grade II IDC was the most common type (23 patients) with percentage of (49%) from all types of breast ca , and then the Grade III IDC (10 patients) , represents(20%) ,this percentage is also rather high comparing with other types.

Malignant lesions were histologically proven in 50 of the patient in this study; the patient's age at the time of biopsy was assessed , ranging from (20 to 80) years. With

Median of (48 years) & (SD of 0.93) that main that the median age of breast ca in sudan is (49 years) and the age is considered a very important risk factor.

Lesion sizes were measured during the ultrasound scan . Measurements for the lesions ranged from (1 – 10) cm with a mean of 4.35,that main the size of tumor of less than 3 cm is the most frequent size (18 lesions), and the size of tumor less than 10 cm is less frequent (5 lesions).

Information was recorded relative to their appearance in the breast tissue as seen in the ultrasound image. These observations were due to recognition of change that had occurred in the breast tissue relative to prior imaging.

lymph node involvement in our study was high in Grade II IDC about 48% of all the Grade II IDC type, and all the cases of Grade III IDC was have lymph node invasive.

thus all the cases of infiltrating lubular carcinoma and invasive lobular carcinomas had a lymph node invasation. There was no cases of involvement in Grade I , and this is result is expected because of its low grade.

lymph node involvement in Grade II IDC (12 case) of all the sample , in Grade IDC (13 case) , & in infiltrative DC was (3 case), that main the involvement of lymph node is incrase with the increase of the grade.

Metastases spread to the other parts : skeletal , bone , lung ,spine, ribs and brain was high rate in grade IV IDC (70 %) from all cases and (30%) from the Grade III IDC, in infiltrating lubular carcinoma(50%) of all the cases have metastases spread, and all the cases of infiltrating lobular carcinoma have metastases involvement. this is result is also expected because of the high grade of the breast ca.

The percentage of high risk patients in this study (49%) was greater than similar research projects : Susan Hamilton MHSc (2010)(44.9%), (Kolb, Lichy & Newhouse, (2002) 40.6%; Rosenberg et al. (2006) 21% & Berg et al. (2008) 21%) and this has contributed to the increased incidence of breast cancer.

Conclusion

Main objective of this study was to evaluate of the role of breast ultrasound in diagnosis of malignant breast tumors and in the evaluation of palpable masses that are mammographically occult, in the evaluation of clinically suspected breast lesions in women younger than 30 years of age, and in the evaluation of many abnormalities seen on mammograms. US now is considered the primary modality for the evaluation of palpable masses in women 30 years of age and older. US is also useful in the guidance of biopsies and therapeutic procedures; research is currently under way to evaluate its role in cancer screening of patient suspected of breast cancer As a safe modality has no hazard.

The data of this study showed that The appearance of specific types of breast carcinoma has been studied. Although appearances vary greatly, some patterns are typical, Mucin-containing carcinomas are often circumscribed but may have irregular margins. These lesions may be either hypoechoic or isoechoic relative to subcutaneous fat. The most frequent type was Grade II : 46% and then Grade III invasive ductal carcinomas :20% ,the most frequent patient age ranging from (20 to 80) years . most frequent lesion size was from (1-2.9) cm :36% , lymph node involvement in Grade II IDC was 38% of all cases and this was the most frequent type involved by lymph node .Metastases spread was high rate in grade IVIDC: 70 %

In summary it is recommended that ultrasonographic screening for breast disease be reserved for special situations, such as for highly anxious patients who request it and for women who have a history of mammographically occult carcinoma and it was used primarily as a relatively inexpensive and effective method of differentiating cystic breast masses, which did not require sampling, from solid breast masses that were usually examined with biopsy; in many cases, the results of these biopsies were benign. However, it is now well established that ultrasonography also provides valuable information about the nature and extent of solid masses and other breast lesions.

The study confirmed that Ultrasonography (US) has been playing an increasingly important role in the evaluation of breast cancer.

Recommendations:

- Recognizing there is a need for regular scan experience to establish and maintain competence in performing breast ultrasound, the establishment of minimum yearly examination numbers is necessary so that diagnostic competence is maintained.

- Establishment of a national protocol whereby the patient with risk factors and/ or dense breast tissue could be clearly identified – for patients attending BSA this could mean additional imaging be performed at specialist imaging centre.

- Enabling the use of ultrasound in all radiology or breast imaging practices through the teaching and mentoring of sonographers .

- Follow-up research could be performed on more numbers patients in this study; gaining additional information on patient risk factors, breast density and whether the given true negative and false negative results for these patients was accurate by reviewing patient data from subsequent imaging.

References:

Adrian Lee; Carlos Arteaga (14 Dec 2009). "32nd Annual CTRC-AACR San Antonio Breast Cancer Symposium". *Sunday Morning Year-End Review*.

American Cancer Society. Breast Cancer Facts & Figures 2011-2012. Available at http://www.cancer.org/Research/CancerFactsFigures/BreastCancerFactsFigures/breast-cancer-facts-and-figures-2011-2012 . Accessed June 10, 2013.

American College of Surgeons (September 2013), "Five Things Physicians and Patients Should Question", *Choosing Wisely: an initiative of the ABIM Foundation* (American College of Surgeons), retrieved 2 January 2013

American Society of Clinical Oncology, "Five Things Physicians and Patients Should Question", *Choosing Wisely: an initiative of the ABIM Foundation* (American Society of Clinical Oncology), retrieved 14 August 2012

Anderson GL, Chlebowski RT, Aragaki AK, Kuller LH, Manson JE, Gass M, et al. Conjugated equine oestrogen and breast cancer incidence and mortality in postmenopausal women with hysterectomy: extended follow-up of the Women's Health Initiative randomised placebo-controlled trial. *Lancet Oncol*. May 2012;13(5):476-86. [Medline]. [Full Text].

Anderson WF, Reiner AS, Matsuno RK, Pfeiffer RM. Shifting breast cancer trends in the United States. *J Clin Oncol*. Sep 1 2007;25(25):3923-9. [Medline].

Anonymous: Prognostic factors in breast cancer: Biology or chronology? **Lancet*340*:**517-*518*, ***1992*** *(editorial)*

answers.com. "Oncology Encyclopedia: Cystosarcoma Phyllodes". Retrieved 2010-08-10.

Ashbeck EL, Rosenberg RD, Stauber PM, Key CR. Benign breast biopsy diagnosis and subsequent risk of breast cancer. *Cancer Epidemiol Biomarkers Prev*. Mar 2007;16(3):467-72. [Medline].

Baer HJ, Colditz GA, Rosner B, Michels KB, Rich-Edwards JW, Hunter DJ, et al. Body fatness during childhood and adolescence and incidence of breast cancer in premenopausal women: a prospective cohort study. *Breast Cancer Res*. 2005;7(3):R314-25. [Medline]. [Full Text].

Begg CB, Haile RW, Borg A, Malone KE, Concannon P, Thomas DC, Langholz B, Bernstein L, Olsen JH, Lynch CF, Anton-Culver H, Capanu M, Liang X, Hummer AJ, Sima C, Bernstein JL (January 2008). "Variation of breast cancer risk among BRCA1/2 carriers". *JAMA* 299 (2): 194–201. doi:10.1001/jama.2007.55-a. PMC 2714486. PMID 18182601.

Beral V. Breast cancer and hormone-replacement therapy in the Million Women Study. *Lancet*. Aug 9 2003;362(9382):419-27. [Medline].

Bonadonna G: Evolving concepts in the systemic adjuvant treatment of breast cancer. **Cancer Res*52*:**2127-*2137,* ***1992***

Bordeleau L, Pritchard K, Goodwin P, Loprinzi C. Therapeutic options for the management of hot flashes in breast cancer survivors: an evidence-based review. *Clin Ther*. Feb 2007;29(2):230-41. [Medline].

"Cancer Survival in England: Patients Diagnosed 2007–2011 and Followed up to 2012". *Office for National Statistics*. 29 October 2013. Retrieved 29 June 2014.

Cancer Research Campaign Working Party: Cancer Research Campaign (King's/Cambridge): Trial for Breast Cancer. **Lancet*2*:**55-*60,* ***1980***

Cardeñosa G. Clinical breast imaging, a patient focused teaching file. Lippincott Williams & Wilkins. (2006) ISBN:0781762677. Read it at Google Books - Find it at Amazon

Carlson RW, Allred DC, Anderson BO, Burstein HJ, Carter WB, Edge SB, Erban JK, Farrar WB, Goldstein LJ, Gradishar WJ, Hayes DF, Hudis CA, Jahanzeb M, Kiel K, Ljung BM, Marcom PK, Mayer IA, McCormick B, Nabell LM, Pierce LJ, Reed EC, Smith ML, Somlo G, Theriault RL, Topham NS, Ward JH, Winer EP, Wolff AC (2009). "Breast cancer. Clinical practice guidelines in oncology".

Journal of the National Comprehensive Cancer Network : JNCCN 7 (2): 122–192. PMID 19200416.

Carmichael A, Sami AS, Dixon JM. Breast cancer risk among the survivors of atomic bomb and patients exposed to therapeutic ionising radiation. *Eur J Surg Oncol*. Jun 2003;29(5):475-9. [Medline].

Cavalieri E, Chakravarti D, Guttenplan J, Hart E, Ingle J, Jankowiak R, Muti P, Rogan E, Russo J, Santen R, Sutter T (August 2006). "Catechol estrogen quinones as initiators of breast and other human cancers: implications for biomarkers of susceptibility and cancer prevention". *Biochimica et Biophysica Acta* **1766** (1): 63–78. doi:10.1016/j.bbcan.2006.03.001. PMID 16675129.

Clark GM, Sledge GW Jr Osborne CK, et al: Survival from first recurrence: Relative importance of prognostic factors in 1,015 breast cancer patients. **J Clin Oncol*5*:**55-*61,* ***1987***

Clark GM, Dressler LG, Owens MA, et al: Prediction of relapse or survival in patients with node negative breast cancer by DNA flow cytometry. **N Engl J Med*320*:**627-*633,* ***1989***

Clemons M, Loijens L, Goss P. Breast cancer risk following irradiation for Hodgkin's disease. *Cancer Treat Rev*. Aug 2000;26(4):291-302. [Medline].

Colditz GA, Rosner BA, Chen WY, Holmes MD, Hankinson SE. Risk factors for breast cancer according to estrogen and progesterone receptor status. *J Natl Cancer Inst*. Feb 4 2004;96(3):218-28. [Medline].

Colditz GA, Rosner B. Cumulative risk of breast cancer to age 70 years according to risk factor status: data from the Nurses' Health Study. *Am J Epidemiol*. Nov 15 2000;152(10):950-64. [Medline].

Cox DR: Regression models and life-tables (with discussion). **J R Stat Soc B*34*:**187-*200,* ***1972***

Cox DR, Oakes D: Analysis of survival data. New York, NY, Chapman and Hall, 1984

Coyle YM. The effect of environment on breast cancer risk. *Breast Cancer Res Treat*. Apr 2004;84(3):273-88. [Medline].

Cuzick J, DeCensi A, Arun B, Brown PH, Castiglione M, Dunn B, et al. Preventive therapy for breast cancer: a consensus statement. *Lancet Oncol*. May 2011;12(5):496-503. [Medline].

Dent DM: Axillary lymphadenectomy for breast cancer. Arch Surg131*:1125-1127,* 1996

Deligeoroglou E, Michailidis E, Creatsas G. Oral contraceptives and reproductive system cancer. *Ann N Y Acad Sci*. Nov 2003;997:199-208. [Medline].

Degnim AC, Visscher DW, Berman HK, Frost MH, Sellers TA, Vierkant RA, et al. Stratification of breast cancer risk in women with atypia: a Mayo cohort study. *J Clin Oncol*. Jul 1 2007;25(19):2671-7. [Medline].

Dupont WD, Page DL, Parl FF, Vnencak-Jones CL, Plummer WD Jr, Rados MS, et al. Long-term risk of breast cancer in women with fibroadenoma. *N Engl J Med*. Jul 7 1994;331(1):10-5. [Medline].

Dunning AM, Healey CS, Pharoah PD, Teare MD, Ponder BA, Easton DF (October 1999). "A systematic review of genetic polymorphisms and breast cancer risk". *Cancer Epidemiology, Biomarkers & Prevention* 8 (10): 843–54. PMID 10548311.

Eliassen AH, Colditz GA, Rosner B, Willett WC, Hankinson SE. Adult weight change and risk of postmenopausal breast cancer. *JAMA*. Jul 12 2006;296(2):193-201. [Medline].

Eliassen AH, Missmer SA, Tworoger SS, Spiegelman D, Barbieri RL, Dowsett M, et al. Endogenous steroid hormone concentrations and risk of breast cancer among premenopausal women. *J Natl Cancer Inst*. Oct 4 2006;98(19):1406-15. [Medline].

Endogenous Hormones and Breast Cancer Collaborative Group. Free estradiol and breast cancer risk in postmenopausal women: comparison of measured and

calculated values. *Cancer Epidemiol Biomarkers Prev*. Dec 2003;12(12):1457-61. [Medline].

Evidence-based assessment of the impact of the WHI on women's health. doi: 10.3109/13697137.2012.655564. Burger HG, MacLennan AH, Huang KE, Castelo-Branco C. *Climacteric*. Jun 2012;15(3):281-7.

Eggers C: Cancer surgery: The value of radical operations for cancer after the lymphatic drainage area has become involved. **Ann Surg*106*:**668-*689*, ***1937***

Farlex (2005). "Immunological Surveilliance". The Free Dictionary. Retrieved 2008-02-10.

Fisher B, Redmond C, Fisher ER, et al: Ten year results of a randomized clinical trial comparing radical mastectomy and total mastectomy with or without irradiation. **N Engl J Med*312*:**674-*681*, ***1985***

Fisher B, Costantino JP, Wickerham DL, Redmond CK, Kavanah M, Cronin WM, et al. Tamoxifen for prevention of breast cancer: report of the National Surgical Adjuvant Breast and Bowel Project P-1 Study. *J Natl Cancer Inst*. Sep 16 1998;90(18):1371-88. [Medline].

Fisher B, Costantino JP, Wickerham DL, Cecchini RS, Cronin WM, Robidoux A, et al. Tamoxifen for the prevention of breast cancer: current status of the National Surgical Adjuvant Breast and Bowel Project P-1 study. *J Natl Cancer Inst*. Nov 16 2005;97(22):1652-62. [Medline]. [Full Text].

Fuemmeler BF, Pendzich MK, Tercyak KP. Weight, dietary behavior, and physical activity in childhood and adolescence: implications for adult cancer risk. *Obes Facts*. 2009;2(3):179-86. [Medline]. [Full Text].

Garbe E, Levesque L, Suissa S. Variability of breast cancer risk in observational studies of hormone replacement therapy: a meta-regression analysis. *Maturitas*. Mar 15 2004;47(3):175-83. [Medline].

Gammon MD, Eng SM, Teitelbaum SL, Britton JA, Kabat GC, Hatch M, et al. Environmental tobacco smoke and breast cancer incidence. *Environ Res*. Oct 2004;96(2):176-85. [Medline].

Glass AG, Lacey JV Jr, Carreon JD, Hoover RN. Breast cancer incidence, 1980-2006: combined roles of menopausal hormone therapy, screening mammography, and estrogen receptor status. *J Natl Cancer Inst*. Aug 1 2007;99(15):1152-61. [Medline].

Gøtzsche PC, Jørgensen KJ (4 Jun 2013). "Screening for breast cancer with mammography.". *The Cochrane database of systematic reviews* **6**: CD001877. doi:10.1002/14651858.CD001877.pub5. PMID 23737396

"Breast Cancer Treatment (PDQ®)". *NCI*. 2014-06-26. Retrieved 29 June 2014.

Grambsch PM, Therneau TM: Proportional hazards tests and diagnostics based on weighted residuals. **Biometrika*81*:**515-*526*, ***1994***

Hankinson SE, Eliassen AH. Circulating sex steroids and breast cancer risk in premenopausal women. *Horm Cancer*. Feb 2010;1(1):2-10. [Medline]. [Full Text].

[Guideline] Recht A, Edge SB, Solin LJ, Robinson DS, Estabrook A, Fine RE, et al. Postmastectomy radiotherapy: clinical practice guidelines of the American Society of Clinical Oncology. *J Clin Oncol*. Mar 1 2001;19(5):1539-69. [Medline].

Guideline Greenlee H, Balneaves L, Carlson M, et al. Clinical Practice Guidelines on the Use of Integrative Therapies as Supportive Care in Patients Treated for Breast Cancer. *J Natl Cancer Inst*. 2014;50:346-358. [Full Text].

Holmberg L, Anderson H. HABITS (hormonal replacement therapy after breast cancer--is it safe?), a randomised comparison: trial stopped. *Lancet*. Feb 7 2004;363(9407):453-5. [Medline].

Henderson BE, Bernstein L. The international variation in breast cancer rates: an epidemiological assessment. *Breast Cancer Res Treat*. May 1991;18 Suppl 1:S11-7. [Medline].

Holmes MD, Liu S, Hankinson SE, Colditz GA, Hunter DJ, Willett WC. Dietary carbohydrates, fiber, and breast cancer risk. *Am J Epidemiol*. Apr 15 2004;159(8):732-9. [Medline].

Holmes MD, Willett WC. Does diet affect breast cancer risk?. *Breast Cancer Res*. 2004;6(4):170-8. [Medline]. [Full Text].

Han D, Nie J, Bonner MR, McCann SE, Muti P, Trevisan M, et al. Lifetime adult weight gain, central adiposity, and the risk of pre- and postmenopausal breast cancer in the Western New York exposures and breast cancer study. *Int J Cancer*. Dec 15 2006;119(12):2931-7. [Medline].

Hill DA, Gilbert E, Dores GM, Gospodarowicz M, van Leeuwen FE, Holowaty E, et al. Breast cancer risk following radiotherapy for Hodgkin lymphoma: modification by other risk factors. *Blood*. Nov 15

Halsted WS: A clinical and histological study of certain adenocarcinoma of the breast and a brief consideration of the supraclavicular operation and of the results of operation for cancer of the breast from 1889 to 1898 at the Johns Hopkins Hospital. **Ann Surg*28***:557-*576*, ***1898***

Hahnel R, Woodings T, Vivian AB: Prognostic value of estrogen receptors in primary breast cancer. **Cancer*44***:671-*675*, ***1979***

Howell A, Harland RNL, Bramwell VHC, et al: Steroid-hormone receptors and survival after first relapse in breast cancer. **Lancet*1***:588-*591*, ***1984***

Howat JMT, Harris M, Swindell R, et al: The effect of oestrogen and progesterone receptors on recurrence and survival in patients with carcinoma of the breast. **Br J Cancer*51***:262-*270*, ***1985***

Hartveit F: Axillary metastasis in breast cancer: When, how, and why? **Semin Surg Oncol*5***:126-*136*, ***1989***

Haslam SZ, Woodward TL (June 2003). "Host microenvironment in breast cancer development: epithelial-cell-stromal-cell interactions and steroid hormone action

in normal and cancerous mammary gland.". *Breast Cancer Res.* **5** (4): 208–15. doi:10.1186/bcr615. PMC 165024. PMID 12817994.

Jemal A, Ward E, Thun MJ. Recent trends in breast cancer incidence rates by age and tumor characteristics among U.S. women. *Breast Cancer Res*. 2007;9(3):R28. [Medline]. [Full Text].

Jardé T, Perrier S, Vasson MP, Caldefie-Chézet F (January 2011). "Molecular mechanisms of leptin and adiponectin in breast cancer". *Eur. J. Cancer* **47** (1): 33–43. doi:10.1016/j.ejca.2010.09.005. PMID 20889333.

Jemal A, Bray F, Center MM, Ferlay J, Ward E, Forman D. Global cancer statistics. *CA Cancer J Clin*. Mar-Apr 2011;61(2):69-90. [Medline].

Jatoi I, Anderson WF, Rosenberg PS. Qualitative age-interactions in breast cancer: a tale of two diseases? doi: 10.1097/COC.0b013e3181844d1c. *Am J Clin Oncol*. Oct 2008;31(5):504-6. [Medline].

Jones, GE, ed. *Bostwick's Plastic and Reconstructive Breast Surgery*. 3rd ed. St. Louis, Mo: Quality Medical Pub; 2010.

Kelsey JL, Bernstein L. Epidemiology and prevention of breast cancer. *Annu Rev Public Health*. 1996;17:47-67. [Medline].

Key T, Appleby P, Barnes I, Reeves G. Endogenous sex hormones and breast cancer in postmenopausal women: reanalysis of nine prospective studies. *J Natl Cancer Inst*. Apr 17 2002;94(8):606-16. [Medline].

Kollias J, Ellis IO, Elston CW, Blamey RW. Clinical and histological predictors of contralateral breast cancer. *Eur J Surg Oncol*. Dec 1999;25(6):584-9. [Medline].

Kaaks R. Nutrition, hormones, and breast cancer: is insulin the missing link?. *Cancer Causes Control*. Nov 1996;7(6):605-25. [Medline].

Kaaks R. Nutrition, insulin, IGF-1 metabolism and cancer risk: a summary of epidemiological evidence. *Novartis Found Symp*. 2004;262:247-60; discussion 260-68. [Medline].

Katalinic A, Rawal R. Decline in breast cancer incidence after decrease in utilisation of hormone replacement therapy. *Breast Cancer Res Treat*. Feb 2008;107(3):427-30. [Medline].

Kouros-Mehr H, Kim JW, Bechis SK, Werb Z (Apr 2008). "GATA-3 and the regulation of the mammary luminal cell fate.". *Current opinion in cell biology* **20** (2): 164–70. doi:10.1016/j.ceb.2008.02.003. PMC 2397451. PMID 18358709.

Kumar, Vinay; Abul Abbas (2010). *Robbins and Cotran Pathologic Basis of Disease*. Philadelphia: Saunders, an imprint of Elsevier inc. p. 1090. ISBN 978-1-4160-3121-5.

Kaplan EL, Meier PL: Nonparametric estimation from incomplete observations. **J Am Stat Assoc*53***:457-*481,* ***1958***

Koscielny S, Le MG Tubiana M: The natural history of breast cancer: The relationship between involvement of axillary lymph nodes and the initiation of distant metastases. **Br J Cancer*59***:775-*782,* ***1989***

Lionetto R, Pronzato P, Bertelli GF, et al: Survival of patients with relapsing breast cancer: Analysis of 302 patients. **Oncology*43***:278-*282,* ***1986***

Loprinzi CL, Michalak JC, Quella SK, O'Fallon JR, Hatfield AK, Nelimark RA, et al. Megestrol acetate for the prevention of hot flashes. *N Engl J Med*. Aug 11 1994;331(6):347-52. [Medline].

Lukanova A, Lundin E, Zeleniuch-Jacquotte A, Muti P, Mure A, Rinaldi S, et al. Body mass index, circulating levels of sex-steroid hormones, IGF-I and IGF-binding protein-3: a cross-sectional study in healthy women. *Eur J Endocrinol*. Feb 2004;150(2):161-71. [Medline].

Levin B, Lech D, Friedenson B (2012). "Evidence that BRCA1- or BRCA2-associated cancers are not inevitable". *Mol. Med.* **18**: 1327–37. doi:10.2119/molmed.2012.00280. PMC 3521784. PMID 22972572.

Lawrence RA and Lawrence RM. Breastfeeding: A Guide for the Medical Profession, 7th Ed. Elsevier Mosby, Maryland Hts, Missouri. 2011: pgs 8-11, 66-

81, 100, 109-114, 117-124, 153-195, 319-335, 365-369, 381-390, 421-425, 553-560, 675, 750-909

Marchbanks PA, McDonald JA, Wilson HG, Folger SG, Mandel MG, Daling JR, et al. Oral contraceptives and the risk of breast cancer. *N Engl J Med*. Jun 27 2002;346(26):2025-32. [Medline].

Laden F, Hunter DJ. Environmental risk factors and female breast cancer. *Annu Rev Public Health*. 1998;19:101-23. [Medline].

Li CI, Daling JR. Changes in breast cancer incidence rates in the United States by histologic subtype and race/ethnicity, 1995 to 2004. *Cancer Epidemiol Biomarkers Prev*. Dec 2007;16(12):2773-80. [Medline].

"Male Breast Cancer Treatment". National Cancer Institute. 2014. Retrieved 2014-06-29.

Merck Manual of Diagnosis and Therapy (February 2003). "Breast Disorders: Breast Cancer". Retrieved 2008-02-05.

Lacroix M (December 2006). "Significance, detection and markers of disseminated breast cancer cells". *Endocrine-related Cancer* **13** (4): 1033–67. doi:10.1677/ERC-06-0001. PMID 17158753.

. Retrieved 2008-02-06.

McCann], [executive publisher, Judith A. Shilling (2008). *Nursing.*. Ambler, PA: Lippincott Williams & Wilkins. p. 99. ISBN 978-1-58255-668-0.

Merck Manual of Diagnosis and Therapy (February 2003). "Breast Disorders: Overview of Breast Disorders". Retrieved 2008-02-05.

Marietta C, Thompson LH, Lamerdin JE, Brooks PJ (May 2009). "Acetaldehyde stimulates FANCD2 monoubiquitination, H2AX phosphorylation, and BRCA1 phosphorylation in human cells in vitro: implications for alcohol-related carcinogenesis". *Mutat. Res.* **664** (1–2): 77–83. doi:10.1016/j.mrfmmm.2009.03.011. PMC 2807731. PMID 19428384.

Merck Manual, Professional Edition, Ch. 253, Breast Cancer.

Mittra I: Axillary lymph node metastasis in breast cancer: Prognostic indicator or lead-time bias? **Eur J Cancer*29*:**300-*302*, ***1993***

Mueller CB: Stage II breast cancer is not simply a late stage I. **Surgery*104*:**631-*638*, ***1988***

Mittra I, MacRae KD: A meta-analysis of reported correlations between prognostic factors in breast cancer: Does axillary lymph node metastasis represent biology or chronology? **Eur J Cancer*27*:**1574-*1583*, ***1991***

Maxwell GP, Gabriel A. The evolution of breast implants. *Clin Plast Surg*. Jan 2009;36(1):1-13, v. [Medline].

Maxwell GP, Gabriel A. Breast Reconstruction. In: Aston SJ, Steinbrech DS, Walden JL. *Aesthetic Plastic Surgery*. Philadelphia, Pa: Elsevier; 2009:chap 57.

Mathes SJ, Nahai F. *Reconstructive Surgery: Principles, Anatomy, and Technique*. New York, NY: Churchill Livingston; 1997.

Nelson, HD; Tyne, K; Naik, A; Bougatsos, C; Chan, B; Nygren, P; Humphrey, L (Nov 2009). *Screening for Breast Cancer: Systematic Evidence Review Update for the US Preventive Services Task Force [Internet]*. PMID 20722173

National Cancer Institute (27 June, 2005). "Paget's Disease of the Nipple: Questions and Answers". Retrieved 2008-02-06.

National Cancer Institute (1 September, 2004). "Metastatic Cancer: Questions and Answers"

Newton M and Newton NR. The let-down reflex in human lactation. J Pediatrics. 1948: 33;698-704

Neville MC. Anatomy and Physiology of Lactation. Pediatric Clinics of North America. 2001: 48(1) 13-35.

Parmigiani G, Chen S, Iversen ES Jr, Friebel TM, Finkelstein DM, Anton-Culver H, et al. Validity of models for predicting BRCA1 and BRCA2 mutations. *Ann Intern Med*. Oct 2 2007;147(7):441-50. [Medline]. [Full Text].

Pal T, Permuth-Wey J, Betts JA, Krischer JP, Fiorica J, Arango H, et al. BRCA1 and BRCA2 mutations account for a large proportion of ovarian carcinoma cases. *Cancer*. Dec 15 2005;104(12):2807-16. [Medline].

Pike MC, Pearce CL, Peters R, Cozen W, Wan P, Wu AH. Hormonal factors and the risk of invasive ovarian cancer: a population-based case-control study. *Fertil Steril*. Jul 2004;82(1):186-95. [Medline].

Page DL, Jensen RA. Evaluation and management of high risk and premalignant lesions of the breast. *World J Surg*. Jan-Feb 1994;18(1):32-8. [Medline].

Page DL, Schuyler PA, Dupont WD, Jensen RA, Plummer WD Jr, Simpson JF. Atypical lobular hyperplasia as a unilateral predictor of breast cancer risk: a retrospective cohort study. *Lancet*. Jan 11 2003;361(9352):125-9. [Medline].

Page DL. Breast lesions, pathology and cancer risk. *Breast J*. Jan-Feb 2004;10 Suppl 1:S3-4. [Medline].

Patel KJ, Yu VP, Lee H, Corcoran A, Thistlethwaite FC, Evans MJ, Colledge WH, Friedman LS, Ponder BA, Venkitaraman AR (February 1998). "Involvement of Brca2 in DNA repair". *Mol. Cell* **1** (3): 347–57. doi:10.1016/S1097-2765(00)80035-0. PMID 9660919.

Paredes ES. Atlas of mammography. Lippincott Williams & Wilkins. (2007) ISBN:0781764335. Read it at Google Books - Find it at Amazon

Pater JL, Mores D, Loeb M: Survival after recurrence of breast cancer. **Can Med Assoc J*124:***1591-*1595,* ***1981***

Pansky B. *Review of Gross Anatomy*. 6th ed. New York, NY: McGraw-Hill; 1996.

Peaker M, Wilde CJ and Knight CH. Local control of the mammary gland. Biochem. Soc. Symp., 1998: 63: 71-79

Reeves GK, Beral V, Green J, Gathani T, Bull D. Hormonal therapy for menopause and breast-cancer risk by histological type: a cohort study and meta-analysis. *Lancet Oncol*. Nov 2006;7(11):910-8. [Medline].

Ruder EH, Dorgan JF, Kranz S, Kris-Etherton PM, Hartman TJ. Examining breast cancer growth and lifestyle risk factors: early life, childhood, and adolescence. *Clin Breast Cancer*. Aug 2008;8(4):334-42. [Medline]. [Full Text].

Ravdin PM, Cronin KA, Howlader N, Berg CD, Chlebowski RT, Feuer EJ, et al. The decrease in breast-cancer incidence in 2003 in the United States. *N Engl J Med*. Apr 19 2007;356(16):1670-4. [Medline].

Romond EH, Perez EA, Bryant J, Suman VJ, Geyer CE, Davidson NE, Tan-Chiu E, Martino S, Paik S, Kaufman PA, Swain SM, Pisansky TM, Fehrenbacher L, Kutteh LA, Vogel VG, Visscher DW, Yothers G, Jenkins RB, Brown AM, Dakhil SR, Mamounas EP, Lingle WL, Klein PM, Ingle JN, Wolmark N (October 2005). "Trastuzumab plus adjuvant chemotherapy for operable HER2-positive breast cancer". *N. Engl. J. Med.* **353** (16): 1673–84. doi:10.1056/NEJMoa052122. PMID 16236738.

Rahbar G, Sie AC, Hansen GC et-al. Benign versus malignant solid breast masses: US differentiation. Radiology. 1999;213 (3): 889-94. Radiology (full text) - Pubmed citation

Rees TD, LaTrenta GS. *Aesthetic Plastic Surgery*. 2nd ed. Philadelphia, Pa: WB Saunders; 1994.

Siegel R, Ma J, Zou Z, Jemal A. Cancer statistics, 2014. *CA Cancer J Clin*. Jan-Feb 2014;64(1):9-29. [Medline].

Surveillance Epidemiology and End Results (SEER). SEER Stat Fact Sheets: Breast. Available at http://seer.cancer.gov/statfacts/html/breast.html#incidence-mortality. Accessed May 23, 2013.

Santen RJ, Boyd NF, Chlebowski RT, Cummings S, Cuzick J, Dowsett M, et al. Critical assessment of new risk factors for breast cancer: considerations for development of an improved risk prediction model. *Endocr Relat Cancer*. Jun 2007;14(2):169-87. [Medline].

Schairer C, Lubin J, Troisi R, Sturgeon S, Brinton L, Hoover R. Menopausal estrogen and estrogen-progestin replacement therapy and breast cancer risk. *JAMA*. Jan 26 2000;283(4):485-91. [Medline].

Speroff L. The Million Women Study and breast cancer. *Maturitas*. Sep 25 2003;46(1):1-6. [Medline].

Stoll BA. Breast cancer and the western diet: role of fatty acids and antioxidant vitamins. *Eur J Cancer*. Nov 1998;34(12):1852-6. [Medline].

Smith-Bindman R. Environmental causes of breast cancer and radiation from medical imaging: findings from the Institute of Medicine report. *Arch Intern Med*. Jul 9 2012;172(13):1023-7. [Medline].

Saunders, Christobel; Jassal, Sunil (2009). *Breast cancer* (1. ed. ed.). Oxford: Oxford University Press. p. Chapter 13. ISBN 978-0-19-955869-8.

Screening for Breast Cancer. *US Preventative Services Task Force*. December 2009. Retrieved 24 December 2012.

"SEER Stat Fact Sheets: Breast Cancer". *NCI*. Retrieved 18 June 2014.

S, Srinakarin J, Hirunpat S, Woodtichartpreecha P, Boonlikit S, Teerawattananon Y, Thakkinstian A (2013). "Risk factors of breast cancer: a systematic review and meta-analysis". *Asian Pacific Journal of Public Health* **25** (5): 368–387. doi:10.1177/1010539513488795. PMID 23709491.

Saslow D, Hannan J, Osuch J, Alciati MH, Baines C, Barton M, Bobo JK, Coleman C, Dolan M, Gaumer G, Kopans D, Kutner S, Lane DS, Lawson H, Meissner H, Moorman C, Pennypacker H, Pierce P, Sciandra E, Smith R, Coates R (2004). "Clinical breast examination: practical recommendations for optimizing performance and reporting". *CA: a cancer journal for clinicians* **54** (6): 327–344. doi:10.3322/canjclin.54.6.327. PMID 15537576.

Sotiriou C, Pusztai L (February 2009). "Gene-expression signatures in breast cancer". *N. Engl. J. Med.* **360** (8): 790–800. doi:10.1056/NEJMra0801289. PMID 19228622.

Stavros AT, Thickman D, Rapp CL et-al. Solid breast nodules: use of sonography to distinguish between benign and malignant lesions. Radiology. 1995;196 (1): 123-34. Radiology (abstract) - Pubmed citation

Shek LLM, Godolphin W, Spinelli JJ: Oestrogen receptors, nodes and stage as predictors of post-recurrence survival in 457 breast cancer patients. **Br J Cancer*56*:**825-*829*, ***1987***

The Cancer Genome Atlas Network. Comprehensive molecular portraits of human breast tumours. *Nature*. Oct 4 2012;490(7418):61-70. [Medline]. [Full Text].

The ruvathu JA, Jaruga P, Nath RG, Dizdaroglu M, Brooks PJ (2005). "Polyamines stimulate the formation of mutagenic 1,N2-propanodeoxyguanosine adducts from acetaldehyde". *Nucleic Acids Res.* **33** (11): 3513–20. doi:10.1093/nar/gki661. PMC 1156964. PMID 15972793.

Therneau TM, Grambsch PM, Fleming TR: Martingale-based residuals for survival models. **Biometrika*77*:**147-*160*, ***1990***

Tubiana-Hulin M, Hacene K, Martin PM, et al: Prognostic factor clustering in breast cancer: Biology or chronology? Eur J Cancer 31A:283-284, 1995

Tabar L, Gad A, Holmberg LH, et al: Reduction in mortality from breast cancer after mass screening with mammography. **Lancet*1*:**829-*832*, ***1985***

Thorne CH, Beasley RW. *Grabb and Smith's Plastic Surgery*. 6th ed. Philadelphia, Pa: Wolters Kluwer Health/Lippincott Williams and Wilkins; 2007.

Vogel VG, Costantino JP, Wickerham DL, Cronin WM, Cecchini RS, Atkins JN, et al. Effects of tamoxifen vs raloxifene on the risk of developing invasive breast cancer and other disease outcomes: the NSABP Study of Tamoxifen and Raloxifene (STAR) P-2 trial. *JAMA*. Jun 21 2006;295(23):2727-41. [Medline].

Watson M (2008). "Assessment of suspected cancer". *InnoAiT* **1** (2): 94–107. doi:10.1093/innovait/inn001.

Wiseman BS, Werb Z (May 2002). "Stromal effects on mammary gland development and breast cancer". *Science* **296** (5570): 1046–9. doi:10.1126/science.1067431. PMC 2788989. PMID 12004111.

World Cancer Report 2014. World Health Organization. 2014. pp. Chapter 5.2. ISBN 92-832-0429-8.

"World Cancer Report". International Agency for Research on Cancer. 2008. Retrieved 2011-02-26.

World Cancer Report 2014. World Health Organization. 2014. pp. Chapter 1.1. ISBN 92-832-0429-8.

Wooster R, Weber BL (June 2003). "Breast and ovarian cancer". *N. Engl. J. Med.* **348** (23): 2339–47. doi:10.1056/NEJMra012284. PMID 12788999.

Wood WC: Progress from clinical trials on breast cancer. **Cancer*74:***2606-*2609,* ***1994*** *(suppl 9)*

Williams MR, Todd JH, Nicholson RI, et al: Survival patterns in hormone treated advanced breast cancer. **Br J Surg*73:***752-*755,* ***1986***

Wilde CJ, Addey CVP, Bryson JM et. al. Autocrine regulation of milk secretion. Biochem. Soc. Symp., 1998: 63: 81-90

Yu YH, Liang C, Yuan XZ (2010). "Diagnostic value of vacuum-assisted breast biopsy for breast carcinoma: a meta-analysis and systematic review.". *Breast cancer research and treatment* **120** (2): 469–79. doi:10.1007/s10549-010-0750-1. PMID 20130983.

Zonderland HM, Coerkamp EG, Hermans J. Van de Vijver MJ, Van Voorthuisen AE. Diagnosis of breast cancer: contribution of US as an adjunct to mammography Radiology. 1999; 213:413-22.

http://twitter.com/DrHenryK

Data work sheet

Sudan university of science & technology

Study of breast malignant lesion using ultrasound

- **Personal data:**

1. No of questionnaire: ……..
2. Name of the patients:…….
3. Age:……
4. Material status: Married …….. , Not Married : …….……
   widowed ……. discarded ……..…
5. Gender: Male ……. Female: ……..…. .
6. No of children : ……..……..
7. Occupation:……..
8. Level of education illiterate :

Primary …… , secondary …… university:…….. postgraduate:…….

9. No of years since diagnosis : ……....
10. No of years since started breast ca : ……
11. History of patient breast feeding : …….….
12. Family history of breast ca: …….

- **Histological finding:**

Type of breast ca	**No of cases**	**Patient age**	**Lesion sizes**	**lymph node**	**Metastases involvement**
DCIS					
Grade I **IDC**					

Grade II **IDC**					
Grade III **IDC**					
Grade IV **IDC**					
Infiltrating,lobular carcinoma.					
Invasive,lubular carcinoma.					

- **Sonographic finding :**

  a. *sonographic spiculation*
  b. *deeper (taller) than wide*
  c. *microlobulations*
  d. *thick hyperechoic halo:*
  e. *angular margins:*
  f. *markedly hypoechoic nodule:*
  g. *sonographic shadowing:*
  h. *duct extension:*

Appendix: US Images:

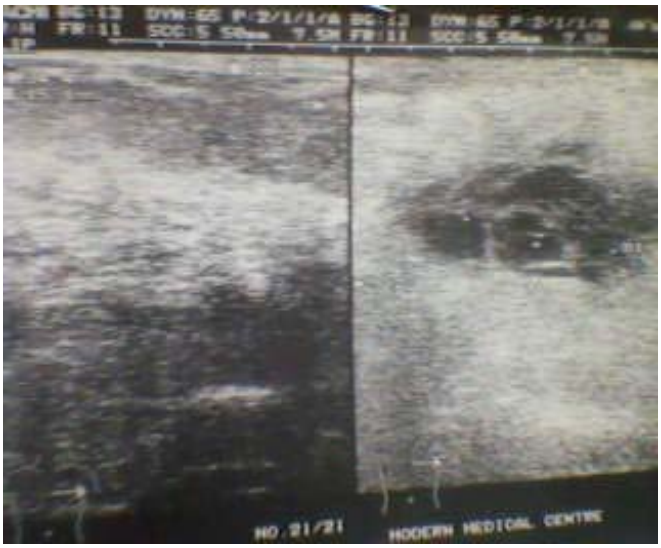

Irregular hypoechoic mass with internal calssification seen.

Infiltrative Ductal Carcinoma with grade III**, irregular margins & hypoechoic mass.**

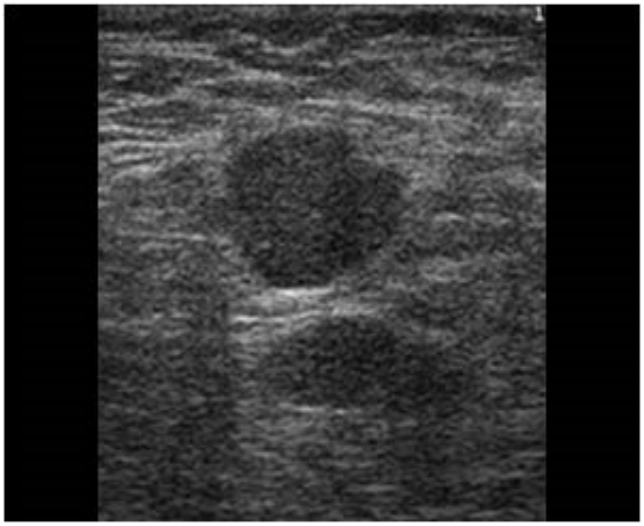

Axillary lymph node metastasis of a breast carcinoma with rounded hypoechoic lymph nodes

Axillary lymph node metastasis of a breast ca with hypoechoic lymph nodes

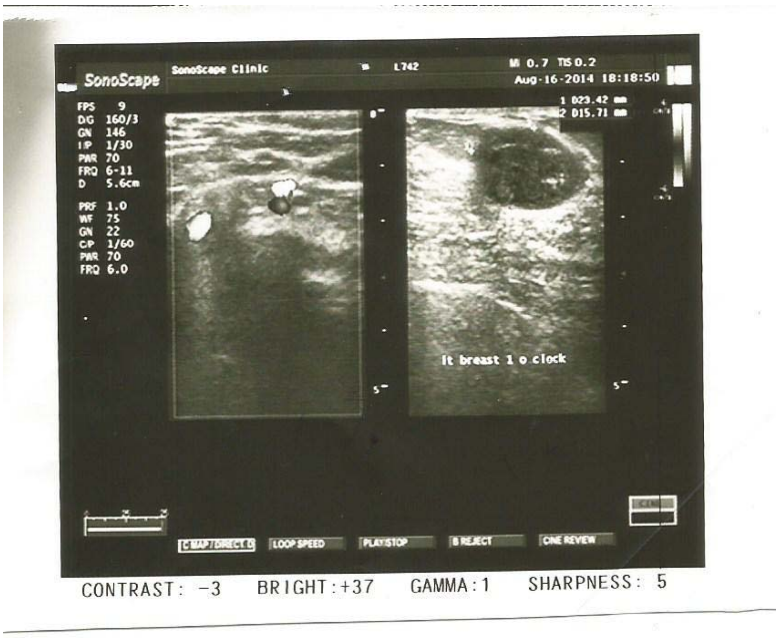

Well defined hypoechoic mass consistent with fibroadnoma

Recurrent malignant mass after mastectomy.

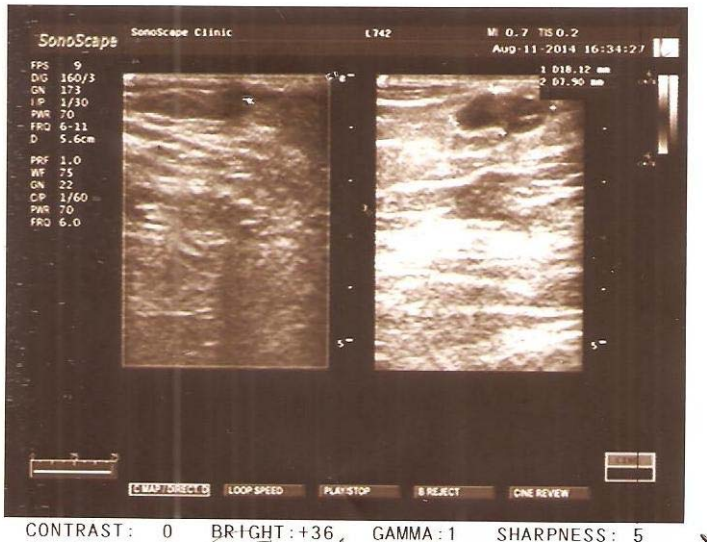

Irregular hypoechoic mass with micro calssification seen.

Malignant breast mass with Irregular margins

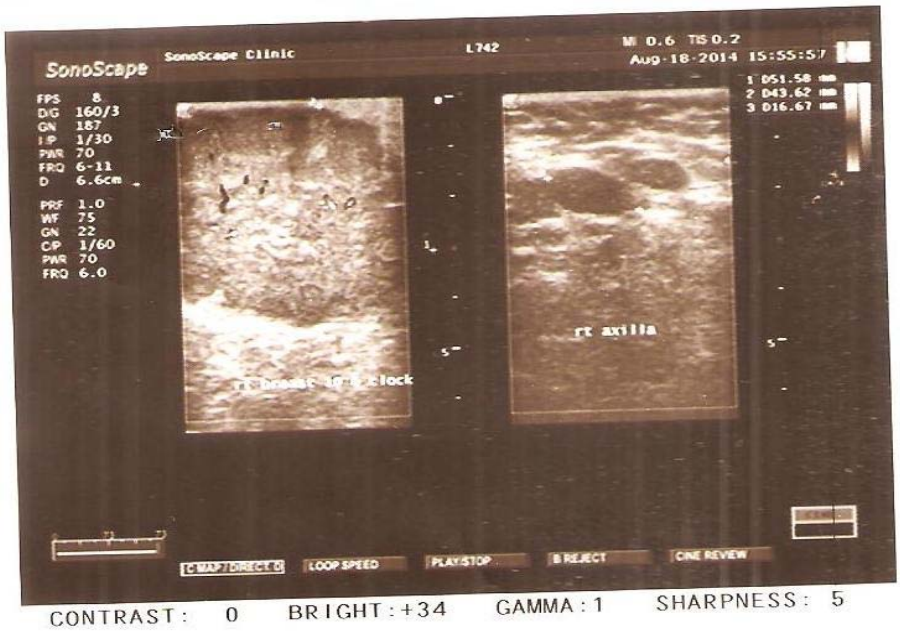

Hypoechoic mass(5.1*4.4cm)in the upper outer quadrant with micro calcification & internal vascularity.

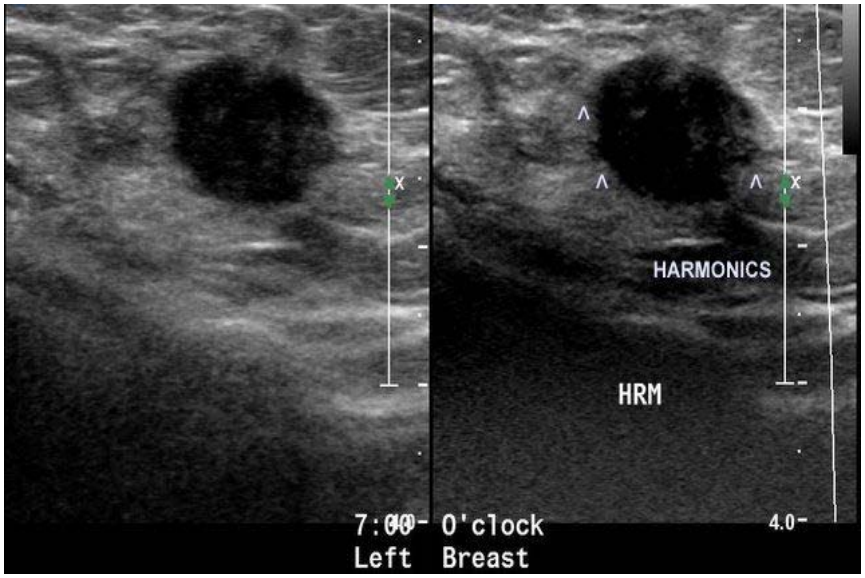

malignant mass of the breast