

1.-1 Introduction:

The words "benign" and "malignant" are important words to understand, especially when discussing potentially cancerous tumors. As the names imply, a malignant tumor is particularly worrisome, requiring immediate attention, whereas a benign tumor is relatively less dangerous. However, simply because a tumor has been determined benign does not mean that it can be ignored. The word "benign" refers to a mass of cells that is limited in growth and is not worsening to a malignant state. Generally, this term is used to describe a defined, encapsulated, non-cancerous tumor. Benign tumors are abnormally growing yet ultimately harmless clumps of cells. Unlike malignant tumors, a benign mass does not spread aggressively to other parts of the body nor does it permeate bodily tissues.(13)

Although abnormal cell masses classified as benign appear in an array of diverse forms under a microscope or scan, their uniting factor is that all benign tumors are non-cancerous. Like their malignant counterparts, benign tumors may be found throughout the body, from the uterus or prostate to the skin. In fact, moles are one of the most common examples of benign tumors. Yet unlike serious or deadly tumors, benign tumors grow relatively slowly. (13)

Malignant refers to large number of diseases characterized by the development of abnormal cells that divide uncontrollably and have the ability to infiltrate and destroy normal body tissue. Cancer also has the ability to spread throughout the body. (13)

sonographic examination of the breast is a well Established adjunct to mammography, especially in patients with dense breasts or those with palpable breast lesions. With the demonstration of specific sonographic features, the accuracy of diagnosing palpable breast lesions is as high as 95.2% although sonography is an excellent tool for detecting and evaluating breast lesions, it is still not widely accepted as a screening modality due to its poor detection rate of micro calcifications and lower accuracy for non-palpable carcinomas. (13)

Benefits of ultrasound in breast scanning are to determine the nature of a breast abnormality either solid or cystic, also used as supplemental breast cancer screening method and supplement mammography by detecting small breast cancers that may not be visible with mammography. This usually considered when the breast tissue is dense. Today ultrasound is being investigated for use as screening tool for women who have dense breast, have silicone breast implants, have pregnancy and those who have strong family history of breast cancer or a prior atypical biopsy result. For standard diagnostic ultrasound there are no known harmful effects on humans. Interpretation of a breast ultrasound examination may lead to additional procedures such as follow-up ultrasound and/or aspiration or biopsy. Absent of predictive sonographic criteria for determine either breasts nodules are benign rather than malignant and vice versa. This absence of course leads to rush in use of unnecessary breast biopsies running after differentiation were the main problems for which this research was designed to solve. (13)

Rahbar, et al in a study about benign versus malignant solid breast masses ultrasound differentiation, conclude certain ultrasonic features can help differentiate benign from malignant masses where ultrasonic features most predictive of a benign tissue diagnosis was circumscribed margins and the features most predictive of a malignant tissue diagnosis was speculated or microlobulated margins, irregular shape and ill-defined margins. Rahbar, et al results were supported by Chen, et al in an analysis of sonographic features for the differentiation of benign and malignant breast tumors of different sizes and conclude that tumor margin is the most important sonographic feature in evaluating breast lesions in any size group. (13)

Stavros, et al in a study about solid breast nodules use of sonography to distinguish between benign and malignant lesions conclude sonography can be used to accurately classify some solid lesions as benign, allowing imaging follow-up rather than biopsy. Such findings confirm and support our objectives which are analyzing the value of various sonographic features in differentiating benign from malignant breast tumors, so as to improve the diagnostic accuracy and replace unnecessary biopsies. (13)

1-2 Problem of study:

How to differentiate between benign and malignant in breast masses.

1-3 Objectives:

1-3-1 the general objective:

To differentiate between benign and malignant mass using ultrasound.

1-3-2 Specific objectives:

- To describe sonographic texture of benign masses.
- To describe sonographic texture of malignant.
- To evaluate efficiency of using ultrasound in young, pregnant and lactating women.

1-4 Sampling:

20 female came to ultrasound department complain of breast pain, mass and nipple discharge.

1-5 Material:

Equipment (U/S machine).

1-6 Duration and place of the study:

This study will be conducted in Khartoum state in 2014.

1-7 Data Analysis:

Depend on the frequencies and the percentages of characteristic sonographic features used to differentiate between benign and malignant condition among the scanned sample.

2-1 Anatomy of the breast:

Women and men both have breasts, but women have more breast tissue than men. Each breast lies over a muscle of the chest called the pectoral muscle. The female breast covers a fairly large area. It extends from just below the collarbone (clavicle), to the armpit (axilla) and across to the breastbone (sternum). (1)

2-1-1 Structure:

The breast is a mass of glandular, fatty and connective tissue. The breast is made up of:

- lobules – glands that produce milk.
- ducts – tubes that carry milk from the lobules to the nipple.
- fatty and connective tissue – surrounds and protects the ducts and lobules and gives shape to the breast.
- areola – the pink or brown, circular area around the nipple that contains small sweat glands, which release (secrete) moisture as a lubricant during breast-feeding.
- nipple – the area at the centre of the areola where the milk comes out. (1)

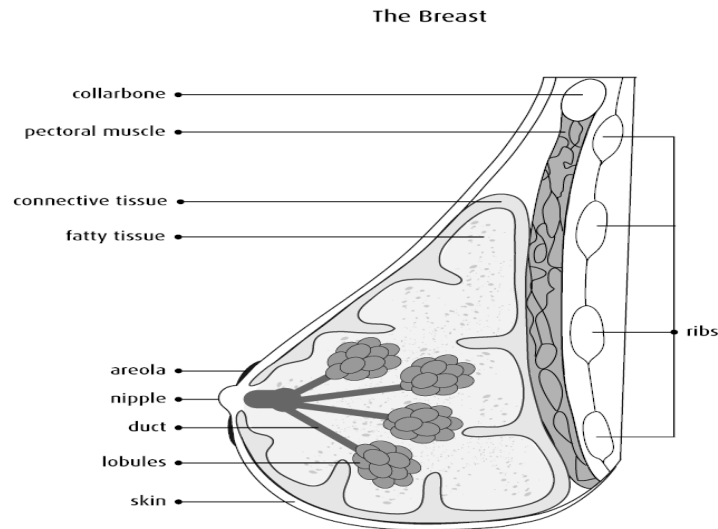


Figure 2-1 breast anatomy

Ligaments support the breast. They run from the skin through the breast and attach to muscles on the chest. (1)

There are several major nerves in the breast area, including nerves in the chest and arm. There are also sensory nerves in the skin of the chest and axilla. (1)

2-1-2 Development and types of the breast tissues:

Breast tissue changes at different times during a woman's life. It changes during puberty, during the menstrual cycle, during pregnancy and after menopause.(2)

Female breasts do not begin growing until puberty (around 10–12 years of age). At this time, the breasts respond to hormonal changes (mostly increased estrogen and progesterone) in the body and begin to develop. During puberty, the breast ducts and milk glands grow. The breast skin stretches as the breasts grow, creating a rounded appearance. Young women tend to have denser breasts (more glandular tissue) than older women. (2)

In older women, much of the glandular and ductal tissue is replaced with fatty tissue and breasts become less dense. Ligaments also lose their elasticity when women age, causing the breasts to sag. (2)

The size and shape of women's breasts vary considerably. Some women have a large amount of breast tissue and have larger breasts. Others have a smaller amount of tissue with little breast fat. A woman's breasts are rarely the same size. Often one breast is slightly larger or smaller, higher or lower or shaped differently than the other. (2)

The breast can be classified into three broad categories depending on the relative amount of fibrous tissues versus fatty tissue. (2)

These three categories are described as follows :

– fibro glandular breast:

The younger breast normally is quite dense, because it contains relatively little fatty tissue. The common age grouping for the fibro glandular category is postpuberty to about age 30. (2)

Pregnant or lactating females of any age also may be placed in this grouping because they possess a very dense type of breast during this time. (2)

– fibro fatty breast:

As the female ages and changes in breast tissue continue to occur, the low amount of fatty tissue gradually shifts to a more equal distribution of fat and fibro glandular tissue. Therefore in the 30_50 years old group, the breast is not quite dense as in younger group. (2)

– Fatty breast:

Which generally occur after menopause commonly in those 15 years old and older, after women's ability to reproduce has reached an end most glandular breast tissue

with converted to fatty tissue in a process called involution. The breast of children and males can be also classified in this category. (2)

2-1-3 The blood supply of the breast :

The mammary gland is highly vascular and is supplied by branches of the internal thoracic, axillary, and intercostals arteries. Deep veins drain into the correspondingly named veins. Connection between the intercostals veins and vertebral plexus allow metastasis to bones and to nervous system. (2)

2-1-4 The lymphatic system of the breast:

The breast has many blood vessels and lymph vessels. Lymph vessels are thin tubes similar to blood vessels. They collect and move lymph fluid away from the breast into small bean-shaped masses of lymphatic tissue, called lymph nodes, in the area around the breast. The lymph vessels and lymph nodes are part of the lymphatic system, which helps fight infections. (2)

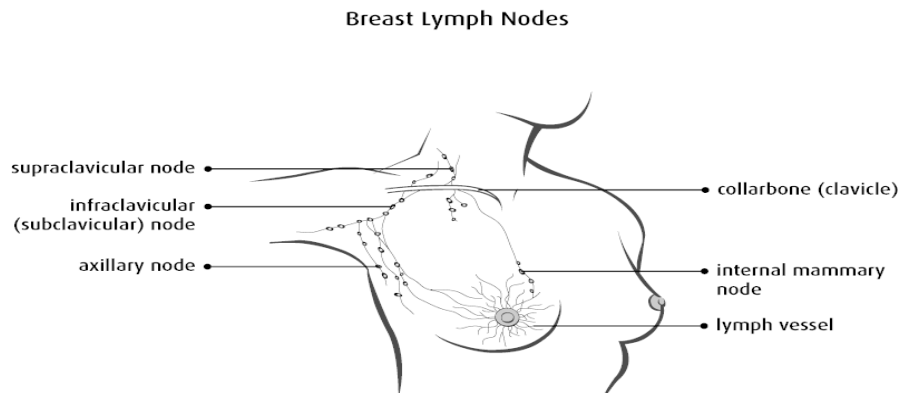


Figure 2-2 breast lymph nodes

- supraclavicular nodes – above the collarbone
- infraclavicular (or subclavicular) nodes – below the collarbone
- axillary nodes – in the armpit (axilla)
- internal mammary nodes – inside the chest around the breastbone (sternum)

When breast cancer spreads, it usually goes to level I lymph nodes first, to level II next and then to level III. (2)

2-1-5 The nerve supply of the breast:

The microscopic character of the innervations of the skin over the breast and usually large number of by multi-branched free- fiber endings in the dermis of the nipple, and ruffian-like and Krause end bulbs in the dermis of the areola and peripheral breast skin. There suggest that this special innervations is associated with the process of erection of the nipple and milk flow, mediated through reflex stimulation of the pituitary. As follows; the skin over the upper part of the breast: third and fourth branches of the cervical plexus. The skin over the lower part intercostals nerve .the thoracodorsal or middle sub scapular nerves. The long thoracic nerve. (2)

2-2 Physiology of the breast:

Breasts are an integral part of the reproductive system, and under the control of the same neuroendocrine system. This is to correlate the breast physiology and its aberrations with other hormonal phenomena. (2)

The breast's main function is to produce, store and release milk to feed a baby. Milk is produced in lobules throughout the breast when they are stimulated by hormones in a woman's body after giving birth. (2)

The ducts carry the milk to the nipple. Milk passes from the nipple to baby during breast feeding. (2)

Estrogen is the main female hormone. It influences female sexual characteristics, such as breast development, and it is necessary for reproduction. Most of the estrogen in a woman's body is made by the ovaries, though a small amount is made by the adrenal glands(2).

Progesterone is the other female sex hormone made in the ovaries. Its role is to prepare the uterus (womb) for pregnancy and the breasts for producing milk for breast-feeding (lactation). (2)

The breast tissues are exposed to monthly cycles of estrogen and progesterone throughout a woman's childbearing years. (2)

In the first part of the menstrual cycle, estrogen stimulates the growth of the milk ducts. (2)

Progesterone takes over in the second part of a woman's menstrual cycle, stimulating the lobules. (2)

After menopause, the monthly cycle of estrogen and progesterone ends. However, the adrenal glands continue to produce estrogen so that a woman keeps her sexual characteristics. (2)

Breast tissue is a complex network of lobules (small round sacs that produce milk) and ducts (canals that carry milk from the lobules to the nipple openings during breastfeeding) in a pattern that looks like bunches of grapes. These “bunches” are called lobes. (2)

2-3 Breast Pathology :

When your breast was biopsied, the samples taken were studied under the microscope by a specialized doctor with many years of training called a pathologist. The pathologist sends your doctor a report that gives a diagnosis for each sample taken. Information in this report will be used to help manage your care. The questions and answers that follow are meant to help you understand medical language you might find in the pathology report from a biopsy, such as a needle biopsy or an excision biopsy. (3)

2-3-1 Benign Breast Conditions:

Benign changes can include adenosis, sclerosing adenosis, apocrine metaplasia, cysts, columnar cell change, columnar cell hyperplasia, collagenous spherulosis, duct ectasia, columnar cell change with prominent apical snouts and secretions (CAPSS), papillomatosis, or fibrocystic changes. (3)

2-3-1-1 Atypical Hyperplasia:

Hyperplasia is a term used when there is an abnormal pattern of growth of cells within the ducts and/or lobules of the breast that is not cancerous. Some growths look more abnormal, and may be called atypical hyperplasia.(3)

2-3-1-2 Mastitis:

Is the inflammation of breast tissue. streptococci is the common etiology.

Mastitis can be classified as milk stasis, non-infectious or infectious inflammation and abscess. It is impossible to correlate this classification with clinical symptoms, in particular milk stasis, non-infectious and infectious inflammation can be distinguished only by leukocyte count and bacteria culturing. Symptoms like fever, intensity of pain, erythema or rapid onset of symptoms cannot be used to distinguish these.(3)

Early stages of mastitis can present with local pain, redness, swelling, and warmth, later stages also present with systemic symptoms like fever and flu like symptoms and in rare cases an abscess can develop. However it is pretty common that symptoms develop very quickly without any warning. (3)

2-3-1-3 A breast cyst:

Is a fluid-filled sac within the breast. One breast can have one or more breast cysts. They're often described as round or oval lumps with distinct edges. In texture, a breast cyst usually feels like a soft grape or a water-filled balloon, but sometimes a breast cyst feels firm. (3)

Breast cysts can be painful and may be worrisome but are generally benign. They are most common in pre-menopausal women in their 30s or 40s. They usually disappear after menopause, but may persist or reappear when using hormone therapy. Breast cysts can be part of fibrocystic disease. The pain and swelling is usually worse in the second half of the menstrual cycle. (3)

2-3-1-4 A galactocele:

Is a retention cyst containing milk or a milky substance that is usually located in the mammary glands. It is caused by a protein plug that blocks off the outlet. It is seen in lactating women on cessation of lactation. Once lactation has ended the cyst should resolve on its own

without intervention. A galactocele does not cause infection as the milk within is sterile and has no outlet for which to become contaminated. (3)

2-3-1-5 Breast Abscess:

Is a painful infection brought on by bacteria. The type of bacteria that most frequently produces breast infection is staphylococcus aureus. An abscess is a hollow space in the breast that becomes filled with pus from the infected milk ducts. An abscess can develop in the presence of severe mastitis. An abscess is generally considered a benign lesion. (4)

2-3-2 Breast Cancer :

Carcinoma is a term used to describe a cancer that begins in the lining layer (epithelial cells) of organs like the breast. Nearly all breast cancers are carcinomas. Most are the type of carcinoma that starts in glandular tissue called adenocarcinoma. (5)

Cancer Begins when cells in a part of the body start to grow out of control. All types of cancer, irrespective of their origin, occur due to this disturbed growth of cells that leads to formation of tumors' and lesions. In addition, the cancer cells possess some rogue like properties:

They have longer life spans and instead of dying continue to grow and form new, abnormal cells. (6)

Cancer cells can also invade other tissues. This is something that normal cells cannot do. This property is called metastasis. (6)

Cancer cells grow into tumors that are supplied by a new network of blood vessels. This is called angiogenesis and is unique in maintaining the blood supply and supply of nutrients to the cancer cells. (6)

A normal cell can become a cancer cell if it undergoes damage to the DNA. Since it is the DNA that regulates the cells' cycle of growth and death and any changes or damage to DNA affects the cell. (6)

For most cells if the DNA is damaged the cell either repairs the damage or the cell dies. In cancer cells, the damaged DNA is not repaired and the damage is propagated to newer abnormal cells that are born of the defective cell. (6)

Damaged DNA by mutation can also be inherited from parents or relatives. DNA damage can also occur due to exposure to toxins like cigarette smoking, alcohol etc. (6)

Breast cancer is a malignant tumor that starts in the cells of the breast. Like other cancers, there are several factors that can raise the risk of getting breast cancer. Damage to the DNA and genetic mutations can lead to breast cancer have been experimentally linked to estrogen exposure. Some individuals inherit defects in the DNA and genes like the BRCA1, BRCA2 and P53 among others. Those with a family history of ovarian or breast cancer thus are at an increased risk of breast cancer. (6)

The immune system normally seeks out cancer cells and cells with damaged DNA and destroys them. Breast cancer may be a result of failure of such an effective immune defense and surveillance. (6)

These are several signaling systems of growth factors and other mediators that interact between stromal cells and epithelial cells. Disrupting these may lead to breast cancer as well. (6)

Benign breast diseases – Around 80 percent of suspicious masses found on mammograms or breast exams are benign, meaning they are not cancerous and pose no health risk. If our pathologists examine your slides and find no evidence of cancer, the surgeon will determine if the benign tumor, usually a fibro adenoma, needs to be removed. If they are large, increasing in size or causing pain, the surgeon will remove them. (6)

Malignant tumors – Malignant tumors are cancerous tumors and need to be treated as such. Our pathologists will carefully evaluate all biopsies and slides to give the treating surgical, medical and radiation oncologists information about the size, type and prognostic factors of the tumor. Armed with these precise facts, our team can create an individualized treatment plan that targets the exact nature of your breast cancer. (6)

Breast cancer grading and specific differentiation must involve a series of investigations and not be based on ultrasound alone. (6)

2-3-2-1 Carcinoma in-situ:

Indicates that the cancer is still contained entirely with the tissue of origin and not penetrated tissue boundaries (a histological diagnosis). (6)

- Ductal Carcinoma In-Situ (DCIS) - The Cancer originated within breast milk ductal epithelium and is still contained by the ductal walls.
- Lobular Carcinoma In-Situ (LCIS)- As the name suggests, the cancer has crossed multiple tissue boundaries, and is no longer contained in the tissue of origin.
- Infiltrating Ductal Carcinoma (IDC) .
- Infiltrating Lobular Carcinoma (ILC) .

There are several grades using the TNM grading. (6)

2-3-2-2 Ductal Carcinoma In Situ:

This term is used for the earliest stage of breast cancer, when it is confined to the layer of cells where it began. (6)

2-3-2-3 Lobular Carcinoma:

Lobular carcinoma in situ (LCIS) is a type of in situ carcinoma of the breast, but it is not considered a pre-cancer. (6)

2-3-2-4 Medullary Carcinoma:

Has better defined margins so has a better prognosis than ductal or lobular. Only accounts for approximately 5% of breast cancers. (6)

2-3-2-5 Colloid (or Mucinous) Carcinoma:

Rarer again. Arises from mucous secreting cells. Also a better prognosis. (6)

2-3-2-6 Tubular Carcinoma:

Is a form of Ductal carcinoma with tubular cells visible on histo-cytology. With increasing early (sub-clinical) screening, tubular carcinomas are being detected with increased frequency. (6)

2-3-2-7 Paget's Disease of the breast:

Greater than 97% of patients with Pagets disease of the nipple have an underlying breast cancer . Accordingly, accurate diagnosis is important. (6)

Clinically, the patient may have an eczema-like rash around the nipple/areola and nipple discharge. There may be itching/tingling or hypersensitivity of the nipple. (6)

As many Pagets related breast cancers begin in the ducts behind the nipple, ensure this area is scanned thoroughly with high resolution equipment. (6)

Mammography and Breast MRI are appropriate investigations in these patients. (6)

2-4 Breast ultrasound

- Sonographic Appearance of normal breast :
Boundaries → strong, bright echo reflection.

Skin line, Nipple, Retromammary Layer and Subcutaneous fat → hypoechoic.

Cooper's Ligaments → echogenic.

Pectoral muscle → low level echoes. Ribs → hyperechoic. (7)

?

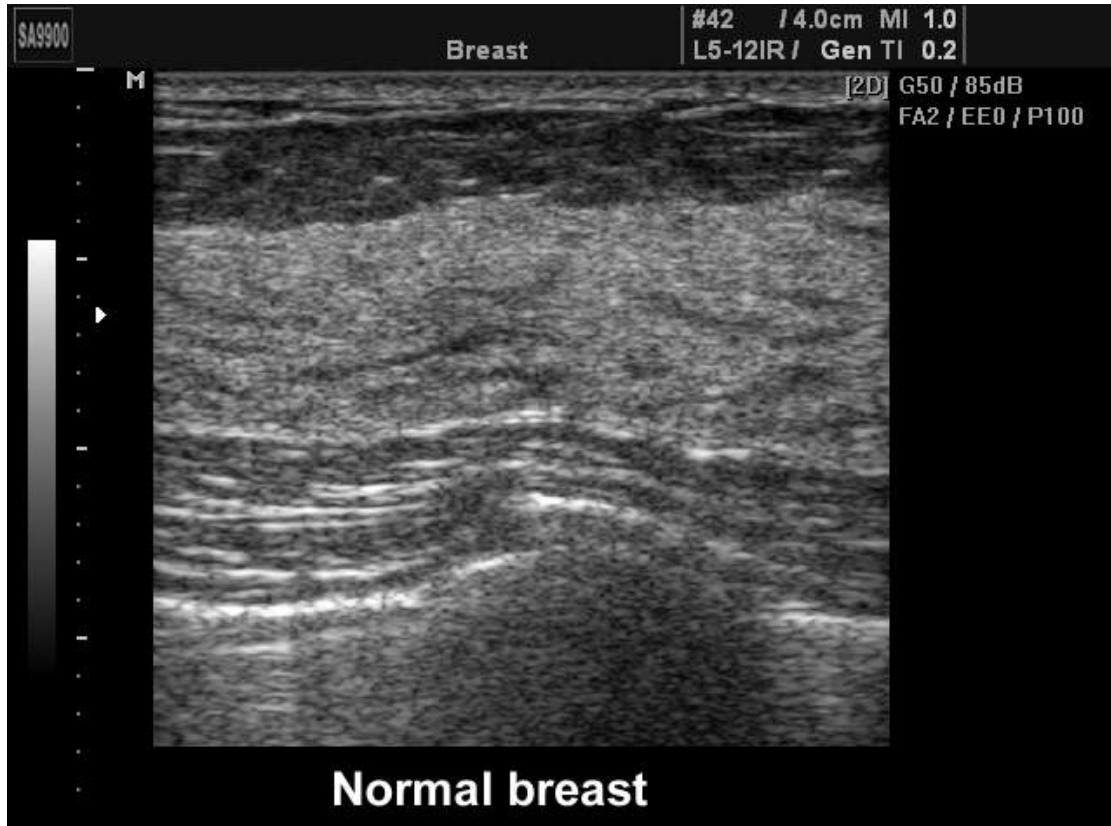

Figure 2-3 ultrasound image show normal breast (7)

- Benign or malignant sonographic characteristics of Solid Breast Nodules:

Ultrasound is a useful diagnostic tool for breast cancer, especially for younger patients. Most of the time breast ultrasound is used as a way to distinguish solid from cystic masses and often to determine the extent of cancer in known or suspected cases. For young women (younger than 30) ultrasound imaging may be the first step which a clinical exam reveals either a palpable mass or nipple discharge. (Since breast cancer tends to happen with older post-menopausal women,

doctors try not to expose younger women to the unnecessary radiation of a mammogram). But sonography can help establish the differentiation between benign and malignant solid tumors as well. A lack of circumscribed margins, heterogeneous echo patterns, and an increased anteroposterior dimension can indicate a higher probability of malignancy in solid breast nodules.(7)

- Ultrasound studies will carefully examine margins, shape, and echogenicity:
- The most important features on a breast ultrasound are the clarity and contour of the mass margins, the orientation and shape of the mass, the echo texture and echogenicity, and the effects on distal echoes. Other aspects of the mass such as compressibility and vascularity may also be noted. Some of the features one might usually find in a sonograph of a malignant breast mass would include a marked hypoechogenicity, acoustic shadowing, a branch pattern or microlobulation, or a duct extension. Other malignant features might be a 'taller than wide' shape, angular margins, the presence of calcifications, and spiculation, which probably has the highest positive predictive value for malignant breast cancer. Benign breast lesions on the other hand tend to appear on ultrasound with intense and uniform hyperechogenicity, as an oval shape with a thin, consistent capsule, and they may have two to three gentle lobulations.(7)

- Ultrasound characteristics typical of malignant breast masses:

The most typical sonographic presentation of a malignant breast mass would probably be an irregular, heterogenous, hypoechoic mass, with spiculations and angular margins. And, these kinds of masses tend to have that 'taller-than-wide' appearance, and also demonstrate acoustic shadowing. The image below shows an ill-defined border, an irregular shape, microlobulations, and spiculations (which appears as a hyperechoic 'band' around the mass). The lesion also appears to be 'taller-than-wide', with an angular margin. This would all be highly predictive of invasive ductal . (7)

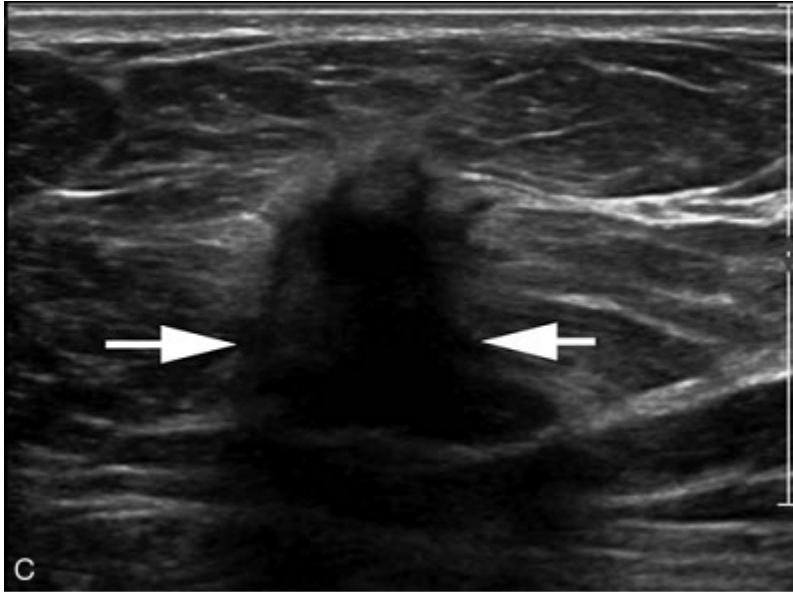


Figure 2-4 Breast carcinoma 62 year-old female showing carcinoma, Ultrasound image show.spiculated margin and posterior shadowing (arrows) (7)

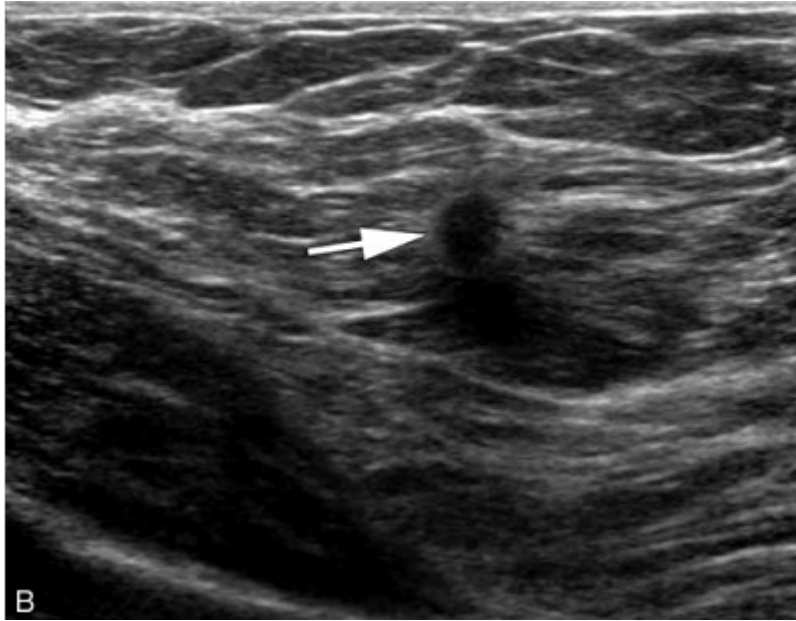


Figure 2-5Ultrasound image shows irregular margin (arrow) taller than wide, suspicious for malignancy.⁽⁷⁾

- Calcifications on breast ultrasound are also suspicious for malignancy:

Mammography is more sensitive than ultrasound when it comes to the detection of microcalcifications. Calcifications on a solid mass which appear 'punctate' are highly suspicious of malignancy, and will usually appear on ultrasound as bright, punctate foci. Since malignant breast lesions are typically either intensely or mildly homogenous hypochoic solid masses, on ultrasound this provides a 'background' which makes it easier to view calcifications sonographically. So, while calcifications are usually not seen on ultrasound, when they do appear vividly, it is highly suspicious for malignancy.⁽⁷⁾

- Benign ultrasound indicators include hyperechogenicity, thin well defined border :

On ultrasound, a benign breast mass will typically be well defined and with smooth margins. The lesion might also be macrolobulated or with just 2 to 4 mild lobulations. Benign breast lesions also tend to be ovoid or round in shape, and are often 'wider-than-tall' (which indicates a parallel orientation to the chest wall). The echo texture of a benign mass will usually be homogeneous with an isoechoic, hyperechoic, to mildly hypoechoic echogenicity. Some benign breast masses will also exhibit mild acoustic enhancement on ultrasound, and might be slightly compressible. Vascularity in an ultrasound of a benign mass is variable and will depend on the specific histology of the suspicious mass.(7)

In terms of sonographic features suggestive of benign breast lesions, a well circumscribed margin has a positive predictive value for being benign about 90% of the time, and an 'oval shape' about 84% of the time. Breast lesions with a 'parallel' orientation are predictive of benignity almost 80% of the time. (7)

The quality of the margins of a breast lesions scanned with ultrasound are is sometimes referred to as its 'capsule'. If the margin of the suspected mass seems well-circumscribed in both it's inner and outer edges, and seems thin and even, this tends to be a sign of a benign mass. The lesion is 'encapsulated' by the compressed adjacent breast tissue, and the mass itself is 'pushing against' this tissue, rather than infiltrating and invading that tissue.(7) Sometimes you do see a mild undulation in contour on ultrasound with a benign fibroadenoma. But there should not be many of these mild 'lobulations', and usually any more than three is considered a potentially malignant sign. Of greater concern are more numerous, smaller, and sharper microlobulations than one tends to find in malignant breast cancer tumors.(7)

Breast lesions which appear as having a marked and uniform hyperechogenicity are highly predictive of a benign lesion. This feature typically represents normal fibrous changes within the breast. But when there are some regions are either hyperechogenicity or isoechogenicity that are larger than normal (larger than either normal ducts or terminal ductal-lobular units) , that would indicate a 'medium' level of concern and would probably result in a biopsy, particularly if these areas were not contained within fat lobules.(7)

The 'compressibility' of a breast lesions scanned with ultrasound refers to changes in the shape of a lesion as a result of the pressure applied by the probe. A solid, likely malignant, breast lesion will not 'compress' at all from the pressure of the probe, but a tumor of benign fibrous or glandular tissue, such as a fibroadenoma, will show some compressibility. A benign breast fibroadenoma is usually oriented horizontally, more wide than tall. Often the compression of the scanner will cause a 'flattened' oval shape of a fibroadenoma, which would not occur with solid malignant breast mass. (7)

- Breast ultrasound sometimes detects abnormal axillary lymph nodes :

Sometimes a breast ultrasound will pick up an enlarged node in axilla. Many breast cancer oncologists would take an enlarged axillary node on ultrasound as proof positive for lymph node metastasis, even without a lymph node dissection. (Sometimes patients will not agree to a lymph node dissection to check for breast cancer metastasis) (7)

- Breast Cysts:

Simple cysts must be:

- I. Anechoic
- II. Well circumscribed
- III. Have posterior enhancement
- IV. It's height should NOT exceed it's width.

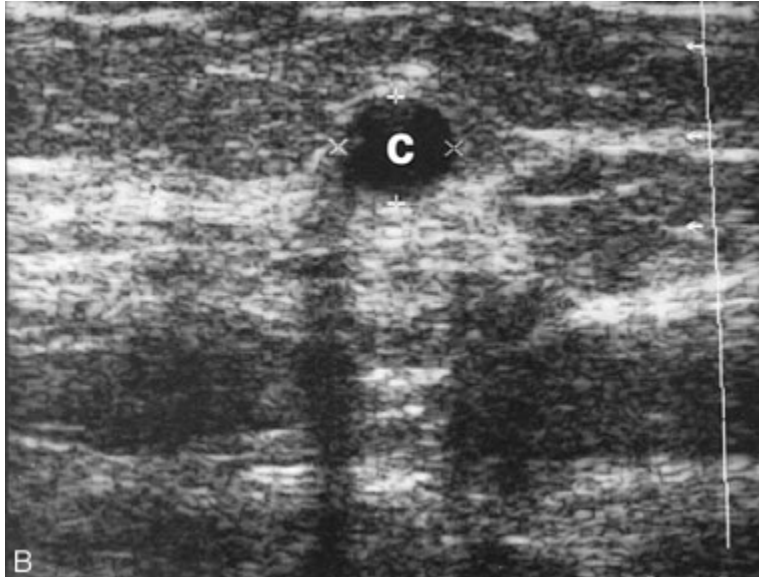


Figure 2-6 Benign breast cyst Ultrasound shows the sonolucent cyst with posterior acoustic enhancement and no internal echoes (7)

- **FIBROADENOMA:**

Classified as Benign mass, Well circumscribed solid ovoid mass with subtle posterior enhancement. Histological confirmation via a biopsy is still recommended. A core biopsy is referable.(7)

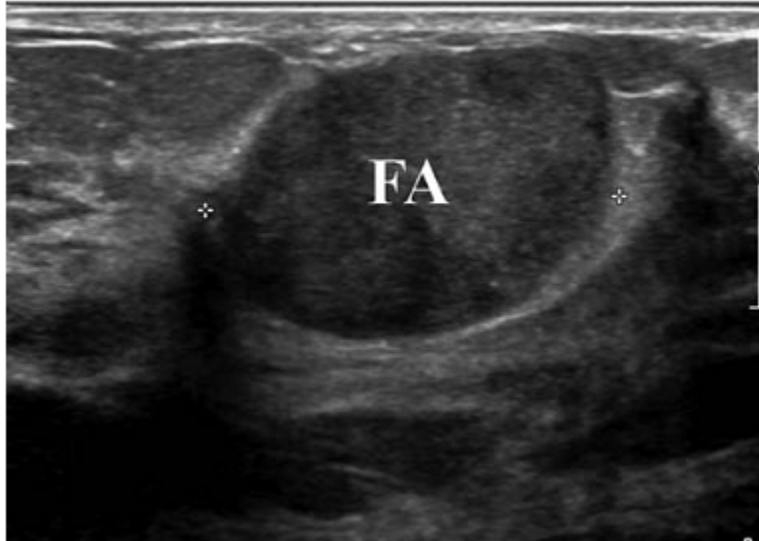


Figure 2-7 Breast sonography , fibroadenoma in a 17-year-old patient. Note smooth border, but internal echo indicating a solid mass.(7)

- **PAPILLOMA:**

Whist often benign, their malignant tendency generally leads to removal. Multiple papillomas have been shown to carry a far greater risk than solitary. They are fibrovascular growths within milk ducts behind the nipple.

Radiographic ductography has often been employed to confirm the diagnosis, however advancements in Ductoscopy are proving to be of great benefit.(7)

2-5 physics of sound :

Sound is mechanical energy transmitted by pressure waves in a medium.

Energy is the capacity to do work.

Mechanical meaning it exists in the form of physical movements of the molecules and particles in the medium.(8)

Waves may be defined as a disturbance or variation that transfers energy progressively from point to point in a medium.(8)

2-5-1 Acoustic Variables:

describe the events in sound wave, which include Pressure is the concentration of force, or in other words, force over a given area. Units of pressure are pounds per square inch (lbs/sq in), pascals (Pa), and newton per square meter (N/m²). (8)

Density is the concentration of mass or weight. Units of density are pounds per cubic feet (lbs/ft³) and kilograms per cubic meter (kg/m³).

Temperature is the concentration of heat energy. The unit of temperature is degrees (Fahrenheit, Celsius, or Kelvin scale). (8)

Particle motion includes the displacement, speed, velocity, and acceleration of a particle. The unit depends on the parameter being assessed. For displacement, any unit of distance can be used such as micrometer (μm) or millimeter (mm). The unit of speed and velocity is feet per second (ft/s) or meters per second (m/s). (8)

Sound Frequency In general, frequency is the number of certain events that occur in a specific period of time. With respect to sound, frequency is the number of cycles of an acoustic variable that occur in one second.

Period is the time it takes for a sound wave to complete one cycle of oscillation. Period is inversely related to frequency. It is determined by dividing the frequency into 1.

$$\text{period} = \frac{1}{\text{frequency}}$$

The ↑ higher the frequency, the ↓ shorter the period, and vice versa. (8)

Wavelength Is the distance between any two consecutive identical points on a wave.

Speed of Sound is the speed a sound wave travels or propagates in a medium along a specified line or direction. The speed of sound in a medium is determined by Density and Compressibility. Also there are other factors such as frequency but it is very small so could be ignored.(8)

Density is the mass of the medium per unit volume, the higher the density of a medium the more mass it contains within a given volume. The unit of density is kilograms per cubic meters (kg/m^3) or grams per cubic centimeters (g/cm^3). (8)

Attenuation is caused by the following processes:

- i. Absorption.
- ii. Reflection.
- iii. Scattering.
- iv. Beam divergence (Refraction). (8)

2-5-2 Modes of Display:

A mode: Spikes where precise length and depth measurements.

B mode (brightness): used most often 2 D reconstruction of the image slice

M mode: motion mode Moving 1D image cardiac mainly(9).

Diagnostic sonography is an ultrasound-based diagnostic imaging technique used for visualizing internal body structures including tendons, muscles, joints, vessels and internal organs for possible pathology or lesions. The practice of examining pregnant women using ultrasound is called obstetric sonography, and is widely used.(8)

In physics, 'ultrasound' refers to sound waves with a frequency too high for humans to hear. Ultrasound images (sonograms) are made by sending a pulse of ultrasound

into tissue using an ultrasound transducer (probe). The sound reflects and echoes off parts of the tissue; this echo is recorded and displayed as an image to the operator.(8)

Many different types of images can be formed using ultrasound. The most well-known type is a B-mode image, which displays a two-dimensional cross-section of the tissue being imaged. Other types of image can display blood flow, motion of tissue over time, the location of blood, the presence of specific molecules, the stiffness of tissue, or the anatomy of a three-dimensional region. Ultrasound can also be used therapeutically, to break up gallstones and kidney stones or to heat and destroy diseased or cancerous tissue.(8)

Compared to other prominent methods of medical imaging, ultrasonography has several advantages. It provides images in real-time , it is portable and can be brought to a sick patient's bedside, it is substantially lower in cost, and it does not use harmful ionizing radiation. Drawbacks of ultrasonography include various limits on its field of view including difficulty imaging structures behind bone, and its relative dependence on a skilled operator.(8)

Typical diagnostic sonographic scanners operate in the frequency range of 2 to 18 megahertz, though frequencies up to 50–100 megahertz have been used experimentally in a technique known as biomicroscopy in special regions, such as the anterior chamber of the eye. The choice of frequency is a trade-off between spatial resolution of the image and imaging depth, lower frequencies produce less resolution but image deeper into the body. Higher frequency sound waves have a smaller wavelength and thus are capable of reflecting or scattering from smaller structures. Higher frequency sound waves also have a larger attenuation coefficient and thus are more readily absorbed in tissue, limiting the depth of penetration of the sound wave into the body.(8)

Sonography is widely used in medicine. It is possible to perform both diagnosis and therapeutic procedures, using ultrasound to guide interventional procedures (for

instance biopsies or drainage of fluid collections). Sonographers are medical professionals who perform scans which are then typically interpreted by radiologists, physicians who specialize in the application and interpretation of a wide variety of medical imaging modalities,

or by cardiologists in the case of cardiac ultrasonography (echocardiography).(8)

Sonographers typically use a hand-held probe (called a transducer) that is placed directly on and moved over the patient. Increasingly, clinicians (physicians and other healthcare professionals who provide direct patient care) are using ultrasound in their office and hospital practices, for efficient, low-cost, dynamic diagnostic imaging that facilitates treatment planning while avoiding any ionising radiation exposure.(8)

Sonography is effective for imaging soft tissues of the body. Superficial structures such as muscles, tendons, testes, breast, thyroid and parathyroid glands, and the neonatal brain are imaged at a higher frequency (7–18 MHz), which provides better axial and lateral resolution.(8) Deeper structures such as liver and kidney are imaged at a lower frequency 1–6 MHz with lower axial and lateral resolution but greater penetration.(8)

A general-purpose sonographic machine may be used for most imaging purposes. Usually specialty applications may be served only by use of a specialty transducer. Most ultrasound procedures are done using a transducer on the surface of the body, but improved diagnostic confidence is often possible if a transducer can be placed inside the body. For this purpose, specialty transducers, including endovaginal, endorectal, and transesophageal transducers are commonly employed. At the extreme of this, very small transducers can be mounted on small diameter catheters and placed into blood vessels to image the walls and disease of those vessels.(8)

Ultrasonography (sonography) uses a probe containing multiple acoustic transducers to send pulses of sound into a material. Whenever a sound wave encounters a material with a different density (acoustical impedance), part of the sound wave is

reflected back to the probe and is detected as an echo. The time it takes for the echo to travel back to the probe is measured and used to calculate the depth of the tissue interface causing the echo. The greater the difference between acoustic impedances, the larger the echo is. If the pulse hits gases or solids, the density difference is so great that most of the acoustic energy is reflected and it becomes impossible to see deeper.(8)

The frequencies used for medical imaging are generally in the range of 1 to 18 MHz. Higher frequencies have a correspondingly smaller wavelength, and can be used to make sonograms with smaller details. However, the attenuation of the sound wave is increased at higher frequencies, so in order to have better penetration of deeper tissues, a lower frequency (3–5 MHz) is used.(8)

Seeing deep into the body with sonography is very difficult. Some acoustic energy is lost every time an echo is formed, but most of it (approximately $0.5 \frac{\text{dB}}{\text{cm depth} \cdot \text{MHz}}$) is lost from acoustic absorption.(8)

The speed of sound varies as it travels through different materials, and is dependent on the acoustical impedance of the material. However, the sonographic instrument assumes that the acoustic velocity is constant at 1540 m/s. An effect of this assumption is that in a real body with non-uniform tissues, the beam becomes somewhat de-focused and image resolution is reduced.(8)

To generate a 2D-image, the ultrasonic beam is swept. A transducer may be swept mechanically by rotating or swinging. Or a 1D phased array transducer may be used to sweep the beam electronically. The received data is processed and used to construct the image. The image is then a 2D representation of the slice into the body.(8)

3D images can be generated by acquiring a series of adjacent 2D images. Commonly a specialised probe that mechanically scans a conventional 2D-image transducer is used. However, since the mechanical scanning is slow, it is difficult to

make 3D images of moving tissues. Recently, 2D phased array transducers that can sweep the beam in 3D have been developed. These can image faster and can even be used to make live 3D images of a beating heart.(8)

Doppler ultrasonography is used to study blood flow and muscle motion. The different detected speeds are represented in color for ease of interpretation, for example leaky heart valves: the leak shows up as a flash of unique color. Colors may alternatively be used to represent the amplitudes of the received echoes.(8)

2-5-3 Producing of sound wave:

A sound wave is typically produced by a piezoelectric transducer or a capacitive micromachined transducer, encased in a housing which can take a number of forms. Strong, short electrical pulses from the ultrasound machine make the transducer ring at the desired frequency. The frequencies can be anywhere between 2 and 18 MHz. The sound is focused either by the shape of the transducer, a lens in front of the transducer, or a complex set of control pulses from the ultrasound scanner machine (Beamforming). This focusing produces an arc-shaped sound wave from the face of the transducer. The wave travels into the body and comes into focus at a desired depth.(8)

Older technology transducers focus their beam with physical lenses. Newer technology transducers use phased array techniques to enable the sonographic machine to change the direction and depth of focus. Almost all piezoelectric transducers are made of ceramic.(8)

Materials on the face of the transducer enable the sound to be transmitted efficiently into the body (usually seeming to be a rubbery coating, a form of impedance matching). In addition, a water-based gel is placed between the patient's skin and the probe.(8)

The sound wave is partially reflected from the layers between different tissues. Specifically, sound is reflected anywhere there are density changes in the body: e.g.

blood cells in blood plasma, small structures in organs, etc. Some of the reflections return to the transducer.(8)

2-5-3-1 Receiving the echoes:

The return of the sound wave to the transducer results in the same process that it took to send the sound wave, except in reverse. The return sound wave vibrates the transducer, the transducer turns the vibrations into electrical pulses that travel to the ultrasonic scanner where they are processed and transformed into a digital image.(8)

2-5-3-2 Forming the image:

The sonographic scanner must determine three things from each received echo:

How long it took the echo to be received from when the sound was transmitted.

From this the focal length for the phased array is deduced, enabling a sharp image of that echo at that depth (this is not possible while producing a sound wave).(8)

How strong the echo was. It could be noted that sound wave is not a click, but a pulse with a specific carrier frequency. Moving objects change this frequency on reflection, so that it is only a matter of electronics to have simultaneous Doppler sonography.(8)

Once the ultrasonic scanner determines these three things, it can locate which pixel in the image to light up and to what intensity and at what hue if frequency is processed .(8)

Transforming the received signal into a digital image may be explained by using a blank spreadsheet as an analogy. First picture a long, flat transducer at the top of the sheet. Send pulses down the 'columns' of the spreadsheet (A, B, C, etc.). Listen at each column for any return echoes. When an echo is heard, note how long it took for the echo to return. The longer the wait, the deeper the row (1,2,3, etc.). The strength of the echo determines the brightness setting for that cell (white for a strong

echo, black for a weak echo, and varying shades of grey for everything in between.)
When all the echoes are recorded on the sheet, we have a grey scale image.⁽⁸⁾

2-5-3-3 Displaying the image:

Images from the sonographic scanner can be displayed, captured, and broadcast through a computer using a frame grabber to capture and digitize the analog video signal. The captured signal can then be post-processed on the computer itself.⁽⁸⁾

2-6 The Ultrasound Machine:

A basic ultrasound machine has the following parts:

- transducer probe - probe that sends and receives the sound waves
- central processing unit (CPU) - computer that does all of the calculations and contains the electrical power supplies for itself and the transducer probe
- transducer pulse controls - changes the amplitude, frequency and duration of the pulses emitted from the transducer probe
- display the image from the ultrasound data processed by the CPU.

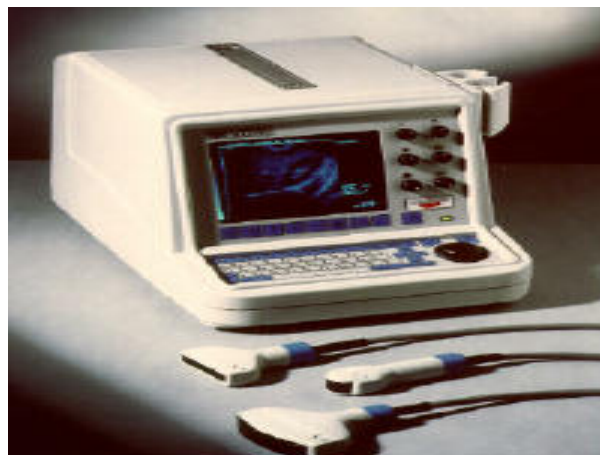

Figure 2-8 ultrasound machine(8)

- keyboard/cursor - inputs data and takes measurements from the display.
- disk storage device (hard, floppy, CD) - stores the acquired images .
- printer - prints the image from the displayed data.(8)

- Transducer Probe:

The transducer probe is the main part of the ultrasound machine. The transducer probe makes the sound waves and receives the echoes. It is, so to speak, the mouth and ears of the ultrasound machine. The transducer probe generates and receives sound waves using a principle called **the piezoelectric (pressure electricity) effect**, which was discovered by Pierre and Jacques Curie in 1880. In the probe, there are one or more quartz crystals called piezoelectric crystals. When an electric current is applied to these crystals, they change shape rapidly. The rapid shape changes, or vibrations, of the crystals produce sound waves that travel outward. Conversely, when sound or pressure waves hit the crystals, they emit electrical currents. Therefore, the same crystals can be used to send and receive sound waves. The probe also has a sound absorbing substance to eliminate back reflections from the probe itself, and an acoustic lens to help focus the emitted sound waves.(8)

Transducer probes come in many shapes and sizes, as shown in the photo above. The shape of the probe determines its field of view, and the frequency of emitted sound waves determines how deep the sound waves penetrate and the resolution of the image. Transducer probes may contain one or more crystal elements; in multiple-element probes, each crystal has its own circuit. Multiple-element probes have the advantage that the ultrasound beam can be "steered" by changing the timing in which each element gets pulsed; steering the beam is especially important for cardiac ultrasound (see Basic Principles of Ultrasound for details on transducers). In addition to probes that can be moved across the surface of the body, some probes are designed to be inserted through various openings of the body (vagina, rectum, esophagus) so that they can get closer to the organ being examined (uterus, prostate gland).

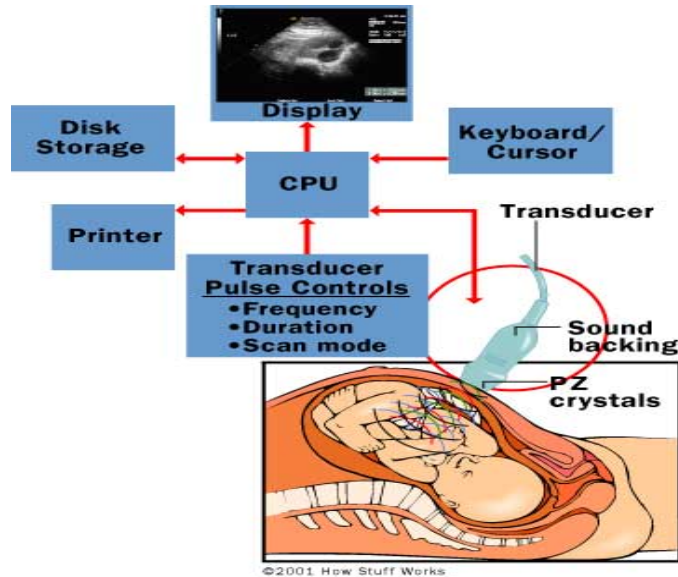


Figure 2-9 The parts of an ultrasound machine.(8)

- Central Processing Unit (CPU):

The CPU is the brain of the ultrasound machine. The CPU is basically a computer that contains the microprocessor, memory, amplifiers and power supplies for the microprocessor and transducer probe. The CPU sends electrical currents to the transducer probe to emit sound waves, and also receives the electrical pulses from the probes that were created from the returning echoes. The CPU does all of the calculations involved in processing the data. Once the raw data are processed, the CPU forms the image on the monitor. The CPU can also store the processed data and/or image on disk. (8)

- Transducer Pulse Controls:

The transducer pulse controls allow the operator, called the ultrasonographer, to set and change the frequency and duration of the ultrasound pulses, as well as the scan mode of the machine. The commands from the operator are translated into changing electric currents that are applied to the piezoelectric crystals in the transducer probe.(8)

- **D i s p l a y :**
The display is a computer monitor that shows the processed data from the CPU. Displays can be black-and-white or color, depending upon the model of the ultrasound machine. (8)
- **K e y b o a r d / C u r s o r :**
Ultrasound machines have a keyboard and a cursor, such as a trackball, built in. These devices allow the operator to add notes to and take measurements from the data. (8)
- **Disk Storage:**
The processed data and/ or images can be stored on disk. The disks can be hard disks, floppy disks, compact discs (CDs) or digital video discs (DVDs). Typically, a patient's ultrasound scans are stored on a floppy disk and archived with the patient's medical records. (8)
- **P r i n t e r s :**
Many ultrasound machines have thermal printers that can be used to capture a hard copy of the image from the display. (8)

Different Types of Ultrasound

we have described so far presents a two dimensional image, or "slice," of a three dimensional object (fetus, organ). Two other types of ultrasound are currently in use, 3D ultrasound imaging and Doppler ultrasound. (8)

Transducer (probe): it have Piezoelectric crystal emit sound after electric charge applied, then sound reflected from patient and returning echo is converted to electric signal → grayscale image on monitor. (8)

Echo may be reflected, transmitted or refracted ,Transmit 1% and receive 99% of the time

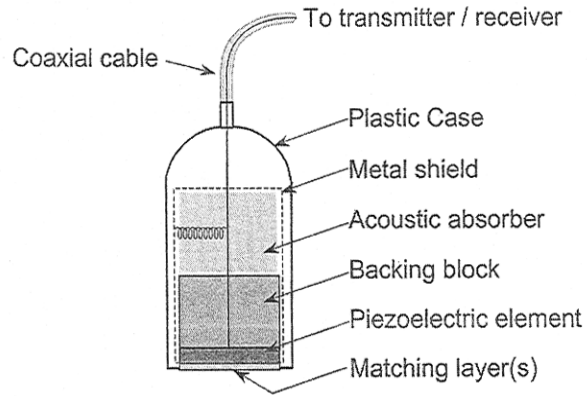


Figure 2-10 internal structure of probe (8)

Sector scanner: Fan-shaped beam and small surface required for contact common used for Cardiac imaging.

Linear scanner: Rectangular beam and Large contact area required.

Curvi-linear scanner: Smaller scan head have wider field of view. (8)

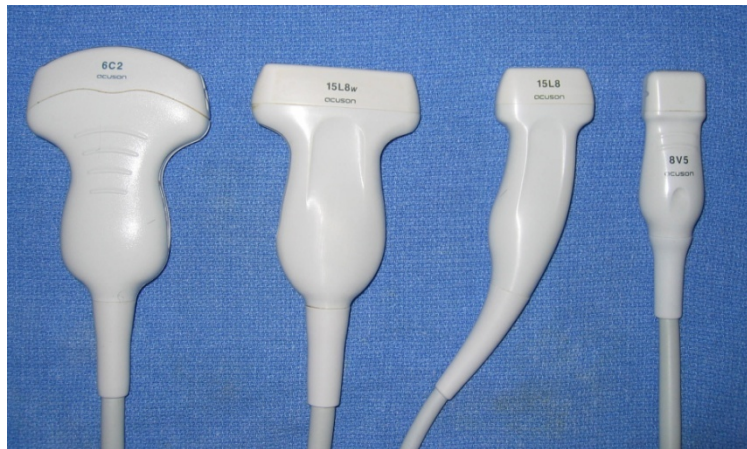

Figure 2-11 types of probe(8)

2-7 Doppler ultrasonography:

2-7-1 doppler physics:

Sonography can be enhanced with Doppler measurements, which employ the Doppler effect to assess whether structures (usually blood)[11] are moving towards or away from the probe, and its relative velocity. By calculating the frequency shift of a particular sample volume, for example flow in an artery or a jet of blood flow over a heart valve, its speed and direction can be determined and visualised.(10)

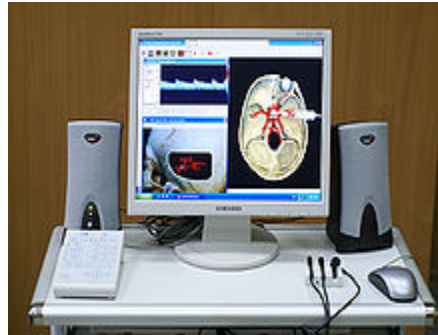

Figure 2-12 Doppler machine(10)

This is particularly useful in cardiovascular studies (sonography of the vascular system and heart) and essential in many areas such as determining reverse blood flow in the liver vasculature in portal hypertension. The Doppler information is displayed graphically using spectral Doppler, or as an image using color Doppler (directional Doppler) or power Doppler (non directional Doppler). This Doppler shift falls in the audible range and is often presented audibly using stereo speakers: this produces a very distinctive, although synthetic, pulsating sound.(10)

Most modern sonographic machines use pulsed Doppler to measure velocity. Pulsed wave machines transmit and receive series of pulses. The frequency shift of each pulse is ignored, however the relative phase changes of the pulses are used to obtain the frequency shift (since frequency is the rate of change of phase). The major advantages of pulsed Doppler over continuous wave is that distance information is obtained (the time between the transmitted and received pulses can be converted into a distance with knowledge of the speed of sound) and gain correction is applied. The disadvantage of pulsed Doppler is that the measurements can suffer from aliasing. The terminology "Doppler ultrasound" or "Doppler sonography", has

been accepted to apply to both pulsed and continuous Doppler systems despite the different mechanisms by which the velocity is measured.(10)

It should be noted here that there are no standards for the display of color Doppler. Some laboratories show arteries as red and veins as blue, as medical illustrators usually show them, even though some vessels may have portions flowing towards and portions flowing away from the transducer. This results in the illogical appearance of a vessel being partly a vein and partly an artery. Other laboratories use red to indicate flow toward the transducer and blue away from the transducer. Still other laboratories prefer to display the sonographic Doppler color map more in accord with the prior published physics with the red shift representing longer waves of echoes (scattered) from blood flowing away from the transducer; and with blue representing the shorter waves of echoes reflecting from blood flowing toward the transducer. Because of this confusion and lack of standards in the various laboratories, the sonographer must understand the underlying acoustic physics of color Doppler and the physiology of normal and abnormal blood flow in the human body.(10)

Although Angiography and Venography which both use X-ray and contrast injection material are more accurate than Doppler Sonography, Doppler Sonography may be chosen because it is faster, less expensive, and non-invasive.(10)

2-7-2 Doppler equation:

$$f' = \left(\frac{v \pm v_o}{v \mp v_s} \right) f_o$$

The f' is the perceived frequency, V_o is the velocity of the observer, V_s is the velocity of the source, V is a reference value: the speed of sound in whatever medium through which the sound is traveling.(10)

2-8 Literature review:

***Sonographic criteria for differentiation of benign and malignant solid breast lesions: size is of value:**

Cheung YC (2002)(11), The purpose of this study was to evaluate whether lesion size may influence the value of sonographic findings in the differential diagnosis between benign or malignant breast lesions.

Sonographic features of 256 histological confirmed (148 benign, 108 malignant) breast lesions were retrospectively and independently reviewed by three radiologists unaware of mammographic findings and pathology results. Each lesion was assessed for several sonographic features and assigned a level of suspicion. Logistic modeling defined the predictive value of each sonographic feature per se and in relation to lesion size. The k statistic (k) evaluated interobserver agreement in lesion classification. The accuracy of breast sonography in characterizing solid lesions was also evaluated.

Analysis of the sonographic features predictive of malignant disease, taken as a whole, showed that only irregular margins and marked hypoechogenicity maintain their predictive value independent of lesion size. When lesion size is considered, the other features remain significant only for lesions larger than 7 mm. Interobserver agreement for sonographic suspicion, when calculated not taking into account lesion size, was good or excellent whereas it was reduced for lesions smaller than 7 mm. Accuracy of breast sonography improved when evaluating lesions larger than 7 mm. Lesion size influences the value of sonographic findings in distinguishing benign from malignant lesions. The usually adopted criteria in sonography have a significantly lower accuracy in characterization of small lesions.

***Sonographic evaluation of benign and malignant breast lesions :**

Hwang TL (2006)(12), Sonography can be used for the differentiation of many benign and malignant solid breast lesions. However, accurate considerable experience , and close correlation with the physical examination and the mammogram, are required to do so. Sixteen sonographic signs useful in this

differentiation are reviewed. The specific sonographic appearances of the most common being entities are described. Primary breast malignancies are divided into five categories according to their sonographic presentations: (1) classic neoplasm's with irregular borders, echoic rims, and usually posterior shadowing, (2) small, round neoplasm with no echoic rim or posterior shadowing, (3) neoplasm with mixed or increased echogenicity, (4) cystic or intracystic carcinomas, and (5) colloid carcinomas. Methods for identification of these different types of invasive malignancy, and of in situ carcinomas, are presented. The usefulness of sonomammography is considered in specific circumstances, including evaluation of mammographic or physical findings, dense breasts, post-radiation breasts, and women under 35 years of age.

***Sonographic features of benign and malignant breast masses in sudanese women :**

Mustafa Z. Mahmoud (2012)(13), This study was conducted with the aim of investigating ultrasonographic features that differentiate benign from malignant breast masses and whether this distinction could be definite enough to obviate biopsy in Sudanese women.

A total of Fifty four samples of Sudanese women between the ages of 15 to 80 years were selected according to the positive evidence of breast(s) nodule that detected after initiated a breast(s) sonographic scan, among the outflow of the patients in order to differentiate between benign and malignant breast masses. Features like character, internal echogenicity, margins and sonographic artifacts were employed. Sonographic classifications of the lesions were compared with fine needle aspiration biopsy (FNAB) findings.

The masses were classified as benign or malignant according to their margins and artifact features only. Malignant masses were irregular and have posterior acoustic shadow, while benign masses were regular in shapes and producing enhanced posterior echo artifacts. These classifications were confirmed, to be as accurate results, by biopsy.

Findings indicate that specific sonographic features can be helpful in differentiating benign from malignant lesions, also sonography can be used widely and accurately to prevent unnecessary biopsies.

3- method and data collection:

3-1-subject:

20 patients came to ultra sound department with abnormal breast masses, firstly we asked them about when the mass began and if mass mobile or not, painful or not, then asked from menstrual cycle and its regularity, also asked from the family history and if the patient married or not.

The data was collected by master sheets using the following variable:

Age, RT or LT breast, the quadrant, and if she married (pregnant, using contraceptive, lactating, having children and number of child).

3-2-The machine:

Real time ultra sound machine general electric with 7.5 MHZ linear probe, using thermal paper for printing the image.

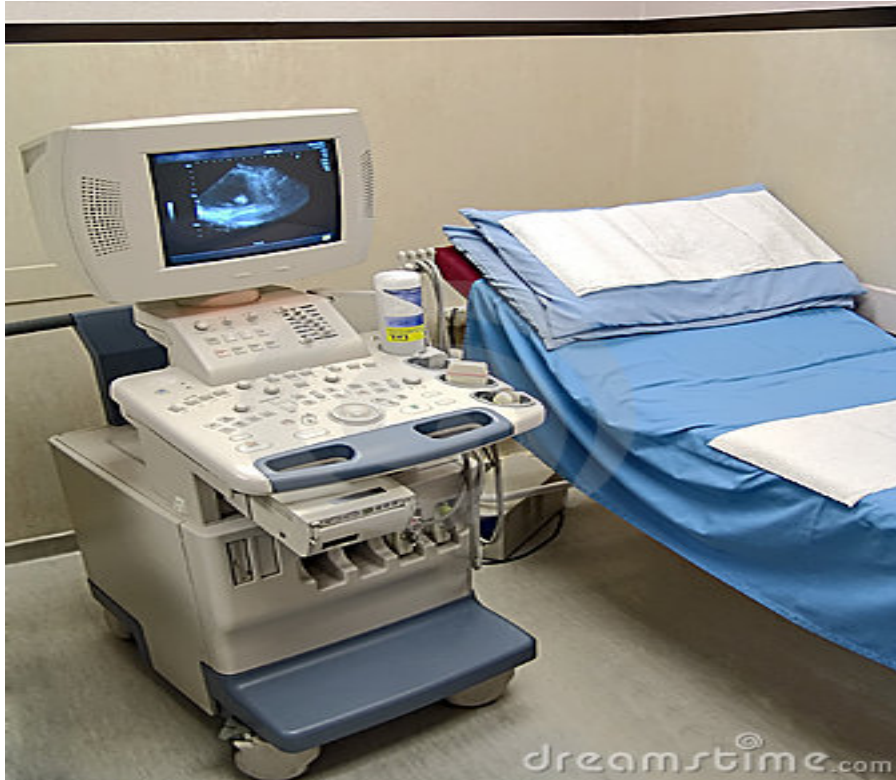

Figure 3-1 ultrasound machine

3-3-The technique:

Patient undress their clothes in upper part of the body, then lying down and begins scanned at 12 o'clock position , Transducer orientation was set up so that the breast was viewed in sections from the nipple outward, where the orientation notch is located. Scanning was initiated around the breast in a clockwise manner, covering all anatomy, including the axillary regions.

Patient asked to lie on her back on an examination table and raise her arm above the head in the side of the breast to be examined; alternatively the patient may be positioned on her side. A conductive paste or gel will be applied to the breasts and a hand-held transducer with high frequency will be placed directly on the skin


overlying the breast the gel will be removed from the breasts after completing the procedure. Breasts scanning done in a radial fashion from the outer margin towards the nipple in a series of scans Mimi clockwise order; either the patient initially lies supine with the ipsilateral hand raised above her head, medial quadrant lesion may be scanned in this position, then the patient is rolled into contra lateral posterior oblique position to a degree which minimizes the breast thickness in the quadrant being scanned larger breasts require greater obliquity, positioning the patient in this fashion will thins the breast, so the near field probe can penetrate to the chest wall.

Result

All collected data analyzed and tabulated in tables and figures as following:

Table 4-1 demonstrate age distribution

Age group	Frequency	Percentage
20-30	5	25%
31-40	4	20%
41-50	3	15%
51-60	5	25%
61-70	3	15%



Figures 4-1 demonstrate age distribution

Table 4-2 explain the family history

Family history	frequency	Percentage
Yes	12	60%
No	8	40%
Total	20	100%




Figure 4-2 explain the family history

Table 4-3 the regularity of menstrual cycle

Period	frequency	Percentage
Regular	7	35%
Not regular	7	35%
None	6	30%
Total	20	100%

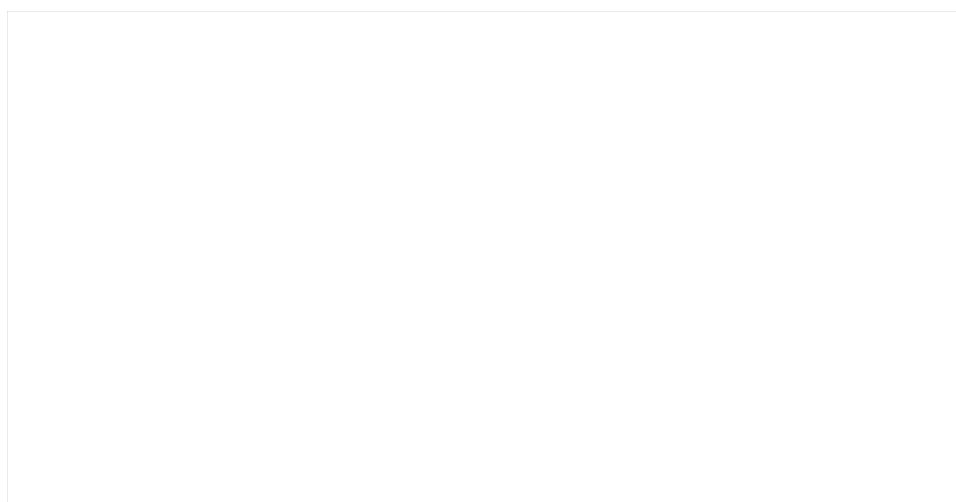


Figure 4-3 The regularity of menstrual cycle

Table 4-4 Explain post menopausal

Post menopausal	Frequency	Percentage
Yes	6	30%
No	14	70%
Total	20	100%



Figure 4-4 Explain post menopausal

Table 4-5 explain using of contraceptive tabs

Contraceptive tabs	frequency	Percentage
Yes	3	15%
No	17	85%
Total	20	100%



Figure 4-5 explain using of contraceptive tabs

Table 4-6 display the frequency of married women

married	frequency	Percentage
Yes	14	70%
No	6	30%
Total	20	100%




Figure 4-6 display the frequency of married women

Table 4-7 display the frequency of pregnant women

Pregnant	frequency	Percentage
Yes	4	20%
No	16	80%
Total	20	100%




Figure 4-7 display the frequency of pregnant women

Table 4-8 display the frequency of women having children

Have children	frequency	Percentage
Yes	13	65%
No	7	35

Total	20	100%
-------	----	------

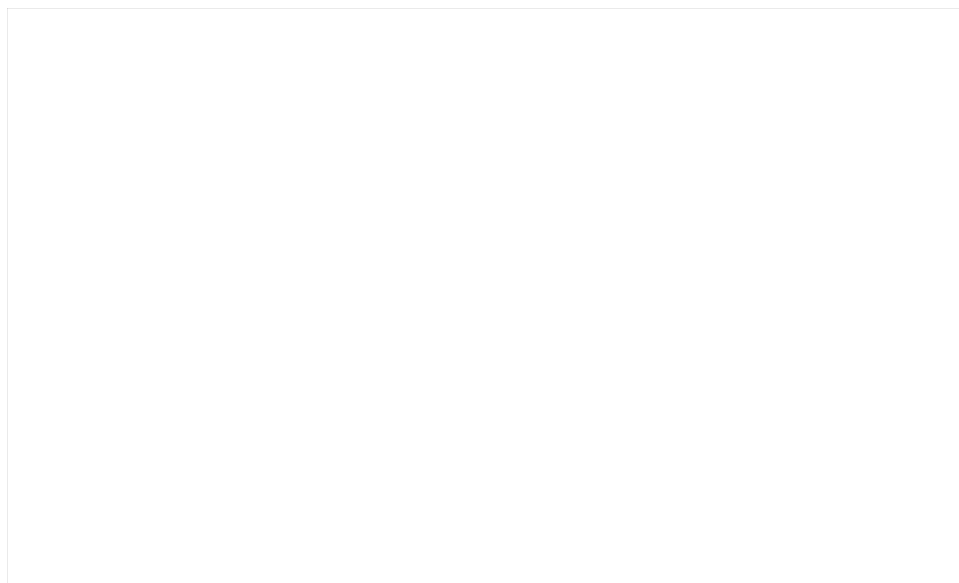


Figure 4-8 display the frequency of women having children

Table 4-9 display the frequency of lactating women

Lactating	frequency	Percentage
-----------	-----------	------------

Yes	1	5%
No	19	95%
Total	20	100%




Figure 4-9 explain display the frequency of lactating women

Table 4-10 explain side of lesion

Side	frequency	Percentage
Right	5	35%
Lift	15	75%
Total	20	100%




Figure 4-10 explain side of lesion

Table 4-11 display affected quadrate

Quadrate	Frequency	Percentage
RUO	2	10%
RUM	1	5%
RLO	1	5%
RLM	0	0%
Rt. Aerolar	1	5%
LUM	3	15%
LUO	7	35%
LLM	1	5%
LLO	2	10%
LT. Aerolar	2	10%
Total	20	100%



Figure 4-11 display affected quadrate

Table 4-12 display type of lesion

Final diagnosis	Frequency	Percentage
Mastitis	1	5%
Abscess	4	20%
Fibro adenoma	4	20%
Ductectasia	3	15%
Lymphadenopathy	2	10%
Cyst disease	3	15%
Malignant	3	15%
Total	20	100%



Figure 4-12 display type of lesion

5-1 Discussion:

Breast lump is the commonest presentation of various breast disease it can be benign or malignant and Early diagnosis of breast cancer is essential because it affects the outcome and prognosis.

In this study, the age of patient presented with breast lumps range between 20-70 years old, The breast lumps occur in young age group (20-30) females 25% as same as elder females age group (51-60) table (4-1).

12 patient presented with lumps has a family history of ca breast which is 60% table (4-2).

The regularity of menstrual cycle has no effect in breast lumps which is 35% of each regular and not regular table (4-3).

Most of patients are not use contraceptive tabs 85% . only 3 patients which 15% are using contraceptive tabs , that means no relationship of using contraceptive tabs table (4-5).

Married patients 70% had lumps while only 6 patients are single (4-6).

The high occurrence in married females could be due to age, married females are older which is 80%, 16 patients are not pregnant table (4-7).

In this study most of patients have children, 13 which is 65 % and 7 patient which is 35% have no children table (4-8).

19 patients of which is 95 % are not lactating women table (4-9).

According to the location of breast lumps 75% were in the left breast and 35% only in the right breast, It was found that in right breast upper outer quadrant 2 which is 10% , upper lateral 5% , right lower outer 5%, right aerolar region 5%, while in left breast upper inner 15%, upper outer 35%, lower inner 5% , lower outer 10% and left aerolar 10%. That means the most common affected area at left breast upper outer quadrant table (4-11).

In this study we found that abscess and fibro adenoma both are 20%, ductectasia and cystic disease and malignant each 15%, only one mastitis 5% and 2 lymphadenopathy which is 10% table (4-12).

5-2 Conclusion :

- Breast lump is a major health problem, which in our study occurred in young and elderly patient as the same percentage.
- Most of patient with lumps has a family history.
- Regularity of cycle and using contraceptive tabs has no effect in occurrence of breast lumps .
- Most lumps are on left breast on upper outer quadrant.
- Most pathology occurrence are abscess and fibroadenoma next ductectasia ,cyst disease and malignant lumps the least was lymphadenopathy.
- We found that ultrasound can differentiate between different breast benign and malignant disease.

5-3 Recommendation:

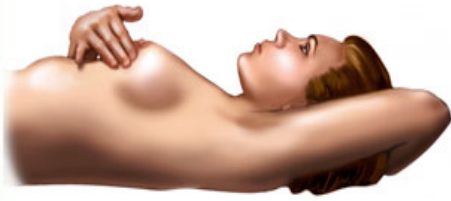- 1- We recommend that use the ultrasound because it is a valuable diagnostic tool in identifying breast masses, simple, portable, non invasive, repeatable, non time consuming and safe.
- 2- We recommend to do ultrasound examination in combination with mammography exam to get the accurate diagnose.
- 3- We recommend to develop simple accepted preliminary screening test (clinical and self exam) before ultrasound.
- 4- We recommend that color Doppler ultrasound be examined before FNA.
- 5- Futures studies most be done using the most advanced ultrasound machines which may confirm the diagnosis without using biopsy examination.

Reference:

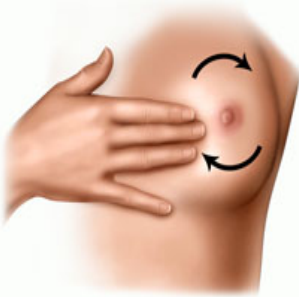- 1- <http://mammary.nih.gov/reviews/developmet human-breast>.
- 2- <http://epe.lac-bac.gc.ca>.
- 3- <http://health.bettermedicine.com/article/breast.abscess>.
- 4- <http://www.emedicinehealth.com/breast-infection/article-em.htm>.
- 5- <http://en.wikipedia.org/wiki/breast cancer>.
- 6- Buchberger W, DeKoekkoek-Doll P, Springer P, Obrist P, Dunser M. Incidental findings on sonography of the breast: Clinical significance and diagnostic workup. AJR Am J Roentgenol [Internet]. 1999 Oct;173(4):921-7
- 7- Clinical radiology
- 8- <http://www.wikiradiograph.com/physics-ultrasound>.
- 9- <http://en.wikipedia.org/wiki/mode-display.com>.
- 10- <http://en.wikipedia.org/wiki/Doppler-physics.com>.
- 11- cheung yc ,charlez ab, (2002) Istituto di Radiologia, Policlinico Universitario di Udine, Via Colugna 50, I-33100, Udine, Italy. chiara.delfrate@med.uniud.it
- 12- hwang tl , mogang D , katren ed (2006) Hill Medical Corporation, Huntington Memorial Hospital, Pasadena, CA 91105, USA.
- 13- Mustafa Z. Mahmoud (2012) asian journal of medical and clinical s

Appendix 1

Breast Self-Examination



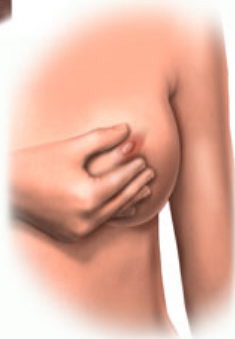1. Lie down and put your left arm under your head. Use your right hand to examine your left breast. With your 3 middle fingers flat, move gently in small circular motions over the entire breast, checking for any lump, hard knot, or thickening. Use different levels of pressure - light, medium, and firm - over each area of your breast. Check the whole breast, from your collarbone above your breast down to the ribs below your breast. Switch arms and repeat on the other breast.



2. Look at your breasts while standing in front of a mirror with your hands on your hips. Look for lumps, new differences in size and shape, and swelling or dimpling of the skin.



3. Raise one arm, then the other, so you can check under your arms for lumps.



4. Squeeze the nipple of each breast gently between your thumb and index finger. Report to your healthcare provider right away any discharge or fluid from the nipples or any lumps or changes in your breast.

© 2007 RelayHealth and/or its affiliates. All rights reserved.

Appendix 2