

1-1 Introduction

The oral cavity diseases are a medical term used to describe a patient who present with mouth pathology or mouth defect as there are numerous etiologies that can result in oral cavity diseases, prompt, accurate diagnoses is necessary to ensure proper patient management.

The study includes all dental patients who are undergoing screening OPG in sections of dental x-rays in the city of Khartoum, to assess the oral health through the images resulting from this examination and determine the feasibility of this examination in the diagnosis of diseases of the mouth and the knowledge of the relationship between food habits of the patient and the health of his mouth, and identify ways best for oral hygiene and to maintain his health and determine the effect of aging on the teeth and gums. In addition to studying effects for women.

1-2 Orthopantomogram (OPG)

Orthopantomogram is a panoramic scanning dental X-ray of the upper and lower jaw.

It shows a two-dimensional view of a half-circle from ear to ear.

Dental panoramic radiography equipment consists of a horizontal rotating arm which holds an X-ray source and a moving film mechanism (carrying a film) arranged at opposed extremities.

The patient's skull sits between the X-ray generator and the film.

The X-ray source is collimated toward the film, to give a beam shaped as a vertical blade having a width of 4-7mm when arriving on the film, after crossing the patient's skull.

Also the height of that beam covers the mandibles and the maxilla regions. The arm moves and its movement may be described as a rotation around an instant center which shifts on a dedicated trajectory

A large number of anatomical structures appear on an OPG:

Soft tissue structures and air shadows: demonstrates the main soft tissue structures seen on an OPG, these are usually outlined by air within the nasopharynx and oropharynx.

Bony structures, the radiographic anatomy of the bony structures has been divided into to the mandible, maxilla and temporal bone.

(journalofosseointegration.eu)

A standard OPG will depict the whole mandible. Also, check the inferior dental canal is well shown.

The dental panoramic image suffers from important distortions because a vertical zoom and a horizontal zoom both vary differently along the image. The vertical and horizontal zooms are determined by the relative position of the recorded element versus film and generator. Features closer to the generator receive more

vertical zoom. The horizontal zoom is also dependent on the relative position of the element to the focal path. Features inside the focal path arch receive more horizontal zoom and are blurred; features outside receive less horizontal zoom and are blurred.

The result is an image showing sharply the section along the mandible arch, and blurred elsewhere. For example, the more radio-opaque anatomical region, the cervical vertebrae (neck), shows as a wide and blurred vertical pillar overlapping the front teeth. The path where the anatomical elements are recorded sharply is called "focal path"

1-2-1 Reasons for OPG requests

Dental Disease

- Caries - appear as different shaped areas of radiolucency in the crowns or necks of teeth.
- Peridontoiditis - when inflammation extends into the underlying alveolar bone and there is a loss of attachment.
- Periodontal Abscess - Radiolucent area surrounding the roots of the teeth.

Extraction of teeth

- OPG shows angulation, shape of roots, size and shape of crown, effect on other teeth.

Teeth Abnormalities

- e.g. Developmental, to show size, number, shape and position.(e.g. wisdom teeth)

Trauma to teeth and facial skeleton

- Mandible fractures are often bilateral.
- Panoramic view of mandible to view the fracture.
- Determine site and direction of fracture lines.
- Relationship of teeth to fracture lines.
- Alignment of bone fragments after healing.
- Evidence of infection or other complications post intervention.
- Follow up to assess healing.(e.g. wisdom teeth)

Transplant workup

- To look for evidence of any underlying dental disease (eg. abscess)
- Patients on steroids after a transplant are immunosuppressed and the mouth is a common site of infection. (wikiradiography.com)

1-3 Problems:

It is expected that the orthopantomography (OPG) is less used for reaching diagnosis of some oral cavity diseases due to less experience of doctors dentistry department ,there for this inappropriate use can lead to a delayed incorrect diagnosis , more work for the personnel involved and increase the hospital cost

1-4 Objectives

1-4-1 General objective:

To update information on the present status of oral health care delivered at Khartoum including physical facilities, human resources, and dental health professionals.

1-4-2 Specific Objectives:

To evaluate the presence of caries

To evaluate infection of the root

To evaluate missing teeth

To find out if there is any correlation between age , site , of disease tribe and what the patient complain of

1-5 Significant of study:

Evaluate the usefulness of OPG examination in the diagnosis of diseases of the mouth.

Knowledge of food habits for optimal oral health.

Evaluation of methods of clean teeth and gums.

Educate pregnant women about the effects of pregnancy on the health of their mouths.

2-1 Oral anatomy

Oral Cavity, or Buccal Cavity, in human anatomy, orifice through which food and air enter the body. The mouth opens to the outside at the lips and empties into the throat at the rear; its boundaries are defined by the lips, cheeks, hard and soft palates, and glottis. It is divided into two sections: the vestibule, the area between

the cheeks and the teeth, and the oral cavity proper. The latter section is mostly filled by the tongue, a large muscle firmly anchored to the floor of the mouth by the frenulum linguae. In addition to its primary role in the intake and initial digestion of food, the mouth and its structures are essential in humans to the formation of speech.

The chief structures of the mouth are the teeth, which tear and grind ingested food into small pieces that are suitable for digestion; the tongue, which positions and mixes food and also carries sensory receptors for taste; and the palate, which separates the mouth from the nasal cavity, allowing separate passages for air and for food. All these structures, along with the lips, are involved in the formation of speech sounds by modifying the passage of air through the mouth.

Anatomically oral consist of:

- 1- Ramus and angle of mandible
 - 2- Coronoid process
 - 3- Mandibular notch
 - 4- Condyle of mandible
 - 5- Alveolar ridge
 - 6- Symphysis menti
 - 7- Maxillary sinuses
 - 8- nasal fossae and 16 upper and 16 lower teeth (wikiradiography.com , basic anatomy)
- as shown in the figures below

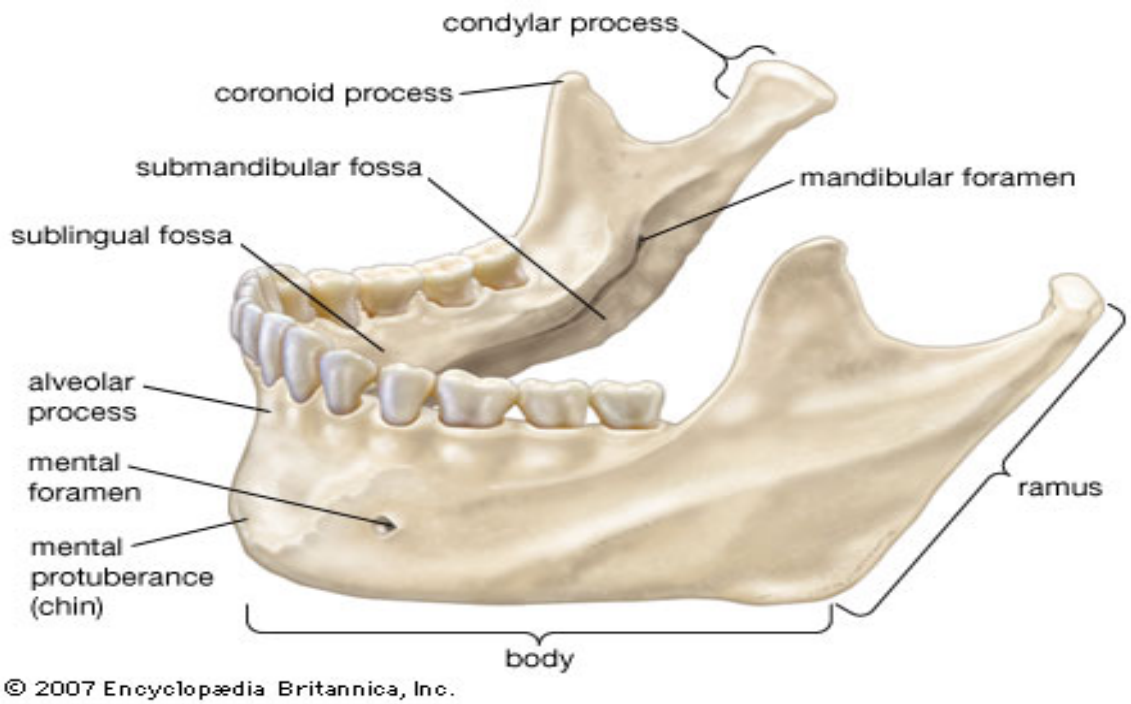


Figure 2.1 oral anatomy (<http://what-when-how.com>)

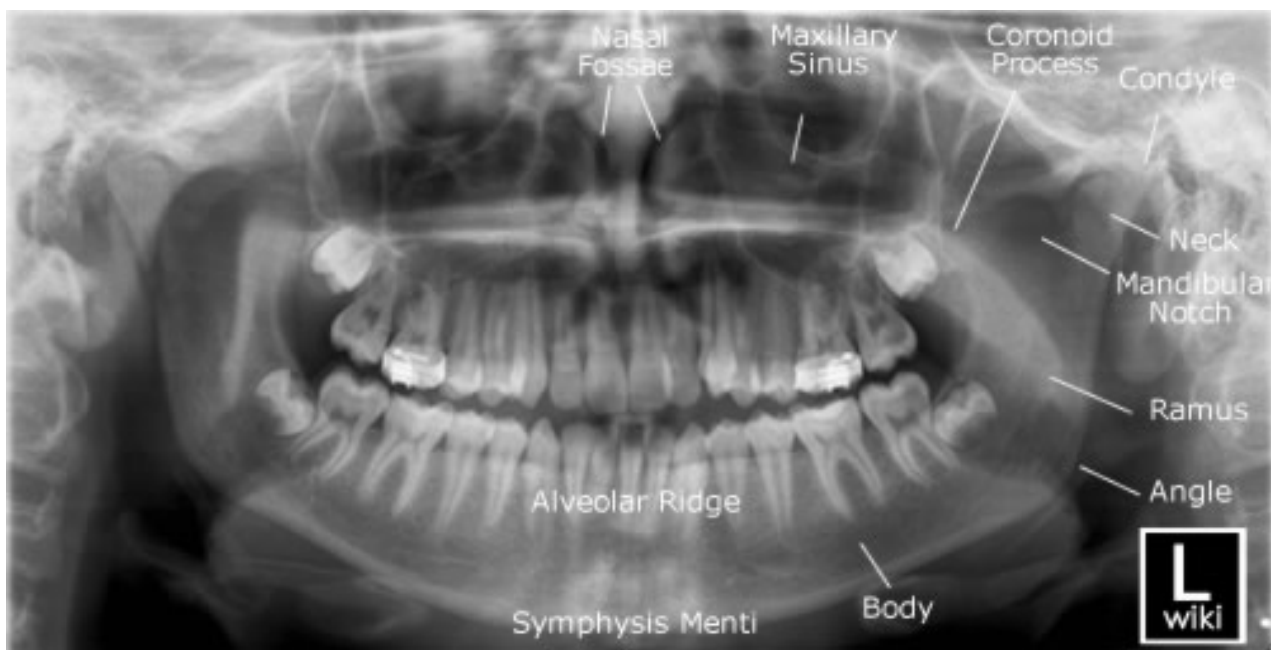


figure 2.2 O.P.G image oral anatomy (wikiradiography.com)

There are two types of teeth, including:

- Dental preliminary (deciduous)
- Dental secondary (permanent)

A tooth is made up of three elements:

- Water
- Organic materials
- Inorganic materials
- Elements

2-1-1 Primary (deciduous)

Consist of 20 teeth, Begin to form during the first trimester of pregnancy, Typically begin erupting around 6 months ,Most children have a complete primary dentition by 3 years of age.

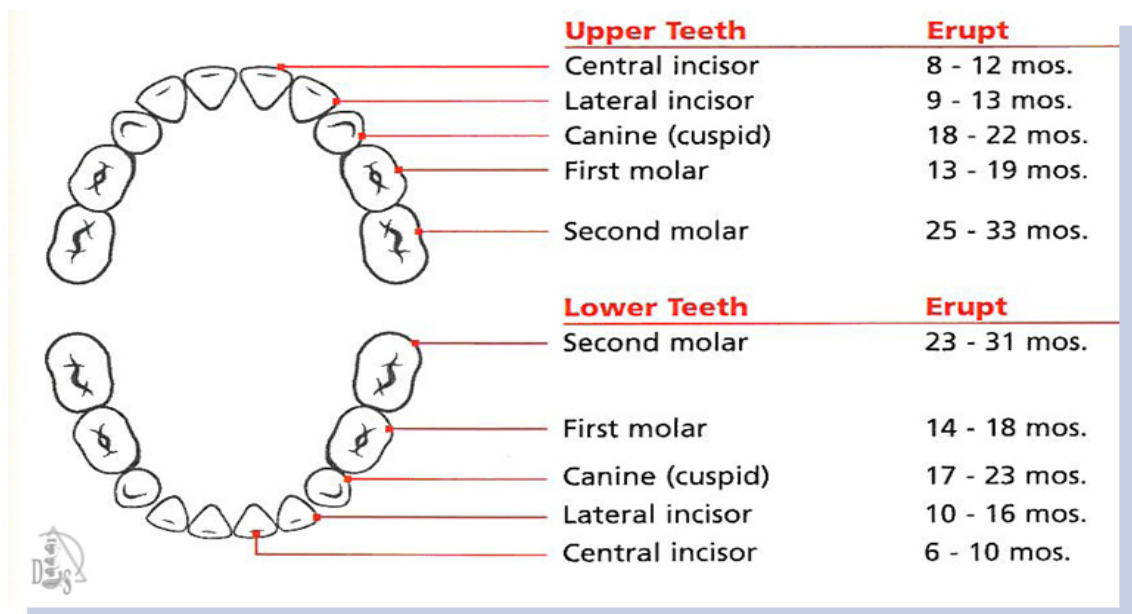


Figure 2.3 Deciduous Teeth(what-when-how.com)

2-1-2 Secondary teeth (permanent)

Consist of 32 teeth in most cases , begin to erupt around 6 years of age ,most permanent teeth have erupted by age 12 , third molars (wisdom teeth) are the exception; often do not appear until late teens or early 20s

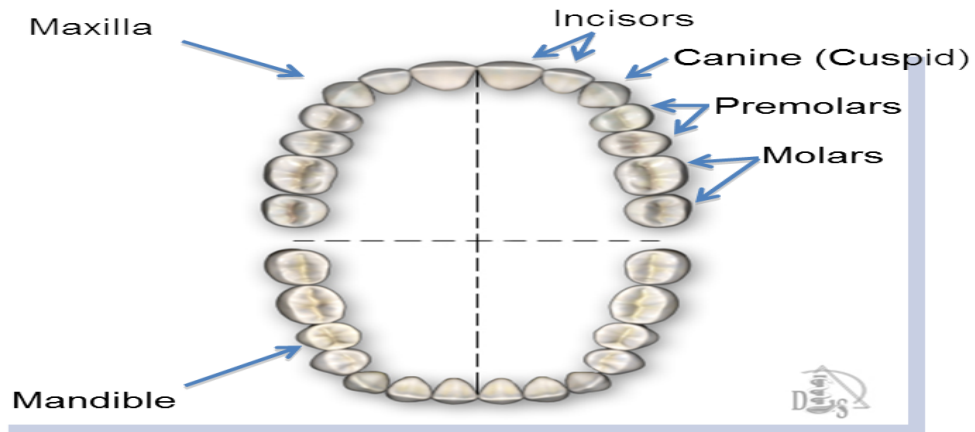


figure2.4 Secondary teeth(what-when-how.com)

2-1-3Classification teeth

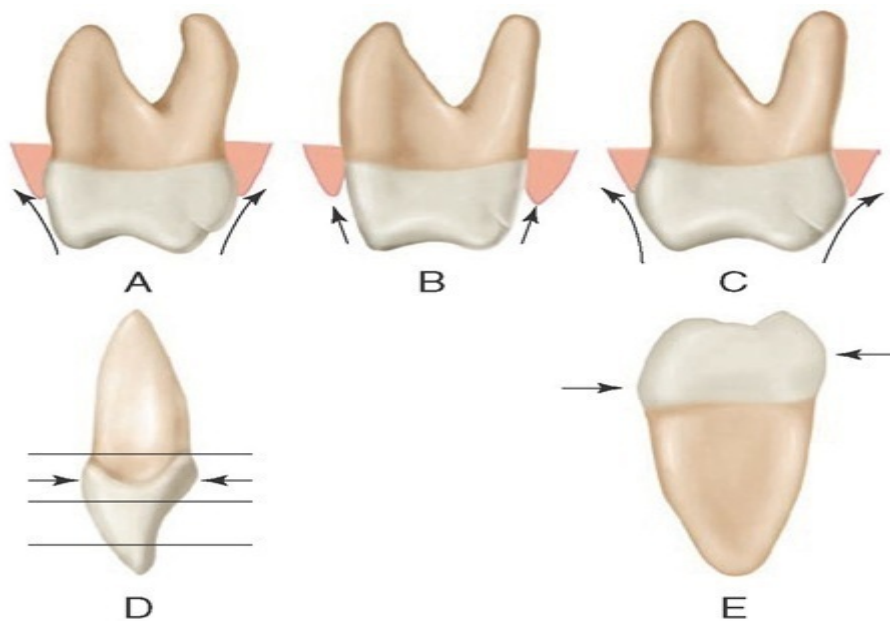


Figure2.5 Classification teeth (what-when-how.com)

-Incisors

Incisors function as cutting or shearing instruments for food.

-Canines

Canines possess the longest roots of all teeth and are located at the corners of the dental arch. . (Wheeler's Dental Anatomy, Physiology, and Occlusion. 8th edition)

-Premolars

Premolars act like the canines in the tearing of food and are similar to molars in the grinding of food.. (Wheeler's Dental Anatomy, Physiology, and Occlusion. 8th edition)

-Molars

Molars are located nearest the temporomandibular joint (TMJ), which serves as the fulcrum during function. (Wheeler's Dental Anatomy, Physiology, and Occlusion. 8th edition)

-Apical, Labial ,Lingual ,Distal , Mesial , Incisal

-Apical:

Pertaining to the apex or root of the tooth

-Labial:

Pertaining to the lip; describes the front surface of anterior teeth

-Lingual:

Pertaining to the tongue; describes the back (interior) surface of all teeth

-Distal:

The surface of the tooth that is away from the median line

-Mesial:

The surface of the tooth that is toward the median line

Enamel (hard tissue)

- Dentin (hard tissue)
- Odontoblast Layer
- Pulp Chamber (soft tissue)
- Gingiva (soft tissue)
- Periodontal Ligament (soft tissue)

- Cementum (hard tissue)
- Alveolar Bone (hard tissue)
- Pulp Canals
- Apical Foramen.(Wheeler's Dental Anatomy, Physiology, and Occlusion. 8th edition)

2-1-4The Dental Tissues:

- Anatomic Crown
- Anatomic Root
- Pulp Chamber

2-1-5The 3 parts of a tooth:

The anatomic crown is the portion of the tooth covered by enamel.

The anatomic root is the lower two thirds of a tooth.

The pulp chamber houses the dental pulp, an organ of myelinated and unmyelinated nerves, arteries, veins, lymph channels, connective tissue cells, and various other cells.(Wheeler's Dental Anatomy, Physiology, and Occlusion. 8th edition)

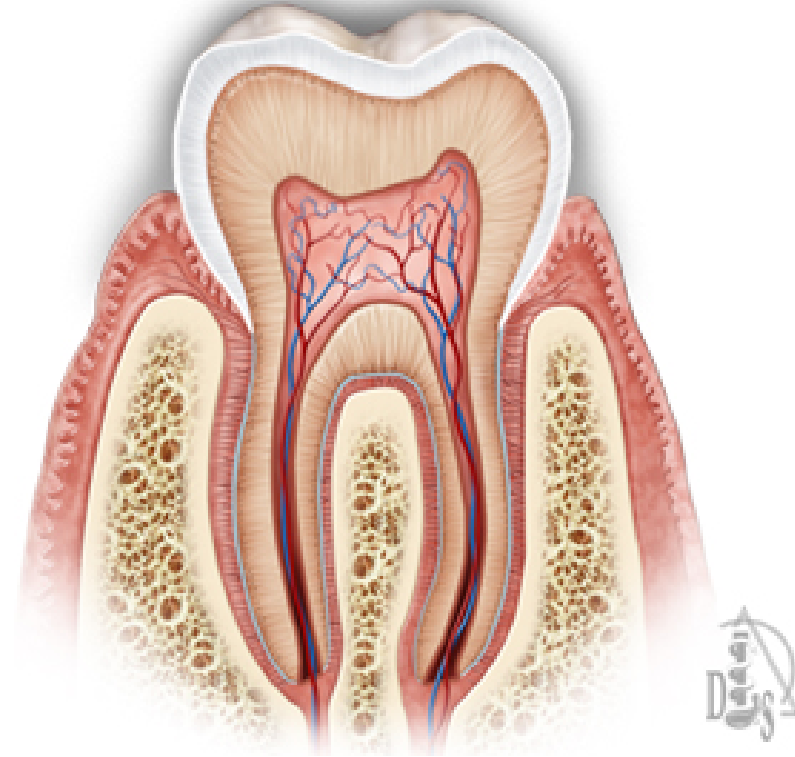


figure2.6 teeth anatomy(<http://www.drlarryakindds.com/dental-care/oral-anatomy>)

2-1-6The 4 main dental tissues:

- Enamel
- Dentin
- Cementum
- Dental Pulp

2-1-7Structure:

- Highly calcified and hardest tissue in the body
- Crystalline in nature
- Enamel rods
- Insensitive no nerves
- Acid-solublewill demineralize at a pH of 5.5 and lower
- Cannot be renewed
- Darkens with age as enamel is lost

2-1-8 Enamel can be lost by:

- Physical mechanism
- Abrasion (mechanical wear)
- Attrition (tooth-to-tooth contact)

Abfraction (lesions)

- Chemical dissolution
- Erosion by extrinsic acids (from diet)
- Erosion by intrinsic acids (from the oral cavity/digestive tract)

Multifactorial etiology

Combination of physical and chemical factors

2-2physiology

2-2-1 introduction

food consist mostly of complex substance . before they can be absorbed into the body, these substance have to break down or modified to simpler forms .It is the function of the GIT to secrete enzymes which break down the complex food materials into simple form; a process referred to as digestion and then conveys the end product to blood stream.

While the food is being processed, it needs to be mixed and propelled along the tract. The first level of GIT is the mouth.(Wheeler's Dental Anatomy, Physiology, and Occlusion. 8th edition)

2-2-2The function of the oral cavity :

-Intake of the food :

the mechanism which control it, is intrinsic factor.

-Mastication:

solid food is broken down by the process of mastication (chewing) mastication also stimulates the secretion of saliva and helps to mix it with the food particles to produce a bolus which can be then be swallowed . mastication is started voluntary but continues as an involuntary reflex. The contact of the food particles with the teeth and gums induce reflex opening of the jaws followed by the closure , this produce rhythmic closure and opening at about one cycle per second. Considerable force can be applied to crush solid pieces of food; the molars can

exert a force of more than 100 kg .when the bolus is of suitable consistency and size . it will be swallowed. (M.Y.Sukar, et at 2004)

-saliva:

about 1 liter of saliva is produced by day it is hypotonic , with PH range from 6.2 – 7.4 increasing with rate of secretion. The saliva include electrolytes, mucin , the enzyme amylase lingual lipase and glycoproteins.

The function of the saliva :

1-moisting and lubricate food and thus facilitated swallowing .

2-digestive function by its enzymes.

-keeps the oral mucosa , this help speech and movement of the tongue.

-protecting function by its enzyme lysozyme.

- Acting as solving , is important for the taste.

- Buffer which help to neutralize gastric HCL in the empty stomach.

vehicle of secretion of substance like lead, mercury fluoride and iodide.(M. Y.sukar,H.A.Elmunshid,M.S.M.Ardawi2004).

Deglutition (swallowing) is buccal stage which processing the oral cavity is voluntary process; pieces of food are collecting by the tongue into the bolus. The tip of the tongue is pressed against the hard palate , thus creating a chamber between the tongue and the palate. Contraction of the muscle causes the tongue to move upward and backward. It propels the bolus towards the pharynx .the soft palate rises and the posterior phalangeal wall moves forward as a result of the contraction of the pharynx muscle. The larynx starts to rise, signaling the of the buccal stage.(M.Y.sukar,,et at 2004)

2-3 Pathology

2-3-1 introduction

The specialty oral and maxillofacial pathology is concerned with diagnosis and study of the causes and effects of diseases affecting the oral and maxillofacial region. It is sometimes considered to be a specialty of dentistry and pathology. Sometimes the term head and neck pathology is used instead, but this might imply that the pathologist deals with otorhinolaryngology disorders (e.y.e. ear, nose and throat) in addition to maxillofacial disorders. In this role there is some overlap between the expertise of head and neck . (Essentials of Oral Pathology -3rd edition)

Terminology Used to Describe Oral Lesions

Lesion is a broad term for abnormal tissues in the oral cavity that includes wounds, sores, and any other tissue damage caused by injury or disease.

Determining the type of lesion in a disease is one of the earliest steps in formulating a differential diagnosis.

Types of lesions of the oral mucosa are classified as to whether they:

- Extend below or extend above the surface.
- Are flat or even with the surface.

Lesions Extending Below the Surface :

Ulcer: A defect or break in continuity of the mucosa that creates a punched-out area similar to a crater.

Erosion of the soft tissue: A shallow defect in the mucosa caused by mechanical trauma.

Abscess: A localized collection of pus in a circumscribed area.

Cyst: A closed sac or pouch that is lined with epithelium and contains fluid or semisolid material.

Lesions Extending Above the Surface:

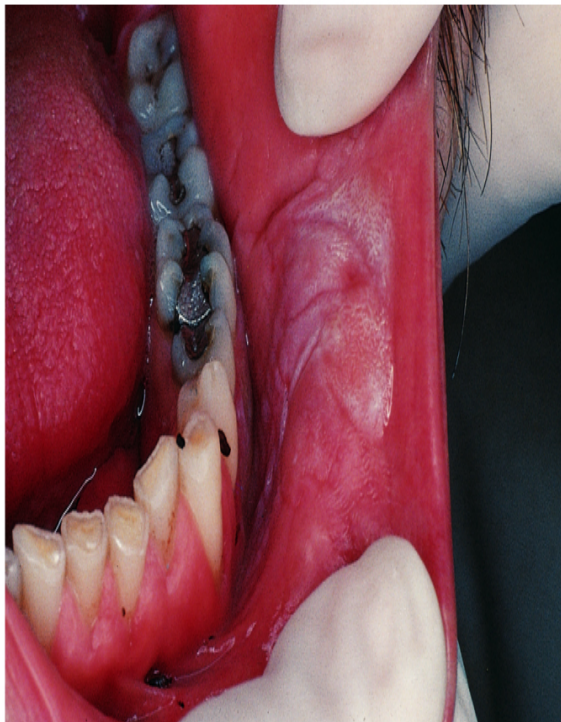-Blisters: Also known as vesicles, lesions filled with a watery fluid.

- Pustule:** Similar in appearance to a blister, but it contains pus.
- Hematoma:** Also similar to a blister, but it contains blood.
- Plaque:** Any patch or flat area that is slightly raised from the surface.

Diseases of the Oral Soft Tissues:

Leukoplakia

Leukoplakia means white patch , Lesions vary in appearance and texture from a fine white transparency to a heavy, thick, warty plaque, the cause is unknown but is commonly linked to chronic irritation or trauma, leukoplakia very often precedes the development of a malignant tumor.



Copyright © 2003, Elsevier Science (USA). All rights reserved.

figure2.7Leukoplakia(brightonimplantclinic.co.uk)

Lichen Planus:

A benign, chronic disease affecting the skin and oral mucosa , many factors have been implicated in lichen plan us , however, the cause remains unknown ,on the oral mucosa, the patchy white lesions have a characteristic pattern of circles and interconnecting lines called **Wickham's striae**.

(Essentials of Oral Pathology -3rd edition)

2-3-2 Congenital

- Malocclusion
- Cleft lip and palate
- Macroglossia
- Ankyloglossia
- Stafne defect
- Torus palatinus
- Torus mandibularis

2-3-3 bacterial

(Plaque-induced) gingivitis

A common periodontal (gum) disease is Gingivitis. Periodontal refers to the area the infection affects, which include the teeth, gums, and tissues surrounding the teeth. Bacteria cause inflammation of the gums which become red, swollen and can bleed easily. The bacteria along with mucus form a sticky colorless substance called plaque which harbours the bacteria. Plaque that is not removed by brushing and flossing hardens to form tartar that brushing doesn't clean. Smoking is a major risk factor. Treatment of gingivitis is dependent on how severe and how far the disease has progressed. If the disease is not too severe it is possible to treat it with chlorhexidine rinse and brushing with fluoride toothpaste to kill the bacteria and remove the plaque, but once the infection has progressed antibiotics may be needed to kill the bacteria. (Essentials of Oral Pathology -3rd edition)

2-3-4 Fungal

Pseudomembranous candidiasis of the posterior mouth and oropharynx Oral candidiasis is by far the most common fungal infection that occurs in the mouth. It usually occurs in immune compromised individuals. Individuals who have undergone a 0commonly develop candida of the mouth and oral cavity. Other risk factors are dentures and tongue piercing. The typical signs are a white patch that may be associated with burning, soreness, irritation or a white cheesy like appearance. (Essentials of Oral Pathology -3rd edition).

2-3-5 teeth Impact and caries

Impact:

An impacted tooth is one that fails to erupt into the dental arch within the specific time. Because impacted teeth do not erupt, they are retained throughout the individual's lifetime unless extracted or exposed surgically. Teeth may become impacted because of adjacent teeth, dense overlying bone, excessive soft tissue or a genetic abnormality. Most often, the cause of impaction is inadequate arch length and space in which to erupt. That is the total length of the alveolar arch is smaller than the tooth arch (the combined mesiodistal width of each tooth). The third molars are frequently impacted because they are the last teeth to erupt in the oral cavity. Mandibular third molars are more commonly impacted than their maxillary counterparts. As a general rule, all impacted teeth must be removed unless otherwise contraindicated (Peterson's Principles of Oral and Maxillofacial Surgery)

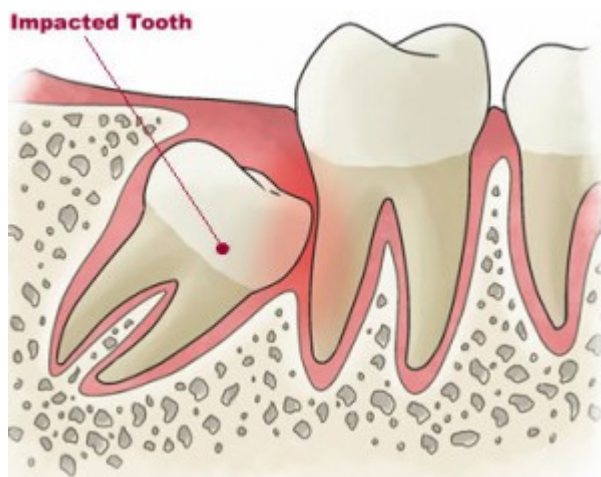


figure2.8.Impacted tooth (www.medexpressrx.com)

Caries:

Dental caries, also known as tooth decay or a cavity, is an infection, bacterial in origin, that causes demineralization and destruction of the hard tissues of the teeth (enamel, dentin and cementum). It is a result of the production of acid by bacterial fermentation of food debris accumulated on the tooth surface. If demineralization exceeds saliva and other remineralization factors such as from calcium and fluoridated toothpastes, these once hard tissues progressively break down, producing dental caries (cavities or carious lesions, that is, holes in the teeth). Today, caries remains one of the most common diseases throughout the world. Cariology is the study of dental caries. (Essentials of Oral Pathology -3rd edition)

Depending on the extent of tooth destruction, various treatments can be used to restore teeth to proper form, function, and aesthetics, but there is no known method to regenerate large amounts of tooth structure. Instead, dental health organizations advocate preventive and prophylactic measures, such as regular oral hygiene and dietary modifications, to avoid dental caries. (New York State Dental Journal 74).

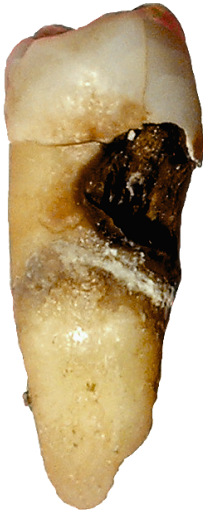

figure 2.9caries (www.jidonline.com)

Cariesclassification

Caries can be classified by location, etiology, rate of progression, and affected hard tissues. These forms of classification can be used to characterize a particular case of tooth decay in order to more accurately represent the condition to others and also indicate the severity of tooth destruction. In some instances, caries are described in other ways that might indicate the cause :

- I - pit and fissure caries (anterior or posterior teeth)
- II - approximal surfaces of posterior teeth
- III - approximal surfaces of anterior teeth without incisal edge involvement
- IV - approximal surfaces of anterior teeth with incisal edge involvement
- V - gingival/cervical surfaces on the lingual or facial aspect (anterior or posterior)
- VI - incisal edge of anterior teeth or cusp heights of posterior teeth (sonis, Stephen T. (2003). Dental Secrets (3rd ed.))

The signs and symptoms of cavities

the signs and symptoms of cavities vary, depending on their extent and location. When a cavity is just beginning, you may not have any symptoms at all. As the decay gets larger, it may cause signs and symptoms such as:

- Toothache.
- Tooth sensitivity.
- Mild to sharp pain when eating or drinking something sweet, hot or cold.
- Visible holes or pits in your teeth.
- Brown, black or white staining on any surface of a tooth.
- Pain when you bite down.(www.mayoclinic.org/diseases-conditions/cavities)

Risk factors

Everyone who has teeth is at risk of getting cavities, but the following factors can increase risk:

- Tooth location:** Decay most often occurs in your back teeth (molars and premolars). These teeth have lots of grooves, pits and crannies that can collect food particles. As a result, they're harder to keep clean than your smoother, easy-to-reach front teeth. Plaque can build and bacteria can thrive between your back teeth, producing the acid that destroys tooth enamel.(Biology of the Human Dentition)
- Certain foods and drinks:** Foods that cling to your teeth for a long time such as milk, ice cream, honey, sugar, soda, dried fruit, cake, cookies, hard candy, breath mints, dry cereal, and chips are more likely to cause decay than foods that are easily washed away by saliva. (Biology of the Human Dentition)
- Frequent snacking or sipping:** When you steadily snack or sip sodas, you give mouth bacteria more fuel to produce acids that attack your teeth and wear them down. And sipping soda or other acidic drinks throughout the day helps create a continual acid bath over your teeth. (mayoclinic.org/diseases-conditions/cavities)
- Bedtime infant feeding:** Parents are encouraged not to give babies bedtime bottles filled with milk, formula, juice or other sugar-containing liquids. These beverages will remain on teeth for hours while your baby sleeps, providing food for decay-causing bacteria. This damage is often called baby bottle tooth decay. Letting a toddler who's transitioning from a bottle wander around drinking from a Sippy cup can cause similar damage.(www.mayoclinic.org/diseases-conditions/cavities)
- Inadequate brushing:** If you don't clean your teeth soon after eating and drinking, plaque forms quickly and the first stages of decay can begin.
- Not getting enough fluoride:** Fluoride, a naturally occurring mineral, helps prevent cavities and can even reverse the earliest stages of tooth damage. Because of its benefits for teeth, fluoride is added to many public water supplies. It's also a common ingredient in toothpaste and mouth rinses. Bottled water may not contain fluoride.(Biology of the Human Dentition)
- Younger or older age:** In the United States, cavities are common in children and teenagers. Older adults also are at higher risk, as more of us keep our teeth as we age. Over time, teeth can wear down and gums may recede, making teeth more vulnerable to root decay. Older adults also may use more medications that reduce saliva flow, increasing the risk of tooth decay.(Biology of the Human Dentition)

-Dry mouth: Dry mouth is caused by a lack of saliva, which helps prevent tooth decay by washing away food and plaque from your teeth. Substances found in saliva also help counter the acid produced by bacteria and can even help repair early tooth decay. Certain medications, some medical conditions, radiation to your head or neck, or certain chemotherapy drugs can increase your risk of cavities by reducing saliva production. ("Biology of the Human Dentition)

-Worn fillings or dental devices: Over the years, dental fillings can weaken, begin to break down or develop rough edges. This allows plaque to build up more easily and makes it harder to remove. Dental devices can also stop fitting well, allowing decay to begin underneath them. ("Biology of the Human Dentition)

-Eating disorders: Anorexia and bulimia can lead to significant tooth erosion and cavities. Stomach acid from repeated vomiting (purging) washes over the teeth and begins dissolving the enamel. Eating disorders can also interfere with saliva production. (The role of sugar in the etiology of dental caries)

-Heartburn: Heartburn or gastroesophageal reflux disease (GERD) can cause stomach acid to flow into your mouth (reflux), wearing away the enamel of your teeth and causing significant tooth damage. Your dentist may recommend that you consult your doctor to see if gastric reflux is the cause of your enamel loss. (The role of sugar in the etiology of dental caries)

Caries diagnosing methods :

- Clinical examination.
- Nutritional analysis.
- Salivary analysis.
- Radiographic assessment.
- Patient history.

O.PG images for caries

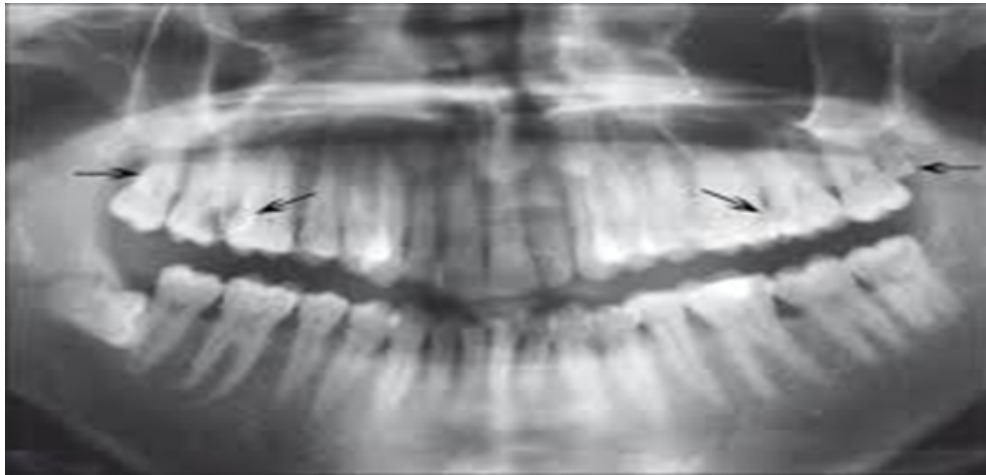


Figure 2.10 .caries(www.medexpressrx.com)

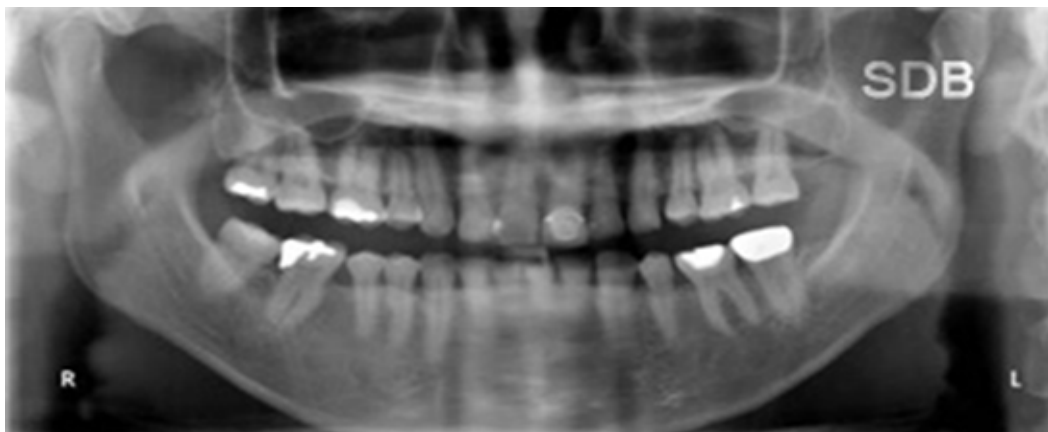


figure2.11caries (www.jidonline.com)

Missing teeth OPG image :

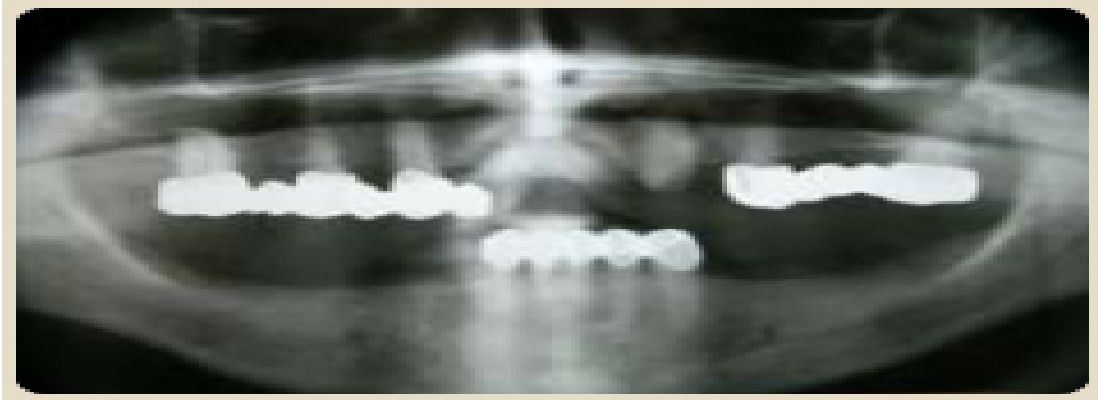

figure2.12 missing teeth (www.dentiimplantclinic.hu)

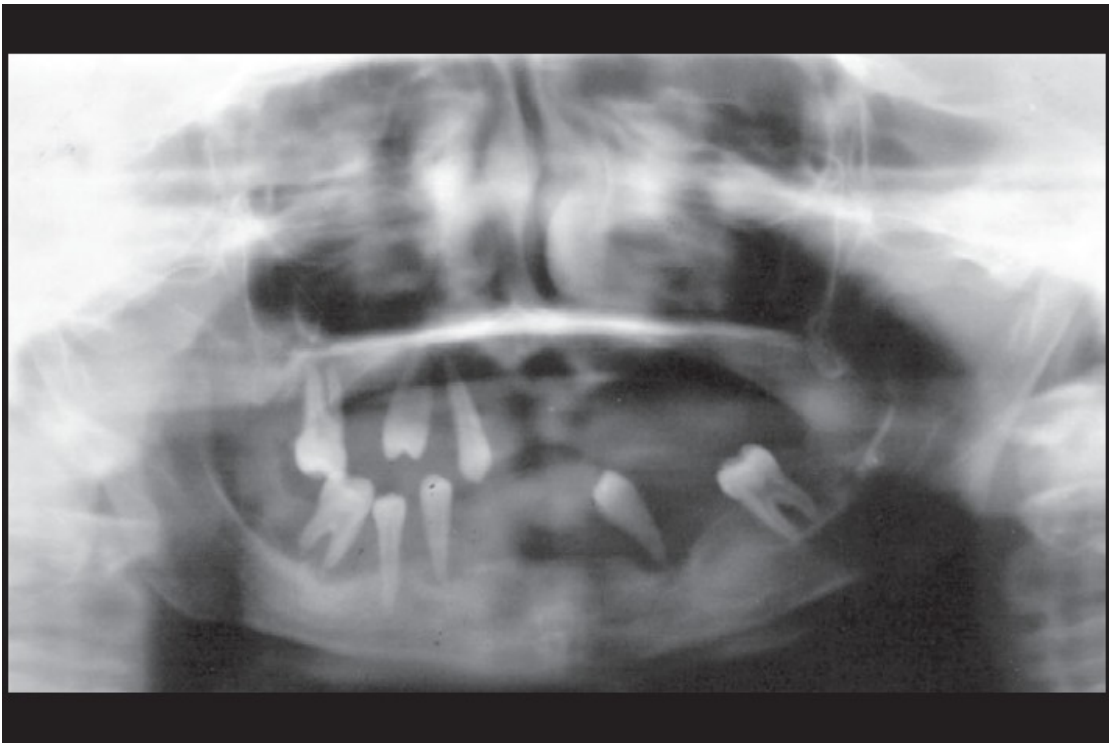


figure 2.13 OPG showing multiple permanent teeth missing with generalized horizontal bone loss in relation to the teeth present giving them a ‘floating-in-air’ appearance (www.ijdr.in/viewimage.asp)

Infection of root in OPG image :

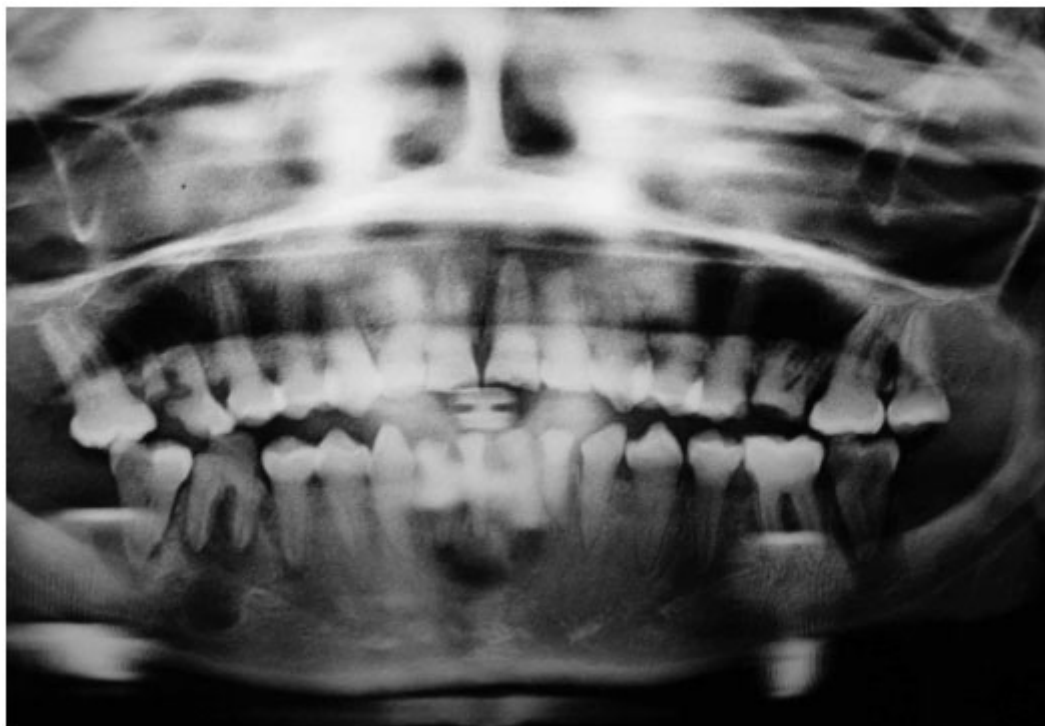

figure2.14 root infection (www.scielo.cl)

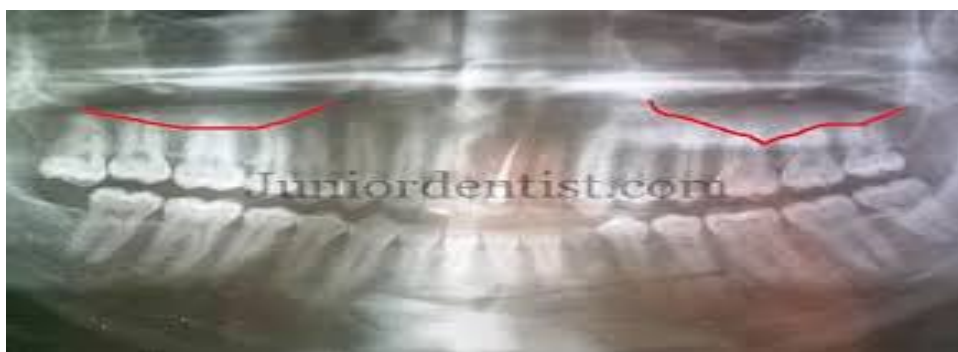

figure2.15(www.juniordentist.com)

2-4The effect of pregnancy on oral health:

During the course of pregnancy, a woman's oral health can undergo significant changes , pregnant women experience gingivitis, pregnancy tumors, and mild to severe gingival enlargement. (According to an article published in the November/December 2010 issue of General Dentistry, the peer-reviewed clinical journal of the Academy of General Dentistry (AGD)).

Clinically, pregnancy gingivitis is no different than non-pregnancy gingivitis. Patients will experience redness and inflammation of the gums, bleeding on probing, and increased tooth mobility. Between 30 and 100 percent of pregnant women will experience varying degrees of gingivitis.

Although bleeding and inflammation of the gums has been noted in all trimesters of pregnancy, it typically disappears three to six months after delivery, provided that proper oral hygiene measures are implemented. (DDS, MS, lead author of the article)

Although bleeding and inflammation of the gums has been noted in all trimesters of pregnancy, it typically disappears three to six months after delivery, provided that proper oral hygiene measures are implemented," says Crystal L. McIntosh, DDS, MS, lead author of the article. "Good oral hygiene and visits to a dentist can help to alleviate gum inflammation.(.sciencedaily.com/releases/2010)

Pregnancy tumors are reported by 10 percent of pregnant women. These tumors, which are not cancerous, appear as a growth in the mouth and usually disappear after the child is born. They typically are painless and purple or red in color, but they can exhibit spontaneous bleeding.(Oral Health Care for the Pregnant Patient) Gingival enlargement, which is an overgrowth or an increase in the size of the gums, occurs less frequently than gingivitis and pregnancy tumors. In severe cases, the gums can "grow" to cover the teeth completely, pregnancy gingivitis and gingival enlargement are thought to be the result of a heightened response to bacteria in the mouth, so it is extremely important to educate and motivate

patients to maintain good oral hygiene during pregnancy.(materials provided by Academy of General Dentistry)

If proper oral hygiene is not initiated prior to or during pregnancy, conditions such as gingivitis, pregnancy tumors, and gingival enlargement can worsen as the pregnancy progresses. Pregnant women should maintain their regular, semi-annual checkups and consult a dentist if they notice any changes in their oral health.(Oral Health Care for the Pregnant Patient)

2-5 miswak:

The miswak (miswak, siwak, sewak) is a teeth cleaning twig made from the *Salvadorapersica* tree (known as arak in Arabic). A traditional alternative to the modern toothbrush, it has a long, well-documented history and is reputed for its medicinal benefits. It also features prominently in Islamic hygienicaljurisprudence. (en.wikipedia.org/wiki/Miswak)



figure2.15. Miaswak shape (www.islam.tc/Miswaak)

The Natural Nutrients found in miswak is fluorine (2x what is found in toothpastes), silicon, Vitamin C, salvadorine and trimethylamine.(The Effect of *SalvadoraPersica* Extract (Miswak) and Chlorahexidine Gluconate on Human Dentin: A SEM Study (PDF))

The Minerals in this root or twig include potassium, sodium, chloride, sodium bicarbonate and calcium oxides, these ingredients all strengthen the tooth enamel, the bark contains an antibiotic which suppresses the growth of bacteria and the formation of plaque. Research shows that regular use of miswaksignificantly reduces plaque, gingivitis and growth of cariogenic bacteria. It is naturally strengthens and protects the enamel with resins and mild abrasives for whiter teeth and fresher breath. It reduces stains from tobacco products, coffee and teas, the form of the twig makes it easier to get to the hard to reach places for a standard toothbrush. It massages the gums for healthier teeth.(Indigenous multipurpose trees of Tanzania (Food and Agricultural Organization)

2-5-1 A few important benefits of Miswak:

- Kills bacteria that causes gum disease
- Fights plaque effectively.
- Useful and effective for teeth whitening
- Helps reduce tooth decay
- Removes Bad breath and odor from mouth.
- Creates a fragrance in the mouth.
- Effectively cleans between teeth due to its parallel bristles.
- Increases salivation and hence inhibits dry mouth (Xerostomia). (Paraclinical Effects of Miswak Extract on Dental Plaque (PDF))

2-5-2 How To Use Miswak:

To use your miswak stick: Remove the stick from the package and trim or chew the bark off one end of the stick; about a 1/2 inch. Chew on the exposed end until the twig forms bristles. Brush as usual. No toothpaste required. The miswak will freshen the mouth. Every few days (when bristles look like an old broom) cut off the exposed bristles, peel bark and start anew.

(www.miswakstick.com/miswak.html)

OPG images for others oral diseases:

Calcifications

Salivary calculi (arrow)

Tonsoliths

Cervical lymph node
calcification

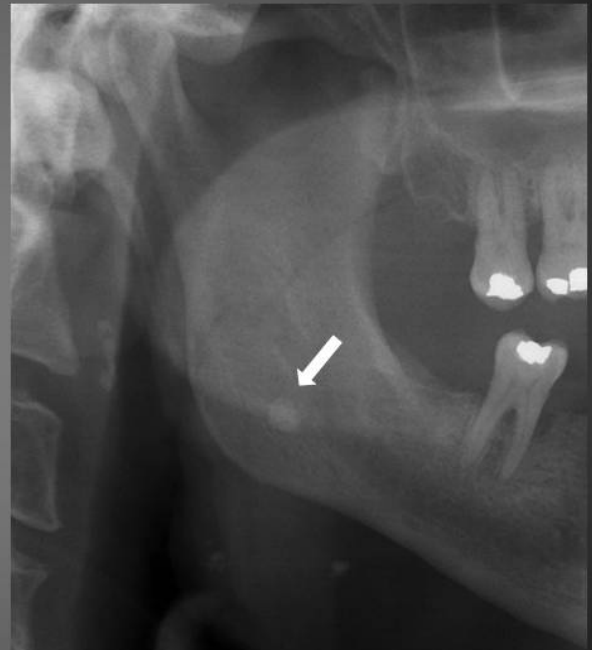
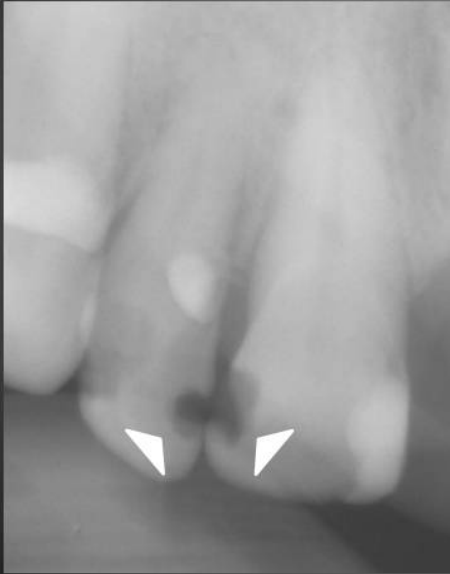
Figure 2.17 oral calcification (OASIS Media Submission Site)

Caries

Interproximal caries
of upper right 1 and upper right 2



Deep caries extending to pulp cavity
of lower right 5

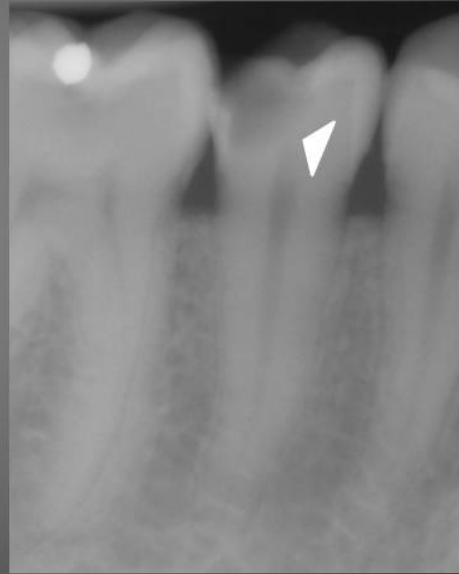

figure2.18teeth caries (OASIS Media Submission Site)

Abscess

Non corticated margin
(arrows)

Associated with carious tooth
and/or dental restoration
(asterisk)

Widened periodontal
ligament space (arrowheads)

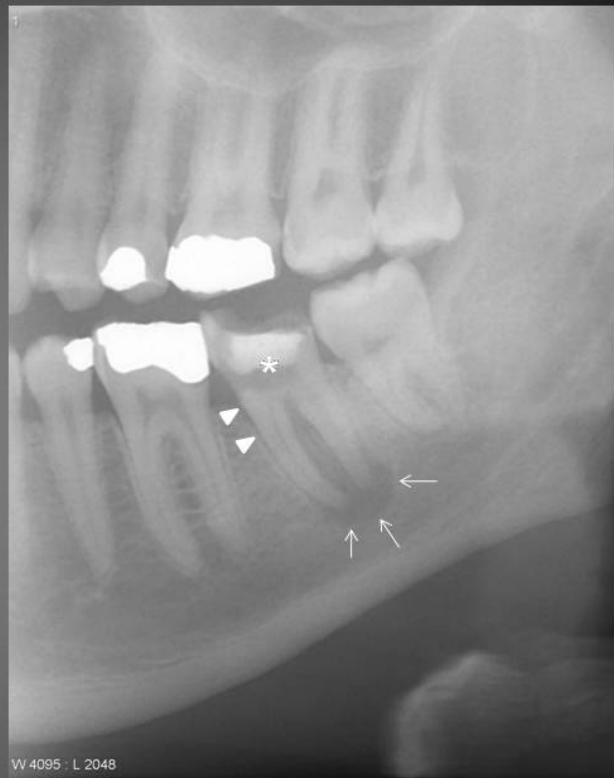

figure2.19oral abscess(OASIS Media Submission Site)

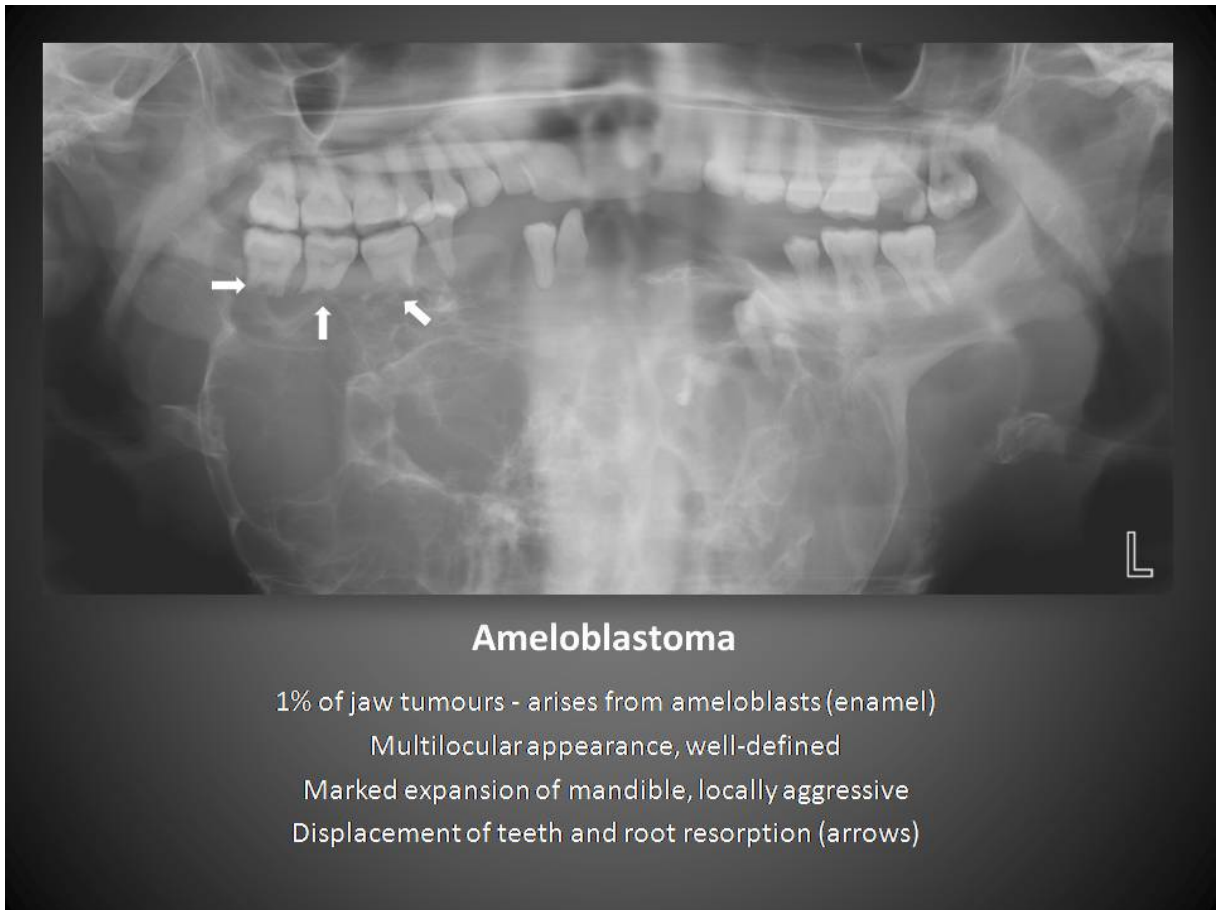


figure2.20.Ameloblastoma (OASIS Media Submission Site)

Periodontal Disease

Periapical radiograph demonstrating:

Moderate to severe loss of alveolar bone (thick arrows)

Crestal irregularities (thin arrows)

Adherent calculus (arrowhead) which is frequently seen with periodontal disease

The dashed line indicates the normal level of the amelocemental junction (ACJ)

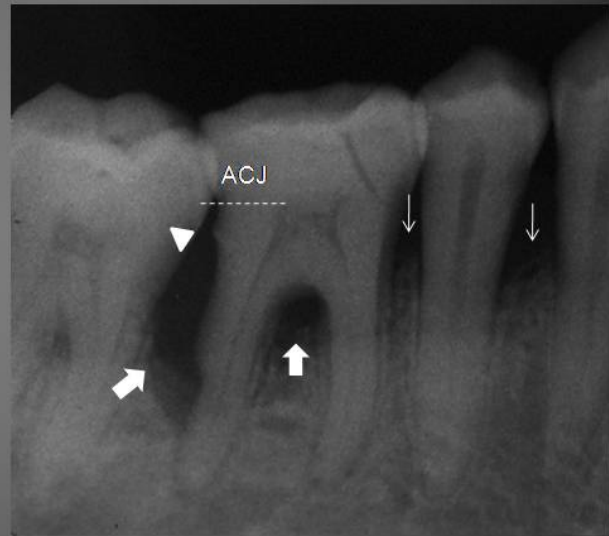


figure2.21periododontal disease(OASIS Media Submission Site)

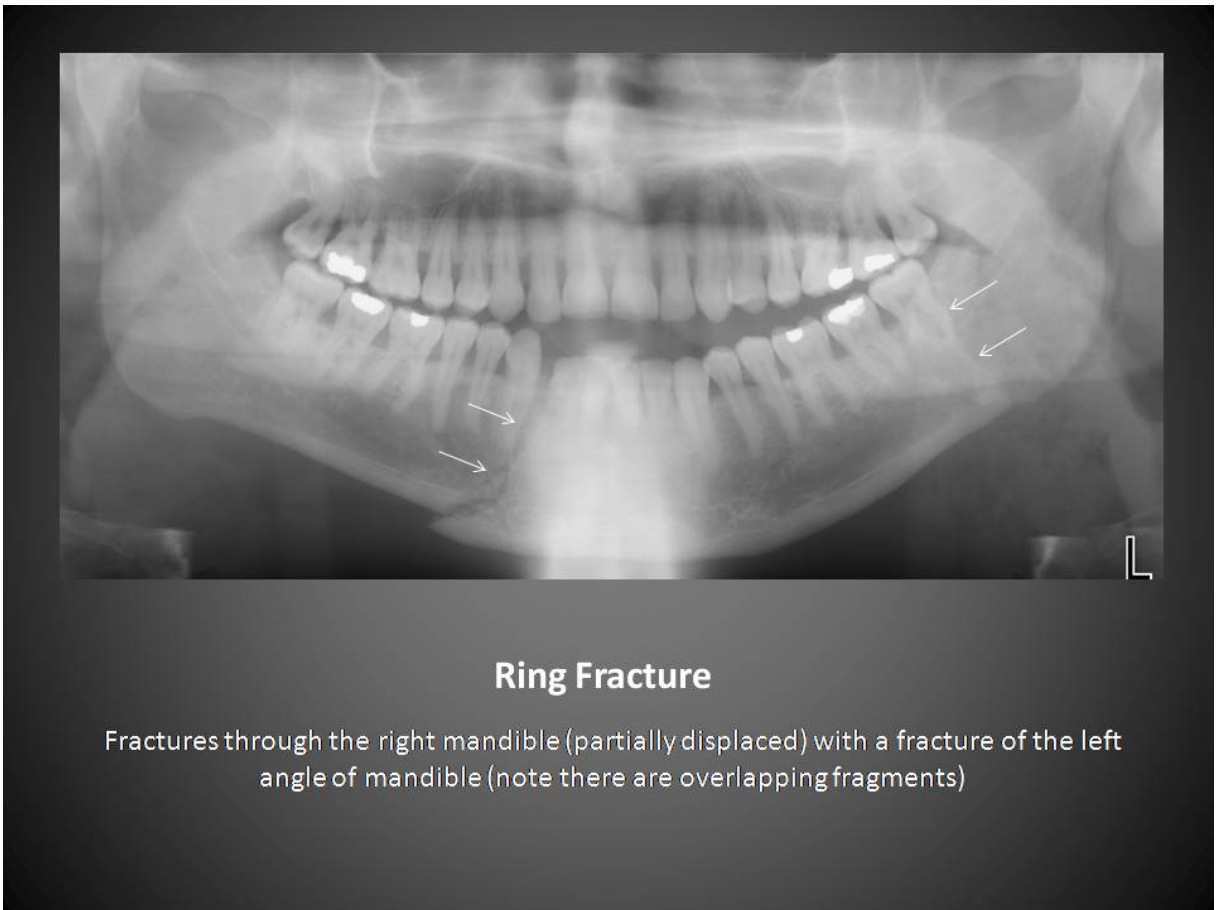
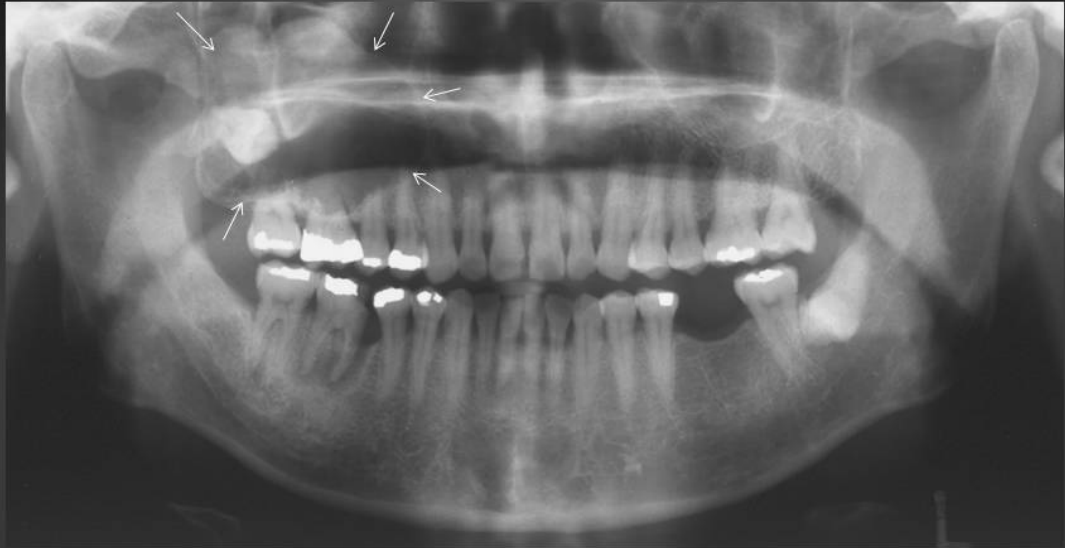

figure2.22 Ring fracture(OASIS Media Submission Site)



Dentigerous Cyst

Most common pericoronal lucency

Associated with the crown of an unerupted tooth (in this instance, the upper right 8)

Has a well-defined, corticated margin (arrows)

Figure 2.23 Dentigerous cyst (OASIS Media Submission Site)

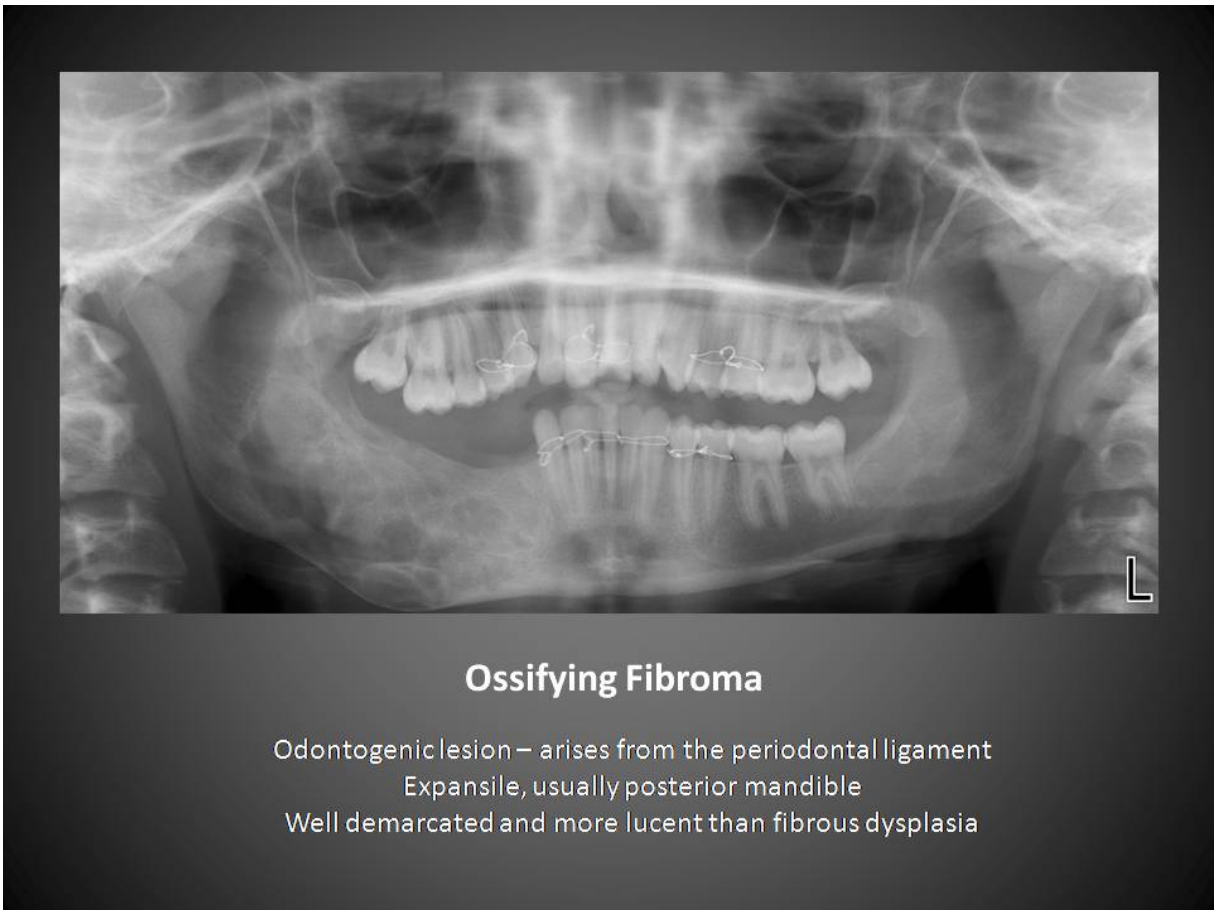


Figure 2.24. ossifying fibroma (OASIS Media Submission Site)

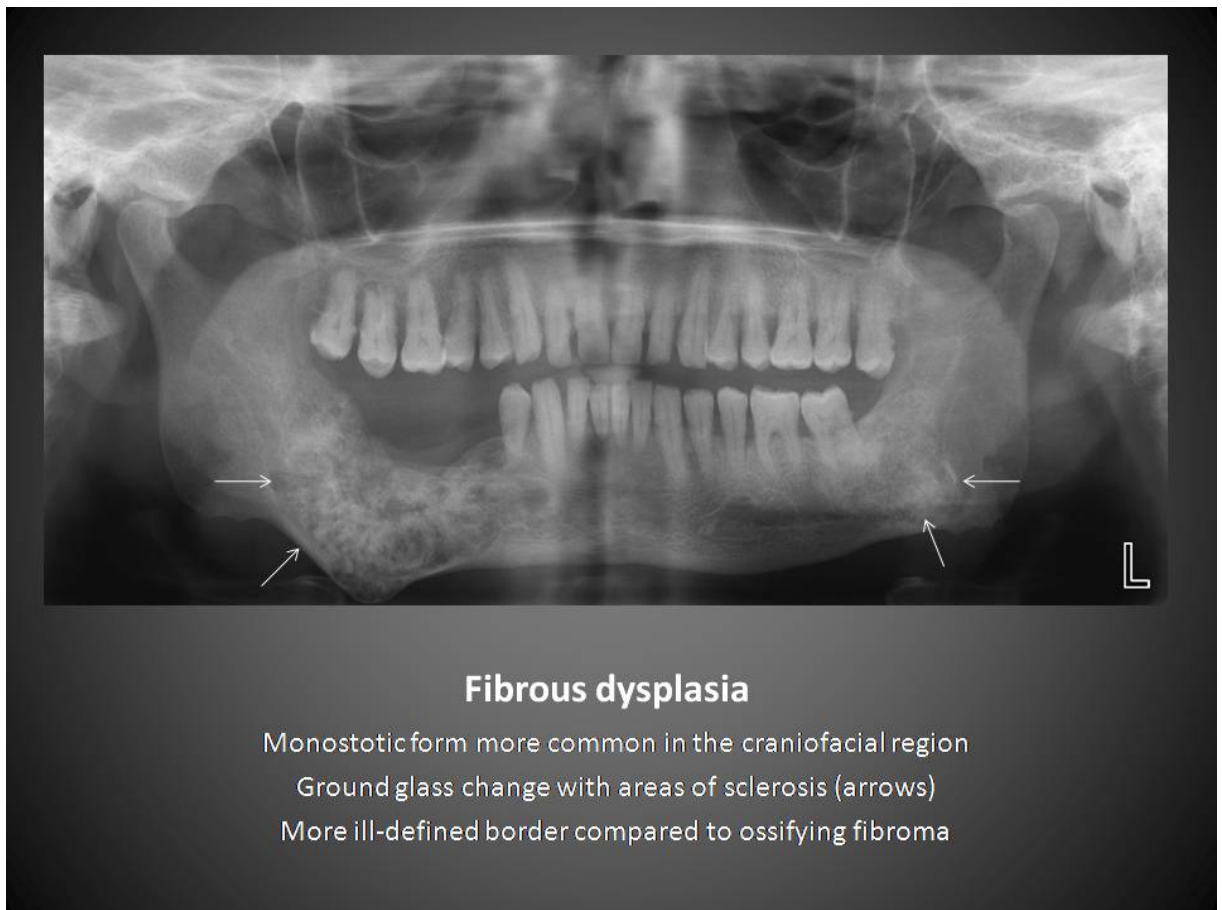


figure2.25 Fibrous dysplasia (OASIS Media Submission Site)

2-6 Previous Studies:

Retrospective study done by (Nazik M Nurelhuda) aimed at evaluating the psychometric properties of done by the Arabic version of Child-Oral health quality, estimating the prevalence, severity and causes of oral impacts on daily performances in 12-year-old public and private school attendees in Khartoum State and to identify socio-demographic and clinical correlates of oral impacts as assessed by the Child- Oral health quality inventory apply to 1109 schoolchildren (Nurelhuda et al.2012)

The result of the study showed Despite the low prevalence of the dental caries pathology (24%), a significant relationship, with an average moderate intensity was found with Oral health quality, focus in this population should be on oral health education, improving knowledge of the prospective treatment opportunities and provision of services.

Retrospectivestudy aim to assess the oral health status and risk factors for dental caries and periodontal disease among Sudanese adults resident in Khartoum State. done by Nazik M Nurelhuda).

The result of the study showed Caries prevalence was high, with 87.7% of teeth examined having untreated decay. Periodontal disease increased in extent and severity with age. For 25.8% of adults, tooth wear was mild; 8.7% had moderate and 1% severe toothwear, multivariate analysis revealed that decay was less prevalent in older age groups but more prevalent in southern tribes and frequent problem based attenders; western tribes and people with dry mouths who presented with less than 18 sound, untreated natural teeth (SUNT), older age groups were more likely to present with tooth wear; increasing age and gender were associated with having periodontal pocketing ≥ 4 mm. (nage .et at 2010)

Retrospective study to assess the status of the present dental and oral health services at Gezira Locality, done by Yousif and Miskeen.et at 2009 , revealed a poor level of oral health services reflected by the presence of a high level of decayed and missing component of DMFT, it is concluded that there is poor provision of dental services in both quantity and quality at Gezira Locality. It recommended that the dental services in Gezira Locality have to be restructured to improve their quantity, quality and efficiency.(Yousif and Miskeenet at 2009).

Retrospective study to conduct a systematic evaluation of miswak as an alternative tool to the modern toothbrush in preventing oral diseases , this involved clinical, microbial and chemical assessment using modern scientific methods ,an adult Sudanese population using miswak or a modern toothbrush ,regularly was examined using clinical and microbial parameters. Freezedried extract of miswak was analyzed for antimicrobial components done by IsmailAbbas et at 2009.The result of the study showed a lower caries experience in the miswak users than in the subjects who used a modern toothbrush. There were no significant differences between the two groups in the periodontal variables examined except for less calculus in the posterior sextants of miswak users .(IamailAbbas.et .at 2009)

A retrospective study was performed using full-mouth periodical and panoramic radiographs of 3491 patients (2146 females and 1345 males) ranging in age from 12 to 25 subjected to Faculty of Dentistry at the University of Ataturk (Erzurum, Turkey .et at 1999).

3-1 Materials

3-1-1 Patient

In this study, we took a sample of 69 patients, (35 were males, 36 were females) their ages were between (5-68), all were examined using O.P.G examination .

3-1-2 Film and cassette :

There are two kinds of film moving mechanisms, one using a sliding flat cassette which holds the film, and another using a rotating cylinder around which the film is wound. There are two standard sizes for dental panoramic films: 30 cm × 12 cm (12" × 5") and 30 cm × 15 cm (12" × 6"). (Clark's positioning in Radiography_12e, [en.wikipedia.org/wiki/Panoramic radiograph](http://en.wikipedia.org/wiki/Panoramic_radiograph))

3-1-2 Orthopantomograph machine:

Linear Tomography

Introducing the Veraviewepocs, advanced radiographic capabilities.

The Veraviewepocs is a dental panoramic x-ray unit with extensive special view capabilities including linear tomographic and cephalometric abilities.

A crystallization of the most advanced technologies with an auto exposure system and the world's only auto focus system utilizing the latest and finest technology.

(www.silomdental.com)

3-2 Methods:

3-2-1 O.P.G Technique

Patient was asked to remove jewelers, eyeglasses, and any metal objects that may obscure the images.

Patient was in erect Position resting chin on bite block , have patient stand in close with spine straight ,The chin rest was adjusted until IOML is aligned parallel with floor, mid sagittal plane was aligned with the vertical center line of the chin rest , The bite block was position between patients front teeth , patients were instructed to place lips together and position tongue on roof of mouth.

3-2-2 direct pre-coded a checklist:

Table contains information about the patients: age, gender and injury of some diseases and some mouth-related habits of the patient's mouth and the number of pregnancies and the time of the last pregnancy .

Oral problems that have been included in the table (caries, infection, and tooth loss). Some mouth-related habits of the patient's mouth (smoking , snuff , cleaning teeth).

3-2-3 Images interpretation

we diagnose diseases mentioned above through the knowledge of how they appear in the images and know the difference between the cases normal and abnormality oral , with reference to the doctor's diagnosis of caries infection was a show in the form of darkening around the roots of the teeth , missing teeth was a lost spaces between teeth with the less of normal number teeth .

3-2-4 Data analysis:

the collected data was analyzed statistically by excel.

Results

This chapter dealt with the data collected from 69 patients with both genders, including males and females all were examined by using OPG films, The oral Health were evaluated by calculating the missing teeth in the upper and lower jaws, the patients traditions were evaluated as using Brush, Miswak, cigarette smoking, Stuff usage /years and according to number of usage. The females history as pregnancy was also been evaluated, the presence of infection or cares were also been evaluated.

Table 4.1 The Classification of the sample according to gender

Gender

		Frequency	Percentage%
Gender	Male	35	50.7
	Female	34	49.3
	Total	69	100.0

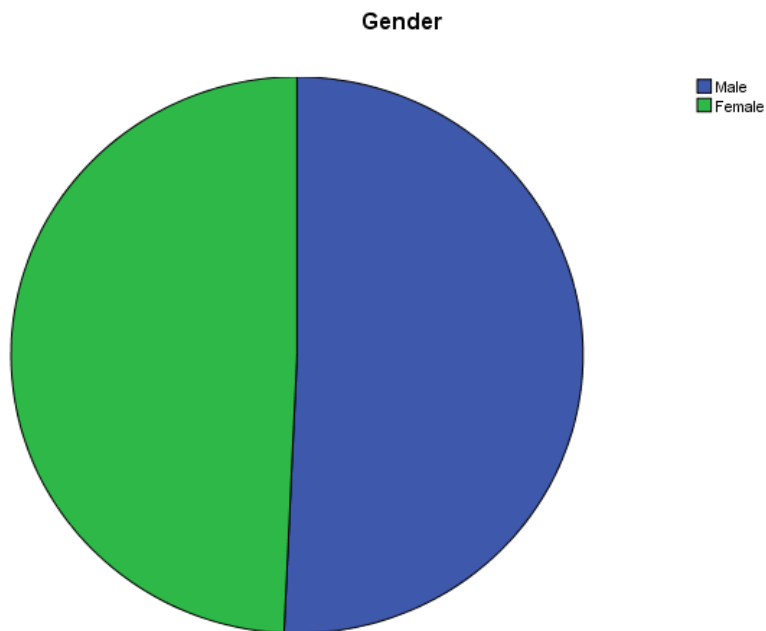


Figure4.1 The Classes according to gender

Table 4.2 The age classes, Frequency and Percentages

Age Classes	Frequency	Percentage%
5-17	8	11.6
18-30	24	34.8
31-42	10	14.5
43-55	16	23.2
56-68	11	15.9
Total	69	100



Figure4.2 Age Classes, Frequency and Percentages

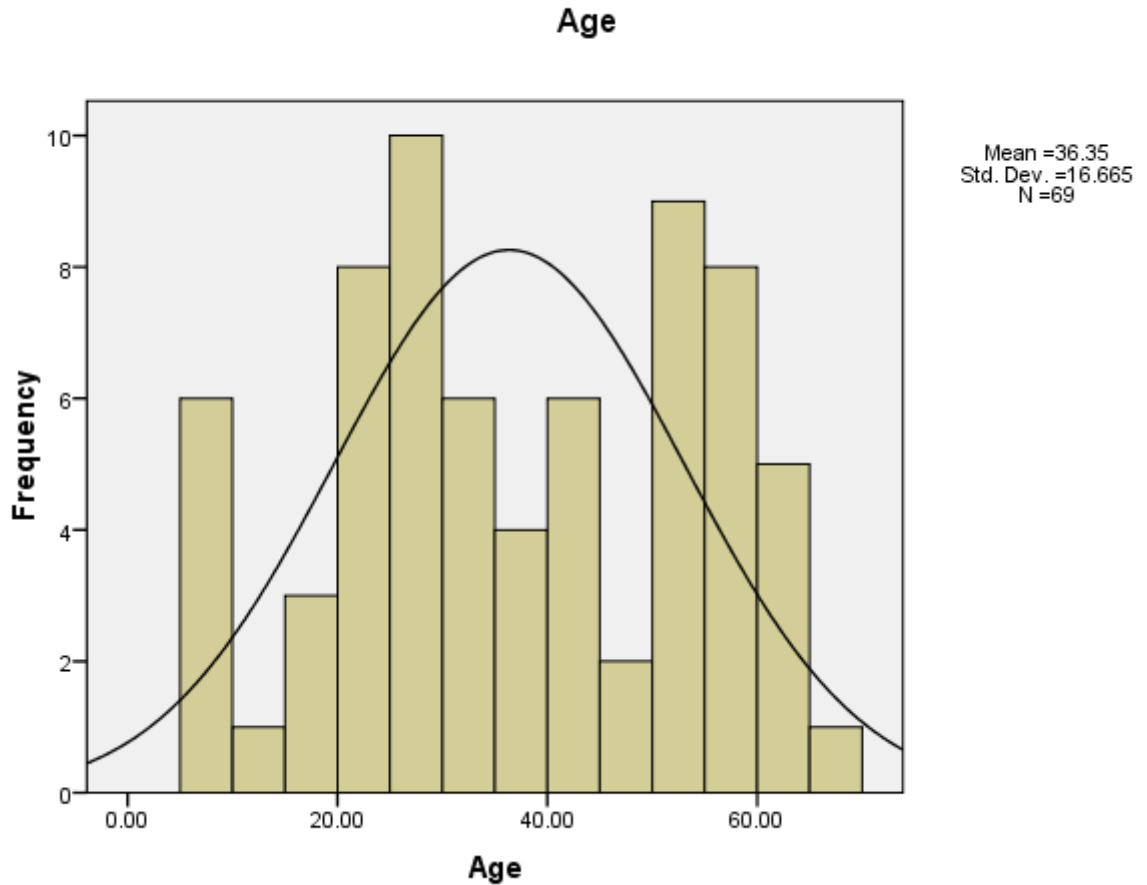


Figure 4.3 Fitted Curve Mean age and Standard Deviation

Table 4.3 Number of patients classified according to Pregnancies, Frequencies and Percentages

Pregnancies, Frequencies and Percentages			
		Frequency	Percentages
Number of Pregnancies	0-2	50	72.5
	3-5	11	15.9
	6-8	8	11.6
	Total	69	100.0




Figure4.4 Number of Pregnancies

Table 4.4 Number of patients who uses Brush for cleaning teeth

Cleaning With Brush			
		Frequency	Percentage%
Usage	Not Used	3	4.3
	Use Brush	66	95.7
	Total	69	100.0



Figure 4.5 Number of Patients using Brushes

Table 4.5 Number of patients who uses Miswak for cleaning teeth

Cleaning Miswak			
		Frequency	Percent
Usage	Not used	47	68.1
	Use Miswak	22	31.9
	Total	69	100.0



Figure4.6 Number of Patients using Miswak

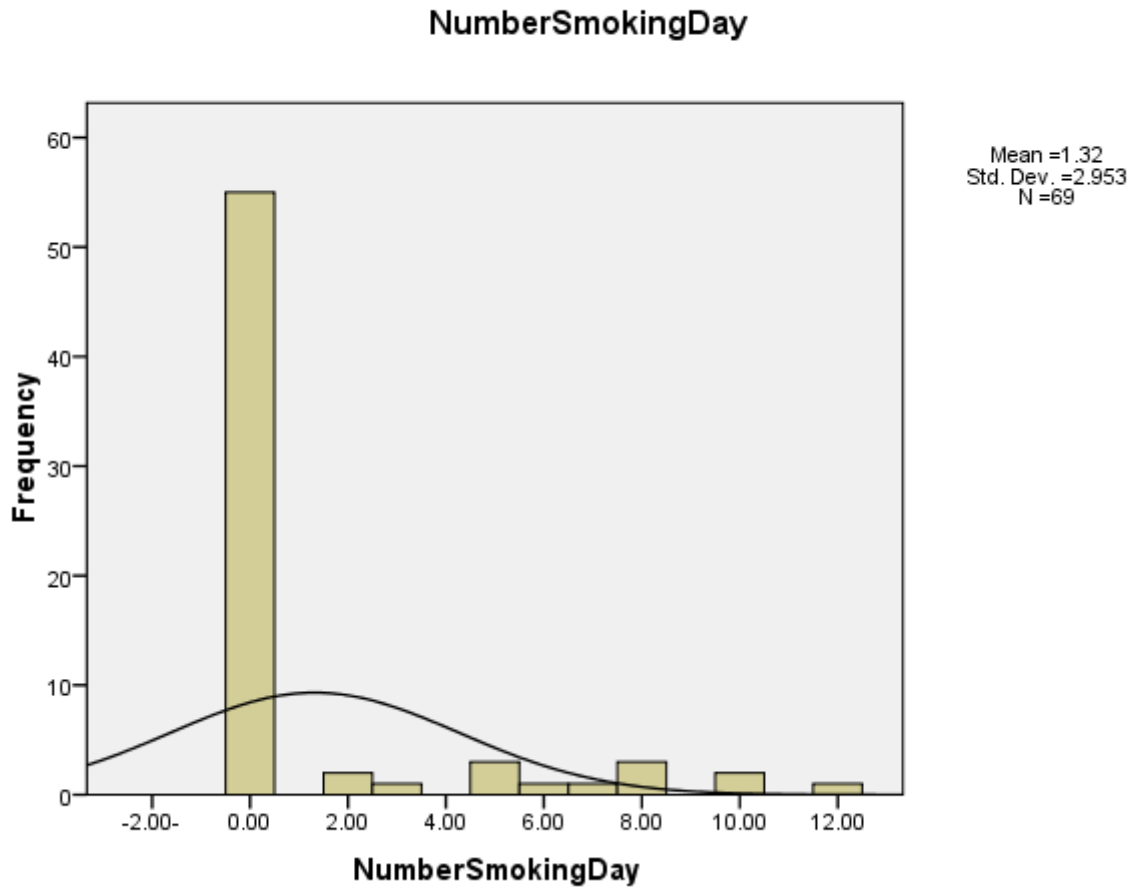


Figure4.7 Number of Smoking per day, Mean and Standard deviation

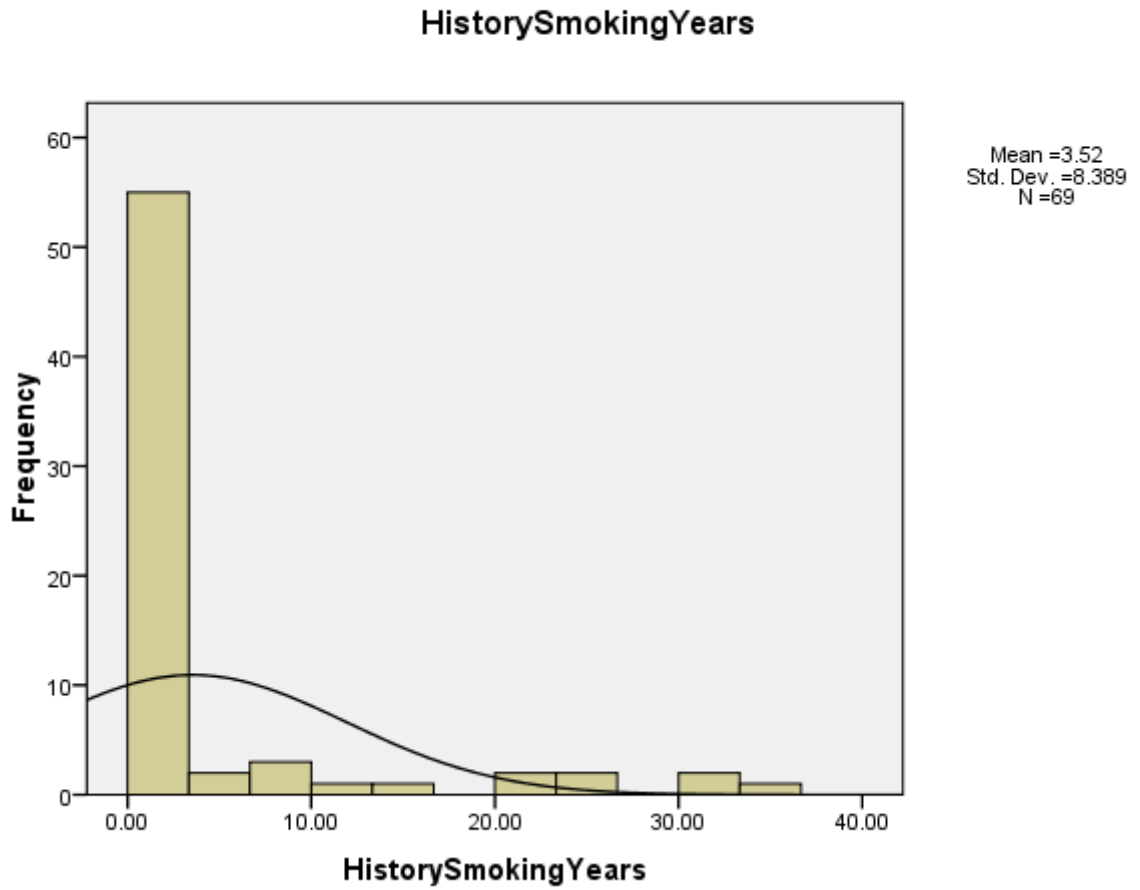


Figure 4.8 History of Smoking, Mean and Standard Deviation

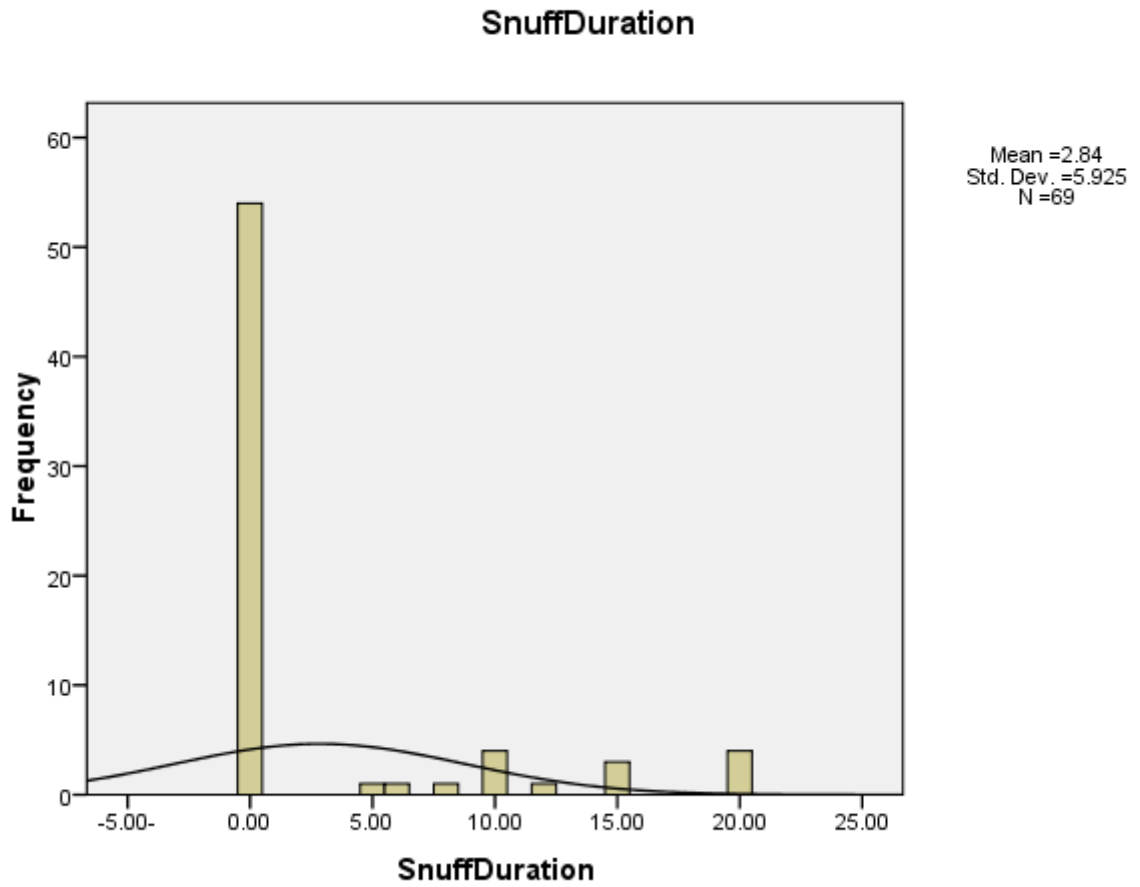


Figure4.9 History of Snuff Duration, Mean and Standard Deviation

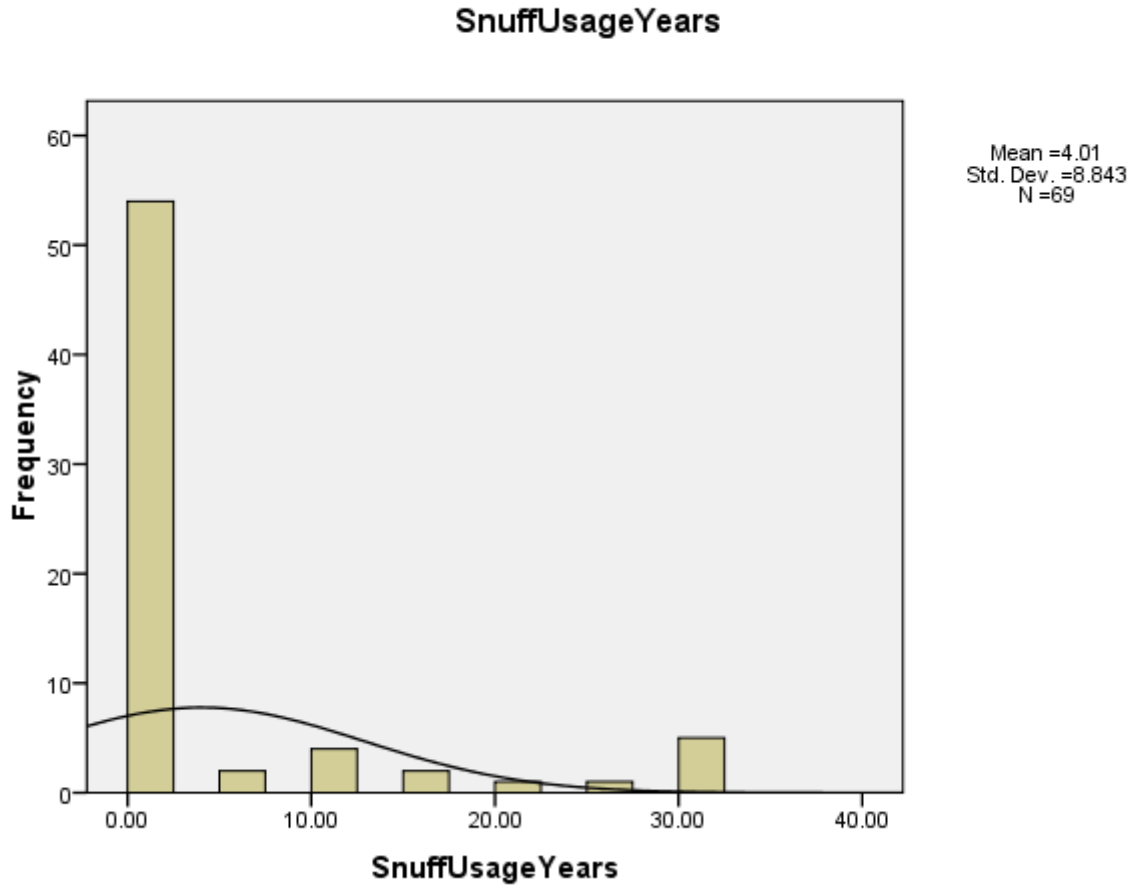


Figure4.10 History of Snuff usage/Years, Mean and Standard Deviation

Table 4.6 the Site of Missing Teeth, Frequency and Percentages

Site of Missing Teeth	Frequency
Right Upper Jaw(Maxilla)	44
Left Upper Jaw(Maxilla)	35
Right Lower Jaw(Mandible)	49
Left Lower Jaw(Mandible)	36

Figure4.11 The site of the missing Teeth

Table4.7 The Characterization of Missing Teeth according to Site (Right side, Left side, Upper Jaw ,Lower Jaw) and affected Teeth(Central, Canine, Molar, premolar)& correlation with age (significant at P value 0.05)

	Site Of Missing Teeth		Correlation With age at P-Value0.005
	Upper Missing RT Center		.052*
	Frequency	Percent	
Normal	58	84.1	
Missed	11	15.9	
Total	69	100.0	
	Upper Missing RT Canine		.575
	Frequency	Percent	
Normal	56	81.2	
Missed	13	18.8	
Total	69	100.0	
	Upper Missing RT Premolar		

	Frequency	Percent	0.002*
Normal	57	82.6	
Missed	12	17.4	
Total	69	100.0	
Upper Missing RT Molar			
	Frequency	Percent	0.027*
Normal	61	88.4	
Missed	8	11.6	
Total	69	100.0	
Upper Missing LT Center			
	Frequency	Percent	0.837
Normal	61	88.4	
Missed	8	11.6	
Total	69	100.0	
Upper Missing LT Canine			
	Frequency	Percent	0.095
Normal	60	87.0	
Missed	9	13.0	
Total	69	100.0	
Upper Missing LT Premolar			
	Frequency	Percent	0.001*
Normal	58	84.1	
Missed	11	15.9	
Total	69	100.0	
Upper Missing LT Molar			
	Frequency	Percent	0.610
Normal	62	89.9	
Missed	7	10.1	
Total	69	100.0	
Lower Missing RT Center			
	Frequency	Percent	.000*
Normal	55	79.7	
Missed	14	20.3	
Total	69	100.0	
Lower Missing RT Canine			
	Frequency	Percent	0.001*
Normal	53	76.8	

Missed	16	23.2	
Total	69	100	
Lower Missing RT Premolar			
	Frequency	Percent	0.069
Normal	61	88.4	
Missing	8	11.6	
Total	69	100.0	
Lower Missing RT Molar			
	Frequency	Percent	0.045
Normal	59	85.5	
Missing	10	14.5	
Total	69	100.0	
Lower Missing LT Center			
	Frequency	Percent	0.698
Normal	61	88.4	
Missing	8	11.6	
Total	69	100.0	
Lower Missing LT Canine			
	Frequency	Percent	0.001*
Normal	59	85.5	
Missing	10	14.5	
Total	69	100.0	
Lower Missing LT Premolar			
	Frequency	Percent	0.071
Normal	59	85.5	
Missing	10	14.5	
Total	69	100.0	
Lower Missing LT Molar			
	Frequency	Percent	0.078
Normal	62	89.9	
Missing	7	10.1	
Total	69	100.0	

Table4.8 Number of affected patients with infections

Infection				Correlation with Age, Significant at P-Value 0.005
		Frequency	Percentages	
Affected Patients	Normal	43	62.3	.177
	Infected	26	37.7	
	Total	69	100.0	

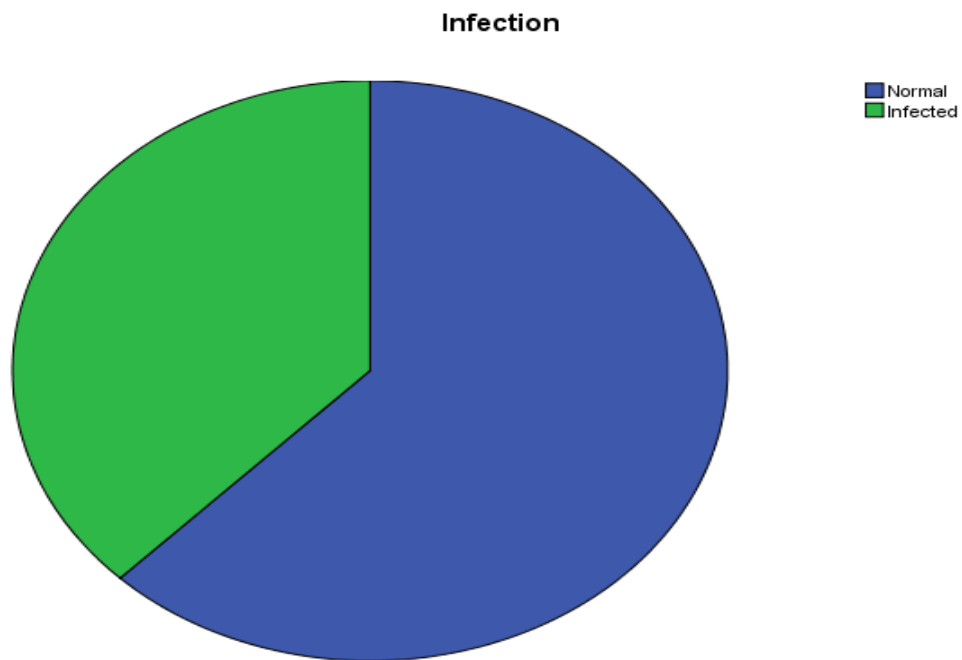


Figure4.12 Number of affected patients with infections

Table 4.9 Number of affected patients with Caries

Caries				Correlation with Age Significant at P-Value 0.005
		Frequency	Percentages	
Affected Patients	Normal	42	60.9	.029*
	With Caries	27	39.1	
	Total	69	100.0	



Figure4.13 Number of affected patients with Caries

- In this data using toothpicks positively affect the health of the oral where at least the presence of caries .
- In this data using snuff affect oral health negatively cause infection.
- In this data using a toothbrush has no effect on oral health.
- In these data Smoking for many years affects negatively on the health of the mouth and tooth brushing with the use of at least the negative impact of smoking.
- Many times the number of pregnancies with the use of snuff for many years in addition to the length of the snuff duration a negative impact on oral health in this sample of data.
- In these data Smoking for many years with the length of the snuff duration together have a negative impact on oral health.
- In this data the number of times during the days smoking a large amount and smoking for many years negatively affect oral health.

5-1 Discussion

In this study, we evaluated the health of oral of the sixty-nine patients in a hospital in Khartoum Dental including 35 male and 34 female As described in the table (4.1).

Spotted age and their gender and some of their habit associated with daily oral then we looked at O.P.G images and diagnosed, and has been linked the diagnostic with information observed for patients, See the table (5.1).

Data were analyzed and then infer conclusions from them.

The study was limited to smoking and snuff and the tools used to clean teeth (toothbrush and miswak) as daily habits related to oral health ,See the table (5.1). The disease, which was spotted images of caries and missing tooth and infection, and there was a special data are women and the number of pregnancies and when was the last pregnancy.

From analysis of these data was assessing the impact of the customs observed as follows:

- Patients who use the msiwaak had better oral health than others, See the table (4.10) , also see DDS, PhD and Nils Skaug
- Patients who continued to use snuff or many years were the most infection, See the table (4.10) , also see Dental Health Service in Gezira Locality.
- Do not brush teeth clear impact on the oral health of patients in this study, See the table (4.10) , see Child-Oral health quality.
- Smoking has negative effects on the health of oral through long time and the large number of smoking during the day ,But these effects were less when users siwaak, See the table (4.10). Also see Dental Health Service in Gezira Locality, DDS, PhD and Nils Skaug .
- Pregnancy does not have a negative effect in this study only in the presence of harmful habits such as substance snuff, See the table (4.10) , see Anne N Astrom, Bio Med central BMC Oral Health.
- Patients who use snuff for many years, and a daily dose of intensive appeared to have more oral health deterioration, See the table (4.10).

5-2 Conclusion

- the O.P.G examination gives a good assessment of oral health as it helps in the diagnosis of a large number of oral diseases.
- Aging has an effect on the components of the mouth and this effect may become more damaging if the owner and the presence of bad habits
- Smoking and snuff habits that affect the long time periods across a negative impact on oral health
- With regard to women, the pregnancy has no obvious effect only in the presence of other factors, such as smoking and snuff
- Use siwaak help improve oral health

5-3 Recommendation

- 1- Rely on the O.P.G Examination greater in the diagnosis of oral diseases in hospitals than it is now.
- 2- When an O.P.G examination must give the patient a comprehensive assessment of the validity of his mouth and awareness regarding the habits beneficial and harmful to the health of the mouth.

References :

- 1-Peterson-Shailer. Orientation of dentistry, in: Dentist and the assistant History. 4th edition London, 1977; p. 4.
- 2-Kostlan J. Oral health services in Europe. World Health Organization – Regional Office of Europe, Copenhagen. WHO, 1979; p. 9.
- 3-WHO oral health country/Area profile programme, Department of non-communicable diseases surveillance/oral health WHO Collaborating Centre, Malm. University Sweden 2000/06/22.
- 4-WHO. Monitoring and evaluation of oral health: Tech Rep ser No. 782 Geneva 1989.
- 5- Wheeler’s Dental Anatomy, Physiology, and Occlusion. 8th edition
- 6-M.Y.Sukar, H.A.ELmunshid,M.S.MArdawi2004.
- 7- Health and Quality of Life Outcomes, 19-Apr-2011; 08-Feb-2012.
- 8-Nazik M Nurelhuda, Mutaz F Ahmed, Tordis A Trovik⁴, Anne N Astrom, Bio Med central BMC Oral Health, 2010.
- 9- Yousif and Miskeen, Dental Health Service in Gezira Locality, Sudan, 2009.
- 10- IsmailAbbasDarout, DDS, PhD and Nils Skaug, 2009.
- 11- Dental Radiographic Examinations: Recommendations For Patient Selection And Limiting Radiation Exposure. Am Dent Assoc, U.S. Dept of Health and Human Services, FDA. Revised: 2012
- 12- Stuart C. White, Micheal J Pharoh, Oral Radiology and Interpretation Mosby 2005
- 13-Essentials of dental radiography and radiology (4th ed.). Edinburgh: Churchill Livingstone. 2007. pp. 187–206. ISBN 978-0-443-10168-7.
- 14-<http://www.patentstorm.us/patents/5018177.html>

- 15-American Heart Association, "Heart Disease and Stroke Statistics," 2010
- 16- The Effect of *Salvadora Persica* Extract (Miswak) and Chlorahexidine (Gluconate) on Human Dentin: A SEM Study (PDF)
- 17- Miswak (chewing Stick): A Cultural And Scientific Heritage (PDF)
- 18- Oral hygiene and periodontal status associated with the use of Miswak or toothbrush among Saudi adult (PDF-
- 19- Strong Antibacterial Effect of Miswak Against Oral Microorganisms Associated With Periodontitis and Caries
- 20- The Immediate Antimicrobial Effect of a Toothbrush and Miswak on Cariogenic Bacteria
- 21- In vitro antimicrobial effects of crude miswak extracts on oral pathogens (PDF).
- Indigenous multipurpose trees of Tanzania (Food and Agricultural Organization).
- 22-Sonis, Stephen T. (2003). *Dental Secrets* (3rd ed.). Philadelphia: Hanley & Belfus. p. 130. ISBN 1-56053-573-3
- 23-Holloway PJ; Moore, W.J. (September 1983). "The role of sugar in the etiology of dental caries". *J Dent* **11** (3): 189–213. doi:10.1016/0300-5712(83)90182-3. PMID 6358295.
- 24-Health Promotion Board: Dental Caries, affiliated with the Singapore government. Page accessed August 14, 2006.
- 3-Ross, Michael H., Gordon I. Kaye, and Wojciech Pawlina, 2003. "Histology: a text and atlas." 4th edition