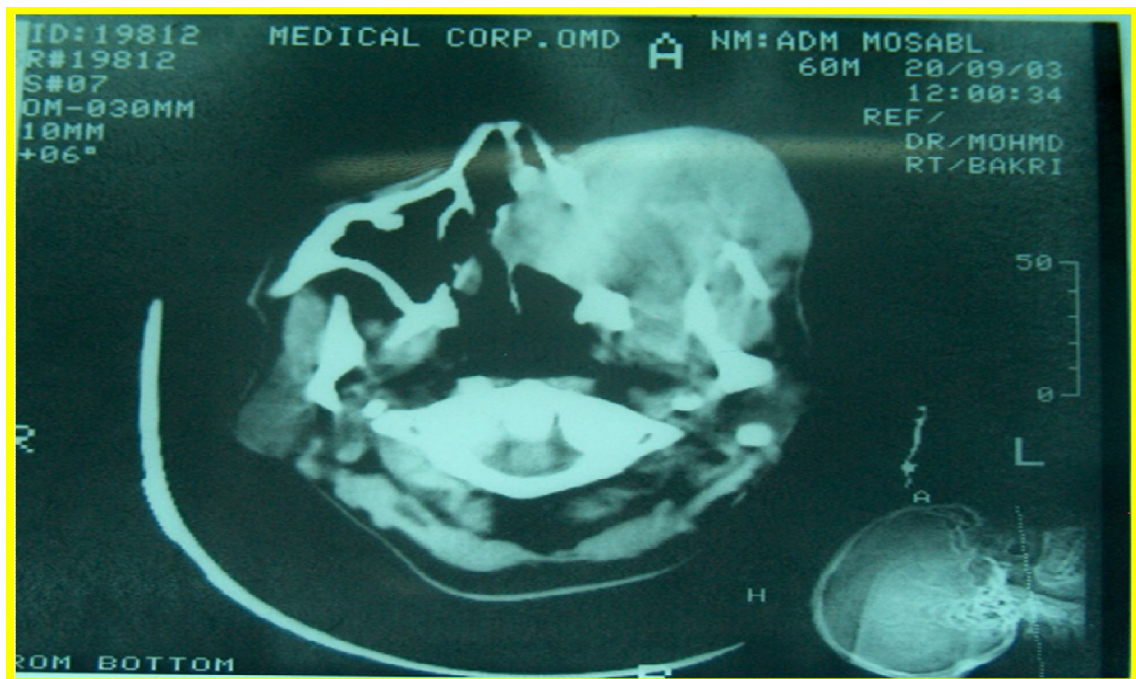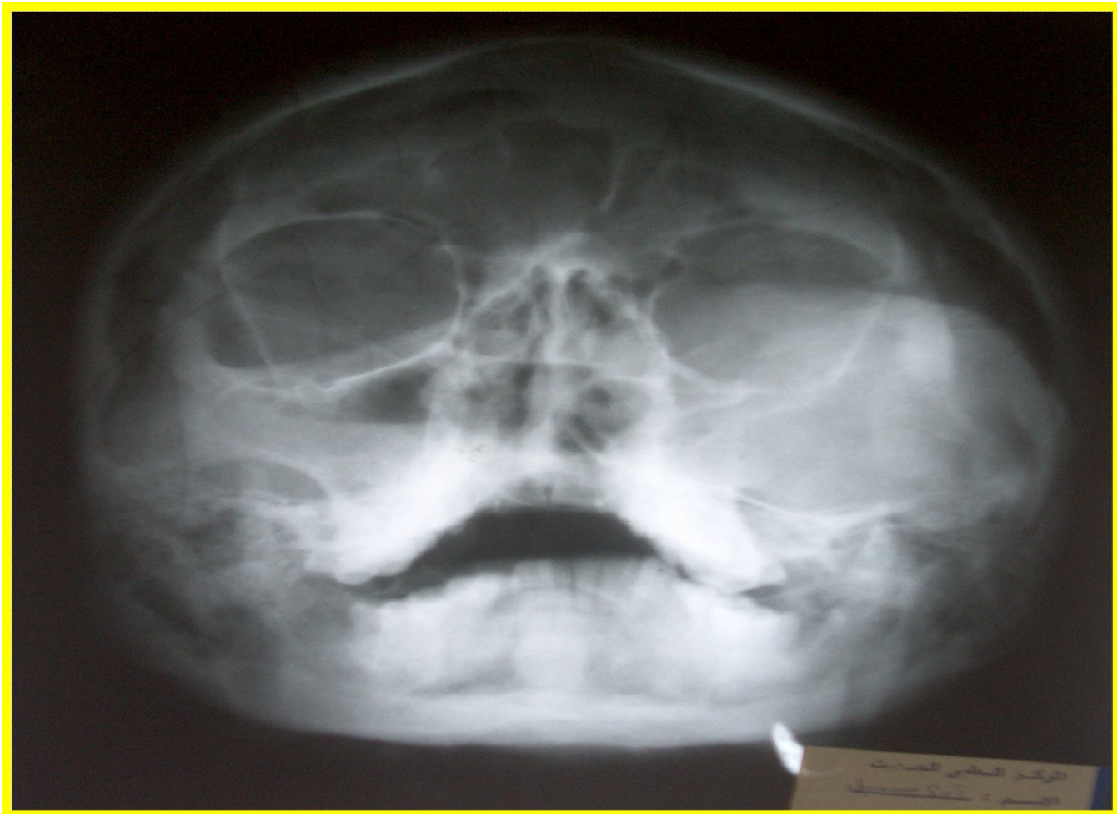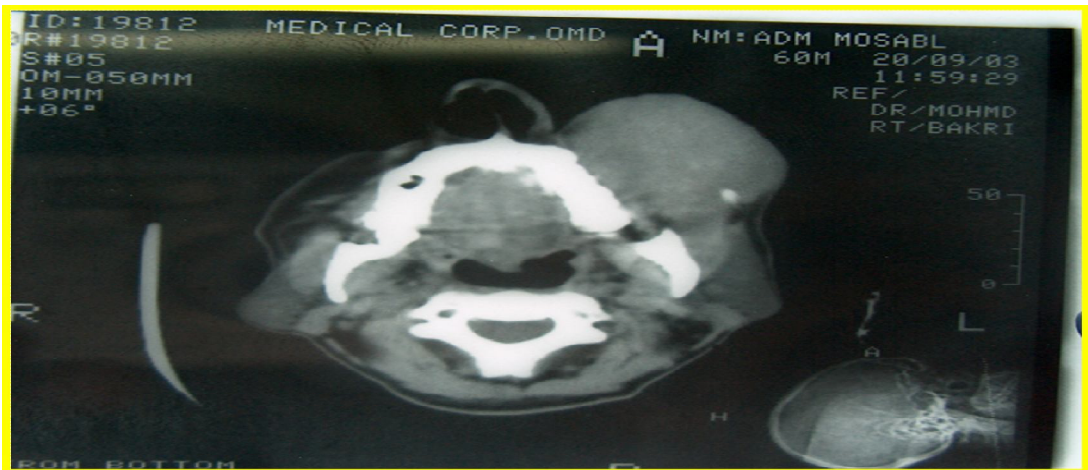
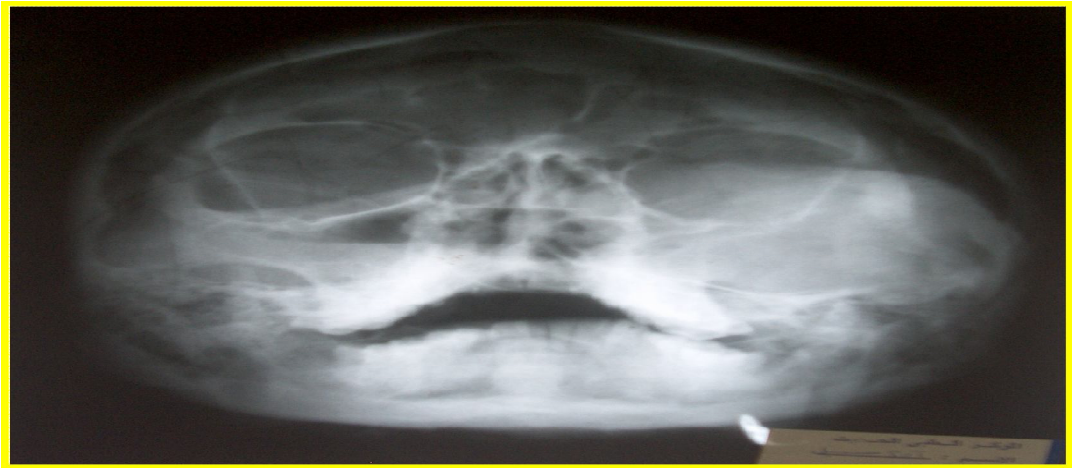
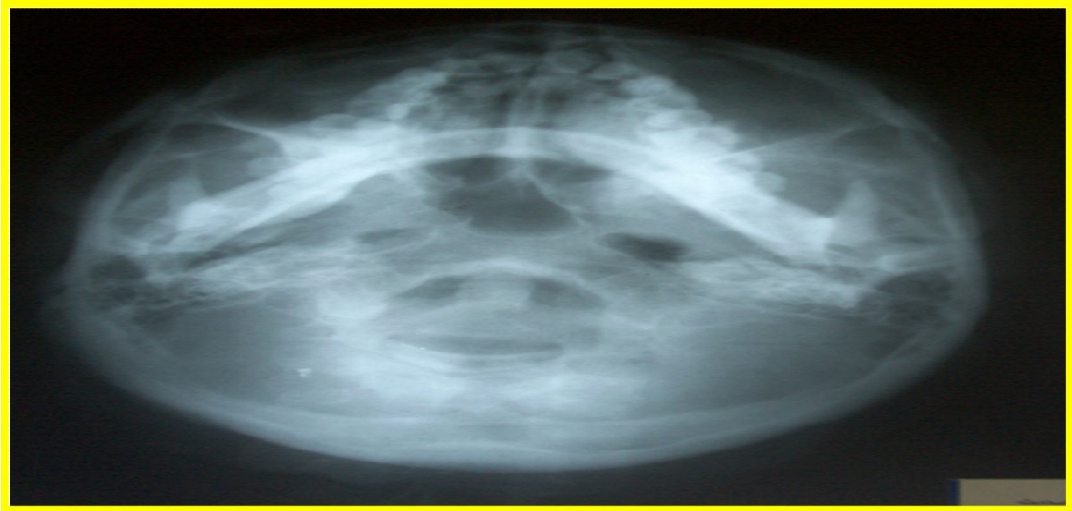
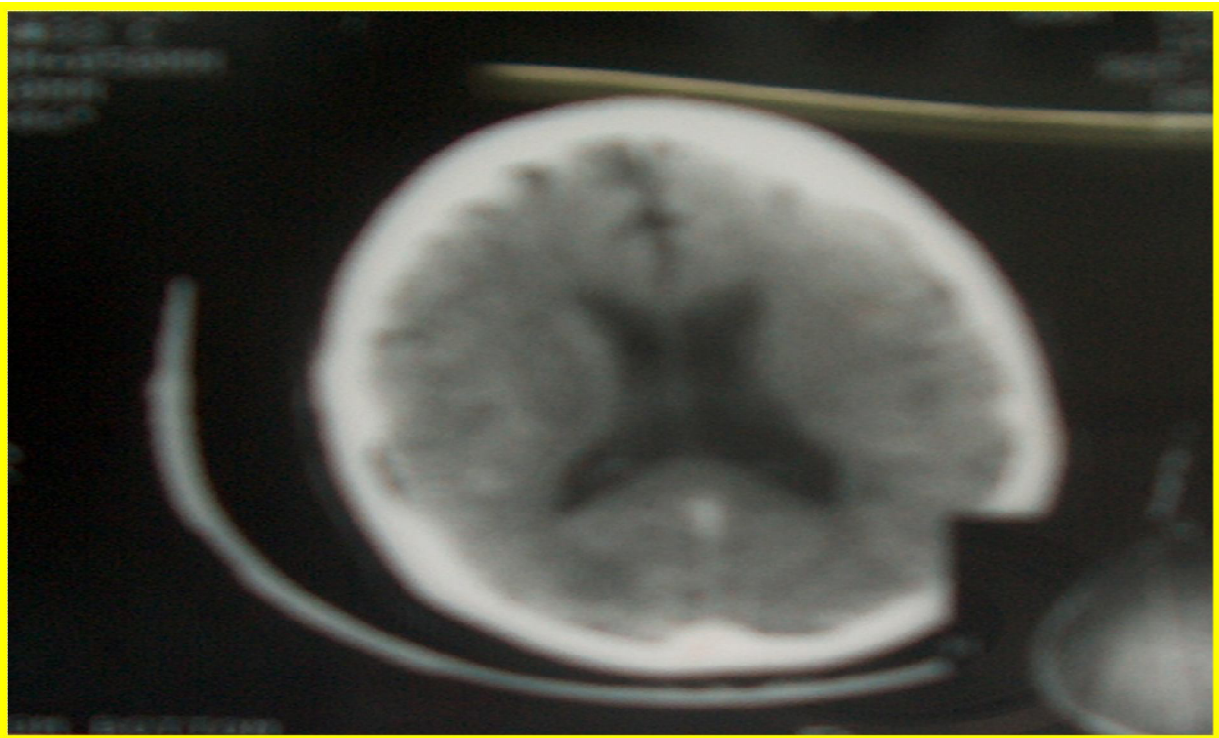
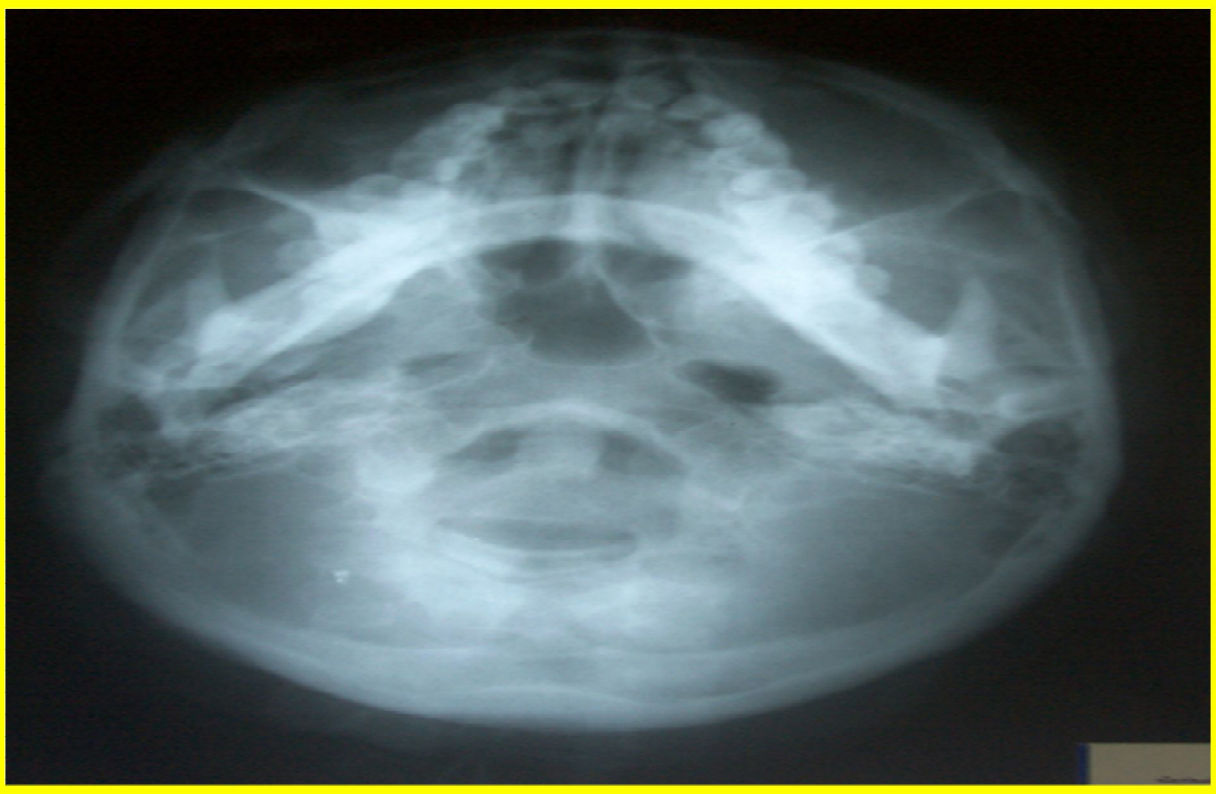


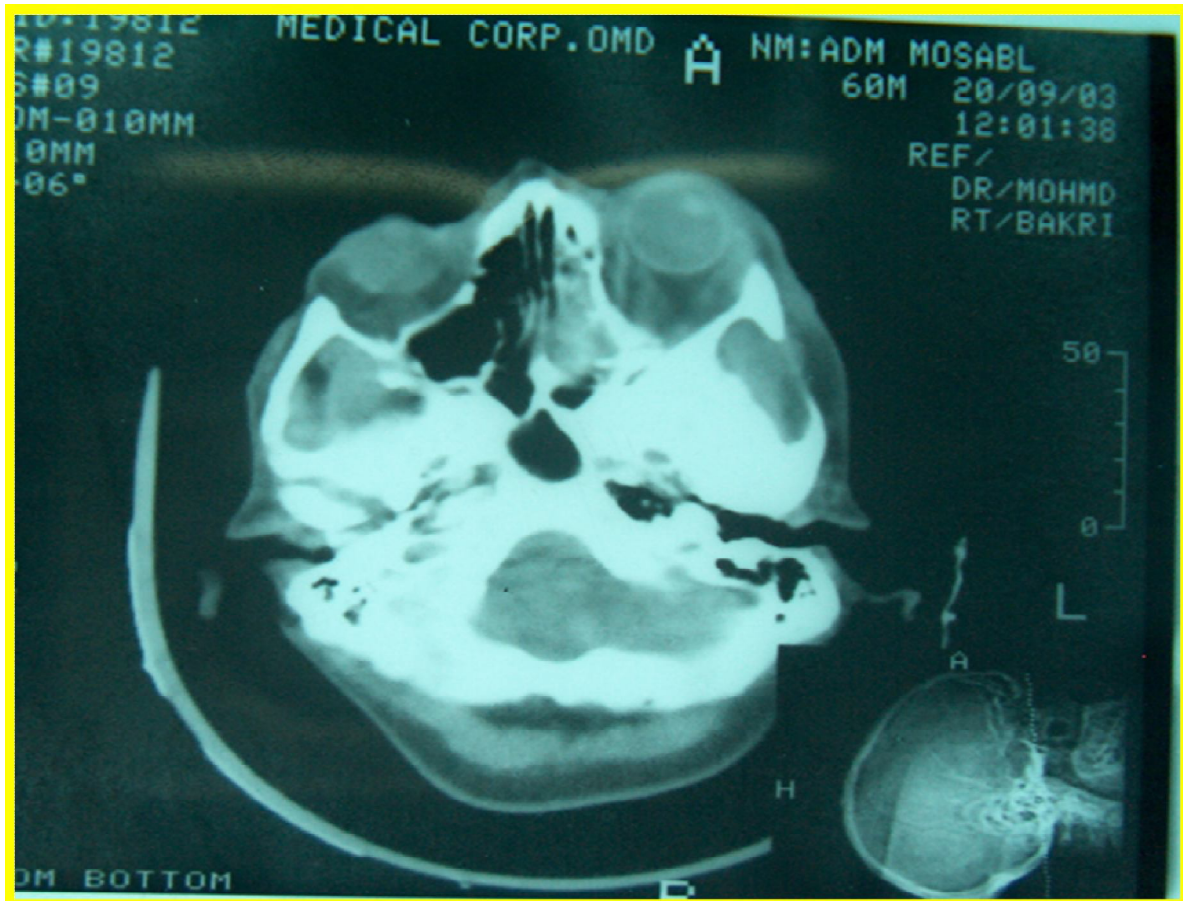
**Case (1) Squamous Cell Carcinoma Male (35) Year**



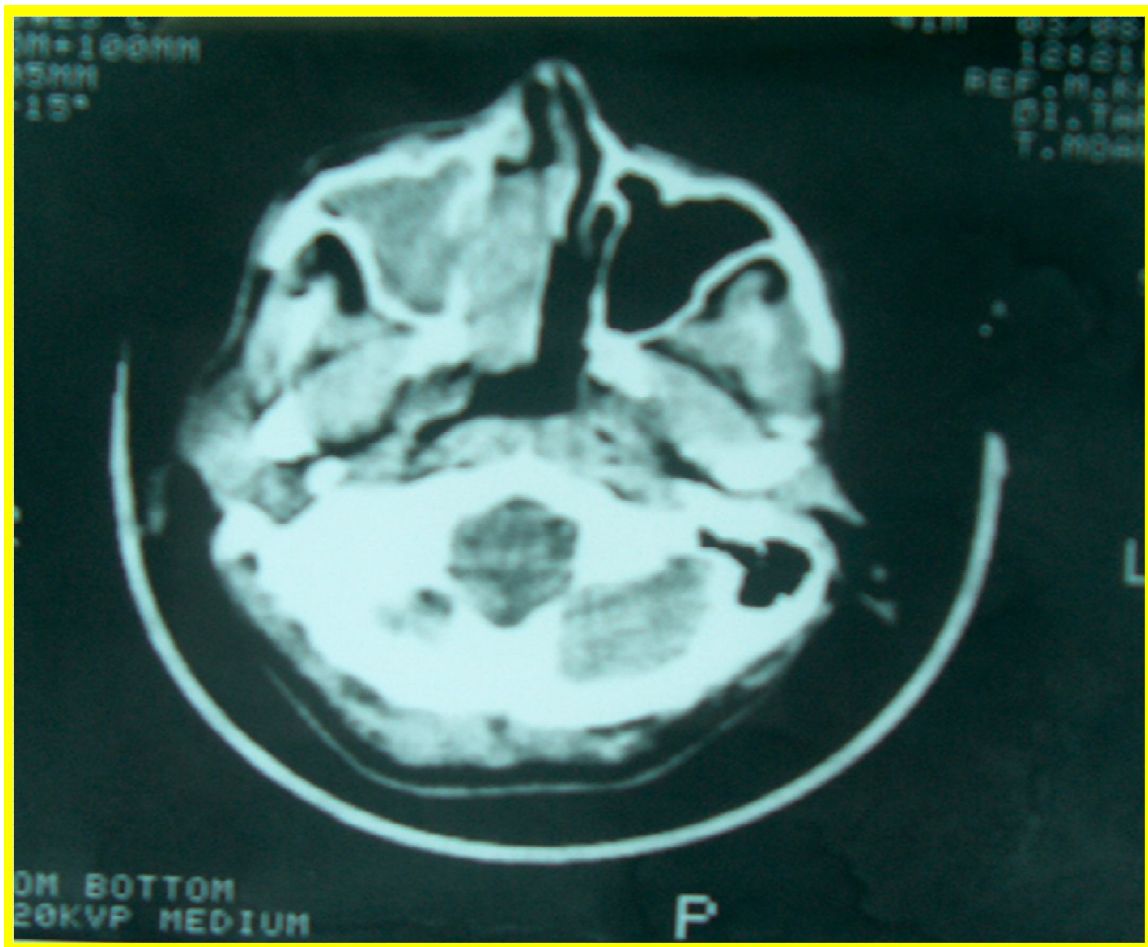
**Case (2) Malignant neoplasm female (42) Year**



**Case (3) Allergic Sinusitis female (35) Year**



**Case (4) Aspergillosis female (28) Year**



**Case (5) benign Mass Male (49) Year**