



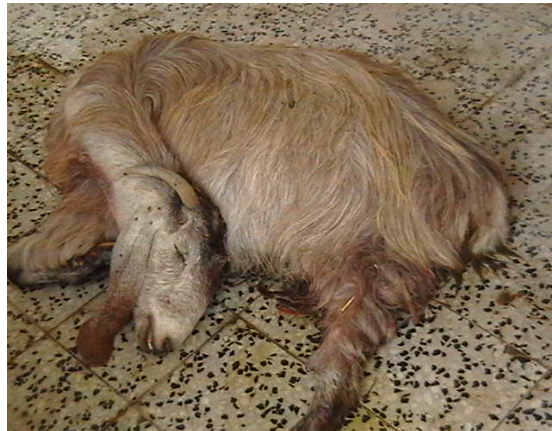Figure(1) mild case of pregnancy toxemic goat with recumbency, twisted head and neck . encephalopathy)



figure(2)- shamia goat with pregnancy toxemia show head against wall (Hypoglycemic)



Fig.(3)



Fig(4)

Sever case pregnancy toxemia showing goat with lateral recumbency and coma.



Fig(5):- Goat with pregnancy toxemia and tetanic convolution.



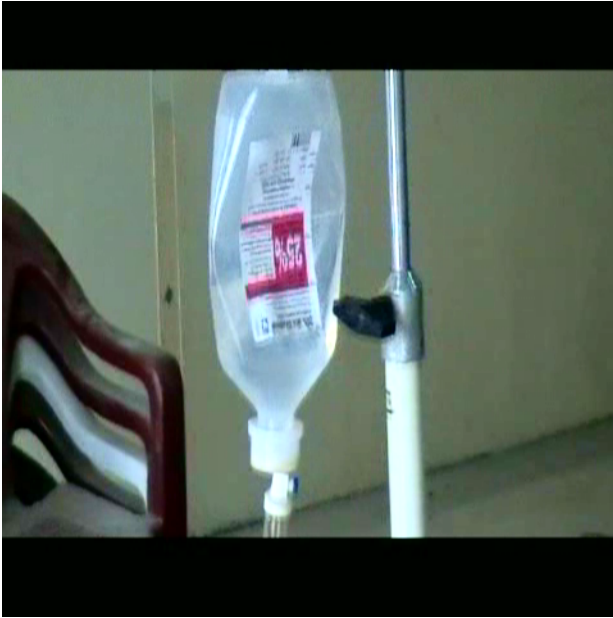Fig(6):-Vaginal prolapse of goat in last stage of pregnancy predispose to pregnancy toxemia.



Fig(7)
Extended abdomen and star grazing goat with mild stage of Pregnancy toxemia

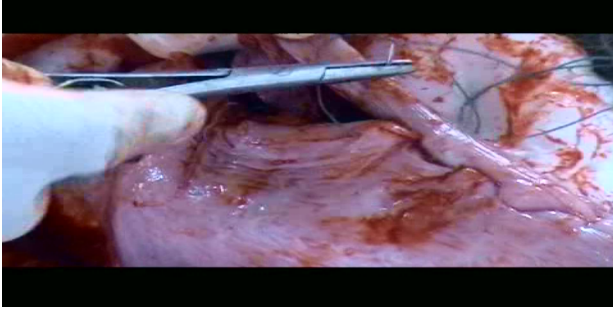


Fig(8)

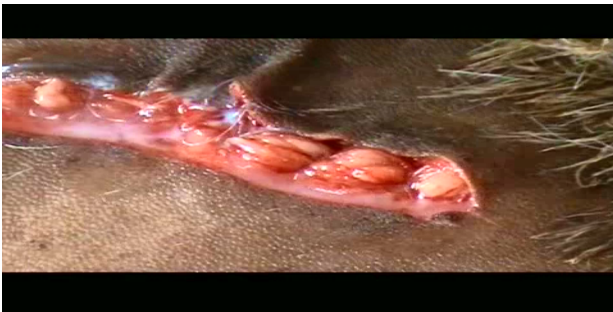

Fig(13)
treatment of pregnancy toxemic goat with 25% glucose by I.V set

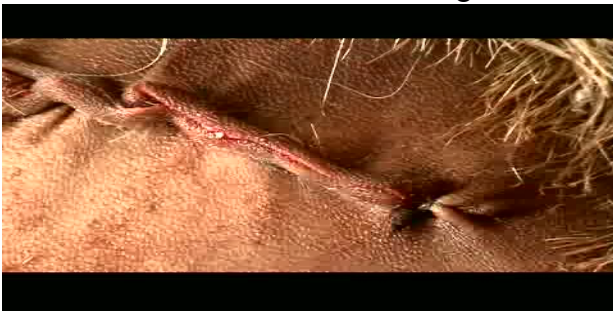Fig(14)



Fig(15)
caesarian section of same goat after closer of uterus and abdomen.



Fig(16)



Fig(17):- skin closer of the same
goat above.
mother

Fig(18):goat after surgery with 3 alive
kids and improvement of the