

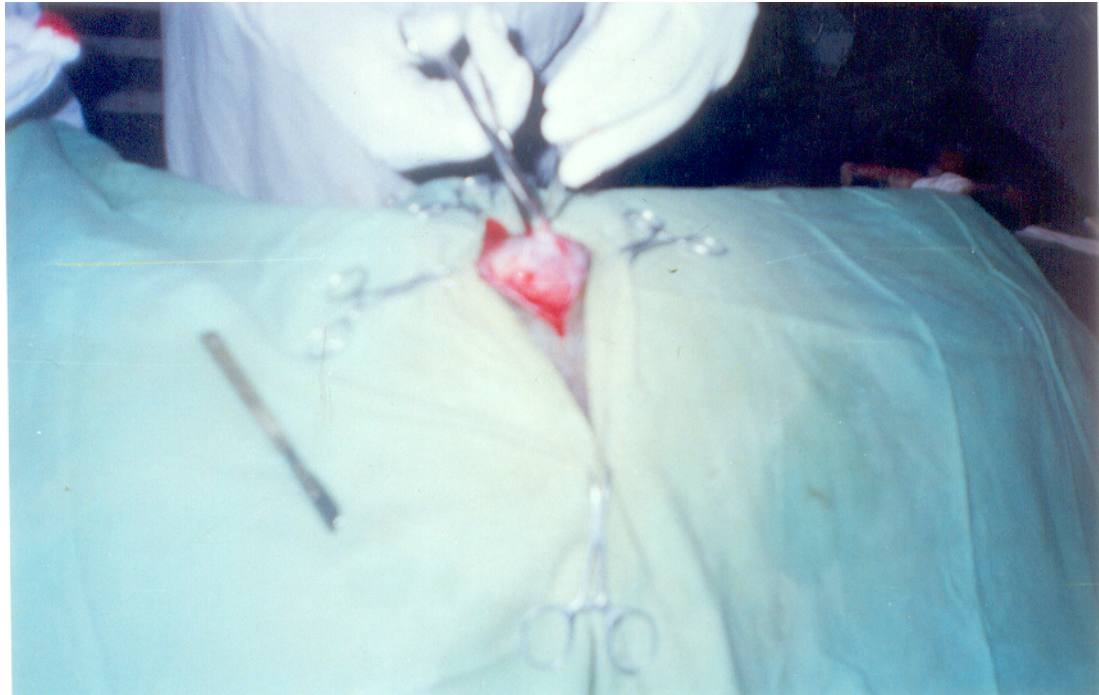Fig (1) Incision of underlying tissue layers

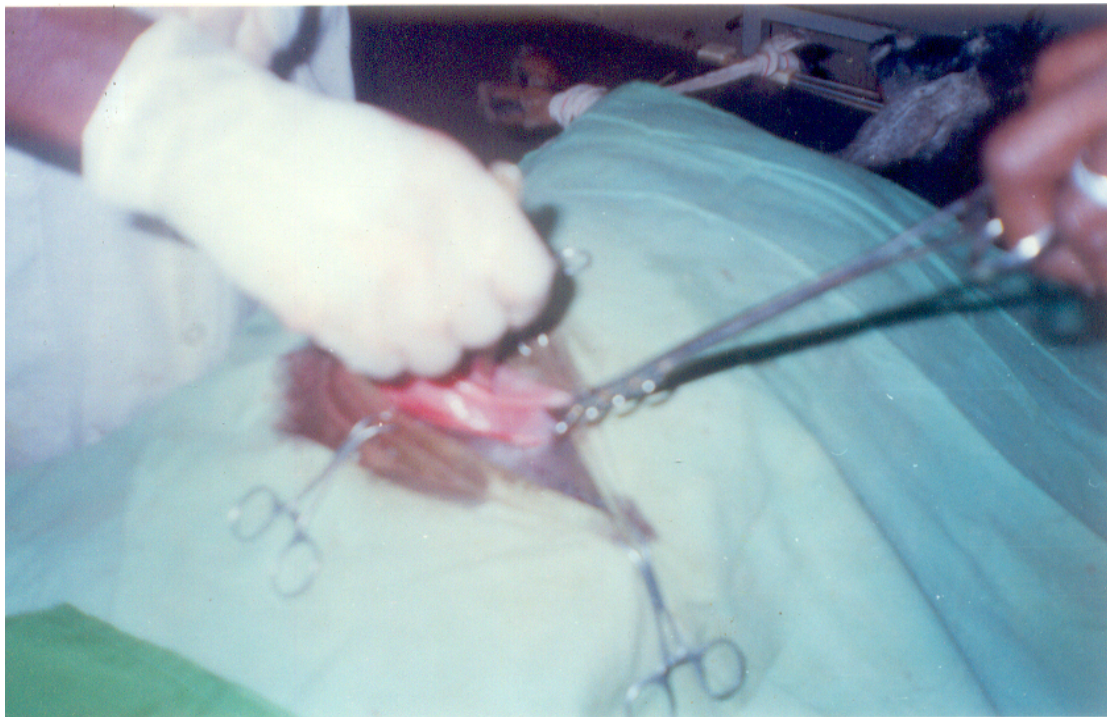


Fig (2) Incision of the uterus by scalpel blade

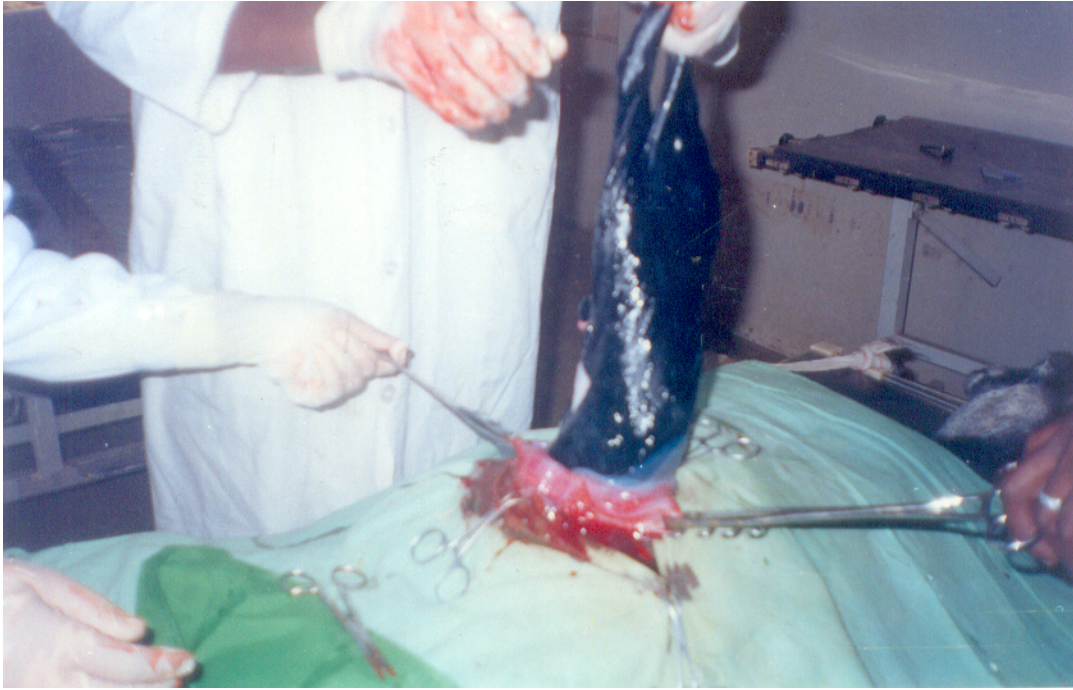


Fig (3) Removal of the fetus

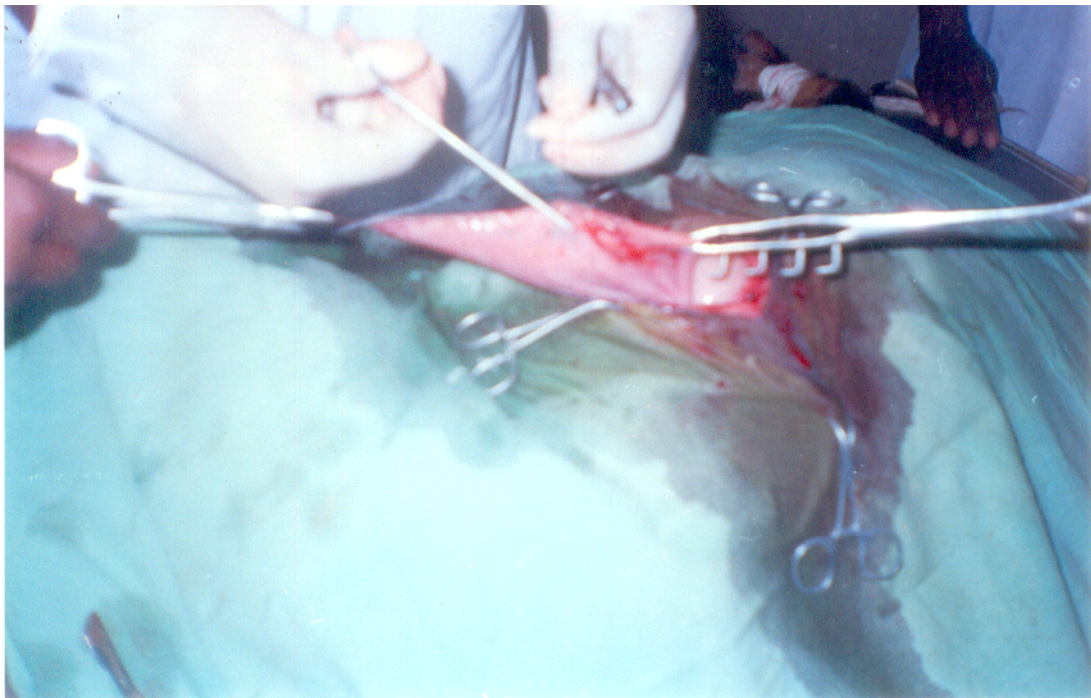


Fig (4) Suture of the uterus

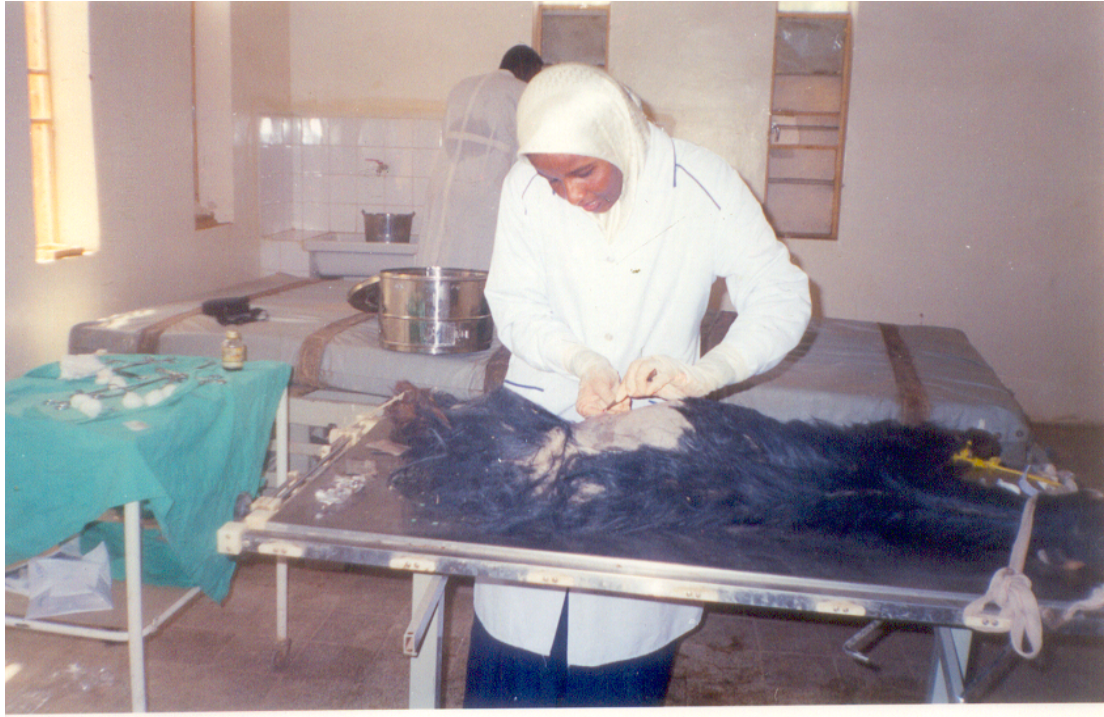

Fig (5) Suture of the skin .

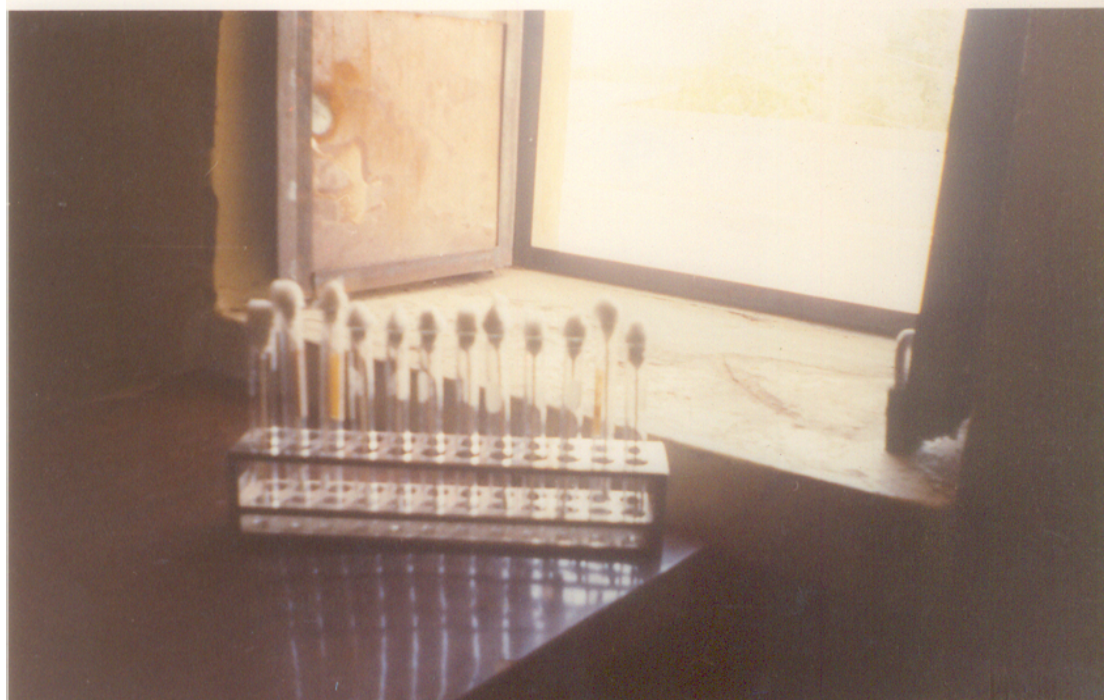


Fig (6)The swabs used for cervical mucus collection



Fig (7) Coldection of cerical swab .

