



Histometric Investigations on the Adrenal Gland of the Dromedary Camel (*Camelus dromedarius*)

Osman E.E¹, Ali H. A.², Ibrahim Z. H.³

1. Department of Anatomy, Faculty of Pharmacy, University of Science and Technology, Khartoum, Sudan.
2. Department of Biomedical Science, College of Veterinary Medicine, Sudan University of Science and Technology, Khartoum, Sudan;
3. College of Agriculture and Veterinary Medicine Qassim University, Buraidah, KSA.

*Corresponding Author: *Corresponding Author: eshtiag33@gmail.com

ABSTRACT:

The histometry of the adrenal glands of the dromedary camel (*Camelus dromedarius*) was described for the first time in this study. Histological samples of the camel right and left adrenal glands collected from eight adult camels of both sexes at AL-Salam abattoir, Khartoum, Sudan were used in this study. Histometric measurements were performed on glandular capsule (Ca), cortical zones {zona glomerulosa (ZG), zona fasciculata (ZF), zona reticularis (ZR)} and glandular medulla (M). The right ZF which measured about 58.5% of the total cortical thickness was significantly thicker ($P < 0.05$) than the right ZG (18.2%) and right ZR (23.3%), whereas the right ZG and ZR were approximately equal in thickness. The right cortex (RCo) which formed 56.4% of the total glandular thickness was significantly thicker ($P < 0.05$) than the right medulla (RM) that measured 43.6%. The left ZF (61.9% of the total cortical thickness) was significantly thicker than the left ZG and left ZR (16.5% and 21.6%, respectively). The mean thickness of the left cortex (LCo) that formed 58.0% of the total glandular thickness was significantly increased compared to the left medulla (LM) (41.9%). Comparing the right gland with the left showed that the mean thickness of the right capsule (RCa) was in-significantly increased ($P > 0.05$) than the left capsule (LCa); in-significant increase ($P > 0.05$) was also observed in the mean thickness of the RCo compared to that of the LCo; the mean thickness of the RM was in-significantly increased compared to the LM. Furthermore, there was significant increase in the mean thickness of the RZG compared to the LZG and significant increase in the RZR than the LZR; however, an in-significant increase was shown in the RZF in comparison with LZF; additionally, the mean thickness of the RZF and LZF was greater than other two cortical layers. In conclusion, the ZF was the thickest zona in the cortex of camel adrenal gland and the ZG was the thinnest in both right and left glands; further, the cortex was generally thicker than the medulla in either side and the glandular capsule, cortical zones and medulla of the right adrenal glands are collectively thicker than those in the left one.

keywords: Histometry, Adrenal Gland, Dromedary Camel.

© 2019 Sudan University of Science and Technology; All rights reserved



Introduction:

The adrenal glands are complex endocrine organs regulating multiple physiological processes, such as metabolism, stress response, immune functions and the cardio-vascular system (Bielohuby *et al.*, 2007; Kigata and Shibata, 2018).

Animals typically possess two adrenal glands, right and left, each of which located cranio- medial to the corresponding kidney (Dyce *et al.*, 1996; Hussain and Qureshi, 2007; Dangi *et al.*, 2008; Karakurum *et al.*, 2008; Chima and Blessing, 2009; Akers and Denbow, 2013; Mescher, 2013; KÖnig and Liebich, 2014; Barszcz *et al.*, 2016; Olukole *et al.*, 2016; Abass, 2017). Abdalla and Ali (1988) and Nabipour *et al.* (2008) noted that the adrenal glands of the camel varied in shapes, colors and positions.

The architecture of the adrenal gland has been reported to be similar in animals and human (Bacha and Bacha, 2000; Monfared *et al.*, 2013; Obike *et al.*, 2014; Sheikhan *et al.*, 2014; Barszcz *et al.*, 2016; Olukole *et al.*, 2016; Ross and Pawlina, 2016; Santosa *et al.*, 2016; Abass, 2017). It was covered by a connective tissue capsule and divided into outer cortex, which consists of three histological zones; ZG, ZF and ZR, and inner Medulla (Jelinek and Konecny, 2011; Parchami, and Dehkordi, 2011; Kumar, 2013; Mescher, 2013; Obike *et al.*, 2014; Olukole *et al.*, 2016; Santosa *et al.*, 2016; Abass, 2017) and similarly in the dromedary camel (Ali, 1987; Nabipour *et al.*, 2008; Ibraheem *et al.*, 2011). In Bactrian camel the cortex was divided into four zones; ZG, zona intermedia (ZI), ZF and ZR (Ye *et al.*, 2017).

Histometric studies on the thickness of different adreno-cortical zones have been carried out in rat (EL-Sayed *et al.*, 1990; Monfared, 2013; Monfared *et al.*, 2013), sows (Opalka *et al.*, 2001), human (Hui *et al.*, 2009), rabbits (Parchami, and Dehkordi, 2011), goat (Qureshi *et al.*, 2013), pig and hamster (Sheikhian *et al.*, 2014) and bacterian camel (Ye *et al.*, 2017). However, there was a lack of information on the histometry of the adrenal glands of dromedary camel. The present study, therefore, was conducted to investigate the histometry of the adrenal glands of dromedary camel.

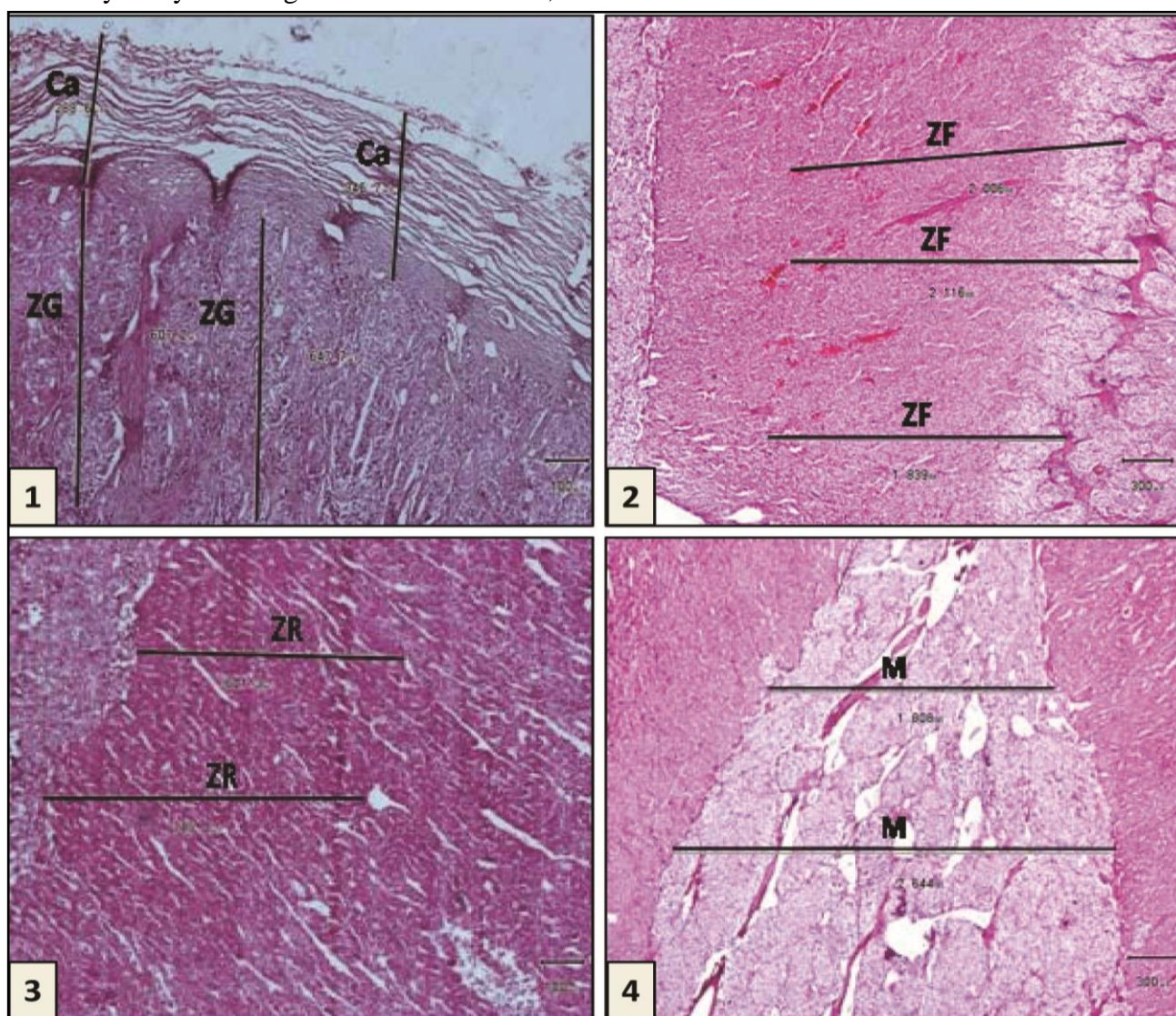
Material and Methods:

Sixteen adrenal glands (8 from either side) were used in this study. The glands were obtained from apparently healthy adult camels slaughtered at AL-Salam abattoir in Khartoum, Sudan. Small tissue slices were taken from the capsule, cortical zones, and medulla of each adrenal gland. Tissue samples were then fixed in 10% neutral buffered formalin and processed for routine histology and cut (3 to 5 μ m) in a rotary manual microtome (LEICA RM 2125RT). The specimens were then stained with heamatoxylin and eosin (Culling, 1974). For histometric investigations the sections were selected on the basis of technical quality (Weibel, 1963), the selected sections were used to determine the thickness of Ca, cortical zones, ZG, ZF and ZR and M (Fig. 1, 2, 3 and 4). Light microscope (Olympus BX51-Japan) equipped with the objective lenses X4 and X10 and connected to a digital camera (Olympus DP20-Japan) was used. The measurements were taken according to the guidelines given by (Thienport *et al.*,

[Type text]

1986). Three measurements of each part of the adrenal gland were recorded and the averages for each were calculated. Then the averages for three slides were calculated. The data were statistically analyzed using ANOVA test for ZG,

ZF and ZR; t-test for right and left Ca, Co and M using SPSS software (version21). The differences were considered statistically significant at $P < 0.05$.



Figs. 1-4 showing the histometric measurements of the capsule, cortical zones and medulla on H&E Stained microphotographs; Fig.1: Measurements of the capsule (Ca) and zona glomerulosa (ZG); Fig.2: Measurements of the zona fascicula (ZF); Fig.3: Measurements of the zona reticularis (ZR); Fig.4: Measurements of the medulla (M).

**Results:**

The histometric measurements of the right and left adrenal gland are shown in tables 1-6 and text figures 1-6.

Thickness of the right adrenal gland layers:

The mean thickness measurements of the right adrenal cortical zones were as follows: RZG was 0.613 ± 0.421 mm, RZF was 1.94 ± 1.425 mm and RZR was 0.787 ± 0.553 mm. The statistical analysis showed that RZF was significantly thicker than RZG and RZR ($P < 0.05$). On the other hand RZG and RZR were approximately equal in thickness. The mean thickness of the RZG constituted 18.2% of the total cortical thickness, RZF was 58.5% and RZR was 23.3%.

The RCo (3.28 ± 2.616 mm) was significantly thicker than the RM (2.924 ± 1.497 mm) ($P < 0.05$). The RCo formed 56.4% of the total gland thickness, while RM constituted 43.6 %.

Thickness of the left adrenal gland layers:

The mean thickness measurements of the left adrenal cortical zones were as follows: the LZG was 0.312 ± 0.5 mm, the LZF was 1.847 ± 1.293 mm and the LZR was 0.635 ± 0.493 mm. There were significant differences in the mean thickness of the cortical zones ($P < 0.05$). The mean thickness of the LZF was greater than the other two cortical layers. The LZG and LZR were approximately equally in thickness. The mean thickness of the LZG constituted 16.5% of the total cortical thickness, the LZF was 61.9% and the LZR was 21.6%.

The mean thickness of the LCo was 2.959 ± 2.134 mm while the mean thickness of the LM

was 2.304 ± 1.265 mm which showed significant differences ($P < 0.05$). The mean thickness of the LCo was greater than the mean thickness of the LM.

The mean thickness of the LCo formed 58.0 % of the total glandular thickness, while the mean thickness of the LM was 41.9 %.

Comparison between the thickness of the layers of the right and the left adrenal glands:

The mean thickness of the RCa was 0.281 ± 0.242 mm, whereas the mean thickness of the LCa was 0.275 ± 0.238 mm which showed insignificant differences ($P > 0.05$). The correlation between the mean thickness showed that the mean thickness of the RCa was greater than the LCa.

There was insignificant increase ($P > 0.05$) in the mean thickness of the RCo compared to that of the LCo.

The mean thickness of the RM was insignificantly increased ($P > 0.05$) compared to the thickness of the LM.

The statistical analysis showed a significant increase in the mean thickness of the RZG compared to the LZG ($P < 0.05$) and significant increase between RZR compared to the LZR ($P < 0.05$); however, there was insignificant increase ($P > 0.05$) in the RZF in comparison with LZF and the mean thickness of the RZF and LZF was greater than other two cortical layers.



Table 1: Showing the mean thickness (mm) of The cortical zones of the camel right adrenal gland

	Sum of Squares	df	Mean Square	F	Sig.
Between Groups	6.557	2	3.278	214.516	.000
Within Groups	.321	21	.015		
Total	6.877	23			

Text- Fig. 1: Thickness (mm) of the cortical zones: zona glomerulosa (ZG), zona fasciculata (ZF) and zona reticularis (ZR) of the camel right adrenal gland

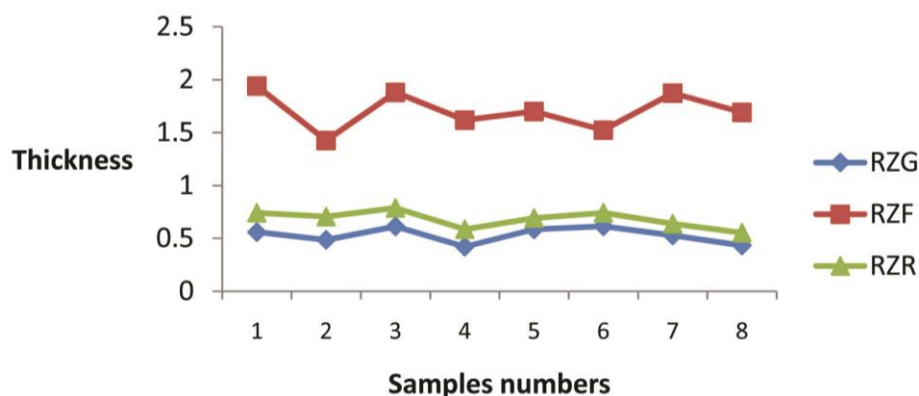


Table 2: Showing the mean thickness (mm) Of the cortex (Co) and medulla (M) of the camel right adrenal gland



[Type text]

	Gland	N	Mean	Std. Deviation	Std. Error Mean
Reading	RCo	8	2.91438	.261539	.092468
	RM	8	2.25187	.401566	.141975

Text- Fig.2: Thickness (mm) of the cortex(Co) and medulla(M) of the camel right adrenal gland

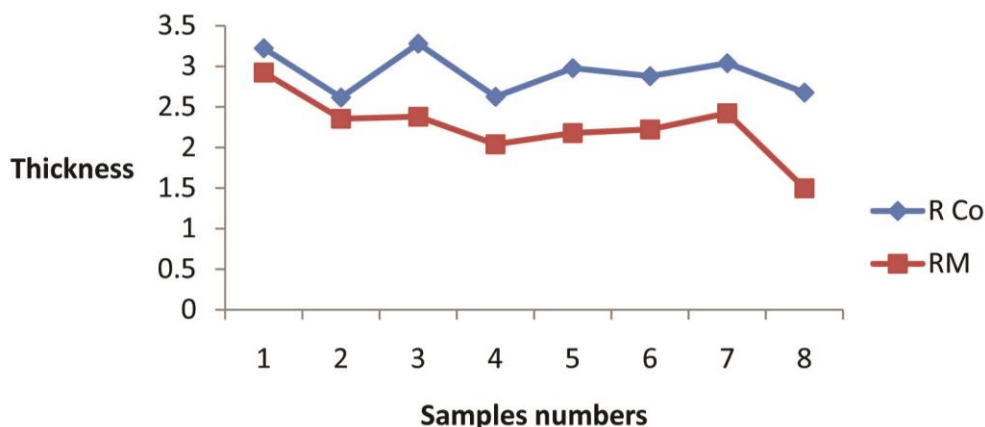


Table 3: Showing the mean thickness (mm) of the cortical zones of the camel left adrenal gland

	Sum of Squares	df	Mean Square	F	Sig.
Between Groups	6.389	2	3.194	198.386	0.000
Within Groups	.338	21	.016		
Total	6.727	23			



[Type text]

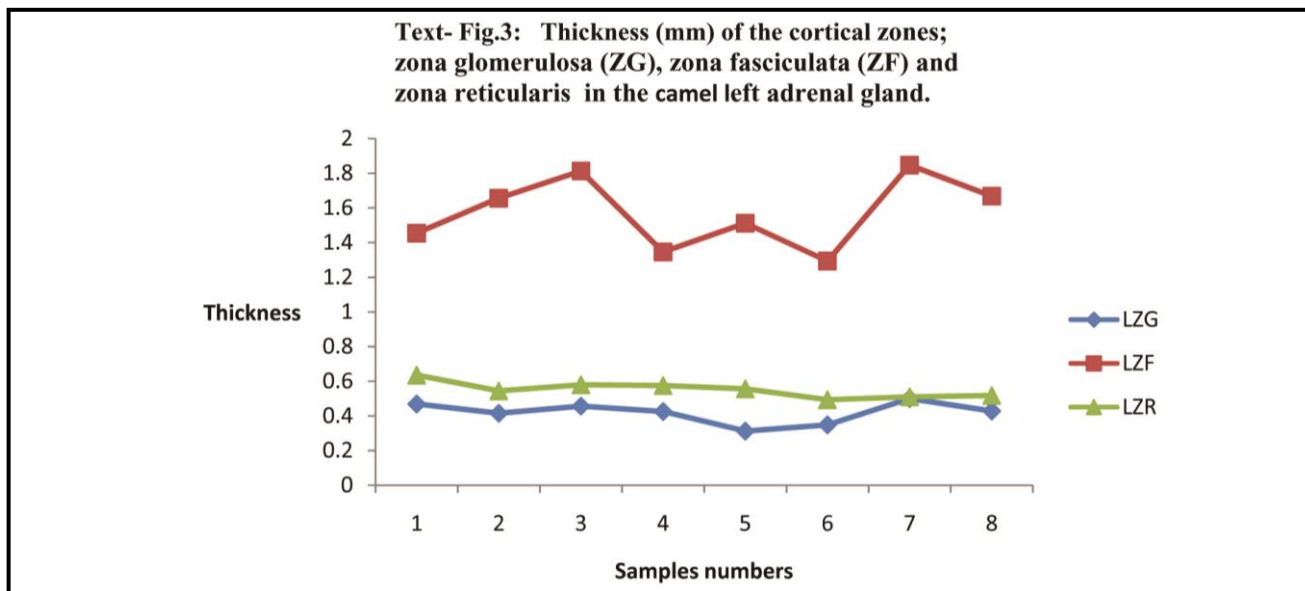


Table 4:S howing the mean thickness (mm) of the cortex (LCo) and medulla(LM)of the camel left adrenal gland

	Gland	N	Mean	Std. Deviation	Std. Error Mean
readings	LCo	8	2.55687	.269336	.095225
	LM	8	1.84663	.413049	.146035

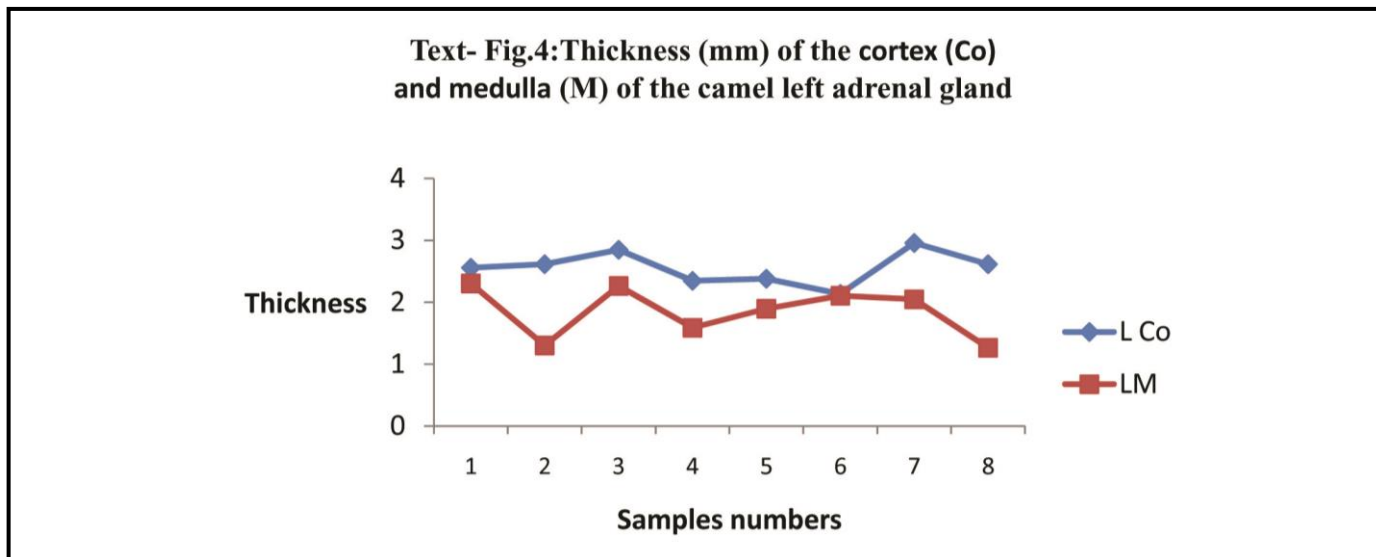


Table 5 : Showing the mean thickness (mm) of the capsule(Ca), cortex (Co) and medulla(M) of the camel right and left adrenal glands

Segment	Right	Left	P value
capsule	265.9	252.3	0.06
Cortex	2914.4	2556.6	0.17
Medulla	2251.9	1846.6	0.07

[Type text]

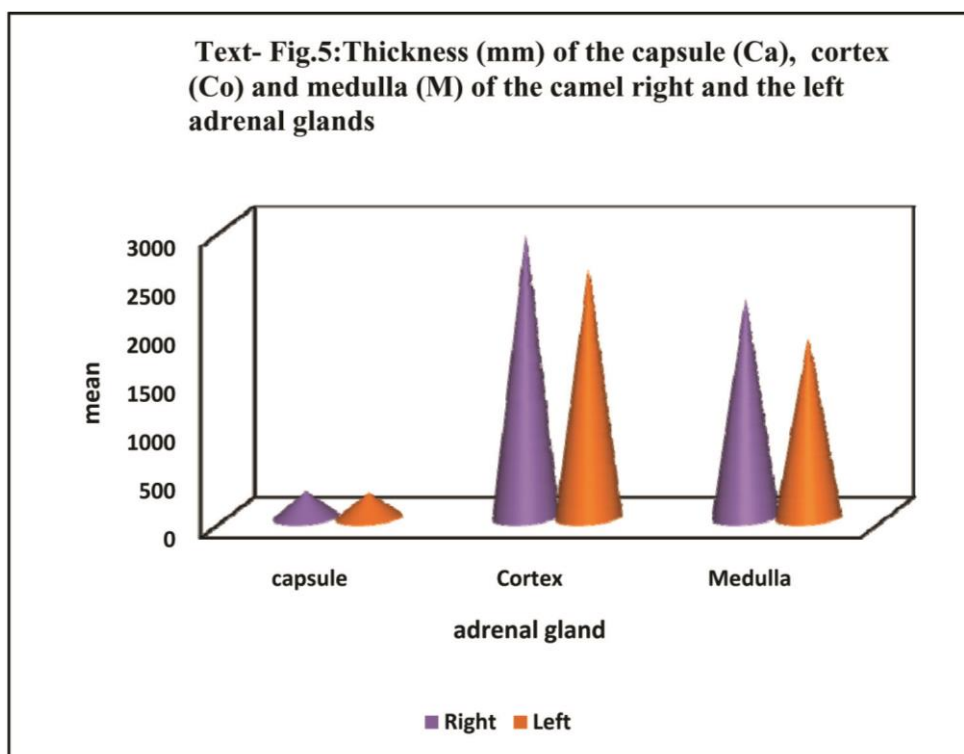
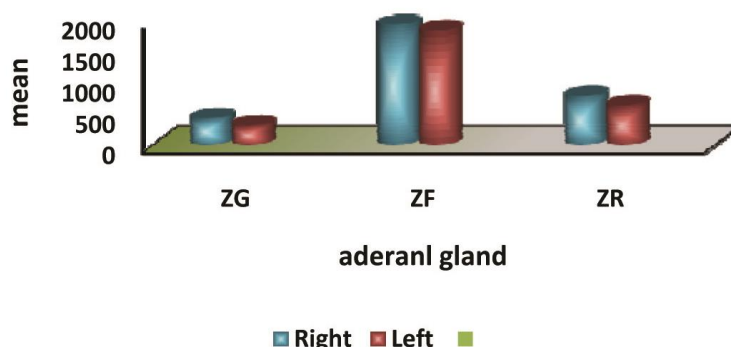


Table 6: Showing the mean thickness (mm) of the cortical zones of the camel right and left adrenal glands

	ZG	ZF	ZR	P value
Right	424	1940	787	0
Left	312	1847	635	0
P value	0.007	0.194	0.002	

Text- Fig.6:Thickness (mm) of the cortical zona glomerulosa (ZG), zona fasciculata (ZF) and zona reticularis in the camel right and left adrenal glands



Discussion:

According to the literature reviewed the current investigation is the first report regarding the adrenal gland histometry in dromedary camels.

The dromedary camels in the present study have paired adrenal glands (right and left), each lying cranio-medial to the corresponding pole of the kidney. This has also been reported in other animals as claimed by Dyce *et al.* (1996), Hussain and Qureshi (2007), Dangi *et al.* (2008), Chima and Blessing (2009), Florina *et al.* (2010), Mescher (2013); König and Liebich (2014); Barszcz *et al.* (2016); Olukole *et al.* (2016); Santosa *et al.* (2016); Abass (2017). Nabipour *et al.* (2008) noted that the adrenal glands of the dromedary camel were situated near the pole of the kidneys.

Histologically, the mammalian adrenal gland was composed of two distinct layers which were cortex and medulla and covered by a connective tissue capsule; the cortex consisted of three histological zones named as ; ZG, ZF and ZR (Bacha and Bacha, 2000; Opałka *et al.*, 2001; Chima and Blessing, 2009; Florina *et al.*, 2010; Jelinek and Konecny, 2011; Parchami and Dehkordi, 2011; Mescher, 2013; Monfared *et al.*, 2013; Obike *et al.*, 2014; Sheikhian *et al.*, 2014; Barszcz *et al.*, 2016; Ross and Pawlina, 2016; Santosa *et al.*, 2016; Olukole *et al.*, 2016; Abass, 2017). The present results showed that the adrenal gland as in the other mammalian species was covered by a thick connective tissue capsule and divided into outer cortex which was subdivided into three zones; ZG, ZF and ZR and inner medulla. This also



[Type text]

confirmed the findings of Ali (1987), Nabipour *et al.* (2008) and Ibraheem *et al.* (2011) in the dromedary camel.

The present results showed that there was in-significant increase in the right glandular capsule than that in the left capsule (LCa). In Bactrian camels the mean thickness of the capsule was found to be greater than that in the dromedary camel (Ye *et al.*, 2017).

The current investigation shows that there was significant increase in the mean thickness of the RZG compared to the LZG and significant increase in the RZR compared to the LZR; also in the present study, an in-significant increase was observed in the RZF compared to the LZF and the mean thickness of the RZF and LZF was greater than other two cortical layers. Earlier reports has shown that the ZF in right and left adrenal glands was thicker than the other two cortical zones in both R and L adrenal glands in the goats (Qureshi *et al.* 2013), rat (Akers and Denbow, 2013; Monfared, 2013; Olukole *et al.*, 2016), mice (Monfared *et al.*, 2013), guinea pig and hamster (Sheikhian *et al.*, 2014) and Bactrian camel (Ye *et al.*, 2017). It has been found that the mammalian adrenal gland ZG was thicker than the ZR (Qureshi *et al.*, 2013, Akers and Denbow (2013), Monfared (2013) and Olukole *et al.* (2016), in rat, Monfared *et al.* (2013) in mice, and Ye *et al.* (2017) in Bactrian camel. However, in the present findings the ZR was thicker than the ZG in right and left adrenal glands.

In the current results there was in-significant increase in the mean thickness of the RCo compared to that in the LCo and the mean thickness of the RM was in-significantly

increased compared to the thickness of the LM. Similarly, Sheikhian *et al.* (2014) stated that the mean thickness of the Co was greater than that in the M of both sides R and L of the glands in guinea pig and hamster. However, Stacey (2007) reported that the M was thicker than the Co in human.

Conclusion

In conclusion, the present study showed that the ZF was the thickest zona in the cortex of camel adrenal gland followed by the ZR, and the ZG was the thinnest in both right and left glands; the cortex was generally thicker than the medulla in either side. Moreover, the glandular capsule, cortical zones and medulla of the right adrenal glands are collectively thicker than those in the left one.

References:

- Abass, Th . A. (2017): Anatomical and histological study of adrenal gland in new natal and adult guinea pig (*Caviaporcellus*)., Kufa Journal For Veterinary Medical Sciences, 8(1):181 - 192.
- Abdalla, M.A. and Ali. A.M. (1988): Morphometric and histological studies on the adrenal glands of the camel (*Camelus dromedarius*). Acta morphologica Neerlando- Scandinavica, 26(4): 269- 281.
- Akers, R.M. and Denow, D. M.(2013): Anatomy and Physiology of Domestic Animals.Ch12, pp357-360. 2nd Ed. Blackwell USA.
- Ali. A. M. (1987): Histological and Morphometric studies of some endocrine glands of The camel (*Camelus Dromedarius*) . Master of Veterinary Science.University of Khartoum.



[Type text]

Bacha, W. J and Bacha, L. M. (2000): Color Atlas Of Veterinary Histology. pp 191-200. 2nd Ed A

Wolters Kulwer Company. Philadelphia, Baltimore, New York and London.

Barszcz, K, Przespolewska, H, Olbrych, K, Czopowicz, M, Klećkowska-Nawrot, J, Goździewska-

Harłajczuk, K and Kupczyńska, M. (2016) :The morphology of the adrenal gland in the European bison (*Bison bonasus*). *BMC Veterinary Research*, 12: Article 161(1-11).

Bielohuby, M., Herbach, N., Wanke, R., Maser-Gluth, C., Beuschlein, F., Wolf, E. and Hoeflich, A. (2007): Growth analysis of the mouse adrenal gland from weaning to adulthood: time- and gender-dependent alterations of cell size and number in the cortical compartment. *American Journal of Physiology- Endocrinology and Metabolism*, 293: 139-146.

Chima, N. I. and Blessing, F. (2009): Morphological Features of fetal And Adult Adrenal glands In Kano Brown Goats (*Capra hircus*). *Animal Research International*, 6(1): 953-957.

Culling, C.F.A. (1974): Handbook of Histopathological and Histochemical Techniques. 3rd Ed.

London: Butterworth and Co. Ltd.

Dangi, A., Joshi, S., Mathur, R. and Nama, K.G. (2008): Gross and morphological studies on adrenal gland of goat in semi arid zone. *Veterinary Practitioner*, 1: 25-26.

Dyce, K.M., Sack, W. O. and Wensing, C.J.G. (1996): Textbook Of Veterinary Anatomy. Philadelphia. 2^{ed} Ed. London. New York. Sydney and Toronto. pp, 213-214.

EL - Sayed, S., Ibrahim, S. N., Tawfik, M. K. and Ekladios, E. Y. (1990): Histological,

Histochemical and Morphometric Changes Of the Contralateral

Adrenal Gland After Unilateral Adrenalectomy. *Sci. Med. J. Cai Med. Synd*, 2(4):89-100.

Florina, P., Nada, M., Maja, J., Vlatko, I., Lazo, P. and Katerina, B. (2010):

Morphofunctional Characteristics Of the Adrenal Cortex In Testotomised Rats Acclimated On Different Ambient Temperature. *Macedonian Veterinary Review*, 33(1): 25 - 32.

Hui, X., Akahira, J., Suzuki, T., Nio, M., Nakamura, Y., Suzuki, H., Rainey,

W.E and Sasano, H. (2009) :Development of the human adrenal zona reticularis: morphometric and immunohistochemical studies from birth to adolescence. *Journal of Endocrinology*, 203: 241-252.

Hussain, R and Qureshi, A. S. (2007) :Age related changes in the morphometric parameters of the

Heart, Kidneys and Adrenal glands of Nili-Ravi buffalo (*Bubalus bubalis*). *Italian Journal Of Animal Science*, 6(2): 995-998.

Ibraheem, A.H., Al-Samarrae, N.S., Bader, K.H and Maher, W. (2011): Histological study for the innervations of the adrenal gland of the Camel (*Camelus dromedaries*). *Tikrit Journal of Pure Science*, 16(2): 1-3.

Jelinek, F. and Konecny, R. (2011): Adrenal glands of slaughtered bulls, heifers and cows: a histological study. *Anatomia, Histologia, Embryologia*, 40(1):28-34.

Karakurum, E., Özgel, Ö. and Dursun, N. (2008): Morphology and Arterial

Vasculature of Donkey (*Equus asinus* L.) Adrenal Gland. *Turkish Journal Of Veterinary and Animal. Sciences*, 32(6): 469-473.

Kigata, T and Shibata, H. (2018): Arterial supply to the rabbit adrenal gland.

Anatomical Science International, 93(4): 437-448.



[Type text]

- KÖnig , H.E and Liebich, H.G. (2014) : Veterinary Anatomy of Domestic mammals. Textbook and Colour Atlas.6th ED. pp 575-578. SchattawerGmb H Germany New York.
- Mescher, A. L. (2013): Junqueira S Basic Histology Text and Atlas. Ch 20, pp 414-418 .13th Ed, New York, San Francisco, London and Toronto.
- Monfared , A.L.(2013) :Histological and Histometrical Examination in Assessment of Potential Immune Modulator Properties of *Glycyrrhizaglabra* Extract in Rats .Global Veterinaria, **10**(4): 453-458.
- Monfared, A.L; Naward, S. H; Bahrami, A. M and Hosseini .E (2013):Histologic and histometric assessments of the potential formaldehyde immunotoxicity in the mice. European Journal of Experimental Biology, **3**(1):429-433.
- Nabipour, A ., Khanzadi, S. and Behdegani, A. (2008): Gross And Histological Studies On the Adrenal Gland In Camel (*Camelusdromedarius*). Journal of Camel Practice and Research, **15**(1):121-125.
- Obike, H. I., Ezejindu, D. N. and Akingboye A .J. (2014): The Effects Of AframomumMelegueta Aqueous Extract On The Adrenal Gland Of Adult Wistar Rats. International Journal of Research In Medical and Health Sciences, **3**(6): 2307-2083.
- Olukole, S. G.; Adeagbo, M. A.and Oke, B. O.(2016): Histology and histochemistry of the adrenal glandAfrican giant rat.(*Cricetomysgambianus*, Waterhouse).International Journal of Morphology,**34**(4):1455-1460.
- Opałka, M., Kamińska, B., Doboszyńska, T. and Dusza, L. (2001):The morphometric parameters of adrenal cortex in sows: in normal condition and after prolactin infusion. Folia Morphologica,**60**(4): 317-322.
- Parchami, A. and Dehkordi, R.F. (2011): Histological Study of Adrenal Gland in Male And Female Rabbits. American- Eurasian Journal Of Agricultural& Environmental Sciences, **10**(6): 1040- 1044.
- Qureshi, A.S. ,Shah, M., Rehan, S.,Raiz, H.P.andAmanUllah, H. (2013): Histomorphometrical Investigations on the Heart, Kidneys and Adrenal glands in Normal Teddy Goats (*Capra hircus*) Using Image Analysis System. PakistanVeterinary Journal, **33**(2):155-159.
- Robert.C.(1937): The Comparative Anatomy of the Thyroid and Adrenal glands in Wild Animals.Ohaio, Journal of Science,**37**(1): 42-61.
- Ross, M. H. and Pawlina, W .(2016) : Histology A Text and Atlas With Correlated Cell and Molecular Biology.Ch21, pp, 666 – 775. 7th Ed. Wolters Kluwer Company Philadelphia, London and New York.
- Santosa, A. C.,Vianaa , D. C. ,Bertassolib, B. M,Vasconcelosc, B. G. Oliveirad, D. M. ,Ricia, R. E. G ,Oliveirad, M. F. ,Miglinoa, M. A. and Assis-Netoa, A.C., (2016): Adrenal glands of Spix's yellow-toothed cavy (*Galeaspixii*, Wagler, 1831): morphological and morphometric aspects. Brazilian Journal ofBiology ,**76**(3): 645-655.
- Sheikhian, A, Saadatfar. Z. and Mohammadpour, A.A.(2014): A histological study of adrenal gland in guinea pig and hamster. Comparative Clinical Pathology,**24**(5):1069 -1074.



Thienport, D. ,Rochette, F. and Vanparijs, O.F.J .
(1986): Diagnosing Helminthiasis By
Corprological Examination. 2nd Ed. Beers,
Belgium.

Weibel, E.R. (1963): Principles and methods for
the volumetric and morphometric study of the lung
and other organs. *Journal of Laboratory
Investigation*, **12**:131-155.

Ye, W; Wang, F, Wang, H. and Wang ,J.(2017):
Morphology and ultrastrucure of the adrenal gland
in Bactrian Camels
(*Camelusbactrianus*).*Tissue and Cell*,**49**:285-295.