



**Sudan University of Science and Technology**

**College of Graduate Studies**



**Assessment of Patients with Right Upper Quadrant Pain using  
Ultrasonography**

**تقييم الم الربع الايمن العلوي باستخدام الموجات فوق الصوتية**

*A Thesis Submitted for Partial Fulfillment of the Requirements of  
M.Sc Degree in Medical Diagnostic Ultrasound*

By:

**Nour Ahmed Mohamed Ali Tabidi**

Supervisor:

**Dr. Hussein Ahmed Hassan**

2020

# الآية

قال تعالى:

﴿وَمَا تَوْفِيقِي إِلَّا بِاللَّهِ عَلَيْهِ تَوَكَّلْتُ وَإِلَيْهِ أُنِيبُ﴾

صدق الله العظيم

سورة هود الآية (88)

# Dedication

*This work is dedicated for my mother  
Soul and all my family and  
friends*

## **Acknowledgment**

The author would like to acknowledge and give thanks to Dr. Hussein Ahmed Hassan for his continuous support and assistance throughout the duration of this project and everyone else who offered help or advice.

## **Abstract**

This is a descriptive cross section study to assess patients affected with right upper quadrant pain. Study was conducted in Modern Medical Center, at ultrasound department carried out during the period from October 2018 to October 2019. The study conducted on 100 patients suffering from right upper quadrant pain by routine transabdominal ultrasound. The main objective of this study is to assess RUQ pain in Sudanese population using ultrasonography. The study was classified and analyzed by statistical package for social science (SPSS) software. The analysis results showed that (57%) cases females and (43%) cases males. The incidence was high among the age group (40-49) which represented (36%). Most of the patients presented with pain mild and moderate (75%). Most common finding was gall stone 42 patients (42%). The rest of findings included (13%) normal, (10%) bowel gasses, (7%) CBD stone, calculus cholecystitis, (5%), Acalculus cholecystitis (4%), pancreatitis (3%), and other finding like fatty liver, liver cyst, portal hypertension and hepatitis. The study found no significant difference between patients gender and gall bladder ultra sound findings  $p = 0.019$ , also was no significant different between gender and liver ultrasound findings  $p = 0.007$ . The study concluded that ultrasound can assess right upper quadrant pain and provides excellent details about the findings in patients. And recommended that transabdominal ultrasonography should be use as routine examination for high risk patient affected with right upper quadrant pain.

## ملخص البحث

هذه دراسة وصفية مقطعية لتقييم المرضى المتضررين من ألم الربع العلوي الأيمن للبطن . أجريت الدراسة على 100 مريض يعانون من ألم الربع العلوي الأيمن بواسطة الموجات فوق الصوتية بطريقة جدار البطن الروتينية اجريت الدراسة خلال الفترة من أكتوبر 2018 - أكتوبر 2019 وقد تم اجراء الدراسة في المركز الطبي الحديث قسم الموجات فوق الصوتية ، الهدف الرئيسي من هذه الدراسة هو تقييم هذا الالم باستخدام الموجات فوق الصوتية. وقد صنفت الدراسة وتم تحليلها بواسطة الحزمة الإحصائية للعلوم الاجتماعية (SPSS) والبرمجيات. وأظهرت نتائج التحليل أن (57%) من الحالات من الإناث و (43%) من الحالات الذكور. وكان ارتفاع معدل بين الفئة العمرية (40-49) التي تمثل (36%) وقد كان شكل الالم في معظم المرضى الذين يعانون من الم خفيف الى متوسط وقد شكل نسبه) (75%) وذلك نسبه لقله عدد الحالات الشديده. وكان النتيجة الأكثر شيوعا حصوي المرارة (42%) بقية النتائج وشملت (13 % العادية، (10 % غازات الأمعاء، (7%) حصوي الصفراويه،و التهاب المرارةالذي تسببه الحصوي (5%)التهاب المرارة لاسباب اخرى (4%)والتهاب البنكرياس (3%) وغيرهامن العثور على مثل الدهنية الكبد،والكيس الكبد وارتفاع ضغط الدم البابي والتهاب الكبد. وجدت الدراسة علاقة ضعيفة بين المرضى بين الجنسين وحصوي المراره كما تم العثور على ارتباط ضعيف جدا بين الجنسين ونتائج الموجات فوق الصوتية للكبد. وخلصت الدراسة إلى أن الموجات فوق الصوتية يمكن تقييم ألم الربع العلوي ،ويقدم تفاصيل ممتازة عن النتائج في المرضى. وأوصت بأن الموجات فوق الصوتية بطريق جدار البطن يجب أن تستخدم لكل المرضى المتضررين مع ألم الربع العلوي الأيمن للبطن.

## List of contents

| Topic                            | page |
|----------------------------------|------|
| الإية                            | I    |
| Dedication                       | II   |
| Acknowledgment                   | III  |
| Abstract (English)               | IV   |
| Abstract (Arabic)                | V    |
| Table of contents                | VI   |
| List of tables                   | VIII |
| List of figures                  | IX   |
| List of abbreviations            | X    |
| <b>Chapter one</b>               |      |
| 1-1 Introduction                 | 1    |
| 1-2 Problem of the study         | 1    |
| 1-3 Objectives                   | 2    |
| 1-4 Hypothesis                   | 2    |
| <b>Chapter two</b>               |      |
| 2-1 Anatomy                      | 3    |
| 2-1-1 Anatomy of the liver       | 4    |
| 2-1-2 Anatomy of the gallbladder | 5    |
| 2-1-3 Pancreatic head            | 7    |
| 2-1-4 The bile duct              | 8    |
| 2-1-5 The duodenum               | 9    |
| 2-1-6 Hepatic flexure            | 9    |
| 2-2 Pancreatic Physiology        | 10   |
| 2-3 Pathology                    | 11   |
| 2-3-1 Liver Pathology            | 12   |

|  |    |
|--|----|
| 2-3-1-1 diffuse liver disease          | 12 |
| 2-3-1-2 focal liver disease            | 14 |
| 2-3-2 Gallbladder Pathology            | 18 |
| 2-3-3 Biliary tract Pathology          | 21 |
| 2-3-4 Pancreatic Pathology             | 22 |
| 2-4 previous studies                   | 27 |
| <b>Chapter three</b>                   |    |
| 3-1 Material                           | 30 |
| 3-2 methods                            | 30 |
| 3-3 scanning guide lines and protocols | 30 |
| 3-4 data analysis                      | 32 |
| 3-5 data presentation                  | 32 |
| 3-6 data storage                       | 32 |
| 3-7 ethical consideration              | 32 |
| <b>Chapter four</b>                    |    |
| 4-results                              | 33 |
| <b>Chapter five</b>                    |    |
| 5-1 Discussion                         | 46 |
| 5-2 concolution                        | 48 |
| 5-3 Recommendations                    | 49 |
| References                             | 50 |



## List of Figures

| Table NO | Title   | Page No |
|----------|---|---------|
| 4-1      | Frequency distribution of patients according to gender                                    | 33      |
| 4-2      | Frequency distribution of patients according to age                                       | 34      |
| 4-3      | Frequency distribution of patients according to residence                                 | 34      |
| 4-4      | Frequency distribution of patients according to pain                                      | 35      |
| 4-5      | Frequency distribution of patients according to GB<br>Ultrasound findings                 | 36      |
| 4-6      | Frequency distribution of patients according to liver<br>Ultrasound findings              | 37      |
| 4-7      | Frequency distribution of patients understudy according to<br>pancreas Ultrasound finding | 38      |
| 4-8      | Frequency distribution of patients understudy according to<br>CBD Ultrasound finding      | 39      |
| 4-9      | Frequency distribution of patient according to others<br>ultrasound findings              | 40      |
| 4-10     | Frequency distribution of patient according to all ultrasound<br>Findings                 | 40      |
| 4-11     | Cross tabulation between gender and GB ultrasound<br>Findings                             | 41      |
| 4-12     | Cross tabulation between gender and liver ultrasound<br>Findings                          | 42      |
| 4-13     | Cross tabulation between gender and Pancreas ultrasound<br>Findings                       | 43      |
| 4-14     | Cross tabulation between gender and CBD ultrasound<br>Findings                            | 44      |
| 4-15     | Cross tabulation between gender and Gasses bowel ultra<br>sound findings                  | 45      |

## List of Figures

| No   | Title   | Page No |
|------|---|---------|
| 2-1  | Showing contents of right upper quadrant (abdomen).                     | 3       |
| 2-2  | anterior view of the liver  | 4       |
| 2-3  | posterior-inferior surface of the liver                                 | 5       |
| 2-4  | Shows three hepatic veins.  | 5       |
| 2-5  | The gallbladder.  | 6       |
| 2-6  | Relation of Pancreas to the Liver and Duodenum                          | 8       |
| 4-1  | Frequency distribution according to gender                              | 33      |
| 4-2  | Frequency distribution according to pain                                | 35      |
| 4-3  | Frequency distribution according to gall bladder ultrasound<br>Findings | 36      |
| 4-4  | Frequency distribution according to liver ultrasound<br>Findings        | 37      |
| 4-5  | Frequency distribution according to pancreas ultrasound<br>Findings     | 38      |
| 4-6  | Frequency distribution according to CBD ultra sound<br>Findings         | 39      |
| 4-7  | Cross tabulation between gender and gall bladder<br>ultrasound findings | 41      |
| 4-8  | Cross tabulation between gender and liver ultrasound<br>Findings        | 42      |
| 4-9  | Cross tabulation between gender and pancreas ultrasound<br>Findings     | 43      |
| 4-10 | Cross tabulation between gender and CBD ultrasound<br>Findings          | 44      |
| 4-11 | Cross tabulation between gender and others ultrasound<br>Findings       | 45      |

## List of abbreviations

| Abbreviation | Meaning              |
|--------------|----------------------|
| CBD          | Common bile duct     |
| GB           | Gallbladder          |
| LUQ          | Left upper Quadrant  |
| RUQ          | Right Upper Quadrant |
| Th           | Thickness            |
| US           | Ultrasound           |
| W            | Width                |

# **Chapter One**

Introduction

## **1-1 Introduction**

The right upper quadrant(RUQ) extends from the median plane to the right of the patient and from umbilical plane to right ribcage,the structure lies on the right upper quadrant are: liver, gall bladder with biliary tree, duodenum, head of pancreas, hepatic flexure of colon. (<http://www.anatomy.med.umich.edu>,2014)

Ultrasound is fast technique, which can be brought to patient bedside and can give rapid information.(Stutton,2003) It has become one of the most widely used diagnostic tools in modern medicine, is relatively inexpensive and portable. Ultrasound is the technique which answers most of the clinical question posed in patient with suspected biliary tract pathology. Right upper quadrant pain is a common complaint that typically stimulates a workup of the hepatobiliary system, gallstone disease is one of the most common causes of RUQ pain. ([http://www. Edward, Bluth, Carol and Benson](http://www.Edward,Bluth,CarolandBenson.com),2007)

Differential diagnosis of RUQ pain: liver and gallbladder disease, bowel lesions, cardiovascular disease, renal disorders, infections, pregnancy, other considerations: Pain may be referred from nerves in the spinal column or peripheral nerves that supply the area and lesions associated with LUQ pain may occasionally present on the other side. Situs inverses occurs in 1 person in 10,000. ([http://www.right upper quadrant pain.edu](http://www.rightupperquadrantpain.edu),2014)

## **1-2 Problem of the study**

There is a high frequency of right upper quadrant pain among adults which encountered mostly in casualties and most of the clinics; diagnosis of the upper quadrant pain cause using ultrasound and cross-correlation of this diagnosis with clinical symptoms might help in the management and predication of the unknown cause of the upper quadrant pain prior examination.

### **1-3 Objectives**

#### **1-3-1 General objective**

To assess patients with right upper quadrant pain using ultrasound.

#### **1-3-2 Specific objectives**

- To find the causes of RUQ pain.
- To find the frequency of the RUQ ultrasound finding
- To find the cross-correlation between clinical symptoms and RUQ ultrasound findings.
- To determine the relationship between ultrasound findings of right upper quadrant pain and patient gender.

### **1-4 Hypothesis**

Most of patient with right upper quadrant pain have many differential diagnosis. The wide spread of right upper quadrant pain among adults makes the usefulness of ultrasound in determining the causes of right upper quadrant pain very important, since the importance of right upper quadrant structures in the body.

# **Chapter Two**

## **Theoretical Background & Previous Studies**

## 2-1 Anatomy

The right upper quadrant of the human abdomen, often abbreviated as RUQ, is used to refer to a portion of the abdomen that allows doctors to localize pain and tenderness, scars, lumps and other items of interest, the right upper quadrant extends from the median plane to the right of the patient, and from the umbilical plane to the right ribcage.

Important organs in the right upper quadrant are: Liver, Gall bladder with biliary tree, duodenum, head of pancreas, and hepatic flexure of colon.

(<http://www.en.wikipedia.org>,2014)

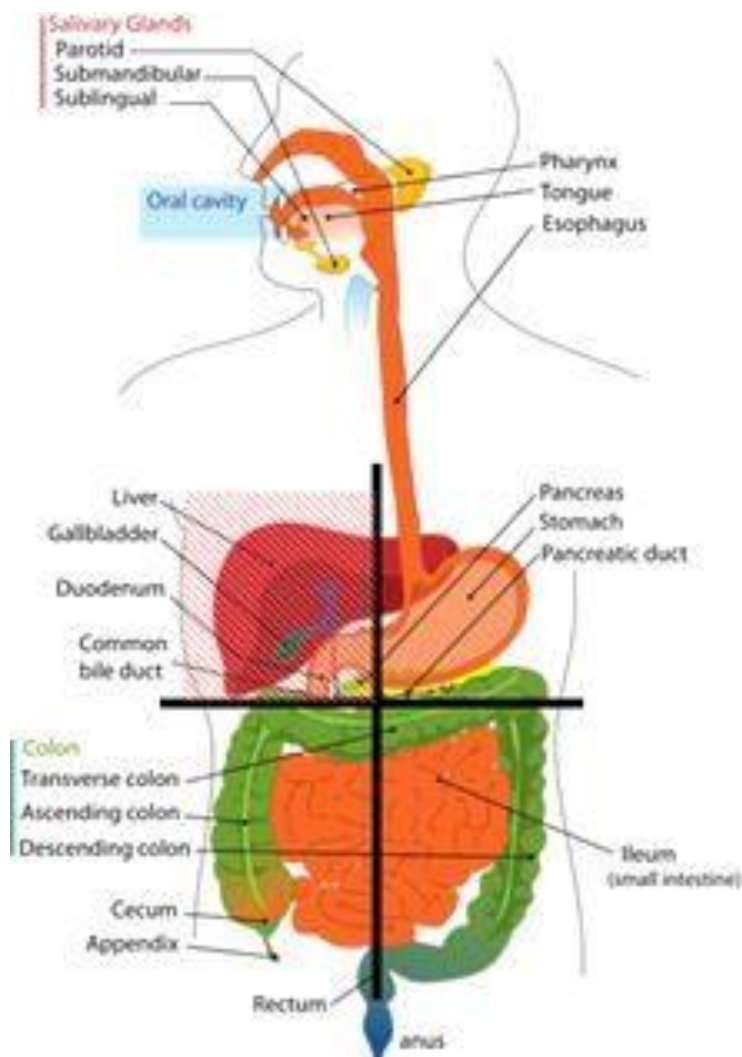


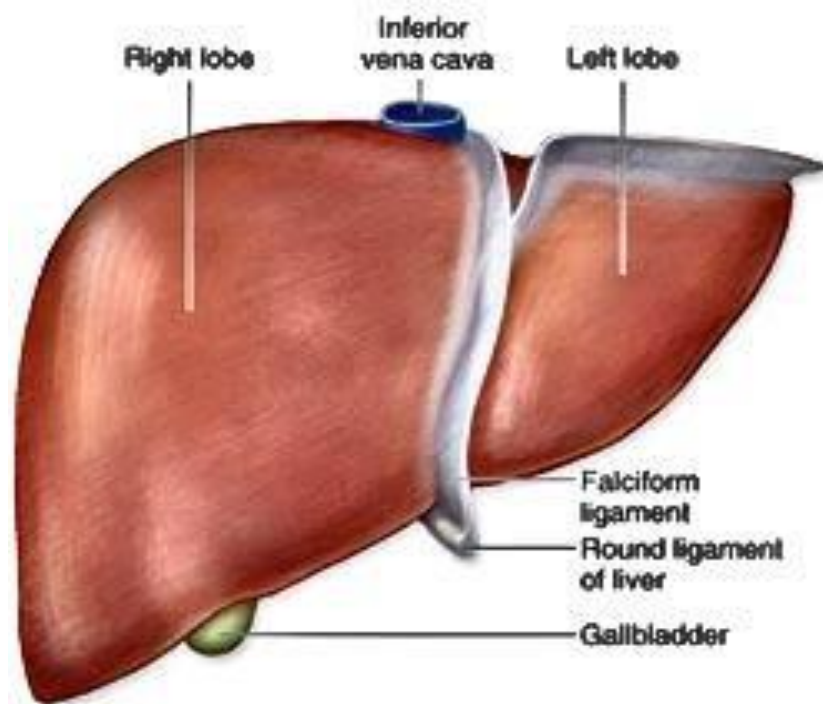
Figure (2-1) showing contents of right upper quadrant (abdomen).

(<http://www.en.wikipedia.org>,2014)



### 2-1-1 Anatomy of the liver

The liver is the largest internal organ and gland in the body, weighs approximately 1500g. The wedge shape organ occupies most of right hypochondrium and epigastrium region. It has two surface, diaphragmatic and visceral, the diaphragmatic surface is convex and descriptively subdivided into anterior, superior, posterior, and right surface. (Moore and et al, 2007)



Figure(2-2) show anterior view of the liver.

(<http://www.illionis.liver.org>.2014)

#### 2-1-1-1 The lobes of the liver

The liver is divided into a large right lobe and a small left lobe by the falciform ligament, the proportion between them being as six to one. Posterior surfaces being marked by three fossa: the portahepatis, the fossa for the gall bladder and inferior vena cava.

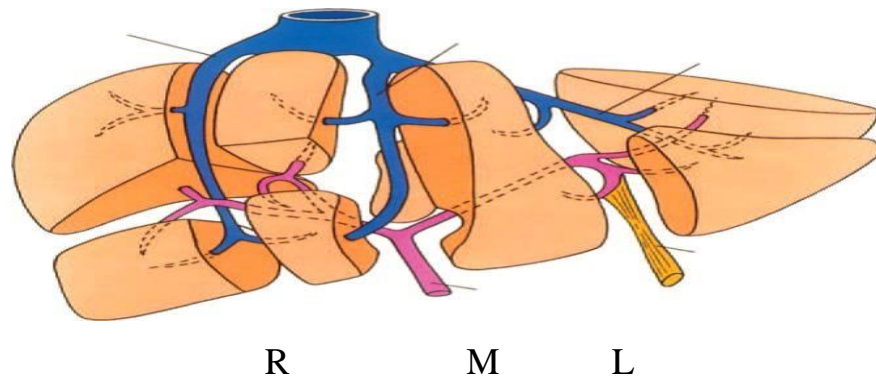
The caudate lobe is situated upon the posterior-superior surface of the liver on the right lobe of the liver; it is bounded on the left side by the

ligamentumvenosum; inferiorly by the portahepatis; on the right by the fossa for the ductusvenosum.

The left lobe is flattened which is situated in the epigastric and left hypochondriac regions. Its upper surface is slightly convex and its under surface presents the gastric impression and omental tuberosity.

The portahepatis, is found on the posterior inferior surface and lies between the caudate and quadrate lobes. In it lie the right and left hepatic ducts, the portal vein, the sympathetic and parasympathetic nerve fibers. (Petral, Willimas and et al,1992)

The liver receives a blood supply from hepatic artery and hepatic portal vein. The hepatic veins draining the blood from the liver, the hepatic veins empty into the IVC just superior posterior liver. (<http://www.uthsca.edu.at>)



Figure(2-3) shows three hepatic veins. (Bates,2004)

The principal lymphatic drainage is via: The celiac nodes into the cistern chili and the thorax to mediastinal trunks.

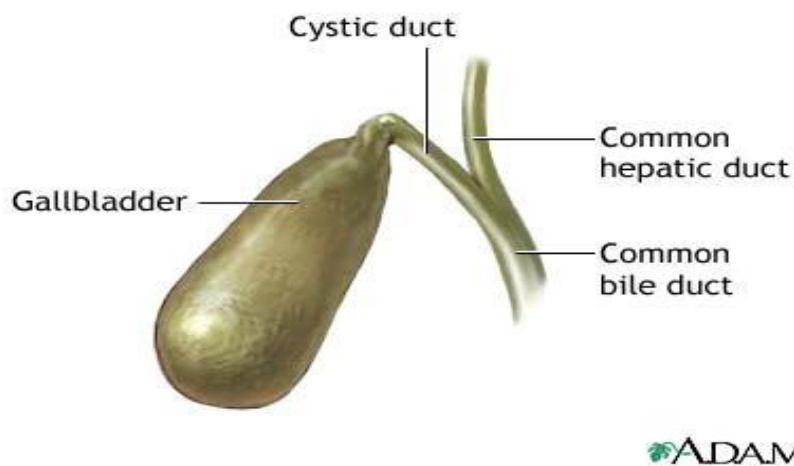
The nerves of the liver derive from the hepatic nerve plexus. It's accompanied by the branches of the hepatic artery and portal vein to the liver. It consists of sympathetic fibers and parasympathetic fibers. (Moore and et al, 2007)

### **2-1-2 Anatomy of the Gallbladder**

The gallbladder is a pear-shaped sac attached to the extrahepatic bile ducts by the cystic duct, it is very variable in size but normally measures up to 10 cm in length and 3 cm in diameter, it is described as having a fundus, body and neck, and it hangs on its bed on the visceral surface of the liver with its neck

lying superiorly and its fundus inferiorly a pouch called Hartmann's pouch on the ventral surface just proximal to the neck is seen when the gallbladder is dilated in disease, but is probably not normal anatomical feature.

The gallbladder is covered by peritoneum on its fundus and inferior surface, it may have a mesentery and hang free from the inferior surface of the liver, the mucosa lining the gallbladder is smooth except at the neck and the cystic duct, where it forms folds that are arranged spirally and called the valves of Heister. **(Ryan, McNicholas and Eustace,2004)**



Figure(2-4) the gallbladder. (<http://www.en.wikipedia.org>, 2014)

The gallbladder is supplied by the cystic artery, a branch of the right hepatic artery, and by branches that supply it directly from the liver in the gallbladder bed, blood from the gallbladder drains via small veins to the liver from the gallbladder bed. **(Ryan, Menicholas and Eustace,2004)**

Lymphatic channels from the gallbladder drain to node in the porta hepatic to the cystic node and to node situated at the anterior boundary of the epiploic foramen, from there lymph pass to the celiac group of pancreatic nodes.**(Ryan,Mcnicholas,andEustace,2004)**

### **2-1-3 Pancreatic Head**

The head is the key pancreatic structure; common bile duct stones, periampullary neoplasms, and pancreaticextrahepatic duct obstructions occur here. Failure to adequately visualize the pancreatic head is uncommon but usually avoidable technical failure.

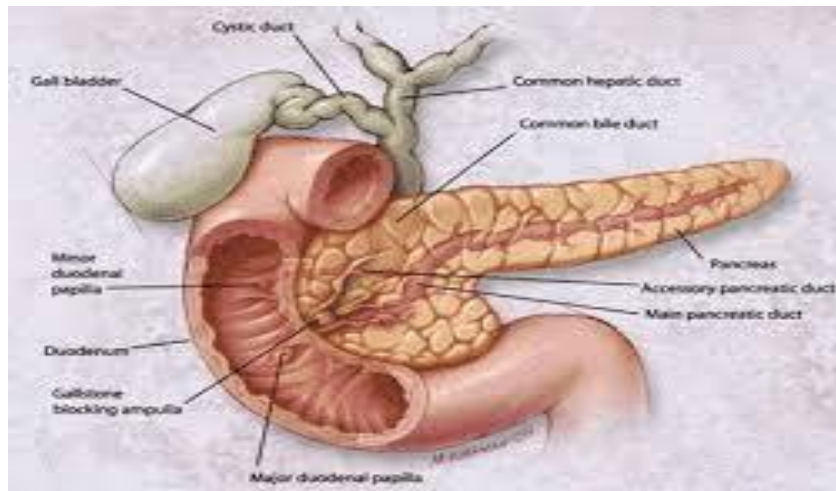
Supine compression imaging is useful but rarely allows demonstration of the periampullary region, vascular landmarks for the pancreatic head are the inferior vena cava (IVC) dorsally, the SMA and (SMV) medially, and the gastroduodenal artery (GDA) and the pancreaticoduodenal arcade anterolateral, the pancreatic head is usually directly ventral to the IVC. Cephalic to the pancreas, the IVC is adjacent to the portal vein; this location is the entrance into the lesser peritoneal sac, the epiploic foramen (foramen of Winslow). (Dean,2005)

The uncinate process (or uncinata) is a portion of the caudal pancreatic head that wraps around behind the SMA and SMV, ending in a point oriented medially, the uncinate process is medial and dorsal to the SMAand SMV. (Dean,2005)

The GDA is a landmark for the ventrolateral pancreatic head; the GDA courses between the pancreas and the second portion of the duodenum. (Dean, 2005)

Another useful vascular landmark for the pancreatic head and uncinate process is the gastroduodenal trunk (GDT), several splanchnic veins variably join to form the GDT,these often include the right or middle colic vein, right gastroepiploic vein, and pancreaticoduodenal veins. (Dean,2005)

The GDT enters the right side of the SMV just anterior to the pancreatic head, thus serving as a ventral landmark for the uncinate process. **(Dean,2005)**



Figure(2-6) Relation of Pancreas to the Liver and Duodenum (<http://www.missinglink.ucsf.edu>, 2014)

Blood is supplied from the splenic and the pancreaticoduodenal arteries; the corresponding veins drain into the portal system.

The lymphatics drain into nodes which lie along its upper border, in the groove between its head and the duodenum, and along the root of the superior mesenteric vessels. (Ellis.2006)

#### **2-1-4The bile duct**

The smallest biliary vessels are microscopic canaliculi; these canaliculi anastomose to form lobular bile ducts that are part of the portal triad. Eventually these small ducts anastomose to form left and right hepatic ducts which in turn join to form the common hepatic duct (CHD), the CHD is approximately 3 cm long. (Ryan, McNicholas and Eustace,2004)

It lies anterior to the main portal vein and lateral to the hepatic artery. These three structures travel in the free edge of the lesser omentum (the hepatoduodenal ligament portion), the common hepatic duct is known as the common bile duct (CBD) once it has joined the cystic duct from the gallbladder, and the CBD is approximately 7 cm long.

Within the lateral aspect of the pancreatic head it is joined by the pancreatic duct (of Wirsung) which together empty into the duodenum through the lumen of the duodenal papilla, controlled by a sphincter (of Oddi). The CBD

enters the duodenum opposite the uncinata process of the pancreas, this is the narrowest part of the biliary tract. The area where the pancreatic duct joins the CBD is the ampulla (of Vater). (Ryan, McNicholas and Eustace,2004)

The cystic duct joins the common bile duct at variable levels, usually 2-3 cm. below the portahepatis. It can join as high up as the porta or as low as within the pancreatic head,the common duct would then be a total of 10 cm in length.(Rayn,McNicholas and Eustace 2004)

Some variation in the intrahepatic ducts occurs in over 40% of cases, these vary more often than the extrahepatic ducts. (Ryan, McNicholas and Eustace,2004)

### **2-1-5 the duodenum**

The duodenum extends from the pylorus to the duodenojejunal flexure, where transition to the small bowel proper is marked by the assumption of a mesentery, the first 2.5 cm of duodenum, like the stomach, is attached to the greater and lesser omentum.(Ryan,McNicholas and Eustace,2004)

The duodenum curves in a C shape around the head of the pancreas, the first part is at the level of L1 lumbar vertebra, it is called the duodenal cap or bulb, passes superiorly, to the right and posteriorly from the pylorus,it is overlapped anteriorly by the liver and gallbladder.

The common bile duct, the portal vein and the gastroduodenal artery pass behind the first part of the duodenum and separate it from the inferior vena cava (IVC). Inferiorly it is in contact with the pancreatic head. (Ryan, McNicholas and Eustace,2004)

### **2-1-6 Hepatic flexure**

Hepatic (or the right colic) flexure is the sharp bend between the ascending

and the transverse colon, the right colic flexure is adjacent to the liver, and is therefore also known as the hepatic flexure. Thus, the left colic flexure is also known as the splenic flexure (as it is close to the spleen). The hepatic flexure lies in the right upper quadrant of the abdomen in humans. (Error! Hyperlink reference not valid., 2014)

## **2-2 Physiology**

### **2-2-1 The liver**

The liver performs numerous functions are: production of bile, metabolic function (Albumin synthesis, amino acids synthesis, fibrinogen, prothrombin and heparin synthesis, proteins metabolism, fat metabolism, and carbohydrate metabolism), storage, detoxification of blood, and reticuloendothelial function. (Dean, 2005)

### **2-2-2 The gallbladder**

The relatively watery bile from the liver is stored in the gallbladder, concentrated by the absorption of water and electrolytes, rendered more alkaline by the secretion of bicarbonate. (Dean 2005)

The discharge of gallbladder bile with stimulated by the entry of food into the duodenum, particularly fatty foods. This involves concentration of the gallbladder accompanied by relaxation of the sphincter of Oddi, a response mediated by cholecystokinin. Initially the gallbladder discharges only a proportion of its contents, and thereafter small quantities are passed at intervals the presence of clay colored, bulky, offensive smelling stools. (Dean, 2005)

### **2-2-3 Pancreatic Physiology**

Although the pancreas is both an exocrine (digestive) gland as well as an endocrine gland, only its endocrine function. The hormone-producing cells of the pancreas are called islets of Langerhans (pancreatic islets they contain alpha cells that produce glucagon and beta cells that produce insulin.

### **2-2-3-1 Insulin**

Insulin increases the transport of glucose from the blood into cells by increasing the permeability of cell membranes to glucose, Insulin is also important in the metabolism of other food types; it enables cells to take in fatty acids and amino acids to use in the synthesis of lipids and proteins (not energy production).

Insulin is a vital hormone; we cannot survive for very long without it. A deficiency of insulin or in its functioning is called diabetes mellitus. Secretion of insulin is stimulated by hyperglycemia, a high blood glucose level. (William and Ganong, 2001)

### **Glucagon**

Glucagon stimulates the liver to change glycogen to glucose and to increase the use of fats and excess amino acids for energy production. The process of gluconeogenesis. The overall effect of glucagon, therefore, is to raise the blood glucose level and to make all types of food available for energy production. The secretion of glucagon is stimulated by hypoglycemia, a low blood glucose level. (William and Ganong, 2001)

The cells that produce the exocrine secretions are grape-like in appearance. The main pancreatic enzymes are amylase which aids in the digestion of carbohydrates, lipase which can complete the digestion of fats and trypsin which aids in the digestion of proteins. (William and Ganong, 2001)

### **2-3 Pathology**

Description of the right upper quadrant pain

Pain in the right upper quadrant (RUQ) can be caused by a wide variety of conditions. The age, gender and general condition of the patient will influence the likely diagnosis, history and examination will also focus the differential diagnosis. Features such as acute or chronic onset, weight loss, pyrexia, general malaise, and urinary or bowel symptoms may all help point to a diagnosis.



Pain felt in the right upper region of the abdomen known as the right upper quadrant, or RUQ often arises from organs in this area. However, other, more distant organs may also direct pain to this region. ([http:// www.medhelp.org](http://www.medhelp.org), 2014)

### Causes of upper Right Abdominal Pain

Right upper quadrant pain can have a variety of causes. These causes are usually related to the underlying organ, tissue, muscle, or, rarely, bone. Pain can be referred to the right upper quadrant from several different places outside of the abdomen.(20)

Liver disorders. Gallbladder disorders, gastric diseases., cardiovascular disorders, respiratory diseases, pelvic Inflammatory disease, Infectio, pregnancy (Dean,2005)

### **2-3 -1 Liver Pathology**

#### **2-3-1-1 Diffuse Liver Disease**

These are changes which involve the entire liver producing an overall change in echogenicity and liver size. The most common abnormality observed is a generalized increase in the echogenicity of the liver parenchyma.

A less common diffuse involvement of the liver is an overall decrease in echogenicity. Multiple hypoechoic poorly attenuating masses may be seen with primary non-Hodgkin's lymphoma of the liver or lymphoma associated with AIDS. (Dean,2005)

#### **Fatty Infiltration (Steatosis)**

The accumulation of fats within the hepatocytes results in a fatty liver. This is an acquired reversible disorder meaning that once the underlying disorder is corrected the liver will return to normal. Liver function tests are usually normal.

The most common causes of fatty infiltration are obesity and chronic alcoholism. Less common causes are: diabetes, excess corticosteroids, pregnancy, total parenteral hyperalimentation (I.V. feedings), glycogen

storage disease, cystic fibrosis, several chemotherapeutic agents, intestinal bypass surgery and toxins such as carbon tetrachloride. (Bates,2004)

## **Cirrhosis**

Cirrhosis is a diffuse process characterized by cell death, fibrosis and nodular regeneration. The normal liver architecture is replaced with structurally abnormal nodules.

Alcohol is the most common cause of liver cirrhosis in the adult population. Chronic viral hepatitis, glycogen storage disease and parasite infestation are also causes of liver cirrhosis , Liver cell damage due to the effects of prolonged liver obstruction can cause cirrhosis.

The classic clinical presentation of cirrhosis is hepatomegaly, jaundice, and ascites. However, serious liver injury may be present without clinical clues. In fact, only 60% of patients with cirrhosis have signs and symptoms of liver disease.(Bates,2004 )

The earliest stages of alcoholic cirrhosis (Laennec's Disease) are characterized by fatty changes in the liver cells. Typically the disease progresses into cell death, fibrosis, and nodular formation.

Advanced cirrhosis is characterized by a shrunken nodular liver. Hepatic circulation is compromised resulting in portal hypertension. Cirrhotic livers have an increased risk of hepatocellular carcinoma (hepatoma). Cirrhosis can compress the hepatic veins resulting in hepatic vein occlusion (the Budd-Chiari syndrome). (Dean,2005)

## **Acute Viral Hepatitis**

The patient may be jaundiced and suffer from anorexia, nausea and fatigue. The liver is often enlarged and tender. There will be a marked increase in the AST and ALT levels indicating hepatic necrosis of an acute nature.(Dean,2005)

## **Chronic Hepatitis**

Chronic hepatitis exists where there is clinical or biochemical evidence of hepatic inflammation for at least 3 to 6 months. Chronic active hepatitis is the severe form and often progresses to cirrhosis and liver failure.

### **(Dean,2005) Passive Congestion of the Liver**

Patients with right heart failure and elevated systemic venous pressure developed marked dilatation of the intrahepatic veins, which produce significant liver function test abnormalities. These patients are frequently referred for ultrasound evaluation. (Dean,2005)

## **2-3-1-2 FOCAL LIVER DISEASE**

### **Echinococcal (Hydatid) Liver Disease**

The most common cause of hydatid disease in humans is infestation by the parasite *Echinococcus granulosus*, which has a worldwide distribution. It is most prevalent in sheep- and cattle-raising countries, notably in the Middle East, Australia, and the Mediterranean. Endemic regions in the United States include the central valley in California, the lower Mississippi River Valley, Utah, and Arizona. Northern Canada is also endemic. *E. granulosus* is a tapeworm 3 to 6 mm in length that lives in the intestine of the definitive host, usually the dog. Its eggs are excreted in the dog's feces and swallowed by the intermediate hosts sheep, cattle, goats, or humans. (Kumar and et al, 2003)

### **Congenital Liver Cysts**

#### **Benign Hepatic Cysts**

A liver cyst is defined as a fluid-filled space with an epithelial lining. Abscesses, parasitic cysts, and posttraumatic cysts therefore are not true cysts. The frequent presence of columnar epithelium within simple hepatic cysts suggests they have a ductal origin, although their precise cause is unclear. Their presentation at middle age is also unclear. Although once thought to be relatively uncommon, ultrasound examination has shown that

liver cysts occur in 2.5% of the general population, increasing to 7% in the population older than 80 years. (Kumar and et al, 2003)

### **Autosomal Dominant Polycystic Renal Disease – ADPRD**

The adult form of polycystic kidney disease is inherited in an autosomal dominant pattern. Liver cysts are associated with this condition in 57% to 74% of patients. No correlation exists between the severity of the renal disease and the extent of liver involvement. Liver function tests (LFTs) are usually normal and, unlike the infantile autosomal recessive form of polycystic kidney disease, there is no association with hepatic fibrosis and portal hypertension. Indeed, if LFTs are abnormal, complications of polycystic liver disease, such as tumor, cyst infection, and biliary obstruction, should be excluded. (Kumar and et al, 2003)

### **Cavernous Hemangiomas**

Cavernous “hemangiomas consist of multiple channels that are lined by a single layer of endothelium and separated and supported by fibrous septae. The vascular spaces may contain thrombi.” (Bates,2004)

These are the most common benign liver tumor occurring in approximately 4% of the population. They are 5 times more common in females and may enlarge during pregnancy or with estrogen treatment.(Bates,2004 )

### **Liver Cell (Hepatic) Adenomas (LCA)**

Hepatic adenomas tend to occur in women using oral contraceptives and in patients with type I glycogen storage disease. These benign lesions consist of normal or slightly atypical hepatocytes. They contain few, if any, Kupffer cells and therefore produce a cold technetium sulfur colloid scan. Hepatic adenomas may undergo malignant transformation to hepatocellular carcinoma. They also have a tendency to rupture and may present with abdominal pain and/or with peritoneal bleeding if rupture of Glisson’s capsule has occurred. For these reasons surgical resection is recommended. (Dean,2005)

## **Focal Nodular Hyperplasia (FNH)**

After hemangiomas, FNH is the second most common benign liver mass. This is a benign hamartoma (an overgrowth of normal cells in an abnormal arrangement). FNH is more common in females, especially of childbearing age. There is no malignant potential and no tendency to rupture. To date, it is not possible to distinguish between FNH and LCA by ultrasound appearances alone. (Dean,2005)

## **Pyogenic Abscess**

The classic signs and symptoms of an infection are fever, chills and pain. Often there will be an elevated white blood cell count and if a differential is done there will be a rise in the number of neutrophils.

A positive ("hot") gallium 67 scan will be demonstrated providing the abscess is not sterile. Pyogenic abscesses usually occur as a complication of an existing condition. Bacteria gain entrance to the liver via the portal triad vessels. Ascending cholangitis due to biliary obstruction, cholecystitis, bacteria in the portal vein from gut infections and septicemia via the hepatic artery are common causes and routes for bacterial invasion of the liver. (Dean,2005)

## **Amebic Abscess**

In about 40% of patients with amebic dysentery, parasites penetrate portal vessels and embolize to the liver to produce solitary, or less often multiple, discrete hepatic abscesses .Some patients may present with amebic liver abscesses, without a clinical history of amebic dysentery.

Originally, it was thought the ameba secreted enzymes that digested human tissue. More recent experiments suggest that the lesion is not produced directly by the ameba but by the lysosomal enzymes of disintegrating dead leukocytes and monocytes. Amebic abscesses range from a few mm up to the size of an entire lobe. Most are 4 to 10 cm. (Dean,2005)

## ***Heppatic Lipoma***

These are extremely rare, asymptomatic and have been associated with renal angiomyolipomas and tuberous sclerosis. (Dean,2005)

### **Hepatocellular Carcinoma (Primary Hepatoma, HCC)**

Clinically the patient is usually a male who presents with RUQ pain, weight loss and a history of cirrhosis either from alcohol abuse or as a result of an infection of the chronic hepatitis B or C variety. Local spread within the liver and pulmonary metastases are common. Often the tumor is well advanced when symptoms occur. The prognosis is poor. Numerous laboratory tests will be abnormal. A positive alpha fetoprotein is found in 50-90% of the cases depending on the author. The carcinoembryonic antigen may be raised. The gallium 67 NM scan is positive. The AST and ALT levels may be increased but these two tests are not done as part of the clinical screen for a primary hepatoma. (Dean, 2005)

There is a longer prothrombin time and the alkaline phosphatase may be increased if the tumor causes biliary obstruction. (Dean, 2005)

### **Liver metastases**

Metastases are 18-20 times more common than HCC. The liver is a common site for metastases from all types of tumors. The dual blood supply enables the tumor to spread readily from the gastrointestinal tract via the portal vein and from general systemic arterial circulation via the hepatic artery. Metastatic neuroblastoma is the most common cause of liver metastases in children. In adults, common carcinomas metastasizing to the liver include lung, colon, pancreas, breast and stomach. (Dean, 2005)

The serum alkaline phosphatase and the serum alpha fetoprotein levels may be elevated with liver metastases.

If a malignancy or a metastatic lesion is found, the rest of the patient's abdomen and pelvis should be scanned for evidence of ascites or other disease. The detection of metastatic liver disease greatly alters the patient's prognosis and very often the management. (Dean, 2005)

## **Lymphoma of the liver**

Is less common diffuse involvement of the liver is an overall decrease in echogenicity may be seen. (Dean,2005)

## **2-3-2 Gallbladder Pathology**

### **2-3-2-1 Cholelithiasis**

This is the presence of gallstones within the gallbladder. Patients most frequently have vague complaints, fatty food intolerance and intermittent episodes of intense pain (called biliary colic) caused by transient impaction of a stone in the gallbladder neck. (<http://www.anatomy.med.umich.edu> ,2014)

Common risk factors are increasing age, female gender, fecundity, obesity, diabetes, and pregnancy. Although most patients are asymptomatic, about one in five develops a complication, often biliary colic. (Rumack and et al, 2011)

### **2-3-2-2 Adenomyomatosis (Adenomatous Hyperplasia)**

Gallbladder adenomyomatosis is a benign condition caused by exaggeration of the normal invaginations of the luminal epithelium (Rokitansky-Aschoff sinuses) with associated smooth muscle proliferation .The affected areas demonstrate thickening of the gallbladder wall with internal cystic spaces, the key to the adenomyomatosis may be focal or diffuse Focal adenomyomatosis is most common in the gallbladder fundus, less often narrowing the midportion of the organ, called hourglass gallbladder. (Rumack and et al, 2011)

Fundal adenomyomas are often folded onto the body of the gallbladder and can occasionally be mistaken for a pericholecystic or even a hepatic mass. The entire gland wall may be involved, causing collapse of the lumen. The absence of the cystic spaces, echogenic foci, or twinkling artifact or the presence of internal vascularity should prompt further investigation to differentiate from neoplasm. (Kumar and et al, 2003)

### **2-3-2-3 Gallbladder Polyps**

Are present in 4 to 6 percent of the population.4,5 An estimated 90% are

benign cholesterol polyps, less than 10 mm in size and are incidental findings. The remaining 10% are adenomatous polyps that have malignant potential.

Most polyps are spherical (attached by a pedicle to the gallbladder wall). Less common are the broad based (sessile) polyps. (Kumar and et al, 2003)

#### **2-3-2-4 Echogenic Bile**

Echogenic bile, or sludge, is seen when cholesterol crystals and/or calcium bilirubinate granules crystallize after prolonged stasis due to prolonged fasting or hyperalimentation, and in patients with biliary obstructions at the level of the gallbladder, cystic duct or common bile duct. Sludge requires 5-7 days to form and is not caused by routine overnight fasting required for GB sonography. Most authors consider the presence of sludge as nonpathological. (Dean, 2005)

#### **- Sludge Balls**

Are masses of sludge in the gallbladder that are mobile and non-shadowing. (Dean, 2005)

#### **- Milk of Calcium Bile**

Is sludge with a high calcium content, It is an uncommon finding associated with cholecystitis and cholelithiasis. (Dean, 2005)

#### **2-3-2-5 Hemophilia**

Blood in the gallbladder and biliary tract and empyema (pus in the gallbladder) may also cause echogenic bile and should be considered in the appropriate clinical setting. Hemobilia may be mobile or partially adherent to the walls. Doppler may be required to differentiate it from neoplasia. Hemobilia has been associated with acute cholecystitis, bleeding disorders, biliary neoplasms and penetrating or blunt trauma to the gallbladder. One study found 28% of patients with hemobilia had bleeding disorders. Percutaneous procedures for the relief of biliary obstruction may also result in hemobilia. (Dean, 2005)



### **2-3-2-6 Acute Cholecystitis**

Acute cholecystitis is second only to acute appendicitis as the leading cause of emergency abdominal surgery. Acute cholecystitis is usually caused by impaction of a gallstone in the GB neck obstructing the GB. (Sutton and et al, 2003)

This results in GB inflammation. Ischemia and bacterial infection are contributing factors. Gallstones are present in 90-95percent of cases.

The patient presents with fever, leukocytosis and biliary colic, which is intense, intermittent, RUQ pain. The pain often begins after a meal containing fatty food. Biliary colic can cause an ileus. An ileus is a transient form of intestinal obstruction where there is failure of peristalsis due to interference with the nerve stimulation of the bowel, occasionally symptoms disappear when the impacted stone spontaneously disimpacts. (Dean,2005)

90 to 95% of acute cholecystitis patients have cholelithiasis; the remaining 5 to 10% have acalculouscholecystitis. Morbidity and mortality rates are much higher with acalculouscholecystitis as the disease frequently is a complication of an unrelated critical illness. There are many predisposing conditions most of which are associated with patients who have been hospitalized for various reasons and who subsequently develop abdominal pain. Some predisposing conditions are: burns, trauma, recent major surgery, debilitating diseases or patients who are immunocompromised. Most cases are related to prolonged biliary stasis, ischemia, and biliary infection.(Dean,2005)

It has been estimated that up to 50% of patients with acalculouscholecystitis are undiagnosed and progress to gangrene and GB perforation. (Dean,2005)

### **2-3-2-7Chronic Cholecystitis**

Chronic cholecystitis is symptomatic but nonacutecholecystolithiasis. These patients complain of recurrent biliary colic that usually lasts for several hours and is caused by transient obstruction of the gallbladder neck or cystic duct by a stone. (Dean,2005)

### **2-3-3Biliary tract**

#### **2-3-3-1Dilated Intrahepatic Bile Ducts**

In the past, any visualization of the intrahepatic ducts was considered a sign of intrahepatic biliary dilatation. However, because of normal variability and improvements in ultrasound equipment, the nondilated central intrahepatic biliary tree can frequently be visualized. As a general rule, the caliber of normal intrahepatic ducts should be 2 mm or less or less than 40% of the accompanying portal vein. (Dean,2005)

#### **2-3-3-2Biliary Obstruction**

Which part of the biliary tree distends in biliary obstruction depends on the level of obstruction. With distal obstruction, the entire system distends including the gallbladder. If the obstruction occurs in the CHD, only the proximal ducts will distend. With obstruction at the junction of the right and left hepatic ducts, the intrahepatic ducts dilate and the extrahepatic ducts remain normal,Intrahepatic obstruction of a segmental duct results in segmental dilatation. (Dean,2005)

#### **Causes of Biliary Obstruction**

The causes are: Choledocholithiasis, Mirizzi Syndrome, Cholangiocarcinoma, Sclerosing Cholangitis and Oriental Cholangitis (oriental cholangiohepatitis, (Dean,2005)

#### **1-Caroli's Disease**

This is a congenital segmental, nonobstructive dilatation of intrahepatic bile ducts. It is an uncommon condition, generally associated with autosomal recessive polycystic renal disease and medullary sponge kidney. The most

common complications of Caroli disease are recurrent bacterial cholangitis, stones in the dilated ducts, hepatic fibrosis, portal hypertension and liver failure. The diagnosis should be suspected in infants in the right clinical setting. However, if asymptomatic, this condition may remain undetected for several years. “Early diagnosis is important not only for the assessment of intrahepatic or extrahepatic manifestations, but also to identify known complications such as hepatic fibrosis and cholangiocarcinoma. Classically, Caroli’s disease is demonstrated as saccular areas of intrahepatic bile duct ectasia, which are separate from the gallbladder, converging toward the portahepatis.(Dean,2005)

In symptomatic patients with pain and fever, ultrasound may detect early abscess formation or any coexisting bile duct calculus.” Evidence of cirrhosis and portal hypertension may be demonstrated. (Dean,2005)

## **2-Hemobilia**

This is an arteriobiliary fistula caused by liver rupture with bleeding into the biliary tract. (Dean,2005)

## **3-Pneumobilia**

Air in the biliary system. There are many different etiologies of pneumobilia usually involving biliary surgery including procedures such as sphincterotomy, Roux-en-Y procedure (choledochoduodenostomy or choledochojejunostomy) and papillectomy. Pneumobilia is a possible side effect of a recently performed ERCP (endoscopic retrograde cholangio-pancreatogram). (Dean,2005)

## **2-3-4 pancreatic pathology**

### **2-3-4-1Cystic Fibrosis**

This common cause of pancreatic disease in childhood is inherited as an autosomal recessive. A specific gene mutation  $\Delta F508$  is present in 70% of cases. The gene(s) code for a membrane protein in epithelial cells which regulates chloride transport (the cystic fibrosis transmembrane regular,

CFTR). Defective chloride channel transport secondarily leads to a failure to hydrate pancreatic secretion. The increased viscosity of such secretions then leads to ductular obstruction and secondary pancreatic damage. Ninety per cent of patients with cystic fibrosis will have pancreatic failure, and in the majority of these this will be present from the perinatal period. (**Rumack and et al, 2011**)

#### **2-3-4-2 Congenital Cysts**

Solitary congenital pancreatic cysts are rare however, "multiple congenital cysts, ranging in size from microscopic to 3 to 5 cm , are associated with cystic disease of the pancreas, liver, spleen, and kidneys as part of the broad spectrum of adult type polycystic kidney disease" (autosomal dominant polycystic renal disease). (Dean,2005)

#### **2-3-4-3 Pancreatitis**

Pancreatitis is divided into acute and chronic. By definition acute pancreatitis is a process that occurs on the background of a previously normal pancreas and can return to normal after resolution of the episode. In chronic pancreatitis there is continuing inflammation with irreversible structural changes. (Rumack and et al, 2011)

##### **-Acute pancreatitis**

In the western world gallstones and alcohol account for the vast majority of episodes. Alcohol also causes chronic pancreatitis. The severity of the pancreatitis may range from mild and self-limiting to extremely severe with extensive pancreatic and peripancreatic necrosis as well as hemorrhage. In its most severe form the mortality rises to between 40-50%. (Rumack and et al, 2011)

##### **- Chronic pancreatitis**

In developed countries by far the most common cause of chronic pancreatitis is alcohol, accounting for 60-80% of cases.

In developing countries malnutrition and associated dietary factors have been

implicated. In a small group of patients chronic pancreatitis has been shown to be hereditary, inherited as an autosomal dominant condition with variable penetrance. Almost all patients with cystic fibrosis have established chronic pancreatitis, usually from birth. Cystic fibrosis gene mutations have also been identified in patients with chronic pancreatitis but in whom there were no other manifestations of cystic fibrosis. (Rumack and et al, 2011)

#### **2-3-4-4Pancreatic Pseudocyst**

A true cyst has a glandular epithelial lining which secretes the fluid contents of the cyst. A pancreatic pseudocyst is a fluid collection that has developed a well defined fibrous capsule a non-epithelial capsule. (Rumack and et al, 2011)

#### **2-3-4-5Pancreatic Neoplasms**

##### **-Adenocarcinoma**

Adenocarcinoma is the most common type of pancreatic cancer. Almost all adenocarcinomas originate in the ductal epithelium rather than the acini. "Approximately 70% of the pancreatic cancers arise in the region of the head, 15% to 20% in the body, and 5% in the tail. In 20% of cases the tumor is distributed diffusely throughout the gland".<sup>1,2</sup> Most patients are males over the age of 60. The prognosis is poor with a one year survival rate of 8%. (Rumack and et al, 2011)

##### **- Cystic Neoplasms of the Pancreas**

Cystic lesions of the pancreas are not uncommon. Seventy-five per cent of these lesions will be pseudocysts but of the remainder the majority are true cystic neoplasms. These neoplastic lesions can be divided into the serous and mucinous cyst adenomata. Serous cyst adenomata are composed of multiple small cystic cavities lined by cuboidal glycogen-rich, mucin-poor cells. These lesions tend to occur in an elderly age group and are often an asymptomatic finding. Malignant transformation in a serous cystadenoma is extremely rare. Mucinous cyst adenomata are almost exclusively found in women in the 5<sup>th</sup>

and 6<sup>th</sup> decade and are sited in the pancreatic body and tail. Multilocular cysts are lined by tall mucin-synthesizing cells. Twenty per cent of these lesions are malignant at the time of presentation and the majority appear to have a malignant potential. As a consequence they are much more likely to produce symptoms. (Rumack and et al, 2011)

#### **- Microcystic or Serous Cystadenoma**

These are moderately well defined multilocular masses often containing a central stellate scar with occasional calcification within the scar. The cysts range from 1 mm to 2 cm and are often located peripherally away from the central scar. microcystic neoplasms are benign and do not require surgery. (Dean,2005)

#### **- Neuroendocrine Tumors**

These tumors have traditionally been called ‘islet cell tumors’ because they were thought to originate in the islets of Langerhans, which are ‘nests’ of endocrine tissue scattered throughout the pancreatic parenchyma. Neuroendocrine tumors may arise from a number of tissues located throughout the body, including the pancreas, stomach, and other abdominal viscera. They may be benign or malignant and the malignant potential varies according to cell type.” Although uncommon endocrine tumors are the second most important pancreatic tumor after pancreatic adenocarcinoma. (Dean,2005)

Neuroendocrine tumors are classified as functioning or nonfunctioning. Functioning tumors secrete hormones which create specific clinical symptoms. Nonfunctioning tumors are called silent tumors because the hormones they secrete do not appear to affect the patient clinically. insulinomas or B cell tumors are the most common type of neuroendocrine tumors. (Dean,2005)

They may be benign or malignant and most commonly present with hypoglycemic symptoms. “insulinomas are diagnosed by finding an

inappropriately elevated serum insulin level in the presence of a low blood glucose level.” insulinomas are usually small and located in the pancreatic body and tail. Malignant lesions metastasize to the regional lymph nodes and the liver. (<http://wwwanatomy.med.umich.edu> ,2014)

## **2-4 previous studies**

Laing et al. (2005) prescribed the role of ultrasound in evaluating acute right upper quadrant pain, a prospective study was performed on 52 patients having clinically suspected acute cholecystitis. ultrasonographic determination of acute or chronic cholecystitis, or diagnosis of a normal gallbladder, was based on analysis of location of tenderness, calculi, sludge, and wall thickness. The diagnosis of acute cholecystitis (34.6% of patients) was based on the highly significant observations of focal gallbladder tenderness and calculi. Sludge and wall thickening were also statistically significant, but to a lesser degree. cholelithiasis allowed differentiation of patients with chronic cholecystitis (32.7%) from patients with normal gallbladders (32.7%). Neither of these two groups had significant focal gallbladder tenderness, sludge, or thickened walls. Because acute cholecystitis is found in the minority of patients with acute right upper quadrant pain, and because ultrasound is rapid, accurate, and noninvasive, it should be the initial modality used to evaluate these patients. (Laing and et al, 2005)

Jang et al. (2002)Evaluated accuracy of Resident-Performed Right Upper Quadrant Ultrasonography.148 patients were included, 66 of whom had gallstones. EMR-performed RUQ US had a sensitivity of 95.5% (95% CI (86.4-98.8%)) and specificity of 90.2% (95% CI (81.2-95.4%)) for gallstones. 14 patients had acute cholecystitis. EMR-performed RUQ US had a sensitivity of 92.9% (95% CI (64.2-99.6%)) and specificity of 93.3% (95% CI (87.3-96.7%)) for acute cholecystitis,EMRs can accurately perform RUQ US to diagnose gallstones and acute cholecystitis in selected patients, which was not previously established. (Jang and et al, 2002)

Jang et al. (2002) evaluated accuracy of Resident-Performed Right Upper Quadrant Ultrasonography. Although few patients with acute abdominal pain will prove to have cholecystitis, ruling in or ruling out acute cholecystitis



consumes substantial diagnostic resources, to determine if aspects of the history and physical examination or basic laboratory testing clearly identify patients who require diagnostic imaging tests to rule in or rule out the diagnosis of acute cholecystitis. Included studies evaluated the role of the history, physical examination, and/or laboratory tests in adults with abdominal pain or suspected acute cholecystitis. Studies had to report definitions of cholecystitis included surgery, pathologic examination, hepatic iminodiacetic acid scan or right upper quadrant ultrasound, or clinical course consistent with acute cholecystitis and no evidence for an alternate diagnosis. Studies of acalculous cholecystitis were included. Seventeen of 195 identified studies met the inclusion criteria, no single clinical finding or laboratory test carries sufficient weight to establish or exclude cholecystitis without further testing (eg, right upper quadrant ultrasound). Combinations of certain symptoms, signs, and laboratory results likely have more useful LRs, and presumably inform the diagnostic impressions of experienced clinicians. Pending further research characterizing the pretest probabilities associated with different clinical presentations, the evaluation of patients with abdominal pain suggestive of cholecystitis will continue to rely heavily on the clinical gestalt and diagnostic imaging. (Jang and et al, 2002)

Imran et al. (2003) described the cause of upper abdominal pain, 500 cases with upper abdominal pain, 248 patients had positive findings on ultrasound. This comes to slightly less than 50%. Bulk of the positive cases had liver, biliary tree and renal pathologies, all roughly with equal numbers. The final outcome of negative cases justified the failure of ultrasound as 157 of them were later found to have gastrointestinal problems like gastritis, uncomplicated peptic ulcer disease, worm infestation and intestinal tuberculosis. Eighteen patients had problems above the diaphragm like basal pneumonitis and myocardial infarction. Fifteen patients had urinary tract

infection. The cause of upper abdominal pain was not clear in 62 patients but they however, responded well to ordinary analgesics and smooth muscle relax. (Imran, 2003)

# **Chapter Three**

## **Materials & Methods**

### **3-1 Materials**

The data of this study was collected using Ultrasound gel applying over the RUQ area. A grey scale real-time MINDARY machine fitted with convex probe (3.5-5 MHZ). And computer device for data analysis.

### **3-2 Methods**

#### **3-2-1 Population of the study**

All patients who presented with right upper quadrant pain, were investigated by U/S.

#### **3-2-2 sample size and type**

The sample taken Of 100 patients with right upper quadrant pain.

#### **3-2-2 duration and place**

The study done in Modern Medical Center in the period from October 2018 to October 2019.

#### **3-2-3 Method of data collection**

Data collection sheet which was designed to include all variables to satisfy the study. Include age, gender, residence, causes of the right upper quadrant pain, type of the right upper quadrant pain, and ultrasound findings.

#### **3-2-4 Patient Preparation**

The patient should take nothing by mouth for 8 hours preceding the examination. If fluid is essential to prevent dehydration, only water should be given.

Infants should be given nothing by mouth for 3 hours preceding the examination

### **3-3 Scanning guidelines and protocols**

A coupling agent is necessary to ensure good acoustic contact between the transducer and the skin and allow total transsimation of the sound beam. (Palmer, 1995)

#### **3-3- 1 liver**

##### **- Longitudinal scanning**

a. Sagittal plane, anterior approach:

- Begin with transducer perpendicular, at the mid line of the body, just inferior to the xiphoid process.
- While viewing the left lobe, use subcostal angles and move the transducer to the patient's left, lateral and inferior along the costal margin until you are beyond the left lobe.
- Return to the midline just inferior to the xiphoid process. **(Palmer, 1995)**

### **Transverse liver scanning**

Transverse plane anterior approach.

### **Breathing technique**

Deep, held inspiration.

Different breathing techniques should be used whenever the suggested breathing technique does not give the desired result. **(Palmer, 1995)**

### **3-3 -2 GB & biliary tract**

Fasting for 8 to 12 hrs, to guarantee maximum GB and biliary tract dilatation but may be scanned after 4 to 6 hrs patient supine. **(Palmer, 1995)**

### **3-3 -3 Pancreas**

#### **Longitudinal scanning**

#### **Transverse plane anterior approach**

- Began with the transducer perpendicular, at the midline of the body, just inferior to the xiphoid process of the sternum.
- Slightly rock the transducer superior to inferior and slowly slide the transducer inferiorly. **(Palmer, 1995)**

#### **Transverse scanning**

#### **Sagittal plane anterior approach**

Began with the transducer perpendicular and locate the distal long axis portion of the IVC where it passes through the liver. Move inferiorly until locate the head of pancreas immediately anterior to it, the pancreatic head lies between the IVC and the liver. **(Palmer, 1995)**

### **3-4 Data analysis**

The data have been analyzed by SPSS by using the various statistic computerize methods.

### **3-5 Data presentation**

For data presentation tables and figures has been used.

### **3-6 Data storage:**

Patient's data sheets kept in locked cabinet, and all data stored on personal computer.

### **3-7 Ethical consideration:**

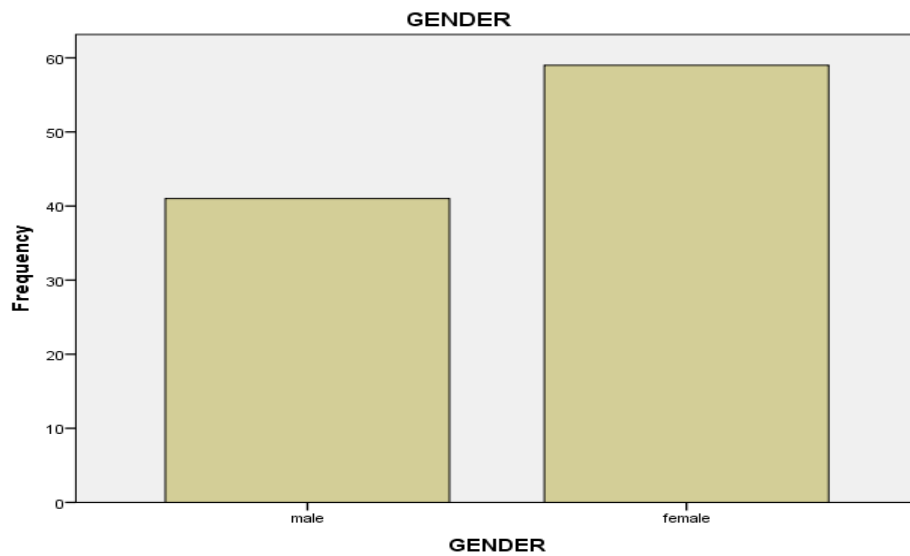
Justice and human dignity was observed by treating selected patients equally when telling them to participate in the research as sample of this study. The patients were free to decide whether to participate or not.

# **Chapter Four**

## **Results**

**Table (4-1): Frequency distribution of patient's according to gender:**

| <b>Gender</b> | <b>Frequency</b> | <b>Percent</b> |
|---------------|------------------|----------------|
| <b>Male</b>   | 43               | 43.0           |
| <b>Female</b> | 57               | 57.0           |
| <b>Total</b>  | 100              | 100.0          |



**Figure (4-1) shows gender distribution**



**Table (4-2): Frequency distribution of patients according to age:**

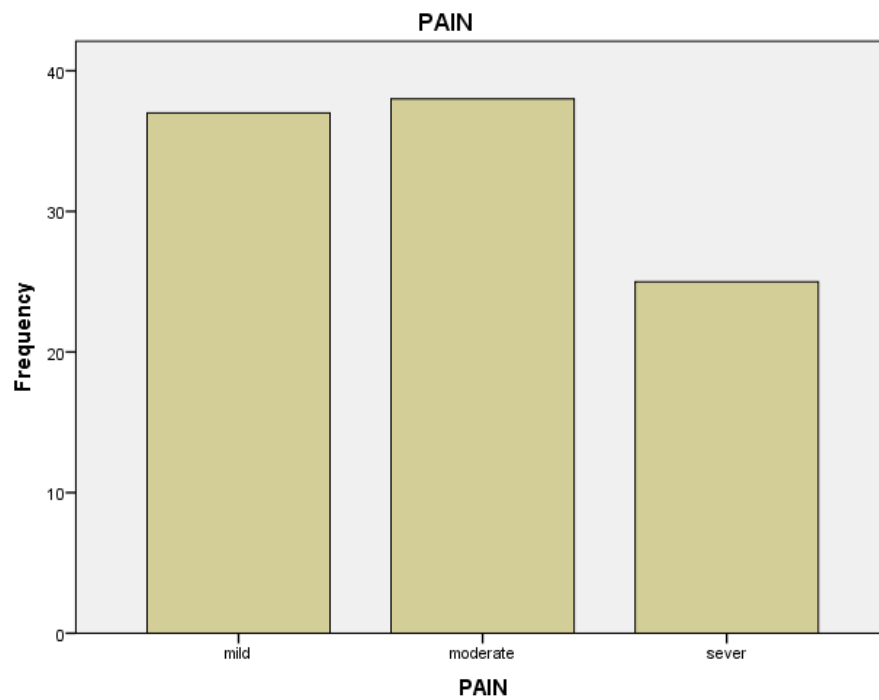
| <b>Age group</b> | <b>Percentage</b> |  | <b>frequency</b> |
|------------------|-------------------|--|------------------|
| <b>&lt; 30</b>   | <b>28.0</b>       |  | <b>28</b>        |
| <b>30-39</b>     | <b>17.0</b>       |  | <b>17</b>        |
| <b>40-49</b>     | <b>36.0</b>       |  | <b>36</b>        |
| <b>50-60</b>     | <b>10.0</b>       |  | <b>10</b>        |
| <b>&gt; 60</b>   | <b>9.0</b>        |  | <b>9</b>         |
| <b>Total</b>     | <b>100.0</b>      |  | <b>100</b>       |

**Table (4-3): Frequency distribution of patients according to residence**

| <b>Residence</b> | <b>Percent</b> | <b>Frequency</b> |
|------------------|----------------|------------------|
| Omdurman         | 16.0           | 16               |
| Khartoum Bahri   | 31.0           | 31               |
| Khartoum         | 53.0           | 53               |
| Total            | 100.0          | 100              |

**Table (4-4): Frequency distribution of patients according to pain**

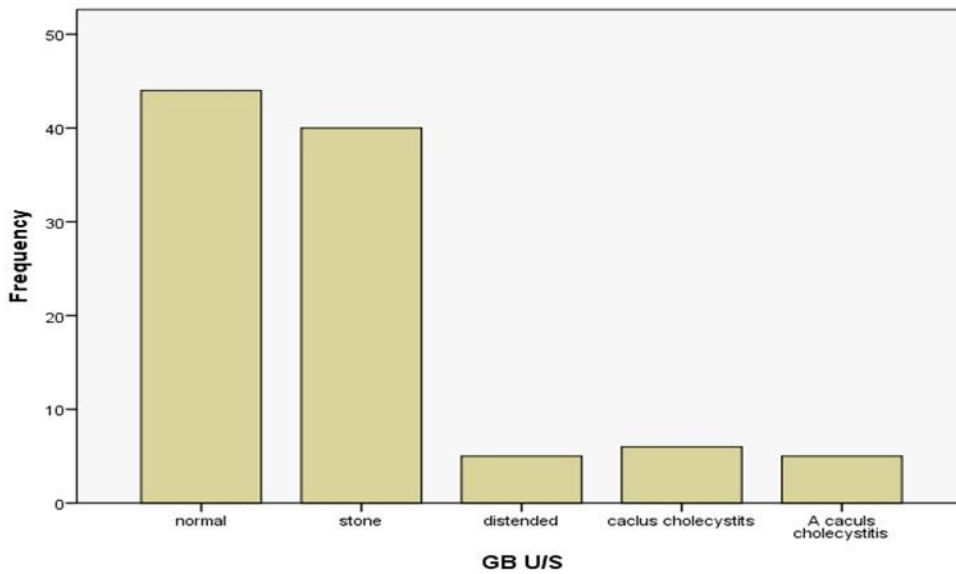
| <b>Pain</b> | <b>Percent</b> | <b>Frequency</b> |
|-------------|----------------|------------------|
| Mild        | 37.0           | 37               |
| Moderate    | 38.0           | 38               |
| Sever       | 25.0           | 25               |
| Total       | 100.0          | 100              |



**Figure (4-2) shows pain distribution**

**Table (4-5): Frequency distribution of patients GB ultrasound**

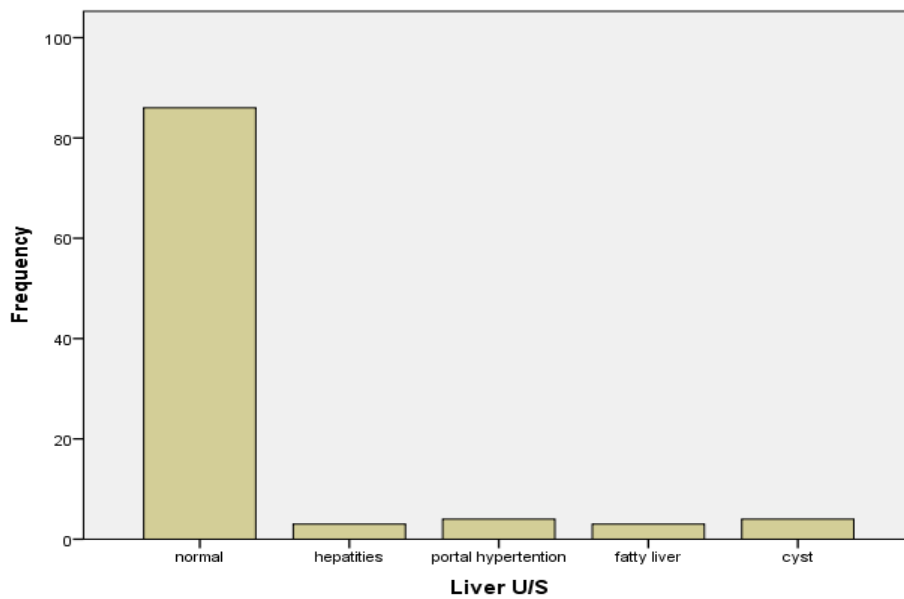
| Ultra sound finding    | Percent | Frequency |
|------------------------|---------|-----------|
| Normal                 | 44.0    | 44        |
| Stone                  | 42.0    | 42        |
| Distended              | 5.0     | 5         |
| calculus cholecystitis | 5.0     | 5         |
| Acalculuscholecystitis | 4.0     | 4         |
| Total                  | 100.0   | 100       |



**Figure (4-3) show gall bladder ultrasound**

**Table (4-6): Frequency distribution of patients according to liver  
Ultrasound findings**

| Ultrasound finding  | Percent | Frequency |
|---------------------|---------|-----------|
| Normal              | 84.0    | 84        |
| Hepatitis           | 4.0     | 4         |
| portal hypertension | 3.0     | 3         |
| fatty liver         | 5.0     | 5         |
| Cyst                | 4.0     | 4         |
| Total               | 100.0   | 100       |

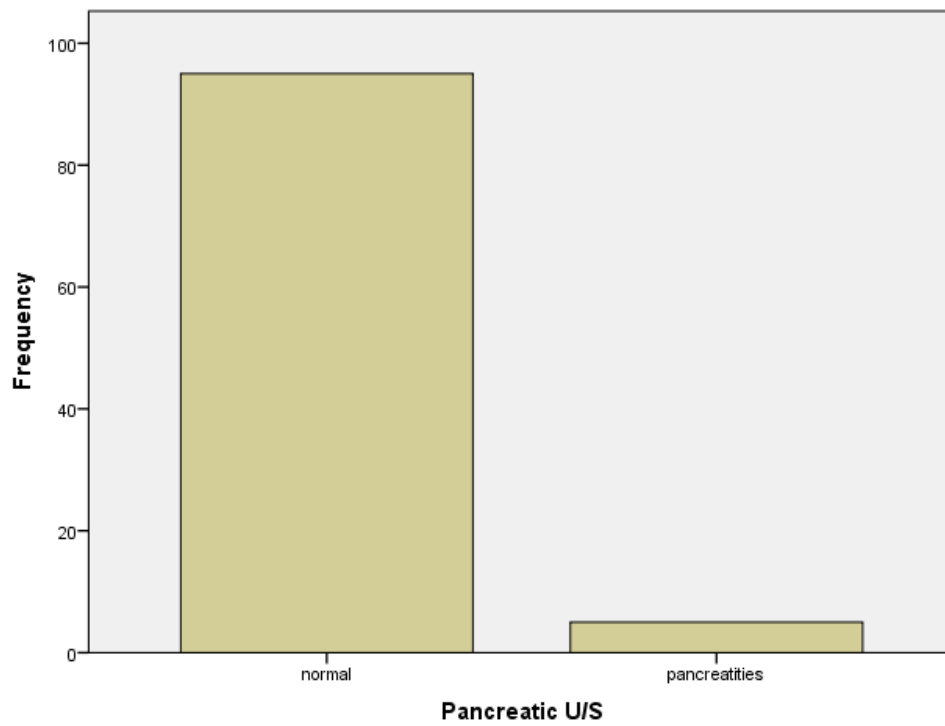


**Figure (4-4) show liver ultrasound**

**Table (4-7): Frequency distribution of patients understudy according to**

| <b>Pancreas US</b>         |                |                  |
|----------------------------|----------------|------------------|
| <b>Ultrasound findings</b> | <b>Percent</b> | <b>Frequency</b> |
| Normal                     | 97.0           | 97               |
| Pancreatitis               | 3.0            | 3                |
| Total                      | 100.0          | 100              |

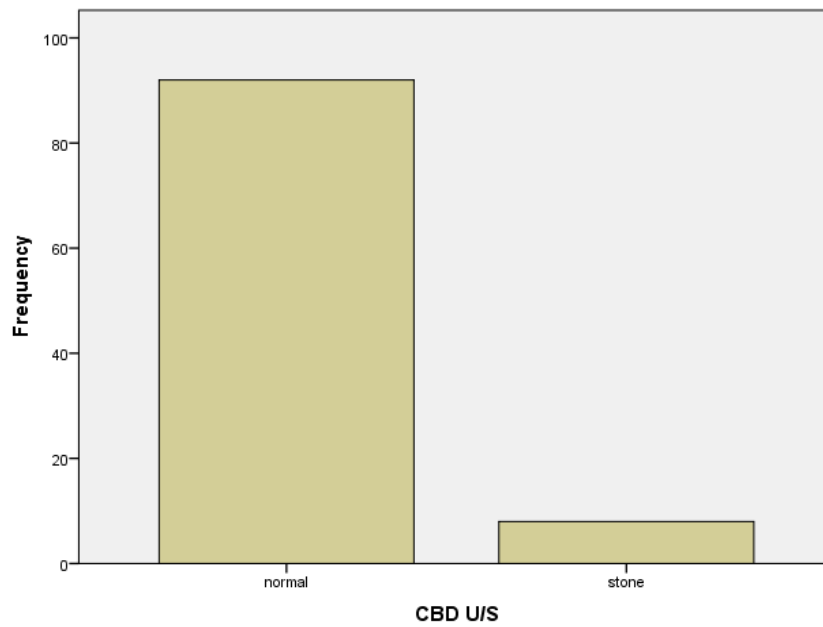
**pancreas Ultrasound findings**



**Figure (4-5) show pancreas ultrasound findings**

**Table (4-8): Frequency distribution of patients understudy according to CBD Ultrasound findings**

| CBD Ultra sound     |         |           |
|---------------------|---------|-----------|
| Ultrasound findings | Percent | Frequency |
| Normal              | 93.0    | 93        |
| Stone               | 7.0     | 7         |
| Total               | 100.0   | 100       |



**Figure (4-6) show CBD ultra sound findings**

**Table (4-9) frequency distribution of patient with other ultrasound findings**

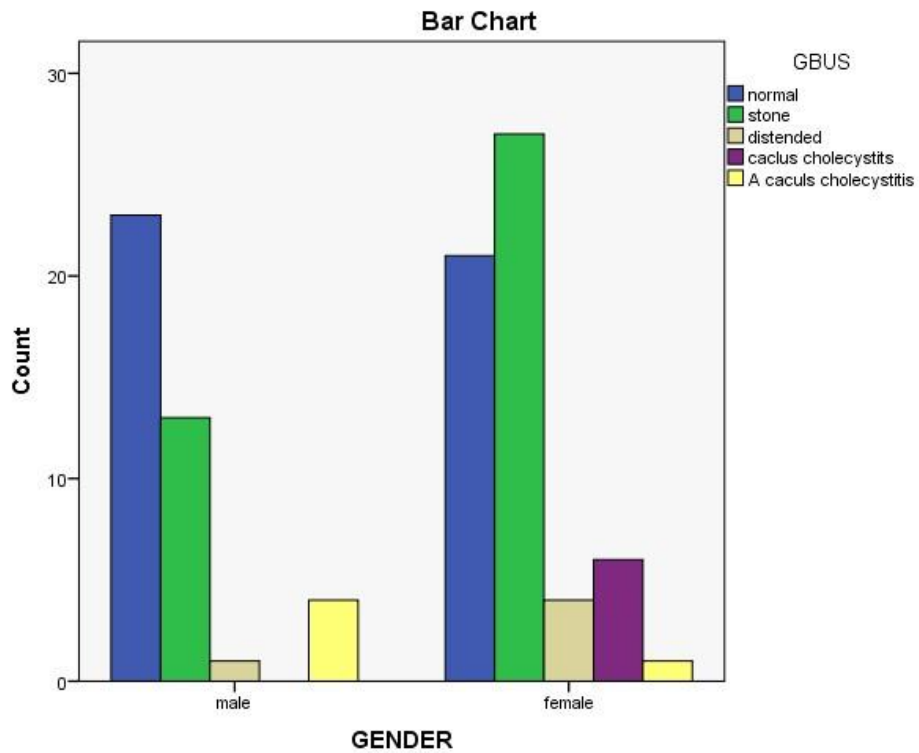
| <b>Gender</b> | <b>Gases in bowel</b> | <b>Normal</b> | <b>Total</b> |
|---------------|-----------------------|---------------|--------------|
| <b>Male</b>   | 6                     | 37            | 43           |
| <b>Female</b> | 4                     | 53            | 57           |
| <b>Total</b>  | 10                    | 90            | 100          |

**Table (4-10) frequency distribution of patient according to ultrasound findings**

| <b>Ultrasound finding</b> | <b>Percentage</b> | <b>Frequency</b> |
|---------------------------|-------------------|------------------|
| Gall stone                | 42%               | 42               |
| Normal                    | 13%               | 13               |
| CBD stone(distended GB)   | 4%                | 4                |
| CBD stone                 | 3%                | 3                |
| Calculuscholecystitis     | 5%                | 5                |
| ACalculuscholecystitis    | 4%                | 4                |
| Pancreatitis              | 3%                | 3                |
| Portal hypertension       | 3%                | 3                |
| Liver cyst                | 4%                | 4                |
| Hepatitis                 | 4%                | 4                |
| Fatty liver               | 5%                | 5                |
| Gases bowel               | 10%               | 10               |
| <b>Total</b>              | <b>100%</b>       | <b>100</b>       |

**TABLE (4-11) Cross tabulation between gender and GB ultrasound**

| GB US & gender |        | GB U/S         |                    |           |       |        | Total |
|----------------|--------|----------------|--------------------|-----------|-------|--------|-------|
|                |        | A calculusitis | calculuschole cyst | distended | stone | normal |       |
| GENDER         | male   | 3              | 1                  | 1         | 14    | 24     | 43    |
|                | female | 1              | 4                  | 3         | 28    | 21     | 57    |
| Total          |        | 4              | 5                  | 4         | 42    | 45     | 100   |

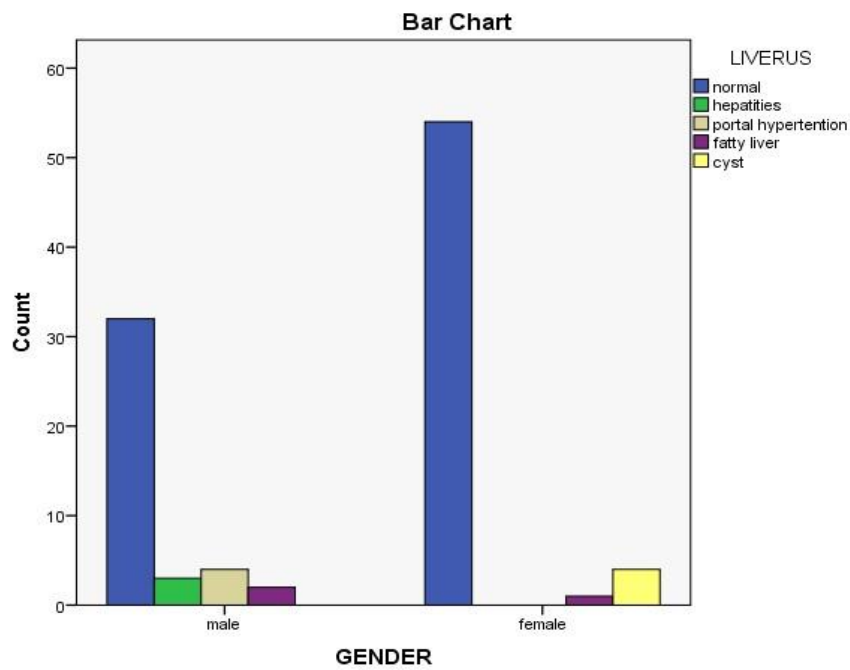


**Figure (4-7) show cross tabulation between gender & GBultra sound**



**Table (4-12) Cross tabulation between gender and liver ultrasound**

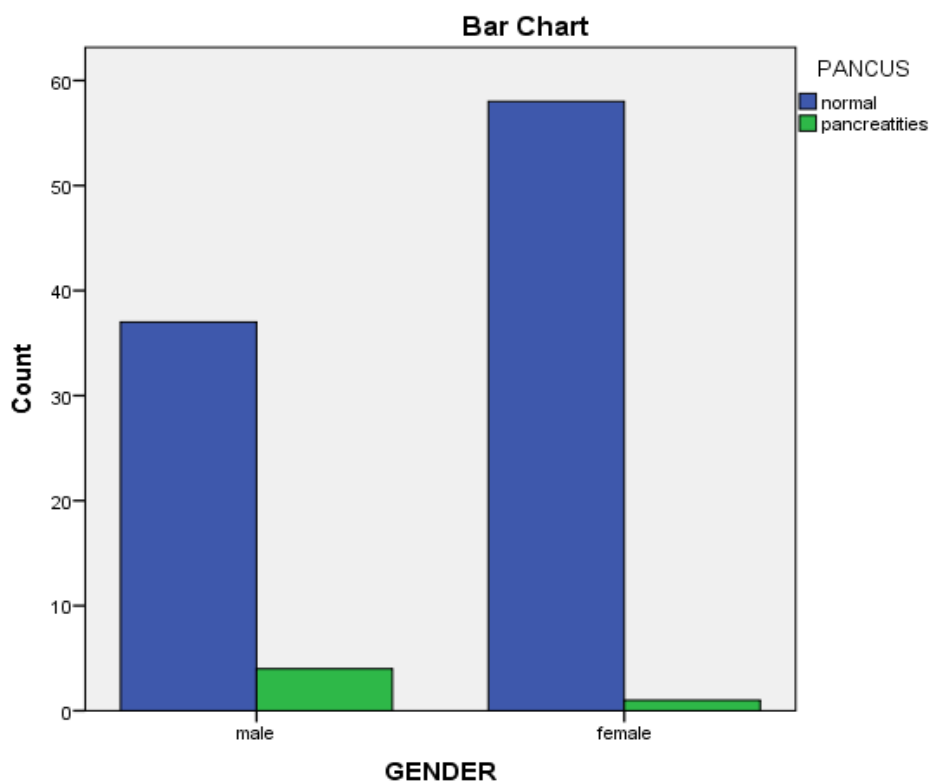
| Gender & Liver US |        | LIVER US |             |                     |           |        | Total |
|-------------------|--------|----------|-------------|---------------------|-----------|--------|-------|
|                   |        | Cyst     | fatty liver | portal hypertension | Hepatitis | Normal |       |
| GENDER            | Male   | 0        | 3           | 3                   | 4         | 33     | 43    |
|                   | Female | 4        | 2           | 0                   | 0         | 51     | 57    |
| Total             |        | 4        | 5           | 3                   | 4         | 84     | 100   |



**Figure (4-8) shows cross tabulation between liver ultrasound & gender**

**Table (4-13) Cross tabulation between gender and Pancreas ultrasound findings**

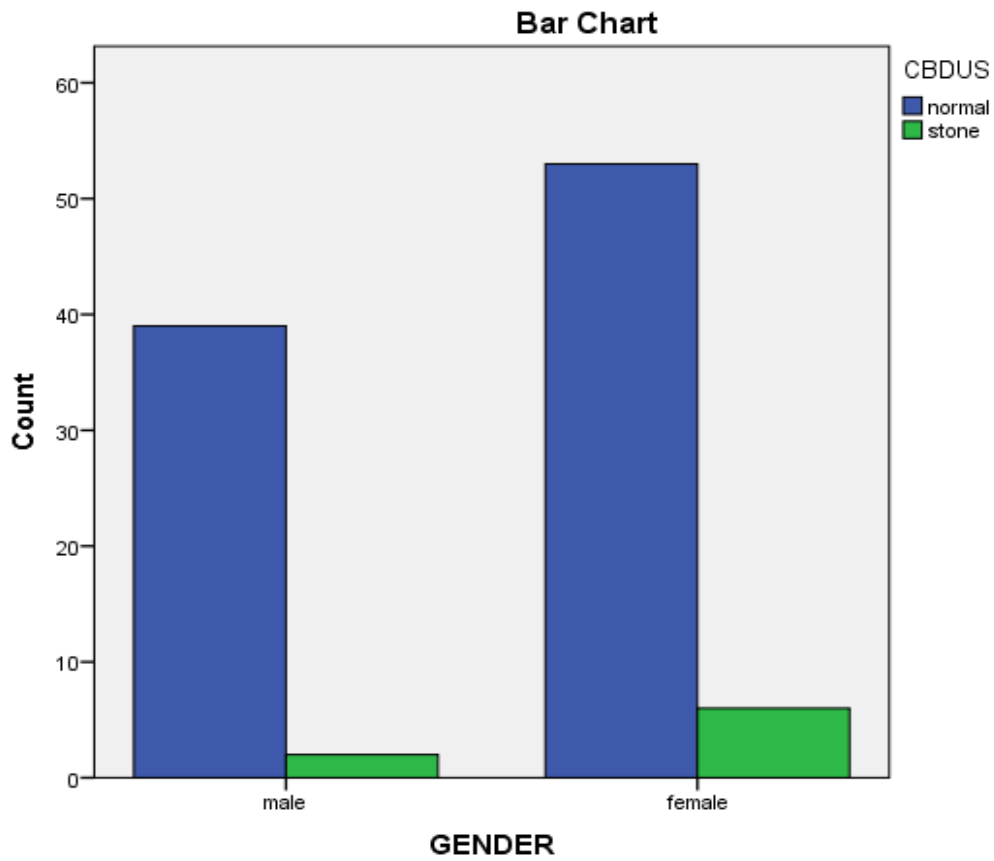
| GENDER & PANCREAS |        |              |        | Total |
|-------------------|--------|--------------|--------|-------|
|                   |        | pancreatitis | Normal |       |
| GENDER            | Male   | 2            | 41     | 43    |
|                   | Female | 1            | 56     | 57    |
| Total             |        | 3            | 97     | 100   |



**Figure (4-9) shows cross tabulation between pancreas ultrasound & gender**

**Table (4-14) Cross tabulation between gender and CBD ultrasound**

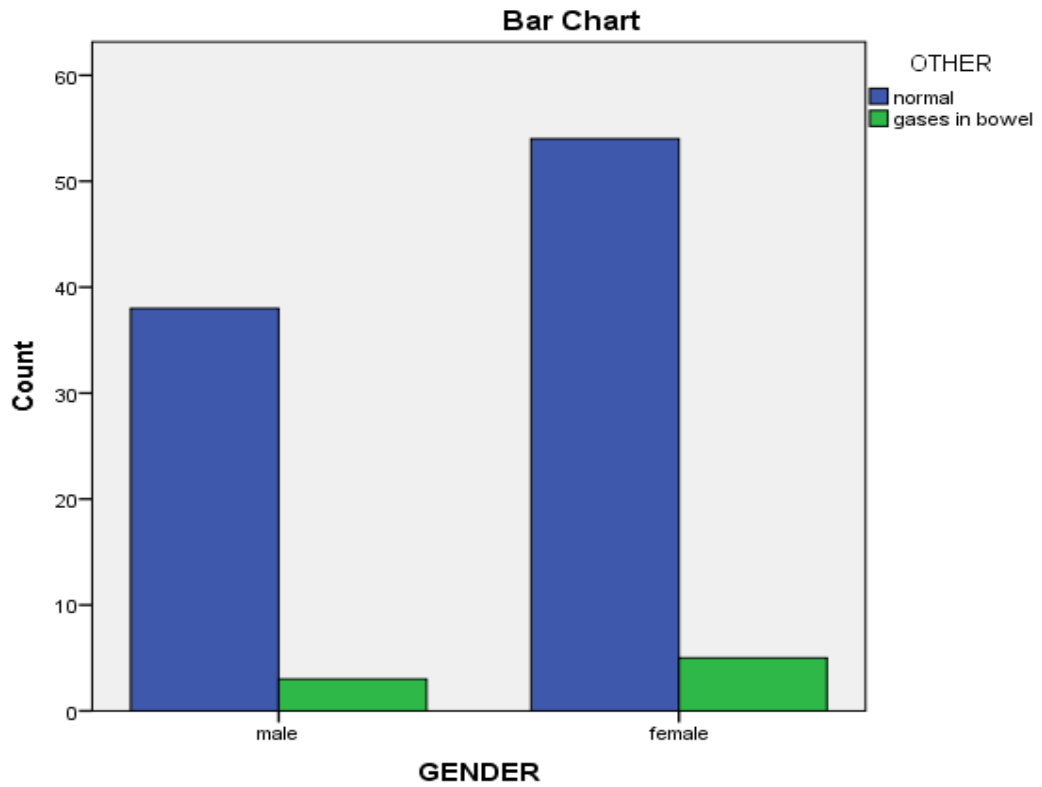
| GENDER & CBDUS |        | CBDUS |        | Total |
|----------------|--------|-------|--------|-------|
|                |        | stone | Normal |       |
| GENDER         | Male   | 2     | 41     | 43    |
|                | Female | 5     | 52     | 57    |
| Total          |        | 7     | 93     | 100   |



**Figure (4-10) show cross tabulation CBD Ultra Sound & Gender**

**Table (4-15) Cross tabulation between gender and Gasses bowel**

| Gender *gases bowel |        | Other          |        | Total |
|---------------------|--------|----------------|--------|-------|
|                     |        | gases in bowel | Normal |       |
| GENDER              | Male   | 3              | 40     | 43    |
|                     | Female | 7              | 50     | 57    |
| Total               |        | 10             | 90     | 100   |



**Figure (4-11) show cross tabulation others Ultrasound & Gender**

# **Chapter Five**

## **Dissection, Conclusion & Recommendations**

## 5-1. Discussion

This study was done to assess patients with right upper quadrante pain using ultrasound. It used sample of 100 patients who was selected randomly and information collected by clinical data collection sheet.

Regarding the patient gender 57% females and 43% males due to high number of females in the study.

Regarding the patient age most of them was in age group about 36% between 40-49 years may be due to high number of gall stone cases, followed 28% less than 30 years.

Regarding to patient residence 53% in Khartoum followed by 31% Omdurman and 16% Khartoum Bahri large patient in Khartoum it due most of data collected from Khartoum area.

Concerning the right upper quadrante pain most of them moderate and mild same equally about 38%,37% respectively and just about 25% severe pain.

Concerning the ultrasound finding most of them had gall bladder stone forming 42% This finding agrees with study done by Jang, C Aubin, RNAunheim.148 patients were included, 66 of whom had gallstones. EMR-performed RUQ US had a sensitivity of 95.5% (95% CI (86.4-98.8%)) and specificity of 90.2% (95% CI (81.2-95.4%)) for gallstones.

Also agree with another study done by Sabina Imran (2003) who reported that out of the 500 patients with RUQ pain 248 patients had positive findings on ultrasound.

The most common ultrasound finding in female was gallbladder stone 28%. While 14% of males had gallbladder stone this agree with gender gall bladder disease.

The most common type of pain in patients with gallbladder stone was moderate 19%. Patient with gaseous bowel 10% of them their pain was mild, moderate and severe, 13% of normal findings their pain was mild and moderate, 4% of acalculuscholecystitis patients their pain was mild and

patients with calculus cholecystitis findings 5% their pain was severe.

The result of spearman is shown highly significant correlation at the 0.01 level was noticed between ultrasound findings and type of pain.

## **5-2.Concolution**

Different pathologies have been demonstrated in patients with right upper quadrant pain. study done from March to May 2017, in Khartoum area hospitals 100 patients suffering from right upper quadrant pain were investigated and assess them with age and pain by ultrasonography which is non-invasive, economic, simple an easily available.

The study found that most of the patients were females, their ages 40-49 years, pain was moderate to mild. The gall stone is prominent finding other findings include , gaseous bowel, normal findings, acalculus cholecystitis, calculus cholecystitis, cystic liver, hepatitis, with portal hypertension, and common bile duct stone.

The study concluded that ultrasound can assess right upper quadrant pain patients and provides excellent details about the findings in patients.



### **5-3. Recommendations**

- ✓ Scanning gallbladder in different scanning planes in addition to basic view to avoid missing of impacted stones.
- ✓ Good preparation is necessary to avoid obscure organs by gas.
- ✓ More training program should be planned for sonographers and sonologists in the field of ultrasound to give accurate results.
- ✓ Another research studies should be done with expanding period of time and include more sample data for more precise and accurate results.
- ✓ International scanning guideline and protocol should be used for scanning RUQ to reduce misdiagnosis

## References

Carol M Rumack et al. Diagnostic ultrasound. 4<sup>th</sup> edition. mosby; USA:2011.p.96.

Causes of right upper quadrant pain Available from: [www.mayoclinic.org](http://www.mayoclinic.org).at 8:17PM ,14June2014.

David Sutton, Philip J.A.ROBINSON ,Jermy P.R.JNIUNS .Text book of radiology and imaging . Seven edition. Elsevier science limited; China : 2003. 701-724.

Devin Dean. Ultrasound of the abdomen and small parts. Part one. The brwinstitute of diagnostic medical ultrasound; Lunenburg, Canada:2005.P.23,26,29-33.

Differential diagnosis of right upper quadrant pain Available from: [www.right upper quadrant pain.edu](http://www.rightupperquadrantpain.edu). at 1:00PM, 1January2014.

Edward I.bluth,carol B.benson. Ultrasound practical approach to clinical problems. second edition. everbest printing co; china:2007.1-2.

gallbladder image available from: [en.wikipedia.org](http://en.wikipedia.org). at 6:17PM ,12June2014.

Harold Ellis. Clinical anatomy. 11<sup>th</sup>ed. Blackwell; USA: 2006.P .101-102.

Hepatic flexure Available from: [en.wikipedia.org/wiki/hepatic-flexure](http://en.wikipedia.org/wiki/hepatic-flexure). at 6:30PM, 12June2014.

Jane Bates. Abdominal ultrasound How, why, and when. 2nd edition. Elsevier limited; china:2004.P.24, 95.

Jang, C Aubin, R Naunheim .*Accuracy of Resident-Performed Right Upper Quadrant Ultrasonography*. The Internet Journal of Emergency Medicine.At

Department of Medicine, University of California; San Francisco: 2002. 94-120 .

Jang, C Aubin, R Naunheim. *Accuracy of Resident-Performed Right Upper Quadrant Ultrasonography*. The Internet Journal of Emergency Medicine; USA :2002 ;1( 2):94

[Laing FC](#), [55Federle MP](#), [55Jeffrey RB](#) and [55Brown TW](#), role of ultrasound in evaluating acute right upper quadrant pain; ;USA:2005.

[liver and duodenum sonography available from: www.missinglink.ucsf.edu.a](#) t 6:20 PM,12June2014.

[Liver- sonography. Available from: www.uthsca.edu.at](#) 12:07AM, 8June2014.

[Liver-anatomy.Available from: illionis.liver.org.at](#) 5:18PM ,7June2014.

Moore et al. Essential clinical anatomy. 3<sup>rd</sup> edition. Williams & Wilkins; Lippincott:2007.p.164-165,167,169.

Palmer P.E.S. Manual of diagnostic ultrasound. 1<sup>st</sup> edition. WHO Geneva;france: 1995. P. 17-25.

Petral L. Willimas. et al. Gray's anatomy's. 37<sup>th</sup> editions. W. B Sanders company; Baltimore London:1992.P.212.

[Right upper quadrant anatomy Avilable from: en.wikipedia.org/wiki/Right-upper-quadrant-\(abdomen\).](#) at 10:06AM, 6 January 2014.

[Right upper quadrant Available from anatomy.med.umich.edu.at](#) 4:17PM, 3 January 2014.

[Right upper quadrant pain Avilable from: www.medhelp.org.](#) at 8:10PM ,14June2014.

Sabina imran,department of radiology,ayub medical college; abttabad Pakistan :Apr-June2003.p150.

Slephanic Ryan, Michelle Mcnicholas,Stephen Eustace.Anatomy for diagnostic image.2end edition.Elisevierlimited ;China:2004.p.176-177.

ultrasound Avilable from:[www.ultrasound.edu](http://www.ultrasound.edu).at1:45PM, 8Fibruary2014.

Vinay Kumar, Ramzi S. Cortan, Stanley L. Robbins. Basic pathology. 7th ed. Saunders; Philadelphia, Pennsylvania: 2003. P . 414-417.

william F. Ganong. Review of medical physiology. 21thedition. Lang medical books; USA: 2001. p.405.

## Appendix I

Sudan University of Science and Technology  
Collage of Graduate Studies

### Assessment of patients with right upper quadrant pain using ultra sound Data Collection Sheet

**Patient No:** -----

Patient Identification:

Age:

Gender:

Residence:

Khartoum:                      Omdurman:      Khartoum Bahri :

Pain grading:

1-mild

2-moderate

3- Sever

Ultrasound Findings:

-Gall bladder ultra sound findings:

Normal ( ) stones ( ) calculus cholecystitis ( )      acalculus chole cystitis

-Gall bladder thickness:

Normal ( )                      thickened ( )

-liver ultra sound findings:

Normal ( ) portal hypertension ( ) cyst ( ) hepatitis ( )

-Liver size:

Normal ( )                      Enlarged ( )

-Pancreas ultra sound findings:

Normal ( )                      pancreatitis ( )

-CBD ultra sound findings:

Normal ( )                      stone ( )

-CBD diameter:

Normal ( )                      increase ( )

- Others ultra sound findings:                      Normal ( )                      gasses bowel ( )

**Final Diagnosis** .....

## Appendix II

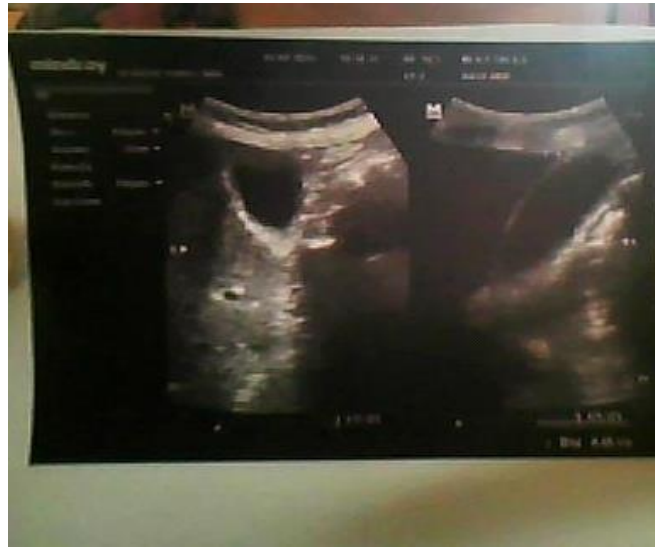

Image (1) Ultrasound of 45 years female showing Acalculous cholecystitis.

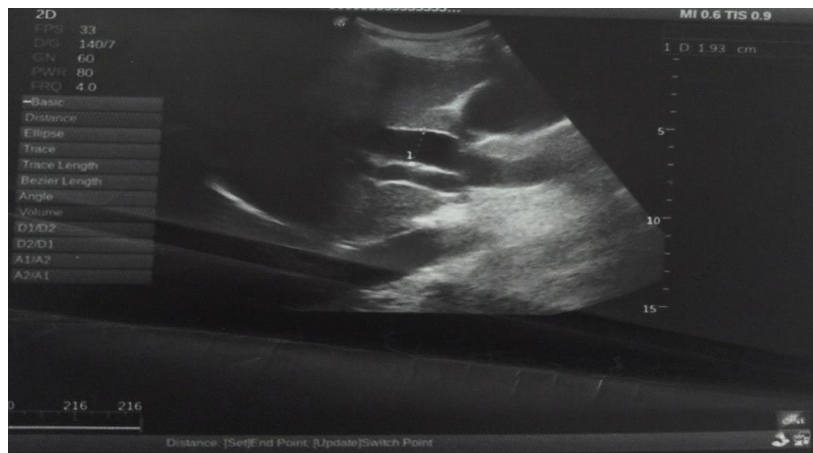


Image (2) Ultrasound image of 34years female showing dilated CBD.

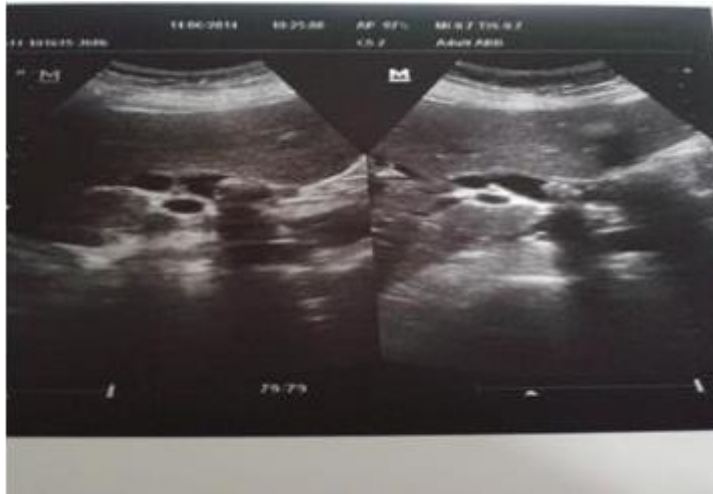

Image (3) Ultrasound image of 32 years female showing common bile duct stone.

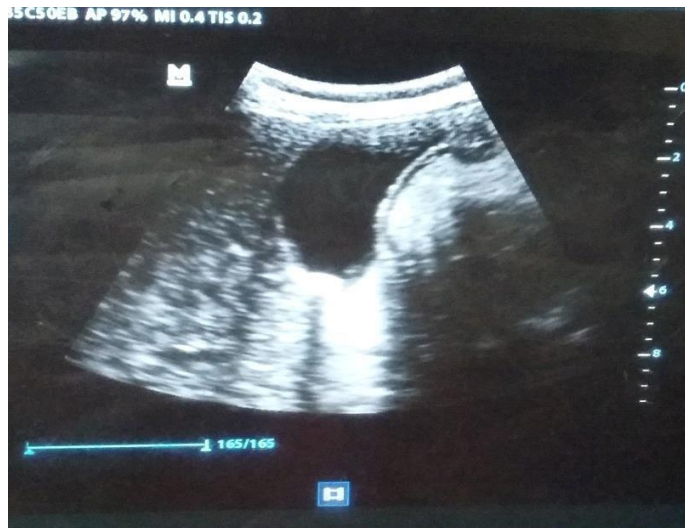

Image (4) Ultrasound image of 30years female showing gallbladder stone

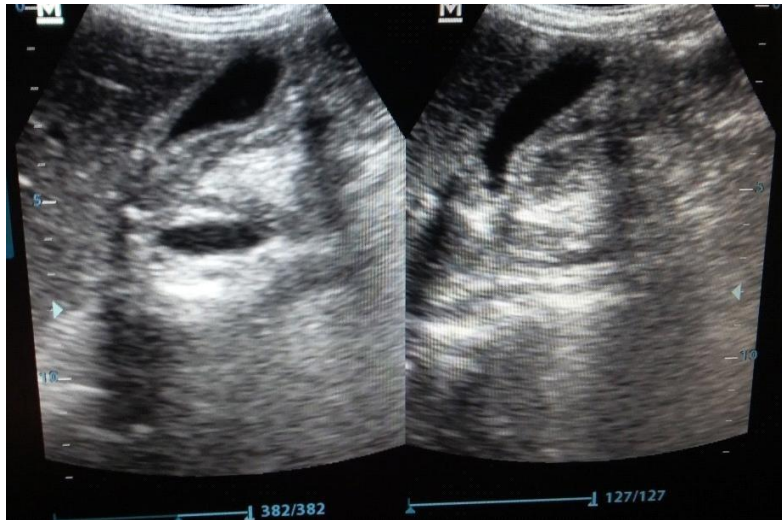


Image (5) Ultrasound image of 36 years male showing acalculous cholecystitis

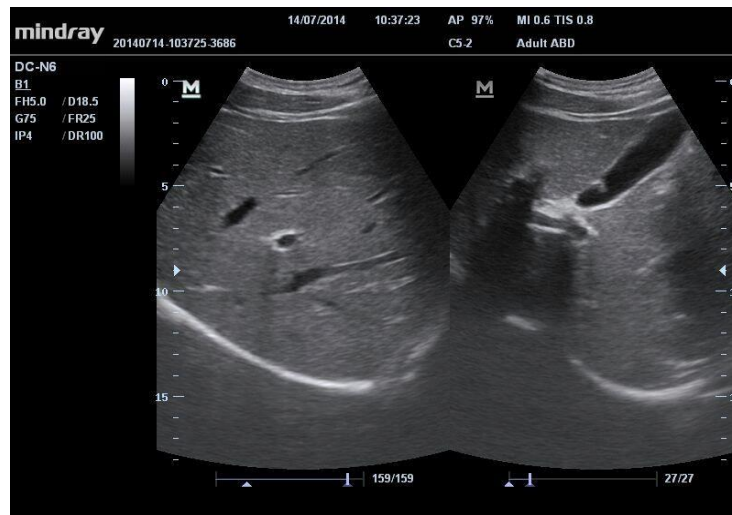


Image (6) Ultrasound image of 40 years female showing normal liver and gallbladder.



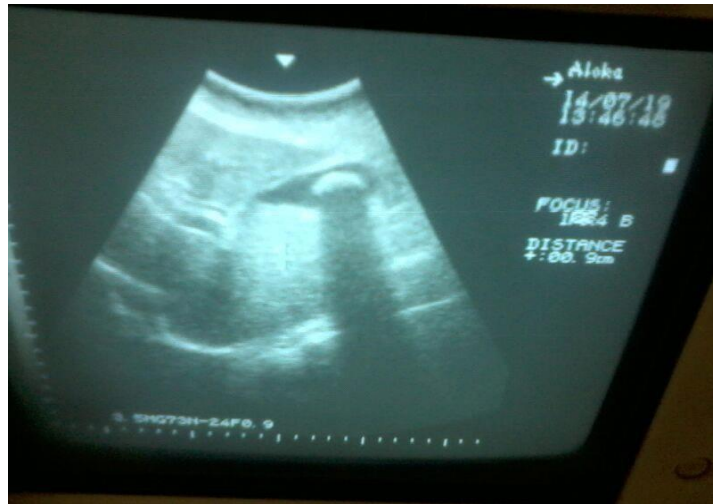

Image (7) Ultrasound image of 27years female showing gall bladder stone(9mm).

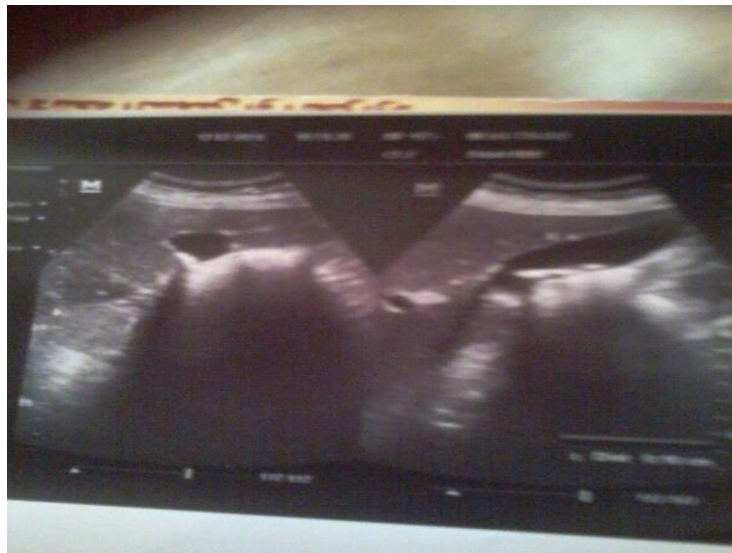

Image (8) Ultrasound image of 35years female showing gallbladder stone(milk of calcium).

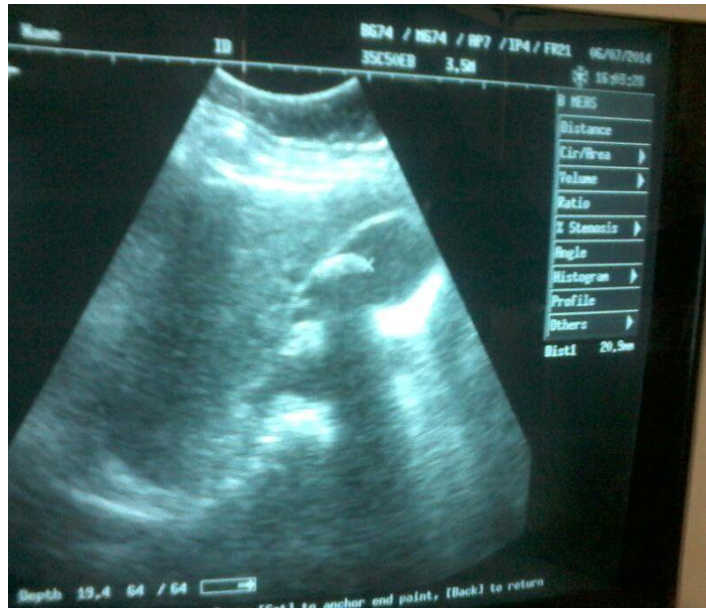

Image (9) Ultrasound image of 30years female showing gallbladder stone (20.9mm).

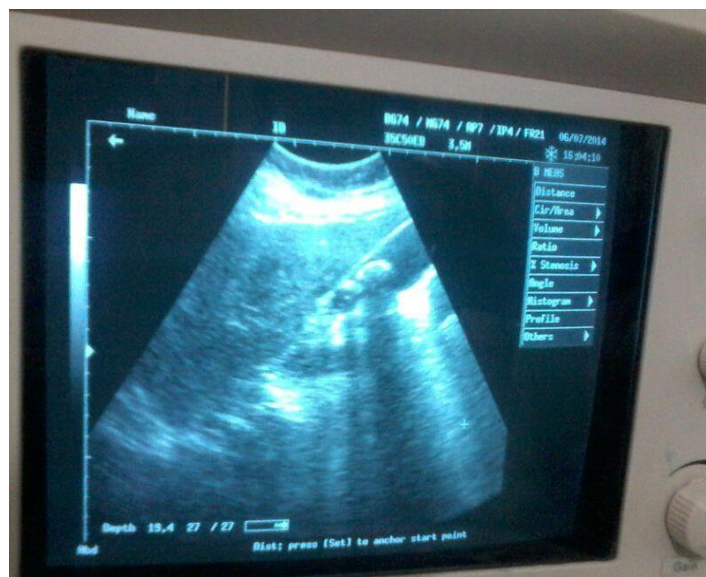

Image (10) Ultrasound image of 40years female showing multiple gallbladder stones.

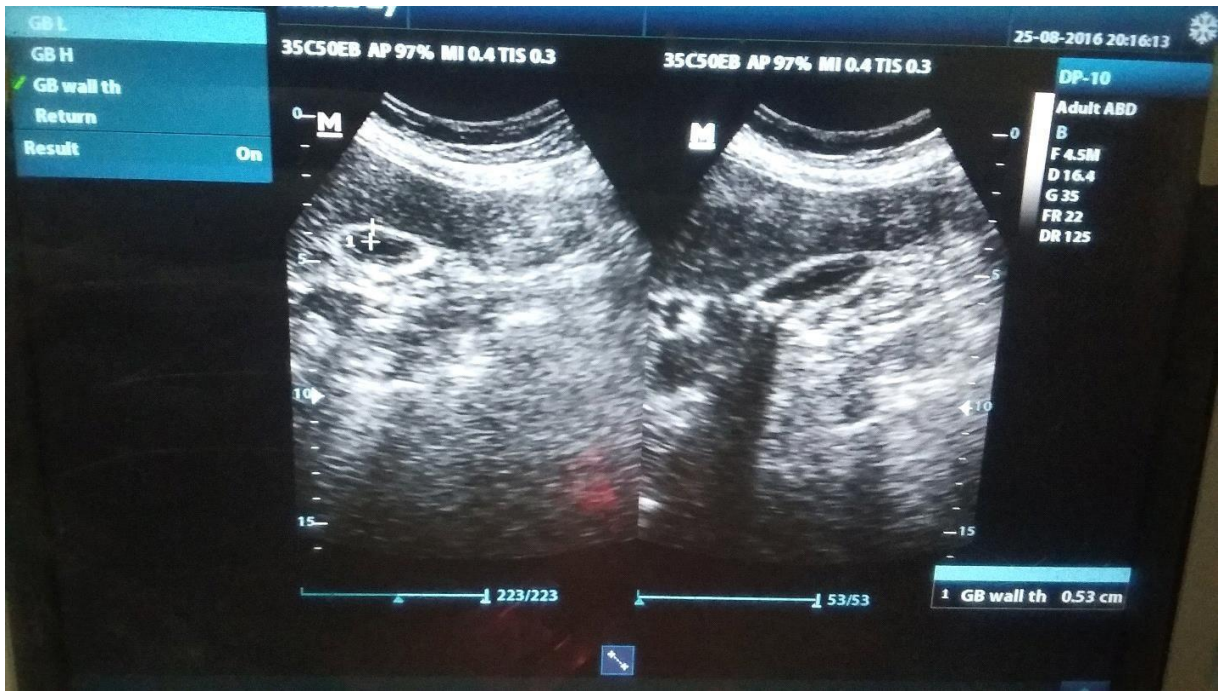

Image (11) Ultrasound image of 60 years female showing calculus cholecystitis.

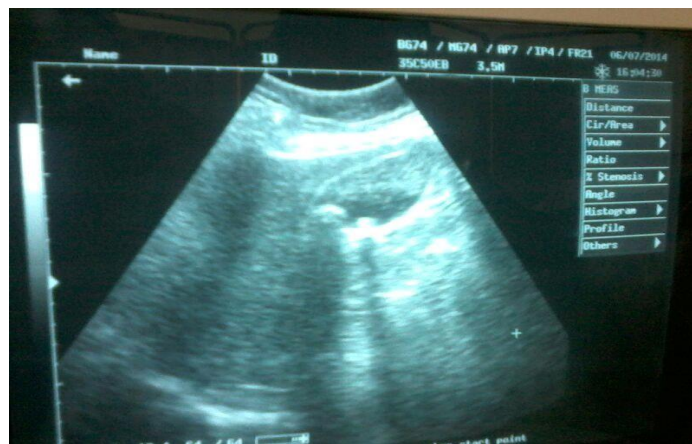

Image (12) Ultrasound image of 32 years male showing multiple gallblader stones.

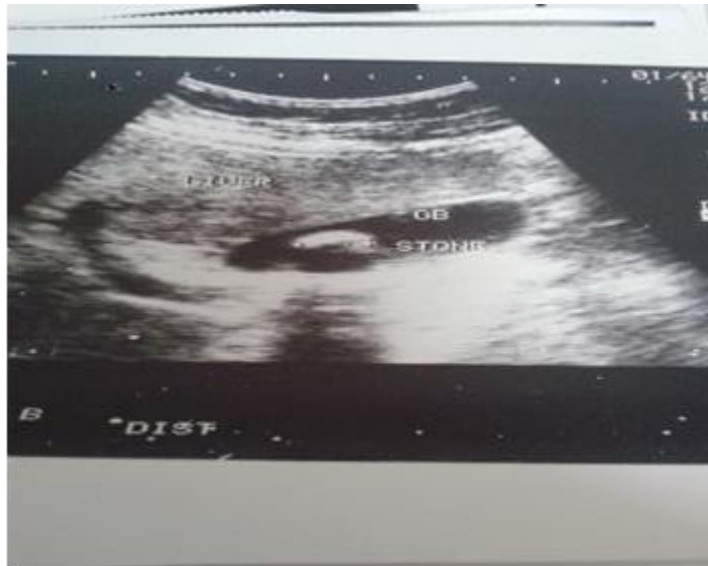

Image (13) Ultrasound image of 38years female showing calculus cholecystitis.

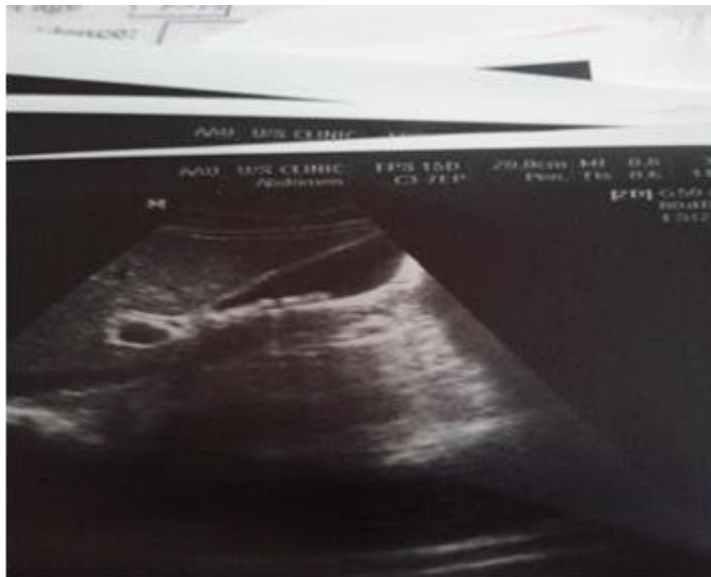

Image (14) Ultrasound image of 22 years male showing multiple gallblader stones.

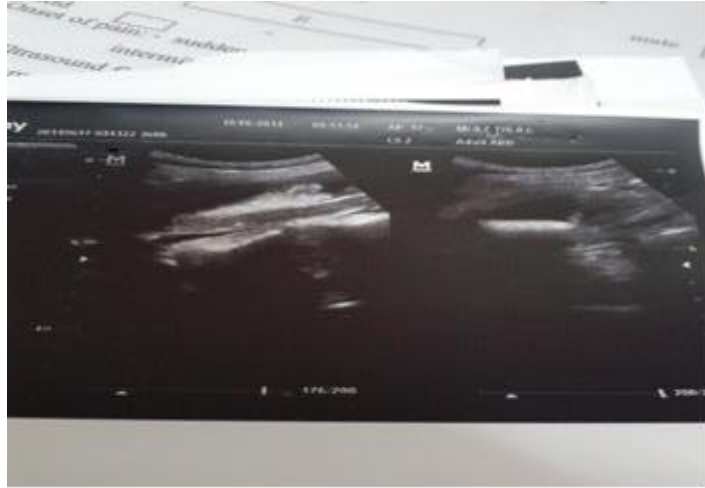

Image (15) Ultrasound image of 35years male showing gallbladder stone(milk of calcium).

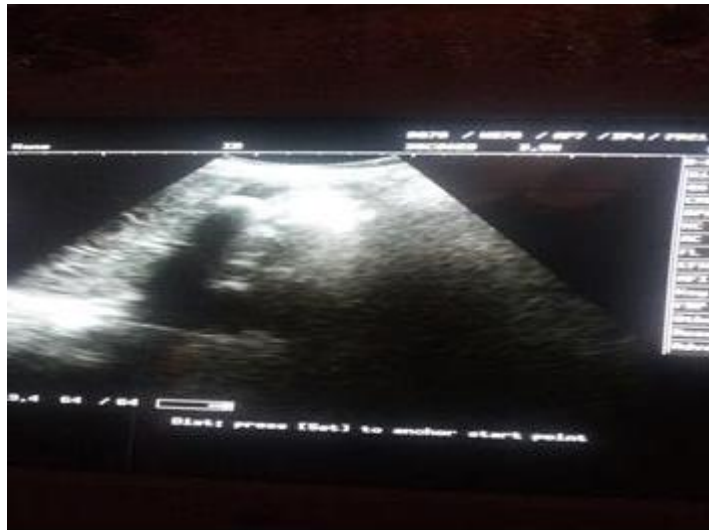

Image (16) Ultrasound image of 25years female showing multiple gallbladder stone.

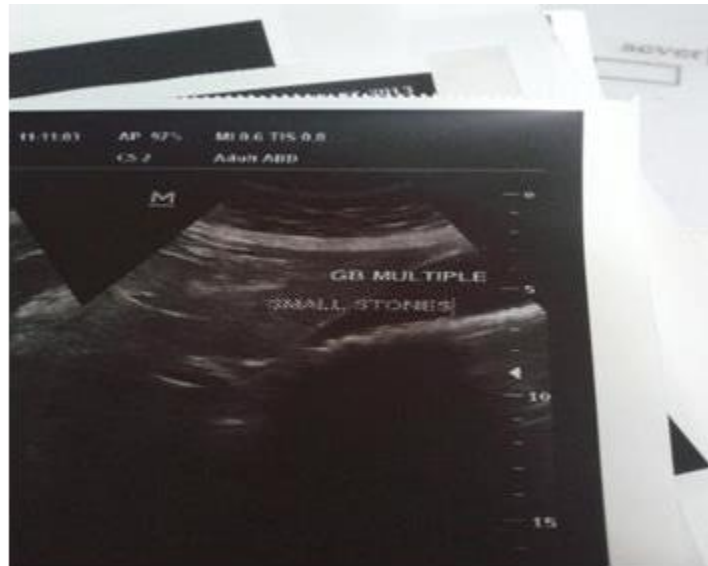

Image (17) Ultrasound image of 33 years female showing multiple gallbladder stones.

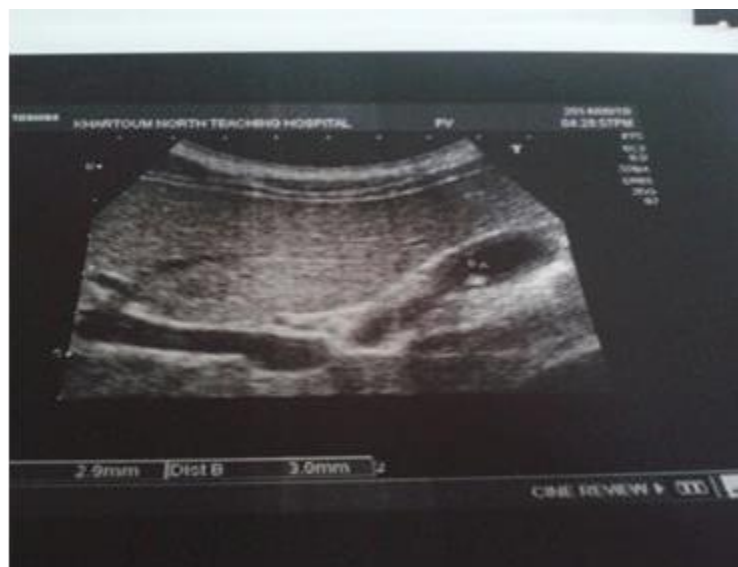

Image (18) Ultrasound image of 35years male showing calculus cholecystitis.

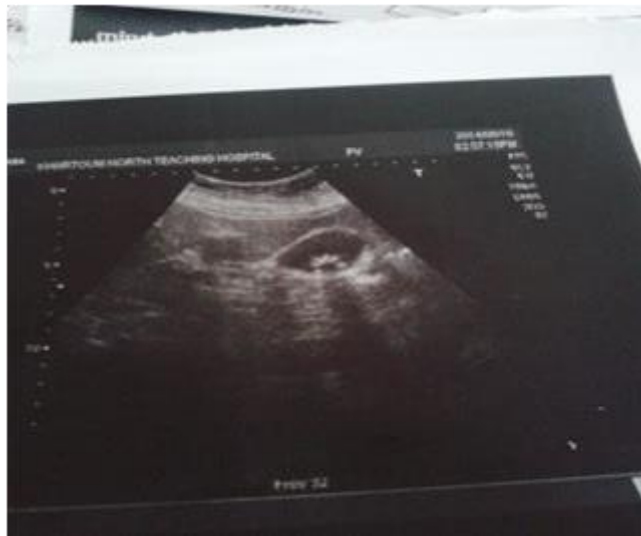
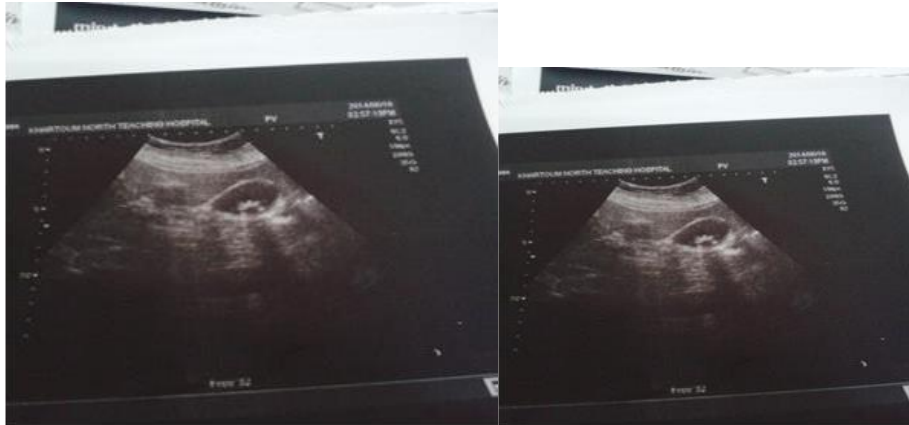
Image (19) Ultrasound image of 39 years female showing multiple Gallbladder stones.

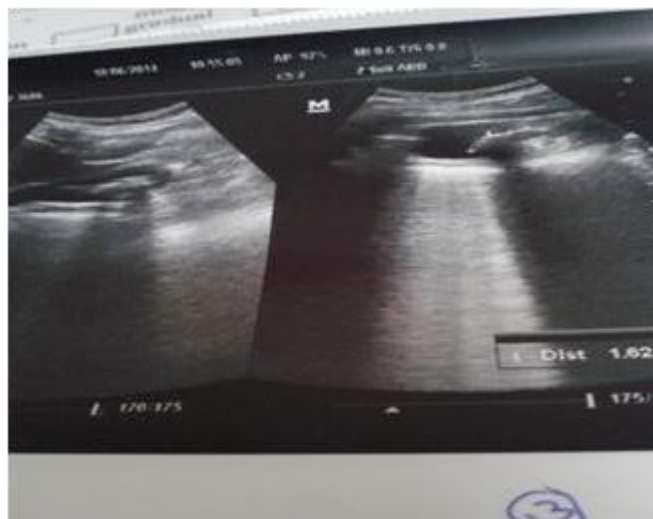

Image (20) Ultrasound image of 45 years male showing multiple gallbladder stone