



بسم الله الرحمن الرحيم

Sudan University of Science and Technology  
College of Graduate Studies



**Rates of Parasitic Contamination for *Arachis hypogaea* L (Groundnuts) ,  
*Citrullus lanatus* Seeds (Watermelon Seeds) , and *Ziziphus spina-christi*  
Fruit (Nabag) Sold by Street Venders in Khartoum State**

معدل التلوث الطفيلي في الفول السوداني وحبوب البطيخ والنبق المباعة بواسطة الباعة المتجولين  
في ولاية الخرطوم

A dissertation submitted in partial fulfillment of the requirements of M.Sc. degree in  
Medical Laboratory Science (Parasitology and Medical Entomology)

**Submitted by**

Arwa Suleiman Mohammed Ahmed

**Supervisor**

Dr. Ahmed Bakheet Abd Alla

Assistant Professor in Parasitology and Medical Entomology, Sudan University of Science  
and Technology

**January, 2020**

بِسْمِ اللَّهِ الرَّحْمَنِ الرَّحِيمِ

الآية

وَهُوَ الَّذِي أَنْزَلَ مِنَ السَّمَاءِ مَاءً فَأَخْرَجْنَا بِهِ نَبَاتَ كُلِّ  
شَيْءٍ فَأَخْرَجْنَا مِنْهُ خَضِرًا نُخْرِجُ مِنْهُ حَبًّا مُتَرَاكِبًا وَمِنْ  
النَّخْلِ مِنْ طَلْعِهَا قِنْوَانٌ دَانِيَةٌ وَجَنَّاتٍ مِنْ أَعْنَابٍ  
وَالزَّيْتُونِ وَالرَّيْحَانِ مُشْتَبِهًا ۗ وَغَيْرَ مُتَشَابِهٍ ۗ انظُرُوا إِلَى  
ثَمَرِهِ إِذَا أَثْمَرَ وَيَنْعِهِ ۗ إِنَّ فِي ذَلِكَ لَآيَاتٍ لِقَوْمٍ يُؤْمِنُونَ

﴿٩٩﴾

صدق الله العظيم

سورة الأنعام

# *Dedication*

*For my sweetheart family,*

*For my treasure friends,*

*For any person who supported me and  
encouraged me at critical times even by a  
phrase,*

*For every one working earnestly to live  
honorably,*

*I dedicate this work with much appreciation  
and sincere wishes for better life full of health  
and happiness...*

# *Acknowledgement*

*First of all, I thank Allah for providing me strength and patience until finishing this work,*

*Faithfully, I express my thanks and gratitude to my supervisor Dr. Ahmed Bakheet Abd Allah for assistance and orientations that let to completion of this study.*

*Profound thank is extending to all members of Parasitology and Medical Entomology Department, College of Medical Laboratory Science, Sudan University of Science and Technology.*

*A lot of gratitude to my friend Alaa Mohammed Ahmed Mohammed for her helps in samples collection.*

## Abstract

Various plants products including seeds are an important source for vitamins, minerals, proteins, and energy. Predominantly they are eaten fresh and uncooked or even if they are cooked; they are handled in un-hygienic manner that change them to a major source of intestinal infection. This study aimed to assess the parasitic contamination in roasted groundnut, nabag, and tasali sold by street vendors at Khartoum state, Sudan at the period from July 2019 to January 2020. A total of 45 samples (15 of each crop) were purchased from different 15 street vendors (5 from each block) at Khartoum state. Samples were washed and exposed to parasitological concentration techniques; Formal Ether Concentration Technique and Saturated Sugar Flootation technique to detect any infective stage. The obtained data were analyzed using SPSS. The frequency of parasitic contamination among all crops products was calculated in addition to using Chi-square to test the significance of relationships. The detected parasites included two genera; *E.histolytica* (33.3%) and *G.lamblia* (15.6%); whereas no any helminthic parasites were detected. Mixed contamination of the mentioned parasites was observed in 11.1%. The most contaminated crop was nabag (22.2%) followed by roasted groundnut (20%), and then tasali (17.8%). There was no relation between the positivity of samples and crop type (P value= 0.757). The relations between the detected parasite species and crop type, Khartoum blocks were also insignificant (p value: 0.639 and 0.460 respectively). Concerning the used techniques; FECT was more sensitive than saturated sugar technique (p value: 0.000). The present study showed that; there was no effect of crop type on the result positivity of used techniques; FECT and saturated sugar solution technique (p value: 0.655 and 0.591 respectively). The recovered parasite species were implicated in large numbers of intestinal parasitic infections at Khartoum state; hence health authorities should take corrective actions including: soil

and water screening at the beginning of agricultural season. In addition to periodic check of vendors themselves and their products in central markets or streets. Improve the health education level of farmers, sellers, and population about the infection acquiring and how to prevent it would provide maximum help.

## مستخلص الدراسة

مختلف أنواع منتجات النباتات متضمنة الحبوب؛ هي مصدر مهم للفيتامينات، المعادن، البروتين، والطاقة. غالباً يتم أكلها طازجة غير مطبوخة أو حتى لو طبخت يتم تناولها بسلوك غير صحي مما يحولها لمصدر رئيسي للأخماج المعوية. هدفت الدراسة لتقييم التلوث الطفيلي في الفول السوداني، النبق، والتسالي المباعة بواسطة الباعة المتجولين في ولاية الخرطوم، السودان في الفترة من يوليو 2019 إلى يناير 2020. مجموع 45 عينة (15 من أي ناتج محصول) تم شراؤها من 15 بائع متجول مختلف (5 من كل حي) في ولاية الخرطوم. العينات غسلت وعرضت لتقنيات التركيز الطفيلية متضمنة تقنية تركيز الفورمال إيثر و تقنية طفو محلول السكر المشبع. النتائج المتحصل عليها حلت باستخدام الحزمة الإحصائية للعلوم الإجتماعية. أظهرت النتائج أن التكرار للتلوث الطفيلي وسط كل منتجات المحاصيل حسب، بالإضافة لاستخدام Chi-square لاختبار أهمية العلاقات الطفيليات المكتشفة تضمنت نوعين: المتحولة الحالة للنسج (33.3%) والجيارديا اللمبية (15.6%) بينما لم تكتشف أي ديدان طفيلية. تلوث مختلط من الطفيليات المذكورة شوهد (11.1%). المحصول الأكثر تلوثاً كان النبق (22.2%) متبوعاً بالفول السوداني المحمص (20%) ومن ثم التسالي (17.8%). لم تكن هناك علاقة بين إيجابية العينات ونوع المحصول ( $P=0.757$ ). العلاقة بين نوع الطفيل المكتشف ونوع المحصول في مختلف أحياء الخرطوم أيضاً كانت غير مهمة ( $P=0.639$  و  $P=0.460$  على التوالي). فيما يتعلق بالتقنيات المستخدمة؛ تقنية تركيز الفورمال إيثر كانت أكثر حساسية من تقنية محلول السكر المشبع ( $P=0.000$ ). الدراسة الحالية؛ أظهرت ذلك؛ لا تأثير لنوع المحصول

على إيجابية نتيجة التقنية المستخدمة؛ تقنية تركيز الفورمال إيثر وتقنية السكر المشبع (0.591 و  $P=0.655$ ) على التوالي. أنواع الطفيليات المغطاة كانت متورطة في أعداد كبيرة من الأخماج المعوية الطفيلية في ولاية الخرطوم؛ لذا يجب على مسؤولي الصحة اتخاذ الأفعال المصححة متضمنة فحص المياه والترربة عند بداية الموسم الزراعي بالإضافة لفحص دوري للباعة أنفسهم ولمنتجاتهم في الأسواق المركزية والشوارع. تعليم المزارعين، الباعة، والمواطنين عن اكتساب الأخماج وكيفية منعها سيساعد بطريقة قصوى.



## List of contents

الأية .....	I
Dedication .....	II
Acknowledgement .....	III
Abstract.....	IV
مستخلص الدراسة .....	V

### Chapter one: Introduction

1.1 Introduction.....	1
1.2 Rationale .....	4
1.3 Objectives.....	5
1.3.1 General objective.....	5
1.3.2 Specific objectives.....	5

### Chapter two: Literature review

2.1 The intestinal protozoa .....	6
2.1.1 Intestinal amoeba .....	6
2.1.1.1 <i>Entamoeba histolytica</i> .....	6
2.1.1.1.1 Background.....	6
2.1.1.1.2 Epidemiology .....	7
2.1.1.1.3 Mode of transmission.....	8
2.1.1.1.4 Morphology.....	8
2.1.1.1.4.1 Trophozoite.....	8
2.1.1.1.4.2 Cyst.....	9
2.1.1.1.5 Life cycle .....	10
2.1.1.1.6 Clinical presentation and pathogenicity .....	11
2.1.1.1.6.1 Clinical presentation .....	11
2.1.1.1.6.1.1 Intestinal disease.....	11
2.1.1.1.6.1.2 Liver abscess .....	12

2.1.1.1.6.2 Pathogenesis.....	13
2.1.1.1.7 Laboratory diagnosis .....	14
2.1.1.1.8 Treatment.....	15
2.1.1.1.9 Prevention and control .....	16
2.1.1.2 <i>Blastocystis hominis</i> .....	16
2.1.1.2.1 Background.....	16
2.1.1.2.2 Epidemiology .....	17
2.1.1.2.3 Mode of transmission.....	18
2.1.1.2.4 Morphology.....	18
2.1.1.2.4.1 Trophozoite.....	18
2.1.1.2.4.2 Cyst.....	18
2.1.1.2.5 Life cycle .....	18
2.1.1.2.6 Clinical presentation and pathogenicity .....	19
2.1.1.2.7 Laboratory diagnosis .....	20
2.1.1.2.8 Treatment.....	21
2.1.1.2.9 Prevention and control .....	21
2.1.2 The intestinal flagellates .....	22
2.1.2.1 <i>Giardia lamblia</i> .....	22
2.1.2.1.1 Background.....	22
2.1.2.1.2 Epidemiology .....	22
2.1.2.1.3 Mode of transmission.....	24
2.1.2.1.4 Morphology.....	24
2.1.2.1.4.1 Trophozoite.....	24
2.1.2.1.4.2 Cyst.....	25
2.1.2.1.5 Life cycle .....	25
2.1.2.1.6 Clinical presentation and pathogenicity .....	25
2.1.2.1.7 Laboratory diagnosis .....	26

2.1.2.1.7.1 Stool examination .....	26
2.1.2.1.7.2 Entero-test (String test) .....	26
2.1.2.1.7.3 Serodiagnosis .....	27
2.1.2.1.7.3.1 Antigen detection.....	27
2.1.2.1.7.3.2 Antibody detection .....	27
2.1.2.1.7.4 Molecular method .....	27
2.1.2.1.8 Treatment.....	27
2.1.2.1.9 Prevention and control .....	28
2.1.3 The intestinal ciliates .....	28
2.1.3.1 <i>Balantidium coli</i> .....	28
2.1.3.1.1 Background.....	28
2.1.3.1.3 Mode of transmission.....	29
2.1.3.1.4 Morphology.....	29
2.1.3.1.4.1 Trophozoite.....	29
2.1.3.1.4.2 Cyst.....	30
2.1.3.1.5 Life cycle .....	30
2.1.3.1.6 Clinical presentation and pathogenicity .....	31
2.1.3.1.7 Laboratory diagnosis .....	31
2.1.3.1.8 Treatment.....	32
2.1.3.1.9 Prevention and control .....	32
2.1.4 The intestinal coccidian .....	32
2.1.4.1 <i>Cryptosporidium parvum</i> .....	32
2.1.4.1.1 Background.....	32
2.1.4.1.2 Epidemiology .....	33
2.1.4.1.3 Mode of transmission.....	34
2.1.4.1.4 Morphology.....	34
2.1.4.1.4.1 Oocysts .....	34

2.1.4.1.4.1 Schizonts and gametocytes .....	35
2.1.4.1.5 Life cycle .....	35
2.1.4.1.6 Clinical presentation, pathogenicity .....	36
2.1.4.1.6.1 Immuno competent hosts.....	36
2.1.4.1.6.2 Childhood diarrhea and malnutrition.....	37
2.1.4.1.6.3 The Immuno-compromised host.....	37
2.1.4.1.7 Laboratory diagnosis .....	38
2.1.4.1.8 Treatment.....	40
2.1.4.1.9 Prevention and control .....	40
2.1.4.2 <i>Isospora belli</i> .....	40
2.1.4.2.1 Background.....	40
2.1.4.2.2 Epidemiology .....	41
2.1.4.2.3 Mode of transmission .....	41
2.1.4.2.4 Morphology.....	41
2.1.4.2.4.1 Oocysts .....	41
2.1.4.2.5 Life cycle .....	42
2.1.4.2.6 Clinical presentation and pathogenicity .....	42
2.1.4.2.6.1 Asymptomatic.....	42
2.1.4.2.6.2 Isosporiasis.....	43
2.1.4.2.7 Laboratory diagnosis .....	43
2.1.4.2.8 Treatment.....	44
2.1.4.2.9 Prevention and control .....	44
2.1.4.3 <i>Cyclospora cayetanensis</i> .....	44
2.1.4.3.1 Background.....	44
2.1.4.3.2 Epidemiology .....	45
2.1.4.3.3 Mode of transmission .....	46
2.1.4.3.4 Morphology.....	46

2.1.4.3.4.1 Oocyst.....	46
2.1.4.3.5 Life cycle .....	46
2.1.4.3.6 Clinical presentation and pathogenicity .....	47
2.1.4.3.7 Laboratory diagnosis .....	47
2.1.4.3.8 Treatment .....	47
2.1.4.3.9 Prevention and control .....	48
2.2 The Intestinal helminths .....	48
2.2.1 The intestinal cestodes .....	48
2.2.1.1 <i>Taenia solium</i> .....	49
2.2.1.1.1 Background.....	49
2.2.1.1.2 Epidemiology .....	50
2.2.1.1.3 Mode of transmission.....	50
2.2.1.1.4 Morphology.....	50
2.2.1.1.4.1 Adult.....	50
2.2.1.1.4.2 Eggs .....	51
2.2.1.1.4.3 Larvae .....	51
2.2.1.1.5 Life cycle .....	52
2.2.1.1.6 Clinical presentation and pathogenicity .....	52
2.2.1.1.6.1 Intestinal Taeniasis.....	52
2.2.1.1.6.2 Cysticercosis.....	53
2.2.1.1.7 Laboratory diagnosis .....	53
2.2.1.1.7.1 Biopsy:.....	53
2.2.1.1.7.2 Imaging methods:.....	53
2.2.1.1.7.3 Serology: .....	54
2.2.1.1.9 Prevention and control .....	54
2.3 The investigated plants products .....	54
2.3.1 Watermelon seeds.....	54

2.3.1.1 Botanical description .....	54
2.3.1.2 Ecology .....	55
2.3.1.3 Utilization.....	55
2.3.1.3.1 Nutritional value .....	55
2.3.1.3.2 Medicinal value.....	56
2.3.1.4 Chemical composition of water melon seed .....	56
2.3.1.4.1 Moisture content .....	56
2.3.1.4.2 Crude protein .....	57
2.3.1.4.3 Oil contents .....	57
2.3.1.4.4 Crude fiber.....	57
2.3.1.4.5 Total ash contents.....	57
2.3.1.4.6 Carbohydrates contents.....	57
2.3.2 Nabag.....	58
2.3.2.1 Local names .....	Error! Bookmark not defined.
2.3.2.2 Botanical description .....	58
2.3.2.3 Ecology .....	59
2.3.2.4 Utilization.....	59
2.3.2.4.1 Nutritional use .....	59
2.3.2.4.2 Medicinal use .....	60
2.3.2.4.3 Other uses .....	62
2.3.2.5 Chemical composition.....	62
2.3.3 Groundnuts.....	62
2.3.3.1 Botanical description .....	62
2.3.3.2 Ecology .....	63
2.3.3.3 Utilization.....	63
2.3.3.3.1 Medicinal use .....	63
2.3.3.3.2 Nutritional use .....	64

2.3.3.4 Chemical composition.....	64
2.3.3.4.1 Oil contents .....	64
2.3.3.4.2 Protein contents.....	65
2.3.3.4.3 Carbohydrate content.....	65
2.3.3.4.4 Minerals contents .....	65
2.3.3.4.5 Vitamins .....	65

### **Chapter three: Materials and methods**

3.1 Study design: .....	66
3.2 Study area and duration: .....	66
3.3 Study populations: .....	66
3.4 Sample size and sampling:.....	66
3.5 Data collection: .....	66
3.6 Methodology: .....	67
3.6.1 Crops sample collection and preparation:.....	67
3.6.2 Formal- ether concentration technique: .....	67
3.6.3 Saturated sugar floatation technique:.....	68
3.7 Statistical data analysis: .....	68
3.8 Ethical considerations: .....	68

### **Chapter four: Results**

4.1 General characteristics of studied population: .....	69
4.2 Overall contamination rate and its relation to the type of crops:.....	70
4.3 The detected parasitic species: .....	70
4.4 Comparison between the sensitivity of FECT and sugar floatation technique in detecting parasites from crops:.....	71
4.5 Comparison between the parasite species detection and the type of used technique:.....	71
4.6 Correlation between crop type and detected parasite species: .....	72

<b>4.7 Comparison between positivity of crop type and used technique: .....</b>	<b>73</b>
<b>4.8 Correlation between Khartoum state block and the species of the detected parasite:.....</b>	<b>73</b>

**Chapter five: Discussion, conclusion, and recommendations**

<b>5.1 Discussion.....</b>	<b>75</b>
<b>5.2 Conclusion.....</b>	<b>78</b>
<b>5.3 Recommendations .....</b>	<b>78</b>
<b>References .....</b>	<b>79</b>
<b>Appendix (1) .....</b>	<b>83</b>
<b>Appendix (2).....</b>	<b>78</b>

**List of tables**

<b>4.1 Frequency of study subjects according to age group:.....</b>	<b>65</b>
<b>4.2 Overall contamination rate and its relation to the type of crops:.....</b>	<b>66</b>
<b>4.3 The detected parasitic species:.....</b>	<b>66</b>
<b>4.4 Comparison between the sensitivity of FECT and sugar floatation technique in detecting parasites from crops:.....</b>	<b>67</b>
<b>4.5 Comparison between the parasite species detection and the type of used technique:.....</b>	<b>67</b>
<b>4.6 Correlation between crop type and detected parasite species:.....</b>	<b>68</b>
<b>4.7 Comparison between positivity of crop type and used technique:.....</b>	<b>69</b>
<b>4.8 Correlation between Khartoum state block and the species of the detected parasite:.....</b>	<b>71</b>



## List of figures

<b>Figure 1: <i>Entamoeba histolytica</i></b>	
cysts.....	<b>78</b>
<b>Figure 2: <i>Giardia lamblia</i></b>	
cysts.....	<b>78</b>
<b>Figure 3: Fungi.....</b>	<b>79</b>
<b>Figure 4: Nabag, Groundnut, and Tasali.....</b>	<b>79</b>

*Chapter One*  
*Introduction*

# Chapter I

## Introduction

### 1.1 Introduction

Intestinal parasitic infections are those whom transmitted usually via the oral route upon the ingestion of the infective organism in contaminated food, water, or hands (Paniker, 2013). The food's contamination and food borne parasitic diseases are frequently occurring globally; which are estimated to be 23.2 million cases, 45.927 deaths annually resulting in 6.64 million disability adjusted life years (DALYs) for helminthic infections; while 67.2 million illnesses or 492,000 (DALYs) for protozoan infections (Torgerson *et al.*, 2015). The fresh fruits and vegetables are an important source for getting food borne parasitic diseases according to previous studies conducted by Shahnazi and Jafari-Sabet (2010), and Tefera *et al.* (2014), on vegetable and fruits revealed that the prevalence rates of parasitic contamination were 37.6%, and 57.8% respectively. The nuts and seeds are also subjects can be contaminated according to Ogban and Ukpong (2018). They detected a wide range of parasitic contaminants in nuts (Tiger nuts) including: Nematoda (*Ascaris lumbricoides*, hookworm, *Strongyloides stercoralis*, *Trichuris trichiura*, *Toxocara* spp., *Enterobius vermicularis*), Cestoda (*Taenia* spp., *Hymenolepis* spp.), Trematoda (*Fasciola* spp.) and Protozoa (*Giardia lamblia*, *Cryptosporidium* spp.). Another study on nuts by Ayeh-Kumi *et al.* (2014) detected other contaminants like: stones, animal droppings, fungi toxins (flavus aflatoxins), and many bacterial species: *Staphylococcus* spp., *Klebsiella oxytoca*, *Enterobacter cloacae*, *Enterobacter* spp., and *Proteus vulgaris*. Since all food types can be exposed to the contamination including plants products and seeds like tiger nuts as reported by Ayeh-

Kumi *et al.* (2014) and Ogban and Ukpong. (2018); groundnuts, *Ziziphus spina Christi* (nabag), and water melon seeds (tasali) can be contaminated also. These mentioned crops products are planted and consumed because of their: nutritive, medicinal, or economical values. The nutritional components of: groundnuts, *Ziziphus spina christi* (nabag), and water melon seeds (tasali) are: oil- protein- minerals (phosphorus, calcium, magnesium and potassium)- and vitamins (E, K, and B group) (Asibuo *et al.*, 2008), carbohydrates- protein- fat- iron- calcium- ascorbic acid- thiamine- riboflavin- and niacin (Saied *et al.*, 2008), and moisture- protein- fat- ash- fiber- carbohydrates- and minerals (sodium, phosphorus, manganese, zinc, ion, and calcium) (Betty *et al.*, 2016) respectively. The medicinal values of groundnuts are: cardio-protective, anti-carcinogenic, anti-inflammatory, and antioxidant properties ([WWW.Peanut-institute.org](http://WWW.Peanut-institute.org)). *Ziziphus* -nabag- used medicinally as hypoglycemic, hypotensive, anti-inflammatory, antimicrobial, antioxidant, anti-tumor, and liver protective agent and as an immune system stimulant (Saied *et al.*, 2008). The medicinal value of watermelon seeds is the antioxidant activity (Betty *et al.*, 2016). Groundnuts in Sudan mainly used for extraction of oil; but can be used as "snacks" freshly or after some processing. Among the three crops products; ground nuts have the widest use; it may be eaten after crushing the grilled nuts to obtain groundnuts butter (Vara *et al.*, 2015). Groundnuts butter locally is known as: "Dakwa"; which is used in preparing sauces that can be involved in salads dishes. Groundnuts is eaten as snack: raw, after grilling (roasting) without its external cortex envelop, or after boiling it in salted water with its external envelop (Vara *et al.*, 2015). Watermelon seeds are dried, salted, and grilled (Betty *et al.*, 2016) or used for animal nutrition "watermelon cake seed" (Beshir and Babiker, 2009); while nabag is eaten directly or after the sweet pulp of fruit is dried to produce fine flour (Saied *et al.*, 2008). Typically, this flour is placed in

small metal cups and cooked under steam (Saied *et al.*, 2008). The process solidifies the flour to the shape of the container (Saied *et al.*, 2008). The dried pulp flour and water are also mixed with sesame and formed into small balls (Saied *et al.*, 2008). The fruit pulp prepared in these two ways can be consumed either immediately or stored to be used in future (Saied *et al.*, 2008). In addition to groundnuts, nabag, and tasali, there are many crops product be sold which represent an important (even the only) source of income for some populations in Sudan. These crops products are sold in many different places; for example: in vehicles stations and in the front of schools, hospitals, restaurants, and along streets where they exposed to various contaminants and can be handled with dirty and contaminated hands.

## **1.2 Rationale**

Intestinal parasitic infections are very common worldwide. They are often not diagnosed and hence not treated too; although they produce harmful effects which can be lethal in some cases; for example parasitic worms may lead to severe B12 vitamin deficiency, severe mechanical damage and toxic effect, rectal prolapse, paralytic ileus, and granulomas as in case of diphylobothriasis, ascariasis, trichuriasis, fasciolopsiasis, and heterophyes infection respectively (Paniker, 2013); whereas protozoan infections can lead to severe dysentery and liver abscess (entamoebiasis) or malabsorption syndrome (giardiasis) (Paniker, 2013). Since most of those intestinal parasitic infections are transmitted orally; food's contamination have the key role in their transmission and be a cause of death rather than necessary of life. Food's contamination occurs when food prepared, stored, or handled; which is common in public places like streets. Streets vendors are considered as an important player in the spread of orally transmitted intestinal parasitic infections; because they present their products usually uncovered and handled it with bare hands exposing it to all contaminants. Furthermore; they occupy the crowded places like: front of schools, hospitals, and vehicles' stations spreading infections in very extensive manner. This study will give approximated value and primary image about the parasitic contamination rates for some street vendor's product because in Sudan there is no available data about contamination of some street vendor's products including: nabag, tasali, and groundnuts which are considered the most desirable crop's products. Identifying the parasitic contamination absolutely will help in fighting those infections; because knowing contamination rates enable taking the necessary measures which are needed to control recent infections and prevent future re-emerging and possible outbreaks.

## **1.3 Objectives**

### **1.3.1 General objective**

To identify parasitic contamination rate of *Arachis hypogaea* L (groundnuts), *Citrullus lanatus* seeds (watermelon seeds), and *Ziziphus spina-christi* (nabag) sold by street vendors in Khartoum state in Sudan.

### **1.3.2 Specific objectives**

- To estimate the parasitic contamination rate for each selected product.
- To correlate between the contamination rate and the type of the purchased product.
- To compare between the sensitivities of FECT and sucrose floatation technique.

*Chapter two*  
*Literature review*



## Chapter II

### Literature review

#### 2.1 The intestinal protozoa

##### 2.1.1 Intestinal amoeba

Amoebae are structurally simple protozoans which have no fixed shape. They are classified under Phylum: Sarco-mastigophora, Subphylum: Sarcodina, Superclass: Rhizopoda and Order: Amoebida (Paniker, 2013). The cytoplasm of amoeba is bounded by a membrane and can be differentiated into an outer ectoplasm and inner endoplasm. Pseudopodia are formed by the amoeba by thrusting out ectoplasm, followed by endoplasm (Paniker, 2013). These are employed for locomotion and engulfment of food by phagocytosis. Reproduction occurs by fission and budding (Paniker, 2013). Cyst is formed in unfavorable conditions and is usually the infective form for vertebrate host (e.g. *Entamoeba histolytica*) (Paniker, 2013). At least 10 amoebae are found in the mouth or intestinal lumen (*E. histolytica*, *E. dispar*, *E. moshkovskii*, *E. hartmanni*, *E. coli*, *E. polecki*, *E. gingivalis*, *E. nana*, *Iodamoeba bütschlii*, and *Blastocystis hominis*) (Garcia, 2007). However, of these only *E. histolytica* and *B. hominis* have been considered to be pathogenic (Garcia, 2007).

##### 2.1.1.1 *Entamoeba histolytica*

###### 2.1.1.1.1 Background

*E. histolytica* was first described by Losch after being isolated in Russia from a patient with dysenteric stools (Garcia, 2007). Although Losch found the organisms in human colonic ulcers at autopsy and was able to induce dysentery in a dog that was inoculated rectally with the patient's stools, he failed to recognize the causal relationship (Garcia, 2007). In

1890, William Osler reported the case of a young man with dysentery, who later died of liver abscess (Paniker, 2013). Councilman and Lafleur in 1891 established the pathogenesis of intestinal and hepatic amoebiasis and introduced the terms 'amoebic dysentery' and 'amoebic liver abscess' (Paniker, 2013).

#### **2.1.1.1.2 Epidemiology**

*E. histolytica* has been recovered worldwide and is more prevalent in the tropics and subtropics than in cooler climates (Garcia, 2007). However, infection rates in unsanitary conditions in temperate and colder climates have been found to equal those seen in the tropics (Garcia, 2007). The World Health Organization reported that *E. histolytica* causes approximately 50 million cases and 110,000 deaths annually (Garcia, 2007). The worldwide distribution of *E. histolytica* therefore primarily reflects the incomplete separation of human feces from water and food sources typical of densely populated areas of developing countries although infrequent outbreaks in developed countries have occurred (Satoskar *et al.*, 2009). In closely examined areas where *E. histolytica* is endemic, most infected adults are asymptomatic (Satoskar *et al.*, 2009). Depending on the age of the person, the time of asymptomatic infection can be considerable, with a half-life of parasite persistence of about 13 months in adults in one area of Vietnam where the 10% of adults are infected (Satoskar *et al.*, 2009). The time of parasite persistence in children appears to be shorter, which may reflect the higher incidence of diarrhea episodes from multiple unrelated causes in that age group that serves to physically remove the parasite (Satoskar *et al.*, 2009). The long (13 months) half-life of asymptomatic parasite infection in adults suggests that up to 5% of individuals can retain the parasite for up to 5 years (Satoskar *et al.*, 2009). Asymptomatic persons can therefore develop

intestinal or extra-intestinal disease (liver abscess) months to years after visiting areas where parasite transmission is known or suspected to occur (Satoskar *et al.*, 2009). Most cases of diagnosed *E. histolytica* infection in the US occur in immigrants, particularly those from Mexico, central and South America and Asia (Satoskar *et al.*, 2009). Sero-positivity reflecting the tissue-invasive capacity of *E. histolytica* is approximately 8% in the entire population of Mexico (Satoskar *et al.*, 2009). In contrast to disease restricted to the lumen of the intestine, which occurs nearly equally in males and females, for unknown reasons extra-intestinal liver abscess shows a 3-20 fold higher incidence in males versus females and in individuals that abuse alcohol (Satoskar *et al.*, 2009).

#### **2.1.1.1.3 Mode of transmission**

The mode of transmission is similar to that found with other protozoa and is related to the ingestion of infective cysts in contaminated food or water (Garcia, 2007). Much less often the cyst or the trophozoite form can be transmitted as a result of oral or oral/anal sexual practices (Satoskar *et al.*, 2009).

#### **2.1.1.1.4 Morphology**

##### **2.1.1.1.4.1 Trophozoite**

The trophozoite exhibits rapid, unidirectional progressive movement, achieved with the help of finger-like hyaline pseudopods (Zeibig, 2013). The size ranges from 8 to 65  $\mu\text{m}$ , with an average size of 12 to 25  $\mu\text{m}$  with a single nucleus typically contains a small central mass of chromatin known as a karyosome which is surrounded by fine and evenly (infrequently unevenly) distributed peripheral chromatin (Zeibig, 2013). Although the karyosome and peripheral chromatin appearance may vary, most trophozoites maintain the more typical features described (Zeibig,

2013). Stained preparations may reveal lightly staining fibrils located between the karyosome and peripheral chromatin (Zeibig, 2013). The trophozoite contains a finely granular cytoplasm, which is often referred to as having a ground glass in appearance, and red blood cells (RBCs) which are considered diagnostic because *E. histolytica* is the only intestinal ameba to exhibit this characteristic (Zeibig, 2013). Bacteria yeast, and other debris may also reside in the cytoplasm, but their presence, however, is not diagnostic (Zeibig, 2013).

#### **2.1.1.1.4.2 Cyst**

The cysts of *E. histolytica* are smaller than the trophs; 8 to 22  $\mu\text{m}$  with an average 12 to 18  $\mu\text{m}$ . Cyst wall is hyaline which helps in the morphological identification (Zeibig, 2013). Young cysts characteristically contain unorganized chromatin material that transforms into squared or round ended structures call chromatoid bars, defined as structures that contain condensed RNA material (Zeibig, 2013). A diffuse glycogen mass, a cytoplasmic area without defined borders that is believed to represent stored food, is also usually visible in young cysts. As the cyst matures, the glycogen mass usually disappears, a process that likely represents usage of the stored food (Zeibig, 2013). One to four nucleus usually appear basically same as those of the trophozoite in all respects but are usually smaller (Zeibig, 2013). Nuclear variations are: eccentric karyosomes, thin plaques of peripheral chromatin, or a clump of peripheral chromatin at one side of the nucleus that appears crescent shaped (Zeibig, 2013). The mature infective cyst is quadri-nucleated (containing four nuclei); cytoplasm remains fine, granular, and doesn't contain RBCs, bacteria, yeast, or any debris (Zeibig, 2013).

### **2.1.1.1.5 Life cycle**

Cysts are released from infected persons they are stable for days to weeks in low-temperature aqueous conditions (Satoskar *et al.*, 2009). Re-ingested cysts are resistant to the low pH of the stomach and appear to be triggered to exit the cyst capsule (ex-cyst) by components of bile and bicarbonate that are encountered in the small intestine. These meta-cystic amoebae are carried to the colon where the 10-30  $\mu\text{m}$  diameter trophozoite form adheres to the mucus layer overlying the colonic epithelium (Satoskar *et al.*, 2009). This adherence is mediated by lectins found on the surface of the trophozoite that have specificity for ligands expressing appropriately spaced terminal N-acetylgalactosamine and galactose sugar residues, as are found on the colonic form of mucin (Satoskar *et al.*, 2009). The trophozoite feeds on host ingesta components of mucus and the resident bacteria and multiplies by asexual binary fission (Satoskar *et al.*, 2009). In response to conditions and stimuli that are not yet completely defined, trophozoites stop multiplying and revert to the cyst form (encyst) (Satoskar *et al.*, 2009). These cysts are released in the tens of millions per gram of feces to allow for completion of the life cycle upon infection of another person (Satoskar *et al.*, 2009). Most cysts are released from asymptomatic carriers of the parasite, suggesting that conditions within the intestine that are conducive to cyst formation are not significantly abnormal (Satoskar *et al.*, 2009). Recent reports have also revealed an ability of products (short-chain fatty acids) normally produced by the enteric bacteria to regulate the encystment process (Satoskar *et al.*, 2009). Mixtures of cysts and trophozoites are more commonly released by symptomatic (dysenteric) persons, but the trophozoite form is generally not considered infectious due to its sensitivity to hypo-osmotic conditions outside the body and the low pH of the stomach (Satoskar *et al.*, 2009).

## **2.1.1.1.6 Clinical presentation and pathogenicity**

### **2.1.1.1.6.1 Clinical presentation**

Presentation of amebiasis can take several forms, depending on the severity of the disease within the intestine and the involvement of extra-intestinal sites (Satoskar *et al.*, 2009).

#### **2.1.1.1.6.1.1 Intestinal disease**

The greatest numbers of infected individuals have parasites restricted to the lumen of the intestine and are asymptomatic (Satoskar *et al.*, 2009). 90-96% of these would normally clear the parasite spontaneously, but the potential for disease development in the remaining 4-10% requires that even asymptomatic individuals be treated if *E. histolytica* is definitively identified (Satoskar *et al.*, 2009). Those persons presenting with colitis typically have a history of several weeks of gradually increasing abdominal cramping tenderness, weight loss and a range of bowel function alterations, ranging from frequent mucoid stools to watery and bloody diarrhea, often with periods of dysentery alternating with constipation (Satoskar *et al.*, 2009). As these symptoms are also typical of those elicited by a variety of bacterial pathogens, differential diagnosis should include other infectious as well as noninfectious causes of colitis (Satoskar *et al.*, 2009). Stools are nearly always heme-positive due to the invasive nature of the parasite, and rectal release of blood without diarrhea is not uncommon in children (Satoskar *et al.*, 2009). Fever is present in less than half of intestinal amebiasis patients (Satoskar *et al.*, 2009). However, fulminant necrotizing colitis developing in less than 1% of patients, has a high mortality rate (40%) and presents with fever, bloody mucoid diarrhea, leukocytosis and peritoneal tenderness (Satoskar *et al.*, 2009). Intestinal perforation occurs in the majority of patients with fulminant

colitis and both it and toxic mega-colon, associated with corticosteroid use, require surgical intervention (Satoskar *et al.*, 2009). Another infrequent intestinal manifestation, ameboma, mimics colonic carcinoma in its radiologic presentation as an annular deposition of granulomatous tissue that locally narrows the lumen of the colon (Satoskar *et al.*, 2009).

#### **2.1.1.1.6.1.2 Liver abscess**

The most common site of extra-intestinal infection (up to 9% of amebiasis cases) is the liver, resulting from hematogenous spread (via portal circulation primarily to the right lobe) of trophozoites that have eroded through the colonic mucosa (Satoskar *et al.*, 2009). Within the liver trophozoites multiply while degrading liver tissue in a spherically expanding abscess that becomes filled with necrotic liver cells (Satoskar *et al.*, 2009). Hepatic amebiasis can present months to years after an individual has traveled to or resided in an endemic area, during which time the patient may be completely asymptomatic and negative for stool parasites (Satoskar *et al.*, 2009). Only 20% of patients with liver abscess have a prior history of clinical dysentery (Satoskar *et al.*, 2009). Not all liver abscesses will progress to a symptomatic stage and some can self-resolve sub-clinically (Satoskar *et al.*, 2009). Once they do become apparent, however, liver abscess symptoms develop relatively rapidly, over a course of 10 days to several weeks and can include right upper quadrant pain, fever, point tenderness of the liver, anorexia and weight loss (Satoskar *et al.*, 2009). Abscesses located just below the diaphragm can lead to pleural pain or referred right shoulder pain (Satoskar *et al.*, 2009). Liver alkaline phosphatase levels are normal and alanine aminotransferase levels are elevated in acute liver abscess, which may, however, reverse over time (Satoskar *et al.*, 2009). Males are ten times more likely to present with liver abscess than females and middle-age and

young adults more than children (Satoskar *et al.*, 2009). Careful history elicitation is important because of the possible length of time ensuing between presentation with liver abscess and past residence or visitation in an endemic geographic region (Satoskar *et al.*, 2009). Serum antibodies to amoeba antigens are nearly always found in such patients, but if residence in an endemic area was prolonged, such antibodies may be the result of prior infection (Satoskar *et al.*, 2009).

#### **2.1.1.1.6.2 Pathogenesis**

The species name, *histolytica*, refers to the impressive ability of this organism to degrade a variety of host tissues (Satoskar *et al.*, 2009). The parasite expresses a large number of factors, including lytic peptides (ameba-pores), cysteine proteinases and phospholipases that are presumably designed to aid in the ingestion and digestion of bacteria and other food materials (Satoskar *et al.*, 2009). These products are considered virulence factors as they can also lyse colonic epithelial, liver and immune cells that come into contact with the trophozoite via its galNAc-specific lectin (Satoskar *et al.*, 2009). *Entamoeba* trophozoites are actively phagocytic and the presence of ingested red blood cells is diagnostic of *E. histolytica* organisms that are found in suitably stained biopsy specimens (Satoskar *et al.*, 2009). As a result of the variability of these activities, the range of pathological findings in the colitic colon includes increased height of the mucosa, isolated ulcerations of the mucosal layer, invasion and erosion of the sub-mucosa, areas of necrosis with loss of large patches of mucosa and completes perforation of the colon (Satoskar *et al.*, 2009). Invasion of the mucosal layer is often stopped by underlying muscularis layers, forcing the parasite to erode tissues laterally in a manner that generates ulcers with a flask-shaped cross sectional appearance (Satoskar *et al.*, 2009). Liver abscesses are well circumscribed with an outer wall of



connective tissue surrounded by normal liver cells, an underlying layer of trophozoites and dying hepatocytes and a central area filled with dead hepatocytes and immune cells (Satoskar *et al.*, 2009). A complication of liver abscess that results from sufficient expansion of the abscess to make contact the liver capsule is the rupture of the abscess into surrounding anatomic spaces, which occurs in up to 20% of abscess patients (Satoskar *et al.*, 2009). Rupture of liver abscess through the diaphragm can yield pleuro-pulmonary amebiasis that presents with cough, chest pain and respiratory distress. Significant leakage of liver abscess material into the lung can yield cough producing brown sputum (Satoskar *et al.*, 2009). Erosions of liver abscesses into the peritoneal and pericardial spaces are less frequent but can be of greater clinical significance even though the liver abscess contents are sterile (Satoskar *et al.*, 2009). Much less common but with highest mortality is the dissemination of trophozoites from live abscesses via general circulation to the brain (Satoskar *et al.*, 2009).

#### **2.1.1.1.7 Laboratory diagnosis**

Blood cell parameters of amebiasis patients are not grossly abnormal, but elevated total white cell counts are found in >75% (Satoskar *et al.*, 2009). Unlike infection with invasive helminth parasites, there is typically no eosinophilia with amebiasis (Satoskar *et al.*, 2009). Chemistry changes are usually limited to increased alkaline phosphatase levels in the majority of liver abscess patients (Satoskar *et al.*, 2009). Microscopic identification of trophozoites or cysts in stool samples or biopsy specimens is the most definitive method of diagnosis (Satoskar *et al.*, 2009). However, cyst passage is known to be inconsistent in asymptomatic carriers and to require the examination of multiple samples (Satoskar *et al.*, 2009). Visualization of the organism is therefore being supplanted by ELISA

assays that detect stool antigen rather than whole cells and importantly, are capable of distinguishing between pathogenic *E. histolytica* and nonpathogenic *E. dispar*. With high sensitivity (80%), specificity (99%) and commercial availability, these tests will make diagnosis of intestinal amebiasis more reliable (Satoskar *et al.*, 2009). Invasive disease presenting as colitis or liver abscess can additionally be diagnosed serologically, as antibodies are present in >90% of such patients and detectable by ELISA and various agglutination and electrophoresis methods (Satoskar *et al.*, 2009). Antibody titers increase with length of infection, so patients presenting with acute suspected disease may be negative initially but positive within 2 weeks (Satoskar *et al.*, 2009). Asymptomatic patients can also develop positive antibody titers, allowing for determination of the infecting organism when stool samples are positive for cysts and consideration of treatment (Satoskar *et al.*, 2009). Amebic liver abscesses are readily detected radio-graphically with ultrasound, CT scan or MRI methods, which, when combined with serology, can distinguish the amebic abscess from other space-occupying lesions such as hepatoma, pyogenic or hydatid abscesses (Satoskar *et al.*, 2009). Nearly all amebic liver abscesses completely resolve, but a small number will leave residual radiographic lesions that do not require further treatment (Satoskar *et al.*, 2009). Amebomas can be visualized by barium contrast radiography, taking into account the risk of perforation if colitis is also present (Satoskar *et al.*, 2009).

#### **2.1.1.1.8 Treatment**

Three classes of drug are used in the treatment of amoebiasis, luminal amoebicides; diloxanide furoate, iodoquinol, paromomycin, and tetracycline act in the intestinal lumen but not in tissues (Paniker, 2013). Tissue amoebicides; emetine, chloroquine, etc. are effective in systemic

infection, but less effective in the intestine. Dosage of chloroquine in amoebic liver abscess is 1 g for 2 days followed by 5 g daily for 3 weeks (Paniker, 2013). Both luminal and tissue amoebicides; Metronidazole and related compounds like tinidazole and ornidazole act on both sites and are the drug of choice for treating amoebic colitis and amoebic liver abscess (Paniker, 2013). Asymptomatic individuals with documented *E. histolytica* infection should also be treated because of the risks of developing amoebic colitis or amoebic liver abscess in the future and risk of transmitting the infection to others. Paromomycin or iodoquinol should be used in these cases (Paniker, 2013). Oral rehydration and electrolyte replacement should be done wherever necessary (Paniker, 2013).

#### **2.1.1.1.9 Prevention and control**

Several steps may be taken to prevent *E. histolytica* infections. Uncontaminated water is essential; this may be accomplished by boiling or treating with iodine crystals. It is interesting to note that the infective (quadri-nucleated) cyst is resistant to routine chlorination (Zeibig, 2013). A water treatment regimen that includes filtration and chemical treatment is necessary to ensure a safe water supply (Zeibig, 2013). Properly washing food products, avoiding the use of human feces as fertilizer, good personal hygiene and sanitation practices, protection of food from flies and cockroaches, and the avoidance of unprotected sexual practices serve as a means to break the transmission cycle (Zeibig, 2013).

#### **2.1.1.2 *Blastocystis hominis***

##### **2.1.1.2.1 Background**

*Blastocystis hominis*, an inhabitant of the human intestinal tract, was first described in 1912. Over the years this organism been classified as an organism related to *Blastomyces* spp., the cyst form of a flagellate, a yeast

of the genus *Schizosaccharomyces*, and a member of the stramenopiles (examples are brown algae such as kelp diatoms, slime nets, and water molds) (Garcia, 2007). However, currently this organism is classified as a protozoan (Garcia, 2007). It has been suggested that it be placed in a new class Blastocystea, and a new order, Blastocystida. Analysis of 10 stocks of *B. hominis* isolated from human stools revealed two distinct groups of organisms (Garcia, 2007). Proteins of the two groups were immunologically distinct, and hybridization studies showed that the DNA contents of the two groups were different (Garcia, 2007). Further studies are under way to determine whether these groups should be classified as separate species and whether there is any epidemiologic significance related to the two groups (Garcia, 2007). Based on PCR-based genotype classification data there may be as many as 12 or more different species within the genus (Garcia, 2007). Confirmation of the existence of these species and determination of their pathogenic status may also explain why some patients are asymptomatic and some have clinical symptoms (Garcia, 2007).

#### **2.1.1.2.2 Epidemiology**

From present information, it appears that *B. hominis* is transmitted via the fecal-oral route through contaminated food or water (Garcia, 2007). Although other possible modes of transmission are not defined, the incidence and apparent worldwide distribution indicate the traditional route of infection (Garcia, 2007). Recent studies suggest the existence of numerous zoonotic isolates, with frequent animal-to-human and human-to-animal transmissions, and of a large potential reservoir in animals for infections in humans (Garcia, 2007).

### **2.1.1.2.3 Mode of transmission**

From present information, it appears that *B. hominis* is transmitted via the fecal-oral route through contaminated food or water (Garcia, 2007). Although other possible modes of transmission are not defined, the incidence and apparent worldwide distribution indicate the traditional route of infection. Recent studies suggest the existence of numerous zoonotic isolates (Garcia, 2007).

### **2.1.1.2.4 Morphology**

#### **2.1.1.2.4.1 Trophozoite**

The classic form that is usually seen in the human stool specimen varies tremendously in size, from 6 to 40 $\mu$ m, and is characterized by a large central body, which may be involved with carbohydrate and lipid storage (visually like a large vacuole) (Garcia, 2007). The more amebic form is occasionally seen in diarrheal fluid but may be extremely difficult to recognize (Garcia, 2007). Generally, *B. hominis* is identified on the basis of the more typical round form with the central body (Garcia, 2007).

#### **2.1.1.2.4.2 Cyst**

Both thin- and thick-walled cysts have been confirmed (Garcia, 2007). It is suggested that the thin-walled cysts are auto-infectious, leading to multiplication of the organism in the intestinal tract (Garcia, 2007). The thick-walled cysts are probably responsible for external transmission via the fecal-oral route (Garcia, 2007).

### **2.1.1.2.5 Life cycle**

*B. hominis* is capable of pseudopod extension and retraction reproduces by binary fission or sporulation, and has a membrane-bound central body

(previously called a vacuole) that takes up 90% of the cell and functions in sexual and asexual reproduction (Garcia, 2007). Other structures with unknown function are not yet defined (Garcia, 2007). The organism is strictly anaerobic normally requires bacteria for growth, and is capable of ingesting bacteria and other debris (Garcia, 2007). The classic form that is usually seen in the human stool specimen varies tremendously in size, from 6 to 40  $\mu\text{m}$ , and is characterized by a large central body, which may be involved with carbohydrate and lipid storage (visually like a large vacuole) (Garcia, 2007). The more amebic form is occasionally seen in diarrheal fluid but may be extremely difficult to recognize. Generally, *B. hominis* is identified on the basis of the more typical round form with the central body (Garcia, 2007). Both thin- and thick-walled cysts have been confirmed. It is suggested that the thin-walled cysts are auto-infectious leading to multiplication of the organism in the intestinal tract (Garcia, 2007). The thick-walled cysts are probably responsible for external transmission via the fecal-oral route (Garcia, 2007). This type of life cycle might explain the high percentage of positive carriers in many studies, showing that the percentage of patients infected with *B. hominis* is often much higher than the percentage of those infected with other intestinal protozoa (Garcia, 2007).

#### **2.1.1.2.6 Clinical presentation and pathogenicity**

When *B. hominis* is present in the absence of other pathogenic parasites, bacteria, or viruses, it may be the cause of diarrhea, cramps, nausea, fever, vomiting, and abdominal pain and may require therapy (Garcia, 2007). In one recent study of patients with irritable bowel syndrome, there was a set of patients in whom the presence of *B. hominis* did not appear to be incidental (Garcia, 2007). Possible relationships between *B. hominis* and intestinal obstruction and perhaps even infective arthritis have been

suggested (Garcia, 2007). In patients with other underlying conditions, the symptoms may be more pronounced (Garcia, 2007). The incidence of this organism appears to be higher than suspected in stools submitted for parasite examination (Garcia, 2007). For symptomatic patients in whom no other etiologic agent has been identified, *B. hominis* should certainly be considered a possible candidate (Garcia, 2007). Other recent studies suggest that when a symptomatic *B. hominis* infection responds to therapy, the improvement probably represents elimination of some other undetected pathogenic organism (*E.histolytica*, *G. lamblia*, or *D. fragilis*) (Garcia, 2007). Data from other geographic areas indicate that although it is commonly seen in stool samples, *B. hominis* is thought to be nonpathogenic (Garcia, 2007). Although for a number of years the true role of this organism in terms of colonization or disease was still somewhat controversial, it is now generally considered a causative agent of intestinal disease (Garcia, 2007). It has also been suggested that ribodemes I, III, and VI may be responsible for gastrointestinal symptoms (Garcia, 2007). In a study of 1,216 adults, including immunocompromised patients, institutionalized psychiatric or elderly subjects, immigrants from developing countries, travelers to developing tropical countries, and controls, the results showed a high prevalence of parasites in all the risk groups studied, and *B. hominis* was the parasite most frequently detected in each studied group (Garcia, 2007). *B. hominis* showed a significant correlation with gastrointestinal symptoms only when detected in the group including subjects with a severe immuno-depression (Garcia, 2007).

#### **2.1.1.2.7 Laboratory diagnosis**

Routine stool examinations are very effective in recovering and identifying *B. hominis*, although the permanent stained smear is the

procedure of choice since the examination of wet preparations may not easily reveal the organism (Garcia, 2007). If the fresh stool is rinsed in water before fixation (for the concentration method), *B. hominis* organisms other than the cysts are destroyed, thus possibly yielding a false-negative report (Garcia, 2007). The organisms should be quantitated on the report form i.e., as rare, few, moderate, or many. It is also important to remember that other possible pathogens should be adequately ruled out before a patient is treated for *B. hominis* (Garcia, 2007). Both ELISA and fluorescent-antibody tests have been developed for detection of serum antibody to *B. hominis* infections (Garcia, 2007). Also, demonstration of serum antibody production both during and after *B. hominis* symptomatic disease provides immunological evidence for the pathogenic role for this protozoan, although it may take years or more with chronic infections before a serologic response is detected (Garcia, 2007).

#### **2.1.1.2.8 Treatment**

Although there is not a great deal of clinical evidence, there have been studies on the in vitro susceptibility of *B. hominis* to numerous drugs (Garcia, 2007). At present metronidazole (Flagyl) appears to be the most appropriate drug diiodohydroxyquin (Yodoxin) has also been effective and dosage schedules for these two drugs are as recommended for other intestinal protozoa (Garcia, 2007). The development of a new drug sensitivity assay may improve our ability to scientifically evaluate the activities of various drugs against this organism (Garcia, 2007).

#### **2.1.1.2.9 Prevention and control**

Prevention would probably involve improved personal hygiene and sanitary conditions. Very specific prevention measures for all of the intestinal protozoa can be done (Garcia, 2007). These recommendations



are relevant for all organisms that can be acquired through the ingestion of food or water contaminated with fecal material (Garcia, 2007).

## **2.1.2 The intestinal flagellates**

Parasitic protozoa, which possess whip-like flagella as their organs of locomotion are called as flagellates and classified as: Phylum: Sarcomastigophora\_ Subphylum: Mastigophora\_ Class: Zoomastigophora (matrix whip) (Paniker, 2013). Depending on the habitat, the intestinal flagellates are belonging to 'Lumen dwelling flagellates' (Paniker, 2013).

### **2.1.2.1 *Giardia lamblia***

#### **2.1.2.1.1 Background**

It is one of the earliest protozoan parasites to have been recorded (Paniker, 2013). The flagellate was first observed by Dutch scientist Antonie von Leeuwenhoek (1681) in his own stools (Paniker, 2013). It is named 'Giardia' after Professor Giard of Paris and 'Lambliia' after Professor Lambie of Prague, who gave a detailed description of the parasite (Paniker, 2013).

#### **2.1.2.1.2 Epidemiology**

Although contaminated food or drink may be the source, intimate contact with an infected individual may also provide the infection mechanism (Garcia, 2007). This organism tends to be found more frequently in children or in groups that live in close quarters (Garcia, 2007). Often, there are outbreaks due to poor sanitation facilities or breakdowns as evidenced by infections of travelers and campers (Garcia, 2007). There is also an increase in the prevalence of giardiasis in the male homosexual population, probably because of anal and/or oral sexual practices (Garcia, 2007). Although seasonal patterns have been identified for some infectious

diseases, limited information is available for giardiasis (Garcia, 2007). Some data suggest an association with the cooler, wetter months of the year; this is not surprising if one considers the issue of environmental conditions advantageous to cyst survival (Garcia, 2007). It has been documented that certain occupations may place an individual at risk for infection; such at-risk individuals include sewage and irrigation workers, who may become exposed to infective cysts (Garcia, 2007). In situations where young children are grouped together, such as nursery schools, there may be an increased incidence of exposure and subsequent infection of both children and staff (Garcia, 2007). Although achlorhydria is associated with blood group A and some evidence suggests that members of this group are more susceptible to giardiasis, subsequent evidence has not confirmed this information (Garcia, 2007). Since reduction in gastric acid also occurs as a result of malnutrition, these factors may be linked and, as a group increase the susceptibility to infection with this organism. This link between malnutrition and giardiasis may also be explained by the impairment of the host immune system (Garcia, 2007). The issue of whether breast milk modifies *Giardia* infection has also been discussed in terms of different interpretations of the results (Garcia, 2007). A lower incidence of giardiasis in children younger than 6 months may be related to an association with breast-feeding and some protection against infection via secretory IgA; however, the lower incidence may also be related to decreased exposure to *Giardia* organisms in breast-fed infants giardiasis is one of the more common causes of traveler's diarrhea and has been recorded in all parts of the world (Garcia, 2007). It has also been speculated that visitors in areas where *Giardia* infections are endemic are more likely to present with symptoms than are individuals who live in the area; this difference is most probably due to the development of immunity of residents from prior and possibly continued exposure to the organism

(Garcia, 2007). There have been a number of outbreaks attributed to either resort or municipal water supplies in Oregon, Colorado Utah, Washington, New Hampshire, and New York, high rates of infection were also reported for hikers and campers who drank stream water (Garcia, 2007). Because some of these areas were remote from human habitation, infected wild animals, especially beaver, are suspected (Garcia, 2007). During the past few years, this infection has received much publicity. With increased travel, there has been a definite increase in symptomatic giardiasis within the United States (Garcia, 2007). Various surveys show infection rates of 2 to 15% in various parts of the world (Garcia, 2007).

#### **2.1.2.1.3 Mode of transmission**

Man acquires infection mainly by ingestion of cysts in contaminated water and food (Paniker, 2013). Direct person to person transmission may also occur in children, male homosexuals, and mentally ill persons (Paniker, 2013). Enhanced susceptibility to giardiasis is associated with blood group A, achlorhydria, use of cannabis chronic pancreatitis, malnutrition, and immune defects such as 19A deficiency and hypo-gammaglobulinemia. Infective dose is 10–100 cysts (Paniker, 2013).

#### **2.1.2.1.4 Morphology**

##### **2.1.2.1.4.1 Trophozoite**

The trophozoite is in the shape of a tennis racket (heart-shaped or pyriform shaped) and is rounded anteriorly and pointed posteriorly (Paniker, 2013). It measures 15  $\mu\text{m}$  x 9  $\mu\text{m}$  wide and 4  $\mu\text{m}$  thick. Dorsally, it is convex and ventrally, it has a concave sucking disc, which helps in its attachment to the intestinal mucosa. It is bilaterally symmetrical and possesses: 1 pair of nuclei, 4 pairs of flagella, blepharoplast; from which the flagella arise (4 pairs), and 1 pair of axostyles running along the midline, two sausage-

shaped parabasal or median bodies lying transversely posterior to the sucking disc (Paniker, 2013). The trophozoite is motile, with a slow oscillation about its long axis, often resembling 'falling leaf'(Paniker, 2013).

#### **2.1.2.1.4.2 Cyst**

It is the infective form of the parasite. The cyst is small and oval, measuring 12  $\mu\text{m}$  x 8  $\mu\text{m}$  and is surrounded by a hyaline cyst wall. Its internal structure includes 2 pairs of nuclei grouped at one end (Paniker, 2013). A young cyst contains 1 pair of nuclei. The axostyle lies diagonally, forming a dividing line within cyst wall. Remnants of the flagella and the sucking disc may be seen in the young cyst (Paniker, 2013).

#### **2.1.2.1.5 Life cycle**

Man acquires infection by ingestion of cysts by any one of the transmission routes (Paniker, 2013). Within half an hour of ingestion, the cyst hatches out into two trophozoites, which multiply successively by binary fission and colonize in the duodenum (Paniker, 2013). The trophozoites live in the duodenum and upper part of jejunum, feeding by pinocytosis (Paniker, 2013). During unfavorable conditions, encystment occurs usually in colon (Paniker, 2013). Cysts are passed in stool and remain viable in soil and water for several weeks. There may be 200,000 cysts passed per gram of feces (Paniker, 2013).

#### **2.1.2.1.6 Clinical presentation and pathogenicity**

*G. lamblia* is typically seen within the crypts of duodenal and jejunal mucosa. It does not invade the tissue, but remains tightly adhered to intestinal epithelium by mean of the sucking disc (Paniker, 2013). They

may cause abnormalities of villous architecture by cell apoptosis and increased lymphatic infiltration of lamina propria. Variant specific surface proteins (VSSP) of *Giardia* play an important role in virulence and infectivity of the parasite (Paniker, 2013). Often they are asymptomatic, but in some cases *Giardia* may lead to mucus diarrhea, fat malabsorption (steatorrhea), dull epigastric pain, and flatulence. The stool contains excess mucus and fat but no blood (Paniker, 2013). Children may develop chronic diarrhea, malabsorption of fat, vitamin A, protein, sugars like xylose disaccharides, weight loss, and sprue-like syndrome (Paniker, 2013). Occasionally, *Giardia* may colonize the gall bladder causing biliary colic and jaundice. Incubation period is variable, but is usually about 2 weeks (Paniker, 2013).

#### **2.1.2.1.7 Laboratory diagnosis**

##### **2.1.2.1.7.1 Stool examination**

Giardiasis can be diagnosed by identification of cysts of *G.lamblia* in the formed stools and the trophozoites and cysts of the parasite in diarrheal stools (Paniker, 2013). On macroscopic examination fecal specimens containing *G. lamblia* may have an offensive odor, are pale colored and fatty, and float in water (Paniker, 2013). On microscopic examination, cysts and trophozoites can be found in diarrheal stools by saline and iodine wet preparations (Paniker, 2013). Often multiple specimens need to be examined and concentration techniques like formal ether or zinc acetate are used. In asymptomatic carriers, only the cysts are seen (Paniker, 2013).

##### **2.1.2.1.7.2 Entero-test (String test)**

A useful method for obtaining duodenal specimen is entero-test (Paniker, 2013). A coiled thread inside a small weighted gelatin capsule is swallowed by the patient, after attaching the free end of the thread in the

check (Paniker, 2013). The capsule passes through the stomach to the duodenum (Paniker, 2013). After 2 hours, the thread is withdrawn, placed in saline, and is mechanically shaken. The centrifuged deposit of the saline is examined for *Giardia* (Paniker, 2013). The use of entero-test is not recommended because of the very high cost of the test (Paniker, 2013).

### **2.1.2.1.7.3 Serodiagnosis**

#### **2.1.2.1.7.3.1 Antigen detection**

Enzyme-linked immuno sorbent assay (ELISA), immuno-chromatographic strip tests and indirect immuno-fluorescent tests (IIF) using monoclonal antibodies have been developed for detection of *Giardia* antigens in feces (Paniker, 2013). The sensitivity of the test is 95% and specificity is 100% when compared to conventional microscopy (Paniker, 2013). The test may be used for quantification of cysts and in epidemiological and control studies, but not for routine use (Paniker, 2013).

#### **2.1.2.1.7.3.2 Antibody detection**

IIF test and ELISA are used. Demonstration of antibodies is useful in the epidemiological and pathophysiological studies; these tests cannot differentiate between recent and past infection and lack sensitivity and specificity (Paniker, 2013).

#### **2.1.2.1.7.4 Molecular method**

DNA probes and polymerase chain reaction (PCR) have been used to demonstrate parasitic genome in the stool specimen (Paniker, 2013).

### **2.1.2.1.8 Treatment**

Metronidazole (250 mg, thrice daily for 5–7 days) and tinidazole (2 g single dose) are the drugs of choice (Paniker, 2013). Cure rates with

metronidazole are more than 90%. Tinidazole is more effective than metronidazole. Furuzolidone and nitazoxamide are preferred in children, as they have fewer adverse effects. Parmomycin, an oral aminoglycoside can be given to symptomatic pregnant females (Paniker, 2013).

#### **2.1.2.1.9 Prevention and control**

Giardiasis can be prevented by following measures: Proper disposal of waste water and feces (Paniker, 2013). Practice of personal hygiene like hand-washing before eating and proper disposal of diapers (Paniker, 2013). Providing safe drinking water is critical if *Giardia* transmission is to be controlled (Satoskar *et al.*, 2009). The traditional methods employed to insure water safety are protection of the watershed, flocculation and sedimentation (using compounds such as alum to bridge contaminating organisms into clumps that can then be removed by sedimentation), chemical disinfection usually with chlorine, and filtration (Satoskar *et al.*, 2009).

### **2.1.3 The intestinal ciliates**

#### **2.1.3.1 *Balantidium coli***

##### **2.1.3.1.1 Background**

It was first described by Malmsten in 1857, in the feces of dysenteric patients (Paniker, 2013). It is present worldwide, but the prevalence of the infection is very low (Paniker, 2013). The most endemic area is New Guinea, where there is a close association between man and pigs (Paniker, 2013). Although *B. coli* is distributed worldwide and outbreaks have been known to occur, the typical incidence of human infection is very low (Zeibig, 2013). The documented frequency of infections in the general population is considered rare (Zeibig, 2013). However, epidemics caused

by infections with *B. coli* have been noted in psychiatric facilities in the United States (Zeibig, 2013). *B. coli* infections are transmitted by ingesting contaminated food and water by the oral-fecal as well as person-to-person routes (Zeibig, 2013). Recently, it has been presumed that water contaminated with feces (the oral-fecal route) from a pig, which is a known reservoir host, may be a significant source of infection (Zeibig, 2013). There is now considerable evidence to support the theory that the pig may not be the primary infection source, because the documented incidence of infection among humans with high pig contact is relatively low (Zeibig, 2013). Infected food handlers appear to be the culprit in person-to-person spread of the disease (Zeibig, 2013).

#### **2.1.3.1.3 Mode of transmission**

The infection is acquired through the ingestion of the infective cysts in contaminated food or water (Zeibig, 2013).

#### **2.1.3.1.4 Morphology**

##### **2.1.3.1.4.1 Trophozoite**

Considered as the largest protozoan known to humans, the typical *Balantidium coli* trophozoite may measure from 28 to 152  $\mu\text{m}$  in length, with an average length of 35 to 50  $\mu\text{m}$  (Zeibig, 2013). The average trophozoite width is approximately 40  $\mu\text{m}$  but may range from 22 to 123  $\mu\text{m}$  (Zeibig, 2013). The ovoid to sac-shaped *B. coli* trophozoite tapers at the anterior end. The organism typically exhibits rotary, boring motility (Zeibig, 2013). The trophozoite contains two nuclei, a small dot-like nucleus (micronucleus) is located adjacent to a large, often kidney bean-shaped nucleus known as a macronucleus. The micronucleus is often not readily visible, even in stained preparations, whereas the macronucleus may often appear as a hyaline mass, especially in unstained preparations



(Zeibig, 2013). Two contractile vacuoles are located in the granular cytoplasm, although sometimes only one is readily visible (Zeibig, 2013). In addition, the cytoplasm may also contain food vacuoles, as well as ingested microbes, bacteria) (Zeibig, 2013). The trophozoite is equipped with a small cytostome (Zeibig, 2013). A layer of cilia surrounds the organism, which serves as its means of locomotion (Zeibig, 2013).

#### **2.1.3.1.4.2 Cyst**

Averaging in size from 52 to 55  $\mu\text{m}$ , the sub-spherical to oval *B. coli* cyst may measure from 43 to 66  $\mu\text{m}$  (Zeibig, 2013). Although the cyst technically contains the macronucleus and micronucleus, the micronucleus may not be observed in wet or permanent preparations. One or two contractile vacuoles may be visible, particularly in young unstained cysts. A double-protective cyst wall surrounds the organism (Zeibig, 2013). A row of cilia may be visible between the two cyst wall layers in unstained young cysts. Mature cysts tend to lose their cilia (Zeibig, 2013). Stained cysts typically reveal only the macronucleus; the other structures are not usually apparent (Zeibig, 2013).

#### **2.1.3.1.5 Life cycle**

The *B. coli* life cycle is similar to that of *E. histolytica*. Human infection with *B. coli* is initiated on ingestion of infective cysts in contaminated food or water (Zeibig, 2013). Unlike that of *E. histolytica*, multiplication of the *B. coli* nuclei does not occur in the cyst phase (Zeibig, 2013). Following excystation in the small intestine, the resulting trophozoites take up residence and feed primarily in the cecal region and terminal portion of the ileum, as well as in the lumen, mucosa, and sub-mucosa of the large intestine (Zeibig, 2013). The multiplication of each trophozoite occurs by transverse binary fission, from which two young trophozoites

emerge. The *B. coli* trophozoites are delicate and do not survive in the outside environment (Zeibig, 2013). Encystation occurs in the lumen (Zeibig, 2013). The resulting cysts mature and ultimately become the infective form for transmission into a new host (Zeibig, 2013). These cysts may survive for weeks in the outside environment (Zeibig, 2013).

#### **2.1.3.1.6 Clinical presentation and pathogenicity**

Similar to that seen in certain patients infected with *E. histolytica* some patients are just carriers of *B. coli* and remain asymptomatic (Zeibig, 2013). Symptomatic balantidiasis patients may experience a variety of discomforts, ranging from mild colitis and diarrhea to full-blown clinical balantidiasis, which may often resemble amebic dysentery (Zeibig, 2013). In this case, abscesses and ulcers may form in the mucosa and sub-mucosa of the large intestine, followed by secondary bacterial infection. Acute infections: are characterized by up to 15 liquid stools daily containing pus, mucus, and blood (Zeibig, 2013). Patients who suffer from chronic infections may develop a tender colon, anemia, cachexia, and occasional diarrhea, alternating with constipation (Zeibig, 2013). *B. coli* have been known to invade areas other than the intestine, such as the liver, lungs, pleura, mesenteric nodes, and urogenital tract (Zeibig, 2013). However, the incidence of such extra-intestinal infections is rare (Zeibig, 2013).

#### **2.1.3.1.7 Laboratory diagnosis**

Laboratory diagnosis of *B. coli* is accomplished by examining stool specimens for the presence of trophozoites and cysts (Zeibig, 2013). Stools from infected patients experiencing diarrhea are more likely to contain *B. coli* trophozoites. Although it does not occur frequently, suspicious formed stools may contain cysts. Sigmoidoscopy material may also reveal *B. coli* organisms when collected from patients suffering from

sigmoidorectal infection (Zeibig, 2013). As with any sample submitted for parasitic study, thorough screening of the wet preparations and the permanent stain is crucial to ensure an accurate laboratory test report (Zeibig, 2013). In addition, the study of multiple samples may be required to determine the presence or absence of the parasite correctly (Zeibig, 2013).

#### **2.1.3.1.8 Treatment**

Two factors play an important role in determining the prognosis of patients infected with *B. coli*, the severity of the infection and the patient's response to treatment (Zeibig, 2013). Asymptomatic patients and those suffering from chronic disease typically have a good chance of recovery (Zeibig, 2013). There are two medication choices for the effective treatment of *B. coli* infections, oxytetracycline (terramycin) and iodoquinol (Zeibig, 2013). Metronidazole (Flagyl) may also be used to treat infected patients (Zeibig, 2013).

#### **2.1.3.1.9 Prevention and control**

Personal hygiene and proper sanitary conditions are effective measures for *B. coli* prevention and control (Zeibig, 2013). Until the questions surrounding the pig's role in transmitting *B. coli* are completely understood, the pig should be considered as a possible source of infection and proper precautions should be exercised when handling and dealing with pigs and their feces (Zeibig, 2013).

### **2.1.4 The intestinal coccidian**

#### **2.1.4.1 *Cryptosporidium parvum***

##### **2.1.4.1.1 Background**

Although the first human cases of *Cryptosporidium* were described in 1976, the contribution of this protozoan parasite to gastrointestinal disease was not fully appreciated until the 1980s when scores of cases were described among patients with acquired immuno-deficiency syndrome (AIDS) (Satoskar *et al.*, 2009). The disease gained greater notoriety after a massive outbreak of waterborne cryptosporidial infection in Milwaukee, Wisconsin in 1993 (Satoskar *et al.*, 2009). The genus *Cryptosporidium* consists of at least 10 species. This group of organisms resides within the subphylum Apicomplexa (Satoskar *et al.*, 2009). It is most closely related to coccidian parasites including other intestinal pathogens such as *Cyclospora* and *Isospora* species (Satoskar *et al.*, 2009).

#### **2.1.4.1.2 Epidemiology**

*Cryptosporidium* has a wide geographic distribution, though infection is more prevalent in regions of the world with poor sanitary conditions. Infection is more common during warm rainy months. The reported prevalence of infection varies widely and is influenced by geographic region, age, immune status, local outbreaks and the range of sensitivities and specificities offered by different diagnostic modalities. In general, exposure rates based on sero-prevalence studies suggest that in North America at least 30% of adults have been previously exposed to *Cryptosporidium* species. Oocysts have been detected in apparently pure surface water sources, though protected spring water sources are less likely to be contaminated. Untreated or raw waste water is substantially contaminated with oocysts. Moreover, municipal wastewater treatment centers, runoff from animal agriculture and various wildlife populations all contribute to a remarkable release of oocysts into the aquatic environment. Oocysts are highly resistant to chlorination and can bypass certain filtration methods. Accordingly, sources of treated potable water can

contain significant numbers of oocysts. Oocysts can survive for a period of time in seawater, and indeed shellfish in coastal areas have been found to be contaminated with infectious oocysts. Most cases among immunocompetent hosts have been associated with waterborne outbreaks and have involved either contaminated drinking water or recreational water sources such as swimming pools and lakes. Disease is also well-described in returning travelers, persons with animal contact (e.g., farmers) and amongst daycare personnel working with young children. Direct person-to-person transmission via the fecal-oral route is also common in a number of settings including during sexual activity. Health care workers should be cognizant of the potential for nosocomial transmission. Foodborne transmission, though relatively infrequent, has been reported from a number of sources including inadequately pasteurized beverages and raw fruits and vegetables (Satoskar *et al.*, 2009).

#### **2.1.4.1.3 Mode of transmission**

Cryptosporidiosis is acquired through the ingestion of the mature oocyst in contaminated water or food. In addition to fecal-oral route. The infectious dose can be as low as 10 oocysts, though considerable variability exists among isolates and a much higher infectious dose is often required in previously exposed seropositive individuals (Satoskar *et al.*, 2009).

#### **2.1.4.1.4 Morphology**

##### **2.1.4.1.4.1 Oocysts**

Measuring only 4 to 6  $\mu\text{m}$ , the roundish *Cryptosporidium* oocysts are often confused with yeast (Zeibig, 2013). Although not always visible, the mature oocyst consists of four small sporozoites surrounded by a thick cell wall (Zeibig, 2013). Contrary to other members of the sporozoa, such as

*Isospora*, *Cryptosporidium* oocysts do not contain sporocysts. One to six dark granules may also be seen (Zeibig, 2013).

#### **2.1.4.1.4.1 Schizonts and gametocytes**

The other morphologic forms required to complete the life cycle of *Cryptosporidium* include schizonts containing four to eight merozoites, microgametocytes, and macro gametocytes (Zeibig, 2013). The average size of these forms is a mere 2 to 4  $\mu\text{m}$ . It is important to note that these morphologic forms are not routinely seen in patient samples (Zeibig, 2013).

#### **2.1.4.1.5 Life cycle**

The lifecycle of *Cryptosporidium* can be completed entirely within a single host. Upon the ingestion and activation of the oocyst in the upper GI tract, it is excyst to release sporozoites (Satoskar *et al.*, 2009). These sporozoites bind intestinal epithelial cells and via induction of actin polymerization, provoke their own engulfment to eventually reside in a parasitophorous vacuole within the microvillus layer. In this sequestered environment, the parasites undergo asexual reproduction termed (merogony) and ultimately produce merozoites that are released intraluminally (Satoskar *et al.*, 2009). These forms in turn bind and are again engulfed by epithelial cells and thus perpetuate the cycle. Alternatively the engulfed merozoites may undergo sexual differentiation and ultimately the fertilization of macro gamonts by microgametes will yield new oocysts (Satoskar *et al.*, 2009). These new oocysts may either be shed into the environment or excyst within the same host. The organism can be found throughout the gastrointestinal tract; however it appears to have an affinity for epithelial cells in the jejunum, ileum and proximal colon-cholangiocytes are also susceptible to infection, and apoptosis of these

epithelial cells likely contributes to biliary tract disease (Satoskar *et al.*, 2009). The respiratory tract also appears to be a site of infection in immuno-compromised individuals. Epithelial cell death, by both apoptotic and necrotic mechanisms, has been noted in involved regions (Satoskar *et al.*, 2009). There is evidence that infected epithelial cells can induce apoptosis in neighboring uninfected cells. Epithelial cell infection usually culminates in dys-regulation of cell signaling pathways including up-regulation of pro-inflammatory cascades as well as cyclooxygenase-2, prostaglandins and neuropeptide production (Satoskar *et al.*, 2009). These perturbations result in epithelial barrier dysfunction, augmented intestinal permeability, dys-regulation of electrolyte absorption and secretion and fluid malabsorption. Accordingly, symptomatic infection usually manifests as watery diarrhea (Satoskar *et al.*, 2009).

#### **2.1.4.1.6 Clinical presentation, pathogenicity**

Non-bloody diarrhea is the most common clinical presentation of cryptosporidiosis; however, clinical findings may vary widely and are dependent on the affected host population being considered. The incubation period is usually 7 to 10 days, though it can range from several days to weeks (Satoskar, 2009).

##### **2.1.4.1.6.1 Immuno competent hosts**

Among immuno-competent adults in developed world, the most common presentation is watery, occasionally mucoid diarrhea. The severity and frequency of diarrhea can be variable ranging from small volume intermittent stools to continuous and voluminous unformed or watery stools (Satoskar *et al.*, 2009). Diarrhea is usually self-limited and persists for up to 14 days, though it can persist in normal hosts for a more prolonged period. Diarrhea may be accompanied by abdominal cramping,

fever, malaise, nausea and occasionally vomiting (Satoskar *et al.*, 2009). Concurrent respiratory symptoms have also been reported. Despite an initial resolution of symptoms, a considerable proportion of infected individuals eventually have recurrent disease within days to weeks. Some individuals with *C. hominis* infection report development of extra-intestinal symptoms late in their course including recurrent headaches, fatigue, dizziness, ocular pain and arthralgias (Satoskar *et al.*, 2009). Accumulating evidence suggests that mild or asymptomatic infection may also be common. Previously exposed seropositive individuals appear to be more resistant to reinfection and when re-infected have milder forms of disease (Satoskar *et al.*, 2009).

#### **2.1.4.1.6.2 Childhood diarrhea and malnutrition**

In the developing world, diarrhea amongst children is the most common clinical presentation of cryptosporidiosis. Little distinguishes *Cryptosporidium*-associated diarrhea from other infectious causes of childhood diarrhea except for its propensity to cause persistent diarrhea beyond 2 weeks duration. Persistent diarrhea is associated with greater morbidity and mortality (Satoskar *et al.*, 2009). Relapsing diarrhea, significant weight loss and growth rate reduction are common sequel of infection in this population. The relationship between cryptosporidiosis and malnutrition is complex (Satoskar *et al.*, 2009). It is unclear whether malnourished children have an increased susceptibility to infection and predilection for more severe and persistent disease (Satoskar *et al.*, 2009).

#### **2.1.4.1.6.3 The Immuno-compromised host**

In the patient with HIV, the course of cryptosporidiosis often correlates with the immune status of the individual. Patients with CD4 counts above 200 cells/ $\mu$ L are likely to have a clinical course similar to immuno-



competent hosts (Satoskar *et al.*, 2009). Patients with AIDS and progressively declining CD4 counts are more likely to present with foul smelling bulky stools in the context of chronic diarrhea and weight loss. Severely immuno-compromised individuals with CD4 counts less than 50 cells/microL develop a more fulminant cholera-like disease with watery and voluminous diarrhea (Satoskar *et al.*, 2009). Biliary and respiratory tract disease is more likely to manifest in severely immuno-compromised persons with CD4 counts less than 50 cells/ $\mu$ L. Biliary tract involvement may result in biliary strictures, papillary stenosis, pancreatitis, acalculous cholecystitis, or sclerosing cholangitis. These may manifest with right upper quadrant pain, nausea, vomiting and low grade fever (Satoskar *et al.*, 2009). Although oocysts have been detected in respiratory secretions of immuno-compromised patients, a causal link between *Cryptosporidium* and pulmonary disease is usually difficult to establish given the occurrence of coexistent opportunistic pathogens in this population (Satoskar *et al.*, 2009). More severe or persistent cryptosporidiosis has also been described in other immuno-compromised settings, including organ transplantation, immunosuppressive therapy, chemotherapy, primary immuno-deficiencies, hematologic malignancies, cytokine deficiencies and a variety of other conditions associated with cell mediated immune dysfunction (Satoskar *et al.*, 2009).

#### **2.1.4.1.7 Laboratory diagnosis**

Traditionally, the diagnosis of cryptosporidiosis has been made on the basis of microscopic identification of round oocysts of 4-6  $\mu$ m in diameter. Standard staining techniques include modified acid fast staining in which oocysts appear pink or red on a blue or blue-green background, allowing clear differentiation from morphologically similar yeasts (Satoskar *et al.*, 2009). Sporozoites may be seen in individual oocysts and their

visualization may assist in the diagnosis. White blood cells are usually not seen. At least three separate specimens should be examined to improve the diagnostic yield. The yield may be enhanced if the stool specimen is unformed and if the laboratory uses a concentration technique prior to staining (Satoskar *et al.*, 2009). Immunofluorescence assays are now commonly used and may be a log more sensitive than acid-fast stains. Antigen-detection assays in the form of ELISA or immunochromatographic kits are now more widely used (Satoskar *et al.*, 2009). A number of commercially available kits now have excellent sensitivity and specificity relative to the modified acid fast technique. The clinician should nevertheless review the diagnostic reliability of such kits before excluding the diagnosis (Satoskar *et al.*, 2009). PCR remains investigational, is more labor intensive and is not widely used though significantly more sensitive than any microscopic technique (Satoskar *et al.*, 2009). Validated in-house assays can be more sensitive than antigen-detection assays and may have the capability to distinguish between different species (Satoskar *et al.*, 2009). In the immuno-compromised patient with biliary disease or pancreatitis, the clinician should maintain a high index of suspicion for a cryptosporidiosis. One should not exclude the diagnosis based on negative stool specimen testing; as such investigations may be negative in this setting (Satoskar *et al.*, 2009). Ultrasonographic abnormalities may include a thickened gallbladder wall as well as dilated and irregular intrahepatic and extra-hepatic bile ducts (Satoskar *et al.*, 2009). A suspicion of cryptosporidium-related cholangiopathy should prompt an endoscopic assessment of biliary involvement with tissue biopsy for histology as well as examination of bile for oocysts (Satoskar *et al.*, 2009).

#### **2.1.4.1.8 Treatment**

Numerous experiments to treat *Cryptosporidium* using a wide variety of medications have been conducted (Zeibig, 2013). Unfortunately, most of these potential treatments have proven ineffective. However, the use of spiramycin, even though still in the experimental stage, has preliminarily proven helpful in ridding the host of *Cryptosporidium* (Zeibig, 2013). More research on this treatment and on the newer anti-parasitic medications is necessary to develop effective medications (Zeibig, 2013).

#### **2.1.4.1.9 Prevention and control**

Proper treatment of water supplies, handling known infected material by using gloves and wearing a gown (when appropriate), proper hand washing, and properly disinfecting potentially infected equipment with full-strength commercial bleach or 5% to 10% household ammonia are crucial to the prevention and control of *Cryptosporidium* (Zeibig, 2013). In addition, enteric precautions should be observed when working with known infected persons (Zeibig, 2013).

#### **2.1.4.2 *Isospora belli***

##### **2.1.4.2.1 Background**

*Isospora belli* is a coccidian parasite which can cause diarrhea in humans. It was originally described by Virchow in 1860 but it was named in 1923. The name belli (from bellium meaning war) was given for its association with war, because several cases of infection with this parasite were seen among troops stationed in Middle East during First World War (Paniker, 2013). Molecular biology studies have demonstrated that *Isospora* spp., particularly those from primates and carnivores, are more closely related to the *Sarcocystiidae* than to the *Eimeriidae*. This has required the transfer

of the species into the family Sarcocystiidae and the genus *Cystoisospora* (Garcia, 2007).

#### **2.1.4.2.2 Epidemiology**

*I. belli* is thought to be the only species of *Isospora* that infects humans, and no other reservoir hosts are recognized for this infection. Transmission is through ingestion of water or food contaminated with mature, sporulated oocysts (Garcia, 2007). Sexual transmission by direct oral contact with the anus or perineum has also been postulated, although this mode of transmission is probably much less common. The oocysts are very resistant to environmental conditions and may remain viable for months if kept cool and moist; oocysts usually mature within 48 h following stool evacuation and are then infectious (Garcia, 2007). It has been speculated that diagnostic methods for laboratory examinations may tend to miss the organisms when they are present. Although isosporiasis has been found in various parts of the world, certain tropical areas in the Western hemisphere appear to contain some well-defined locations of endemic infections (Garcia, 2007). These organisms can infect both adults and children, and intestinal involvement and symptoms are generally transient unless the patient is immuno-compromised. *I. belli* has also been implicated in traveler's diarrhea. However, unlike *C. cayetanensis* large outbreaks of isosporiasis have not been reported (Garcia, 2007).

#### **2.1.4.2.3 Mode of transmission**

Man gets infection by ingestion of food and water contaminated with sporulated oocyst (Paniker, 2013).

#### **2.1.4.2.4 Morphology**

##### **2.1.4.2.4.1 Oocysts**

The oval transparent oocyst of *I. belli* ranges in size from 25 to 35  $\mu\text{m}$  long by 10 to 15  $\mu\text{m}$  wide, with an average of 30 by 12  $\mu\text{m}$  (Zeibig, 2013). The developing morphologic form within the oocyst, known as a sporoblast, consists of a roundish immature sac that contains a small discrete nucleus and granular cytoplasm. As it matures; the young oocyst divides into two sporoblasts (Zeibig, 2013). Each sporoblast continues to mature and eventually becomes a sporocyst, which consists of a mature roundish sac containing four sausage-shaped sporozoites (Zeibig, 2013). This stage is known as the mature oocyst. Throughout its development, the sporoblast and sporocysts are surrounded by a smooth, colorless, two-layered cell wall (Zeibig, 2013). The sporulated oocyst containing 8 sporozoites is the infective stage of the parasite (Paniker, 2013).

#### **2.1.4.2.5 Life cycle**

When a sporulated oocyst is swallowed, 8 sporozoites are released from the 2 sporocysts in the small intestine and invade the intestinal epithelial cells (Paniker, 2013). In the epithelium, the sporozoites transform into trophozoites, which multiply asexually (schizogony) to produce a number of (merozoites) (Paniker, 2013). The merozoites invade adjacent epithelial cells to repeat asexual cycle. Some of the trophozoites undergo sexual cycle (gametogony) in the cytoplasm of enterocytes and transform into macro gametocytes and microgametocytes. After fertilization, a zygote is formed, which secretes a cyst wall and develops into an immature oocyst (Paniker, 2013). These immature oocysts are excreted with feces and mature in the soil. Incubation period: 1–4 days (Paniker, 2013).

#### **2.1.4.2.6 Clinical presentation and pathogenicity**

##### **2.1.4.2.6.1 Asymptomatic**

A number of infected individuals remain asymptomatic. In such cases, the infection is self-limited (Paniker and Zeibig, 2013).

#### **2.1.4.2.6.2 Isosporiasis**

Infected patients may complain of a number of symptoms, ranging from mild gastrointestinal discomfort to severe protracted diarrhoea, lasting for several years can be seen in immuno-compromised persons, particularly in the human immunodeficiency virus (HIV) infected (Paniker and Zeibig, 2013). The more commonly noted clinical symptoms include weight loss, chronic diarrhea, abdominal pain, anorexia, weakness, and malaise. In addition eosinophilia may occur in asymptomatic and symptomatic patients. Charcot-Leyden crystals may form in response to the eosinophilia and may be visible in corresponding stool samples. Patients experiencing severe infection typically develop a malabsorption syndrome (Paniker and Zeibig, 2013). In these cases, patients produce foul-smelling stools that are pale yellow and of a loose consistency. Fecal fat levels of these stool samples maybe increased. Infected patients may shed oocysts in their stools for as long as 120 days. Death may result from such severe infections (Paniker and Zeibig, 2013).

#### **2.1.4.2.7 Laboratory diagnosis**

Examination of a fecal specimen for the oocysts is recommended. However, wet-preparation examination of fresh material either as the direct smear or as concentrated material is recommended rather than the permanent stained smear (Garcia, 2007). The oocysts are very pale and transparent and can easily be overlooked. They can also be very difficult to see if the concentration sediment is from polyvinyl alcohol-preserved stool (Garcia, 2007). The light level should be reduced, and additional contrast should be obtained with the microscope for optimal examination

conditions. It is also quite possible to have a positive biopsy specimen but not recover the oocysts in the stool because of the small numbers of organisms present (Garcia, 2007). These organisms are acid fast and can also be demonstrated by using auramine rhodamine stains. Organisms tentatively identified by using auramine-rhodamine stains should be confirmed by wet smear examination or acid-fast stains, particularly if the stool contains other cells or excess artifact material (more normal stool consistency) (Garcia, 2007).

#### **2.1.4.2.8 Treatment**

The treatment of choice for asymptomatic or mild infections consists of consuming a bland diet and obtaining plenty of rest (Zeibig, 2013). Patient's suffering from more severe infections respond best to chemotherapy, consisting of a combination of trimethoprim and sulfamethoxazole or pyrimethamine and sulfadiazine (Zeibig, 2013). It is interesting to note that chemotherapy at a lower dosage for a longer period may be necessary for AIDS patients infected with *I. belli* (Zeibig, 2013).

#### **2.1.4.2.9 Prevention and control**

The prevention and control measures for *I. belli* are similar to those of *E. histolytica*. They include proper personal hygiene, adequate sanitation practices, and avoidance of unprotected sex, particularly among homosexual men (Zeibig, 2013).

#### **2.1.4.3 *Cyclospora cayetanensis***

##### **2.1.4.3.1 Background**

In recent years, human cyclosporiasis has emerged as an important infection, with a number of outbreaks being reported in the United States and Canada. Prior to 1995 only one outbreak of cyclosporiasis had been

reported in the United States; however, from May through August 1996, more than 1,400 cases were reported from 20 states, Washington, D.C., and two Canadian provinces (Garcia, 2007). Understanding of the biology and epidemiology of *C. cayetanensis* is limited and has been complicated by a lack of information about the parasite's origins, possible animal reservoir hosts, and relationship to other coccidian (Garcia, 2007). During the past few years, there have been several outbreaks of diarrhea associated with *C. cayetanensis*; the distribution is worldwide (United States, Caribbean, Central and South America, Southeast Asia, Eastern Europe, Australia, Nepal). These organisms are acid-fast variable and have been found in the feces of immuno competent travelers to developing countries, immuno competent subjects with no travel history, and patients with AIDS. Patients reported symptoms of "Flu-like" illness with nausea, vomiting, anorexia, weight loss, and explosive diarrhea lasting 1 to 3 weeks (Garcia, 2007). Cumulative evidence suggests that outbreaks in the United States and Canada during the spring months of 1996 and 1997 were related to the importation and ingestion of Guatemalan raspberries (Garcia, 2007). It is quite likely that the outbreak reported from Florida in 1995 was also attributed to contaminated food (Garcia, 2007). The cases reported in all three outbreaks probably represented only a small fraction of those that occurred (Garcia, 2007). These organisms have now been identified as coccidia in the genus *Cyclospora* and were first discovered in the late 1880s but not connected with human infections (Garcia, 2007).

#### **2.1.4.3.2 Epidemiology**

*C. cayetanensis* infections are known to occur in many countries, including the United States and Canada (Zeibig, 2013). Furthermore, cases of infection caused by *C. cayetanensis* have been reported in children living in unsanitary conditions in Lima, Peru, as well as in travelers and



foreigners residing in Nepal and parts of Asia. Contaminated water in Chicago presumably was the source of a mini-outbreak in 1990 that occurred in a physician's dormitory (Zeibig, 2013). Contaminated lettuce and fresh fruit (raspberries have been known to be a source of infection), often imported, have also been associated with *C. cayetanensis* infections (Zeibig, 2013).

#### **2.1.4.3.3 Mode of transmission**

The infection is acquired via the ingestion of an oocyst. The oocyst contains two sporocysts, each enclosing two sporozoites (Zeibig, 2013).

#### **2.1.4.3.4 Morphology**

##### **2.1.4.3.4.1 OOcyst**

Infected patients shed oocysts that measure 7 to 10  $\mu\text{m}$  in diameter and, on maturation, form two sporocysts each containing only two sporozoites (Zeibig, 2013).

##### **2.1.4.3.5 Life cycle**

The life-cycle of *C. cayetanensis*, like that of *Isospora*, begins with ingestion of an oocyst. The oocyst contains two sporocysts, each enclosing two sporozoites. Once inside a human host, cells in the small intestine provide a suitable environment for the emergence of sporozoites (Zeibig, 2013). The sporozoites undergo asexual reproduction, producing numerous merozoites, as well as sexual development, resulting in macro gametocyte and microgametocyte production (Zeibig, 2013). Male and female gametocytes unite and form oocysts. Infected humans pass immature oocysts in the stool. Under optimal conditions, these oocysts continue to develop and mature outside the human body, a process that may take 1 or more weeks to complete. Once the maturation process is

complete, the resultant oocysts are capable of initiating a new cycle. No animal reservoir exists (Zeibig, 2013).

#### **2.1.4.3.6 Clinical presentation and pathogenicity**

The clinical symptoms associated with *C. cayetanensis* infections in children are similar to those seen in cases of cryptosporidiosis (Zeibig, 2013). The notable difference among infections caused by these two organisms in adults is that *C. cayetanensis* produces a longer duration of diarrhea. There is no known connection between *C. cayetanensis* infection and immuno-compromised patients (Zeibig, 2013).

#### **2.1.4.3.7 Laboratory diagnosis**

Diagnosis of *C. cayetanensis* may be accomplished when stool samples are concentrated non-traditionally without the use of formalin fixative (Zeibig, 2013). *C. cayetanensis* oocysts sporulate best at room temperature. The addition of 5% potassium dichromate allows the sporocysts to become visible (Zeibig, 2013). Flotation methods followed by examination using the preferred phase contrast or bright field microscopy have also proven successful in isolating *C. cayetanensis* (Zeibig, 2013). Modified acid-fast stain may also be used to detect the oocysts. Oocysts are auto-fluoresce under ultraviolet light microscopy (Zeibig, 2013).

#### **2.1.4.3.8 Treatment**

Apparently, patients do not respond to conventional antimicrobial therapies. Some patients have been treated symptomatically with antidiarrheal preparations and have obtained some relief; however, the disease appears to be self-limiting within a few weeks (Garcia, 2007). Trimethoprim- sulfamethoxazole (TMP-SMX) is currently the drug of

choice (adults: 760/800 mg given orally twice daily for 7 days children: 5 mg of TMP/kg plus 25 mg of SMX/kg given orally twice daily for 7 days); relief of symptoms has been seen by 1 to 3 days post treatment (Garcia, 2007). Patients with AIDS may need higher doses and long-term maintenance treatment. However, symptoms recur within 1 to 3 months post treatment in over 40% of patients. In a study with TMP-SMX in Nepal, shedding of oocysts and symptoms disappeared after 7 days of treatment (Garcia, 2007).

#### **2.1.4.3.9 Prevention and control**

Prevention and control measures associated with *C. cayetanensis* consist of properly treating water prior to use and only using treated water when handling and processing food (Zeibig, 2013).

## **2.2 The intestinal helminths**

### **2.2.1 The intestinal cestodes**

Adult cestodes, or tapeworms, live attached to the mucosa in the small intestine and absorb food from the host intestine. The attachment organ is called the scolex, to which is attached a chain of segments or proglottids called the strobila. Each proglottid contains a male and female reproductive system (Garcia, 2007). The proglottids are classified as immature, mature, or gravid (the latter are found at the end of the strobila and contain the fully developed uterus full of eggs) (Garcia, 2007). The uterine structure in the gravid proglottids is often used as the main criterion for identification. The eggs and/or scolex can also be used to identify a cestode to the species level. Cestodes have complex life cycles that usually involve both the intermediate and definitive hosts (Garcia, 2007). In some infections, humans serve as only the definitive hosts, with the adult worm in the intestine (*Diphyllobothrium latum*, *Taenia saginata*,

*Hymenolepis diminuta*, and *Dipylidium caninum*). In other cases, humans can serve as both the definitive and intermediate hosts (*T. solium* and *H. nana*) (Garcia, 2007). Tapeworms have been recorded in writings from about 1500 BC and are among the earliest known human parasites. Galen, in the second century, recognized Taenia, and other tapeworms have been recognized since the late 1500s apparently, eggs of *Diphyllobothrium* spp. have been found in Alaska and date from the 13th and 17th centuries (Garcia, 2007). It was not until 1993 that a new human species was identified and described, *Taenia asiatica*; however, there is some discussion regarding whether this is actually a separate species or a subspecies of *T. saginata*. The exact prevalence of human intestinal tapeworms is not really known, but estimates are that as many as 100 million people are infected with *T. saginata* and *T. solium* while approximately 75 million are probably infected with *H. nana* (Garcia, 2007). Certainly, the presence of adult tapeworms in the intestinal tract is not life-threatening; however, infection with larval tapeworms can be very serious and can lead to death (Garcia, 2007).

### **2.2.1.1 *Taenia solium***

#### **2.2.1.1.1 Background**

*T. solium* is worldwide in distribution except in the countries and communities, which proscribe pork as taboo (Paniker, 2013). Its life cycle was elucidated when Leuckart, in 1861, first experimentally demonstrated that cattle serve as the intermediate host for the worm (Paniker, 2013). The name *Taenia* is derived from the Greek word meaning tape or band. It was originally used to refer to most tapeworms, but is now restricted to the members of the Genus *Taenia* (Paniker, 2013).

#### **2.2.1.1.2 Epidemiology**

The ingestion of cysticerci from raw or undercooked meat facilitates the transmission of *T. solium* from pigs to humans and is presumably responsible for the high prevalence of human cysticercosis in these regions (Satoskar *et al.*, 2009). It is estimated that anywhere between 5-40% of individuals carrying the adult tapeworm will develop cysticercosis (Satoskar *et al.*, 2009). Taenia infections are less common in North America; however neuro-cysticercosis has been recognized as an important health problem in California (Satoskar *et al.*, 2009). Although this disease is mainly seen in migrant workers from Latin American, it has also been reported in US residents who have not traveled to endemic countries (Satoskar *et al.*, 2009).

#### **2.2.1.1.3 Mode of transmission**

Humans are infected by consuming inadequately cooked pork containing *cysticercus cellulosae* (measly pork) (Paniker, 2013). Man harboring adult worms may auto-infect oneself either by un-hygienic personal habits or by reverse peristaltic movements of the intestine (Paniker, 2013).

#### **2.2.1.1.4 Morphology**

##### **2.2.1.1.4.1 Adult**

The adult worm is usually 2-3 meters long. The scolex of *T. solium* is small and globular about 1mm in diameter, with 4 large cup-like suckers (0.5 mm in diameter), and a conspicuous rounded rostellum armed with a double row of alternating round and small dagger-shaped hooks, 20–50 in number (Paniker, 2013). The neck is short and half as thick as the head. The proglottides number less than a thousand. They resemble those of *T. saginata* in general. The gravid segments are twice as long as broad, 12

mm by 6 mm. The testes are composed of 150 to 200 follicles (Paniker, 2013). There is an accessory lobe for the ovary. The vaginal sphincter is absent. The uterus has only 5 to 10 (under 13) thick lateral branches (Paniker, 2013). A lateral thick-lipped genital pore is present, alternating between the right and left sides' adjacent segments (Paniker, 2013). The gravid segments are not expelled singly, but pass passively out as short chains. The eggs escape from the ruptured wall of the uterus (Paniker, 2013).

#### **2.2.1.1.4.2 Eggs**

The egg is spherical, measuring 30–40  $\mu\text{m}$  in diameter. It has a thin hyaline embryonic membrane around it which soon disappears after release (Paniker, 2013). The inner embryophore is radially striated and is yellow-brown due to bile staining. In the center is a fully-developed embryo (oncosphere) with 3 pairs of hooklets (hexacanth embryo) (Paniker, 2013). The eggs do not float in saturated salt solution and they are infective to pigs and humans too (Paniker, 2013).

#### **2.2.1.1.4.3 Larvae**

It is called: "*Cysticercus cellulosae*" (Paniker, 2013). It is the infective form of the parasite. It can develop in various organs of pig as well as in man (Paniker, 2013). The *C. cellulosae* or 'bladder worm' is ovoid opalescent milky-white, measuring 8–10 mm in breadth and 5 mm in length (Paniker, 2013). The scolex of the larva, with its suckers, lies invaginated within the bladder and can be seen as a thick white spot and can remain viable for several months (Paniker, 2013).

#### **2.2.1.1.5 Life cycle**

When *T. solium* causes intestinal taeniasis, its life cycle is similar to that of *T. saginata* except: definitive host is the man while the intermediate host is the pig and the infective stage is the *C. cellulosae* (larva) (Paniker, 2013). Humans are infected by consuming inadequately cooked pork containing *C. cellulosae* (measly pork) (Paniker, 2013). When *Taenia* leads to cysticercosis, the life cycle is as follows: definitive host, Intermediate host is both man and infective stage is the eggs of *T. solium* (not larva) (Paniker, 2013). Man acquires infection by ingesting eggs with contaminated food and water or the autoinfection when man harboring adult worm may auto-infect oneself, either by un-hygienic personal habits or by reverse peristalsis of the intestine (Paniker, 2013). The further development of the eggs is similar in man and pigs. The oncospheres are released in the duodenum or jejunum and penetrate the intestinal wall (Paniker, 2013). They enter the mesenteric venules or lymphatics and are carried in systemic circulation to the different parts of the body (Paniker, 2013). They are filtered out principally in the muscles where they develop into the larval stage in about 60–70 days (Paniker, 2013). In humans, it is a dead end and the larvae die without further development (Paniker, 2013).

#### **2.2.1.1.6 Clinical presentation and pathogenicity**

##### **2.2.1.1.6.1 Intestinal taeniasis**

It can be caused by both *T. saginata* and *T. solium*. The adult worm, in spite of its large size, causes surprisingly little inconvenience to the patient (Paniker, 2013). When the infection is symptomatic, vague abdominal discomfort, indigestion, nausea, diarrhea, and weight loss may be present (Paniker, 2013). Occasional cases of acute intestinal obstruction, acute appendicitis, and pancreatitis have also been reported (Paniker, 2013).

#### **2.2.1.1.6.2 Cysticercosis**

It is caused by larval stage (*C. cellulosae*) of *T. solium* (Paniker, 2013). *C. cellulosae* may be solitary or more often multiple (Paniker, 2013). Any organ or tissue may be involved, the most common being subcutaneous tissues and muscles (Paniker, 2013). It may also affect the eyes, brain, and less often the heart, liver, lungs, abdominal cavity, and spinal cord (Paniker, 2013). The Cysticercus is surrounded by a fibrous capsule except in the eye and ventricles of the brain (Paniker, 2013). The larvae evoke a cellular reaction starting with infiltration of neutrophils, eosinophils, lymphocytes, plasma cells, and at times, giant cells (Paniker, 2013). This is followed by fibrosis and death of the larva with eventual calcification (Paniker, 2013). The clinical features depend on the site affected.

#### **2.2.1.1.7 Laboratory diagnosis**

Diagnosis of cysticercosis is based on:

##### **2.2.1.1.7.1 Biopsy:**

Definitive diagnosis of cysticercosis is by biopsy of the lesion and its microscopic examination to show the in-vaginated scolex with suckers and hooks (Paniker, 2013).

##### **2.2.1.1.7.2 Imaging methods:**

X-ray: Calcified cysticerci can be detected by radiography of subcutaneous tissue and muscles particularly in the buttocks and thigh (Paniker, 2013). X-ray of the skull many demonstrate cerebral calcified cyst (Paniker, 2013).

Computed tomography (CT) scan of brain is the best method for detecting dead calcified cysts (Paniker, 2013). The cysticercal lesions appear as



small hypo densities (ring or disc-like) with a bright central spot (Paniker, 2013).

Magnetic resonance imaging (MRI) scans of the brain is more helpful in detection of non-calcified cysts and ventricular cysts. It also demonstrates spinal cysticerci (Paniker, 2013).

#### **2.2.1.1.7.3 Serology:**

Antibody detection: Anti cysticercus antibodies in serum or cerebrospinal fluid (CSF) can be detected by ELISA and enzyme-linked immuno-electro-transfer blot (EITB) tests (Paniker, 2013).

Antigen detection: Antigen can be detected in serum and CSF by ELISA, using monoclonal antibodies and indicate recent infection (Paniker, 2013).

#### **2.2.1.1.9 Prevention and control**

Pork to be eaten by man should be subjected to effective inspection for cysticerci in slaughter house. Raw or undercooked pork meat should not be eaten (Paniker, 2013). The critical thermal point of cysticercus is 56°C for 5 minutes (Paniker, 2013). Developing good sanitary measures and improving the personal habits (Paniker, 2013).

### **2.3 The investigated plants products**

#### **2.3.1 Watermelon seeds**

##### **2.3.1.1 Botanical description**

Watermelon (*Citrullus lanatus*) is of the *cucurbitaceae* family. As a member of the *cucurbitaceae*, watermelon is related to the cantaloupe, squash and pumpkin and other plants that grows on vines on the ground (Rekha and Rose, 2016).

### **2.3.1.2 Ecology**

Watermelon (*Citrullus lanatus*) a fruit crop, is an herbaceous creeping plant (Betty *et al.*, 2016). It is mainly propagated by seeds and thrives best in warm areas (Betty *et al.*, 2016). It is a tropical plant and requires a lot of sunshine and high temperature of over 25°C for optimum growth (Betty *et al.*, 2016). Watermelon thrives best in a drained fertile soil of fairly acidic nature (Betty *et al.*, 2016). It can be grown along the coastal areas of Ghana, the forest zone and especially along river beds in the Northern Savannah areas (Betty *et al.*, 2016). The Sudan is considered as the country of origin for watermelon, especially, Kordufan zone where it grows as a wild plant. Sweet watermelon has many local names in Middle East countries such as (battikh) in Sudan, (Hub –Hub) in Saudi Arabia (Mohammed, 2005). In Sudan and Egypt watermelon seeds when used to prepare snack which is called: "Tasali".

### **2.3.1.3 Utilization**

#### **2.3.1.3.1 Nutritional value**

Watermelon fruits include numerous flattened seeds constituting about 1.9-4% of fresh fruit (Mohammed, 2005). Seeds are contained in the pulp (Mohammed, 2005). Seeds of different varieties vary in size, thickness, texture of the seeds coat and the thickness of the seeds edges (Mohammed, 2005). There are small, moderate and large sized seeds (Mohammed, 2005). The seeds differ in color; they may be black, brown, red, yellow, or rarely white (Mohammed, 2005). Watermelon seeds length and width may be about (0.6 – 1.5cm) and (0.5 – 0.7cm) respectively (Mohammed, 2005). Watermelon seeds are known to be highly nutritional; they are rich sources of protein, vitamins B, minerals (such as magnesium, potassium, phosphorous, sodium, iron, zinc, manganese and copper) and fat among

others as well as phytochemicals (Mohammed, 2005). The seeds of watermelons are known to have economic benefits especially in countries where cultivation is on the increase (Mohammed, 2005). The seeds are for instance used to prepare snacks, milled into flour and used for sauces (Betty *et al.*, 2016). Oil from the seeds is used in cooking, incorporated into the production of cosmetics and soap making and sometime for illumination (Mohammed, 2005; Betty *et al.*, 2016). The seeds of the wild variety of watermelon can be used for animal feeding after the extraction of the oil by making watermelon cake seed which can be compared with coconut, cotton, and linseed cake (Mohammed, 2005). The cake can be fed to animal safely and no adverse effects have been noticed, and gave a good account of its nutritional and medicinal benefits (Mohammed, 2005). In spite of the various potential applications, the watermelon seeds are often discarded while the fruit is eaten (Betty *et al.*, 2016).

#### **2.3.1.3.2 Medicinal value**

According to Betty *et al.* (2016); watermelon seeds have phytochemical and antioxidant properties. In addition, watermelon seed oil has advantage of containing low amount of saturated fatty acids which can benefit patients with cardio vascular disease (Mohammed, 2005).

#### **2.3.1.4 Chemical composition of water melon seed**

##### **2.3.1.4.1 Moisture content**

The moisture content of water melon seeds from different places are as to be 2.8% and 4.94% for Sudanese watermelon seeds special type obtained from western Sudan and another type obtained from Kordofan in the vicinity of Elobied respectively, 7.9% and 5.6% for two Nigerian varieties of water melon seeds respectively, 2.61 for an Egyptian watermelon seeds,

3.14 for an Iranian, and 3.24 for Chinese water melon seeds (Mohammed, 2005).

#### **2.3.1.4.2 Crude protein**

The crude protein content in the seed contained about 40.5%, 24.55, 39%, and 30.8-34% crude protein for an Egyptian, Iranian, Chinese variety, and Oyo state in Nigeria respectively (Mohammed, 2005).

#### **2.3.1.4.3 Oil contents**

The oil content of many Sudanese varieties of whole ground watermelon seed is in the range of 25.8 to 28.7%. Different values for oil contents can be detected; this variation in oil contents may be explained due to varieties differences, source of seed, and climatic and growing condition (Mohammed, 2005).

#### **2.3.1.4.4 Crude fiber**

Fibers content of whole watermelon seed on dry matter bases 47.7%. The high levels of crude fiber content in both of watermelon seeds and meal may interfere with their levels of inclusion in broiler ration since; nutritionally permissible level of fiber in broiler should not exceed 8% (Mohammed, 2005).

#### **2.3.1.4.5 Total ash contents**

Ash content of watermelon seeds was investigated by several workers was found in range of 1.85-5.2% (Mohammed, 2005).

#### **2.3.1.4.6 Carbohydrates contents**

With respect to the carbohydrate content of watermelon seed the range is 3.50 % - 8.38%; but other studies reported proximate or higher values (Mohammed, 2005).

## 2.3.2 Nabag

### 2.3.2.2 Botanical description

The genus *Ziziphus* belongs to the *Rhamnaceae* family which consists of about 100 species of deciduous or evergreen trees and shrubs distributed throughout the tropical and subtropical regions of the world, from which twelve species are cultivated (Saied *et al.*, 2008). *Z. spina-christi* is a spiny shrub or small tree that strongly resists heat and drought (Saied *et al.*, 2008). Normally the species grows into a tree form, but it often acquires a bush form due to intensive grazing during the latter part of the dry seasons and heavy destructive cutting for fencing material and fuel (Saied *et al.*, 2008). It develops very deep taproot and has an extraordinary regenerative power (Saied *et al.*, 2008). It is evergreen but can drop some of its leaves during very dry seasons (Saied *et al.*, 2008). The tree can reach a size of 5–10 m and a trunk diameter (DBH) of up to 45 cm (Saied *et al.*, 2008). The bark is whitish brown or pale grey and is deeply fissured (Saied *et al.*, 2008). The crown is rounded or umbelli-form with dense branches that spread widely and have a tendency to weep at the ends (Saied *et al.*, 2008). Spines are light brown in color and paired, with one of each pair being up to 8 mm long, straight and directed forward while the other is shorter and slightly curved (Saied *et al.*, 2008). Leaves are simple, alternate, narrowly ovate-lanceolate, varying from 1 to 9 cm in length and 1–3.5 cm in width, are glabrous above, minutely and densely pubescent beneath, have three basal, conspicuous veins running up to the apex and around 0.5–1.0 cm long petioles (Saied *et al.*, 2008). The flowers have a sweet scent and are found in dense clusters in the axils of the leaves. They are small, greenish yellow, sub-sessile with 5 min sepals 2 mm long and five petals 1.5 mm long (Saied *et al.*, 2008). Stamens are five opposite the petals and inserted at the base of flat lobed disc (Saied *et al.*, 2008). The ovary is 2-locular;

styles short and divided above into two lobes (Saied *et al.*, 2008). In Sudan the flowering time is August until December (Saied *et al.*, 2008). Fruit is a globose drupe about 1–1.5 cm in diameter, red-brown, with a hard stone surrounded by a sweet edible pulp (Saied *et al.*, 2008). Fruiting time extends from October until April (Saied *et al.*, 2008).

### **2.3.2.3 Ecology**

The genus *Ziziphus* is known to be drought tolerant and very resistant to heat (Saied *et al.*, 2008). It can be found in desert areas with very low rainfall. *Z. spina-christi* is found over the whole Sahelian area from Senegal to Sudan and across a large area in North Africa, Middle East, east Afghanistan and North West India (Saied *et al.*, 2008). The species is native to Sudan where it grows extensively in the north and center of the country and along the Nile banks in Khartoum (Saied *et al.*, 2008). *Ziziphus spina-christi* can generally be found at altitudes up to 600 m. However, Jongbloed (2003) said that; in the United Arab Emirates it has been reported to grow at elevations of around 1,500 m (Saied *et al.*, 2008). The species can tolerate high temperatures. It grows in desert areas with an annual rainfall of 50–300 mm, but is often also found in wadis where underground water is available (Saied *et al.*, 2008). Boulos (2000) said that; In Egypt apart from spontaneous growth, the tree is cultivated in the Nile valley in villages and parks (Saied *et al.*, 2008). The shrub thrives on a wide range of soil types, but prefers light silty ones (Saied *et al.*, 2008).

### **2.3.2.4 Utilization**

#### **2.3.2.4.1 Nutritional use**

Fruits of *Z. spina-christi* are used as food especially for people in western and central Sudan and other Saharan regions (Saied *et al.*, 2008). Fruits are collected by women and children and sold on local markets (Saied *et al.*,

2008). This provides an additional source of income for local people, who may use the revenue to buy important non-food items (Saied *et al.*, 2008). Similarly, in Oman fruits are collected from wild and cultivated plants and sold on local markets (Saied *et al.*, 2008). Fruits are consumed either fresh or dried and the sweet pulp of fruit is dried to produce fine flour (Saied *et al.*, 2008). Typically, this flour is placed in small metal cups and cooked under steam (Saied *et al.*, 2008). This process solidifies the flour to the shape of the container (Saied *et al.*, 2008). The dried pulp flour and water are also mixed with sesame and formed into small balls (Saied *et al.*, 2008). The fruit pulp prepared in these two ways can be consumed either immediately or stored for future use (Saied *et al.*, 2008). Small branches are often lopped as dry season fodder for camels and goats and later used to make thorn fences as (Saied *et al.*, 2008). The honey collected from the flowers of *Z. spina christi* is of excellent flavour and is normally sold at a price higher than that derived from the flowers of other trees (Saied *et al.*, 2008). Sider leave extract could be applicable in food processing as a natural preservative (Ibraheem, 2017).

#### **2.3.2.4.2 Medicinal use**

*Ziziphus spina-christi* extracts are important in drug development with pharmacological activities in the Middle East and South and East of Asia (Asgarpanah and Haghighat, 2012). For a long time, *Z. spina-christi* has been used in alternative medicine (Asgarpanah and Haghighat, 2012). The vast majority of rural people in Sudan has no access to modern medicine and relies heavily on traditional cures, mostly prepared from plants (Saied *et al.*, 2008). The genus *Ziziphus* is known for its medicinal properties as a hypoglycemic, hypotensive, anti-inflammatory, antimicrobial, antioxidant, anti-tumor, and liver protective agent and as an immune system stimulant (Said *et al.*, 2008). In central Sudan, *Z. spina-christi* fruits are eaten to

treat diarrhoea and malaria and as an antispasmodic. The powder of the twigs is used externally to treat rheumatism and scorpion sting (Saied *et al.*, 2008). The strong and wide antimicrobial activity of this plant makes it a strong substitution for synthetic antibiotics (Motamedi *et al.*, 2014). In northern Kordofan the poultice of the powdered leaves is used to heal swellings and macerated roots are used as an anti-purgative (Saied *et al.*, 2008). In the White Nile states the decoctions of the bark are used to treat intestinal spasms (Saied *et al.*, 2008). In the Sahel region the roots are reported as a treatment against headaches, while spines and ashes are applied to heal snake bites (Saied *et al.*, 2008). Boiled leaves are applied to various surface wounds and against diarrhoea. In Egypt a beverage made from fruits is considered to be a sedative (Saied *et al.*, 2008). In Palestine leaves and young branches are used as anti-inflammatory for eye wash, treat toothache and stomachache and as an anti-rheumatic (Saied *et al.*, 2008). In the United Arab Emirates leaves are boiled in water and used as a shampoo or mixed with lemon and applied to the face and hair to soften or to soothe it (Saied *et al.*, 2008). Ash of wood mixed with vinegar is applied to heal snake bites and a tea made of fruit is used to treat measles. Fruits and crashed kernels are eaten to treat chest pains, respiratory problems and as a tonic (Saied *et al.*, 2008). Moreover, in Oman fruits are regarded as having purifying properties such as cleansing the stomach, removing impurities from blood as well as being a restorative for the whole system (Saied *et al.*, 2008). The water in which crushed leaves had been boiled is given to women in prolonged labor or with a retained placenta for its oxytocic properties (Saied *et al.*, 2008). In India, a preparation from bark is used to clean wounds and sores, while the gum that exudes from the tree in hot weather is used in eye remedies (Saied *et al.*, 2008). The chewed leaves are said to numb the taste buds, which



provides a method of suppressing the unpleasant flavor of some oral medicines (Saied *et al.*, 2008).

#### **2.3.2.4.3 Other uses**

The wood is used as a source of fuel and it produces an excellent charcoal. The timber is used for tool handles, fence posts, bedstead legs, walking sticks, furniture, bent wood chairs, roofing beams, doors, windows and turned items. It is hard and heavy and is known to resist termites. In some parts of West Africa *Ziziphus* trees are planted to stabilize sand dunes and erosion-prone areas because of their deep taproot and spreading lateral roots (Saied *et al.*, 2008). The tree is planted around towns and villages for shade as it makes useful windbreaks and shelterbelts (Saied *et al.*, 2008). The tree is also intercropped with millet as it is known to improve soil fertility by increasing available phosphorous. For Muslims seeds are used as rosaries, while for Christians the thorns are reported to have made up the crown of thorns of Jesus (Saied *et al.*, 2008). In natural religions the tree's roots are used in superstitious practices (Saied *et al.*, 2008).

#### **2.3.2.5 Chemical composition**

The flesh of *Z. spina-christi* fruits is rich in carbohydrates (80.6%) in dry matter notably starch (21.8%), sucrose (21.8%), (glucose (9.6%), and fructose (16%). Iron (3mg 100g<sup>-1</sup> dried fruit. One hundred gram dried fruit pulp contains 314 calories, 4.8 g protein, 0.9 g fat, 140mg calcium, 0.04 mg of thiamin, 0.13 mg riboflavin, 3.7 mg niacin and 30 mg ascorbic acid. This is a rather high value if compared with those of orange (50 mg), grape (38 mg) and strawberry (59 mg) (Saied *et al.*, 2008).

### **2.3.3 Groundnuts**

#### **2.3.3.1 Botanical description**

The genus *Arachis* belongs to the family *Fabaceae*, sub-family *Papilionaceae*, tribe *Aeschynomeneae*, sub-tribe *Stylosanthineae*, and it has 70 wild species. Botanically; groundnuts seed consists of two cotyledons; a hypocotyle, epicotyle, and radicle (Vara *et al.*, 2015).

### **2.3.3.2 Ecology**

Peanut (*Arachis hypogaea L.*) production worldwide is reported to be greater than 36 million tons per year (Favero *et al.*, 2015).

### **2.3.3.3 Utilization**

#### **2.3.3.3.1 Medicinal use**

According to Peanut Institute (2014); a study, published in the New England Journal of Medicine, is the largest to date to look at death from all causes in nut eaters (WWW.Peanut-institute.org). The study tracked nearly 119,000 men and women from the Nurses' Health Study and the Health Professionals Follow-up Study over a 30-year period (WWW.Peanut-institute.org). They found that the more frequently peanuts and nuts were consumed, the lower the risk of death (WWW.Peanut-institute.org). Compared to non-nut eaters, those who consumed peanuts and nuts occasionally reduced risk of death by 7%, weekly eaters reduced risk by 11%, eating peanuts two to four times a week cut risk by 13%, and eating peanuts and nuts seven or more times a week cut risk by about 20%. When researchers looked at death rates based on peanuts, they found that eating peanuts just twice a week reduced death from any cause by 12% (WWW.Peanut-institute.org). When they looked at death by specific cause, they found that eating peanuts daily reduced risk of death due to heart disease by 24%, respiratory disease by 16%, infections by 32%, and kidney disease by 48% (WWW.Peanut-institute.org). When researchers looked at peanuts alone and compared them to a mixture of tree nuts, they

found the results were about the same (WWW.Peanut-institute.org). Previous research from Harvard School of Public Health showed that a 1-ounce serving of peanuts or a half serving (one tablespoon) of peanut butter eaten five or more times a week, can decrease the risk of diabetes by 27% and 21% respectively (WWW.Peanut-institute.org). Additional work by Harvard showed that a handful of peanuts eaten five or more times per week can cut the risk of heart disease in half because of its Nutrients, such as unsaturated fatty acids, high-quality protein, fiber, vitamins, minerals, and phytochemicals which may confer the cardio-protective, anti-carcinogenic, anti-inflammatory, and antioxidant properties of the peanuts (WWW.Peanut-institute.org).

#### **2.3.3.3.2 Nutritional use**

Groundnuts mainly used for extraction of oil; but can be used as "snacks" freshly or after some processing (Vara *et al.*, 2015). Among the three crops products; ground nuts have the widest use; it may be eaten after crushing the grinded nuts to obtain groundnuts butter (Vara *et al.*, 2015). Groundnuts butter locally is known as: "Dakwa"; which is used in preparing sauces that can be involved in salads dishes. Groundnuts is eaten as snack: raw, after grilling (roasting) without its external cortex envelop, or after boiling it in salted water with its external envelop (Vara *et al.*, 2015).

#### **2.3.3.4 Chemical composition**

##### **2.3.3.4.1 Oil contents**

Oil content ranged from 33.6 to 54.95%. The mean oil content of Virginia types was slightly higher (49.7%) than the Spanish types (47.3%) (Asibuo *et al.*, 2008).

#### **2.3.3.4.2 Protein contents**

Crude protein of seed ranged from 18.92 to 30.53%. Seed protein content of most of the cultivars was higher than cowpea which contains about 24% seed protein (Asibuo *et al.*, 2008). Cowpea and groundnut are the major protein sources to the poor and rural dwellers. Broni fufuo had the highest crude protein content (30.53%) while Sinkazie had the least (18.92%) (Asibuo *et al.*, 2008). The results also demonstrate that groundnut is a valuable source of protein for improving the nutrition of humans and farm animals (Asibuo *et al.*, 2008). Broni Fufuo had unusually higher crude protein content (Asibuo *et al.*, 2008).

#### **2.3.3.4.3 Carbohydrate content**

Carbohydrate differed between 19.02 and 27.16% with a mean of 23% (Asibuo *et al.*, 2008).

#### **2.3.3.4.4 Minerals contents**

Potassium content ranged from 1180 to 1693 mg/100 g, sodium ranged from 19 to 40 mg/100 g, calcium ranged from 44 to 134 mg/100 g and magnesium ranged from 308 to 456 mg/100 g, Zinc ranged from 0 to 6.5 mg/100 g with a mean of 5.2 mg/100 g, Copper differed from 0 to 2.7 mg/100 g with a mean 1.9 mg/100 g, Iron ranged from 0.2 to 3.7 mg/100 g with a mean of 2.8 mg/100 g, Manganese ranged from 1.7 to 2.9 mg/100 g with a mean of 2.1 mg/100 g. All the varieties had appreciable amounts of zinc, copper, iron and manganese, except “Kintampo local” which had no Zinc and copper (Asibuo *et al.*, 2008).

#### **2.3.3.4.5 Vitamins**

The vitamins contained in the groundnut are: E, K, and B group (Asibuo *et al.*, 2008).

*Chapter three*  
*Materials and methods*

## **Chapter III**

### **Materials and methods**

#### **3.1 Study design:**

It was a descriptive cross- sectional study.

#### **3.2 Study area and duration:**

This study was conducted in Khartoum state; the national capital city of Sudan Republic. It is 22,142 km<sup>2</sup> in size with 5, 274,321 inhabitants according to 2008 census. The state lies between longitudes 31.5 to 34 °E and latitudes 15 to 16 °N. Geographically divided into blocks or clusters (Bahri, Omdurman, and Khartoum), which are further subdivided into localities, there are a total of three blocks and seven localities (WWW. Google. Com). This study was conducted in the period from July 2019 to January 2020.

#### **3.3 Study populations:**

The study was carried out on streets vendors' products including: groundnuts, nabag, and tasali in Khartoum state.

#### **3.4 Sample size and sampling:**

Sampling method was a cluster sampling technique. The sample size was 45 samples totally (15 sample of each crop) taken from 15 vendors in each locality in Khartoum state (5 vendors from each locality).

#### **3.5 Data collection:**

Data in this study were collected using observational method for each vendor in addition to the results obtained from macroscopic and microscopic examination of the crops.

### **3.6 Methodology:**

#### **3.6.1 Crops sample collection and preparation:**

About 69.8 g of nabag, 50 g of tasali, and 69.9 g of groundnut were purchased from 15 sellers in Khartoum state of Sudan (5 sellers from each block; Bahri, Khartoum, and Omdurman) making a total of 45 sample; 15 sample from each crop product type. The purchased products were transported to the laboratory to be examined macroscopically for insect, larvae, animal dropping, and dirt. Then each product of those purchased from the same seller was put separately in clean, dry glass bottles after labeling and covered until the surface with distilled water; about 100-150 ml according to need. Bottles were left for one hour and then the three washes of nabag, tasali, and ground nuts were collected in another labeled, clean, dry glass bottles. The previous step was repeated twice to achieve three washes for each product type which was mixed together. 15 ml of each of the three washes was centrifuged in conical tubes, the supernatant was discarded, and the deposit was re-suspended in 2 ml of distilled water to be used in formal ether concentration technique and sugar floatation technique. The entire process was repeated for the fourteen samples.

#### **3.6.2 Formal- ether concentration technique:**

Using a pasture pipette about 1ml from the wash of the crop which was previously suspended in distilled water. Crops washes were added to 4 ml of 10% v/v formal saline contained in a conical centrifuge tube. The contents were mixed well by shaking for 20 seconds. An equal volume about 3-4 ml of diethyl ether was added to the crop suspension in the conical tube and the contents were stoppered and shaken for 1 minute and immediately the stoppered was centrifuged for one minute at 3000 rpm. After centrifugation four layers of: ether, plant debris, formal saline, and

deposit were formed. Using a stem of plastic bulb pipette the layer of plant debris was removed and then the tube was inverted to discard the ether, plant debris, and formal saline while the sediment or deposit which may contains the parasites was remained. The tube was returned to the up-right position and the remained fluid was collected using a pasture pipette and then transferred to clean dry slide, covered with cover glass, and examined microscopically (Cheesbrough, 2005).

### **3.6.3 Saturated sugar floatation technique:**

About 1 ml of the previously prepared certain crop wash was put into a glass tube and then the floatation solution was added gradually until a convex surface was formed on the top of the glass tube. A cover slip was put and then the tube was left for 15-30 min, removed, and examined under the light microscope (Abdalazim *et al.*, 2019).

### **3.7 Statistical data analysis:**

For analysis the statistical package of social science (SPSS), IBM SPSS version 20 software was used. Statistical tests were carried out at 5% significance level ( $P < 0.05$ ) and confidence interval (CI) set at 95%. Frequency was calculated. Pearson's chi-squared test was used to test the statistical significance of the association.

### **3.8 Ethical considerations:**

Approval was taken from the College of Medical Laboratory Science- Sudan University of Science and Technology.



*Chapter four*  
*Results*

## Chapter IV

### Results

#### 4.1 General characteristics of studied population:

The present study involved 15 street vendors who were selling: groundnuts, nabag, and tasali. The Ages of studied population were divided into 6 groups; 10\_20, 20\_30, 30\_40, 40\_50, 50\_60, and more than 60 years. The more frequent age group was 30\_40 (46.7%) followed by: 40\_50 (20%), 20\_30 (13.3%), 10\_20 (6.7%), 50\_60 (6.7%), and more than 60 (6.7%). Out of 15 subjects; 8 (53.3%) were females and 7 (46.7%) were males (Table 4.1).

**Table (4.1): Frequency of study subjects according to age groups:**

Age groups (years)	Frequency		Total
	Males	Females	
10_20	1	0	1 (6.7%)
20_30	1	1	2 (13.3%)
30_40	3	4	7 (46.7%)
40_50	2	1	3 (20%)
50_60	0	1	1 (6.7%)
More than 60	0	1	1 (6.7%)
Total	7 (46.7%)	8 (53.3%)	15 (100%)
	15 (100%)		

#### 4.2 Overall contamination rate and its relation to the type of crops:

The overall contamination rate was 60% (27 samples) divided as: 20% (9) for groundnut, 22.2% (10) for nabag, and 17.8% (8) for tasali. Chi-square used to test relation between crop type and positivity of results and gave an insignificant level at P. value=0.757(Table 4.2).

**Table (4.2): Overall contamination rate and its relation to the type of crops:**

Crop type	Positive	Negative	Total
Groundnut	20%(9)	13.3%(6)	33.3%(15)
Nabag	22.2%(10)	11.1%(5)	33.3%(15)
Tasali	17.8%(8)	15.6%(7)	33.3%(15)
<b>Total</b>	60%(27)	40%(18)	100%(45)

P=0.757

#### 4.3 The detected parasitic species:

Among the 27 positive samples; the detected species were: *E. histolytica* (33.3%) and *G.lambliia* (15.6%) with no other protozoan species neither helminthes species. Co- appearance of both *E. histolytica* and *G.lambliia* represented (11.1%) of the positive results (Table 4.3).

**Table (4.3): The frequency of parasitic species:**

Parasite spp.	Result		Total
	Positive	Negative	
<i>E. histolytica</i>	33.3% (15)	0%	33.3% (15)
<i>G.lambliia</i>	15.6% (7)	0%	15.6% (7)
<i>E. histolytica</i> and <i>G.lambliia</i>	11.1%(5)	0%	11.1%(5)
None	0%	40%(18)	40%(18)
<b>Total</b>	60%(27)	40%(18)	100%(45)

#### 4.4 Comparison between the detecting rate of FECT and sugar floatation technique in detecting parasites from crops:

The contamination rate using FECT was 53.3% (24 samples); while it was 48.9% (22 samples) using sugar floatation technique. Testing relation showed highly significant value at P.value=0.000 (Table 4.4).

**Table (4.4): Comparison between the sensitivity of FECT and sugar floatation technique in detecting parasites from crops:**

Technique	Result		Total
	Positive	Negative	
<b>FECT</b>	53.3%(24)	46.7%(21)	100%(45)
<b>Sugar floatation</b>	48.9%(22)	51.1%(23)	100%(45)

P=0.000

#### 4.5 Comparison between the parasite species detection and the type of used technique:

Using FECT the prevalence of *E.histolytica*, *G.lamblia*, and mixed contamination of *E.histolytica* and *G.lamblia* were: 33.3% (15), 11.1% (5), and 8.9% (4) respectively; while they were 37.8% (17), 8.9% (4), and 2.2% (1) for *E.histolytica* and *G.lamblia* respectively using sugar floatation technique (Table 4.5).

**Table (4.5): Comparison between the parasite species detection and the type of used technique:**

Parasite spp.	Technique			
	FECT		Sugar	
	Positive	Negative	Positive	Negative
<i>E. histolytica</i>	33.3%(15)	0%	37.8%(17)	0%
<i>G.lamblia</i>	11.1%(5)	0%	8.9%(4)	0%
<i>E.histolytica</i> and <i>G.lamblia</i>	8.9%(4)	0%	2.2%(1)	0%
None	0%	46.7%(21)	0%	51.1%(23)
<b>Total</b>	53.3%(24)	46.7%(21)	48.9%(22)	51.1%(23)
	100%(45)		100%(45)	

#### 4.6 Correlation between crop type and detected parasite species:

Among the different crops; groundnut, nabag, and tasali; the prevalence rates of *E.histolytica* were: 15.6% (7), 8.9% (4), and 8.9% (4); and for *G.lamblia* were: 2.2% (1), 6.7% (3), and 6.7% (3) respectively. Mixed contamination was observed in groundnut, nabag, and tasali as: 2.2% (1), 6.7% (3), and 2.2% (1) respectively. The dominant parasite for all crops types was *E.histolytica*. There was no relation between the crop type and the species of detected parasite (P. value =0.639) (Table 4.6).

**Table (4.6): Correlation between crop type and detected parasite species:**

Crop type	Parasite spp.			Total
	<i>E.histolytica</i>	<i>G.lamblia</i>	<i>E.histolytica</i> & <i>G.lamblia</i>	
Groundnut	15.6%(7)	2.2%(1)	2.2%(1)	20%(9)
Nabag	8.9%(4)	6.7%(3)	6.7%(3)	22.3%(10)
Tasali	8.9%(4)	6.7%(3)	2.2%(1)	17.8%(8)
<b>Total</b>	33.4%(15)	15.6%(7)	11.1%(5)	60.1%(27)

P=0.639

#### 4.7 Comparison between positivity of crop type and used technique:

For groundnut, nabag, and tasali the contamination rates using FECT were: 20%(9), 20%(9), and 13.3%(6); while using sugar floatation technique they were: 20%(9), 13.3%(6), and 15.5%(7) respectively. The relation between the positivity of crop type and the used technique was insignificant with both FECT (P.value = 0.655) and sugar floatation technique (P.value = 0.591) (Table 4.7).

**Table (4.7): Comparison between positivity of crop type and technique:**

Crop type	Positive results	
	FECT	Sugar floatation
Groundnut	20%(9)	20%(9)
Nabag	20%(9)	13.3%(6)
Tasali	13.3%(6)	15.5%(7)
<b>Total</b>	<b>53.3%(24)</b>	<b>48.8%(22)</b>

FECT: (P=0.655) Sugar floatation: (P=0.591)

#### 4.8 Correlation between Khartoum state block and the species of the detected parasite:

The result showed that, *E.histolytica* was the dominant parasite throughout all blocks; its prevalence rates among Khartoum, Bahri, and Omdurman were: 17.8%, 17.8%, and 8.9% respectively; while *G.lambliia* had lower rates among Khartoum, Bahri, and Omdurman (13.4%, 4.4%, and 8.9% respectively). Relation testing gave in-significant result (Table 4.8).

**Table (4.8): Correlation between Khartoum state block and the species of the detected parasite:**

<b>Block</b>	<b>Result</b>				<b>Total</b>
	<i>E.histolytica</i>	<i>G.lamblia</i>	Mix	None	
Khartoum	11.1% (5)	6.7% (3)	6.7% (3)	8.9%(4)	33.3% (15)
Bahri	15.6%(7)	2.2%(1)	2.2%(1)	13.3% (6)	33.3% (15)
Omdurman	6.7% (3)	6.7% (3)	2.2%(1)	17.8%(8)	33.3% (15)
<b>Total</b>	33.3% (15)	15.6%(7)	11.1% (5)	40%(18)	100% (45)

P=0.460

*Chapter five*  
*Discussion, conclusion*  
*and recommendations*



## Chapter V

### Discussion, conclusion, and recommendations

#### 5.1 Discussion

This study most probably was the first one that investigated the parasitic contamination of groundnuts, nabag, and tasali presented by street venders in Sudan. This was reflected by the data of concern in-availability. Two - similar to some extent- studies were carried out in Ghana and Nigeria estimated the parasitic contamination in *Cyperus esculentus L* (Tiger nuts) which is a root plant; and founded a significant contamination; *C. parvum* 30%- *A. duodenale* 25%- *S. stercoralis* 22.5%- *C. cayetanensis* 22.5%, *A. lumbricoides* 34%- *T. trichiura* 20%- *S.stercoralis* 20%- and *E.histolytica* 25% respectively (Ayeh-Kumi *et al.*, 2014, Ogban and Ukpong, 2018). In this study; the overall contamination rate was seen in 60% (27) of samples which is considered as a significant rate. This rate was predictable; because venders sell their products un-covered and handled it with bare hands. Contamination is not necessarily to occur at selling stage; it may be happen during: crop growing in the farm, harvesting, storing and transporting, and even at home as reported by Idahosa (2011) and Porter *et al.* (1990). At planting phase the contamination may be result from polluted irrigational water as mentioned by Amoah *et al.* (2007) which be contaminated due to the poor or inappropriate sanitation infra-structure that must cope with the urbanization rate. Nabag was the most contaminated crop (22.2%) followed by groundnut (20%) and finally tasali (17.8%). This perhaps due to the fresh- raw up taking usually without previous washing of nabag which in addition is exposed to the previously mentioned contamination factors especially at the phase of greenness and harvesting; when it fall on the ground for undetermined periods; hence

staying in contact with soil which may be contaminated; in addition to other external contaminants brought by wind, human, or animals.

On the other hand; since groundnut grows under the soil surface (Vara *et al.*, 2015); its contact with soil which may be contaminated itself or due to the polluted irrigational water. In spite of this; the salting and roasting may reduce the contamination level. In comparison; tasali had the lowest contamination rate. This may explained due to: its protected position inside the fruit during growing and harvesting, and the washing, salting, roasting processes before eating it. The detected parasites were represented in two species; *E.histolytica* (44.4%) and *G.lambliia* (26.7%). The most prevalent of both among all crops was *E.histolytica* (groundnut: 17.8%, nabag: 15.6%, and tasali: 11.1%) in comparison to *G.lambliia* (groundnut: 4.4%, nabag: 15.6%, and tasali: 8.9%). The highest rate of *E.histolytica* was notice in the groundnut (44.4%). This finding was in agreement with a Nigerian study on tiger nuts which resemble the groundnut in growth nature that detected *E.histolytica* as the only identified protozoa (25%) (Vara *et al.*, 2015, Ogban and Ukpong, 2018). In fact; the accurate prevalence rates of *E.histolytica* and *G.lambliia* in Khartoum state is unknown; but there are some studies that may give a concise view. For example; studies on school children which revealed that *E.histolytica* and *G.lambliia* were common parasites at: Alhag-yousif area (*G.lambliia*: 46.4% and *E.histolytica*: 15.50%), Elengaz area (*G.lambliia*: 33.4% and *E.histolytica*: 3.6%), and Alkalakla area (*E.histolytica*: 15.5% and *G.lambliia*: 12.5%) (Gabbad and Alawad, 2014, Siddig *et al.*, 2017, and Abdalazim *et al.*, 2019). This finding suggested that; these contaminated crops products may be a major source for acquiring the certain parasitic infections. Between saturated sugar floatation technique which showed (prevalence rate 48.9%) and FECT (prevalence rate

53.3%); the latter was the technique of choice for crops examination (P. value: 0.000). This finding exactly agreed Abdalazim *et al.* (2019) study (P. value: 0.000). Moreover; FECT was also better than saturated sugar floatation technique for detecting both parasites i.e.; using FECT *E. histolytica* prevalence was: 44.2% and *G. lamblia*: 20%; while using sugar floatation technique *E.histolytica* prevalence was: 40% and *G. lamblia*: 11.1%.

## **5.2 Conclusion**

This study concluded that; roasted groundnut, nabag, and tasali which were sold by street vendors at Khartoum state, Sudan were highly contaminated with protozoan parasites.

## **5.3 Recommendations**

- Increasing the sample size and involve other products sold by those vendors.
- Using permanent staining technique in addition to the used.
- In sampling process; include the central markets that distribute crops products to street vendors also; to get knowledge if contamination occurred at the distribution points rather than selling points.
- Collect samples twice; during summer and autumn.
- Trying to scan field soil that grew the crops and compare the results with central markets and street vendor's results to determine the phase at which the contamination had occurred.
- Collection of stool samples and under nail scrapping from each seller to compare these findings with crops examination results.
- Examination of the plant debris layer obtained during FECT procedure for the presence of any parasitic stage.

## References

- **Abdalazim, H., Abd Alla A.B., Elfaki T.E.M., and Saad M.BEA. (2019).** Frequencies of parasite infections among students of primary school in Alkalakla locality, Khartoum, Sudan: a cross-sectional study. *F1000 Research*, **1**: 1729 (<http://doi.org/10.12688/F1000research.20610.1>).
- **Amoah, P., Drechsel P., Abaidoo R.C., and Henseler M. (2007).** Irrigated urban vegetable production in Ghana: microbiological contamination in farms and markets and associated consumer risk groups, *Journal of Water and Health*, **5** (3): 455-466.
- **Asgarpanah, J., and Haghightat E., (2012).** Phytochemistry and pharmacologic properties of *Ziziphus spina christi* (L) wild, *African Journal of Pharmacy and pharmacology*, **6** (31): 2332-2339.
- **Asibuo, JY., Richard A., Osei SK., Hanskofi AD., Seth OD., and Adelaide A., (2008).** Chemical composition of groundnut, *Arachis hypogaea* (L) landraces, *African Journal of Biotechnology*, **7** (13): 2203-2208.
- **Ayeh-Kumi, P.F.,Tetteh-Quarcoo P.B., Duedu1, K.O.,Obeng, A.S., Addo-Osafo,K., Mortu, S., and Asmah, R.H., (2014).** A survey of pathogens associated with *Cyperus esculentus* L (tiger nuts) tubers sold in a Ghanaian city, *BMC Research Notes*, **7**:343.
- **Beshir, A.A., and Babiker S.A. (2009).** The effect of substitution of Groundnut cake by watermelon seed cake (*Citrullus lanatus*) in Ration for lamb fattening in Sudan, *Research Journal of Agriculture and Biological Sciences*, **5** (6): 1130-1142.
- **Betty T, Agbenorhevi J.K., Wireko-Manu F.D., and Ompouma E.I., (2016).** Watermelon seeds as food: nutrient composition,

phytochemical and antioxidant activity, *International Journal of nutrition and food sciences*, **5** (2): 139-144.

- **Cheesebrough, M. (2009)**. District Laboratory Practice in Tropical Countries part 1, 2<sup>nd</sup> edition, Cambridge University Press, New York.
- **Favero, A.P., Santos R.F., Simpson C.E., Valls J.M., and Vello N.A., (2015)**. Successful cross between fungal resistant wild species of *Arachis hypogaea*, *Genetics and Molecular Biology*, **38**(3):353-365.
- **Gabbad, A. E. S., and Elawad M. A. (2014)**. Prevalence of Intestinal Parasite Infection in Primary School Children in Elengaz area, Khartoum, Sudan, *Academic Research International*, **5** (2): 86-90.
- **Garcia, L. S. (2007)**. Diagnostic Medical Parasitology, 5<sup>th</sup> edition, American Society for Microbiology press (ASM press), Washington.
- **Ibraheem, A.A., (2017)**. Using Natural Polyphenol Extracts of Sider (*Ziziphus spina -Christi L.*) Leaves and Seeds as Anti-microbial, *Middle East Journal of Applied Sciences*, **7** (2): 262-271.
- **Idahosa, O.T. (2011)**. PARASITIC CONTAMINATION OF FRESH VEGETABLES SOLD IN JOS MARKETS. *Journal of Medical Research*, **11**(1).
- **Jongbloed, M. (2003)**. The Comprehensive guide to the wild flowers of the United Arab Emirates, Environmental research and wild life development agency (ERWDA).
- **Mohammed, E.A.E., (2005)**. Nutritive Evaluation of watermelon seed (*Citrallus lanatus*) parts and byproducts as ruminant feed, B.sc (Honours) dissertation. University of Khartoum-faculty of animal production.
- **Motamedi, H., Seyyednejad S.M., Hsannejad Z., and Dehghani F., (2014)**. A comparative study on the effects of *Ziziphus spina*

*Christi* alcoholic extracts on growth and structural integrity of bacterial pathogens, *Iranian Journal of Pharmaceutical Sciences*, **10** (2): 1-10.

- **Ogban, E.I., and Ukpong I.G., (2018).** Intestinal Parasites Associated with Tiger Nuts, *Cyperus esculentus L.* in Calabar, Nigeria: Implications for Public Health, *Scholars Academic Journal of Biosciences*, **6** (10): 634-638.
- **Paniker, C. K. (2013).** Paniker's Textbook of Medical Parasitology, 7<sup>th</sup> edition, Jaypee Brothers Medical Publishers (P) Ltd, New Delhi.
- **Porter, J.D., Gaffney C., Heymann D., and Parkin W. (1990).** Food-borne outbreak of *Giardia lamblia*, *American Journal of Public health*, **80**(10): 1259-1266.
- **Rekha, G., and Rose A.L., (2016).** Proximate nutritional analysis of dried watermelon seed, *International Journal of engineering research and general science*, **4** (6): 2091-2730.
- **Saied, A.S., Gebauer J., Hammer K., and Buerkert A., (2008).** *Ziziphus spina Christi (L)* wild a multipurpose fruit tree, *Genetic Resources and Crop Evolution*, **55**: 929-937.
- **Satoskar, A. R. Simon, G. L., Hotez, P. J. and Tsuji, M. (2009).** Medical Parasitology, 1<sup>st</sup> edition, Landes Bioscience, Texas.
- **Shahnazi, M., and Jafari-Sabet M., (2010).** Prevalence of parasitic contamination of raw vegetables in villages of Qazin Province, Iran. *FOODBORNE PATHOGENS AND DISEASES*. **7**(9): 1026-1030, Doi: 10.1089\fpd.2009.0477.
- **Siddig, H.S., Mohammed I.AEG., Mohammed M. NED., and Bashir A.M. (2017).** Prevalence of Intestinal Parasites among Selected group of Primary School Children in Alhag- yousif area, Khartoum, Sudan, *International Journal of Medical Research and*

*Health Sciences*, **6** (8): 125-131. Available online at: [WWW.ijmrhs.com](http://WWW.ijmrhs.com).

- **Tefera, T., Biruksew A., Meckonnen Z., and Eshetu T., (2014).** Parasitic contamination of fruits and vegetables collected from selected local markets of Jimma Town, south west Ethiopia. *Hindawi Publishing Corporation International Scholarly Research Notices*, ID 382715.
- **Torgerson, P.R., Devleesschauwer B., Praet N., Speybreck N., Willingham A.L., et al., (2015).** World Health Organization Estimates of the Global and Regional Disease Burden of 11 Foodborne Parasitic Diseases, 2010: A Data Synthesis. *PLOS Medicine*, **12**(12): e 1001920.
- **Vara, P.V., Kakani V.G., and Upadhyaya H.D (2015).** Growth and Production of Groundnuts. *SOILs, PLANTs GROWTH AND CROP PRODUCTION*, volume 2, Encyclopedia of Life Support Systems (EOLSS).
- **WWW. Google. Com.** Available at: [www.en.m.wikipedia.org/wiki/Khartoum](http://www.en.m.wikipedia.org/wiki/Khartoum), 2015.
- **WWW.Peanut-institute.org**. Available at: [http://www.peanut-institute.org/resources/downloads/fft\\_v13i.pdf](http://www.peanut-institute.org/resources/downloads/fft_v13i.pdf), 2014.
- **Zeibig, E. A. (2013).** Clinical Parasitology-A practical approach, 2<sup>nd</sup> edition, Saunders, an imprint of Elsevier Inc.



## Appendix (1)

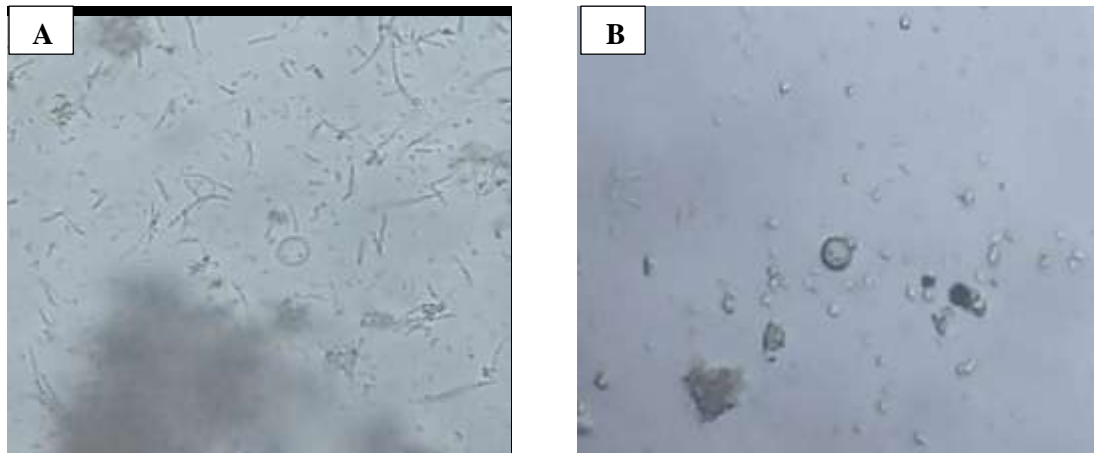


Figure 1: A and B: *E. histolytica* cysts

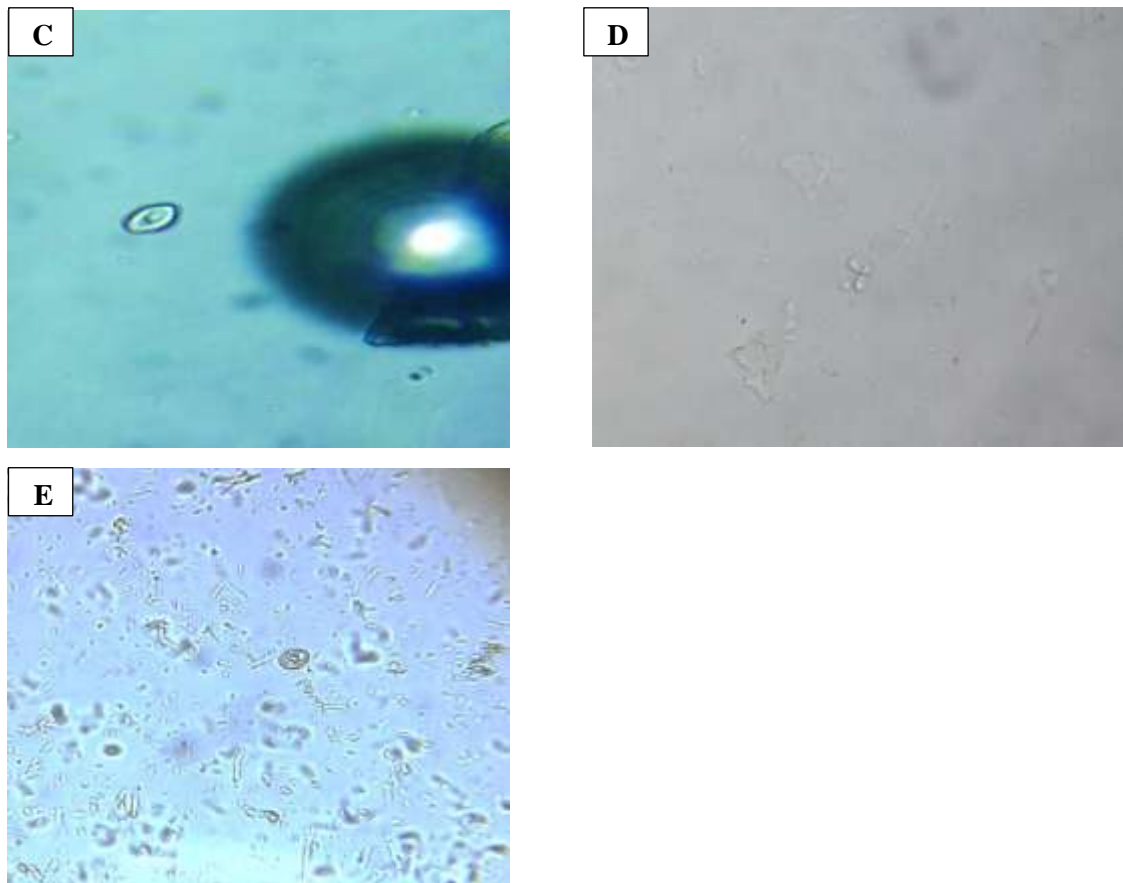


Figure 2: C, D, and E: *G. lamblia* cysts

## Appendix (2)

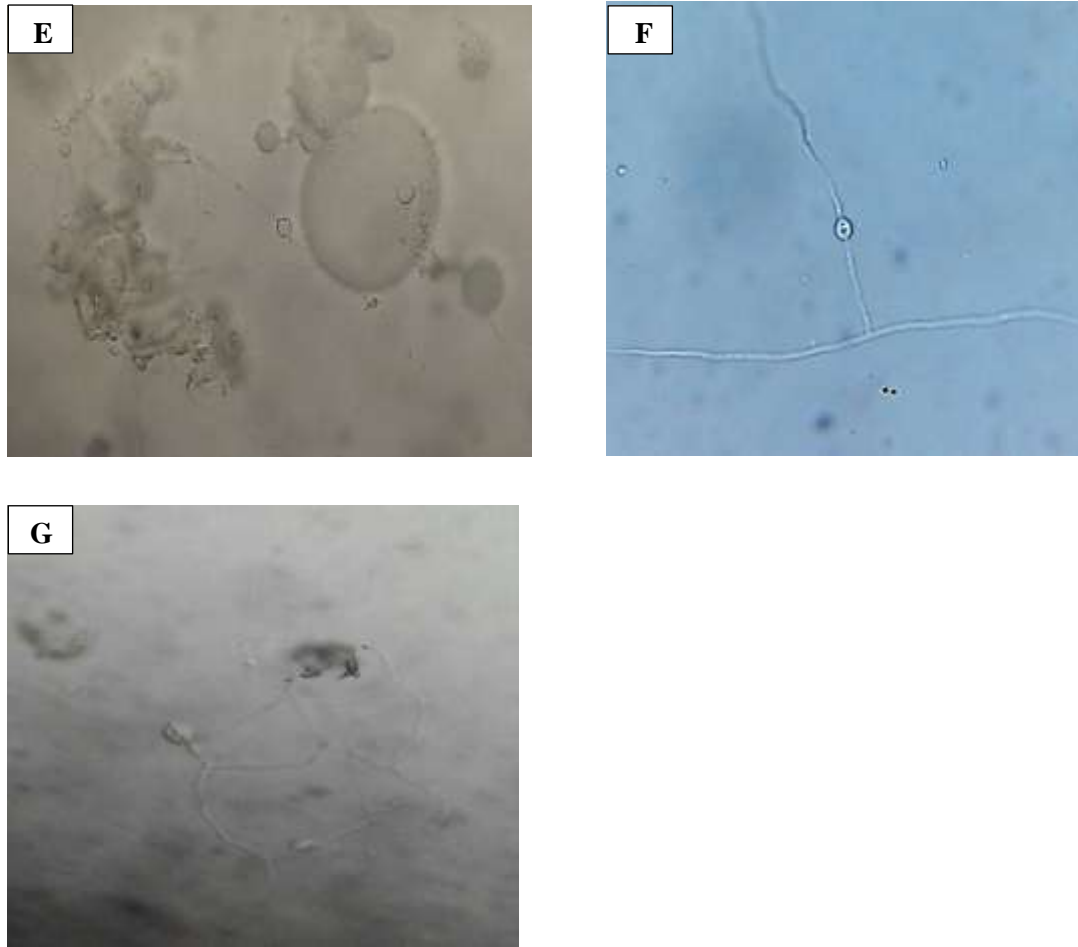


Figure 3: E, F, and G: Fungi




Figure 4: H, I, and J: Nabag, Groundnut, and Tasali