

# Chapter one

## Introduction

### 1.1 Introduction:

Biliary disease presents with some diversity, from no symptoms to a constellation of signs and symptoms of varying severity and combination. Accurate diagnosis, therefore, begins with listening closely to the patient. Reaching an accurate diagnosis is aided by clinical experience and often involves imaging studies.

Biliary system is the organs and ducts that create and store bile and release it into the duodenum (the small intestine). The Biliary system includes the gallbladder and bile ducts inside and outside the liver. It is also known as the Biliary, or bile tract. The Biliarytract, (Biliarytree or Biliarysystem) refers to the liver, gall bladder and bile ducts, and how they work together to make, store and secrete bile ,Bile is secreted by the liver into small ducts that join to form the common hepatic duct. Between meals, secreted bile is stored in the gall bladder. During a meal, the bile is secreted into the duodenum to rid the body of waste stored in the bile as well as aid in the absorptionofdietary fats and oils.

MRI is able to show the bile in the bile ducts from many different angles. Some believe that MRI is about as good a modality for detecting stones in the bile ducts as there is, excluding the much more interventional TranshepaticCholangiogram.

Problems with MRI include limited availability in certain areas, limited cholangiographic skills and experience, and relatively high costs. MRI has no bone or air artifact and virtually all other internal body structures? MRI doesn't use ionizing radiation.

Magnetic resonance (MR) imaging besides being non-invasive has the advantages of allowing detailed evaluation of the pancreatic-biliary tract with a large field of view(FOV), excellent patient tolerance, and three-dimensional(3D) data sets that can be cholangio-pancreatico graphically displayed. Two unique properties of bile that are exploited to produce MRCP images are its relatively high water content & stasis of bile, in comparison with the blood owing through adjacent vessels in the portal tract .

This study is aimed to screen gallbladder of Saudi patient in Najran to assess the gallbladder pathologies and their incidence.

## **1.2 Problem of the study:**

Increase number of patient who complains of Biliary system diseases.

## **1.3 Objectives**

### **1.3.1 General objective:**

To study of Biliary system diseases using Magnetic Resonance Imaging .

### **1.3.2 Specific objectives:**

To correlation between biliary diseases and age.

To correlation between biliary diseases and gender.

To identify the most common types of biliary system diseases appears of MRI images.

To identify the MRI protocols used to identify biliary system pathology.

To evaluate spectrum of findings in cases of biliary disorders on MRCP.

To evaluate role of MRCP in surgical management and outcome of biliary disorders.

### **1-4 Overview of the study:**

This study fall into five chapters:

Chapter 1: which include Introduction, problem of the study, objectives of the Study and general information about the study, Chapter 2: Literature review. (Theoretical back ground and previous study), Chapter 3: which discuss the material and methods. , Chapter 4: which include the result of the study, Chapter 5: include Conclusion, discussion and recommendation.

## Chapter two

### Theoretical Background

#### 2.1 Anatomy of the Biliary Tract:

The right hepatic duct is formed by the intrahepatic union of the dorsocaudal and ventrocranial branches draining the two sectors of the right liver (segments V-V III): the ventrocranial duct is in direct line with the right hepatic duct and crosses in front of the dorsocaudal branch as this arches downwards before reaching the confluence of the two ducts. (Matos C et al 2001)

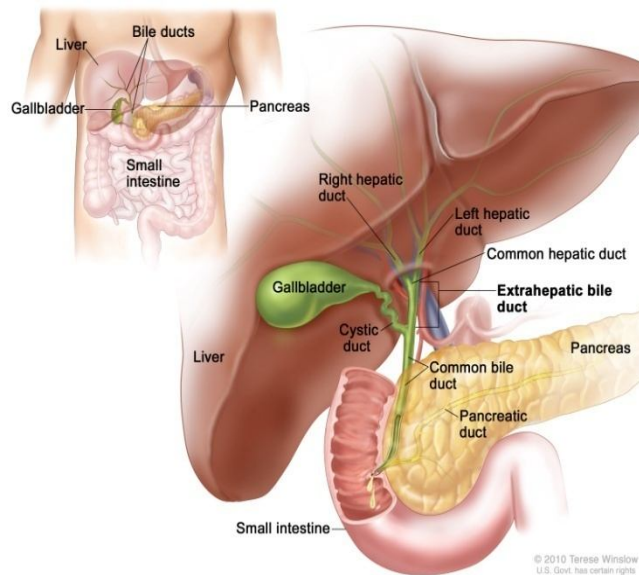


Figure 2-1: shows Anatomy of the extra hepatic bile duct. The extra hepatic bile duct is made up of the common hepatic duct and the common bile duct. Bile is made in the liver and flows through the extra hepatic bile duct to the gallbladder where it is stored. (<http://www.cancer.gov>).

The left hepatic duct, which is formed by medial and lateral branches draining (segments II-IV), is longer than the right hepatic duct. It follows a partial extra hepatic course (of variable length depending on the width of the quadrate lobe) and, therefore, dilates readily in the presence of distal obstructive disease. The extra hepatic portion of the left duct and its segment III branch can be accessed surgically at the hilum by the following the insertion of the round ligament (ligament terse) in the depths of the recesses of Rex. This round ligament' approach is an effective method of bilio-enteric by pass for inoperable cholangiocarcinomam of the extra hepatic ducts' (Matos C et al 2001)

The union of the right and left hepatic ducts is usually extra hepatic (90% within 1.0 cm of liver parenchyma), high up in the portaheptis. The resulting common hepatic duct receives the cystic duct lower down, whereupon it becomes the common bile duct. It is customary, however, in surgical anatomy to use the term common bile duct' or simply 'bile duct' for the entire extra hepatic conduit as it obviates difficulties in nomenclature, especially when there is low insertion of the cystic duct. The junction of the right and left hepatic ducts is also referred to as the hilarbifurcation. Together with the hepatic artery to its left and the portal vein behind, the common bile duct is surrounded by fibrous-tissue known as the glissoniansheath. At the hilum this is thickened and forms a condensation that is often referred to as the hilar plate. If the liver is incised anteriorly and posteriorly (between the hilum and the caudate lobe) to the hilar plate, finger dissection enables the mobilization of the main divisions of the hepatic duct, hepatic artery and portal vein and this maneuver allows inferior displacement and thus access in case o high bile duct strictures. It is also used for segmental resection of the liver. (Matos C et al 2001)

### **2.1.1 Gall bladder and cystic duct:**

The gall bladder is a pear-shaped sac- about 10 cm in length. And is situated on the inferior surface of segment V of the right lobe of liver, it is covered with a layer of peritoneum I that contains many small veins that require coagulation during cholecystectomy. It is customarily divided into the fundus, the body and the neck which leads to the cystic duct. Not infrequently, the neck has an abnormal sacculation, which is referred to as Hartman's pouch. This may become adherent to the surrounding structure of the portahepatis, particularly the common bile duct, seriously obscuring anatomical relationship during dissection of this region (Matos C et al 2001)

The cystic duct runs a variable course from the neck of the gall bladder to join the common hepatic duct. Its mucosa is arranged in a spiral fold or valve (valve of Heister) which often causes difficulties. In Annulations during operative transcystic cholangiography. Although most anatomical textbooks indicate that the cystic duct joins the bile duct along its right margin, several large series of surgical dissections and analyses of operative cholangiograms demonstrate clearly that this arrangement is rare. Much more commonly, the cystic duct enters the bile duct either posteriorly or anteriorly. It may also pursue a spiral or a Parallel course with the bile duct, with the two structures being enclosed in a common fibrous sheath that tends to obscure the exact location of the entry of the cystic duct into the bile duct. The spiral cystic duct runs down and behind the common hepatic duct to enter on its medial aspect. The parallel cystic duct runs parallel to the bile duct for a variable distance before entering it. This is the rarest arrangement and is encountered I n 5-7% of patients. Rarely, the cystic duct joins the right hepatic duct and very infrequently the left duct. (Matos C et al 2001)

### **2.1.2 Common bile duct:**

The bile duct (choledochus) is formed by the union of the right and left hepatic ducts each draining the respective hem-liver. It is joined at available distance along its course by cystic duct. In strict anatomical term, the segment between the hilar bifurcation and the cystic duct is referred to as the common hepatic duct and the junction. From the surgical standpoint, however, it is best to consider it as one structure, which is divisible into the supraduodenal, retro duodenal, intrapancreatic and intraduodenal segment. It serves as a conduit of bile from the liver and gallbladder to the duodenal papilla and in the adult measures 11-12 cm in length with an average diameter of 7 mm, range 4-10 ml. The supraduodenal segment is important surgically because it is the area that is most commonly explored. It lies in the free edge of the hepatoduodenal ligament of the right of the hepatic artery and anterolateral to the portal vein. The retroduodenal segment curves to the right away from the portal vein behind the first part of the duodenum before entering the head of the pancreas. However, in 20% of patients the duct has a partial or complete extra pancreatic course. The trans duodenal segment (also known as the infundibulum) which transverse obliquely the duodenal wall and usually joins the pancreatic duct, opens into the duodenal lumen at the small part of the major duodenal papilla, the lower end of the common bile duct, therefore, deviates to the right before entering the lumen of the duodenum almost at right angles. This is an important practical consideration since forcible probing through this area may perforate the bile duct and result in a hematoma, post-operative pancreatitis, choledochoduodenal fistula or stricture of the lower end of the bile duct (Chang Wh et al 1999)

The main pancreatic duct (Wirsung) joins the poster medial wall of the transduodenal segment of the bile duct to form a common channel in 90/0 of cases. A localized dilatation of the common channel to form an ampulla of water is uncommon (1020%) and in 10% of patients the two ducts open separately into the duodenum. The ventral segment includes the lower 2.5.-3.0 cm of the common bile duct, the distal part of the pancreatic duct, the ampulla or common bile channel and the major duodenal papilla. Theses structure are surrounded by a condensation of circular and longitudinal smooth muscle fibers often referred to as the sphincter of Oddi, although it was Boyden who described the detailed anatomy of the various components of this sphincter complex. (Chang Wh et al 1999)

The inferior sphincter is the strongest component and is also known as the papillary muscular ball. It surrounds the terminations of the bile and pancreatic ducts and the common channel the middle sphincter is the longest and the thinnest of the components and surround the transduodenal and a variable portion of the Trans pancreatic segment of the bile duct and the duct ofWirsung. The superior sphincters consist of localized thickenings of the middle sphincters round the bile and pancreatic ducts at the proximal end of the sphincter complex (Chang Wh et al 1999)

An important variation of the anatomy of the Ventral segment is the condition known as pancreas division, which results from failure of fusion of the ventral and dorsal pancreas during embryological development. The rest of the common bile duct contains few muscle fibers. Its epithelial lining rests on a loose stoma containing elastic fibers, which Disappear with age or disease. Thus “stone impaction, prolonged distension disappears with age or disease. Thus” stone impaction, prolonged distension or cholangitis may



lead to rigidity of the common bile duct and it occurs at its point of entrance into the duodenal wall and this is often indicated by a notch on the Cholangiogram. The diameter of the Trans duodenal papilla varies from 0.5 to 1.5 mm. The commonest site for calculus arrest or impaction is just proximal to the transduodenal segment. (Chang Wh et al 1999)

The major duodenal papilla is situated on the posteromedial aspect of the second part of the duodenum about 7.0-10.0 cm from the pylorus. Its appearance may vary from the usual well-defined papilla with a varying degree of projection to a flattened depression between the mucosal folds. Irrespective of its exact configuration, the major duodenal papilla frequently has a dorsal mucosal fold. The papilla is more easily located by ERCP than by direct inspection during surgical intervention. The minor (accessory) papilla is more proximally situated and assumes clinical importance only in patients with pancreas divisum. (Chang Wh et al 1999)

The activity of the choledochal sphincteric complex is independent of the duodenal musculature but may be influenced by it. Thus, the effect of certain drugs on the choledochal sphincter from their action on the duodenal wall, and duodenal muscular activity has no significant effect on the common bile duct pressure. The choledochal sphincter is an active structure and measure up to 2.5 cm in length. It consists of well-developed longitudinal and circular smooth muscle. Contraction of the longitudinal muscle tends to open the duct lumen, whereas the circular muscle has the opposite effect. These contracted (systolic) and relaxed (diastolic) states of the choledochal sphincter, lead to quite distinct appearance of the lower end of the common bile duct at cholangiography. During contraction, contrast often forms a meniscus with the concavity facing downward simulating a stone (the pseudo calculus phenomenon). (Chang Wh et al 1999)

## **2.2. Physiology:**

### **2.2.1 Hepatobiliary Physiology:**

The liver is the largest and most metabolically active organ in the body. And in ancient times it is functionally interposed between the gut. From which it receives macronutrients and micronutrients, and the other organs to which it supplies energy source in exchange for metabolites that are either incorporated into complex molecules or degraded. Toxic endogenous and exogenous substances (xenobiotic) are detoxified and excreted into the bile or blood stream for disposal through the kidneys. In addition, the liver responsible for the synthesis of specific proteins, e.g. albumin, clotting Factors, immunoglobulin and lipoproteins, and plays a crucial role in bilirubin metabolism (Guibaud L et al 2001)

### **2.2.2 Physiology of the Gallbladder:**

#### **2.2.2.1 Storage:**

The gallbladder acts as a storage vessel for bile produced by the liver. Bile is produced by hepatocytes cells in the liver and passes through the bile ducts to the cystic duct. From the cystic duct, bile is pushed into the gallbladder by peristalsis (muscle contractions that occur in orderly waves). Bile is then slowly concentrated by absorption of water through the walls of the gallbladder. The gallbladder stores this concentrated bile until it is needed to digest the next meal (Guibaud L et al 2001)

### **2.2.2.2 Stimulation:**

Foods rich in proteins or fats are more difficult for the body to digest when compared to carbohydrate-rich foods (see Macronutrients). The walls of the duodenum contain sensory receptors that monitor the chemical makeup of chyme (partially digested food) that passes through the pyloric sphincter into the duodenum. When these cells detect proteins or fats, they respond by producing the hormone cholecystokinin (CCK). CCK enters the bloodstream and travels to the gallbladder where it stimulates the smooth muscle tissue in the walls of the gallbladder (Guibaud L et al 2001)

### **2.2.2.3 Secretion:**

When CCK reaches the gallbladder, it triggers the smooth muscle tissue in the muscularis layer of the gallbladder to contract. The contraction of smooth muscle forces bile out of the gallbladder and into the cystic duct. From the cystic duct, bile enters the common bile duct and flows into the ampulla of Vater, where the bile ducts merge with the pancreatic duct. Bile then flows from the ampulla of Vater into the duodenum where it breaks the fats into smaller masses for easier digestion by the enzyme pancreatic lipase (Guibaud L et al 2001)

## **2.3 Pathology of Biliary tract and pancreatic duct:**

### **2.3.1. Cholelithiasis (Gallstone)**

Gallstone is a crystalline concretion formed within the gallbladder by accretion of bile components. These calculi are formed in the gallbladder but may distally pass into other parts of the biliary tract such as the cystic duct, common bile duct, pancreatic duct or the ampulla of Vater. Rarely, in cases of severe inflammation, gallstones may erode through the gallbladder into adherent bowel potentially causing an obstruction termed gallstone ileus. :(Toouli et al 2000)

Presence of gallstones in the gallbladder may lead to acute cholecystitis, an inflammatory condition characterized by retention of bile in the gallbladder and often secondary infection by intestinal microorganisms, predominantly *Escherichia coli*, *Klebsiella*, *Enterobacter* and *Bacteroides* species. Presence of gallstones in other parts of the biliary tract can cause obstruction of the bile ducts, which can lead to serious conditions such as ascending cholangitis or pancreatitis. Either of these two conditions can be life-threatening and are therefore considered to be medical emergencies. (Toouli et al 2000)

#### **Characteristics and composition :**

Gallstones can vary in size and shape from as small as a grain of sand to as large as a golf ball. (Hanyu 1990) The gallbladder may contain a single large stone or many smaller ones. Pseudoliths, sometimes referred to as sludge, are thick secretions that may be present within the gallbladder, either alone or in conjunction with fully formed gallstones. The clinical presentation is similar to that of Cholelithiasis. The composition of gallstones is affected by age, diet and ethnicity. On the basis of their composition, gallstones can be divided into the following types: (Toouli et al 2000)

### **2.3.1.1. Cholesterol stones:**

Cholesterol stones: vary from light yellow to dark green or brown and are oval, between 2 and 3 cm long, each often having a tiny, dark, central spot. To be classified as such, they must be at least 80% cholesterol by weight (or 70%, according to the Japanese- classification system).(Behar et al 1989)

### **2.3.1.2 Black Pigment stones:**

Pigment stones are small and dark and comprise bilirubin and calcium salts that are found in bile. They contain less than 20% of cholesterol (or 30%, According to the Japanese-classification system). (Behar et al 1989)

### **2.3.1.3 Mixed stones:**

Mixed gallstones typically contain 20–80% cholesterol (or 30–70%, according to the Japanese- classification system). Other common constituents are calcium carbonate, palmitate phosphate, bilirubin and other bile pigments. Because of their calcium content, they are often radiographically visible.(Behar et al 1989)

### **2.3.2 Cholecystitis:**

Cholecystitis is abnormal bile composition and an inflammation of the gallbladder. Cholecystitis usually develops when a person has gallstones, can be large or small, single or multiple, symptomatic or silent .Which are rock-like deposits that form inside the gallbladder. If a gallstone blocks the cystic duct (the outflow from the gallbladder), bile becomes trapped in the gallbladder. Chemicals in the trapped bile or a bacterial infection can then lead to inflammation of the gallbladder (Bolondi et al 1984)

### **2.3.2.1 Acute Cholecystitis:**

Result in necrosis, ulceration, swelling, and edema is not common in children. That causes marked abdominal pain, often with nausea, vomiting, and fever (Bolondi et al 1984)

### **2.3.2.2 Chronic cholecystitis:**

Is more common among elderly persons. Is a lower intensity inflammation of The Gallbladder that lasts a long time and it is multiple episodes of the acute Process. It may be caused by repeat attacks of acute cholecystitis. ChronicCholecystitis may cause intermittent mild abdominal pain or no symptoms atAll. Damage to the walls of the gallbladder leads to a thickened , scarred Gallbladder. Ultimately, the gallbladder can shrink and lose its ability to store and release bile. Gallstones alone can cause episodes of cramps abdominal pain without any infection. This is called Biliary colic (Bolondi et al 1984)

### **2.3.2.3 A calculus cholecystitis:**

Inflammation of the gallbladder without the presence of the stones. The cause of the inflammation is uncertain, but it is a condition mostly seen in patients who are seriously ill and require intensive care.

Conditions that may give rise to Calculus cholecystitis include trauma, burns, sepsis, dehydration, Crohn's disease, mass transfusions, and pediatric biliary malformations. (Gullo et al 1984)

The pathologic potential of ductal calculi consists of the triad: Jaundice, cholangitis and acute gallstone-associated pancreatitis, Ductal calculi can result from migration of gallstones through a patent cystic duct. These are referred to as secondary ductal calculi (cholesterol) or black pigment), as distinct from primary ductal stones, which arise de novo. Within the bile ducts are brown pigment stones. These are associated with biliary tract

colonization by glucuronidase- accreting bacteria, e.g. Escherichia coli, usually in the presence of sub clinical obstruction at the distal end of the common bile duct. Calculi may also form around foreign bodies within the lumen of the common bile duct. These become encrusted with calcium bilirunate. A common example of this nowadays is caused by the international of titanium metal clips used to secure the medial end of the cystic duct stump during laparoscopic cholecystectomy (LC). The exact pathology for this eventuality is not known but pressure necrosis by the clip that included the adjacent wall of the Common bile duct is thought to be involved. The patients present several months after an uneventful surgery with jaundice and / or cholangitis. (L Gullo et al 1984)

Several other clinical terms are used in relation to ductal calculi : Unsuspected, missed or retained, and recurrent. Unsuspected stones are those discovered accidentally during cholecystectomy for symptomatic Gallstone disease when routine intraoperative cholangiography (IOC) is performed. The stones are usually small and floating, and the common bile duct is of normal caliber. The liver function tests are normal, although some patients may have an elevation of the alkaline phosphates that is either missed or attributed to other cause. The estimated incidence of unsuspected stones is 5-10% of patients undergoing cholecystectomy(L Gullo et al 1984)

The terms missed and retained are synonymous and indicate that the intervention (surgical or endoscopic) failed to achieve complete ductal clearance. By custom, ductal calculi that present or are diagnosed within 2 years of the intervention are designated as missed or retained. Most are, in fact, detected much earlier. The insertion of T-tube or cystic duct drainage cannulae after surgical ductal clearance (Open or laparoscopic) permits the

performance of a postoperative tube cholangiogram as a check for complete ductal clearance' (L Gullo et al 1984)

Recurrent ductal stones present at least 2 years after the first intervention. These tend to be primary ductal stone (brown pigment) and are almost always associated with significant dilatation of the Common bile duct, indicating a fibrotic or dysfunctional terminal segment of the common bile duct. There is a mistaken belief that endoscopic sphincterotomy is sufficient to overcome this obstruction. This is not the case as the Vaterian segment (containing the entire choledochal sphincter complex) cannot be completely divided by an endoscopic sphincterotomy (essentially a papillotomy), however generous. If fit, these patients are best managed by ductal clearance and an internal surgical drainage procedure, most commonly a choledochoduodenostomy, which can be open or laparoscopic' (L Gullo et al 1984)

#### **2.3.4 Carcinoma of the gallbladder:**

This is the most common malignancy of the biliary tract and accounts for 3.4% of all gastrointestinal malignancies. It is, a disease of old age and carries a uniformly poor prognosis. Gallstones are present in 75.90% of cases. The clinical presentation is with jaundice and 01' accrued cholecystitis' (L Gullo et al 1984)

#### **2.3.5 Cholangiocarcinomas:**

These tumors of the Biliary tract, all of which present with jaundice, usually occur in the elderly but some occurs as early as the fifth decade. They are classified by the anatomical site of origin: Intrahepatic: From minor hepatic ducts. Often multicentre and usually classified with primary liver tumors.



Proximal: From right and left hepatic ducts, hilal confluence and proximal common hepatic ducts. A/it/die: From the distal common hepatic ducts, cystic duct and its confluence with common bile duct. Distal: Include with periampullary tumours. Most of these tumors are of the cirrhosis variety and some can be very cellular, such that histological confirmation may be difficult. Radio logically; they give rise to a 'stricture' with proximal dilatation' (L Gullo et al 1984) .

### **2.3.6 Benign bile duct strictures:**

Most benign bile duct strictures are the result of iatrogenic injury during cholecystectomy. The constriction and compression of the intrapancreatic segment of the common bile duct by the pseudotumour of chronic pancreatitis can result in jaundice complicates the course of this disease in some patients' (L Gullo et al 1984)

### **2.3.7 Malignant Jaundice:**

This term is used to jaundice due to malignant large bile duct obstruction, e.g. biliary and pancreatic cancer, or jaundice occurring in association with hepatic malignancy, which can be primary (hepatocellular carcinoma) or secondary from a primary in another site. The presence of jaundice in association with liver tumors indicates extensive involvement of the liver parenchyma;, with the patient being incurable and unlikely to benefit from any form of treatment. Undoubtedly, surgical treatment and chemotherapy are contraindicated malignancy in jaundiced patients who harbor hepatic' (L Gullo et al 1984)

### **2.3.8 Biliary obstruction:**

A Biliary obstruction is a blockage of the bile ducts. The bile ducts carry bile from the liver and gallbladder through the pancreas to the duodenum, which is a part of the small intestine. Bile is a dark-green or yellowish-brown fluid secreted by the liver to digest fats. After you eat, the gallbladder releases bile to help in digestion and fat absorption. Bile also helps clear the liver of waste products; obstruction of any of these bile ducts is referred to as a biliary obstruction. Many of the conditions related to Biliary obstructions can be treated successfully. However, if the blockage remains untreated for a long time, it can lead to life-threatening diseases of the liver. (NIDDK 2013)

#### **2.3.8.1 Types of bile ducts :**

You have several types of bile ducts. The two types of bile ducts in the liver are intrahepatic and extra hepatic ducts. Intrahepatic ducts: Intrahepatic ducts are a system of smaller tubes within the liver that collect and transport bile to the extra hepatic ducts. Extra hepatic ducts: The extra hepatic ducts begin as two parts, one on the right of the liver and the other on the left. As they descend from the liver, they unite to form the common hepatic duct. This runs directly toward the small intestine. The Biliary duct, or the duct from the gallbladder, also opens into the common hepatic duct. The bile duct from this point onward is known as the common bile duct or choledochus. Before emptying into the small intestine, the common bile duct passes through the pancreas (NIDDK 2013)

### **2.3.9 Biliary colic:**

Also known as a gallbladder attack or gallstone attack is when pain occurs due to a gallstone temporarily blocking the bile duct. Typically, the pain is in the right upper part of the abdomen, and it can radiate to the shoulder. Pain usually lasts from one to a few hours. Often, it occurs after eating a heavy meal, or during the night. Repeated attacks are common. (NIDDK 2013)

Gallstone formation occurs from the precipitation of crystals that aggregate to form stones. The most common form is cholesterol gallstones. Other forms include calcium, bilirubin, pigment, and mixed gallstones. Other conditions that produce similar symptoms include appendicitis, stomach ulcers, pancreatitis, and gastro esophageal reflux disease. (Ansaloni L et al 2016)

### **2.3.10 Gallbladder cancer:**

Is a relatively uncommon cancer. It has peculiar geographical distribution being common in central and South America, central and eastern Europe, Japan and northern India; it is also common in certain ethnic groups e.g. Native American Indians and Hispanics. If it is diagnosed early enough, it can be cured by removing the gallbladder, part of the liver and associated lymph nodes. Most often it is found after symptoms such as abdominal pain, jaundice and vomiting occur, and it has spread to other organs such as the liver. It is a rare cancer that is thought to be related to gallstones building up, which also can lead to calcification of the gallbladder, a condition known as porcelain gallbladder. Porcelain gallbladder is also rare. Some studies indicate that people with porcelain gallbladder have a high risk of

developing gallbladder cancer, but other studies question this. The outlook is poor for recovery if the cancer is found after symptoms have started to occur, with a 5-year survival rate close to 3%. (Kapoor et al 2003)

### **2.3.11 Jaundice:**

Jaundice of the skin caused by pancreatic cancer  
Specialty Gastroenterology, hepatology, and general surgery. Symptoms Yellowish coloration of skin and whites of the eyes, purities Causes High bilirubin levels Diagnostic method Blood bilirubin, liver panel Differential diagnosis Carotenemia, taking rifampin Treatment Based on the underlying cause  
Jaundice, also known as icterus, is a yellowish or greenish pigmentation of the skin and whites of the eyes due to high bilirubin levels. It is commonly associated with itchiness. The feces may be pale and the urine dark. Jaundice in babies occurs in over half in the first week following birth and in most is not a problem. If bilirubin levels in babies are very high for too long, a type of brain damage, known as kernicterus, may occur. (Bassari et al 2015)

Causes of jaundice vary from non-serious to potentially fatal. Levels of bilirubin in blood are normally below 1.0 mg/dL (17  $\mu\text{mol/L}$ ) and levels over 2–3 mg/dL (34–51  $\mu\text{mol/L}$ ) typically results in jaundice. High bilirubin is divided into two types: unconjugated (indirect) and conjugated (direct) Conjugated bilirubin can be confirmed by finding bilirubin in the urine. Other conditions that can cause yellowish skin but are not jaundice include carotenemia from eating large amounts of certain foods and medications like rifampin high unconjugated bilirubin may be due to excess red blood cell breakdown, large bruises, genetic conditions such as Gilbert's syndrome, not eating for a prolonged period of time, newborn jaundice, or thyroid problems. High conjugated bilirubin may be due to liver diseases such as

cirrhosis or hepatitis, infections, medications, or blockage of the bile duct. In the developed world, the cause is more often blockage of the bile duct or medications while in the developing world, it is more often infections such as viral hepatitis, leptospirosis, schistosomiasis, or malaria .Blockage of the bile duct may occur due to gallstones, cancer, or pancreatitis Medical imaging such as ultrasound is useful for detecting bile duct blockage(Roger Jones 2004)

Treatment of jaundice is typically determined by the underlying causeIf a bile duct blockage is present, surgery is typically required; otherwise, management is medical management may involve treating infectious causes and stopping medication that could be contributing Among newborns, depending on age and prematurity, a bilirubin greater than 4–21 mg/dL (68–360  $\mu\text{mol/L}$ ) may be treated with phototherapy or exchanged transfusion .The itchiness may be helped by draining the gallbladder or ursodeoxycholic acidThe word jaundice is from the French jaunisse, meaning "yellow disease" (Fred F et al 2014)

### **2.3.12 Lesion:**

lesion is any abnormal damage or change in the tissue of an organism, usually caused by disease or trauma. Lesion is derived from the Latin laesio "injury" Lesions may occur in plants as well as animals (MwdicineNet2016)

#### **2.3.12.1 Types:**

There is no designated classification or naming convention for lesions. Because the definition of a lesion is so broad, the varieties of lesions are virtually endless. Although most frequently found in the mouth, on the skin, and in the brain, or anywhere where a tumor may occur,[citation needed] lesions can occur anywhere in the body that comprises soft tissue or osseous

matter. Generally, lesions may be classified by their patterns, their sizes, their locations, or their causes. Lesions are sometimes also named after the person who discovered them. Some lesions have specialized names, such as Ghon lesions in the lungs of tuberculosis victims, which is named after the lesion's discoverer the characteristic skin lesions of a vermicelli zoster virus (VZV) infection are called chickenpox. Lesions of the teeth are usually called dental caries.(MedicineNet2016)

#### **2.3.12.2 Location:**

Lesions are often classified by their tissue types or locations. For example, a "skin lesion" or a "brain lesion" are named for the tissue where they are found. If there is an added significance to regions within the tissue - such as in neural injuries where different locations correspond to different neurological deficits - they are further classified by location. For example, a lesion in the central nervous system is called a central lesion, and a lesion in the peripheral nervous system is called a peripheral lesion. A myocardial lesion results from damage to the heart muscle, and a coronary lesion is a subtype that describes a lesion in the coronary arteries. Coronary lesions are then further classified according to the side of the heart that is affected and the diameter of the artery in which they form. (Farooq et al 2011)

#### **2.3.12.3 Cause and behavior:**

If a lesion is caused by a tumor it can be classified as malignant or benign after analysis of a biopsy. A benign lesion that is evolving into a malignant lesion is called "pre-malignant." Cancerous lesions are sometimes classified by their growth kinetics, such as the Lodwick classification, which characterizes classes of bone lesions. Another type of lesion is excitotoxic lesions, which can be caused by excitatory amino acids like

kainic acid, which kill neurons through over-stimulation. (Stephen M et al 1992).

#### **2.3.12.4 Size and shape:**

Lesion size may be specified as gross or histologic depending on whether they are visible to the unaided eye or require a microscope to see. A space-occupying lesion, as the name suggests, has a recognizable volume and may impinge on nearby structures, whereas a non space-occupying lesion is simply a hole in the tissue, e.g. a small area of the brain that has turned to fluid following a stroke . Lesions may also be classified by the shape they form, as is the case with many ulcers, which can have a bullseye or 'target' appearance. A coin lesion is identifiable in an X-ray as appearing like a coin sitting on the chest of the patient. (Stephen M et al 1992).

#### **2.3.13Cyst:**

A cyst is a closed sac, having a distinct membrane and division compared with the nearby tissue. Hence, it is a cluster of cells that has grouped together to form a sac (not unlike the manner in which water molecules group together, forming a bubble); however, the distinguishing aspect of a cyst is that the cells forming the "shell" of such a sac are distinctly abnormal (in both appearance and behavior) when compared with all surrounding cells for that given location. It may contain air, fluids, or semi-solid material. A collection of pus is called an abscess, not a cyst. Once formed, sometimes a cyst may resolve on its own. When a cyst fails to resolve, it may need to be removed surgically, but that would depend upon its type and location.(ZadikY et al 2011)

Cancer-related cysts are formed as a defense mechanism for the body, following the development of mutations that lead to an uncontrolled cellular division. Once that mutation has occurred, the affected cells divide

incessantly (and become known as cancerous), forming a tumor. The body encapsulates those cells to try to prevent them from continuing their division and to try to contain the tumor, which becomes known as a cyst. That said, the cancerous cells still may mutate further and gain the ability to form their own blood vessels, from which they receive nourishment before being contained. Once that happens, the capsule becomes useless and the tumor may advance from benign to a cancer. Some cysts are neoplastic and thus, are called cystic tumors; many types are not neoplastic. Some are dysplastic or met plastic. Pseudo cysts are similar to cysts (having a sac filled with fluid), but lack an epithelial lining. (GreenholzSK et al 1997)

#### **2.3.14 Pancreatic and ability malignancy:**

The clinical picture of both pancreatic and biliary cancer is dominated by jaundice (large bile duct obstruction) and itching. In pancreatic ductal Aden carcinoma weight loss is also an important clinical feature, as is recent onset of diabetes (Matos C et al 2001)

#### **2.3.15 pancreatic cancer:**

It is important to distinguish between pancreatic Aden carcinoma (head, body, tail) and periampullary tumours because of their vastly different Prognosis. Food contaminated with aflatoxins produced by the fungus *Aspergillus flavus* has been incriminated in some cases. There is also a high incidence of the disease in patients with certain familial/congenital disorders such as antitrypsin deficiency and tyrosinemia. The fibrolumellar variant of the disease is encountered predominantly in young patients without cirrhosis and carries a good prognosis after complete resection. The symptoms include pain in the right hypochondrium, hepatic enlargement and ascites. The tumor gives rise to systemic manifestations. These include



polycythaemia, carcinoid syndrome, hypoglycemia and hypocalcaemia. Raised  $\alpha$ -fetoprotein is present in 60-70% of cases. (Matos C et al 2011)

### **2.3.16 Pancreatitis:**

Is inflammation of the pancreas? The pancreas is a large organ behind the stomach that produces digestive enzymes and a number of hormones. There are two main types, acute pancreatitis and chronic pancreatitis. Signs and symptoms of pancreatitis include pain in the upper abdomen, nausea and vomiting. The pain often goes into the back and is usually severe. In acute pancreatitis a fever may occur and symptoms typically resolve in a few days. In chronic pancreatitis weight loss, fatty stool, and diarrhea may occur. Complications may include infection, bleeding, diabetes mellitus, or problems with other organs (Matos C et al 2011)

The most common causes of acute pancreatitis are gallstones and heavy alcohol use. Other causes include direct trauma, certain medications, infections such as mumps, and tumors among others. Chronic pancreatitis may develop as a result of acute pancreatitis. It is most commonly due to many years of heavy alcohol use. Other causes include high levels of blood fats, high blood calcium, some medications, and certain genetic disorders such as cystic fibrosis among others. Smoking increases the risk of both acute and chronic pancreatitis. Diagnosis of acute pancreatitis is based on a threefold increase in the blood of either amylase or lipase. In chronic pancreatitis these tests may be normal. Medical imaging such as ultrasound and CT scan may also be useful (Matos C et al 2011)

## **2.4 Imaging of Biliary system:**

### **2.4.1 Plain abdominal radiography:**

The plain abdominal film is rarely used in the diagnosis of gall stones in the elective situation as only 10% of gall stones are radio- opaque. However, a plain film of the abdomen can provide useful diagnostic information in the acute situation. It may demonstrate gas in the biliary tract in patients with bilio-enteric fistulas. The stones itself rarely visualized in the film. Also plain can provide valuable diagnostic information of emphysematous cholecystitis. Finally calcification within the gall bladder wall which is established risk factor for carcinoma of the gall bladder, is best detected by a plain abdominal a film' (Taylor ACF et al 2002)

### **2.4.2 Endoscopic retrograde cholangiopancreattography (ERCP):**

ERCP and PTC should not be seen as competitors but as allies in evaluation of the biliary tract. Advantages of ERCP are that both the biliary and pancreatic ducts studied, and it ALLOWS direct inspection and biopsy of the papilla and duodenum and therapeutic procedures of sphinctertomy and stone extraction. As with PTC a diagnostic procedure can become a therapeutic one with sent placement and relief of jaundice. In patient with obliterativecholangiopathies, such as sclerosing cholangitis or with biliary hyperplasia, pacification on the biliary tree may be technically easier by a retrograde approach, conversely if there has been previous sugary with a hepaticojejunostomy or if there is duodenal obstruction from a pancreatic carcinoma, then there is no access for an endoscopic examination. This illustrates the importance of a Biliary team radiologist, endoscopist and

hepato-biliary surgeon matching the need of the patient to local expertise and availability (Taylor ACF et al 2002)

### **2.4.3 Magnetic Resonance image(MRI) and MagneticCholangiopancreatography(MRCP):**

#### **2.4.3.1 Physics:**

Magnetic resonance Cholangiopancreatography (MRCP) is a medical imaging technique, which uses magnetic resonance to visualize the Biliary tree and pancreatic ducts in a non-invasive way. Though several variations of this technique have been developed in the recent years, they all share the use of a heavily T2W pulse sequence, which selectively displays static or show –moving fluid-filled structures as high intensity areas. The recent development of many the three dimensional (3D) sequences has substantially enhanced the quality of the MRCP images. Likewise, the introduction of hepatobiliary contrast media and secretion has enabled functional assessment of biliary excretion and the exocrine pancreas, respectively. In this article, we present new MRCP. In addition, we discuss commonly imaged biliary and pancreatic duct pathologies, including congenital anomalies, obstruction, trauma and tumor. When patients have suspected biliary or pancreatic disease, ultrasound imaging is the traditional screening technique. However, ultrasound is limited in its ability to image abnormalities in the biliary and pancreatic ductal systems and further evaluation may be necessary with either endoscopic retrograde cholangiopancreatography (ERCP) or MRCP.(ASRT)

ERCP is a minimally invasive procedure that combines endoscopy with the injection of iodinated contrast agent into the biliary and pancreatic

ducts. ERCP has the advantage of combining diagnosis with intervention. In addition, manometry can be performed and the ampulla can be directly visualized. However, ERCP carries a small but significant risk of complications, including pancreatitis, hemorrhage, and perforation. At MGH, the complication rate is 1-2% significantly lower than the national average. In addition; ERCP may be difficult in patients with post-surgical anastigmatic complications. MRCP is a less costly, non-invasive, and sensitive technique for evaluating the biliary and pancreatic duct systems. In MRCP, multilane images are obtained parallel to the orientation of the biliary tree, using a T2-weighted MR sequence that is sensitive to static fluid without the need for exogenous contrast agents. Fluid in the ducts appears bright against the darker tissue. Image post-processing (maximal intensity projection) is used to make multi-dimensional images of the entire biliary tree and the pancreatic ducts. Although MRCP images have somewhat lower resolution than ERCP, MRCP shows the ducts in their natural, non-distended state and can easily be combined with MRI for the surrounding viscera (AOAMC)

MRCP can diagnose the presence of the bile duct obstruction and the level of obstruction in most cases. Biliary calculi smaller than 6mm can be missed although 2 mm calculi can be seen in some cases. Primary sclerosing cholangitis affects the biliary ducts. Benign and malignant causes of biliary dilatation can be differentiated and MRCP can be coupled with imaging of the adjacent viscera. Malignant neoplasms and metastases can be detected and evaluated. MRCP has an advantage over ERCP for the detection of cholangiocarcinoma since there is a risk of sepsis following ERCP. Post-operative bile-duct injuries and anastigmatic leaks can be readily detected

with MRCP and it is suitable for assessment of the biliary tree after orthotopic liver transplantation. In patients with recurrent pancreatitis, MRCP can be performed to be used to evaluate parenchyma changes due to pancreatitis or to detect pancreatic cancer. Examine diseases of the liver, gallbladder, bile ducts, pancreas and pancreatic duct. These may include tumors, stones, inflammation or infection. Evaluate patients with pancreatitis to detect the underlying cause. In patients with pancreatitis, an MRCP may be performed using a medication called Secretion to assess for long term scarring and to determine the amount of healthy pancreatic function and secretions. Help to diagnose unexplained abdominal pain. Provide a less invasive alternative to endoscopic retrograde cholangiopancreatography (ERCP). ERCP is a diagnostic procedure that combines endoscopy, which uses an illuminated optical instrument to examine inside the body, with iodinated contrast injection and x-ray images. (ASRT) .

#### **2.4.3.2 Equipment:**

The traditional MRI unit is a large cylinder-shaped tube surrounded by a circular magnet. You will lie on a moveable examination table that slides into the center of the magnet. Some MRI units, called short-bore systems, are designed so that the magnet does not completely surround you. Some newer MRI machines have a larger diameter bore which can be more comfortable for larger size patients or patients with claustrophobia. Other MRI machines are open on the sides (open MRI). Open units are especially helpful for examining larger patients or those with claustrophobia. Newer open MRI units provide very high quality images for many types of exams. Older open MRI units may not provide this same image quality. Certain

types of exams cannot be performed using open MRI. For more information, consult your radiologist. The computer workstation that processes the imaging information is located in a separate room from the scanner (ASRT)

#### **2.4.3.3 Patient Preparation:**

You may be asked to wear a gown during the exam or you may be allowed to wear your own clothing if it is loose-fitting and has no metal fasteners. Guidelines about eating and drinking before an MRI exam vary at different facilities. Usually, you will be instructed not to eat or drink anything for several hours before your procedure. Because your procedure may require use of contrast material that is swallowed or injected into your bloodstream, the radiologist or technologist may ask if you have allergies of any kind, including allergies to food or drugs, hay fever, hives or allergic asthma. However, the contrast material used for an MRI exam is based on gadolinium and does not contain iodine. A gadolinium contrast agent is less likely to cause an allergic reaction compared to the iodinated contrast agents used in CT scanning. The radiologist should also know if you have any serious health problems and what surgeries you have undergone. Some conditions, such as kidney disease, may prevent you from having an MRI with contrast material<sup>(ASRT)</sup>

Women should always inform their physician or technologist if there is any possibility that they are pregnant. MRI has been used for scanning patients since the 1980s with no reports of any ill effects on pregnant women or their unborn babies. However, because the unborn baby will be in a strong magnetic field, pregnant women should not have this exam in the first three to four months of pregnancy unless the potential benefit from the MRI exam is assumed to outweigh the potential risks. Pregnant women should not

receive injections of gadolinium contrast material except when absolutely necessary for medical treatment. (ASRT)

If you have claustrophobia (fear of enclosed spaces) or anxiety, you may want to ask your physician for a prescription for a mild sedative prior to your scheduled examination. Jewelry and other accessories should be left at home, if possible, or removed prior to the MRI scan. Because they can interfere with the magnetic field of the MRI unit, metal and electronic items are not allowed in the exam room. In addition to affecting the MRI images, these objects can become projectiles within the MRI scanner room and may cause you and/or others nearby harm. These items include: jewelry, watches, credit cards and hearing aids, all of which can be damaged pins, hairpins, metal zippers and similar metallic items, which can distort MRI images , removable dental work, pens, pocket knives, eyeglasses and body piercings. In most cases, an MRI exam is safe for patients with metal implants, except for a few types. People with the following implants cannot be scanned and should not enter the MRI scanning area: cochlear (ear) implant, some types of clips used for brain aneurysms, some types of metal coils placed within blood vessels, nearly all cardiac defibrillators and pacemakers .(ASRT)

You should tell the technologist if you have medical or electronic devices in your body. These objects may interfere with the exam or potentially pose a risk, depending on their nature and the strength of the MRI magnet. Many implanted devices will have a pamphlet explaining the MRI risks for that particular device. If you have the pamphlet, it is useful to bring that to the attention of the scheduler before the exam and bring it to your exam in case the radiologist or technologist has any questions. Some implanted devices require a short period of time after placement (usually six weeks) before

being safe for MRI examinations. Examples include but are not limited to: artificial heart valves, implanted drug infusion ports, artificial limbs or metallic joint prostheses, implanted nerve stimulators, metal pins, screws, plates, stents or surgical staples. If there is any question of their presence, an x-ray may be taken to detect and identify any metal objects. In general, metal objects used in orthopedic surgery pose no risk during MRI. However, a recently placed artificial joint may require the use of another imaging procedure. (ASRT)

Patients who might have metal objects in certain parts of their bodies may also require an x-ray prior to an MRI. You should notify the technologist or radiologist of any shrapnel, bullets, or other pieces of metal that may be present in your body due to prior accidents. Foreign bodies near and especially lodged in the eyes are particularly important because they may move during the scan, possibly causing blindness. Dyes used in tattoos may contain iron and could heat up during an MRI scan, but this is rare. Tooth fillings and braces usually are not affected by the magnetic field, but they may distort images of the facial area or brain, so you should let the radiologist know about them. Your child may need to be sedated in order to hold still adequately during the procedure. If this is the case, you will be given instructions for your child about not eating or drinking several hours prior to sedation and the examination. For the safety of your child during the sedation, it is important that you fully understand and follow any instructions that have been given. After the procedure there will be a recovery period from the sedation. Your child will be discharged when the nurses and physicians believe he/she is sufficiently awake to be safely sent home. (ASRT)



#### **2.4.3.4 Procedure:**

Unlike conventional x-ray examinations and computed tomography (CT) scans, MRI does not utilize ionizing radiation. Instead, radiofrequency pulses re-align hydrogen atoms that naturally exist within the body. This does not cause any chemical changes in the tissues. As the hydrogen atoms return to their usual alignment, they emit different amounts of energy depending on the type of body tissue they are in. The MR scanner captures this energy and creates a picture of the tissues scanned based on this information. The magnetic field is produced by passing an electric current through wire coils in most MRI units. Other coils, located in the machine and in some cases, placed around the part of the body being imaged, send and receive radio waves, producing signals that are detected by the coils. The electric current does not come in contact with the patient. A computer then processes the signals and generates a series of images, each of which shows a thin slice of the body. The images can then be studied from different angles by the interpreting radiologist. Frequently, the differentiation of abnormal (diseased) tissue from normal tissues is better with MRI than with other imaging modalities such as x-ray, CT and ultrasound. MRI examinations may be performed on outpatients or inpatients.<sup>(ASRT)</sup>

You will be positioned on the moveable examination table. Straps and bolsters may be used to help you stay still and maintain the correct position during imaging. Devices that contain coils capable of sending and receiving radio waves may be placed around or adjacent to the area of the body being studied. If a contrast material will be used in the MRI exam, a physician, nurse or technologist will insert an intravenous (IV) catheter, also known as an IV line, into a vein in your hand or arm. A saline solution may be used to

inject the contrast material. The solution will drip through the IV to prevent blockage of the IV catheter until the contrast material is injected.

You will be placed into the magnet of the MRI unit and the radiologist and technologist will perform the examination while working at a computer outside of the room. If a contrast material is used during the examination, it will be injected into the intravenous line (IV) after an initial series of scans. Additional series of images will be taken during or following the injection. The actual MRCP exam takes approximately 10-15 minutes, but it is often performed with a standard MRI of the abdomen, which may last approximately 30 minutes and involves the use of contrast material. In this case, the entire examination is usually completed within 45 minutes.

### **What will I experience during and after the procedure?**

Most MRI exams are painless. However, some patients find it uncomfortable to remain still during MR imaging. Others experience a sense of being closed-in (claustrophobia) while in the MRI scanner. Therefore, sedation can be arranged for those patients who anticipate anxiety, but fewer than one in 20 require medication. If contrast material is used, there may be brief discomfort during initial placement of the intravenous catheter line. The oral contrast used at some institutions may have an unpleasant taste and cause temporary fullness, but most patients usually tolerate it well.

It is normal for the area of your body being imaged to feel slightly warm, but if it bothers you, notify the radiologist or technologist. It is important that you remain perfectly still while the images are being obtained, which is typically only a few seconds to a few minutes at a time. You will know when images are being recorded because you will hear and feel loud tapping or thumping sounds when the coils that generate the radiofrequency pulses

are activated. Some centers provide earplugs, while others use headphones to reduce the intensity of the sounds made by the MRI machine. You may be able to relax between imaging sequences, but will be asked to maintain your position without movement as much as possible. (ASRT)

You will usually be alone in the exam room during the MRI procedure. However, the technologist will be able to see, hear and speak with you at all times using a two-way intercom. Many MRI centers allow a friend or parent to stay in the room as long as they are also screened for safety in the magnetic environment. Children will be given appropriately sized earplugs or headphones during the exam. MRI scanners are air-conditioned and well-lit. Music may be played through the headphones to help you pass the time. In some cases, intravenous injection of contrast material may be administered before the images are obtained. The intravenous needle may cause you some discomfort when it is inserted and you may experience some bruising. There is also a very small chance of irritation of your skin at the site of the IV tube insertion. Some patients may sense a temporary metallic taste in their mouth after the contrast injection. If you do not require sedation, no recovery period is necessary. You may resume your usual activities and normal diet immediately after the exam. On very rare occasions, a few patients experience side effects from the contrast material, including nausea, headache and pain at the site of injection. Similarly, patients are very rarely allergic to the contrast material and experience hives, itchy eyes or other reactions. If you experience allergic symptoms, notify the technologist. A radiologist or other physician will be available for immediate assistance. (ASRT)

## **Who interprets the results and how do I get them?**

A radiologist, a physician specifically trained to supervise and interpret radiology examinations, will analyze the images and send a signed report to your primary care or referring physician, who will share the results with you.

### **2.4.3.5. Benefits**

MRI is a noninvasive imaging technique that does not involve exposure to ionizing radiation.

MRI can provide detailed images of the soft-tissue structures of the body—such as the heart, liver, pancreas and many other organs. This detail makes MRI an invaluable tool in early diagnosis and evaluation of cancer.

MRI has proven valuable in diagnosing a broad range of conditions, including heart and vascular disease, stroke, and joint and musculoskeletal disorders.

MRI can help physicians evaluate both the structure of an organ and how it is working.

MRI enables the discovery of abnormalities that might be obscured by bone with other imaging methods.

The contrast material used in MRI exams is less likely to produce an allergic reaction than the iodine-based contrast materials used for conventional x-rays and CT scanning.

MRCP can produce images comparable to those obtained by a more invasive exam called endoscopic retrograde Cholangiopancreatography (ERCP) without its associated risks including pancreatitis, or inflammation of the pancreas, perforation of pancreatic and bile ducts and bowel, and the risks for intravenous sedation required for ERCP.

#### **2.4.3.6. Risks**

The MRI examination poses almost no risk to the average patient when appropriate safety guidelines are followed.

If sedation is used, there are risks of excessive sedation. However, the technologist or nurse will monitor your vital signs to minimize this risk.

Although the strong magnetic field is not harmful in itself, implanted medical devices that contain metal may malfunction or cause problems during an MRI exam.

Nephrogenic systemic fibrosis is currently a recognized, but rare, complication of MRI believed to be caused by the injection of high doses of gadolinium-based contrast material in patients with very poor kidney function. Careful assessment of kidney function before considering a contrast injection minimizes the risk of this very rare complication.

There is a very slight risk of an allergic reaction if contrast material is injected. Such reactions are usually mild and easily controlled by medication. If you experience allergic symptoms, a radiologist or other physician will be available for immediate assistance.

Reaction to the oral contrast given at some institutions for MRCP is very rare. Also, the oral contrast used at some institutions may have an unpleasant taste and cause temporary fullness, but most patients usually tolerate it well.

Manufacturers of intravenous contrast indicate mothers should not breastfeed their babies for 24-48 hours after contrast medium is given.

However, both the American College of Radiology (ACR) and the European Society of Urogenital Radiology note that the available data suggest that it is safe to continue breastfeeding after receiving intravenous contrast. *For further information please consult the ACR Manual on Contrast Media and its references.*

### **What are the limitations of MRCP?**

High-quality images are assured only if you are able to remain perfectly still and follow breath-holding instructions while the images are being recorded. If you are anxious, confused or in severe pain, you may find it difficult to lie still during imaging. A person who is very large may not fit into the opening of certain types of MRI machines.

The presence of an implant or other metallic object sometimes makes it difficult to obtain clear images due to streak artifacts from the metallic objects. Patient movement can have the same effect.

A very irregular heartbeat may affect the quality of images obtained using techniques that time the imaging based on the electrical activity of the heart, such as electrocardiography (ECG).

MRI generally is not recommended for patients who have been acutely injured; however, this decision is based on clinical judgment. This is because traction devices and many types of life support equipment may distort the MR images and as a result, must be kept away from the area to be imaged. Furthermore, the examination takes longer than other imaging modalities (typically x-ray and CT) and the results may not be immediately available, as is often necessary in trauma situations. Although there is no reason to believe that magnetic resonance imaging harms the fetus, pregnant

women usually are advised not to have an MRI exam during the first trimester unless medically necessary. <sup>(ASRT)</sup>

## 2.5 Previous Study:

Adameka et al (1998) Studied eighty six patients with suspected common biliary duct obstruction who presented between January and December 1996 were enrolled. Twenty six were excluded due to anatomical reasons or because MRCP or ERCP could not be performed successfully. Results of MRCP were interpreted by two radiologists and a gastroenterologist unaware of clinical diagnosis. Final diagnosis was determined by ERCP and histopathological findings or a follow up of at least 12 months to assess the diagnostic accuracy of MRCP and endoscopic retrograde cholangiopancreatography (ERCP) and to determine whether MRCP may help to prevent unnecessary Interventional procedures. They found MRCP images of diagnostic quality were obtained in all 60 patients. Thirteen patients had a clear bile duct. Sensitivity and specificity for the detection of any abnormality (n=47) were 89% and 92%, and for the detection of malignancy (n=27) 81% and 100%, respectively. These results were equivalent to the respective figures of ERCP (91% and 92% for any abnormality, and 93% and 94% of malignant diseases) they Concluded MRCP is as sensitive as ERCP in the evaluation of biliary tract diseases. As the specificity of this non-invasive technique is close to 100%, MRCP may prevent inappropriate invasive explorations of the common bile duct and pancreatic duct (E A Adameka et al 1998)

Diwanji et al (2016) conducted a prospective study carried out over a period of 2 years. If on ultrasonography patient having pancreatobiliary disease, then s/he would be selected for the study. Once the patient agrees to participate in the study, information is obtained as per the performance. MRCP was done in all participants to describe the MRCP appearance of pancreatobiliary



diseases and differentiating benign from malignant strictures, and also to determine sensitivity, specificity, and accuracy of MRCP in the detection of pancreatico-biliary diseases they found the peak incidence of pancreatico-biliary diseases is seen in the age group of 61–70 years with 9 (22.5%) participants. Common presenting complaint were right upper quadrant pain seen in 37 (92.5%) patients followed by yellowish discoloration of skin and sclera, present in 29 (32.5%) of patients. The cases of cholangiocarcinoma predominated and was seen in 08 (20 %) patients followed by choledochal cyst in 06 (15 %) and cholelithiasis-choledocholithiasis in 6 (15%). Benign diseases were seen in 21 (52.5%) participants while malignant diseases in 19 (47.5%). Sensitivity and specificity of MR Pancreatico-cholangiography scan for pancreatico-biliary diseases was nearly 95%. Also accuracy of diagnosis was also 95% They Concluded MRCP is providing useful criteria in differentiating benign from malignant strictures. MRI in combination with MRCP has the advantage of multiplanar capability, high tissue contrast, combining projection, and cross sectional images in the evaluation of the biliary system. After the initial USG examination in these patients, the next investigation should be MRI with MRCP.(Nehal Diwanji et al 2016)

Akhter et al (2016) .The retrospective study was conducted at Aga Khan University Hospital, Karachi, and comprised data related to the period between August 2005 and December 2013. All children from age of 1 day to 17 years who had undergone Magnetic Resonance Cholangiopancreatography examination for suspected pancreatico-biliary disorders were included. Clinical presentation, Magnetic Resonance Cholangiopancreatography findings, operative findings and histopathological results were recorded. Sensitivity and specificity of Magnetic Resonance Cholangiopancreatography for different diseases was worked out To evaluate

the role of Magnetic Resonance Cholangiopancreatography in the diagnosis of biliary disorders in children 50 patients in the study, 12(24%) showed findings of choledochal cyst. Of these patients, 11(91.6%) underwent surgery and operative findings were consistent with choledochal cyst. Only 1(8.3%) who was assessed as Biliary atresia was found to have choledochal cyst on surgery Magnetic Resonance Cholangio-pancreatography was found to be 91% sensitive and 100% specific for diagnosis of choledochal cyst with diagnostic accuracy of 98% they Concluded Magnetic Resonance Cholangiopancreatography is a very accurate non-invasive investigation for the diagnosis of Biliary disorders(Waseem Akhter et al 2016)

Karwaetal (2017). Study consists of fifty unselected patients of different age groups in whom there was clinical suspicion of Biliary disease. This is a prospective cross sectional study carried out in department of radio diagnosis, DVVPF'S Medical College and Hospital, Ahmednagar. All cases of Biliary pathology attending DVVPF'S Hospital, Ahmednagar were included in the study, excluding those with cardiac pacemakers, prosthetic heart valves, cochlear implant or any metallic implant. To evaluate the spectrum of findings in cases of Biliary disorders on MRCP and evaluate role of MRCP in surgical management and outcome of biliary disorders. They found in the present study the cases of duct calculi predominated and was seen in 16 patients (32%) followed by congenital (choledochal cyst) in 12(24%) and gall bladder masses in 6 (12%). In our study, patients of biliary pathology especially stricture and mass lesion in lower part of CBD were better evaluated by MRCP. In patient with Klatskintumour, in which hepatic ducts were better evaluated by MRCP. ERCP, histopathological reports and post-operative findings were compared. MRCP was 98% accurate in

diagnosing the diseases. False negative result in one patient was due to technical problem. In this patient MRCP diagnosis was mass lesion in 2nd part of duodenum, but on operation it was pancreatic head carcinoma we have concluded that, the introduction of MRCP has revolutionized the technique of non invasive evaluation of the anatomy and pathology of Biliary tree. Patient of suspected biliary obstruction or cholangiopathy can undergo MRCP as it is non-invasive, non-operator dependant & free of complication with diagnostic accuracy comparable to ERCP in evaluation of Biliary system. Successful outcome in diagnosing the Biliary pathology on MRCP depends on knowledge of technique of MR imaging and careful evaluation of wall of duct, ductal lumen and surrounding soft tissue structures. (Sneha Karwa et al 2017)

Mandelia et al (2013): performed prospective study included 30 patients with suspicion of choledocholithiasis based on clinical evaluation, biochemical, or radiological investigations. Ultrasonography and MRCP were performed in all patients. All patients underwent open surgery. CBD exploration was performed in all patients, either due to presence of palpable stones or due to the presence of dilated CBD (>7 mm). Demonstration of CBD stones intraoperatively was considered the "gold standard" for their presence, defined as stones visualized, and extracted or attempted for extraction during surgical CBD exploration to assess Magnetic resonance Cholangiopancreatography(MRCP) is a noninvasive radiological investigation, performed rapidly, and does not expose the patients to ionized radiation or iodinated contrast material. The present study was conducted to evaluate the role of MRCP in detection of common bile duct (CBD) stones in patients with suspected choledocholithiasis they found that In the traoperatively, 21 (70%) out of 30 patients had Cholelithiasis. 26 (86.67%)

out of 30 patients had dilated CBD intraoperatively. In 20 (66.67%) out of 30 patients, choledocholithiasis was detected intraoperatively. The sensitivity, specificity, positive, and negative predictive values of ultrasonography in detecting CBD stones in the present study were 65%, 60%, 76.47%, and 46.15%, respectively. The sensitivity, specificity, positive, and negative predictive values of MRCP in diagnosis of CBD stones in the present study were 95%, 90%, 95%, and 90%, respectively. They performed prospective study included 30 patients with suspicion of choledocholithiasis based on clinical evaluation. Concluded MRCP is a noninvasive investigation without complications and has high sensitivity, specificity, positive, and negative predictive values in detecting CBD stones. MRCP should be done in all cases with suspicion of CBD stones, where facilities and expertise are available. (Mandelia A et al 2013)

Liddellr.Petal (1999) study 191 consecutive patients referred for diagnostic ERCP, choledocholithiasis was diagnosed in 34 patients using direct cholangiography. The latter took the form of ERCP ( $n = 29$ ), intraoperative cholangiography ( $n = 3$ ) or percutaneous transhepatic cholangiography ( $n = 2$ ). All patients underwent MRCP and ultrasound examinations and their findings for choledocholithiasis were compared with those at direct cholangiography. Finally, in the 29 patients with choledocholithiasis diagnosed under ERCP, stone characteristics were compared across the three investigations of ERCP, MRCP and ultrasound to determine the diagnostic accuracy of magnetic resonance cholangiopancreatography (MRCP) and trans-abdominal ultrasound in the detection of choledocholithiasis, and to compare bile duct stone characteristics using endoscopic retrograde cholangiopancreatography (ERCP), MRCP and ultrasound. They results Compared with direct cholangiography, MRCP

showed a sensitivity, specificity and diagnostic accuracy of 91%, 98% and 97%, respectively, in the diagnosis of choledocholithiasis . MRCP resulted in three false-negative and three false-positive findings, four of which occurred due to confusion with lesions at the ampulla. Ultrasound showed a sensitivity, specificity and diagnostic accuracy of 38%, 100% and 89%, respectively, in the diagnosis of choledocholithiasis. ERCP revealed a greater number of stones and these were more proximally distributed within the bile ducts when compared to MRCP they concluded MRCP is highly accurate in the diagnosis of choledocholithiasis and has the potential to replace diagnostic ERCP.MRCP underestimates the number of bile duct stones present.(Liddellr,P et al 2000)

C.F.TaylorMBBSetal2002 studied patients referred to a teaching hospital for ERCP were eligible for study entry. MRCP was performed within 24 hours before ERCP. MRCP findings were compared with ERCP findings or, when the initial ERCP was unsuccessful, with results of repeat ERCP, percutaneous transhepatic cholangiography, or surgery to assess ERCP has been the only reliable method for imaging the biliary tree, but it is invasive and carries a risk of complications. Magnetic resonance cholangiopancreatography (MRCP) is a noninvasive method for imaging the biliary tree. The aim of this study was to prospectively assess the accuracy of MRCP in a large number of patients theyresults One hundred forty-six patients underwent 149 ERCP/MRCP procedures, of which 129 were evaluable with successful MRCP and ERCP or an ERCP-equivalent study. Diagnoses included choledocholithiasis in 46 and biliary stricture in 12 patients. The sensitivity, specificity, positive, and negative predictive values for MRCP in the diagnosis of choledocholithiasis were 97.9%, 89.0%, 83.6%, and 98.6%, respectively. All 12 strictures were diagnosed by MRCP

(sensitivity 100%, specificity 99.1% concluded MRCP is an accurate, noninvasive alternative to ERCP for imaging the biliary tree. Choledocholithiasis and Biliary strictures can be reliably diagnosed or excluded by MRCP. MRCP should be used increasingly in patients with suspected biliary obstruction to select those who require a therapeutic procedure. ( Andrew C,F, Taylor et al 2002)

Paul Angulo et al 2000 conducted MRC and invasive cholangiography (ERCP or PTC) were both performed in 73 patients, (33 male, 40 female, mean age 56 years) with clinical and/or biochemical evidence of cholestasis. Images were interpreted by two radiologists unaware of the results of other studies to assess Magnetic resonance cholangiography (MRC) is a non-invasive diagnostic procedure whose role in the management of patients with primary sclerosing cholangitis (PSC) is unclear. The aim of this study was to determine the usefulness of MRC in the evaluation of the biliary tree in patients with suspected biliary disease and in particular, PSC they found Forty-two patients (58%) had benign biliary disease, including 23 patients (32%) with PSC; 9 patients (12%) had malignant biliary disease; and 22 patients (30%) had a normal Biliary tree. Diagnostic quality images were obtained in 73/73 (100%) of MRC, and in 70/73 (96%) of invasive cholangiography (68 ERCP's, 2 PTC's) procedures. Using ERCP/PTC findings as the reference standard, MRC had accuracy greater than 90% in the diagnosis of normal bile ducts, Biliary dilatation, Biliary obstruction, bile duct stones, and PSC. Using the final diagnosis, MRC had an overall diagnostic accuracy of 90% in the detection of biliary disease compared to 97% for invasive cholangiography. Additional diagnostic/therapeutic interventions were performed during ERCP in 73% of patients with PSC and

in 43% of patients without PSC ( $p=0.02$ ) .*Concluded* MRC has excellent diagnostic accuracy in the presence of biliary disease. Because of its noninvasive nature, MRC may have advantages over invasive cholangiography when diagnosis is the major goal of the procedure.

Vikas Y Sacheretal 2013 studied from January 2009 to July 2012, all patients at our institution in whom MRCP was used to diagnose and classify the choledochal cysts were identified. Demographic information, clinical characteristics, and imaging details, and operative reports were collected for each patient. MRCP results were compared with intraoperative findings. ERCP's if done, were also included and compared to the MRCP results to assessed Magnetic resonance Cholangiopancreatography (MRCP) is used as primary diagnostic approach in various biliary pathologies. This is the first literature review of published studies discussing MRCP as a diagnostic modality for choledochal cysts. This review further outlines how recent imaging techniques have improved diagnostic accuracy of MRCP in diagnosing choledochal cysts and their associated anatomic variants. Advantages, disadvantages and contraindication for MRCP with respect to endoscopic retrograde Cholangiopancreatography are also discussed they found Eight patients from our institution were included in the initial part of the study. The patients ranged in age from 6 years to 74 years old, and 5 were females. Summarizes demographics, symptoms, initial imaging results, MRCP and subsequent surgical findings. Demographics, physical exam, abdominal ultrasound, computed tomography scan, magnetic resonance Cholangiopancreatography, endoscopic retrograde Cholangiopancreatography and intraoperative findings for each subject they concluded our retrospective study and review of relevant literature suggest that MRCP is as effective as an initial pre-operative diagnostic study for choledochal cysts in adult and

pediatric populations. In addition, MRCP is equivalent to ERCP in determining choledochal cyst type, and helpful in diagnosing related pancreatico-biliary anomalies, such as ABPJ, cholangiocarcinoma, and choledocholithiasis. Given its relatively moderate risk profile and lower cost, MRCP should be the diagnostic test of choice when pre-operatively evaluating choledochal cysts and their associated anomalies. But more evaluation needs to be done to assess the MRCP ability to detect APBJ and choledochoceles. ERCP should be used when MRCP inadequately visualizes the terminal CBD or the pancreatico-biliary duct junction, or when a therapeutic procedure is anticipated. (Paul Angulo et al 2000)

John Grab et al 2015 retrospectively observed and studied consecutive MRCPs (n = 375) from October 2010–June 2013 at West Middlesex University Hospital. MRCP findings were correlated with the presence of dilated or non-dilated biliary tree on initial imaging ultrasound scanning (USS)/computed tomography (CT), deranged liver function tests, abdominal pain and demographics. Multivariate logistic regression analysis was performed with SPSS statistical software to assess Magnetic resonance Cholangiopancreatography (MRCP) is increasingly used in the diagnosis of Biliary abnormalities, particularly in stone disease. Studies of its role in the absence of a dilated Biliary system on prior imaging have shown a low diagnostic yield and the aim of this study was to assess factors predictive of diagnostic outcome. John Grab et al 2015 They found There were 243 female, 132 male patients (mean age of 62). The sensitivity of MRCP was 81% and specificity 80%. Multivariate analysis identified that age (p = 0.0253), jaundice (p = 0.0247) and abnormal index imaging (p = 0.0003) are statistically significant predictors of biliary tree abnormalities on MRCP. The c statistic for the multivariate analysis was



moderately high at 0.665 (95% confidence interval [CI] 0.614–0.712,  $p < 0.001$ ). They concluded these data confirm the low diagnostic yield of MRCP in the absence of dilated Biliary system on initial USS/CT. We propose there should be a specific rationale for performing MRCP when initial imaging is normal especially when bilirubin is normal. (John Grab et al 2015)

Henry Mendler M. Detal 1998 conducted Fifty-eight consecutive patients underwent MRC (GYROSCAN ACS II 1.5 Tesla, TSE T2 axial/coronal-MIP sequences) for clinical and biochemical signs of main bile duct obstruction. MRC images were interpreted by two radiologists and consensus was established according to presence or absence of main bile duct dilation, choledocholithiasis, and malignant or benign stricture. MRC was compared to a final diagnosis established by ultrasound and CT in 19 cases, endoscopic retrograde cholangiopancreatography (ERCP) in 25, intraoperative cholangiography and exploration in 14, and clinical, biochemical, and histological presentation when relevant. Included were single or multiple choledocholithiasis (28, including 11  $\leq$  3 mm), malignant (10) and benign (12) strictures and intrahepatic cholestasis .to evaluate magnetic resonance cholangiography (MRC) in the diagnosis of biliary tree obstruction. They found Overall, MRC was sensitive (94%) and specific (92%) in detecting main bile duct dilation and choledocholithiasis (86% and 97%), but was less sensitive (64%) for small stones  $\leq$  3 mm. Sensitivity for stones  $>$  3 mm was 100%. For benign and malignant strictures, MRC was less sensitive (67% and 80%) but remained specific (98% and 96%). In the detection of normal main bile duct, MRC was highly sensitive (100%) and specific (94%). Diagnostic accuracy ranged from 91% to 98%. They *Concluded* MRC appears to be specific for choledocholithiasis and sensitive except for small stones. Results for Biliary stricture are less satisfactory, but remain specific. Our data confirm that MRC can be useful in the diagnostic workup of main bile duct obstruction. (Henry Mendler et al 1998)

## **Chapter Three**

### **Material & Method**

#### **3.1 Material:**

This is Prospective descriptive quantitative Study using data from King Khalid hospital in Najran , with an aim to assess the biliary system pathologies in Najran patients (20-80 ) years old

#### **3.2 Study design:**

This study conducted during the period from February 2017-february 2019 using MRI.

#### **3.3 Area of study:**

King Khalid hospital (Najran –Saudi Arabia)

#### **3.4 Study population and sampling :**

##### **3.4.1 The population:**

The population was patient with different Biliary system diseases pathology (male and female) their age between (20-80) years old.

##### **3.4.2 The sample:**

Randomly selected 92 patients whom present in King Khalid hospital with signs and symptoms of Biliary diseases.

#### **3.5 Inclusion criteria:**

Patients with Biliary system diseases .

### **3.6 Exclusion criteria:**

Patient with Biliary system diseases under 20 years old

### **3.7 Study variable:**

#### **3.7.1 Main variable :**

Biliary system diseases

#### **3.7.2 Dependantvariable:**

Age, Sex, Weight, contrast, histoy, MRI finding.

### **3.8 Method of collecting data and instrumentation:**

#### **3.8.1 Method of collecting data:**

Data collected by check list from the king Khalid hospital using

Picture Archive and Communication System (PACS)

### **3.9 Equipment:**

Biliary system diseases was performed on Magnetic Resonance Imaging Machine using (1.5 and 3.0) Tesla.

### **3.10. Technique:**

The MRCP technique was based on heavily T2-weighted images which result in a dramatic increase in contrast between stationary fluids (bile) and the background (hepatic and pancreatic parenchyma, abdominal fat). As a result, the bile presents a very high signal intensity compared with low signal intensity background. In addition, no signal comes from flowing blood. The examination does not require an intravenous contrast agent. It is recommended that patients fast for 3–4 hours before undergoing an MRCP in order to reduce fluid content within the stomach, decrease duodenal peristalsis and promote gall bladder filling. MRCP is performed using

breath-hold and non-breath-hold sequences. The breath-hold sequence acquires a single slab of data, between 40 and 80 mm thick, in 1 or 2 seconds. This gives similar projection images to those acquired by ERCP. Thin slabs (4 mm thick) can also be acquired using breath-hold T2-weighted half Fourier acquisition single-shot turbo spin echo (HASTE) sequences. These are obtained in coronal or oblique coronal views. In addition, the MRCP involves acquiring multiple thin collimation slices, a non-breath-hold, respiratory-triggered 3D turbo spin-echo (TSE) T2-weighted sequence, (1.5 mm) that can be post-processed on an imaging workstation. The commonly used post-processing method is a maximum intensity projection (MIP) algorithm. The source images from a thin collimation multislice acquisition are reviewed in addition to the MIP reconstructions in order to demonstrate small stones or other intraductal pathology that may be obscured by partial volume averaging effect .(Patel HT et al 2009)

### **3.11 data analysis:**

Statistical analysis will perform using SPSS software (Statistical Package for social science).

### **3.12 Ethical consideration:**

Concern was taking from King Khalid hospital to perform the study.

## Chapter four

### Results

Table 4.1: Shows frequency distribution of gender.

Gender	Frequency	Percent
Female	57	61.3 %
Male	36	38.7 %
Total	93	100.0 %

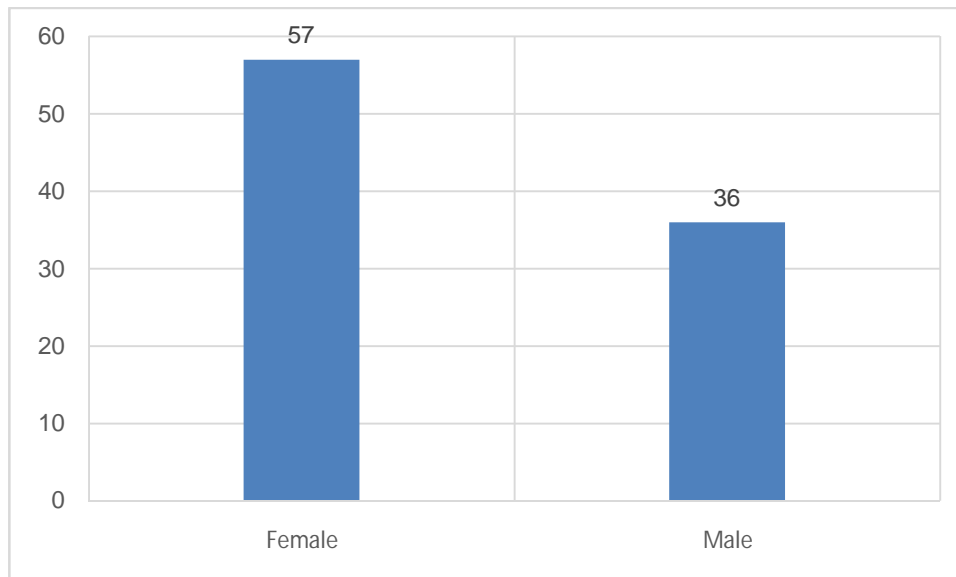


Figure 4.1: Shows frequency distribution of gender.

Table 4.2: Shows age group distribution for all patients.

<b>Age Group</b>	<b>Frequen cy</b>	<b>Percent</b>	<b>Valid Percent</b>	<b>Cumulative Percent</b>
18-30	13	14.0 %	14.0 %	14.0 %
31-45	40	43.0 %	43.0 %	57.0%
46-60	22	23.7 %	23.7 %	80.6 %
61-80	14	15.1 %	15.1 %	95.7 %
81-100	4	4.3 %	4.3 %	100.0 %
<b>Total</b>	<b>93</b>	<b>100.0 %</b>	<b>100.0 %</b>	
The mean age =46 +_16.53				

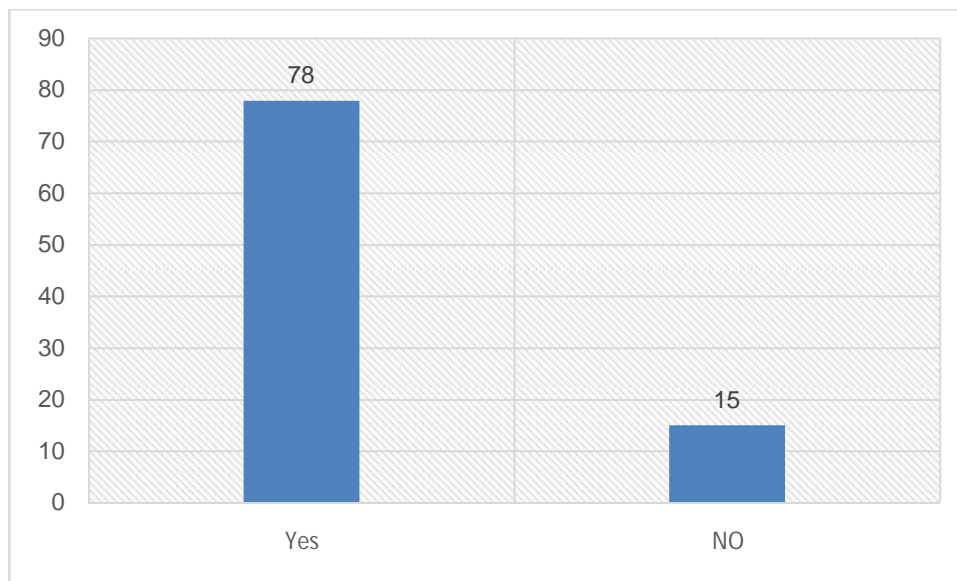
Table 4.3: Shows cross tabulation between genders with age group.

**Gender \* Age Group Cross tabulation**

<b>Gender</b>	<b>Age Group</b>					<b>Total</b>
	18-30	31-45	46-60	61-80	81-100	
Female	8	23	14	10	2	57
Male	5	17	8	4	2	36
<b>Total</b>	<b>13</b>	<b>40</b>	<b>22</b>	<b>14</b>	<b>4</b>	<b>93</b>

Table 4.4: Shows contrast frequency distribution

Contrast	Frequency	Percent
Yes	78	83.9 %
NO	15	16.1 %
Total	93	100.0 %



**Figure 4.2: Shows contrast frequency.**

Table 4.5: Shows contrast frequency distribution.

**Gender \* Contrast Cross tabulation**

Gender	Contrast		Total
	Yes	NO	
Female	46	11	57
Male	32	4	36
Total	78	15	93

Table 4.6: Shows cross tabulation between contrast histories with age group.

**Contrast \* Age Group Cross tabulation**

Contrast	Age Group					Total
	18-30	31-45	46-60	61-80	81-100	
Yes	11	32	19	12	4	78
NO	2	8	3	2	0	15
Total	13	40	22	14	4	93



Table 4.7: Shows frequency distribution of patents history.

History	Frequency	Percent
GB Stone	1	1.1 %
Cancer	7	7.5 %
Cyst	3	3.2 %
None	4	4.3 %
Lesion	13	14.0 %
Cholelithiasis	6	6.5 %
Jaundice	3	3.2 %
Cholecystitis	6	6.5 %
Obstructive jaundice	15	16.1 %
Pancreatitis	6	6.5 %
Stone	9	9.7 %
Abdominal pain	13	14.0 %
Obstruction	7	7.5 %
Total	93	100.0 %

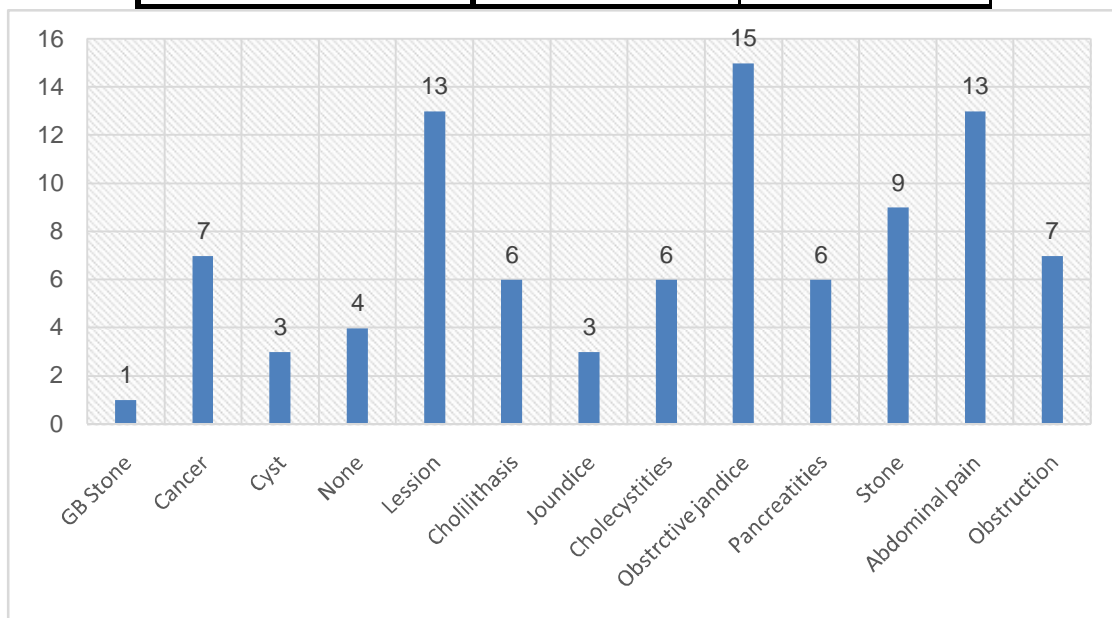
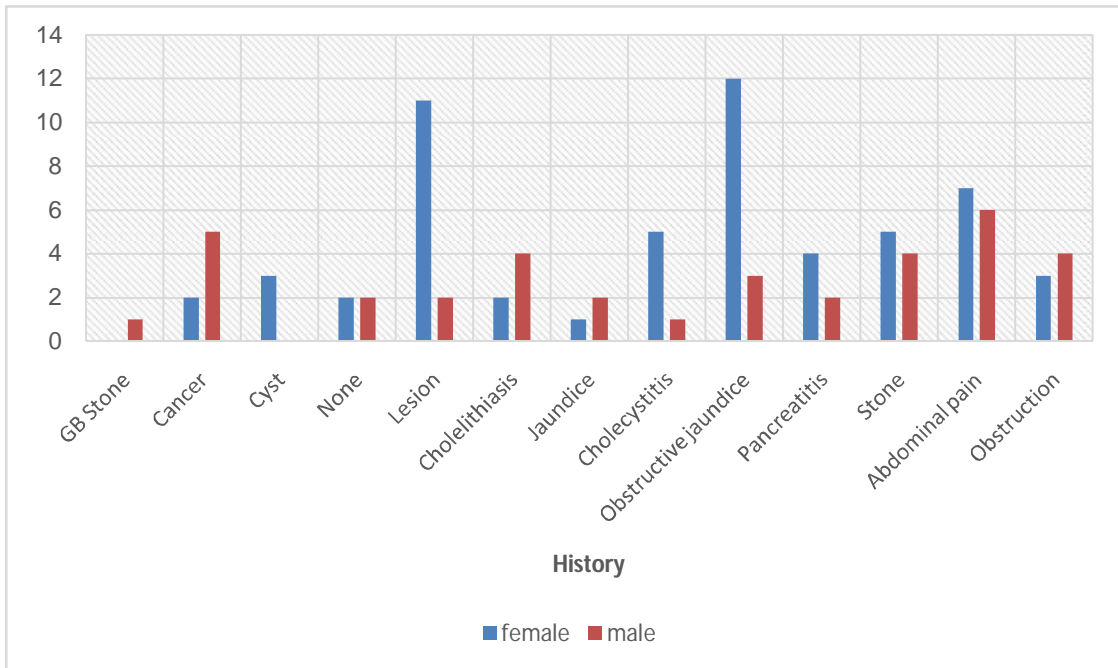


Figure 4.3 shows history frequency distribution

Table 4.8: Shows cross tabulation between the patient's histories with gender

**History \* Gender Cross tabulation**

History	Gender		Total
	Female	Male	
GB Stone	0	1	1
Cancer	2	5	7
Cyst	3	0	3
None	2	2	4
Lesion	11	2	13
Cholelithiasis	2	4	6
Jaundice	1	2	3
Cholecystitis	5	1	6
Obstructive jaundice	12	3	15
Pancreatitis	4	2	6
Stone	5	4	9
Abdominal pain	7	6	13
Obstruction	3	4	7
Total	57	36	93



**Figure 4.4 shows correlation between histories with gender female**

Table 4.9: Shows cross tabulation between histories with age group

**History \* Age Group Cross tabulation**

History	Age Group					Total
	18-30	31-45	46-60	61-80	81-100	
GB Stone	0	1	0	0	0	1
Cancer	0	3	3	1	0	7
Cyst	0	0	1	2	0	3
None	1	1	1	1	0	4
Lesion	1	4	5	3	0	13
Cholelithiasis	1	2	2	0	1	6
Jaundice	1	1	0	0	1	3
Cholecystitis	1	4	0	1	0	6
Obstructive jaundice	3	9	1	2	0	15
Pancreatitis	1	2	1	1	1	6
Stone	1	4	3	1	0	9
Abdominal pain	2	5	4	2	0	13
Obstruction	1	4	1	0	1	7
Total	13	40	22	14	4	93

Table 4.10: Shows frequency distribution of MRI Finding for all patients:

MRI Finding	Frequency	Percent
Hemangioma	9	9.7 %
Mets	3	3.2 %
Tumor	3	3.2 %
Stone	40	43.0 %
Normal	4	4.3 %
None	1	1.1 %
Obstruction	1	1.1 %
Cyst	15	16.1 %
Lesion	10	10.8 %
Pancreatitis	1	1.1 %
Multiple Stone	5	5.4 %
Obstruction Jaundice	1	1.1 %
Total	93	100.0 %

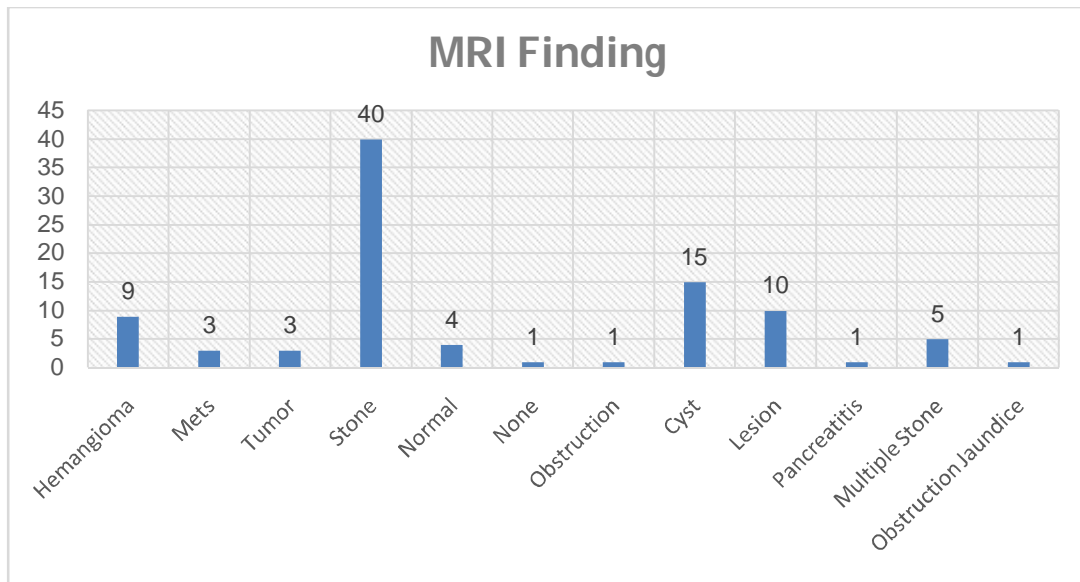
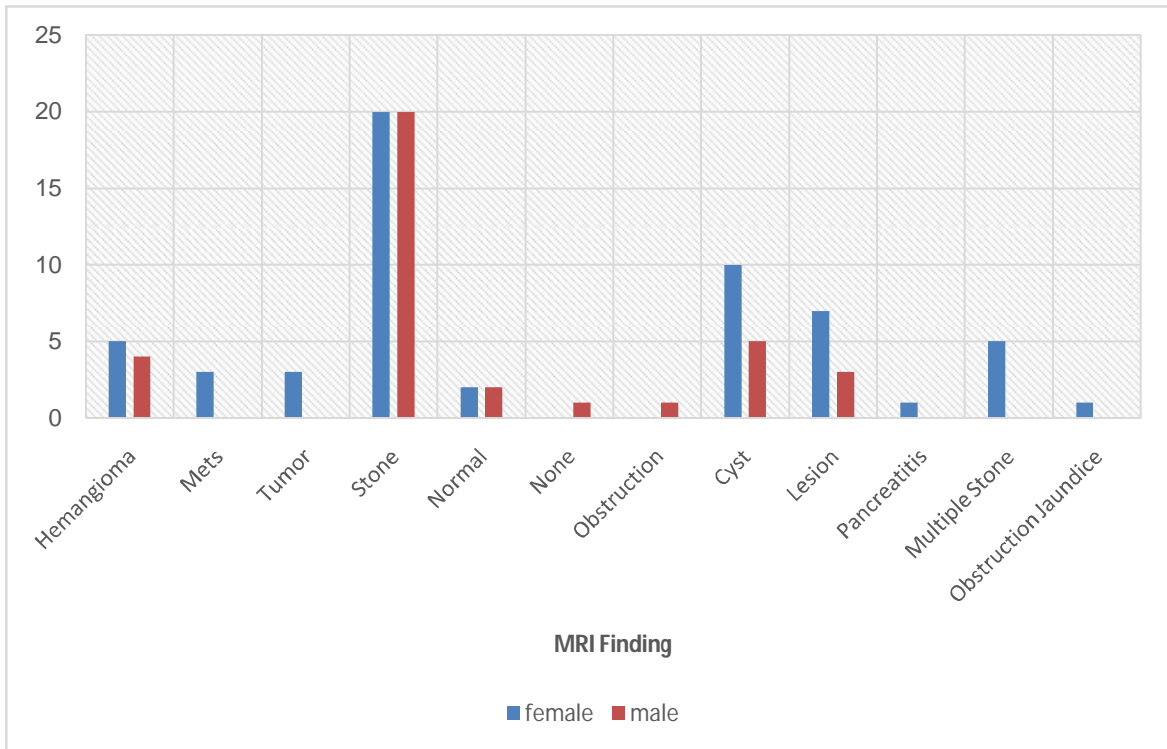


Figure 4.5 shows MRI finding frequency distribution

Table 4.11: Shows cross tabulation between the patient's MRI Finding with gender

**MRI Finding \* Gender Cross tabulation**

MRI Finding	Gender		Total
	Female	Male	
Hemangioma	5	4	9
Mets	3	0	3
Tumor	3	0	3
Stone	20	20	40
Normal	2	2	4
None	0	1	1
Obstruction	0	1	1
Cyst	10	5	15
Lesion	7	3	10
Pancreatitis	1	0	1
Multiple Stone	5	0	5
Obstruction Jaundice	1	0	1
Total	57	36	93



**Figure 4.6: Shows correlation between MRI Finding.**

Table 4.12: Shows cross tabulation between histories with gender

**MRI Finding \* Age Group Cross tabulation**

MRI Finding	Age Group					Total
	18-30	31-45	46-60	61-80	81-100	
Hemangioma	0	3	6	0	0	9
Mets	0	2	1	0	0	3
Tumor	0	0	1	2	0	3
Stone	7	19	9	2	3	40
Normal	2	0	1	1	0	4
None	0	1	0	0	0	1
Obstruction	0	1	0	0	0	1
Cyst	1	6	3	5	0	15
Lesion	1	5	1	2	1	10
Pancreatitis	0	0	0	1	0	1
Multiple Stone	1	3	0	1	0	5
Obstruction Jaundice	1	0	0	0	0	1
Total	13	40	22	14	4	93

Shows cross tabulation between histories with gender the maximum in MRI finding.



## Chapter five

### Discussion, conclusions and recommendation

#### 5-1 Discussion:

Study of biliary system disease using magnetic resonance imaging at king Khalid hospital- KSA with two magnetic resonance machine 2 and 3 tesla. And the results presented in tables and figures as showed in chapter four.

The number of samples was 92 patients, 57 (61.3%) of the patients were female and 36 (38.7%) were male. Most of the patient in our study was female as shown in table 4.1. and showed that the most abnormalities for all patients in the female than the male for all diseases. However Paul Angulo et al 2000 conducted MRC and invasive cholangiography were both performed in 73 patients, (33 male, 40 female, mean age 56 years).

And the mean age of study sample was  $46 \pm 16.53$ . and Age group between (18-30), (31-45), (46-60), (61-80), and (81-100) were 14%, 43%, 23.7%, 15.1%, and 4.3% respectively. Maximum age group was range from (31-45) and Minimum age was range from (81 – 100). However Diwanji 2016 et al found the peak incidence of pancreatobiliary diseases is seen in the age group of 61–70 years as shown in table 4.2.

According to table (4-3) there was a correlation between gender with age groups, age group (18-30) the most frequently was 8 female, in age group (31-45) the most frequently was 23 female, in age group (46-60) the most frequently was 14 female, in age group (61-80) the most frequently was 10 female in age group (81-100) the most frequently was 2 female. Correlate between the gender and age group that divided to five groups; the most age period frequently for both genders was 31-45 years repeated 23 and 17 time

for female and male respectively. Then 46-60 years repeated 14 and 8 times for female and male respectively.

From table and figure (4-4) and (4-2) patient with contrast 78 (83.9%) and patients with out contrast 15 (16.1%). Most of the study cases with contrast and minimum were without contrast.

According to table(4- 5) the study found a correlation between gender and contrast, 46 of the patients was female with contrast and 32 of the patients was male, 11 of the patients was female without contrast and 4 of the patients was male . There was 46 and 32 patient with contrast female and male respectively .And there were 11 and 4 patient without contrast male and female respectively.

Table (4- 6) showed the patients with contrast in age group (18-30) was 11, in age group (31-45) was 32 , in age group (46-60) was 19 , in age group (61-80) was 12 , in age group (81-100) was 4 . The patient without contrast in age group (18-30) was 2 , in age group (31-45) was 8 , in age group (46-60) was 3 , in age group (61-80) was 2 , in age group (81-100) was 0 . Most of the patient whom does contrast was in age group range between 31-45, and minimum was in age group range from (81-100).

According to table(4-7) and figure (4-3) the patients was GB Stone 1 (1.1%) , Cancer was 7 (7.5%) , Cyst was 3 (3.2%) , None was 4 (4.3%) , Lesion was 13 (14%) , Cholelithiasis was 6 (6.5%) , Jaundice was 3 (3.2%) , Cholecystitis was 6 (6.5%) , Obstructive jaundice was 15 (16.1%) ,Pancreatitis was 6 (6.5%) , Stone was 9 (9.7%) , Abdominal pain was 13 (14 %) , Obstruction was 7 (7.5%) . The most frequency disease was Obstructive jaundice. However, Mandelia et al (2013) studied 30 patients with suspicion of choledocholithiasis based on clinical

evaluation Concluded MRCP is a noninvasive investigation without complications and has high sensitivity, specificity, positive, and negative predictive values in detecting CBD stones. MRCP should be done in all cases with suspicion of CBD stones, where facilities and expertise are available.

A correlation from table (4-8) and figure (4-4) the patients histories with gender, patients was GB Stone 0 female and 1 male ,patient was Cancer 2 female and 5 male , patient was Cyst 3 female and 0 male ,patient was None 2 female and 2 male , patient was Lesion 11 female and 2 male ,patient was Cholelithiasis 2 female and 4 male ,patient was Jaundice 1 female and 2 male , patient was Cholecystitis 5 female and 1 male , patient was Obstructive jaundice 12 female and 3 male , patient was Pancreatitis 4 female and 2 male , patient was Stone 5 female and 4 male , patient was Abdominal pain 7 female and 6 male ,patient was Obstruction 3 female and 4 male . Show correlation between the history and patients gender, were the number of patients 57 and 36 for female and male respectively. And the most disease for female was lesion, obstructive jaundice and abdominal pain repeated 11, 12 and 7 times respectively. And for male cancer and abdominal pain repeated 5 and 6 times. Cross tabulation for the history with age group most frequency disease in male was abdominal pain and in female obstructive jaundice.

According to table (4-9) the correlation between MRI findings with age groups the most frequently of GB disease was 1 in age group (31-45) , ) the most frequently of Cancer was 3 in age group (31-45) ,(46-60) , the most frequently of Cyst was 2 in age group (61-80) , the most frequently of none in age group (18-30) , the most frequently of Lesion was 5 in age group (46-60) , the most frequently of Cholelithiasis 2 in age group (31-45),

(46-60) , the most frequently of jaundice was 1 in age group (18-30) , the most frequently of Cholecystitis was 4 in age group (31-45) . the most frequently of obstructive jaundice was 9 in age group (31-45) ,the most frequently of Pancreatitis was 2 in age group (31-45) , the most frequently of Stone was 4 in age group (31-45) , the most frequently of Abdominal pain was 5 in age group (46-60) , the most frequently of Obstruction was 4 in age group (31-45) . Most age period for all patients with disease was (31-45). The most frequently disease was obstructive jaundice in the age period 31-45 years repeated 9 times. Over all the most age period for all patients with disease was 31-45 years, then 46-60 years, and less age period 81-100 years.

According to table (4-10) and figure (4-5) MRI finding for all patients 9 ( 9.7% ) of the patients was Hemangioma , 3 (3.2% ) of the patient was Tumor , 3 ( 3.2% ) of the patients was Mets , 40 (43% ) of the patient was Stone , 1 ( 1.1% ) of the patients was None , 1 (1.1% ) of the patient was Obstruction , 15 ( 16.1% ) of the patients was Cyst, 10 (10.8% ) of the patient was Lesion . 1 (1.1%) of the patient was Pancreatitis, 5 (5.4%) of the patient was Multiple Stone, 1 (1.1%) of the patient was obstructive jaundice, the most frequency disease was stone. However Paul Angulo et al 2000 studied to determine the usefulness of MRI in the evaluation of the biliary tree in patients with suspected Biliary disease and in particular, PSC they found Forty-two patients (58%) had benign Biliary disease, including 23 patients (32%) with PSC; 9 patients (12%) had malignant Biliary disease; and 22 patients (30%) had a normal Biliary tree.

And correlate from table (4-11) and figure (4-6) between MRI findings with gender over all the stone was superior for all findings. According to gender the most diseases finding for both female and male was stone, cyst and

lesion with frequently for female 20, 10 and 7 and for male 20, 5 and 3 times respectively. The frequency disease in both male and female was stone.

And correlation between MRI finding over all results was stone, cyst and lesion, and the most age period repeated was ( 31-45) and 46-60. The most disease was stone, cyst and lesion repeated 19, 6 and 5 respectively in age period from 31 to 45 years. And with same frequently for all ages period mostly table 4.12.

## **5-2 Conclusions:**

Magnetic resonance Cholangiopancreatography (MRCP) is a technique that has evolved over the past two decades, and consider as a noninvasive diagnostic modality capable to produce high-quality images of the biliary and pancreatic disorders. Study of biliary system disease using magnetic resonance imaging at king Khalid hospital- KSA with two magnetic resonance machine 2 and 3 tesla, in period from Feb to Oct 2017 .

The results show that the most abnormalities for all patients in the female than the male for all diseases. most frequently disease lesion, obstructive jaundice and abdominal pain. Comparing between the history and MRI finding notice that the most history diseases for female lesion, obstructive jaundice and abdominal pain but in MRI finding the most diseases was stone, cyst and lesion. for male the most history diseases cancer, Cholelithiasis and abdominal pain but in MRI results was stone, cyst and hemangioma ,the correlate between the history and age group show that the most disease history was obstructive jaundice, lesion and abdominal pain.

In the relation between the MRI finding with age group showed that the most daises finding stone, cyst and lesion repeated 40, 15 and 10 times respectively.

### **5-3 Recommendations:**

- MRCP has a good roll in evaluation of Biliary system diseases without using ionizing radiation & contrast media or sedation .
- It is important to start with MRCP before doing ERCP in any patient which did not conformed with U/S .
- It is important to do plain CT scan abdomen complementary if MRCP failed to demonstrate the stones.

## References:

American Society of Radiologic Technologists (ASRT) Careers in Radiologic Technology Portal

Andersen, D.H. (1938). "Cyst leiesic fibrosis of the pancreas and its relation to celiac disease". *Am J Dis Child.* 56: 344–399. doi:10.1001/archpedi.1938.01980140114013.

Bassari, R; Koea, JB (7 February 2015). "Jaundice associated pruritis: a review of pathophysiology and treatment". *World Journal of Gastroenterology.* 21 (5): 1404–13. doi:10.3748/wjg.v21.i5.1404. PMC 4316083. PMID 25663760.

Biliary tract at the US National Library of Medicine Medical Subject Headings (MeSH).

Chang WH, Kortan P, Haber GB . Outcome in patients with bifurcation tumors who undergo unilateral versus bilateral hepatic duct drainage. *Gastrointest Endosc*1998;47:354-62

E. A. Boyden1957, "The anatomy of the choledochoduodenal junction in man," *Surgery, Gynecology & Obstetrics*, vol. 104, no. 6, pp. 641–652,. View at Google Scholar · View at Scopus

Fahad Ali, WaseemAkhter, Muhammad Arshad 2016 ( Department of Radiology, Aga Khan University Hospital Karachi. ), Keywords: Magnetic Resonance Cholangio-pancreatography , Biliary disorders. (JPMA 66: 27;2016 )Read PDF.



Farooq, Vasim; Brugaletta, Salvatore; Serruys, Patrick W. (2011-12-01). "Contemporary and evolving risk scoring algorithms for percutaneous coronary intervention". *Heart*. 97 (23): 1902–1913. doi:10.1136/heartjnl-2011-300718. ISSN 1468-201X. PMID 22058284. Ferri, Fred F. (2014).


Ferri's Clinical Advisor 2015: 5 Books in 1. Elsevier Health Sciences. p. 672. ISBN 9780323084307. Archived from the original on 2017-09-08.

Greenholz SK, Krishnadasan B, Marr C, Cannon R (1997). "Biliary obstruction in infants with cystic fibrosis requiring Kasai portoenterostomy". *J. Pediatr. Surg.* 32 (2): 175–9, discussion 179–80. doi:10.1016/S0022-3468(97)90174-3. PMID 9044117.

H E Adameka, J Alberta, M Weitzb, H Breerb, D Schillinga, J F Riemanna . Pancreas and biliary tract , A prospective evaluation of magnetic resonance cholangiopancreatography in patients with suspected bile duct obstruction , <http://dx.doi.org/10.1136/gut.43.5.680> .

HenryMendlerM.D.<sup>a</sup>PhilippeBouilletM.D.<sup>b</sup>DenisSautereauM.D.<sup>a</sup>PierreChau  
merliacM.D.<sup>b</sup>FrançoisCessotM.D.<sup>a</sup>AnneLe  
SidanerM.D.<sup>a</sup>BernardPillegandM.D.<sup>a</sup> , Value of MR cholangiography in the  
diagnosis of obstructive diseases of the biliary tree,  
[https://doi.org/10.1016/S0002-9270\(98\)00589-9](https://doi.org/10.1016/S0002-9270(98)00589-9)Get rights and content

J. Behar and P. Biancani1985, "Role of cat sphincter of Oddi motor activity on trans-sphincteric flow (TSF)," *Gastroenterology*, vol. 88, p. 1320,. View at Google Scholar

^ Jump up to:<sup>a b c d e f</sup> Ansaloni, L. (2016). "2016 WSES guidelines on acute calculus cholecystitis". *World journal of emergency surgery: WJES*. 11: 25. Doi:10.1186/s13017-016-0082-5. PMC 4908702 . PMID 27307785.

Jump up to:<sup>a b c d e f g h</sup> "Gallstones". NIDDK.NIH.gov. Washington DC: National Institute of Diabetes and Digestive and Kidney Diseases. November 2013. Archived from the original on 16 August 2016. Retrieved 27 July 2016.

Jump up^ Internal Clinical Guidelines Team (October 2014). "Gallstone Disease: Diagnosis and Management of Cholelithiasis, Cholecystitis and Choledocholithiasis". NICE.org. London: National Institute for Health and Care Excellence. p. 21. PMID 25473723. Clinical Guideline 188. Retrieved 24 June 2018.

Jump up^ Kapoor VK, McMichael AJ (2003). "Gallbladder cancer: an 'Indian' disease". *Natl Med J India*. 16 (4): 209–13. PMID 14606770

J. Toouli and A. Craig 2000, "Sphincter of Oddi function and dysfunction," *Canadian Journal of Gastroenterology*, vol. 14, no. 5, pp. 411–419,. View at Google Scholar · View at Scopus

John Graby, Catherine Ramsey, Mark McPhail, Anouchka Goldman, Kevin Monahan 2015, The role of MRCP in potential gallstone disease when the Biliary tree is normal on initial imaging, <https://doi.org/10.1016/j.crad.2015.06.011> Get rights and content .

Kosslyn, Stephen M.; Intriligator, James M. (1992). "Is Cognitive Neuropsychology Plausible? The Perils of Sitting on a Juan-Legged Stool". *Journal of Cognitive Neuroscience*. 4 (1): 96–105. doi:10.1162/jocn.1992.4.1.96.

L. Behar, K. Y. Lee, W. R. Thompson, and P. Biancani 1989, "Gallbladder contraction in patients with pigment and cholesterol

stones,” *Gastroenterology*, vol. 97, no. 6, pp. 1479–1484,. View at Google Scholar · View at Scopus

L. Gullo, L. Bolondi, P. Priori, P. Casanova, and G. Labò1984, “Inhibitory effect of atropine on cholecystokinin-induced gallbladder contraction in man,” *Digestion*, vol. 29, no. 4, pp. 209–213,.View at Google Scholar · View at Scopus

"Lesion...What Does The Doctor Mean?".*MedicineNet*. Retrieved 2016-03-03.

Mandelia A, Gupta AK, Verma DK, Sharma S2013. The value of magnetic resonance cholangiopancreatography in the detection of choledocholithiasis. *West Afr J Radiol*;20:23-9

Matos C, Winant C, Deviere J et al . Magnetic resonance pancreatography . *Abdom Imaging* 2001;26:243-253.

[medicine.georgetown.edu/divisions/gastroenterology/knowledge/biliary-obstruction](http://medicine.georgetown.edu/divisions/gastroenterology/knowledge/biliary-obstruction) 13

*Nehal Diwanji, Rajeev B Dibbad, Mona Sastri, Ekta Desai*2016, The study of role of magnetic resonance cholangio-pancreatography (MRCP) in pancreato-biliary disorders , *Int J Med Sci Public Health.*; 5(12): 2635-2640 doi: 10.5455/ijmsph.2016.14072016578

N. Hanyu, W. J. Dodds, R. D. Layman, and W. J. Hogan1990, “Cholecystokinin-induced contraction of opossum sphincter of Oddi. Mechanism of action,” *Digestive Diseases and Sciences*, vol. 35, no. 5, pp. 567–576,. View at Publisher · View at Google Scholar · View at Scopus

Patel HT, Shah AJ, Khandelwal SR, Patel HF, Patel MD. MRcholangiopancreatography at 3.0 T. Radiographics: a review publication of the Radiological Society of North America, Inc. 2009;29(6):1689–706. Describes and illustrates in detail 3.0T MRCP appearances of normal biliary tract anatomy, variants and benign and malignant pathologies .

(Prof.), Roger Jones (2004). Oxford Textbook of Primary Medical Care. Oxford University Press. p. 758. ISBN 9780198567820. Archived from the original on 2017-09-08.

Publication Review By: Stanley J. Swierzewski 2000 , III, M.D. Published: 01 May Last Modified: 22 Jul 2015.

Reprint requests: Andrew C.F. Taylor, MBBS, FRACP, Department of Gastroenterology, St. Vincent's Hospital Melbourne, 41 Victoria Parade Fitzroy 3065, Victoria, Australia. Copyright © 2002 American Society for Gastrointestinal Endoscopy. Published by Mosby, Inc. All rights reserved.

R. Honda, J. Toouli, W. J. Dodds, S. Sarna, and W. J. Hogan 1982, “Relationship of sphincter of Oddi spike bursts to gastrointestinal myoelectric activity in conscious opossums,” Journal of Clinical Investigation, vol. 69, no. 4, pp. 770–778,. View at Google Scholar View at Scopus.

\* Sneha Karwa, Department of Radiodiagnosis and Imaging, Memorial Hospital and Medical College, Ahmednagar, Maharashtra, India, Tel: +919890849900; Email: drsaurabhsutada@gmail , Role of Magnetic Resonance Cholangiopancreatography in Biliary Disorders, Volume 2 Issue 4 – 2017

Trade M, Rumstadt B, Wendl K et al . Ultrafast MR imaging improves the staging of pancreatic tumors. Ann Surg 1997;226:393-407

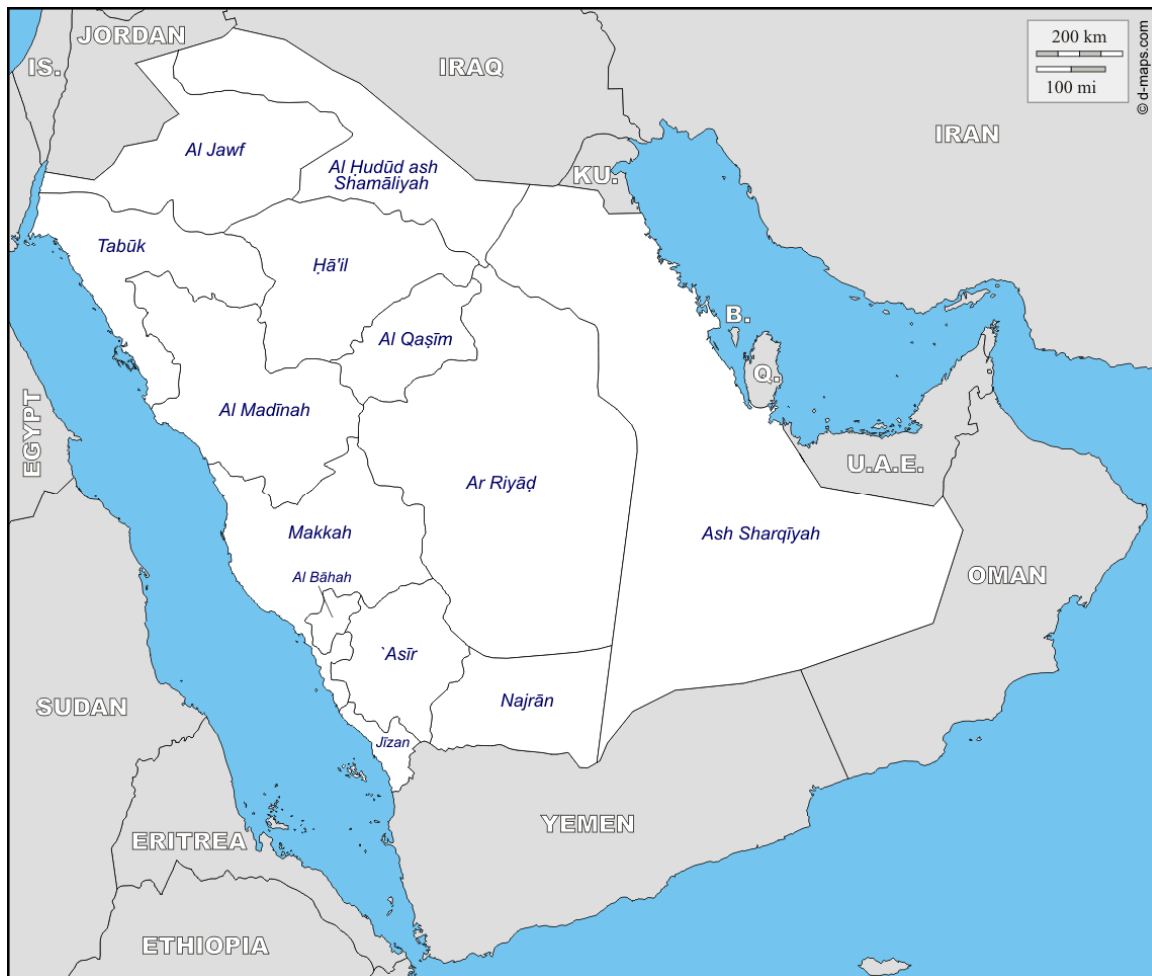VARGHESE J.C.<sup>a</sup> LIDDELL R.P.<sup>a</sup> FARRELL M.A.<sup>a</sup> MURRAY F.E.<sup>b</sup> OSBORN ED.H.<sup>c</sup> LEEM J.J.<sup>a</sup> 2000, Diagnostic Accuracy of Magnetic Resonance Cholangiopancreatography and Ultrasound Compared with Direct Cholangiography in the Detection of Choledocholithiasis, <https://doi.org/10.1053/crad.1999.0319> Get rights and content, Varghese, J. C. (). *Clinical Radiology* 55, 25–35.

Vikas Y Sacher, James S Davis, Danny Sleeman, and Javier Casillas 2013, Role of magnetic resonance cholangiopancreatography in diagnosing choledochal cysts: Case series and review, *World J Radiol.* August 28; 5(8): 304–312. Published online 2013 August 28. doi: 10.4329/wjr.v5.i8.304

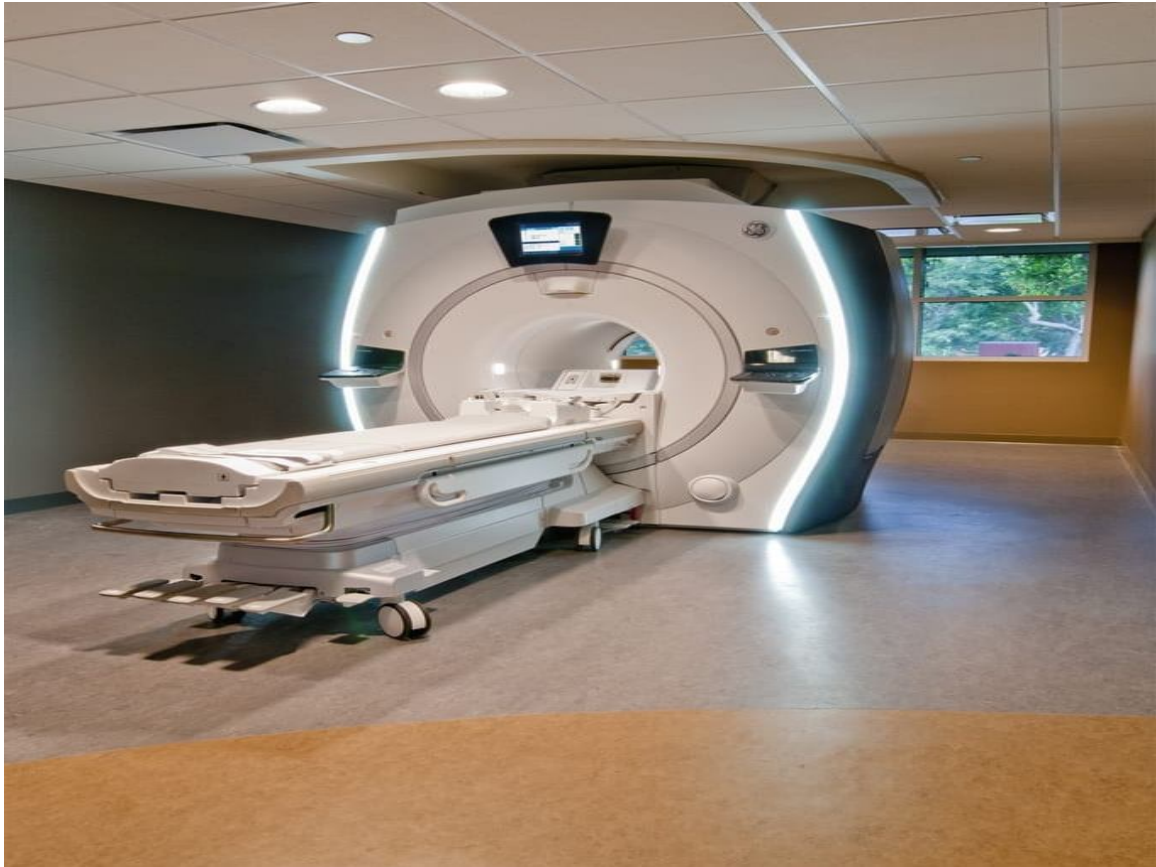Yun EJ, Choi CS, Yoon DY, et al 2009. Combination of magnetic resonance cholangiopancreatography and computed tomography for preoperative diagnosis of the Mirizzi syndrome. *J Comput Assist Tomogr.* Jul-Aug. 33(4):636-40. [Medline].

Zadik Y, Yitschaky O, Neuman T, Nitzan DW (May 2011). "On the Self-Resolution Nature of the Buccal Bifurcation Cyst". *J Oral Maxillofac Surg.* 69 (7): e282. doi:10.1016/j.joms.2011.02.124. PMID 21571416.

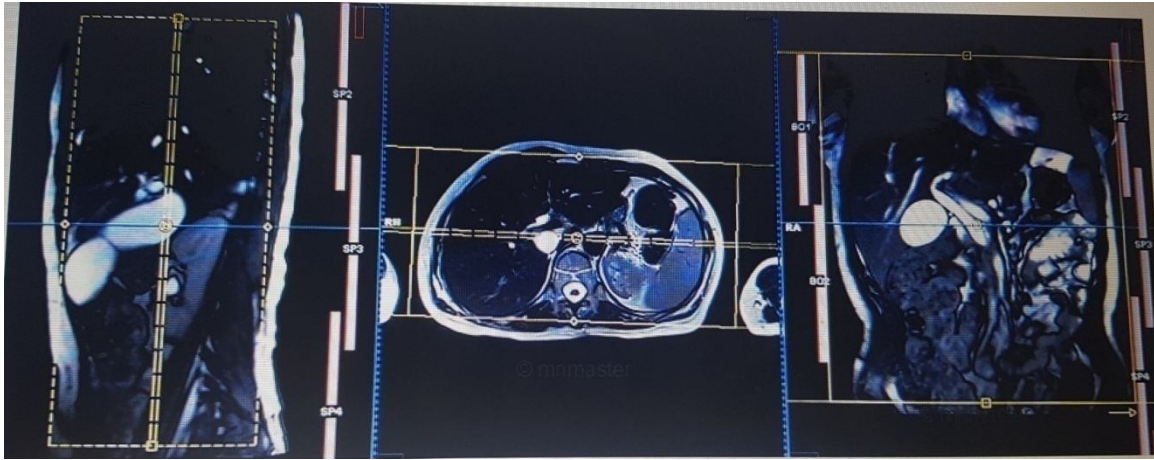
## Appendixes:



Appendix (1) Najran Map

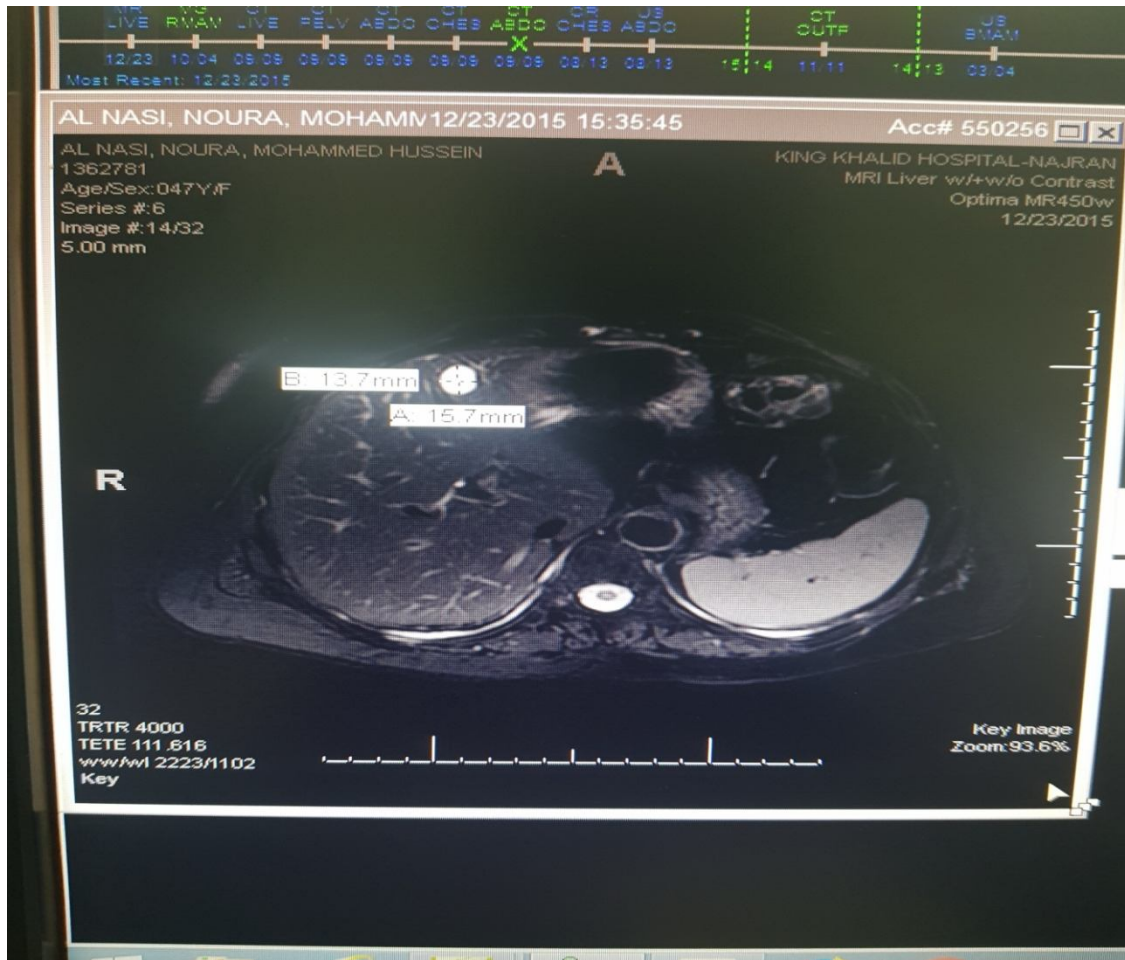


Appendix (2) MRI Machine 1.5 Tesla

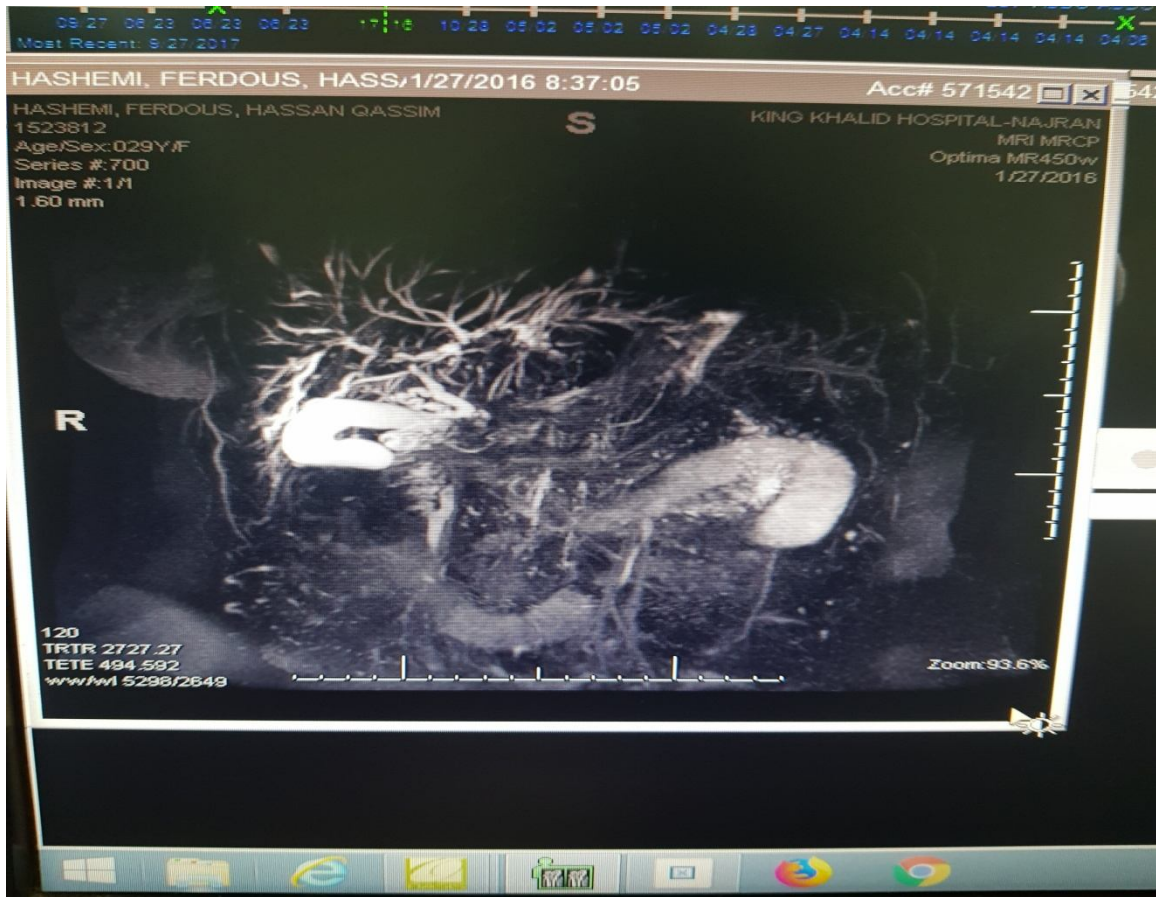

Appendix (3) Localizer for planning MRCP protocol

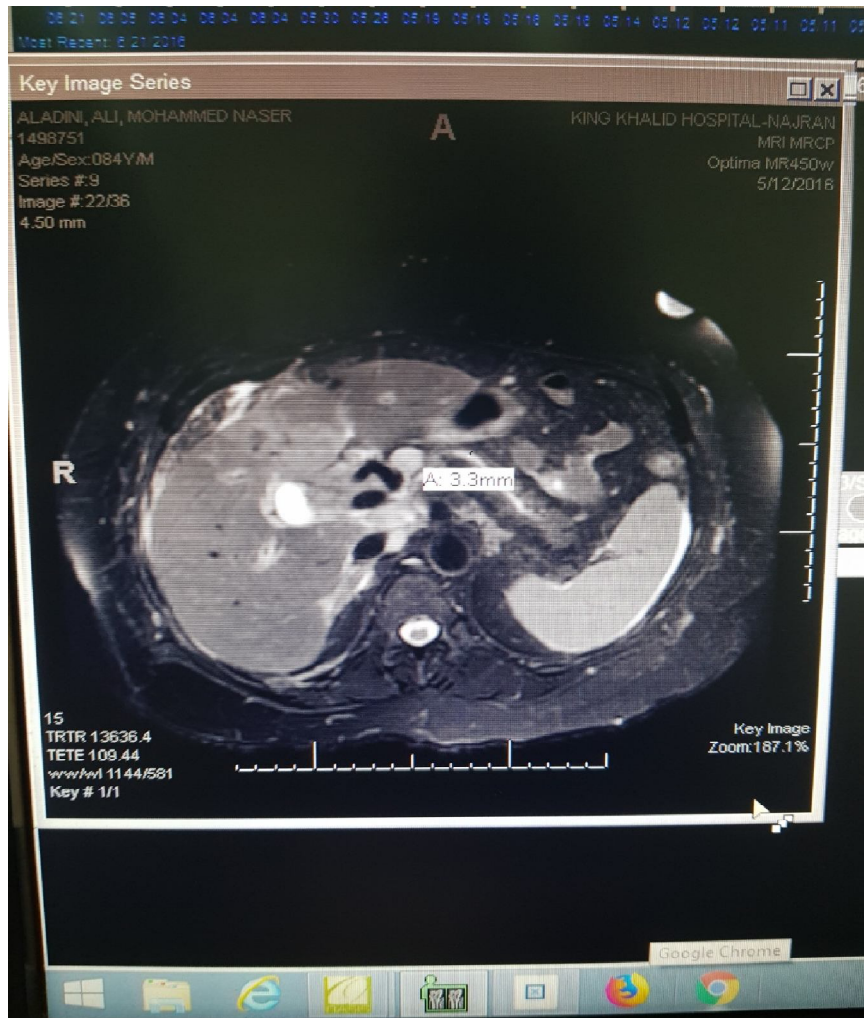




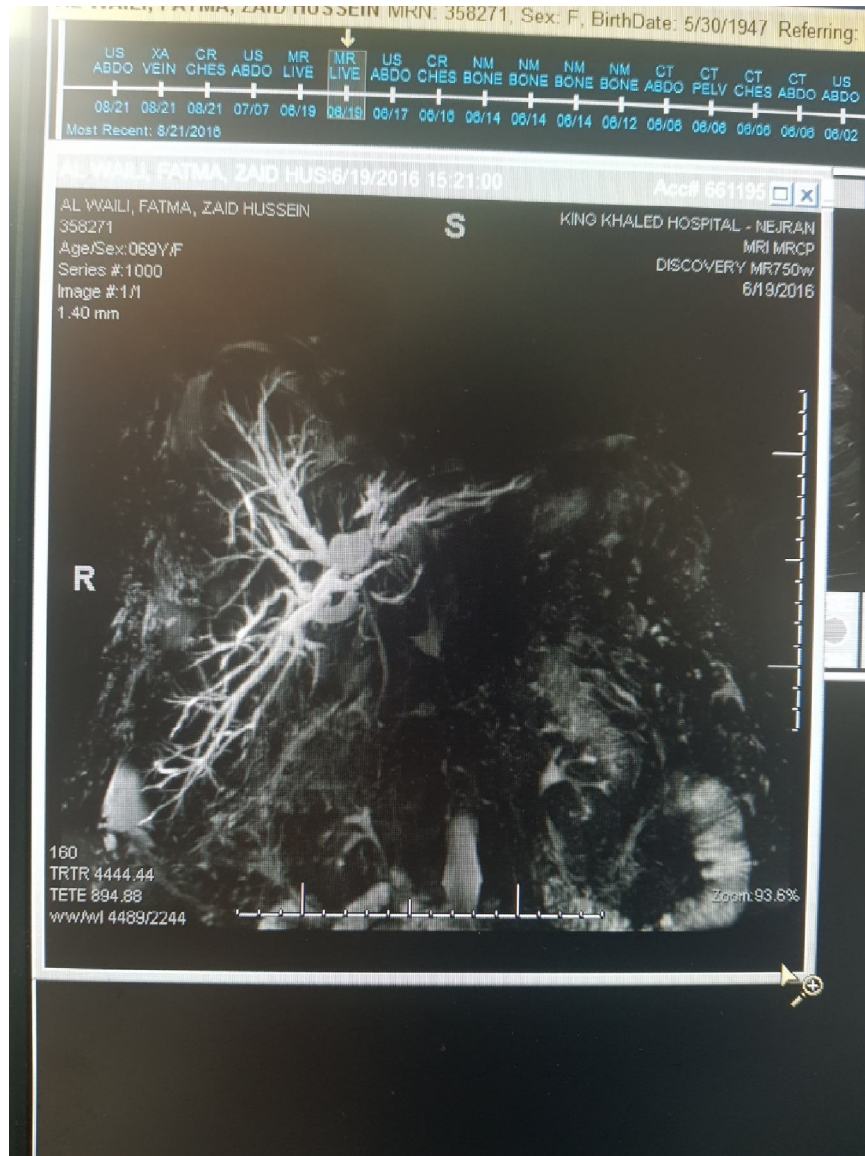Appendix (4) female 47 years old has Lt breast ca with multiple lesion we did MRI hyper intense signal in T2-weighted images and hypo intense signal in GRE-weighted image shows two Hemangioma within the right lobe of liver.



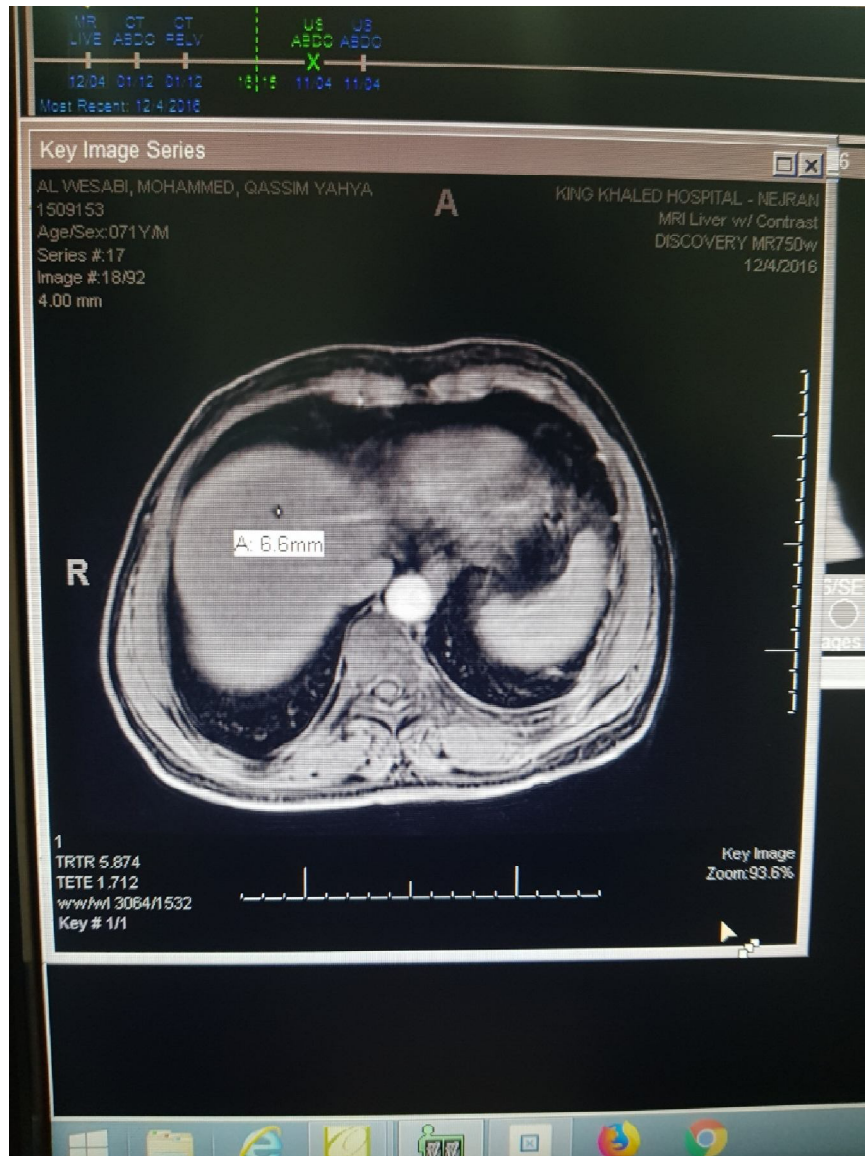
Appendix (5) female 29 years old with consisted liver disease we did multiplaner,multisequential MRCP image shows filling defect at common hepatic duct due to lesion as Klatskin tumor .



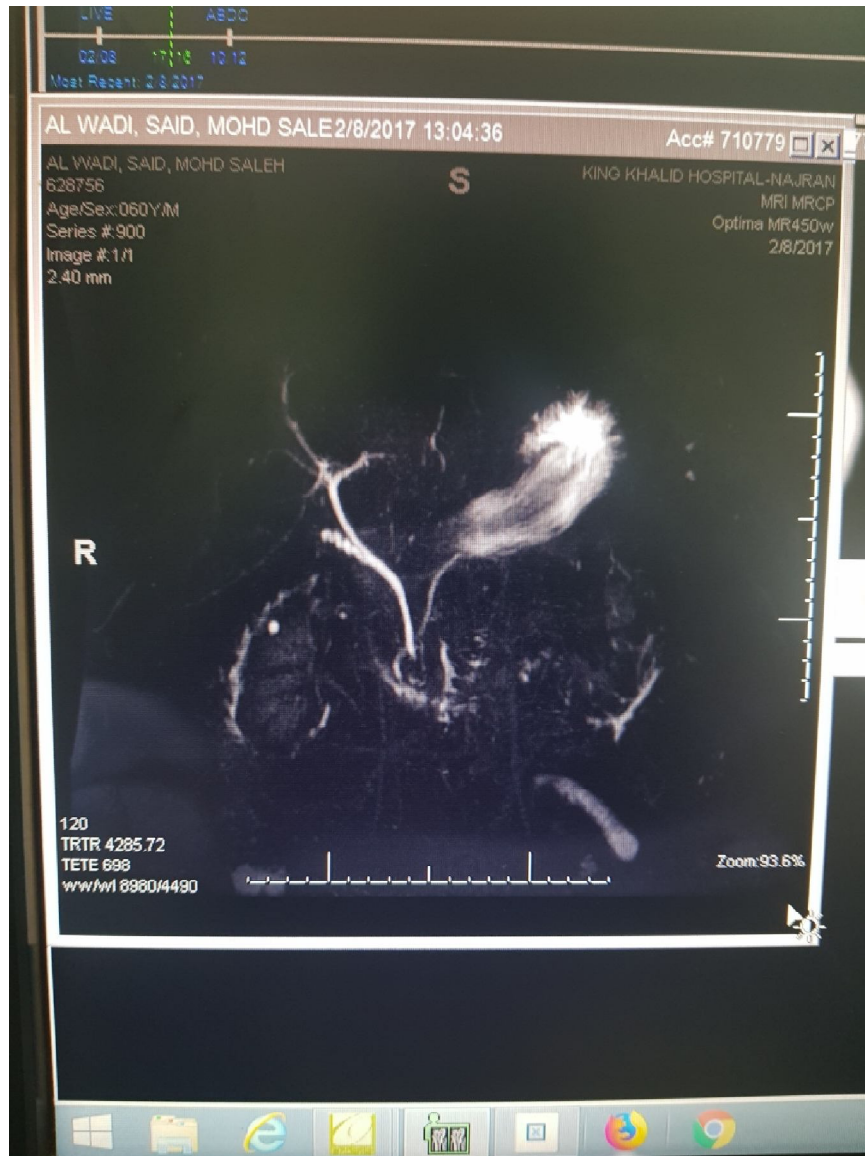Appendix (6) male 34 years old has obstructive jaundice post ERCP done 4 month ago with stent inserted came to ER with 3 days history of yellowish body we did MRCP image shows large stone on the neck of GB .



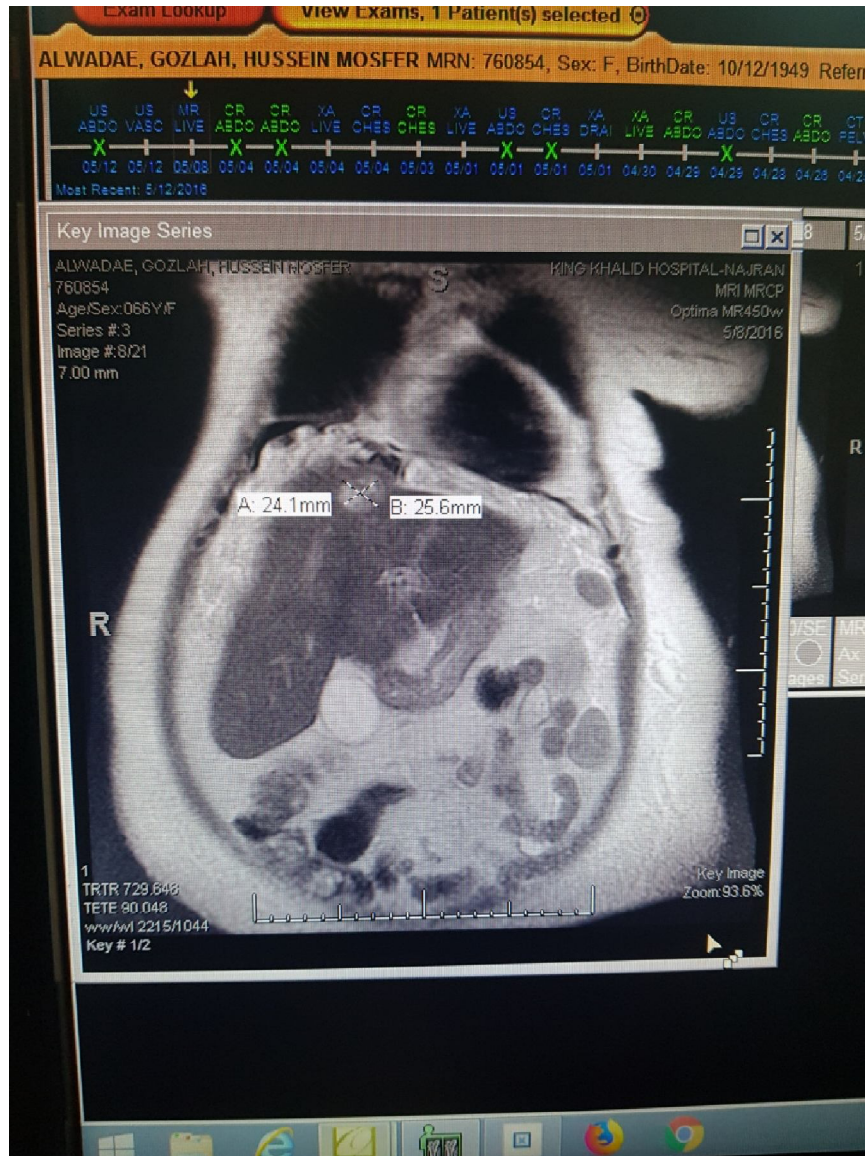
Appendix (7) Female 69 years old Multiplaner, multisequential MRCP image shows focal aneurismal dilatation of the right hepatic duct



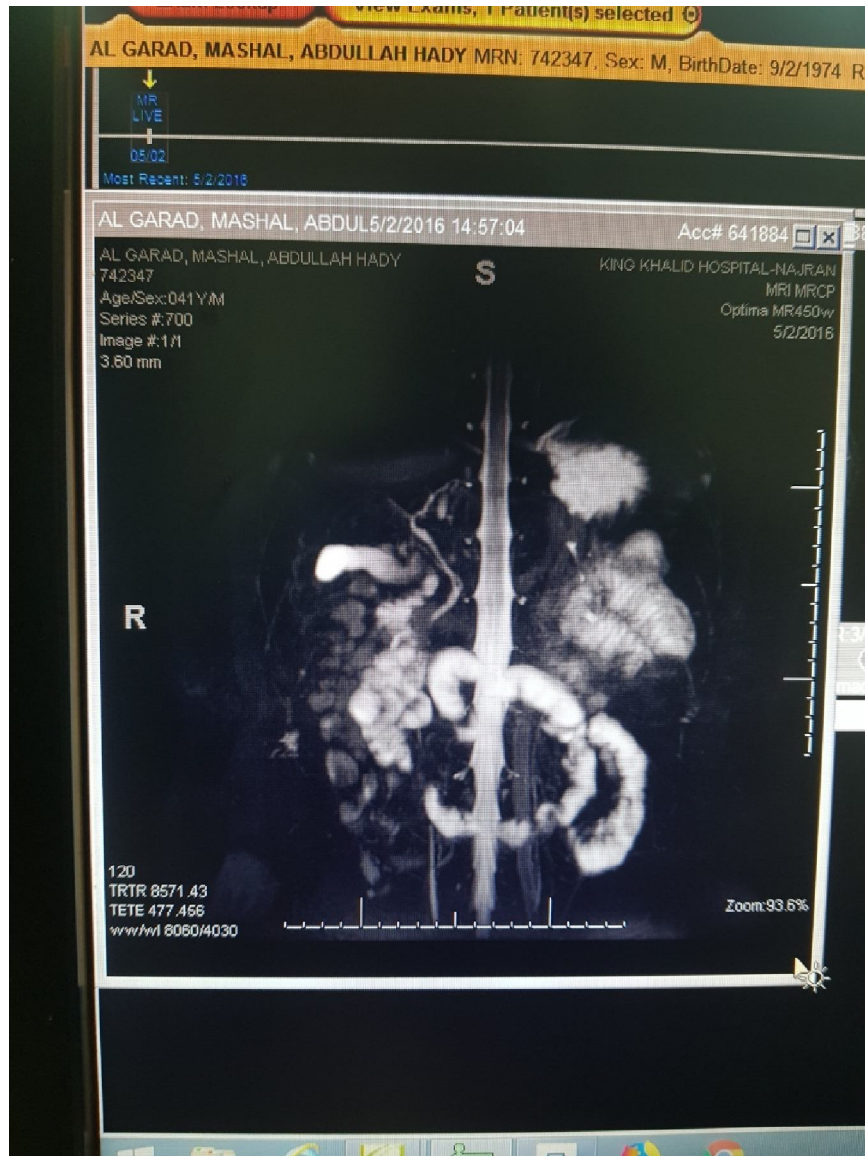
Appendix (8) male 71 years old has upper abdominal pain for long time upper endoscopy negative abdomen CT shows thickening of the wall of the jejunum loop may be inflammatory we did MRCP image shows cyst.



Appendix (9) male 60 years old with chronic pancreatitis we did MRCP image shows cyst



Appendix (10) female 66 years old with obstructive jaundice



Appendix (11) Female 41 years old multiple stone of gallbladder