



Sudan University of Science & Technology
College of Graduate Studies



Characterization of Chronic Renal Failure using Ultrasonography

توصيف الفشل الكلوي المزمن باستخدام التصوير بالموجات فوق الصوتية

A Thesis Submitted for Partial Fulfillment of the Requirements of M.S.c
Degree in Medical Diagnostic Ultrasonography

By

Yasmin Ahmed MohamedAwadalseed

Supervisor

Dr. Babiker Abd Elwahab Awadalla

2019

الآية

بسم الله الرحمن الرحيم

قال الله تعالى

(سَنُرِيهِمْ آيَاتِنَا فِي الْآفَاقِ وَفِي أَنْفُسِهِمْ حَتَّى
يَتَبَيَّنَ لَهُمْ أَنَّهُ الْحَقُّ)

صدق الله العظيم

فصلت الآية (53)

Dedication

To my family for their support and to my friend saidaltaif

Acknowledgment

First and foremost, I would like to thank Allah for achieve this work and then thanks to Dr.Babiker Abd alwahab for supporting and guiding me to accomplish this work,in addition,I would like to thank my brother Mammon Ahmed.

Abstract

This descriptive study was conducted via the selection of fifty patients in the Nile river state, Almeknimer Hospital, renal unit, (shendi-sudan), during the period from the first of September to December 2018. The aim of this study was to know characterization of chronic renal failure using ultrasonography. The researcher analyzed all the results and compared them to previous studies. The study results showed that there were 32% femals, 64% males, All patients had chronic renal failure, any had Acute renal failure was excluded from this study. All those patients were scanned transabdominal using Fukuda denshi ultrasound machine to evaluate size, shape, cortico medullary deferentiation, and assess acquired cystic disease.

Collected data analyzed using SPSS program. Study found that both kidneys were small in size, 62% had abnormal shape in right kidney, 38% had normal, 64% had abnormal shape in left kidney, 36% had normal, 54% loses corticomedullary deferentiation and 46% decreased in right kidney and the result same in left kidney, there were 100% had no hydronephrosis for both kidneys. There were 34% with acquired cyst and 66% without. there was no mass 100% in both kidneys.

From all of that the study found that there is certain appearance of kidneys in chronic renal failure so the study recommended that ultrasound scanning should be used routinely to every patient with renal pathology.

The study recommended that further studies with large samples in the future could be done in the same topic to know more about the characterization of kidneys using ultrasonography in chronic renal failure, in general Sudan.

مستخلص البحث

هذه دراسة توصيفيه تمت في مدينة شندي مستشفى الملك نمر (وحدة الكلى) عبر اختيار 50 مريضا بالفشل الكلوي المزمن خلال الفترة من سبتمبر 2018 إلى ديسمبر من نفس العام.

هدفت الدراسة إلى توصيف الفشل الكلوي المزمن باستخدام الموجات فوق الصوتية وأوضحت نتائج هذه الدراسة أن المرض أكثر انتشارا بين الرجال بنسبة 68% بينما الإناث 32% تم استبعاد مرضى الفشل الكلوي الحاد من الدراسة. كل المرضى تم تصويرهم عبر البطن بواسطة جهاز فوكودانشي لتقييم حجم الكلية وشكلها وتمايزها والكشف عن وجود الأكياس المكتسبة.

حللت البيانات بواسطة برنامج إحصائي وجدت الدراسة أن كلتا الكليتين صغيرتا الحجم 62% لها شكل غير طبيعي في الكلية اليمنى بينما 38% لها شكل طبيعي 64% لها شكل غير طبيعي في الكلية اليسرى بينما 36% لها شكل طبيعي 54% فقدت تمايزها كلياً بينما 46% قل تمايزها في الكليتين بالتساوي. كذلك أوضحت الدراسة أن 34% لديهم أكياس مكتسبة ولم تسجل الدراسة وجود حصاوي أو أورام من كل ما سبق نستخلص أن هناك صفات ومظهر محدد للكلية مما يؤهل الموجات فوق الصوتية لتوصيف مرض الفشل الكلوي المزمن بدقة لذلك أوصت الدراسة بان يتم إجراء الموجات لكل مريض يعاني من أمراض الكلى.

List of contents

الآية	I
Dedication	II
Acknowledgment	III
Abstract	IV
Abstract Arabic	V
List of contents.....	VI
List of tables.....	IX
List of figures.....	X
List of Abbreviations	XI

Chapter One: Introduction

1.1 Introduction.....	1
1.2 problem of the study	1
1.3 Objectives of study	1
1.3.1 General objective	1
1.3.2 Specific objectives	1
1.4 Overview of study.....	2

Chapter Two: Literature Review

2.1 Theoretical Background.....	3
2.1.1 Anatomy of kidneys.....	3
2.1.2 Relationships.....	4
2.1.3 General Structure of the Kidneys	6
2.1.4 Blood Supply of the Kidneys.....	7
2.2 physiology.....	8
2.2.1 Functions of the Kidneys	8
2.3 Anomalies of Structure And Function.....	8
2.3.1 Ectopic Kidney	8
2.3.2 Crossed Fused Ectopia.....	9
2.3.3 Unilateral Renal Agenesis	9

2.3.4 Hypoplastic Kidneys.....	10
2.3.5. Duplicated Collecting System	10
2.3.7. (Persistent) Fetal Lobation.....	10
2.3.8. Junctional Parenchymal Defect	11
2.3.9. Interrenicular Septum	11
2.3.10. Renal Sinus Lipomatosis	11
2.3.11. Dromedary Hump	11
2.3.12. Renal Column Hypertrophy.....	11
2.3.13. Ureteropelvic Junction Obstruction (UPJ)	12
2.3.14. Medullary Sponge Kidney (MSK)	12
2.4 Renal Pathology.....	12
2.4.1 Renal cystic disease	12
2.4.1.1 Simple Renal Cysts.....	12
2.4.1.2 Atypical Renal Cysts	13
2.4.1.3 Parapelvic Cysts.....	13
2.4.1.4 Acquired Uremic Cysts, Adenomas and Carcinomas	13
2.4.1.5 Multicystic Dysplastic Kidney	14
2.4.1.6 Autosomal Recessive Polycystic Renal Disease (ARPRD).....	14
2.4.1.7 Autosomal Dominant Polycystic Renal Disease (ADPRD).....	14
2.4.1.8 Medullary Cystic Disease	15
2.4.2. Calyceal Diverticulum.....	15
2.4.3 Hydronephrosis.....	15
2.4.4 Renal Calculus Disease.....	15
2.4.5 NEOPLASMS.....	16
2.4.5.1 A. BENIGN LESIONS	16
2.4.5.1.1 Angiomyolipoma (AML).....	16
2.4.5.1.2 Oncocytoma	16
2.4.5.2 B. Malignant Lesions.....	16
2.4.5.2.1 Renal Cell Carcinoma (RCC).....	16

2.4.5.2.2 Renal Lymphoma.....	17
2.4.5.2.3 Leukemia	18
2.4.5.2.4 Nephroblastoma	18
2.4.6 Acute Renal Failure (ARF).....	18
2.4.7 Chronic Renal Failure (CRF):	18
2.4.7.1 Signs and symptoms:	19
2.4.7.2 Causes:	19
2.5 Previous studies	22

Chapter three: Materials and Methods

3.1 Material	23
3.1.1 Subject	23
3.1.2. Patients preparation	23
3.1.3. Patient position	23
3.1.4 Machine used	23
3.2 Method	23
3.2.1 Technique used	23
3.2.2 Image interpretation	24
3.2.3 data analysis	24
3.2.4 duration	24

Chapter four: Results

Results_.....	25
---------------	----

Chapter Five: Discussion, Conclusion and Recommendations

5.1 Discussion	40
5.2 Conclusion	42
5.3 Recommendations.....	43
References.....	44
Appendix.....	

List of tables

Table(4. 1) frequency distribution of age	25
Table(4. 2) frequency distribution of gender	26
Table(4. 3) frequency distribution of occupation	27
Table(4. 4) frequency distribution of complains.....	28
Table(4. 5) frequency distribution of duration.....	29
Table(4. 6) frequency distribution of urea	30
Table(4. 7) frequency distribution of criatinine	31
Table(4. 8) frequency distribution of size of both kidneys.....	32
Table(4. 9) descriptive statistic (min, max, mean \pm std) for age, duration...	33
Table(4. 10) frequency distribution of shape of right kidney	33
Table(4. 11) frequency distribution of shape of left kidney	33
Table(4. 12) frequency distribution of CMD	34
Table(4. 13) frequency distribution of Cysts	35
Table(4. 14) frequency distribution of Cyst side and number	36
Table(4. 15) cross tabulation duration and CMD	37
Table(4. 16) cross tabulation duration and RTK size	37
Table(4. 17) cross tabulation duration and LTK size	37
Table(4. 18) cross tabulation duration and presence of cyst.....	38
Table(4. 19) correlation between duration and kidney measurements	39

List of figures

Figure(2. 1) Renal anatomy (Devin, 2005).....	4
Figure(2. 2) intrarenal arteries (Buturovic 2003)	8
Figure(4. 1) frequency distribution of age.....	25
Figure(4. 2) frequency distribution of gender.....	26
Figure(4. 3) frequency distribution of occupation.....	27
Figure(4. 4) frequency distribution of complains	28
Figure(4. 5) frequency distribution of duration	29
Figure(4. 6) frequency distribution of urea.....	30
Figure(4. 7) frequency distribution of criatinine	31
Figure(4. 8) frequency distribution of size of both kidneys	32
Figure(4. 9) frequency distribution of CMD	34
Figure(4. 10) frequency distribution of Cyst	35
Figure(4. 11) frequency distribution of Cyst side and number.....	36
Figure(4. 12) scatterplot shows inverse relationship between duration and kidneys length.....	38
Figure(4. 13) scatterplot shows inverse relationship between duration and kidneys width.....	38

List of Abbreviations

Abbreviation	Meaning
CRF	Chronic renal failure
CT	Computerized Tomography
CMD	Corticomedullary differentiation
ESKD	End stage kidney disease
LK	Left kidney
NM	Nuclear medicine
PCS	Pelvic Calyceal System
RK	Right kidney
US	Ultrasound
UPJ	Urethro-prostatic junction
WHO	World Health Organization

Chapter One

1.1 Introduction

Chronic renal failure and end stage renal disease are functional diagnosis characterized by progressive decrease in glomerular filtration rate(GFR).

According the 2010 Global Burden of Disease Study, chronic kidney disease was ranked 27th in the list of causes of total number of deaths worldwide in 1990, but rose to 18th in 2010. This degree of movement up the list was second only to that for HIV and AIDS (Garcia, 2013).

Over 2 million people worldwide currently receive treatment with dialysis or a kidney transplant to stay alive, yet this number may only represent 10% of people who actually need treatment to live. Of the 2 million people who receive treatment for kidney failure, the majority are treated in only five countries – the United States, Japan, Germany, Brazil, and Italy. These five countries represent only 12% of the world population. Only 20% are treated in about 100 developing countries that make up over 50% of the world population. (Couser et al, 2011).

1.2 problem of the study

Chronic renal failure spread widely in Shandi city, so we need available, cheap and accurate tools for evaluate and early detection of it.

1.3 Objectives of study

1.3.1 General objective

To study the characterization of chronic renal failure using ultrasonography.

1.3.2 Specific objectives

To diagnose chronic renal failure using ultrasound.

To show kidneys size.

To demonstrate ultrasound findings in chronic renal failure.

To correlate kidney size with duration of disease.

1.4 Overview of study

The study contains five chapters. Chapter one which was an introduction deals with introduction, problem and objectives of the study. Chapter two deals with theoretical background and literature review. Chapter three about research methodology, which includes materials and method. Chapter four deals with result (data presentation). Chapter five includes discussion, conclusion and recommendation.

Chapter Two

Literature Review

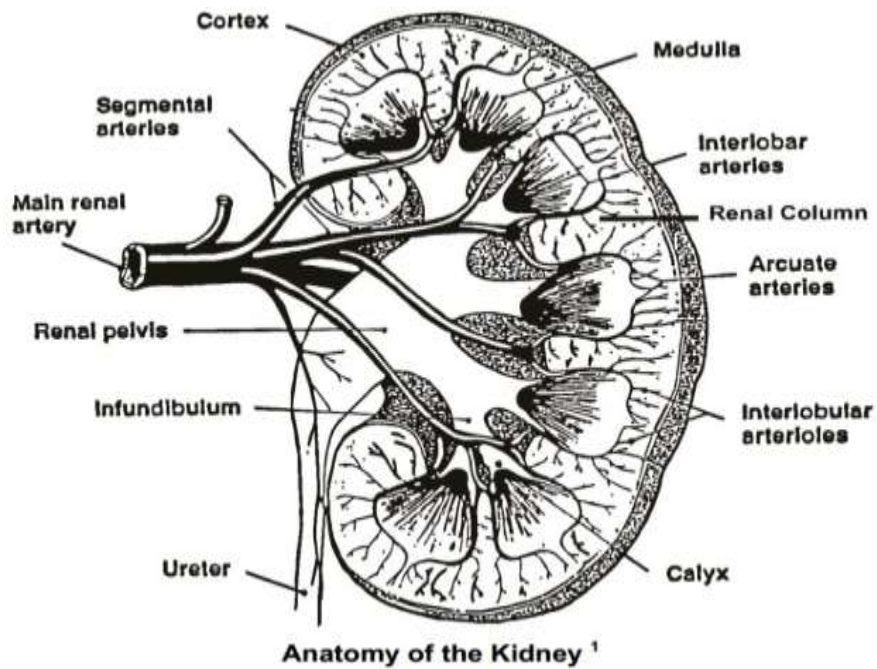
2.1 Theoretical Background

2.1.1 Anatomy of kidneys

The kidneys are two bean-shaped organs situated in the retroperitoneum on each side of the vertebral column. Their posterior surfaces are separated from the psoas major and the quadratus lumborum muscles by the posterior pararenal space. Each kidney consists of an upper and lower pole, anterior and posterior surfaces, a convex lateral margin and a concave medial margin. (Devin, 2005).

The long axis of the kidney runs obliquely and parallels the lateral border of the psoas major muscle. This means the upper poles are closer to midline than the lower poles. The upper poles of the kidneys are located more posterior than the lower poles. When you are scanning in the coronal plane, it is necessary to remember this orientation in order to obtain an adequate long axis scan. (Devin, 2005).

The medial margins of the kidneys are more anterior than the lateral margins. This means scans in the transverse plane will show the kidneys lying in an oblique plane relative to the midline of the body. The kidneys move inferiorly with inspiration and superiorly with expiration (Devin, 2005).



Figure(2. 1) Renal anatomy (Devin, 2005)

2.1.2 Relationships

Anterior Surface Relationships of the Right Kidney:

The Right Adrenal (Suprarenal) Gland sits on a small part of the anterior surface of the upper pole and upper part of the medial border. The adrenal gland is separated from the kidney by perirenal fat.

The Right Lobe of the Liver covers approximately three-quarters of the anterior surface of the kidney.

Anterior Surface Relationships of the Kidneys right adrenal gland, liver, Duodenum, Right colic (hepatic) flexure, Small Intestine,Ureter, IVC, aorta, superior mesenteric A.O. left adrenal, stomach, spleen, pancreas, jejunum and left colic (splenic) flexure.

The Descending Duodenum overlies a narrow area on the medial border. Other portions of the small Intestinecover a small portion of the lower anterior surface between the duodenum and the hepatic flexure of the colon.

The Hepatic Flexureof the Colon overlies the lower anterolateral surface of the kidney.

Anterior Surface Relationships of the Left Kidney:

The Left Adrenal (Suprarenal) Gland covers a small part of the medial border of the upper pole. The adrenal gland is separated from the kidney by perirenal fat. The Spleen overlies a large portion of the anterolateral surface of the upper pole.³ The Stomach is related to the anterior surface of the kidney between the splenic and suprarenal areas.

The Body/Tail of the Pancreas and Splenic Vessels are related to the middle of the anterior surface of the left kidney. The Splenic Flexure of the Colon is related to a portion of the anterolateral surface of the inferior half of the kidney. The Jejunum overlies the lower medial anterior surface. This is the first coil which occupies a recess between the left part of the transverse mesocolon and the left kidney. The rest of the jejunum lies in the umbilical region. The posterior surfaces are embedded in fat and are devoid of peritoneum. The diaphragm is related to the posterior surfaces of the upper poles of the kidneys.

A large pleural effusion located in the costodiaphragmatic recess may be demonstrated posterior to the upper pole of the kidney but separated from the kidney by the intervening diaphragm.

The costodiaphragmatic potential spaces extend inferiorly as far as the renal hila. The psoas major muscles have a relationship to the medial portions of the posterior surfaces of the kidneys.

The quadratus lumborum muscles are related to the central portions of the posterior surfaces. The aponeuroses of the transversus abdominis muscles are related to the lateral portions of the posterior surfaces. The right kidney rests upon the 12th rib and the left kidney against the 11th and 12th ribs.

Posterior Surface Relationships of the Kidneys aorta , IVC, left renal artery , right renal artery, right renal vein, psoas major muscle, quadratus lumborum muscle, transversalis fascia, 12th rib, area covered by diaphragm, inferior border of diaphragm, adrenal vessels and left gonadal vein

Lateral Border Relationships

The left kidney is related to the spleen via the splenorenal ligament. The right kidney is related laterally to the right lobe of the liver.

Medial Border Relationship

The hilum (hilus) is a slit on the medial border opposite the level of the first lumbar vertebra. The hilum leads to a central cavity called the renal sinus.

The adrenal gland is related to the medial border superior to the level of the hilum. The upper part of the ureter is related to the medial border below the level of the hilum (Devin, 2005).

2.1.3 General Structure of the Kidneys

A fibrous tissue capsule which is adherent to the renal parenchyma. The capsule provides a specular interface and is well demonstrated on the portions of the kidneys which are located at right angles to the central axis of the sound beam.

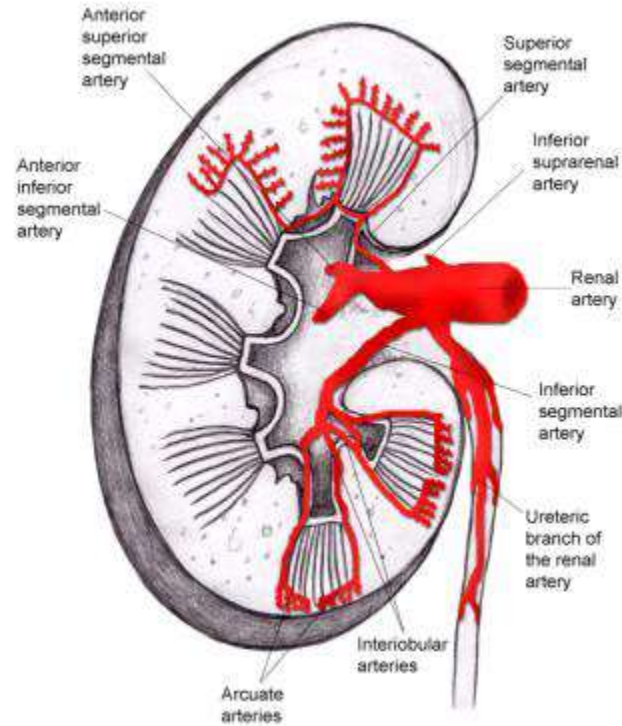
The renal parenchyma is divided into the cortex and the medulla. The renal cortex is the outer portion of the parenchyma and contains the functional units of the kidney called the nephrons. Columns of renal parenchyma extend centrally between the renal pyramids. The renal columns are also known as the septal cortex or the columns of Bertin. The columns contain the interlobar arteries and veins (Devin, 2005).

The renal medulla consists of conical masses of tissue called renal pyramids. The bases of the pyramids are directed toward the cortex and the apices of the pyramids converge toward the renal sinus. The apices form pointed processes called papillae. The papillae project into minor calyces which are cup-shaped structures that drain into a major calyx. Several major calyces drain into the renal pelvis. The pyramids consist of collecting tubules which convey urine from the nephrons into the minor calyces. Each lobe of a kidney will consist of a pyramid capped by cortical substance. The number of lobes is variable (Devin D, 2005).

The collecting system of the kidney consists of the renal pelvis which divides within the renal sinus into 2-3 large branches called major calyces. Each major calyx divides into several short branches called minor calyces. The expanded end of each minor calyx is moulded around 1-3 renal papillae. The major calyces are demonstrated on scans as fine extensions from the pelvis which end in cup-shaped structures near the apices of the pyramids. The major calyces are often referred to as the infundibula (singular - infundibulum) (Devin, 2005).

2.1.4 Blood Supply of the Kidneys

The renal artery divides into several segmental branches within the renal sinus. Some branches go posterior to the pelvis while others go anterior to the pelvis. The interlobar arteries enter the parenchyma through the renal columns and extend to the bases of the pyramids. At the junction of the cortex with the medulla the vessel arches across the base of the pyramid. This is known as the arcuate artery. It gives off branches called the interlobular arteries which supply the majority of the cortical nephrons via afferent arterioles. In summary, interlobar arteries run through the renal columns and become arcuate arteries as they run between the cortex and medulla at the base of the pyramids. The arcuate arteries give rise to the interlobular arteries which extend through the cortex as far as the capsule. The nephrons are supplied by afferent arterioles which are branches of the interlobular arteries. Venae rectae vessels drain the nephrons and coalesce to form the arcuate vein. Other small venules flow into the interlobular vein which in turn drains into the arcuate vein. The remainder of the venous drainage of the kidney corresponds to the arteries. The venous blood flow is of course in the opposite direction to the arterial flow (Devin, 2005).



Figure(2. 2) intrarenal arteries (Buturovic 2003)

2.2 physiology

2.2.1 Functions of the Kidneys

The kidneys eliminate water and are therefore the principal means of fluid volume regulation. Many metabolic wastes are eliminated by the kidneys; in particular, urea, uric acid, creatinine and ammonia which are wastes derived from the breakdown of protein. The kidneys also regulate the pH of plasma, the electrolyte pattern of extracellular fluid and play a role in the elevation of blood pressure (Burwin,2005).

2.3 Anomalies of Structure And Function

2.3.1 Ectopic Kidney

An ectopic kidney is a kidney located outside the renal bed. The kidney can be located anywhere between the pelvis and upper abdomen. However, most ectopic kidneys are located in the pelvis and are called pelvic kidneys. Often ectopic kidneys lie on an unusual plane which may impair the normal drainage of the organ.

2.3.2 Crossed Fused Ectopia

“In crossed renal ectopia, both kidneys are found on the same side. In 85% to 90% of cases, the ectopic kidney will be fused to the other kidney.”³ Usually the lower pole of the normally positioned kidney is fused to the upper pole of the ectopic kidney. The pelvis of the ectopic kidney is directed anteriorly whereas, the normal kidney may have the standard orientation or have its pelvis also directed anteriorly. The ectopic ureter crosses midline and inserts on the correct side of the bladder. Sonographically, the fused kidney has a normal transverse diameter but is unusually long. There is often a notch defect at the fusion point. There are two separate renal sinuses and pelvis and the ureteropelvic junctions are normally located. The opposite kidney is absent. “Horseshoe kidney is the most common renal fusion anomaly, with a prevalence of approximately 1:400 births and a male predominance. The lower poles of the kidneys fuse and this fused area is called the isthmus. The hilus of each kidney looks forwards and the ureters always pass in front of the connecting piece which lies across the vertebral column caudal to the inferior mesenteric artery. (The inferior mesenteric artery arrested the ascent of the fused kidneys) The blood supply is abnormal and often is from regional vessels. Their abnormal position often impairs drainage resulting in a higher incidence of infection, obstruction and stone formation. On ultrasound, the isthmus can be seen anterior to the aorta and IVC; the low position and abnormal renal alignment will be seen.

2.3.3 Unilateral Renal Agenesis

This is congenital absence of a kidney. There is an empty renal fossa and the adrenal gland appears flattened. The solitary kidney on the opposite side may be enlarged due to compensatory hypertrophy. The differential diagnosis should include an ectopic kidney and a hypoplastic kidney.

2.3.4 Hypoplastic Kidneys

These are small, underdeveloped kidneys. If unilateral, the opposite kidney may be enlarged due to compensatory hypertrophy. Sonographically the kidney appears small but otherwise normal.

2.3.5. Duplicated Collecting System

This is a very common cause of unilateral renal enlargement. Sonographically The scan demonstrates a large, cortical area between two renal sinuses and an enlarged kidney.

2.3.5.1 Incomplete duplication is most common and involves two complete renal pelvises with fusion of ureters so only one ureter inserts into the bladder. The bladder insertion site is normal. Since nondilated ureters are seldom seen on US, precise classification may not be possible sonographically. “Incomplete duplication generally has no pathologic consequences.

2.3.5.2 Complete duplication consists of two renal pelvises and two ureters. The upper moiety (portion) ureter will have an ectopic insertion into the bladder.

2.3.6. Extrarenal Pelvis

The renal pelvis is not within the renal sinus but instead is located medially in the perinephric fat. Lower surrounding tissue pressure permits chronic dilatation of the pelvis

2.3.7. (Persistent) Fetal Lobation

Normally lobation “disappears at birth or shortly thereafter. If it persists beyond this time, it is an inconsequential anatomic variant. Occasionally, if it is palpated, it may be misdiagnosed as cystic disease. This is easily identified with an ultrasound scan as prominent indentations on the surface of the kidneys with the remainder of the kidney appearing normal.

2.3.8. Junctional Parenchymal Defect

Each kidney is formed embryologically from upper and lower units of parenchyma that fuse along an oblique line. The junction points of these limits may persist as a prominent indentation of the cortical surface. The parenchymal defect is a triangular shaped echogenic focus best demonstrated on longitudinal scans.

2.3.9. Interrenicular Septum

The interrenicular septum is the site of fusion of the two embryological renal units. It is also called the junctional line and is more common in the right kidney. “The inter-renicular septum is seen in longitudinal view as an oblique, echogenic linear band through the medial aspect of the kidney connecting the junctional parenchymal defect to the renal hilum.(Devin,2005).

2.3.10. Renal Sinus Lipomatosis

This is a heavy deposition of fat in the renal sinus. With increasing age, the amount of renal parenchyma decreases whereas the amount of renal sinus fat increases. The cortex will be thinner than in a younger adult and the highly echogenic sinus will be larger. The overall size of a kidney decreases with age.

2.3.11. Dromedary Hump

Either kidney, but more commonly the left, can demonstrate a lateral bulge at its midportion. If the internal architecture is normal, the variant is not clinically significant.(Devin,2005).

2.3.12. Renal Column Hypertrophy

This is a common anatomic variant and is a double layer of renal cortex that is folded toward the center of the kidney, displacing a portion of the renal sinus. The echo texture is exactly the same as the adjacent renal cortex, and the width of the mass is twice as great as the adjacent renal cortical

thickness. Renal column hypertrophy is also known as hypertrophy of the septal cortex or a prominent column of Bertin.(Devin,2005).

2.3.13. Ureteropelvic Junction Obstruction (UPJ)

Congenital narrowing at the junction of the ureter and the renal pelvis is a common anomaly. It is twice as common in men and the left kidney is affected twice as often. It is bilateral in one third of patients. Innocuous UPJ narrowing causes minimal pyelocaliectasis and is associated with normal renal parenchymal thickening and a normal sized kidney. The ureter is of normal caliber. There is an increased incidence of contralateral multicystic dysplastic kidney and renal agenesis. When a patient with UPJ narrowing becomes significantly obstructed, there will be moderate to severe urinary tract distention and parenchymal thinning. UPJ obstruction is the most common obstructive cause of renal pelvic dilatation.(Devin,2005).

2.3.14. Medullary Sponge Kidney (MSK)

MSK is also called renal collecting tubular ectasia. MSK is a congenital defect of the kidney leading to cystic dilatation of the renal collecting tubules. Its inheritance is uncertain and is therefore considered familial rather than inherited. The disease is present at birth but usually does not become apparent until adulthood. Infections, calculi and hematuria are complications of MSK. Sonographically, in adults, there are enlarged hyperechoic pyramids caused by calcium deposition. In children, the sonogram is usually normal(Devin,2005).

2.4 Renal Pathology

2.4.1 Renal cystic disease

2.4.1.1 Simple Renal Cysts

These are true cysts that have a serous epithelial lining and are fluid filled, benign cortical masses.(Devin,2005).

Sonographic appearance They meet all the ultrasound criteria of a simple cyst: they are spherical, anechoic, thin-walled and have accentuated posterior

enhancement. These lesions range in size from a few millimeters to several centimeters.(Devin,2005).

2.4.1.2 Atypical Renal Cysts

An atypical renal cyst is any cyst that does not meet the strict criteria of a simple cyst. Many atypical cysts are simple cysts complicated by hemorrhage or infection.

Sonographic appearances Complicated (i.e. atypical) cysts may have thick walls, contain septations and generate low levels of echogenicity from particulate matter associated with hemorrhage or infection. The echogenic cyst contents may be diffuse or show dependent layering. The cyst wall may be calcified and is considered a benign finding if all other US criteria for simple cyst are met.Thick walled circular lesions are associated with abscesses and cystic renal tumors, therefore, further investigation would be required.(Devin,2005).

2.4.1.3 Parapelvic Cysts

Parapelvic cysts are cysts of the renal sinus. Most parapelvic cysts are asymptomatic.

Sonographic Appearances Parapelvic cysts may not appear anechoic due to beam width averaging. Acoustic enhancement may be difficult to demonstrate because of the highly reflective nature of the renal sinus in which they are located.(Devin,2005).

2.4.1.4 Acquired Uremic Cysts, Adenomas and Carcinomas

“Cysts and neoplasms have been identified with remarkable frequency in the end stage kidneys of chronic hemodialysis or peritoneal dialysis patients. Cysts generally do not become visible until the patient has completed 3 years of dialysis. Thereafter, they increase rapidly in number to a prevalence level approaching 100%.These cysts are prone to hemorrhage, rupture and the creation of perinephric hematomas.

Sonographic Appearances typical simple cysts appear within the cortex of an endstage kidney. The kidney may be difficult to visualize because end-stage kidneys are typically shrunken and highly echogenic blending with the echogenic perirenal fat. (Devin, 2005).

2.4.1.5 Multicystic Dysplastic Kidney

Multicystic dysplastic kidney disease (MCDK) is a congenital, nonhereditary, cystic renal disease. MCDK is typically unilateral, affecting a single kidney in its entirety, but may be bilateral or segmental.

Sonographic appearances characteristically, the kidney is large and filled with cysts of various sizes. The cysts do not communicate and appear benign. (Devin, 2005).

2.4.1.6 Autosomal Recessive Polycystic Renal Disease (ARPRD)

“Autosomal recessive polycystic kidney disease is an inherited disorder characterized by nephromegaly, microscopic or macroscopic cystic dilatation of the renal collecting tubules, and periportal hepatic fibrosis.

Sonographic Appearances are kidneys are bilaterally and symmetrically enlarged. The parenchyma is highly echogenic due to multiple microscopic cystic interfaces. The dilated collecting ducts extend from the cortex through the medulla, so that the normal sharp distinction between echogenic renal cortex and anechoic pyramids is lost. (Devin, 2005).

2.4.1.7 Autosomal Dominant Polycystic Renal Disease (ADPRD)

This is an autosomal dominant disorder which often lies latent for many years and then manifests itself in the third, fourth, or fifth decades in what had appeared to be normal renal parenchyma. ADPRD consists of numerous cystic lesions in an enlarged kidney.

Sonographic Appearances in the early stages, the kidneys appear enlarged and contain more cysts than expected for the patient's age. The cysts involve both the cortex and medulla. (Devin, 2005).

2.4.1.8 Medullary Cystic Disease

Medullary cystic disease is a hereditary disorder resulting in cysts located within the medullary portions of the kidney.

Sonographic Appearances are small echogenic kidneys with numerous small cysts in the central portion of the kidney or at the corticomedullary junction. The cysts range in size from 1 to 10 mm.(Devin,2005).

2.4.2. Calyceal Diverticulum

This is an outpouching from the calyx. Stasis of urine may occur predisposing the patient to infection and stone formation. The diverticulum can project into the renal parenchyma.(Devin,2005).

2.4.3 Hydronephrosis

Hydronephrosis refers to dilatation of the renal collecting system most frequently caused by incomplete or complete obstruction. Hydroureter is dilatation of the ureter also caused by complete or incomplete obstruction.(Devin,2005).

The role of ultrasound is to detect the presence or absence of hydronephrosis; estimate the amount of residual cortex present and to detect the presence of a pelvic mass or other etiology.

2.4.4 Renal Calculus Disease

Urolithiasis is most prevalent in males aged 20-40 years. Calculi can form in any part of the urinary tract but most form in the kidneys. They may be clinically silent associated with flank pain. Hematuria (gross or microscopic) and renal colic are most often associated with ureteric calculi. Stones can occur within any part of the kidneys - the renal cortex, medulla, vessels, calyces or renal pelvis. Most calculi arise in the collecting system. Stone formation may be idiopathic or associated with stasis (stagnation) of urine, prolonged ingestion of stone forming substances, chronic urinary infections and climate conditions associated with dehydration. Stasis also predisposes the patient to infection.

Sonographic appearance ultrasound demonstrates calculi as highly echogenic structures regardless of chemical composition. Shadow detection posterior to the stone depends on stone size, transducer frequency, and transducer focal zone. Tiny calculi will not shadow if they are smaller than the focal zone.

2.4.5 NEOPLASMS

2.4.5.1 A. BENIGN LESIONS

2.4.5.1.1 Angiomyolipoma (AML)

AML is a benign solid tumor containing variable amounts of blood vessels (angio), smooth muscle (myo) and fat (lipoma).

sonographic appearances depend upon the predominance of one of the three components. Typically, AMLs are extremely hyperechoic indicating the predominance of fat however, if muscle or vascular components predominate the lesion may be hypoechoic. Shadowing is demonstrated in 33% of AMLs.

2.4.5.1.2 Oncocytoma

Oncocytoma is a benign solid renal tumor occurring most often in men in their 60's. It is usually asymptomatic and an incidental finding.

Sonographically, the tumor is solid, homogeneous and generates low levels of echogenicity. A stellate central hyperechoic scar is seen in about 25% of cases and then only in lesions greater than 3 cm.

2.4.5.2 B. Malignant Lesions

2.4.5.2.1 Renal Cell Carcinoma (RCC)

This is a primary tumor of the renal parenchyma thought to originate from the renal tubular epithelium. It is also called a hypernephroma or a renal adenocarcinoma.

ultrasound appearances of a renal pelvic TCC are characteristically those of a solid, homogeneous, hypoechoic or isoechoic mass centrally located within the renal sinus.

2.4.5.2.2 Renal Lymphoma

The kidney does not contain lymphoid tissue, therefore lymphomatous involvement of the kidney is metastatic in origin and occurs by hematogenous dissemination or direct extension of retroperitoneal disease.

Sonographic Appearances

Focal parenchymal involvement, which is most common (60%), consists of multiple, small (1-3 cm), bilateral, solid, homogeneous, hypoechoic tumors. It is rare for renal lymphomatous masses to be unilateral or to demonstrate calcification.

Direct invasion (25-30%) into the renal sinus from retroperitoneal lymph node masses is typically nodular, hypoechoic and homogeneous. The mass may cause hydronephrosis. Typically, the large retroperitoneal adenopathy encircles the renal artery and vein, IVC and aorta. "The blood vessels remain patent despite encasement, a finding that is typical of lymphoma.

A solitary homogeneous, hypovascular solid mass may be seen in 10-20% of renal lymphomas.¹ They can become large - 15 cm in size and be indistinguishable sonographically from RCC.

Diffuse infiltration globally enlarges the kidney with minimum or no alteration in the shape. Invasion of the renal sinus results in the loss of the echogenic central echo complex.

Perirenal involvement occurs when the disease invades the perirenal space and surrounds the kidney. The kidney may not be directly involved. Sonographic appearance: This appears as a hypoechoic mass or rind partially or completely surrounding the kidney. "This pattern of involvement is virtually pathognomonic of lymphoma, but is uncommon." The appearances may be confused with hematoma in the perirenal space.

2.4.5.2.3 Leukemia

“Lymphoma and leukemia have a predilection for infiltration of the renal parenchyma and often cause focal or diffuse renal enlargement.” Acute lymphoblastic leukemia is the most common form to involve the kidney.

Sonographically, diffuse, bilateral renal enlargement is most common with loss of corticomedullary definition. The parenchyma may have increased or decreased echogenicity. There may be distortion of the central echo complex. Discrete renal masses are uncommon but when they occur they resemble lymphoma. Renal, subcapsular or perinephric hemorrhage may be demonstrated, as these patients are prone to bleed.

2.4.5.2.4 Nephroblastoma

A nephroblastoma is the most common renal tumor in children. It is seen most commonly in children between 2 to 3 years of age. A Wilms' tumor is a rapidly growing malignant tumor of the kidneys, it is also known as, Wilms' embryoma or embryonal carcinoma, sonographically characteristically a large, intrarenal, solid mass with a well-defined margin or pseudocapsule of fibrous tissue and compressed renal parenchyma. The tumor may be homogeneous or heterogeneous,

2.4.6 Acute Renal Failure (ARF)

Renal failure is considered acute if it develops over days or weeks, and chronic if it spans months or years. Acute or chronic renal failure may result from insufficient renal perfusion (prerenal causes), intrinsic renal disease (renal causes), or obstructive uropathy (postrenal causes). In the setting of ARF, the main purpose of the US study is to exclude hydronephrosis (Devlin D, 2005).

2.4.7 Chronic Renal Failure (CRF):

Renal failure, also known as kidney failure or renal insufficiency, is a medical condition in which the kidneys fail to adequately filter waste products from the blood. The two main forms are acute kidney

injury, which is often reversible with adequate treatment, and chronic kidney disease, which is often not reversible. In both cases, there is usually an underlying cause.

Kidney failure is mainly determined by a decrease in glomerular filtration rate, which is the rate at which blood is filtered in the glomeruli of the kidney. The condition is detected by a decrease in or absence of urine production or determination of waste products (creatinine or urea) in the blood. Depending on the cause, hematuria (blood loss in the urine) and proteinuria (protein loss in the urine) may be noted. In kidney failure, there may be problems with increased fluid in the body (leading to swelling), increased acid levels, raised levels of potassium, decreased levels of calcium, increased levels of phosphate, and in later stages anemia. Bone health may also be affected. Long-term kidney problems are associated with an increased risk of cardiovascular disease. Kidney failure can be divided into two categories: acute kidney injury or chronic kidney disease. The type of renal failure is differentiated by the trend in the serum creatinine; other factors that may help differentiate acute kidney injury from chronic kidney disease include anemia and the kidney size on sonography as chronic kidney disease generally leads to anemia and small kidney size.

2.4.7.1 Signs and symptoms:

Symptoms of kidney failure include the following: High levels of urea in the blood, nausea, weight loss, nocturnal urination, more frequent urination, or in greater amounts than usual, with pale urine, less frequent urination, or in smaller amounts than usual, with dark coloured urine, blood in the urine Pressure, or difficulty urinating, unusual amounts of urination, usually in large quantities, a buildup of phosphates and potassium in the blood.

2.4.7.2 Causes:

Chronic kidney disease (CKD) has numerous causes. The most common causes of CKD are diabetes mellitus and long-term,

uncontrolled hypertension. Polycystic kidney disease is another well-known cause of CKD. The majority of people afflicted with polycystic kidney disease have a family history of the disease. Other genetic illnesses affect kidney function, as well. Overuse of common drugs such as ibuprofen, and acetaminophen (paracetamol) can also cause chronic kidney damage. Some infectious diseases, such as hantavirus, can attack the kidneys, causing kidney failure.

Laboratory Value:

Blood Urea Nitrogen: The normal 11 to 23 mg/dL, produced from the breakdown of food proteins, elevated in urinary obstruction, renal dysfunction, or dehydration and Decreased levels associated with overhydration, pregnancy, liver failure, decrease in protein intake, and smoking.

The four basic examinations of the urinary tract are the: intravenous urogram (IVU); computed tomography (CT); nuclear medicine (NM) or radionuclide studies and sonography. (Devin, 2005).

ken before as well as after an intravenous contrast medium is given. If the kidneys are functioning they will collect and excrete the contrast agent thus enabling an evaluation of renal function. (Devin, 2005).

Ultrasound: Sonography is frequently called upon to rule out hydronephrosis in patients with renal failure since ultrasound is supreme in showing fluid filled structures. It also provides information regarding retroperitoneal masses or fluid collections that may be causing the urinary problems. Sonography does not require renal function in order to be effective. (Devin, 2005).

Sonography is used primarily for anatomy; the IVU and CT for anatomy and function and NM for function (Burwin, 2005).

Normal Sonographic Appearances of Adult Kidneys:

The kidney is an ellipsoid structure when demonstrated in its long axis. The capsule is an echogenic white boundary separating the kidney from adjacent structures anteriorly and the musculature posteriorly. Perirenal fat is highly echogenic. The renal cortex is homogeneous, fine textured and poorly echogenic. The cortex is equal to, or less echogenic than the normal liver. The renal columns (septal cortex or columns of Bertin) are the projections of cortex that extend between the pyramids. The columns are sonographically identical to the peripheral cortex. The medulla consists of pyramids which are anechoic structures with their bases adjacent to the renal cortex and their apices directed towards the renal sinus. The renal sinus is the most echogenic portion of the adult kidney. This echogenic area is called the central echo complex. In the nonhydrated state the renal pelvis is collapsed.

2.5 Previous studies

The corticomedullary differentiation was mainly disturbed, the echogenicity of renal parenchyma and cortex increased in all types of renal parenchymal disease. The corticomedullary differentiation was mainly disturbed in acute parenchymal disease (69.04%), loss in chronic end stage parenchymal disease (85%), and there was significant difference (p-value 0.0001). (Gareeballah, 2015).

Cysts are frequently found in chronic kidney disease (CKD) and they have different prognostic significance depending on the clinical context. Simple solitary parenchymal cysts and peripelvic cysts are very common and they have a clinical significance. Acquired cystic kidney disease, finally, is secondary to progressive structural end stage kidney remodeling and may be associated with renal cell carcinoma. (Meola, 2016).

Evaluation of renal size by sonography has become common practice when treating patients with kidney disease. A reduction in renal size has been used as an indicator of chronic kidney diseases. Furthermore, according to certain studies, it is possible to use renal size to predict the renal function in healthy individuals or patients with chronic kidney disease. (Zhangw, 2014).

Many chronic renal diseases lead to the final common state of decrease in renal size, parenchymal atrophy, sclerosis and fibrosis. The frequency of renal cysts increases with the progression of disease (Buturovic, 2003).

Chapter Three

Materials and Methods

3.1 Material

The data used in this study were collect from department of ultrasound of AlmekNimer Hospital.

3.1.1 Subject

Atotal of 50 patients referred to renal dialysis center in the period of the study, the data include gender,age,occupation,changing in the kidneys, acquired cysts.

3.1.2. Patients preparation

none. Transducer (curved) for mid large patient 3.5 MHZ & 5MHZ for very thin patient.

3.1.3. Patient position

Supine, left lateral oblique, left lateral decubitus.

3.1.4 Machine used

The study uses only one machine,which is FUKUDA DENSHY (Japanese model).

3.2 Method

Using curvilinear probe (3.5-5MH),selection of frequency according to the patient weight,the data analysis program used in this study is SPSS

3.2.1 Technique used

The examination begins with the patient in the supine position. Scans are performed in the sagittal and transverse planes from the anterior approach using the liver and spleen as acoustic windows. Various maneuvers may enhance demonstration of the kidneys: left lateral decubitus or lateral oblique positions for the right kidney and right lateral decubitusor lateral oblique positions for the left kidney. Coronal longitudinal and transverse scansmay also be obtained and are recommended for evaluating the renal pelvis and proximal ureter on hydronephrotic patients. The highest frequency

transducer permitting adequate penetration is used. This is usually in the 3 to 5 MHz range. A phased array sector probe with its small footprint permits subcostal and intercostal scanning (Burwin,2005).

3.2.2 Image interpretation

All patients included in the study were scanned by me(the researcher) and confirmed y sonologist the department.

3.2.3 data analysis

The data was statistically performed by using computer programs mainly SPSS.

3.2.4 duration

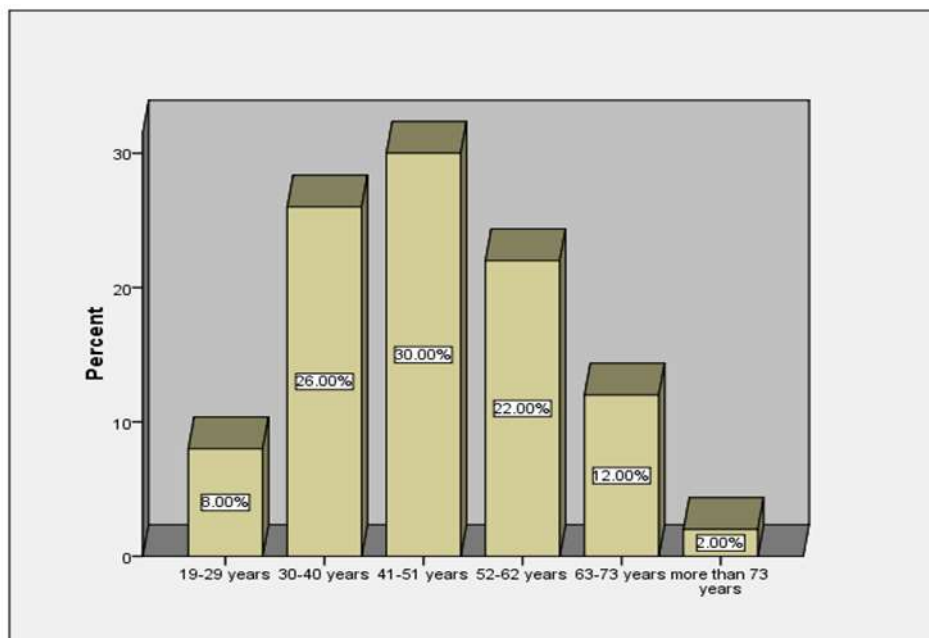
during the period from the September to December 2018.

Chapter Four

Results

Table(4. 1) frequency distribution of age

	Frequency	Percent	Valid Percent	Cumulative Percent
19-29	4	8.0	8.0	8.0
30-40	13	26.0	26.0	34.0
41-51	15	30.0	30.0	64.0
52-62	11	22.0	22.0	86.0
63-73	6	12.0	12.0	98.0
more than 73	1	2.0	2.0	100.0
Total	50	100.0	100.0	

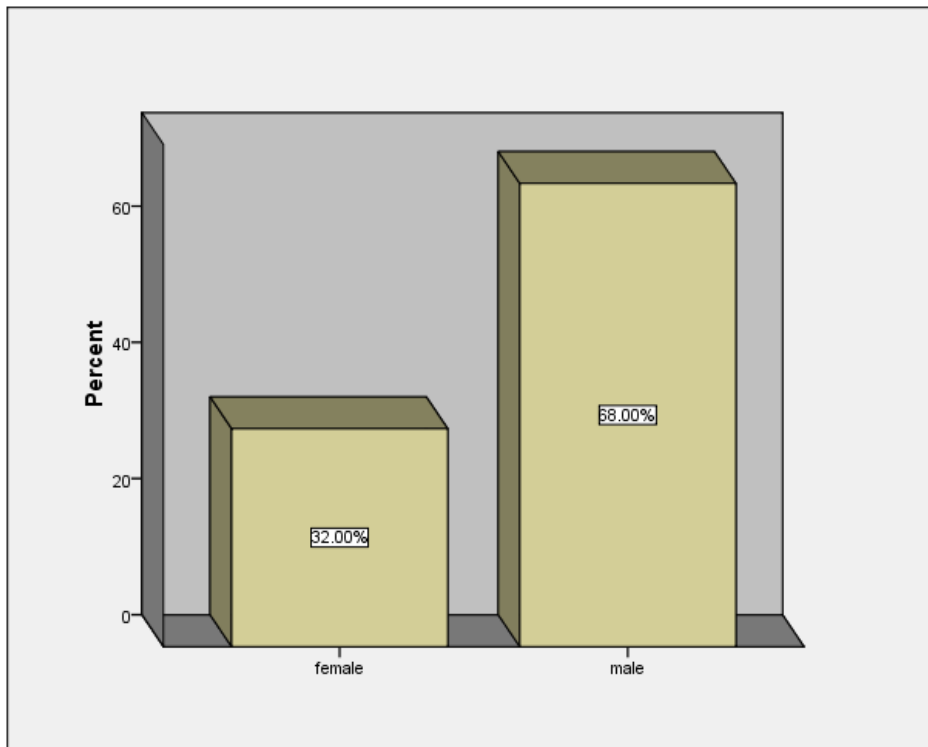


Figure

Figure(4. 1) frequency distribution of age

Table(4. 2) frequency distribution of gender

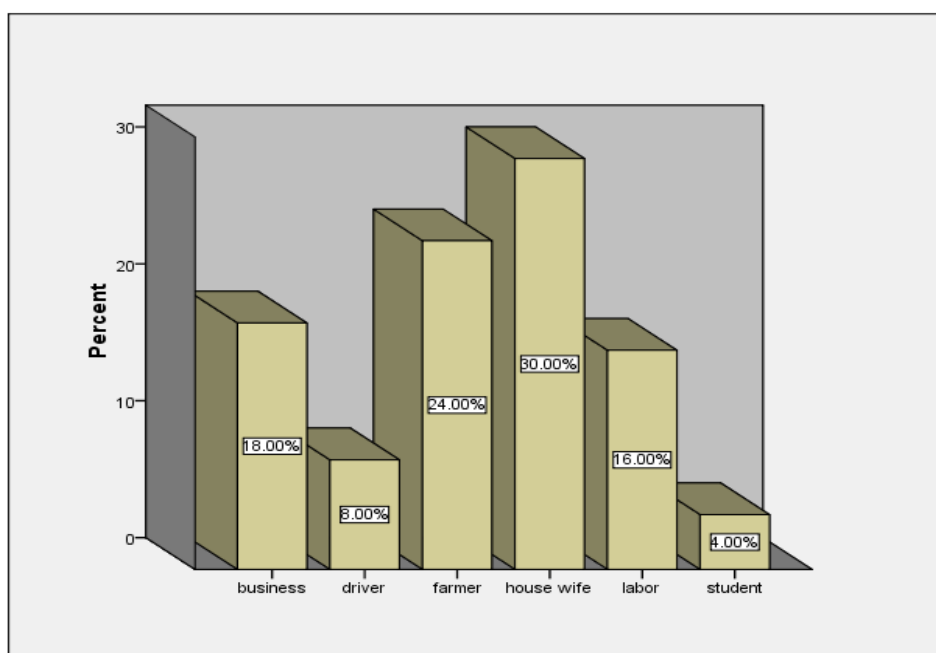
Gender	Frequency	Percent	Valid Percent	Cumulative Percent
Female	16	32.0	32.0	32.0
Male	34	68.0	68.0	100.0
Total	50	100.0	100.0	



Figure(4. 2) frequency distribution of gender

Table(4. 3) frequency distribution of occupation

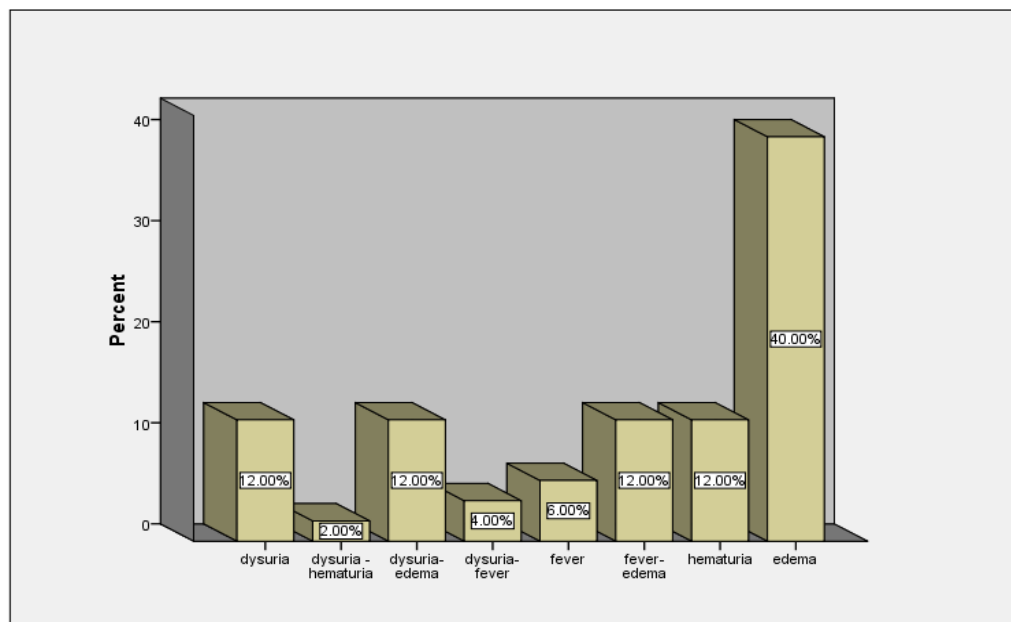
Occupation	Frequency	Percent	Valid Percent	Cumulative Percent
Business	9	18.0	18.0	18.0
Driver	4	8.0	8.0	26.0
Farmer	12	24.0	24.0	50.0
house wife	15	30.0	30.0	80.0
Labor	8	16.0	16.0	96.0
Student	2	4.0	4.0	100.0
Total	50	100.0	100.0	



Figure(4. 3) frequency distribution of occupation

Table(4. 4) frequency distribution of complains

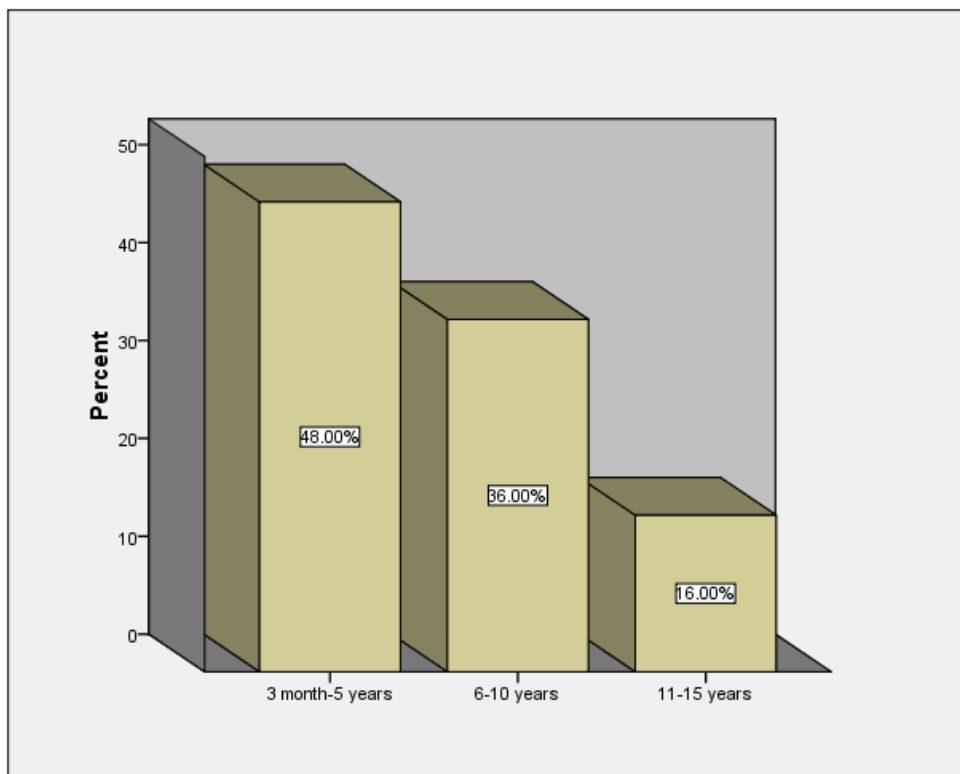
Complains	Frequency	Percent	Valid Percent	Cumulative Percent
Dysuria	6	12.0	12.0	12.0
dysuria -hematuria	1	2.0	2.0	14.0
dysuria- edema	6	12.0	12.0	26.0
dysuria-fever	2	4.0	4.0	30.0
Fever	3	6.0	6.0	36.0
fever- edema	6	12.0	12.0	48.0
Hematuria	6	12.0	12.0	60.0
Edema	20	40.0	40.0	100.0
Total	50	100.0	100.0	



Figure(4. 4) frequency distribution of complains

Table(4. 5) frequency distribution of duration

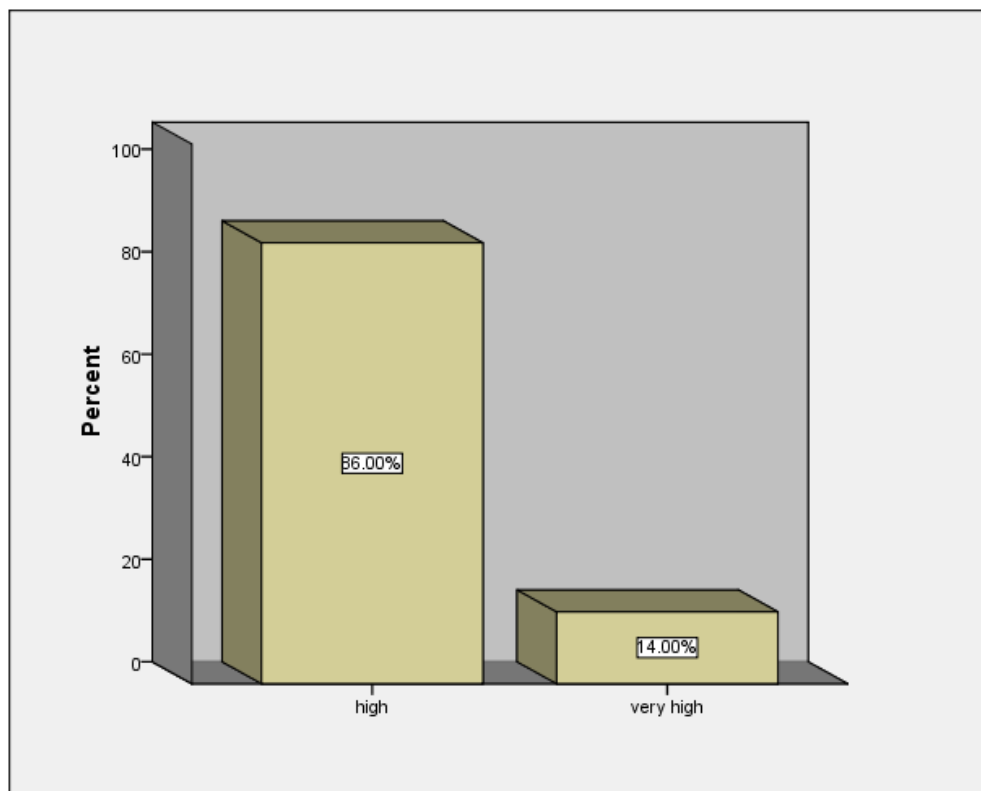
Duration	Frequency	Percent	Valid Percent	Cumulative Percent
3 month-5 years	24	48.0	48.0	48.0
6-10 years	18	36.0	36.0	84.0
11-15 years	8	16.0	16.0	100.0
Total	50	100.0	100.0	



Figure(4. 5) frequency distribution of duration

Table(4. 6) frequency distribution of urea

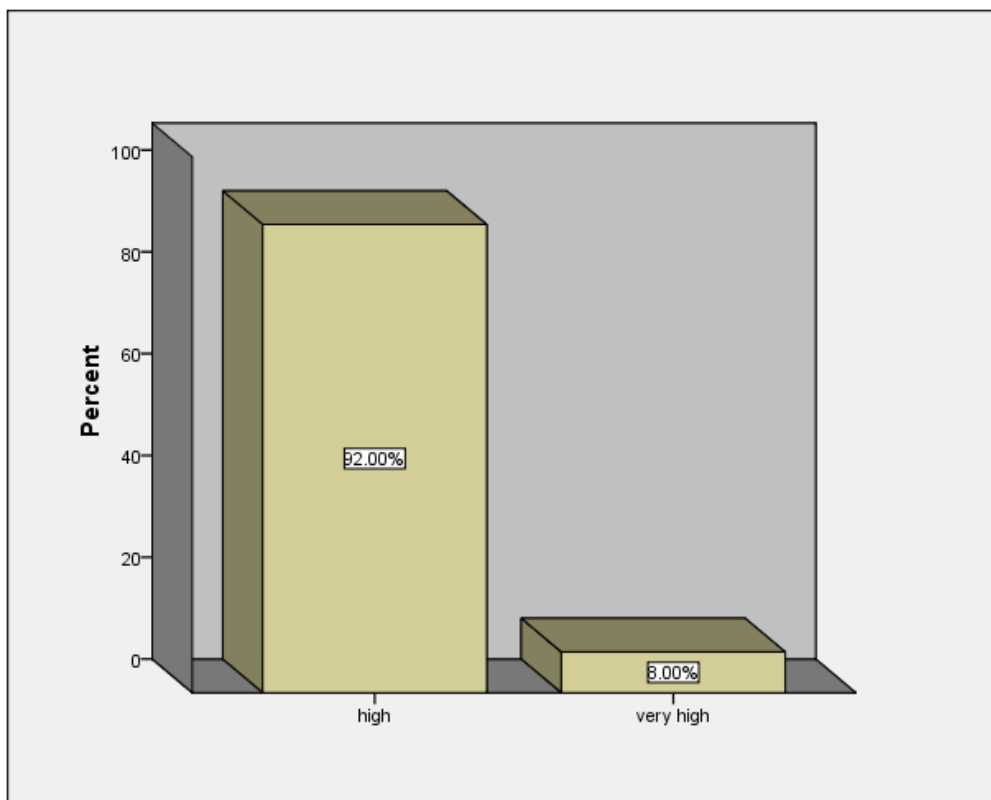
Urea	Frequency	Percent	Valid Percent	Cumulative Percent
High	43	86.0	86.0	86.0
very high	7	14.0	14.0	100.0
Total	50	100.0	100.0	



Figure(4. 6) frequency distribution of urea

Table(4. 7) frequency distribution of criatinine

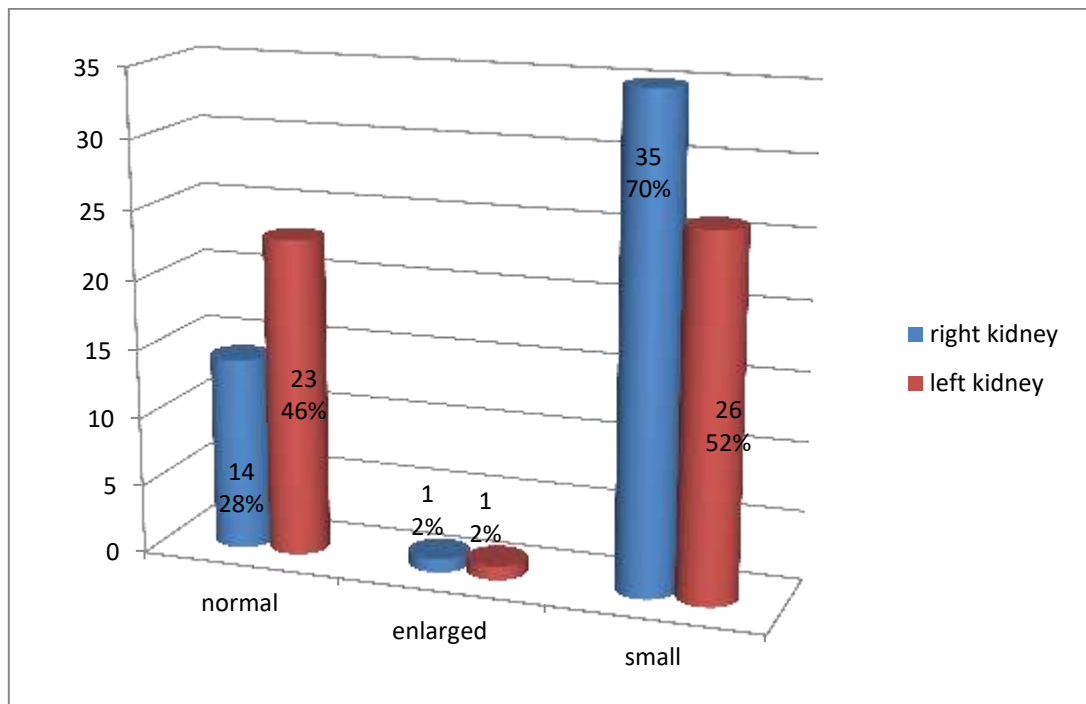
Criatinine	Frequency	Percent	Valid Percent	Cumulative Percent
High	46	92.0	92.0	92.0
very high	4	8.0	8.0	100.0
Total	50	100.0	100.0	



Figure(4. 7) frequency distribution of criatinine

Table(4. 8) frequency distribution of size of both kidneys

Size	Frequency		Percent	
	Right	Left	Right	Left
Normal	14	23	28.0	46.0
Enlarged	1	1	2.0	2.0
Small	35	26	70.0	52.0
Total	50	50	100.0	100.0



Figure(4. 8) frequency distribution of size of both kidneys

Table(4. 9) descriptive statistic (min, max, mean \pm std) for age, duration and measurements of both kidneys

Variables	N	Minimum	Maximum	Mean	Std. Deviation
Age	50	19	75	46.84	12.500
Duration	50	.25	15.00	6.1980	4.02604
Right kidney length	50	3.00	10.45	6.7542	1.87645
Right kidney width	50	1.00	5.14	2.9784	1.04121
Left kidney length	50	3.92	14.42	7.4884	2.13102
Left kidney width	50	1.22	7.44	3.5060	1.22198
Valid N (listwise)	49				

Table(4. 10) frequency distribution of shape of right kidney

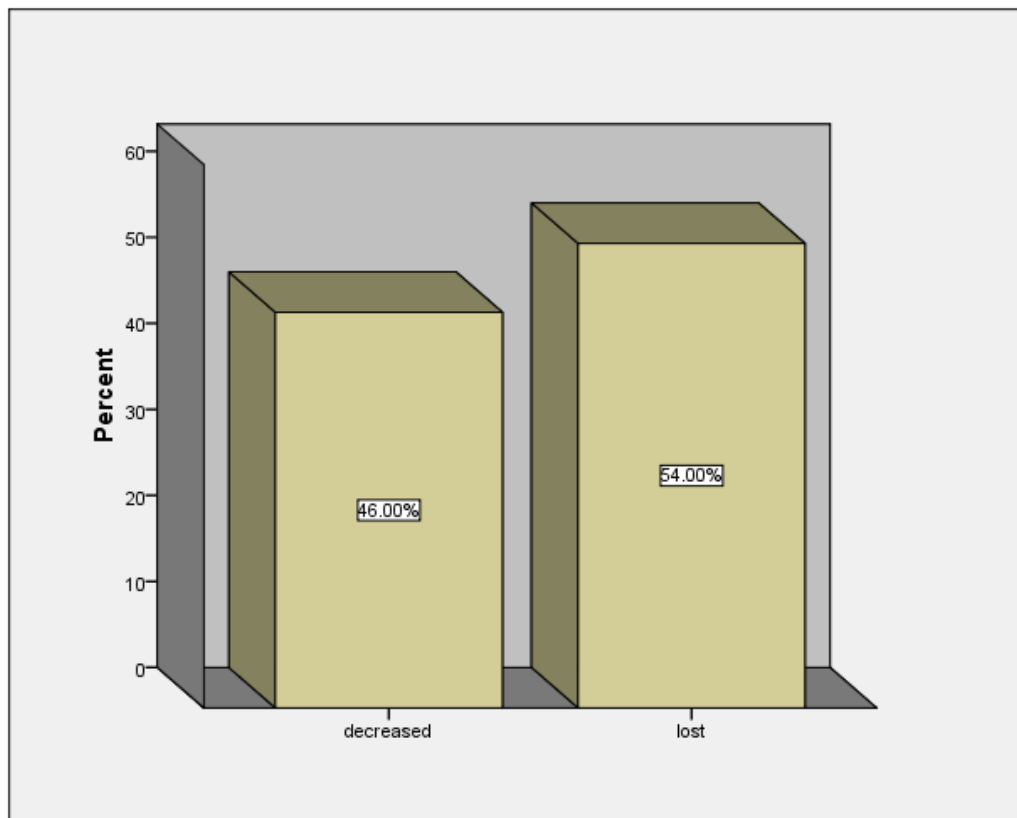
Right Shape	Frequency	Percent	Valid Percent	Cumulative Percent
abnormal	31	62.0	62.0	62.0
Normal	19	38.0	38.0	100.0
Total	50	100.0	100.0	

Table(4. 11) frequency distribution of shape of left kidney

Left shape	Frequency	Percent	Valid Percent	Cumulative Percent
abnormal	32	64.0	64.0	64.0
Normal	18	36.0	36.0	100.0
Total	50	100.0	100.0	

Table(4. 12) frequency distribution of CMD

CMD	Frequency	Percent	Valid Percent	Cumulative Percent
decreased	23	46.0	46.0	46.0
Lost	27	54.0	54.0	100.0
Total	50	100.0	100.0	

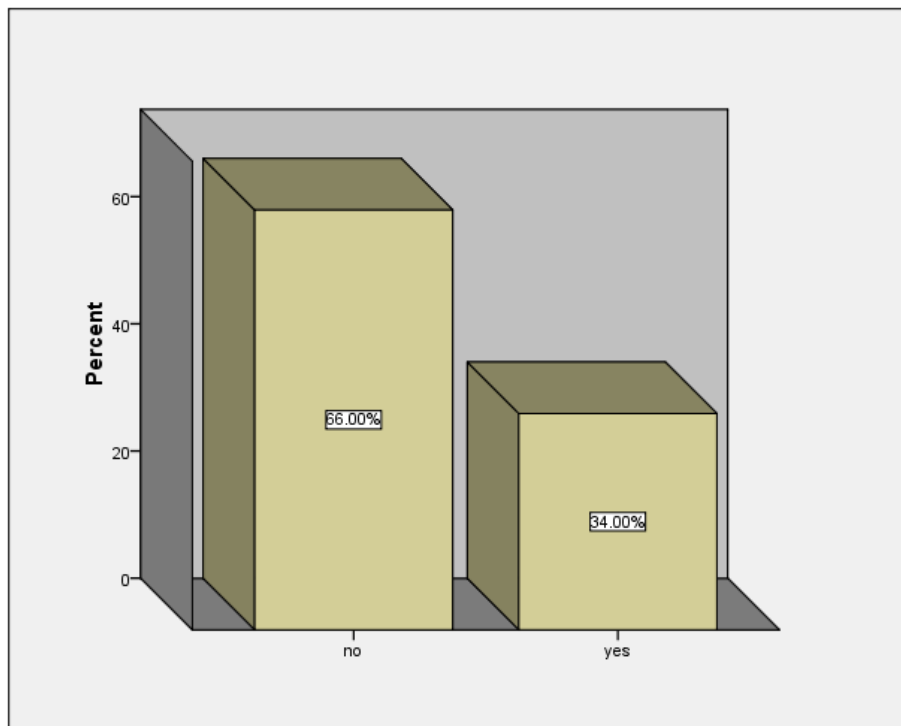


Figure(4. 9) frequency distribution of CMD

Table(4. 13) frequency distribution of Cysts

Cyst	Frequency	Percent	Valid Percent	Cumulative Percent
no	33	66.0	66.0	66.0
yes	17	34.0	34.0	100.0
Total	50	100.0	100.0	

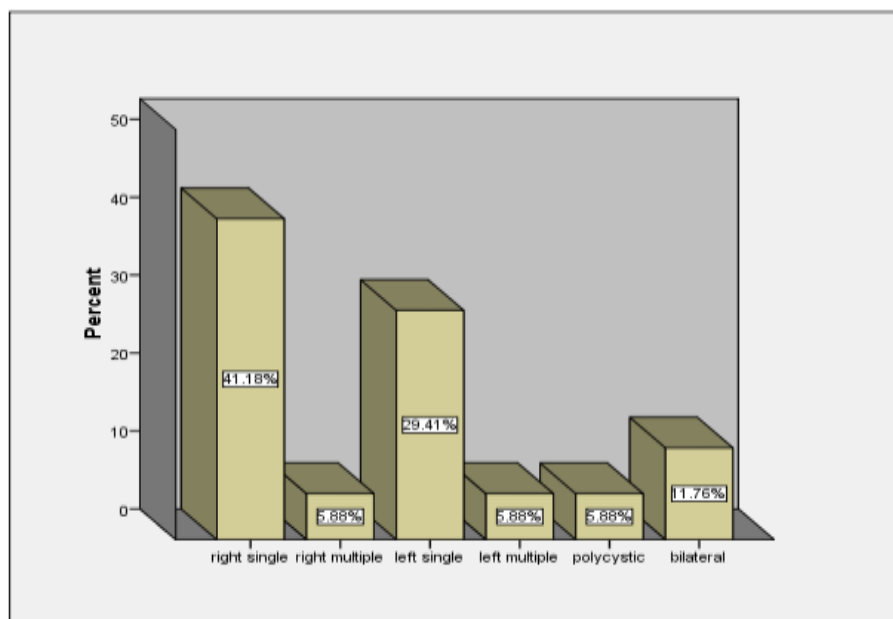
\



Figure(4. 10) frequency distribution of Cyst

Table(4. 14) frequency distribution of Cyst side and number

Cyst side and number	Frequency	Percent	Valid Percent	Cumulative Percent
right single	7	14.0	41.2	41.2
right multiple	1	2.0	5.9	47.1
left single	5	10.0	29.4	76.5
left multiple	1	2.0	5.9	82.4
Polycystic kidneys	1	2.0	5.9	88.2
bilateral	2	4.0	11.8	100.0
Total	17	34.0	100.0	



Figure(4. 11) frequency distribution of Cyst side and number

Table(4. 15) cross tabulation duration and CMD

Duration	CMD		Total
	decreased	Lost	
3 month-5 years	23	1	24
6-10 years	0	18	18
11-15 years	0	8	8
Total	23	27	50
P <0.01			

Table(4. 16) cross tabulation duration and RTK size

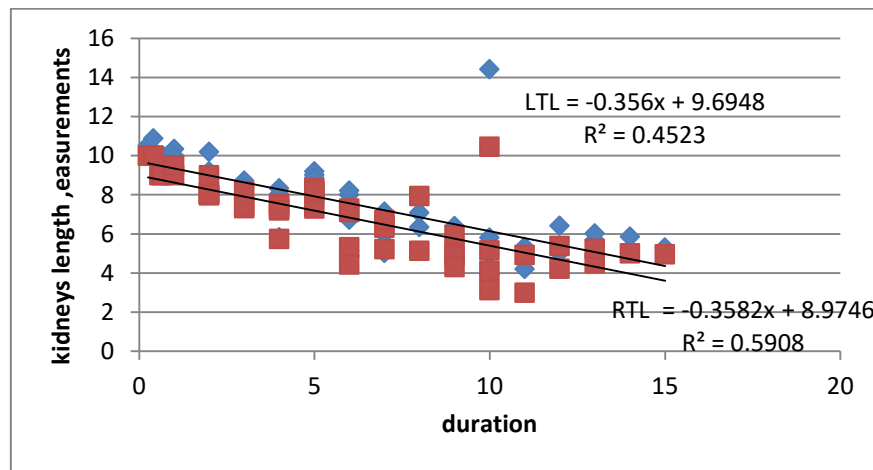
Duration	size			Total
	normal	enlarged	small	
3 month-5 years	14	0	10	24
6-10 years	0	1	17	18
11-15 years	0	0	8	8
Total	14	1	35	50
P <0.01				

Table(4. 17) cross tabulation duration and LTK size

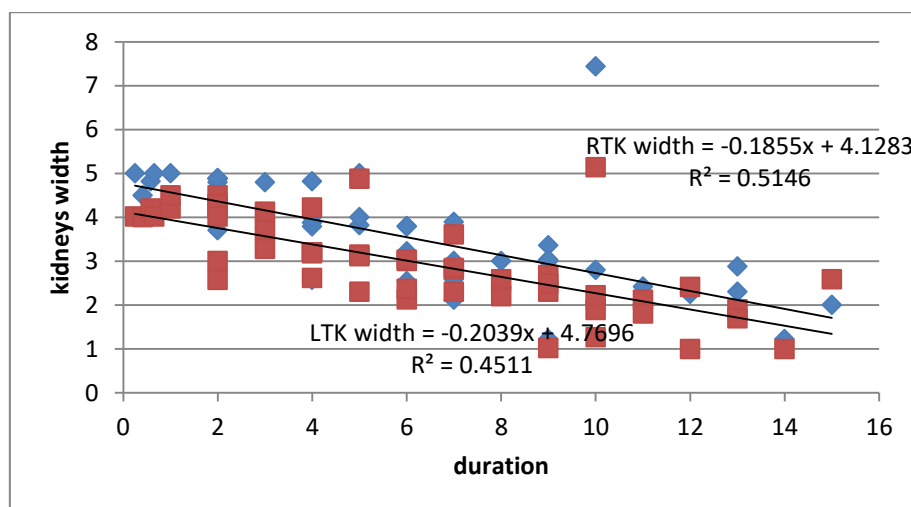
Duration	Lt kidney size			Total
	normal	enlarged	small	
3 month-5 years	21	0	3	24
6-10 years	2	1	15	18
11-15 years	0	0	8	8
Total	23	1	26	50
P < 0.01				

Table(4. 18) cross tabulation duration and presence of cyst

Duration	cyst		Total
	No	yes	
3 month-5 years	23	1	24
6-10 years	8	10	18
11-15 years	2	6	8
Total	33	17	50
P < 0.01			



Figure(4. 12) scatterplot shows inverse relationship between duration and kidneys length



Figure(4. 13) scatterplot shows inverse relationship between duration and kidneys width

Table(4. 19) correlation between duration and kidney measurements

		RTK length	RTK width	LTK length	LTK width
Duration	Pearson Correlation	-.769**	-.717**	-.673**	-.672**
	Sig. (2-tailed)	.000	.000	.000	.000
	N	50	50	50	50

** Correlation is significant at the 0.01 level (2-tailed).

Chapter Five

5.1 Discussion

From the collective finding data of this study the more effective age lied between (41-51) year as shown in table (4-1).

The study explained that chronic renal failure is more common in male (68%) than females (32%) as shown in table (4-2).

Housewife in this study are more affected(30%) then farmers (24%), businessman (18%), labors(16%), driver(8%) and student(4%) as shown in table [4-3] and this result was not consisting with previous studies.

Patients with chronic renal failure were came with different disorders and the more common is the edema (40%) as shown in table[4-4].

The study explained that patients with chronic renal failure from (3 months-5years)are more affected than whose suffered for (6-10)years,then from (11-15)years as in table [4-5].

Chronic renal failure cause increase s in urea and creatinine levels.patient with high urea(86%) and who with high level (14%) as in table [4-6] patients with high level of creatinine(92%) and very high level(8%) as in table [4-7].

The measurement of Rt and Lt kidney size explained that there is a reduction in Rt kidney (70%) and in Lt kidney (52%) as in table [4-8].and this result was consisting with ZHANG W[2014]

The shape of rt kidney show abnormality (62%),normal(38%) as shown in table [4-10], Lt kidney abnormal shape (64%) and the normal was (36%) as in table[4-11].

In table[4-12] explained that there was loss of corticomedullary differentiation(54%) and decrease (46%) and this result was consisting with(GareeballhA,2015).

Study explained that patients withacquired simple cysts(34%) in table (4-13) and this result was consisting with Meola(2016).

Rt kidney more affected by (14%), Lt kidney (10%) as in table [4-14],

Table [4-14] also explained that Rt and Lt are affected equally by multiple cysts(2%), polycystic kidney(2%).

Patients whose suffer from chronic kidney disease for (6-10)years they explained loss of corticomedullary differentiation(18%) and decrease(23%) as shown in table[4-15].

Table[4-16] explained that small rt kidney size(17%) with duration of disease was (6-10)years also table [4-17] explain lt kidney small size was(15%) at duration (6-10)years. In table [4-18] patients with renal failure for duration(6-10)years have higher percentage of cysts(10%).

Table (4.19) explained that there was inverse relation between duration of disease and kidney size.

The study found that there was significant statistical correlation between kidney size and duration, as duration increased kidney size decreases p less than 0.01.

Significant correlation duration of disease probability and presence of cyst. p less than 0.01.

5.2 Conclusion

The aim of this descriptive study was to know the characterization of kidney in chronic renal failure by ultrasound, the researcher was analyzed all the result and compared to previous studies the study was explained that ultrasonography is available, relatively low cost, and safe, with a good role in evaluation of chronic renal failure according to the characterization of kidneys.

5.3 Recommendations

The study recommended that ultrasound examinations should be a routine examination when there is suspicion of renal impairment.

The study recommended that further studies with large sample must be made in the same topic to know more about characterization of kidney with other parameters such as volume of kidney.

References

Jha v, Garcia-Garcia G,Isekik K, et al. chronic kidney disease: global dimension and perspectives.lancet.Jul 20 2003;382 (9888):260-272.

CouserWG,etal.The contribution of chronic kidney disease to the global burden of major noncommunicable disease. Kidney Int. Dec 2011; 80 (12): 1258-1270.

Devin D.Abdominal Ultrasound and Instrumentation.part 1. Module2.1sted. TheBurwin institute of diagnostic medical ultrasound. Canada: Luneburg;2005.p.23-27.

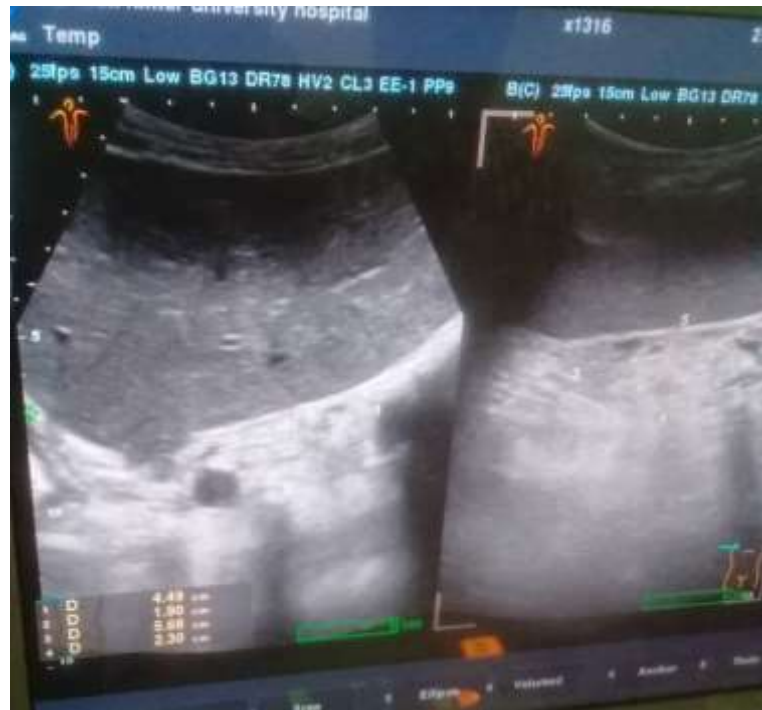Gareeballah,A,etal.sonographic findings in renal parenchymal diseases at Sudanese.Open Journal of Radiology,5:243-249,2015.

MeolaM,Petruccil,Ronco C (eds):Ultrasound Imaging in acute and chronic kidney disease.Contribnephrol.Basel, Karger,2016,vol 188,pp 120-130.

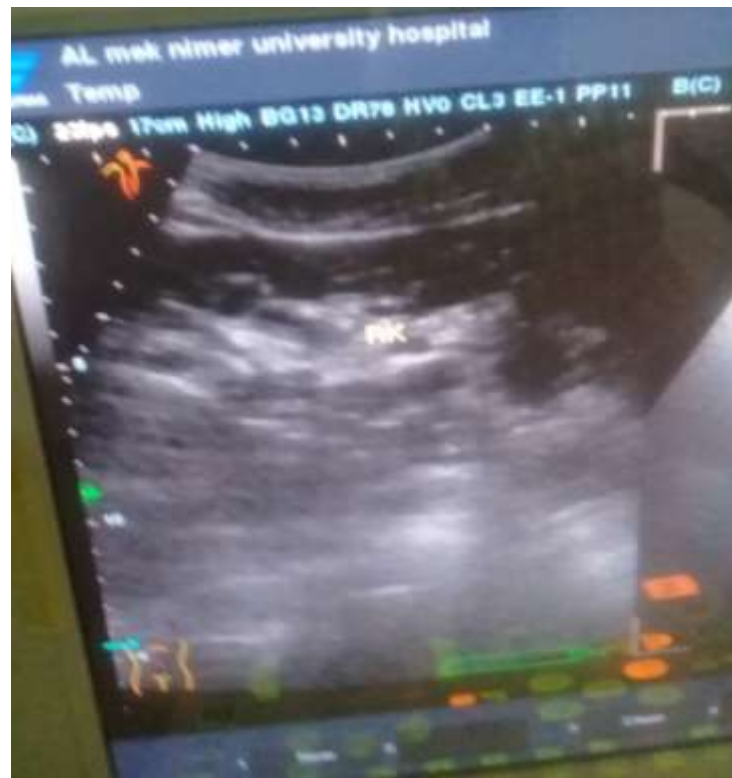ZHANG w, et al. sonographic measurement of renal size in patients undergoing chronic hemodialysis: correlation with residual renal function.EXPERIMENTAL AND THERAPEUTIC MEDICINE 7:1259-1264,2014.

Buturovic J, et al. Ultrasonography in chronic renal failure.Eur J Radiol 2003; 46:22-115.

Appendix



Imag 1 show sechognic Small Kidneys



Imag 2 show right Small Kidney with Small cyst