



**Sudan University of Science and
Technology College of Graduate Studies**

**Measurement of Portal Tract Blood Vessels Among
Youth Sudanese Using Duplex Ultrasonography**

قياس الأوعية الكبدية البابية لدى الشباب
السودانيين
باستخدام الموجات فوق الصوتية

**A Thesis Submitted for Partial Fulfillment of the award of M.Sc. Degree in
Diagnostic Ultrasonography**

By

Badawi Elbalal Mohammed

Supervisor:

Dr. Mona Ahmed Mohammed

June 2019

بِسْمِ اللَّهِ الرَّحْمَنِ الرَّحِيمِ

قال تعالى:

(وَاللَّهُ أَخْرَجَكُمْ مِنْ بُطُونِ أُمَّهَاتِكُمْ لَا تَعْلَمُونَ شَيْئًا وَجَعَلَ لَكُمُ السَّمْعَ وَالْأَبْصَارَ وَالْأَفْئِدَةَ لَعَلَّكُمْ تَشْكُرُونَ)

صدق الله العظيم

صورة النحل الآية (78)

Dedication

To my greatest father and lovely mother...

To My wife, sons, daughter, brothers and sisters whom i love

To my friends, colleagues, and everyone who help me at any time in my life

Acknowledgment

First of all, I Thank Allah the almighty for helping me to complete this project.
I Thank Dr. **Mona Ahmed Mohamed** my supervisor for her help and guidance,
my great fullness for my all teachers in different educational levels, specially
thanks for my teacher

Dr. Ashraf Mustafa

Finally I would like to thank everybody who helped me in this project.

Abstract:

This is a cross sectional descriptive study carried out in Ribat teaching hospital Khartoum state - Sudan from June to August 2018 was done to investigate the utility of Doppler ultrasound in detecting the range of spectrum of the portal vein and hepatic artery of the healthy patient. A sample of 50 young patients of different gender and age group were selected, their age range (16-30 years) Male 24 (48%) Females 26 (52%).

The resistive index (RI), velocity and diameter of portal vessels (portal vein, hepatic artery) of the patients were taken to get the range of these values in healthy young Sudanese peoples.

Trans abdominal scanning was done for all cases using Toshiba with curvilinear probe of 2 to 3.5 Megahertz (MHz).

Data collected using special data collection sheet designed to evaluate gender, age, weight, height and Portal vein. For analyzing of collected data study used Statistical Package for Social Sciences (SPSS).

Study resulted that mean of age for cases under study was 21.9 years with stander deviation ± 4.63 years, while the mean of Resistive index (RI) of hepatic artery 0.62 with stander deviation 0.07, mean of Portal vein diameter (mm) 9.9 mm with stander deviation 2.08 mm, while mean portal vein velocity (cm/s) 15.1 (cm/s) with stander deviation 3.10 (cm/s).

Study concluded that there was no difference significant correlation between portal vein diameter, velocity with age and gender of cases, while there was a difference significant correlation between hepatic artery resistive index (RI) with gender.

The correlation coefficient between the resistive index, age , gender and velocity of portal vein and hepatic artery there was no relationship except of

portal vein diameter with gender (P-value <0.05) it was a proportional relationship.

Study recommended that further studies should be done with increased number of sample and introduced other age group.

ملخص البحث

هذه دراسة وصفية مقطعية اجريت في مستشفى الرباط الوطني التعليمي في الفترة من يونيو حتي أغسطس من العام 2018 هدفت الدراسة تقدير لقياس القطر الطبيعي للوريد البابي الرئيسي والشريان الكبدي الرئيسي باستخدام الموجات فوق الصوتية الملونة (الدوبلر). تمت دراسة خمسون حالة من للفئات العمرية بين 16 سنة وحتى 30 سنة عشوائياً من حيث العمر والجنس ، حيث كان عدد حالات الذكور (24 حالة) تشكل نسبة 48 في المائة من إجمالي عدد الحالات وعدد حالات الإناث (26 حالة) تشكل نسبة 52 في المائة من إجمالي عدد الحالات وكانت كل الحالات ذات كبد طبيعي.

تم استخدام المسح البطني لكل هذه الحالات باستخدام جهاز توشيبا موديل 2011 باستخدام مسبار ذو خطوط منحنية ذو تردد من 3.5 حتي 7 وخطي ذو تردد 7.5 حتي 12 ميغاهيرز.

تم جمع البيانات باستخدام ورقة تجميع بيانات خاصة لتقييم الجنس والعمر ومؤشر التسارع خلال فترة سريان الدم في الوريد البابي وقياس قطره ومؤشر المقاومة الشريانية (RI) , وللتحليل تم استخدام تحليل الحزم الإحصائية للعلوم الإجتماعية.

وخلصت الدراسة الي ان متوسط العمري للحالات 21.9 سنة بانحراف معياري 4.63 سنة, بالإضافة لمتوسط مؤشر المقاومة الشريانية (RI) 0.62 بانحراف معياري 0.07 ، ومتوسط قطر الوريد البابي 9.9 ملمتر بانحراف معياري 2.08 ملمتر، ومتوسط مؤشر التسارع خلال فترة سريان الدم في الوريد البابي (velocity cm/s) 15.1 سنتمتر/ ثانية بانحراف معياري 3.10 سنتمتر/ ثانية .

وخلصت الدراسة الي أنه لا توجد هنالك أي علاقة إختلاف بين قطر الوريد البابي ومؤشر التسارع خلال فترة سريان الدم والعمر والجنس لتلك الحالات , وبينما كانت هنالك إختلاف معنوي بين مؤشر المقاومة الشريانية والجنس.

لا توجد أي علاقة معنوية بين المتغيرات كمؤشر المقاومة الشريانية ، العمر ، الجنس ومؤشر التسارع لكل من للوريد البابي الشريان الكبدي بينما توجد علاقة طردية بين قطر مقياس الوريد البابي والجنس.

أوصت الدراسة بعمل دراسات في المستقبل بزيادة عدد الحالات وادخال فئات عمرية اخري.

Table of contents

No	Contents	Page No
1	الآية	I
2	Dedication	II
3	Acknowledgements	III
4	Table of contents	IV
5	Abstract (English)	VI
6	Abstract (Arabic)	VI I
7	List of tables	VIII
8	List of figures	IX
9	List of abbreviations	XI
Chapter one: Introduction		
1.1	Introduction	1
1.2	Problem of the study	2
1.3	Objectives of the study	2
1.3.1	General objective	2
1.3.2	Specific objectives	2
Chapter two: Literature review		
2.1	Anatomy	3
2.2	Portal venous physiology	11
2.3	Pathologies of the portal vein& hepatic artery	16
2.4	Portal vein & hepatic artery Ultrasound	25
2.5	Previous studies	30
Chapter three: Materials & Methods		
3	Methodology	33

3.1	Type of study	33
3.2	Sample size	33
3.3	Area of the study	33
3.4	Duration of the study	33
3.5	Materials	33
3.6	Data collection	33
3.7	Variables of data collection	34
3.8	Ethical approval	34
3.9	Technique	35
3.10	Data analysis	35
Chapter four: Results		
	Result	36
Chapter five: Discussion, Conclusion, and Recommendations		
5.1	Discussion	42
5.2	Conclusion	44
5.3	Recommendations	45
References		46
Appendix(1)		
Appendix(2)		

List of tables

Table 4-1	Distribution of sample study according to gender
Table 4-2	Descriptive Statistics for variables of study
Table 4-3	Compare means to variables of study according to gender
Table 4-4	Correlation coefficient between variables of study

List of figures

Figure	Name of figure
Figure 2-1	The portal vein and its tributaries.
Figure 2-2	Oblique colour Doppler image of the porta hepatis
Figure 2-3	Spectral Doppler tracing of normal portal vein flow
Figure 2-4	Transverse image of the mid-abdomen at the level of the superior mesenteric.
Figure 2-5	Spectral Doppler tracing of a normal hepatic artery
Figure 2-6	Spectral Doppler tracing of normal portal vein and hepatic artery flow
Figure 2-7	Colour image and spectral Doppler tracing of the porta hepatis
Figure 2-8	Ultrasound image of Portal vein
Figure 2-9	The portal vein and its tributaries
Figure 2-10	Spectral hepatic vein Doppler tracing in a patient with alcoholic cirrhosis
Figure 2-11(A)	Spectral Doppler tracing of a patient with end-stage liver disease being considered for liver transplantation
Figure 2-11(B)	When instructed to forcefully breathe in and out, this patient's portal flow became more dynamic. During forced expiration with elevated intra thoracic pressure there is increasing resistance to hepatic venous outflow forcing portal vein flow to become hepatofugal.
Figure 2-12	Longitudinal colour Doppler image in the midline of a patient with portal hypertension. A large tortuous left gastric varix is seen coursing from the region of the coeliac axis towards the gastro-oesophageal junction.
Figure 2-13	Grayscale imaging, colour Doppler and spectral Doppler tracing over the portal vein in a patient with known advanced hepatocellular carcinoma (HCC).
Figure 2-14	Spectral Doppler tracing of the portal vein in a patient with pneumatosis intestinalis.
Figure 2-15	Transverse colour Doppler image of the mid-liver. A rounded lesion is present with some internal debris. Flow is perceived

	around this debris.
Figure 2-16	Diagram showing the scanning areas used to obtain the portal vein.
Figure 2-17	Shows normal portal vein ultrasound.
Figure 2-18	Showing scan plane intercostal of liver
Figure 4-1	Distribution of sample study according to gender
Figure 4-2	Shows scatter plot between Age & RI
Figure 4-3	Shows scatter plot between Age & Velocity (cm/s)
Figure 4-4	Shows scatter plot between Age & Diameter (mm)
Figure 4-5	Shows scatter plot between RI & Diameter (mm)
Figure 4-6	Shows scatter plot between RI & Velocity (cm/s)
Figure 4-7	Shows scatter plot between Diameter (mm) & Velocity (cm/s)

List of Abbreviations

Abbreviation	Meaning
PV	Portal vein
HA	Hepatic artery
PI	Pulsatility index
PSV	Peak systolic velocity
RI	Resistive index
HVPG	Hepatic venous pressure gradient
Cm	Centimeter
Mm	Millimeter
NS	No Significant difference
HCC	Hepatocellular carcinoma
MPV	Main portal vein
SA	Splenic artery
MHA	Main hepatic artery

Chapter One

Introduction

Chapter one

Introduction:

Portal vein is a special conduit which transmits blood from the capillaries of intestinal wall and spleen to capillaries of hepatic sinusoids (1, 2) the most common abnormality of this special conduit (portal venous system) is portal hypertension. Portal hypertension is a prevalent clinical syndrome defined as an increase in portal venous pressure, and this leads to impendence of blood flow through the vein into the hepatic circulation. The most common causes of portal hypertension cited in different studies were cirrhosis (in developed countries) .schistosomiasis (in endemic areas) and hepatic vascular abnormalities. As a result of portal hypertension, dilatation of portal vein, splenomegaly and formation of portal systemic collaterals at different sites are consequently developed. (Anakwue 2009).

Sonography is non-ionizing, easily accessible, non-invasive and portable in nature, reliable, low in cost and also it is rapid. These features make Sonography a good diagnostic tool for portal hypertension. The normal portal vein diameter (PVD) can vary normally between 7 to 15 mm while 2 normal portal venous pressure lies between 5 and 10 mmHg (14 cm of H₂O) .If portal venous pressure is more than 15 mmHg (30 cm of H₂O), then it might indicate portal hypertension .A portal vein diameter greater than 13 mm is assumed to be the cutoff point for portal hypertension in the appropriate clinical setting .On the contrary, a portal vein diameter greater than 10 mm was also considered as portal hypertension in previous literatures .However, mean normal portal vein diameter greater than 10 mm was also indicated from previous studies:13 mm ,greater than 11mm in Nigeria . 11.54 mm in Kolkata, this contradicts with the

mentioned cut off point. (Anakwue 2009)

These imply the existence of limited evidence on normal portal vein diameter for all populations in all countries of the world prior to setting the cutoff points. On top of this, the need for having scientific evidence on mean portal vein diameter among normal and with portal hypertensive clients in all countries was cited by literatures.(Anakwue 2009).

1.1 Problem of the Study:

Doppler indices of the portal vein and hepatic artery (RI, velocity, and PSV) are varying from subject to subject; this variation may be due to physiological or pathological condition.

1.3 Objectives of the study:

1.3.1 General objective:

To evaluate the portal tract blood vessels in tropical countries; using Doppler ultrasound; like Sudan many problems affecting the size of (PV, HA).

1.3.2 Specific Objectives:

1. To measure the portal vein diameter in healthy liver.
2. To calculate the resistive index of the portal vein in healthy livers.
3. To measure the Doppler indices of the hepatic artery.

Chapter Two

Theoretical Background and Literature Review

Chapter two

2.1 Theoretical Background and Literature Review

2.1.1 Portal vein anatomy

The portal vein or hepatic portal vein is a blood vessel that carries blood from the gastrointestinal tract and spleen to the liver. This blood is rich in nutrients that have been extracted from food, and the liver processes these nutrients; it also filters toxins that may have been ingested with the food. 75% of total liver blood flow is through the portal vein, with the remainder coming from the hepatic artery proper. The blood leaves the liver to the heart in the hepatic veins. (Henry Gray et al 1901)

The portal vein is not a true vein, because it conducts blood to capillary beds in the liver and not directly to the heart. It is a major component of the hepatic portal system, one of only two portal venous systems in the body – with the hypophyseal portal system being the other. (Henry Gray et al 1901)

The portal vein is usually formed by the confluence of the superior mesenteric and splenic veins and also receives blood from the inferior mesenteric, gastric, and cystic veins. (Henry Gray et al 1901)

It is accompanied by the hepatic artery and common bile duct which together make up the portal triad (Fig. 2.2). (Myron A Pozniak et al 2014) (Page 149)

Conditions involving the portal vein cause considerable illness and death. An important example of such a condition is elevated blood pressure in the portal vein. This condition, called portal hypertension, is a major complication of cirrhosis. (Henry et al 1901)

Portal vein

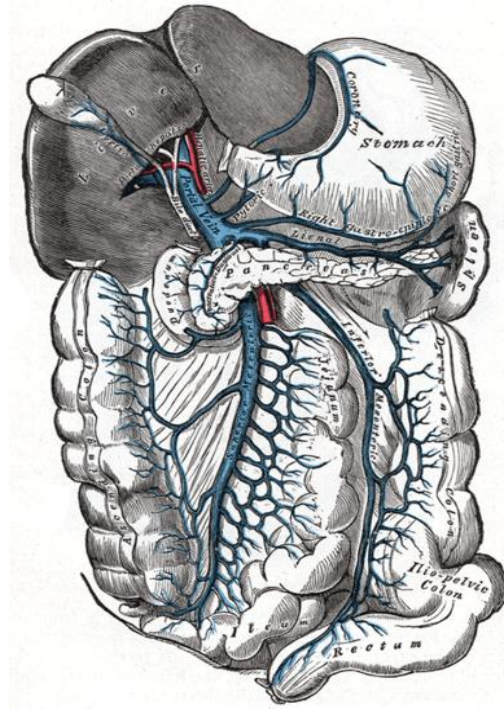


FIGURE 2.1: The **portal vein** and its tributaries. (Henery et al 1918)

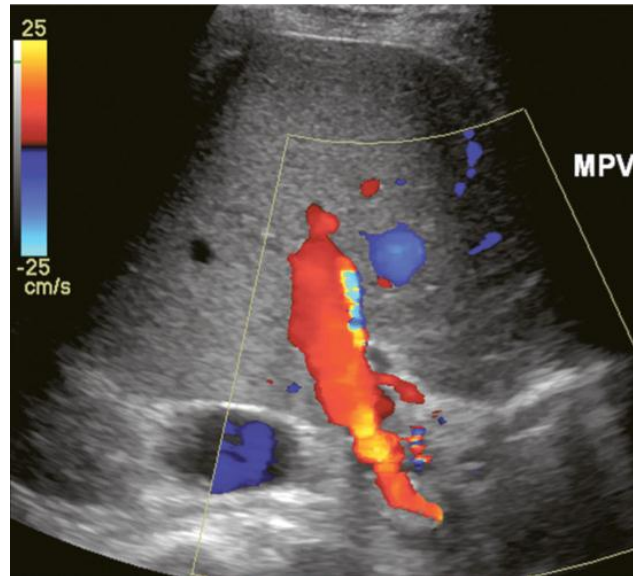


FIGURE 2.2: Oblique colour Doppler image of the porta hepatis. The hepatic artery (HA) accompanies the portal vein (PV) and bile ducts. With the colour scale appropriately set for the slow flow within the portal vein, hepatic arterial flow projects as colour aliasing. (Myron A Pozniak et al 2014)

The portal vein Doppler flow profile in a fasting patient has a relatively constant velocity of approximately 18 cm/s (± 5 cm/s) towards the liver (hepatopetal) (Fig. 2.3). The flow velocity is uniform because cardiac pulsation is damped by the splenic parenchyma and the capillaries of the gut at one end of the portal system and by the liver sinusoids at the other. Slight phasicity may be seen on the portal spectral tracing due to respiration and a mild degree of periodicity may be present, due either to retrograde pulsation transmitted from the right heart via the hepatic vein (A-wave) or to the hepatic artery systolic pressure wave. Because these brief pressure surges into the liver transiently elevate intracapsular pressure, they increase resistance to portal venous inflow and, thereby, effect a momentary slowing of antegrade flow in the portal vein. (<http://www.healthline.com/human-body-maps/portal-vein>).

Although some periodicity may be expected in portal vein flow, marked velocity variation or reversal of flow, even if brief, should be considered an abnormal finding.

The blood in the portal vein is relatively deoxygenated since it comes to the liver after perfusing the intestine and spleen. It is rich in nutrients after a meal, and arrives at the liver to be processed by the cells of the hepatic sinusoids.

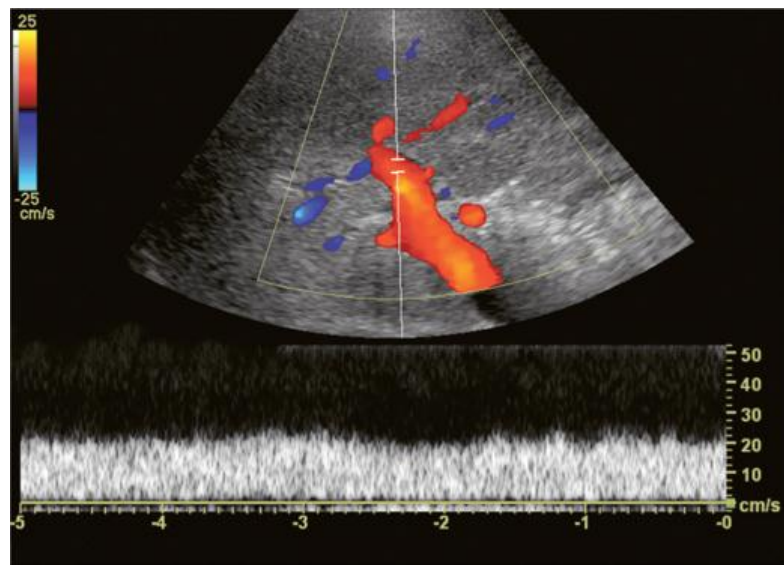


FIGURE 2.3: Spectral Doppler tracing of normal portal vein flow. The flow velocity of 20 cm/s is relatively uniform and in a hepatopetal direction. (Myron A Pozniak et al 2014).

2.1.1.1 Structure of portal vein

Measuring approximately 8 cm (3 inches) in adults, the portal vein is located in the right upper quadrant of the abdomen, originating behind the neck of the pancreas. (Harold, et al 2008)

In most individuals, the portal vein is formed by the union of the superior mesenteric vein and the splenic vein. For this reason, the portal vein is occasionally called the splenic-mesenteric confluence. Occasionally, the portal vein also directly communicates with the inferior mesenteric vein, although this is highly variable. Other tributaries of the portal vein include the cystic and gastric veins. (Plinio Rossi, et al 2000) (Benjamin et al 2008).

Immediately before reaching the liver, the portal vein divides into right and left. It ramifies further, forming smaller venous branches and ultimately portal venules. Each portal venule courses alongside a hepatic arteriole and the two vessels form the vascular components of the portal triad. These vessels ultimately empty into the hepatic sinusoids to supply blood to the liver. (Henry Gray et al 1901)

The main portal vein enters the liver at the porta hepatis, also referred to as the liver hilum. The portal vein provides the liver with approximately 70% of its total blood supply. (Nyberg, et al 2003)

The blood within the portal vein is partially oxygenated, as it is derived from the intestines. The remainder of hepatic perfusion is via the hepatic artery. As the main portal vein enters the liver, it splits into the right and left portal veins. (Nyberg, et al 2003)

The right portal vein, like the right hepatic lobe, is separated into an anterior and posterior division. The left portal vein, like the left hepatic lobe, is separated into a medial and lateral division. These vessels supply blood to their related segments. (Nyberg, et al 2003).

Enlargement of the portal vein is indicative of portal hypertension. (Nyberg, et al 2003)

2.1.1.2 Accessory hepatic portal veins

Accessory hepatic portal veins are those veins that drain directly into the liver without joining the hepatic portal vein. These include the Para umbilical veins as well as veins of the lesser omentum, falciform ligament, and those draining the gallbladder wall. (Plinio, et al 2000)

2.1.1.3 Hepatic artery anatomy

The hepatic arterial blood supply arises solely from the celiac axis in approximately 75% of individuals. The celiac trifurcates into the splenic artery left gastric artery and common hepatic artery. After the take-off of the gastroduodenal artery, the common hepatic is then called the proper hepatic artery. It enters the liver alongside the portal vein where it divides into left and right hepatic arteries and from there branches into the Couinaud segments. There are, however, numerous variants of hepatic artery anatomy. (Myron A. Pozniak et al 2014)

These include accessory vessels which exist in conjunction with normal branches of the hepatic artery and replaced arteries which make up the sole supply of a segment or lobe. For example, a replaced right hepatic artery arising from the superior mesenteric artery (SMA) is the sole blood supply to the entire right lobe of the liver in 15% of the population. In a slender patient, colour Doppler US may be able to identify the replaced right hepatic artery behind the main portal vein as it courses towards the right lobe from the SMA (Fig. 2.4). (Myron A. Pozniak et al 2014)

A branch of the left gastric artery may supply the left lobe of the liver. This occurs less frequently and is more difficult to identify by Doppler US because of its small size.

The normal proper hepatic artery in a fasting patient has a low-resistance Doppler flow profile, [about 60–70% resistive index (RI)] (Fig. 2.5). During systole, the velocity is approximately 30–60 cm/s; while during diastole, it normally slows to approximately 10–20 cm/s. Normal systolic acceleration time of the hepatic artery is brisk – less than 0.07 seconds. (Myron A. Pozniak et al 2014)

Diastolic arterial velocity approximates the velocity of the portal vein. A comparison between hepatic artery diastolic velocity and the portal vein velocity is called the liver (or hepatic) vascular index. To acquire this comparison one can increase the sample volume size so that both vessels are incorporated into the same tracing (Fig. 2.6) or swing the sample volume from one vessel to the other in the same tracing (Fig.2.7). (Myron A. Pozniak et al 2014)

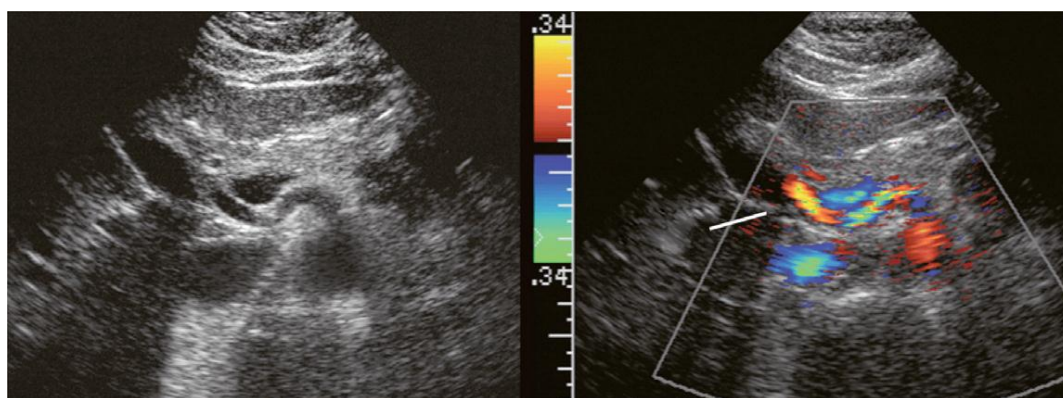


FIGURE 2.4: Transverse image of the mid-abdomen at the level of the superior mesenteric artery origin. A tubular structure is seen coursing from the superior mesenteric artery (SMA) to the right lobe of the liver, between portal vein (PV) and the inferior vena cava (IVC). The addition of colour Doppler identifies this tubular structure as a vessel. An arterial signal on spectral Doppler, identification of its SMA origin and a course towards the right lobe of the liver confirm this to be a replaced right hepatic artery.

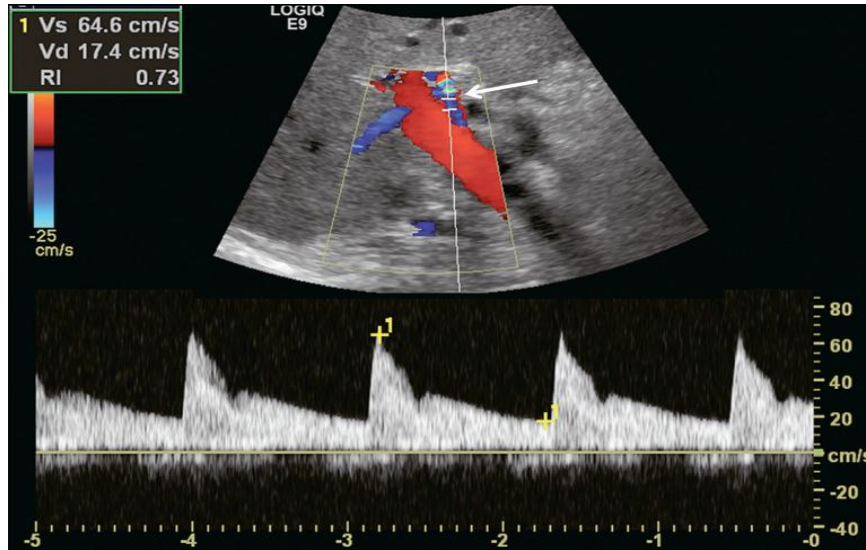


FIGURE 2.5: Spectral Doppler tracing of a normal hepatic artery. Systolic upstroke is brisk with acceleration time <0.07 s. Resistive index measures 73%. Velocity at end diastole approximates 17 cm/s.

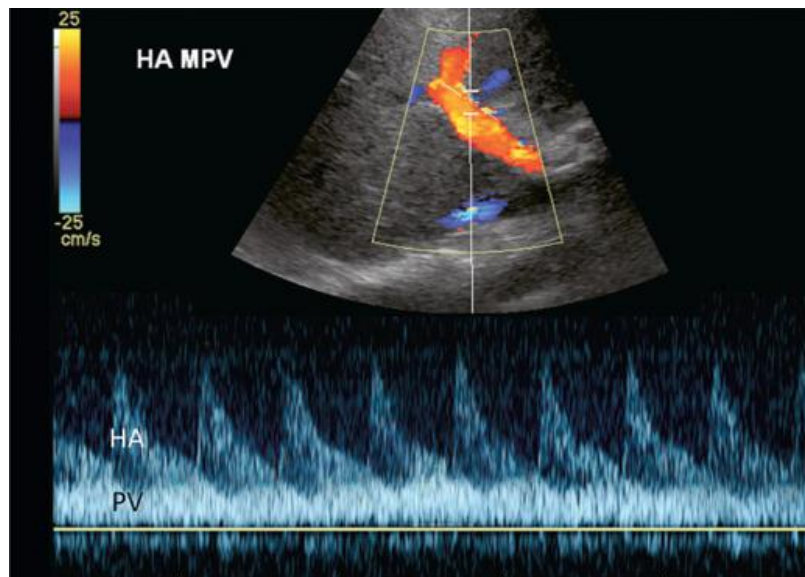


FIGURE 2.6: Spectral Doppler tracing of normal portal vein and hepatic artery flow. Slight periodicity is present in this patient's portal vein tracing. The dip in antegrade velocity coincides with hepatic arterial systole. The comparison of the two flow profiles is achieved by interrogating with a wide sample volume that encompasses both the artery and the vein in one tracing. Velocity variation may also occur due to pressure change with the hepatic vein A-wave but those

are harder to compare since the vessels are separated and cannot be simultaneously interrogated.

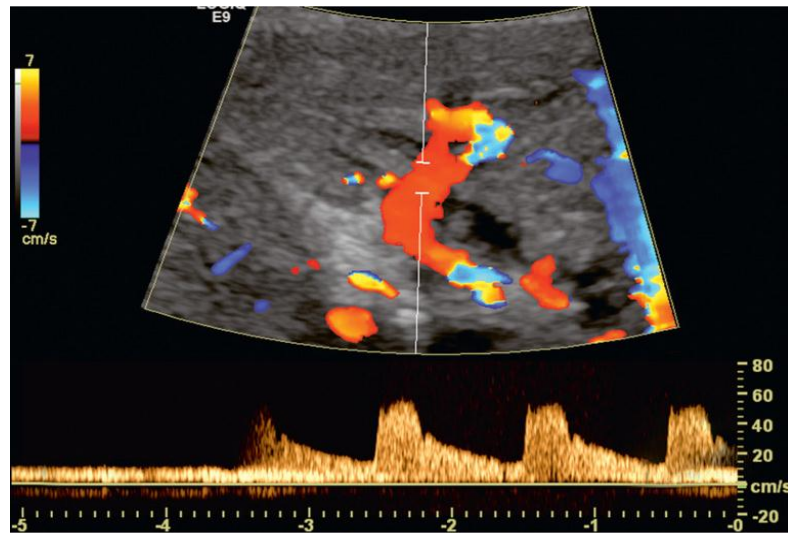


FIGURE 2.7: Colour image and spectral Doppler tracing of the porta hepatis. A comparison of hepatic artery and portal vein velocities is achieved on a single tracing by gently rocking the transducer from one vessel to the other.

2.1.2 Porto venous system physiology

2.1.2.1 Portal vein function:

The portal vein and hepatic arteries form the liver's dual blood supply. Approximately 75% of hepatic blood flow is derived from the portal vein, while the remainder is from the hepatic arteries. (Plinio, et al 2000)

Unlike most veins, the portal vein does not drain into the heart. Rather, it is part of a portal venous system that delivers venous blood into another capillary system, the hepatic sinusoids of the liver. In carrying venous blood from the gastrointestinal tract to the liver, the portal vein accomplishes two tasks: it supplies the liver with metabolic substrates and it ensures that substances ingested are first processed by the liver before reaching the systemic circulation. (Plinio, et al 2000).

This accomplishes two things. First, possible toxins that may be ingested can be detoxified by the hepatocytes before they are released into the systemic circulation. Second, the liver is the first organ to absorb nutrients just taken in by the intestines. After draining into the liver sinusoids, blood from the liver is drained by the hepatic vein. (Plinio, et al 2000)

The portal venous system is responsible for directing blood from parts of the gastrointestinal tract to the liver. Substances absorbed in the small intestine travel first to the liver for processing before continuing to the heart. Not all of the gastrointestinal tract is part of this system. The system extends from about the lower portion of the esophagus to the upper part of the anal canal. It also includes venous drainage from the spleen and pancreas. (Jeremy et al, 2008)

Many drugs that are absorbed through the GI tract are substantially metabolized by the liver before reaching general circulation. This is known as the first pass effect. As a consequence, certain drugs can only be taken via certain routes. (Jeremy et al, 2008)

For example, nitroglycerin cannot be swallowed because the liver would inactivate the medication, but it can be taken under the tongue or transdermal (through the skin) and thus is absorbed in a way that bypasses the portal venous system. Inversely, dextromethorphan, a cough suppressor, is best taken orally because it needs to be metabolized by the liver into dextrophan in order to be effective. (Jeremy et al, 2008)

This latter principle is that of most prodrugs. The use of suppositories is a way to by-pass partially the portal vein: the upper 1/3 of the rectum is drained into the portal vein while the lower 2/3 is drained into the internal iliac vein that goes directly in the inferior vena cava (thus by-passing the liver). (Jeremy et al, 2008)

Blood flow to the liver is unique in that it receives both oxygenated and (partially) deoxygenated blood. As a result, the partial gas pressure of oxygen (pO₂) and perfusion pressure of portal blood are lower than in other organs of the body. (Jeremy et al, 2008)

Blood passes from branches of the portal vein through cavities between "plates" of hepatocytes called sinusoids. Blood also flows from branches of the hepatic artery and mixes in the sinusoids to supply the hepatocytes with oxygen. (Jeremy et al, 2008)

This mixture percolates through the sinusoids and collects in central vein which drains into the hepatic vein. The hepatic vein subsequently drains into the inferior vena cava. The hepatic artery provides 30 to 40% of the oxygen to the liver, while only accounting for 25% of the total liver blood flow. The rest comes from the partially deoxygenated blood from the portal vein. The liver consumes about 20% of the total body oxygen when at rest. That is why the total liver blood flow is quite high, at about 1 liter a minute and up to two liters a minute. That is on average one fourth of the average cardiac output at rest. (Jeremy et al, 2008)

On a sonogram, their walls appear much brighter than those of the hepatic veins. This may be because of an increase in the amount of collagen within their walls compared with the hepatic veins. (Curry, et al 2004)

Normal flow within the portal veins should be hepatopetal and monophasic, with some variation noted with respiratory changes and after meals. (Curry, et al 2004).

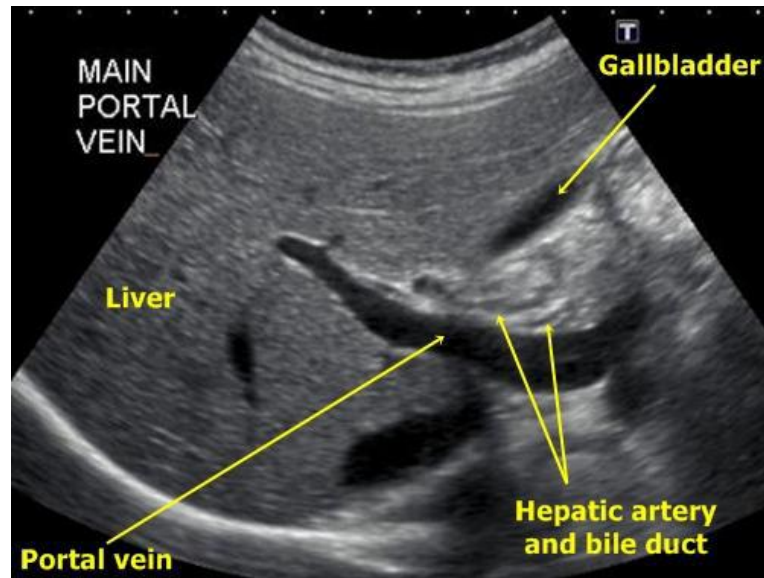


FIGURE 2.8: Ultrasound image shows the Portal vein (Zaka,et al 2011)

2.1.2.1 .1Hepatic portal system

In human anatomy, the hepatic portal system is the system of veins comprising the hepatic portal vein and its tributaries. It is also called the portal venous system, although it is not the only example of a portal venous system, and splanchnic veins, which is not synonymous with hepatic portal system and is imprecise (as it means visceral veins and not necessarily the veins of the abdominal viscera).

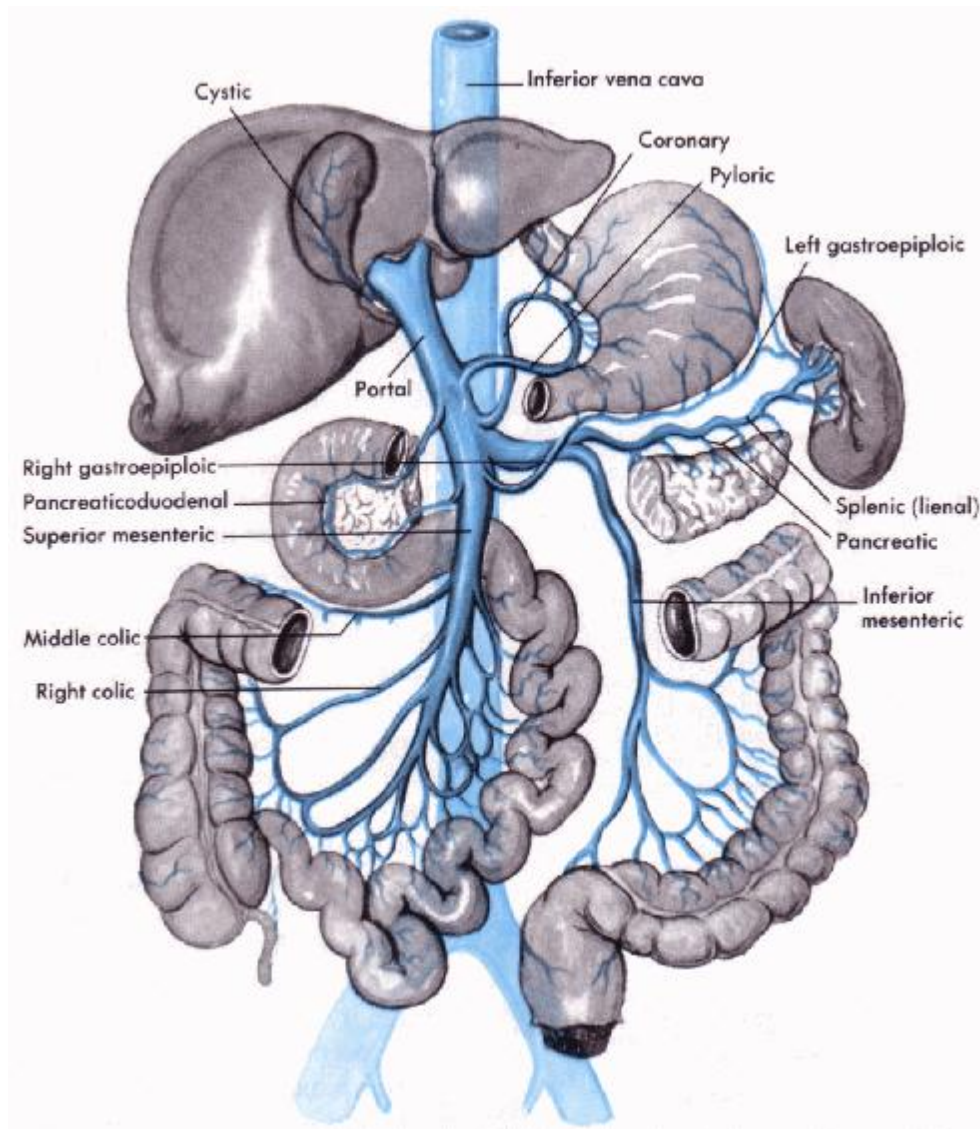


FIGURE 2.9: The portal vein and its tributaries. (Henery et al, 1918)

Hepatic venous pressure gradient (HVPG) is a clinical measurement of the pressure gradient and is an estimate of the pressure gradient between the portal vein and the inferior vena cava. An HVPG of ≥ 10 mmHg defines clinically significant portal hypertension, and if the measurement exceeds 12 mmHg variceal hemorrhaging may occur. While not widely performed, its assessment in people with CLD is recommended to monitor response to treatment.

2.1.3 Portal vein pathology:

2.1.3.1 Portal hypertension:

Portal hypertension is hypertension (high blood pressure) in the portal vein system, which is composed of the portal vein, and its branches and tributaries. Portal hypertension is defined as elevation of hepatic venous pressure gradient to $>5\text{mmHg}$. Generally, in clinical practice the pressure is not measured directly until the decision to place a transjugular intrahepatic portosystemic shunt (TIPS) has already been made. As part of that procedure, a hepatic vein wedge pressure is measured with the assumption of no pressure drop across the liver yielding portal vein pressure. (Kok T et al 1999)

2.1.3.1 .1Signs and symptoms:

Consequences of portal hypertension are caused by blood being forced down alternate channels by the increased resistance to flow through the systemic venous system rather than the portal system. They include:

- Ascites (free fluid in the peritoneal cavity).
- Hepatic encephalopathy.
- Increased risk of spontaneous bacterial peritonitis.
- Increased risk of hepatorenal syndrome.
- Splenomegaly (enlargement of the spleen) with a consequent accumulation of red blood cells, white blood cells, and platelets, together leading to mildpancytopenia.
- Development of varices at portacaval anastomoses: esophageal varices, gastric, varices, anorectal varices (not to be confused with hemorrhoids), and caput medusae. Esophageal and gastric varices pose an ongoing risk of life-threatening bleeding, with bloody vomiting or melena. (Kok T et al 1999)

Causes can be divided into pre-hepatic, intra-hepatic, and post-hepatic:

- Prehepatic causes include portal vein thrombosis or congenital atresia.
- Intrahepatic causes include liver cirrhosis, hepatic fibrosis (e.g. due to Wilson's disease, hemochromatosis, or congenital fibrosis), and less commonly noncirrhotic causes such as schistosomiasis, massive fatty change and diffuse granulomatous diseases (e.g. sarcoidosis, miliary tuberculosis).
- Posthepatic obstruction occurs at any level between liver and right heart, including hepatic vein thrombosis, inferior vena cava thrombosis, inferior vena cava congenital malformation, and constrictive pericarditis.
- HVPG (hepatic venous pressure gradient) measurement has been accepted as the gold standard for assessing the severity of portal hypertension, and replaced the old one - contrast angiography. Portal hypertension is defined as HVPG greater than or equal to 5mm Hg and is considered to be clinically significant when HVPG exceeds 10 to 12 mm Hg) .(Kok T et al 1999)

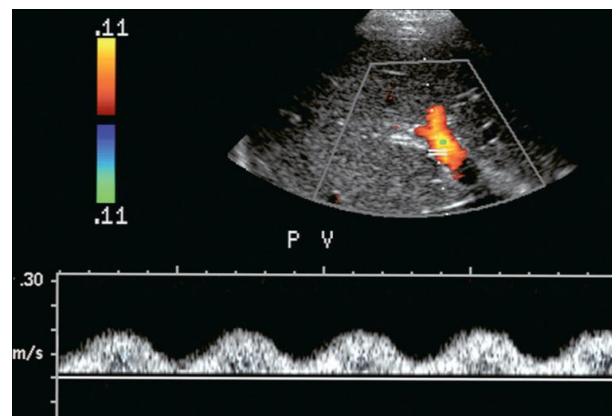


FIGURE 2.10: Spectral hepatic vein Doppler tracing in a patient with alcoholic cirrhosis. Portal vein flow profile has become more sinusoidal although the flow direction does remain hepatopetal throughout the cardiac cycle. This degree of periodicity is beyond what we would expect in a normal portal vein. The dip in antegrade velocity coincides with hepatic arterial systole. (Myron A. Pozniak et al 2014)

2.2.2 Portal vein thrombosis:

Portal vein thrombosis, previously known as Cauchois–Eppinger–Frugoni syndrome, is a form of venous thrombosis affecting the hepatic portal vein, which can lead to portal hypertension and reduction in the blood supply to the liver. (Myron A. Pozniak et al 2014)

2.2.2 .1 Signs and symptoms

Portal vein thrombosis can cause fever, symptoms of indigestion, and gradually worsening abdominal pain. However, it can also develop without causing symptoms, leading to portal hypertension before it is diagnosed.

Other symptoms can develop based on the cause. For example, if portal vein thrombosis develops due to liver cirrhosis, bleeding or other signs of liver disease may be present. If portal vein thrombosis develops due to pylephlebitis, signs of infection such as fever, chills, night sweats may be present. Causes can include pancreatitis, cirrhosis, diverticulitis, and cholangiocarcinoma. It is also a known complication of splenectomy. The diagnosis of portal vein thrombosis is usually made by ultrasound, computed tomography with contrast or magnetic resonance imaging.

D-dimer levels in the blood may be elevated as a result of fibrin degradation. (Myron A. Pozniak et al 2014).

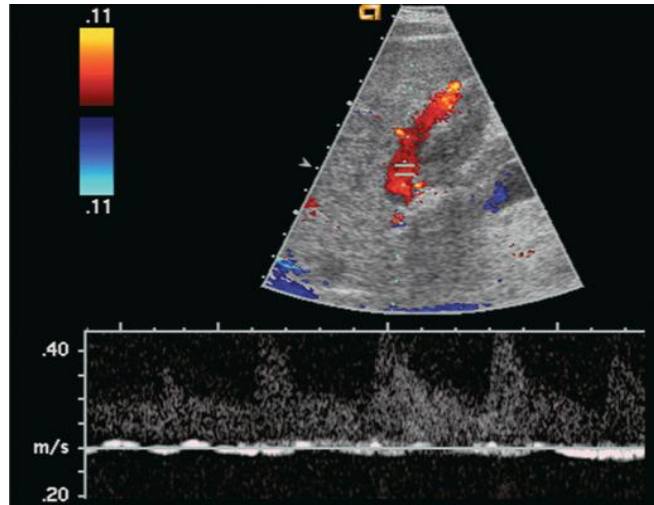


FIGURE 2.11 (A): Spectral Doppler tracing of a patient with end-stage liver disease being considered for liver transplantation. With neutral breath hold, flow in this portal vein is barely perceptible. It oscillates between hepatofugal during arterial systole and hepatopetal during arterial diastole.

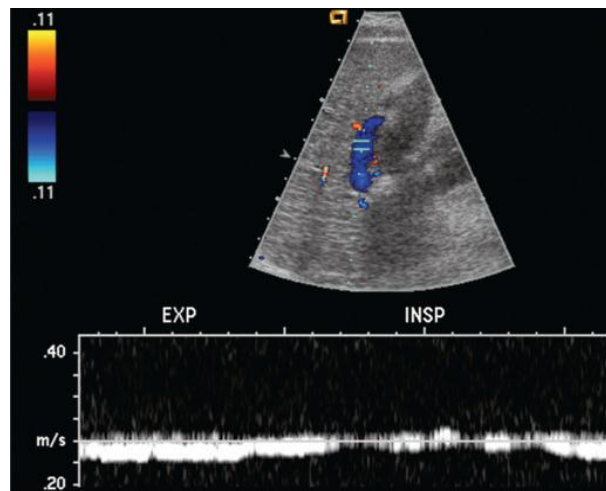


FIGURE 2.11 (B): When instructed to forcefully breathe in and out, this patient's portal flow became more dynamic. During forced expiration with elevated intra thoracic pressure there is increasing resistance to hepatic venous outflow forcing portal vein flow to become hepatofugal. During inspiration with negative intra thoracic pressure, this decreases the resistance to hepatic venous outflow, thereby causing flow to become almost stagnant. Note also that colour

Doppler flow in the portal vein is reversed from the prior image, simply by the change in intra thoracic pressure. (Myron A. Pozniak et al, 2014.p165)

2.2.3 Portal vein Varices:

As portal hypertension progresses and pressure raises to 15 or 20 mmHg, sufficient pressure exists to cause the development of avarices. These collateral pathways shunt blood from the portal to the systemic circulation.

The more common channels are the short gastric, left gastric and coronary veins; recanalised umbilical or paraumbilical vein; and splenorenal-mesenteric collaterals.

Other, less typical, pathways include pericholecystic, iliolumbar, gonadal, haemorrhoidal, and ascending retrosternal veins. Indeed, any vein in the abdomen may serve as potential collateral to the systemic circulation and may be incorporated in a very convoluted shunt. (Myron A. Pozniak et al, 2014)

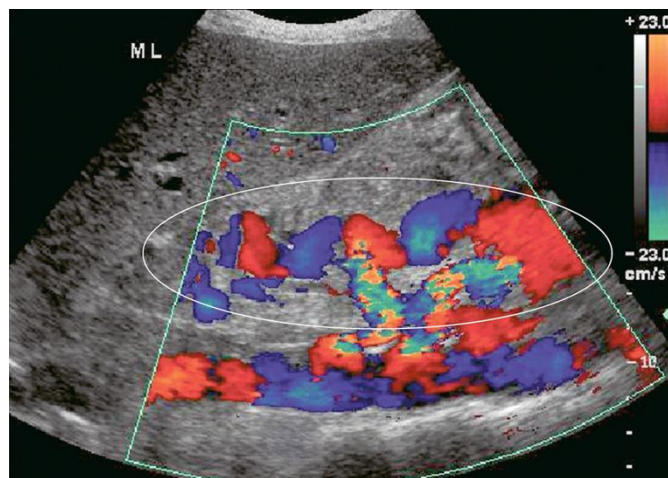


FIGURE 2.12: Longitudinal colour Doppler image in the midline of a patient with portal hypertension. A large tortuous left gastric varix is seen coursing from the region of the coeliac axis towards the gastro-oesophageal junction. Whereas short gastric varices tend to be a plexus of small vessels, the left gastric varix is typically a single large tortuous vessel. (Myron A. Pozniak et al 2014. 161)

2.2.4 Neoplastic Invasion:

HCC has a propensity to invade the portal and hepatic veins. Intravascular tumour is classified as stage IV disease and is considered unresectable. Involvement of the portal vein by tumour may cause an increase in its cross-sectional area and a decrease in portal vein flow. (Myron A. Pozniak et al, 2014)

Tumour in the portal vein receives its blood supply from the hepatic artery and spectral Doppler of the ‘thrombus’ will show an arterial waveform. Arterial velocities usually project in a hepatofugal direction, supplying the tumour as it grows out of the liver. Bland thrombus will not manifest such a tracing on Doppler, so that invasive tumour can be differentiated from bland thrombus and the diagnosis of stage IV HCC with vascular invasion confirmed. (Myron A. Pozniak et al, 2014)

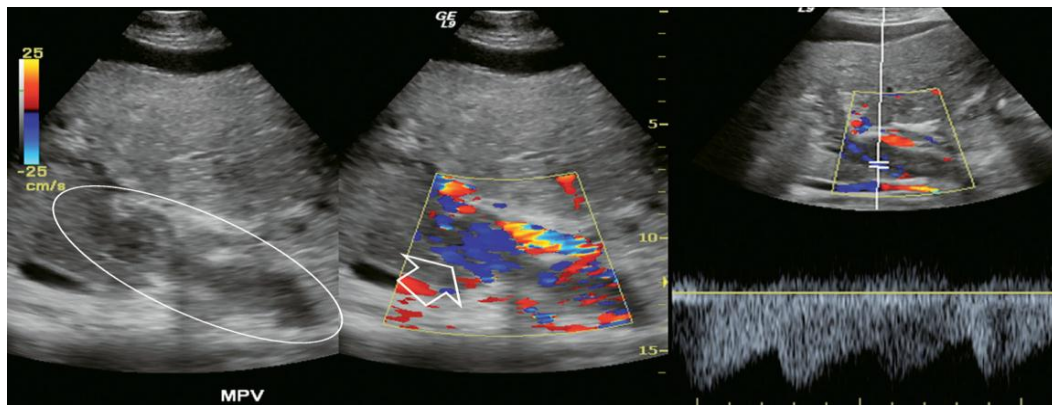


FIGURE 2.13: Grayscale imaging, colour Doppler and spectral Doppler tracing over the portal vein in a patient with known advanced hepatocellular carcinoma (HCC). Echogenic material fills the portal vein. Colour Doppler shows numerous small vessels with flow but in a hepatofugal direction. Spectral Doppler tracing over these vessels shows a very low-resistance arterial waveform. This is vascular invasion of the portal vein by hepatocellular

carcinoma. The tumour originates in the liver and grows outward; therefore, the arterial supply runs in a hepatofugal direction. This is tumour neovascularity, therefore, resistance is low. (Myron A. Pozniak et al, 2014).

2.2.5 Portal Vein Aneurysm:

Aneurysm of the portal vein has been reported, but it is extremely rare. The vein may enlarge to a diameter of 3 cm or larger. Spectral Doppler should be applied to confirm a portal vein waveform and rule out hepatic artery aneurysm since the latter carries a much higher incidence of complications and rupture. (Myron A. Pozniak et al 2014)

2.2.6 Portal Vein Gas:

Air bubbles may be seen in the portal vein and its branches in a variety of gastrointestinal disorders, such as sepsis, obstruction with distension, necrotizing enterocolitis, infarction or ulceration. Numerous tiny hyperechoic foci can be seen in the portal vein, flowing into the liver. Since these bubbles are moving fairly rapidly, their perception is best with high temporal resolution. (Myron A. Pozniak et al, 2014)

This is accomplished by limiting the field of view to the area of the portal vein, scanning with a single focal zone and minimising, or turning off, frame averaging. The spectral Doppler tracing reveals sharp bidirectional spikes superimposed on the Doppler tracing of the portal vein. These spikes do not reflect a higher velocity of the air bubbles but are due to artifact resulting from the system being set to the strength of reflected signal from red blood cells. Since air bubbles are much more intense reflectors, their echoes register as spikes of noise on the tracing. (Myron A. Pozniak et al, 2014)

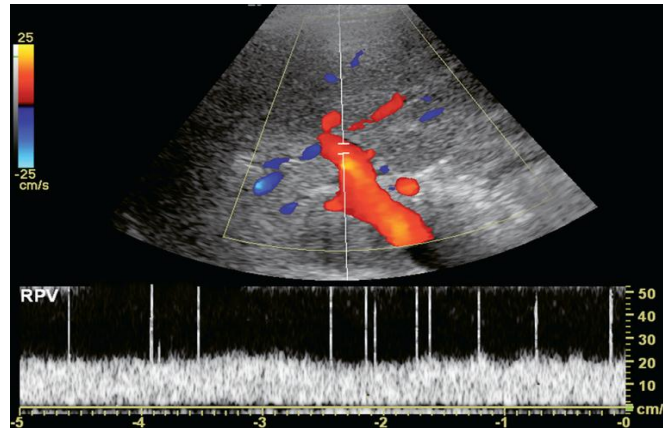


FIGURE 2.14: Spectral Doppler tracing of the portal vein in a patient with pneumatosis intestinalis. The spikes present in this spectral Doppler tracing are caused by air bubbles in the portal vein. These bubbles are travelling at the same velocity as the rest of the blood in the portal vein, but with the spectral gain set for blood, the intense sound reflection caused by the passing air bubbles creates spikes of noise. (Myron A. Pozniak et al, 2014)

2.3 Hepatic artery pathology:

2.3.1 Hepatic Artery Aneurysm/Arteriovenous Fistula:

Most hepatic artery aneurysms are extrahepatic and may be congenital or acquired. Pancreatitis, trauma, or liver biopsy are the most common aetiologies. Mycotic aneurysms can be seen in immunocompromised patients, those with bacterial endocarditis or those abusing intravenous drugs. Sonography demonstrates a rounded area with swirling flow on colour. The spectral tracing is usually quite distorted due to turbulence. A clot may eventually develop within the aneurysm or pseudoaneurysm. (Myron A. Pozniak et al, 2014)

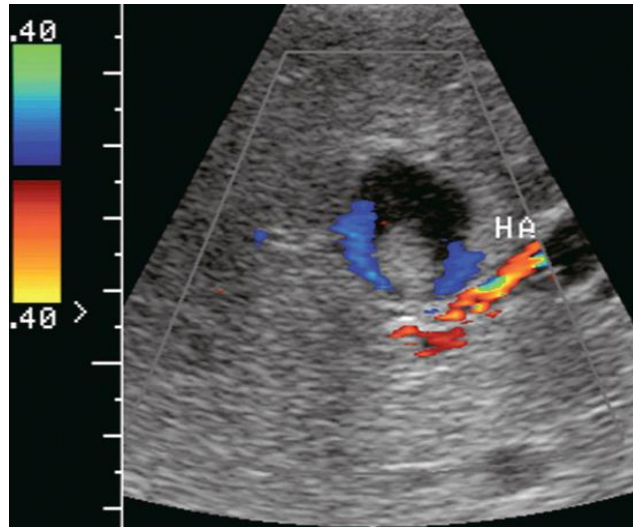


FIGURE 2.15: Transverse colour Doppler image of the mid-liver. A rounded lesion is present with some internal debris. Flow is perceived around this debris. A turbulent arterial spectral Doppler waveform was identified at the neck. Angiography confirmed that this was a partially thrombosed intrahepatic hepatic artery aneurysm. (Myron A. Pozniak et al, 2014)

2.3.2 Hereditary Haemorrhagic Telangiectasia (Osler–Rendu–Weber Disease):

This disease is characterised by multiple small aneurismal telangiectases distributed over the skin, mucous membranes, alimentary tract, liver, brain and spleen. These patients have a tendency for frequent haemorrhages requiring transfusion. Vascular lesions in the liver can evolve into arterial venous fistulas and aneurysms. Ultrasound may reveal large hepatic arteries feeding large, ectatic, serpiginous arteriovenous malformations, which in turn feed large draining veins. (Myron A. Pozniak et al, 2014).

2.4 Portal Vein Examination Technique

The PV ultrasound examination was explained to each subject and a brief history obtained. Biodata, which include age and sex was recorded for each patient. Prior to the examination patients were asked to fast for at least 6-8 h. This reduces excess bowel gas that may obscure the main PV and distends the biliary ducts. The examination was performed using a high-resolution real-time Doppler ultrasound scanner equipped with 3.5 MHz curvilinear transducer. (Carol M. Rumack. et al 2011)

This transducer provides excellent resolution for deep abdominal visceral organs such as the liver. The ultrasound examination was conducted in the supine position. Ultrasound gel was applied, and transducer placed in the epigastrium in both transverse and longitudinal planes to evaluate the main PV, and right hypochondria region to evaluate the right and left PVs. The intrahepatic PVs in some patients were also examined in sub-coastal or inter-coastal approach with the patient either in supine, right anterior oblique or left posterior oblique as needed. In patients with excess gas in the duodenum and antrum that obscured the distal extrahepatic PV, they were placed in an erect right anterior oblique position to displace the air. The PVs were identified using color Doppler, which differentiates them from the adjacent hepatic arteries and bile ducts. Antero-posterior (AP) and transverse diameter of the main PV were measured at its midpoint (A to B), while the values for right PV (C to D) and left PV (E to F) were measured at the level of their bifurcation and. The AP diameter from proximal to distal wall was obtained using the longitudinal view while the transverse diameter from the medial to lateral wall was obtained from the transverse view. (Au / members2003).

2.4.1 Imaging protocol:

Patient should be fasted at least 6 to 8 hours prior to US examination.

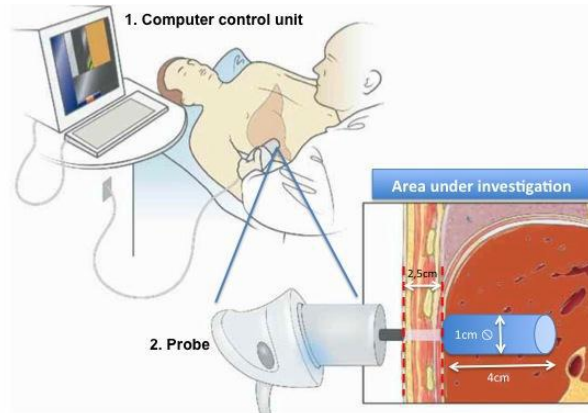


FIGURE 2.16: Diagram showing the scanning areas used to obtain the portal vein (ultrasound pedia, 2007).

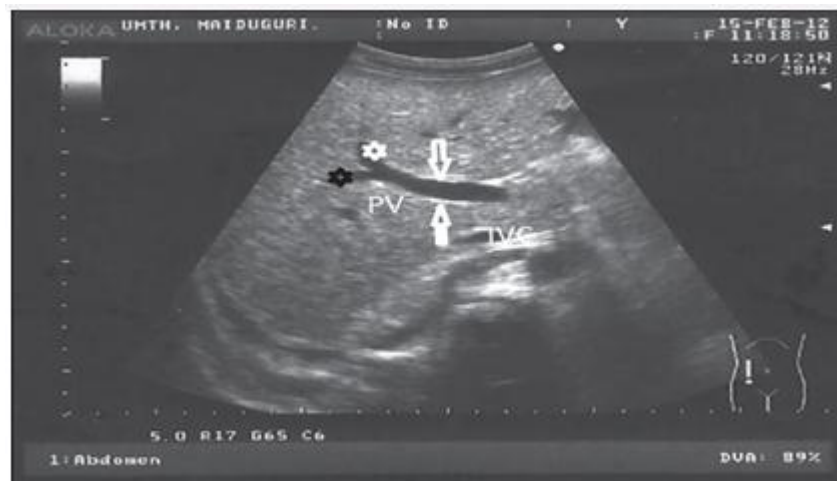

FIGURE 2.17: Shows normal portal vein ultrasound (au/members2003)

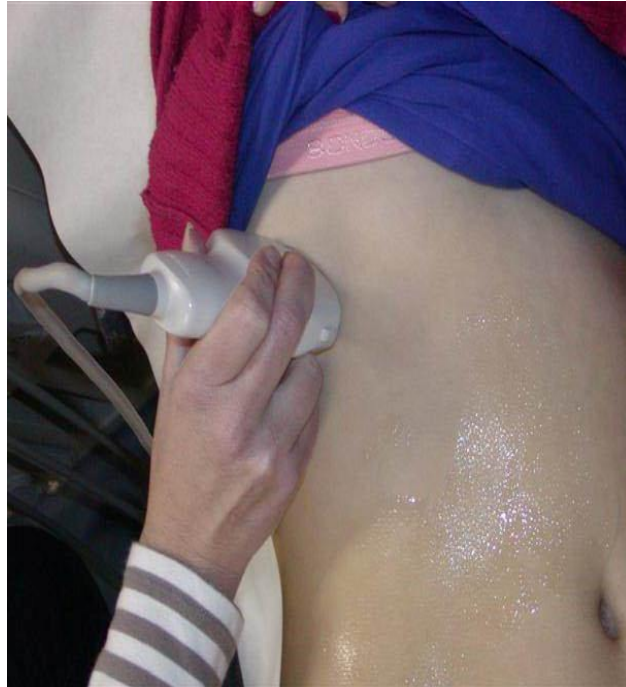

FIGURE 2.18: Showing scan plane intercostal of liver from (Wikipedia 2016)

2.4.2History:

The potential of ultrasound as an imaging modality was realized as early as the late 1940s when, utilizing sonar and radar technology developed during World War II, several groups of investigators around the world started exploring diagnostic capabilities of ultrasound (Goldberg and Kimmelman, 1988). In the early 1950s, John Wild and John Reid in Minnesota developed a prototype B-mode ultrasonic imaging instrument and were able to demonstrate the capability of ultrasound for imaging and characterization of cancerous tissues at frequencies as high as 15 Mhz. John Wild's pioneering effort and accomplishment were recognized with the Japan Prize in 1991.

At the same time, apparently unaware of the effort by Wild and Reid, Douglas Howry and Joseph Holms at the University of Colorado at Denver also built an ultrasonic imaging device with which they produced cross-sectional images of the arm and leg. Starting in the late 1940s, medical applications of ultrasound in Japan were explored by Kenji Tanaka and Toshio Wagai. Two Japanese investigators, Shigeo Satomura and Yasuhara Nimura, were credited with the earliest development of ultrasonic Doppler devices for monitoring tissue motion and blood flow in 1955. Virtually simultaneously with the work going on in Japan and in the U.S., Inge Edler and Hellmuth Hertz at the University of Lund in Sweden worked on echocardiography, an ultrasound imaging technique for imaging cardiac structures and monitoring cardiac functions. In parallel with these developments on the diagnostic front, William Fry and his colleagues at the University of Illinois at Urbana worked on using high-intensity ultrasound beams to treat neurological disorders in the brain. The primary form of ultrasonic imaging to date has been that of a pulse–echo mode. The principle is very similar to that of sonar and radar. In essence, following an ultrasonic pulse transmission echoes from the medium being interrogated are detected and used to form an image. Much of the terminology used in ultrasound

was imported from the field of sonar and radar. Although pulse–echo ultrasound had been used to diagnose a variety of medical problems since the 1950s, it did not become a widely accepted diagnostic tool until the early 1970s when gray-scale ultrasound with nonlinear echo amplitude to gray level mapping was introduced. Continuous wave (CW) and pulsed wave Doppler (PW) ultrasound devices for measuring blood flow also became available during that time. Duplex ultrasound scanners that combined both functions, thus allowing the imaging of anatomy and the measurement of blood flow with one single instrument, soon followed. Today, ultrasound is the second most utilized diagnostic imaging modality in medicine, second only to conventional x-ray, and is a critically important diagnostic tool of any medical facility.(diagnostic ultrasound Imaging and blood flow Measurements(K. Kirk Shung © 2006).

2.5: Previous studies:

2.5.1. Assessment of Normal Doppler Parameters of Portal Vein and Hepatic Artery in 37 Healthy Iranian Volunteers: Hadi Rokni Yazdi 2006 Tehran, Iran.

Doppler sonography is a valuable noninvasive method for the diagnosis of various liver diseases. However, there is scarce information on normal parameters of hepatic artery (HA) and portal vein (PV) in Iran. This study was conducted to assess normal Doppler indices of HA and PV in normal Iranian population. In this cross-sectional study, 37 (18 female, 19 male) healthy volunteers aged 20-40 years underwent Doppler sonography after 8 hours of fasting. PV was assessed at crossing point with inferior vena cava in normal respiration and HA in the hepatic hilum. The mean \pm SD PV diameter was 9.36 \pm 1.65 mm. The mean \pm SD maximum, and mean velocity of PV were 35.28 \pm 16.54 and 27.317 \pm 13.139, respectively. The mean \pm SD peak systolic velocity and resistance index of HA were 67.64 \pm 33.48 and 0.76 \pm 0.07, respectively. Normal Doppler parameters of HA and PV depend on different factors like gender, respiratory phase and technique of measurement and there is no uniform standard technique for these measurements. These factors must be considered when using Doppler parameters for diagnosis of liver disease.

2.5.2 Portal vein Measurement by Real Time Sonography: Jeffrey Weinreb¹, Sheila Kumari, Gail Phillips, Rubem Pochaczewsky 1982 American Roentgen Ray Society.

Real-time sonography affords a simple and reliable definition of the portal veins. A standard chart of normal portal vein measurements is presented. The mean diameter of the portal vein in 107 patients aged 21 -40 years was 11 \pm 2 mm. This information can be useful in evaluating portal hypertension in a variety of clinical situations. Sonography has been found to be a valuable tool for diagnosing abnormalities of the portal venous system. With the development

of real-time gray- scale sonography, evaluation of the portal venous system has become relatively simple and reliable. While the medical literature abounds with descriptions of normal and abnormal sonographic portal venous anatomy, little attention has been focused on actual measurements of the portal vein. This information may be particularly important in detecting and evaluating patients with portal hypertension. To obtain this data, we sonographically measured the portal veins in a large series of normal patients.

2.5.3 Sonographic Evaluation of Normal Portal Vein Diameter in Nigerians Anakwue A. C., Uloma Nwogu, 2009, Nigeria Portal vein size is a diagnostic index useful in measuring portal hypertension which is found in many disease conditions including cirrhosis where it occurs in > 60% of cases. The aim of this work is to determine the normal portal vein diameter in adult Nigerians. Method: In this work we used a 2D ultrasound – a non- invasive method to assess the portal vein size in 200 adults aged 20 -79 years of both sexes. Results: The mean diameter of normal portal vein in the subjects was 11.45mm+/- 1.49. Conclusion: The portal vein diameter obtained in this work is comparable to that found in Caucasians. This information can be useful in diagnosing and treating portal hypertension in a variety of clinical situations.

2.5.4 Impact of anthropometrical parameters on portal vein diameter and liver size in a subset of Karachi based population Tanya Raza Siddiqui, Nuzhat Hassan, and Pashmina Gul, 2014; Karachi The purpose was to study the impact of anthropometrical parameters on portal vein diameter and liver size by ultrasound in a subset of Karachi population.

Methods: Four hundred and fifty nine apparently healthy subjects were included in this cross sectional study. After recording weight and height of each subject, Portal vein diameter and both liver lobes were measured by gray scale

ultrasonography. Students T test and ANOVA were applied for statistical analyses. Results: With increasing age, portal vein diameter and right lobe of liver increased significantly (p value < 0.001). Increase in portal vein diameter was also observed with rise in body mass index (0.8 cm in underweight - 1.1 cm in obese subjects). Sizes of right and left liver lobes also increased with a rise in body mass index (p value < 0.001 and 0.001). Gender, however, did not have any effect on portal vein diameter and liver size. Conclusion: Age and body mass index are reliable parameters to consider for avoiding false positive diagnosis of hepatomegaly and portal hypertension. Knowing the right and left liver size with respect to anthropometrical measurements also assist a clinician in selecting a subject for liver transplantation. Key Words: Anthropometrical measurements, Liver, Portal vein diameter.

Chapter Three

Materials and methods

Chapter three **Materials and methods**

3. Methodology

3.1.1 types of the study:

Fifty Sudanese patients coming for checking up they are not complain, their age ranged between 16-30yrs, (26) female and (24) male.

Inclusion criteria:

- Sudanese patient with expected normal liver.
- Aged between 16-30yrs.

Exclusion criteria:

- Very ill or known liver disease patient.
- Hypertensive and diabetic patient.

3.2 Sample size

Adult subjects of age ranged between 16 and 30 Years.

3.3 Area of the study:

This study was conducted at Ribat teaching hospital, Khartoum state.

3.4 Duration of the study:

This study was conducted during the period from June to August 2018.

3.5 Materials:

All studies were obtained with high resolution ultrasound machine (Ultrasound machine of complete capabilities (TOSHIBA US SYSTEM); with two probes (curvilinear = 3.5-7 MHz & linear=7.5 -12 MHz).

3.6 Data collection:

The data of the study was collected by using data sheet to obtain variables of the portal vein and hepatic artery flow direction (Doppler indices) and velocity in normal liver.

Researcher uses excel and SPSS to analyze the data to find the significant difference between the patients (normal), and Variables used for data collection are age, gender, RI, velocity, and relationship between body characteristics and

blood flow indices.

3.7 variables of data collection:

The data of the study was collected using the following variables: the portal vein caliber, flow direction and velocity in normal liver. The third variable will be the liver texture as well as the hepatic artery peak systolic and end diastolic velocities plus the resistive index in normal livers.

The fifth variable is the liver size which then followed by the following variables: the Doppler indices =RI, PI, S/D ratio, PSV, EDV, sonic window of the hepatic artery.

3.8 Ethical approval:

Ethical approval was granted from the hospital. In addition, consent from the patients signed and oral agreement after they understand what will be done in the study. The objects will be informed that this did not include or disclose any [ID] information concerning the patient.

Ethical approval of all procedures performed in this study involving human participants in accordance with the ethical standards of the institutional research committee and with the 1964 Helsinki declaration and its later amendments or comparable ethical standards (Kaunas Regional Committee for Biomedical Research Ethics No. BE 2–17).

3.9 Technique:

We would performed both transverse and longitudinal ultrasound techniques plus coronal oblique; putting the transducer in four main points: 1-

the mid-line, 2- the mid clavicular line, 3- the anterior and 4- the mid axillary lines all are intercostally line that made a perpendicular imaginary line from the xiphisternum. In addition, sub costal scan done in the same points.

3.10 Data analysis:

Data were analyzed using SPSS statistical program for significance of tests.

Chapter four

Results and Analysis

Chapter four

Results and Analysis

The following tables presented the data obtained from 50 patients who were examined using ultrasonography. The portal vein diameter, velocity, and hepatic artery resistive index measured.

Table (4-1): Distribution of sample study according to gender

Gender	Frequency	Percent
Male	24	48%
Female	26	52%
Total	50	100%

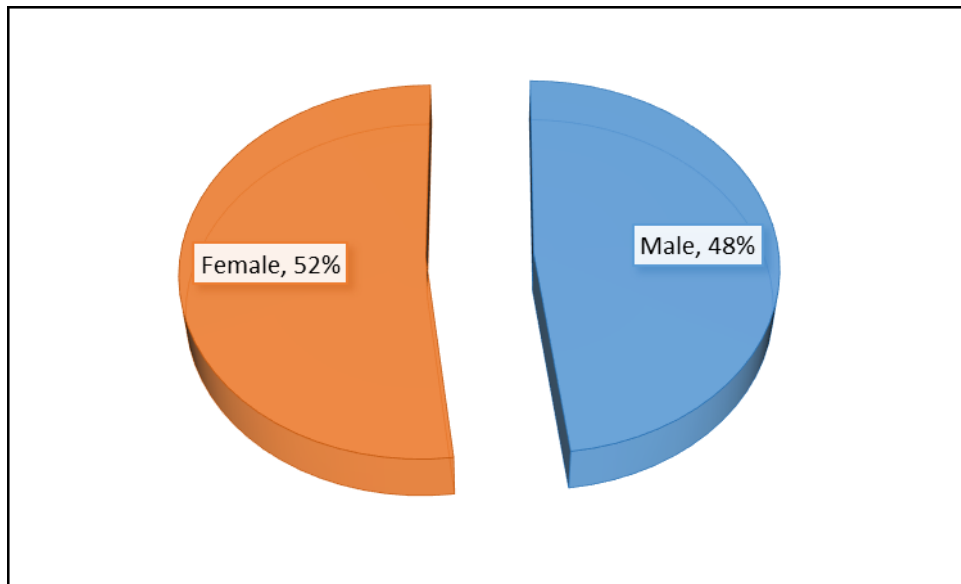


Figure (1): Distribution of sample study according to gender

Table (2): Descriptive Statistics for variables of study

Descriptive Statistics	[Min, Max]	Mean \pm SD
Age	[16, 30]	21.9 \pm 4.63
Resistive Index (RI)	[0.55, 0.76]	0.62 \pm 0.07
Diameter (mm)	[7, 13]	9.9 \pm 2.08
Velocity (cm/s)	[10, 20]	15.1 \pm 3.10

Max= Maximum, Min= Minimum, SD= Standard deviation

Table (3): Compare means to variables of study according to gender

Gender	Age	Resistive Index (RI)	Diameter (mm)	Velocity (cm/s)
Male	22.3 \pm 4.4	0.64 \pm 0.07	10.1 \pm 2.3	15.1 \pm 2.8
Female	21.5 \pm 4.9	0.60 \pm 0.06	9.7 \pm 1.9	15.1 \pm 3.4
P-value	0.531	0.024*	0.428	0.994

*There is a significant difference between means

Table (4): Correlation coefficient between variables of study

Correlations		Resistive Index (RI)	Diameter (mm)	Velocity (cm/s)
Age	Pearson Correlation	-0.003	0.436	0.077
	<i>P</i> -value	0.983	0.002*	0.593
Resistive Index (RI)	Pearson Correlation		-0.063	0.146
	<i>P</i> -value		0.661	0.31
Diameter (mm)	Pearson Correlation			-0.091
	<i>P</i> -value			0.532

*There is a significant relationship between the variables

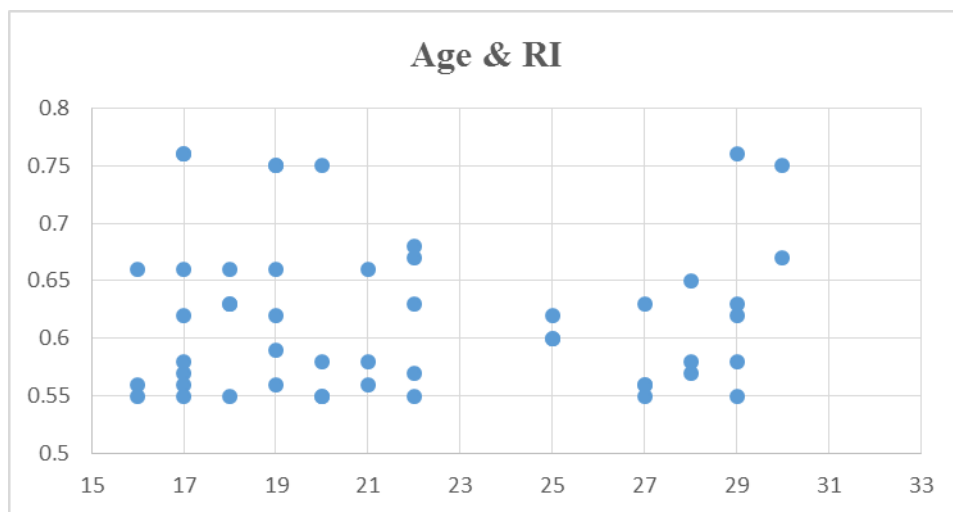


Figure (2): Scatter plot between Age & RI

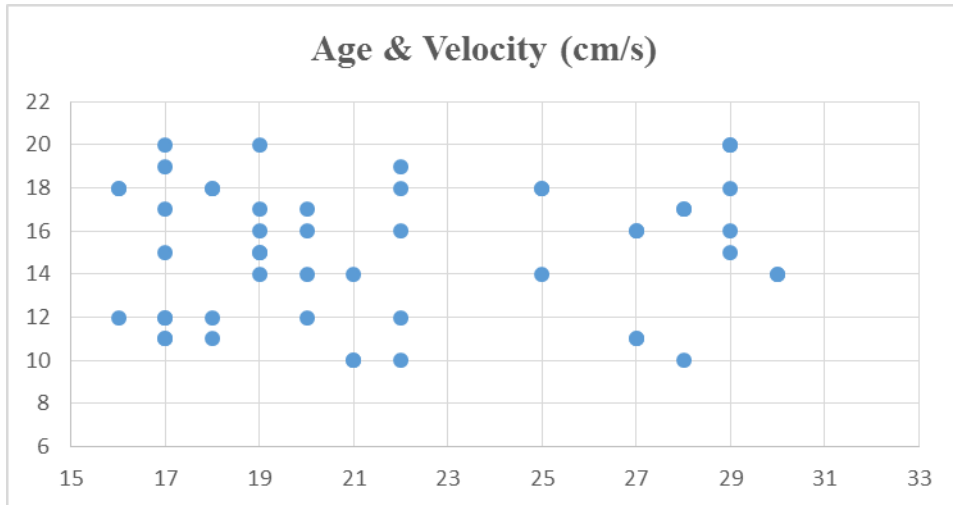


Figure (3): Scatter plot between Age & Velocity (cm/s)

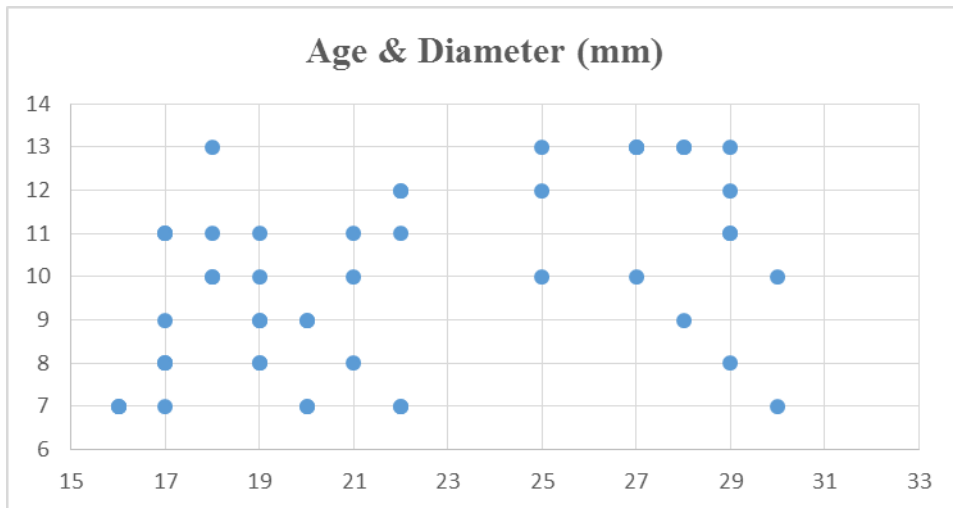


Figure (4): Scatter plot between Age & Diameter (mm)

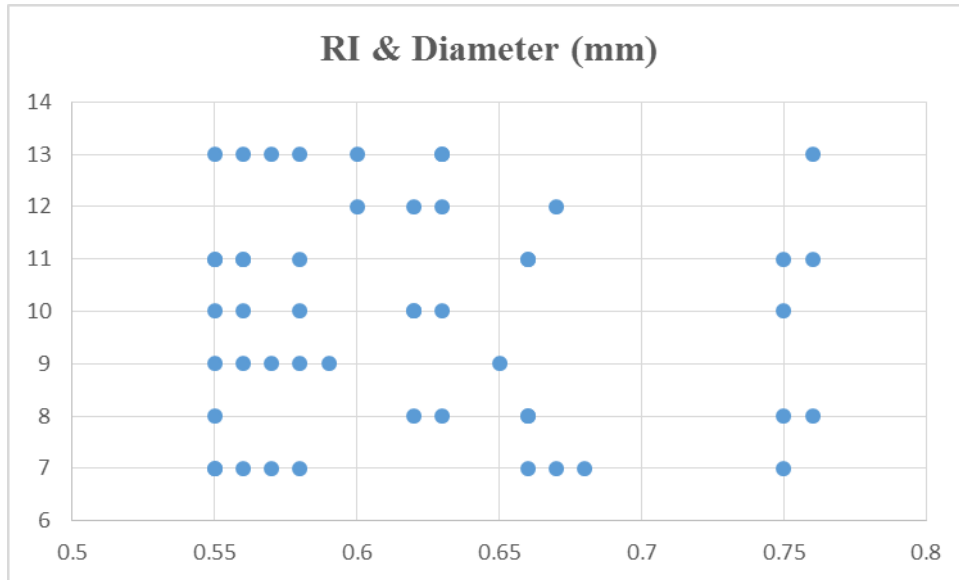


Figure (5): Scatter plot between RI & Diameter (mm)

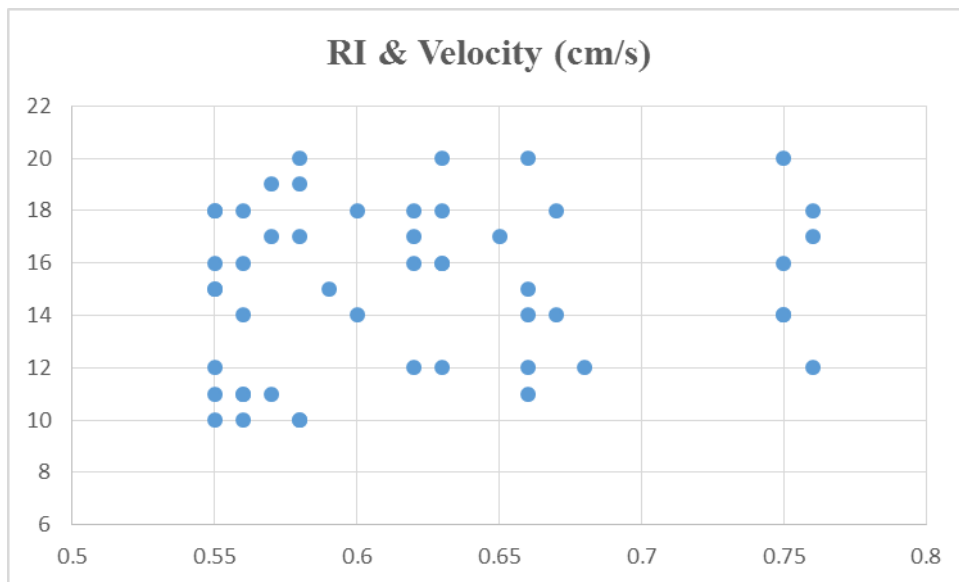


Figure (6): Scatter plot between RI & Velocity (cm/s)

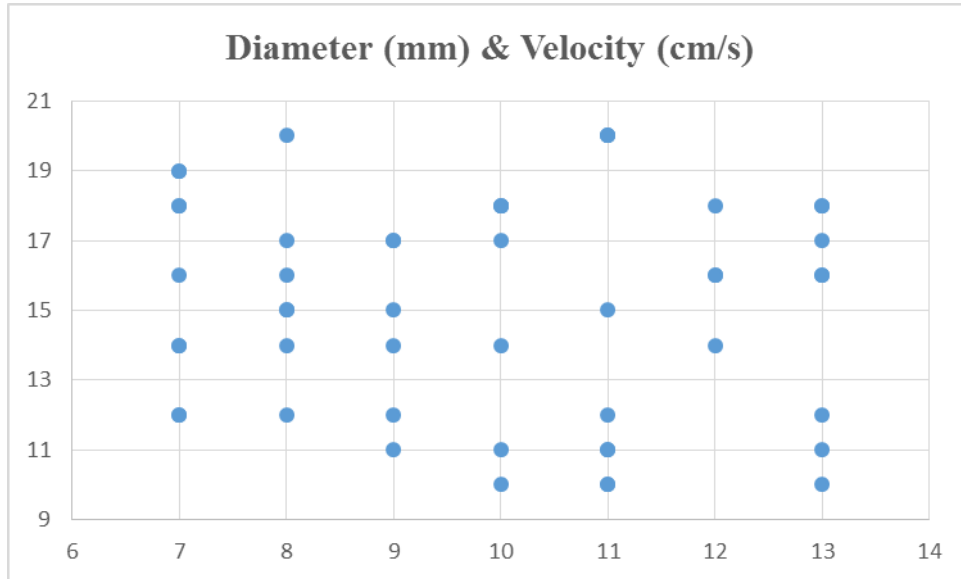


Figure (7): Scatter plot between Diameter (mm) & Velocity (cm/s)

Chapter Five

Discussion, conclusion and Recommendations

Discussion, conclusion and Recommendations

5-1 Discussion

This research conducted to know the importance of duplex Ultrasonography in measurement of portal tract blood vessels among youth Sudanese. Fifty normal liver Doppler scan was done to be as a reference as a Sudanese normal index. The 50 normal objects population is the patients attending Al Rabat University Hospital to scan for diseases not related to liver. The study done during the period from 1st June 2018 to 30th August 2018. The following analysis used the Statistical Package for Social Science – SPSS version 20.0. The following pages discuss the results of the analysis.

This study includes 50 patients, the data were collected by selected 4 variables (The RI, velocity, age, gender and diameter) using Duplex ultrasonography. The results include the mean, maximum, minimum and standard deviation of the variables as well as relationship between body characteristics and blood flow indices. The percentage of males was 48%, while the percentage of females was 52%, this is shown in both table (4-1) & represented in an exploded pie chart, (Figure 4-1).

Table 4-2 shows the mean age of patients included in this study was 21.9 ± 4.63 , with their mean velocity 15.1 ± 3.10 . Their average measurement of their portal vein diameter was 9.9 ± 2.08 mm, which coincides with the normal ranges in the literature (< 13 mm). The blood flow index (RI) of these patients in average was 0.62 ± 0.07 ; this is within the normal range (0.55-0.75).

The Study resulted that mean of age for cases under study was 21.9 years with stander deviation ± 4.63 years, while the mean of Resistive index (RI) of hepatic artery 0.62 with stander deviation 0.07, mean of Portal vein diameter (mm) 9.9 mm with stander deviation 2.08 mm, while mean portal vein velocity (cm/s)

15.1 (cm/s) with stander deviation 3.10 (cm/s).

The Study concluded that there was no significant difference of correlation between the portal vein diameters, velocity with age and gender of cases, while there was a difference significant correlation between hepatic artery resistive indexes (RI) with gender.

The correlation coefficient between the resistive index, age, gender and velocity of portal vein and hepatic artery show there was no relationship except of portal vein diameter with gender (P-value < 0.05) it was a proportional relationship.

The scatter plot seen in figure (4-6) show the relation between the resistive index of the hepatic artery & the velocity; the majority of the velocities ranges between (12-18 cm/s) all show a resistive index with normal range known in the literature(0.55-0.75).

In conclusion; the whole study done using Doppler Ultrasonography in the portal vein diameter & velocity plus the hepatic artery & the resistive index among Sudanese people was found to be within normal and similar to other studies in the literature (see chapter 2).

5.2 Conclusion

This study is concerned with normal portal vein diameter by using gray scale and Doppler ultrasound. The study gives indigenous index for Sudanese normal portal vein diameter and velocity correlate with body characteristic. Ultrasound scanning is noninvasive, informative, and cost effective tools measuring portal vein and its velocity. There is significance relation between Sudanese portal vein diameter and velocity and stander one. There is significant correlation found between portal vein diameter and age as well as the weight of patient respectively, increase diameter when these parameter increase.

No significant correlation was detected between portal vein diameter and height and abdominal circumference of patient, respectively. While highly significant correlation was noticed between portal vein diameter and portal vein velocity of patient under investigation. The result was expected and goes with previous studies.

The resistive index of the main hepatic artery ranges show the same values seen in the literature all over the world; this reflects that any deviation from normality can diagnose the deep liver pathology specially to differentiate between benign & malignant nodules as well as the cirrhotic nodules.

5.3 Recommendations

- Measurement of portal vein diameter and velocity is important in ultrasound examination in order to early detecting of portal hypertension; therefore, it is a must to know the normal values.
- Duplex Ultrasound should be used routinely for early detection of portal hypertension as well as to have indigenous index for correlate that with body characteristic.
- Sonographer should be well trained in taking measurement accurately.
- Taking into account the patient preparation before ultrasound get correct measurements.
- Observance the importance of body characteristic that affect in measurement.
- Further studies are recommended to correlate normal portal vein diameter, velocity and resistive index of hepatic artery with liver size using large sampling for accurate result.

References:

- 1) Anakwue AC, Anakwue RC, Ugwu AC, Nwogu UB, Idigo FU, Agwu KK 2009, Sonographic Evaluation of Normal Portal Vein Diameter in Nigerians. *European Journal of Scientific Research*.
- 2) Assessment of Normal Doppler Parameters of Portal Vein and Hepatic Artery in 37 Healthy Iranian Volunteers: Hadi Rokni Yazdi 2006 Tehran, Iran. *J. Radiol.*, Summer 2006.
- 3) Benjamin L. Shneider; Sherman, Philip M. (2008). *Pediatric Gastrointestinal Disease*. Connecticut: PMPH-USA. p. 751. ISBN 1-55009-364-9.
- 4) Carol M. Rumack. et al 2011. *Diagnostic Ultrasound*. 4th Ed, ISBN 978-0-323-05397-6 Curry R, Tempkin B. 2004 *Sonography: Introduction to Normal Structure and Function*. 2nd Ed. St. Louis: Saunders, 2004:356–363.
- 5) Harold M Chung; Chung, Kyung Won (2008). *Gross anatomy*. Philadelphia: Wolters Kluwer Health/Lippincott Williams & Wilkins. p. 208. ISBN 0-7817-7174-9.
- 6) Henry Gray (1901). *Anatomy, Descriptive and Surgical* (16 ed.). Philadelphia: Lea Brothers. p. 619. Harold.
- 7) Impact of anthropometrical parameters on portal vein diameter and liver size in a subset of Karachi based population Tanya Raza Siddiqui, Nuzhat Hassan, and Pashmina Gul , 2014.
- 8) Jeffrey Weinreb¹, Sheila Kumari, Gail Phillips, Rubem 1982 American Roentgen Ray Society.
- 9) Kok T, van der Jagt EJ, Haagsma EB, Bijleveld CM, Jansen PL, Boeve WJ. The value of Doppler ultrasound in cirrhosis and portal hypertension. *Scand J Gastroenterol Suppl* 1999;230:82-8.
- 10) Myron A. Pozniak et al 2014. *Clinical Doppler Ultrasound* (3rd ed). P.149 e-book ISBN: 9780702055379.
- 11) Nyberg D, Mc Gaham J, Pretorius D, et al 2003. *Diagnostic Imaging of Fetal Anomalies*. Philadelphia: Lippincott Williams & Wilkins, 2003:85–132.
- 12) Plinio Rossi; L. Broglia (2000). *Portal Hypertension: Diagnostic Imaging and Imaging-Guided Therapy*. Berlin: Springer. p. 51. ISBN 3-540-65797-5.
- 13) Wood MM, Romine LE, Lee YK, et al. 2010, Spectral Doppler signature waveforms in ultrasonography: a review of normal and abnormal waveforms .*Ultrasound Q*;26(2):83–99.

Links:

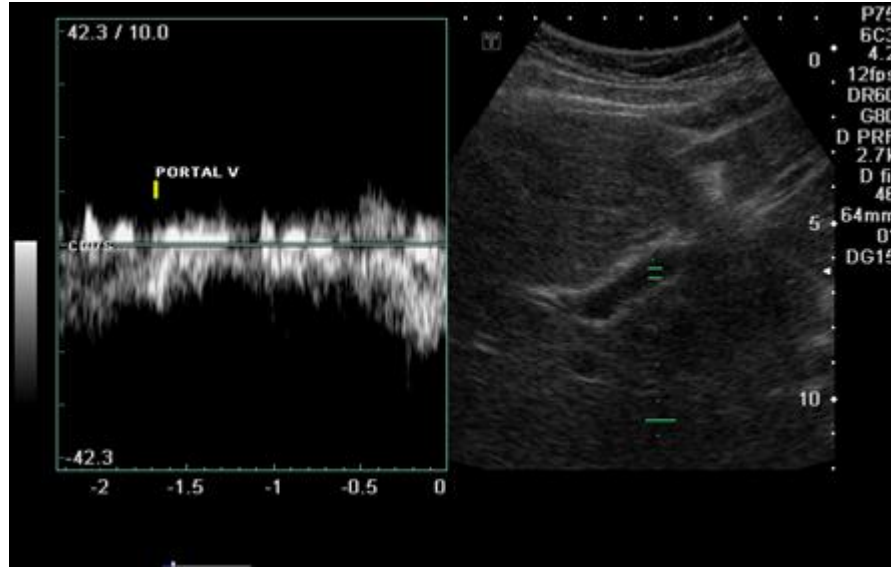
<http://www.healthline.com/human-body-maps/portal-vein>.

Sonographic Evaluation of Normal Portal Vein Diameter in Nigerians Anakwue

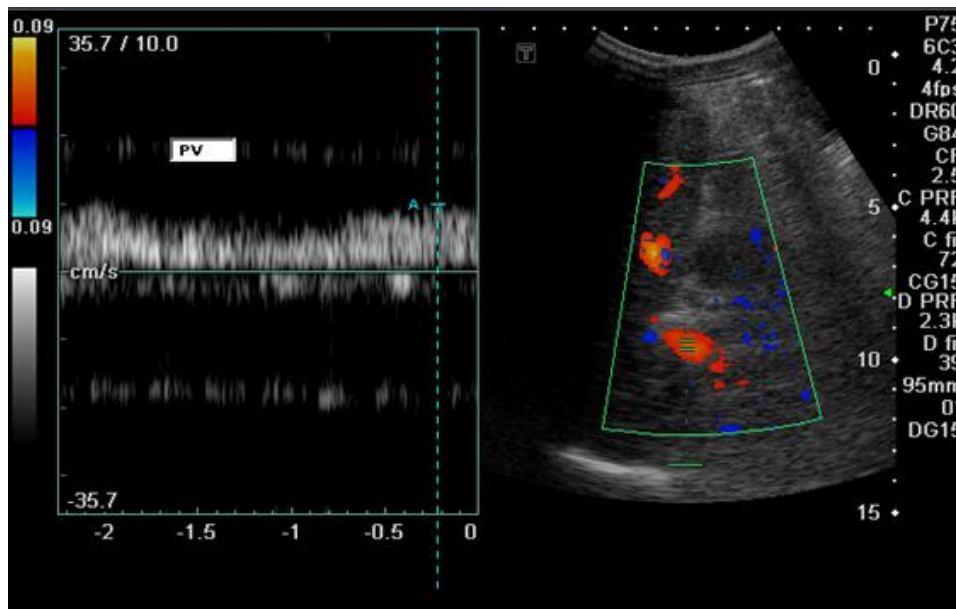
A.C., Uloma Nwogu, 2009, Nigeria.

(<http://www.ultrasoundpaedia.com/normal-liver2/#protocol>).

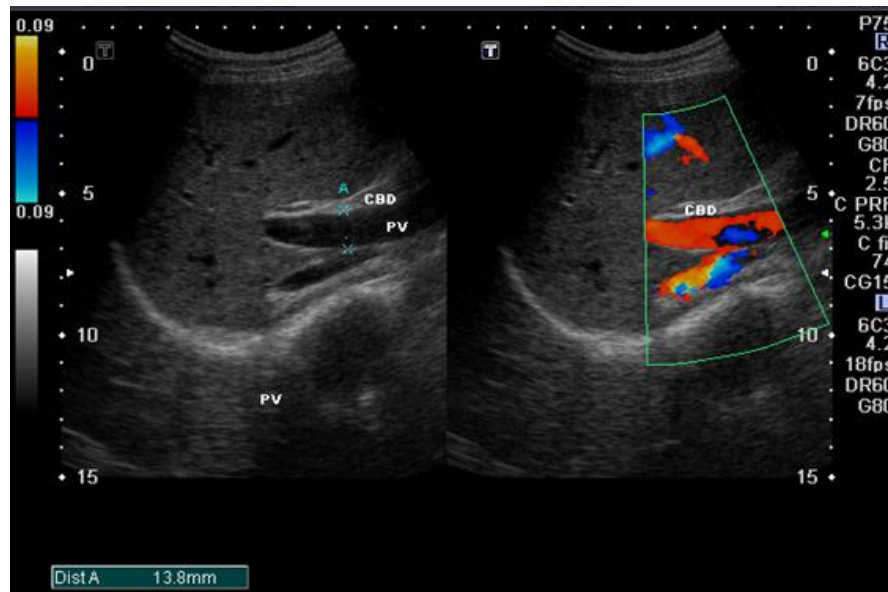
Appendix 2



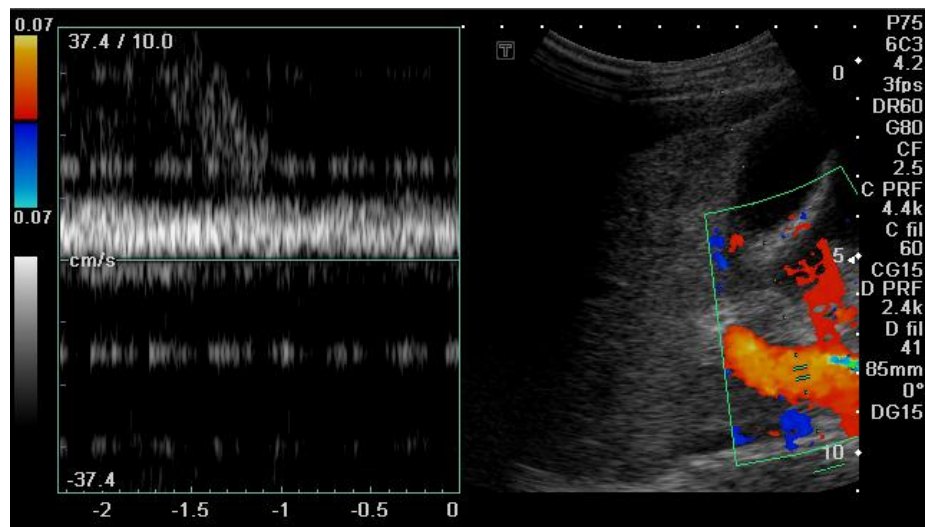
(Image I): Normal Duplex Ultrasound image of portal vein (velocity is about 18.0 cm/s).



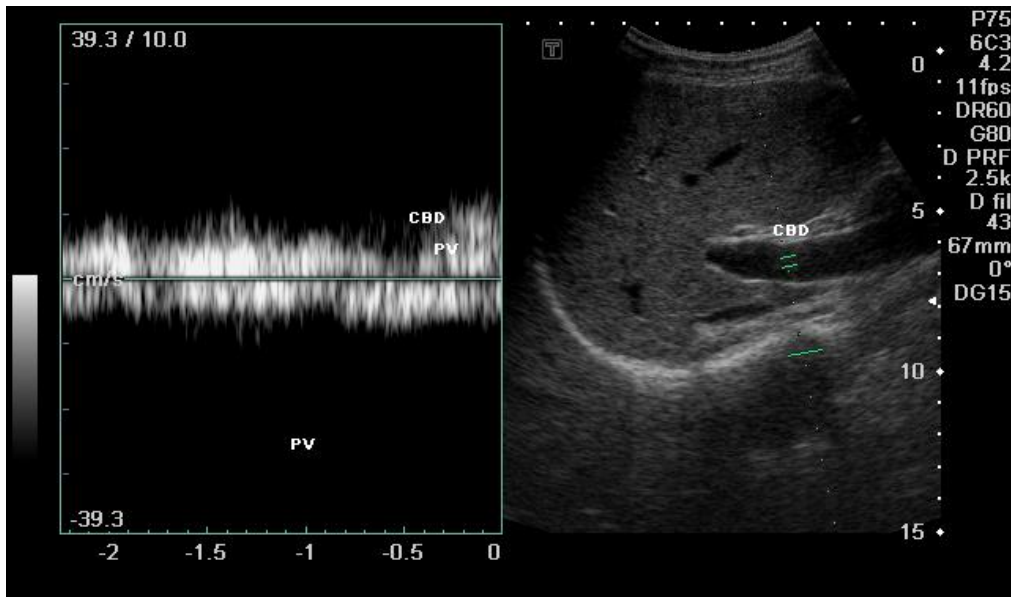
(Image II): Color Doppler study & spectral trace of the MPV in normal liver (velocity about =9.0cm/s)



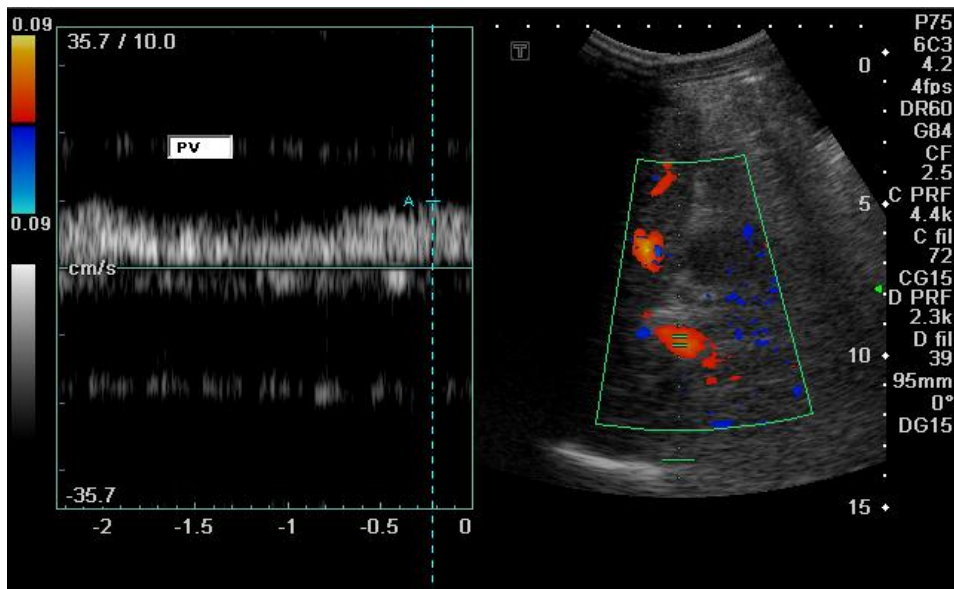
(Image III): Gray scale (PV diameter=13.8 mm) & color Doppler study of the normal MPV in young Sudanese shows no filling defect.



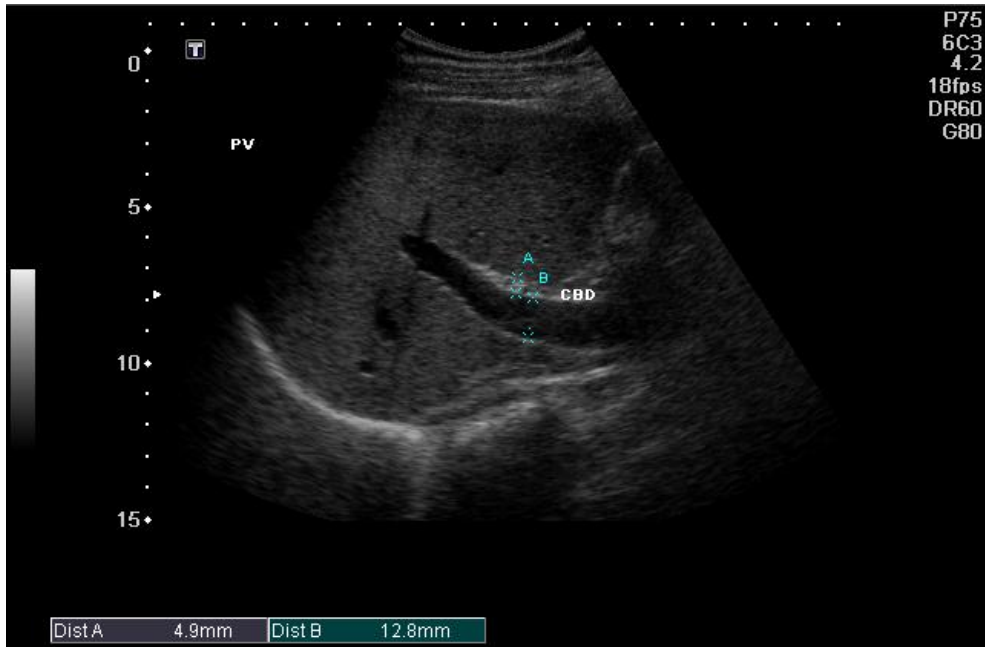(Image IV): Triplex study in normal Sudanese young man show a monophasic normal flow of the MPV velocity = 9.0cm/s



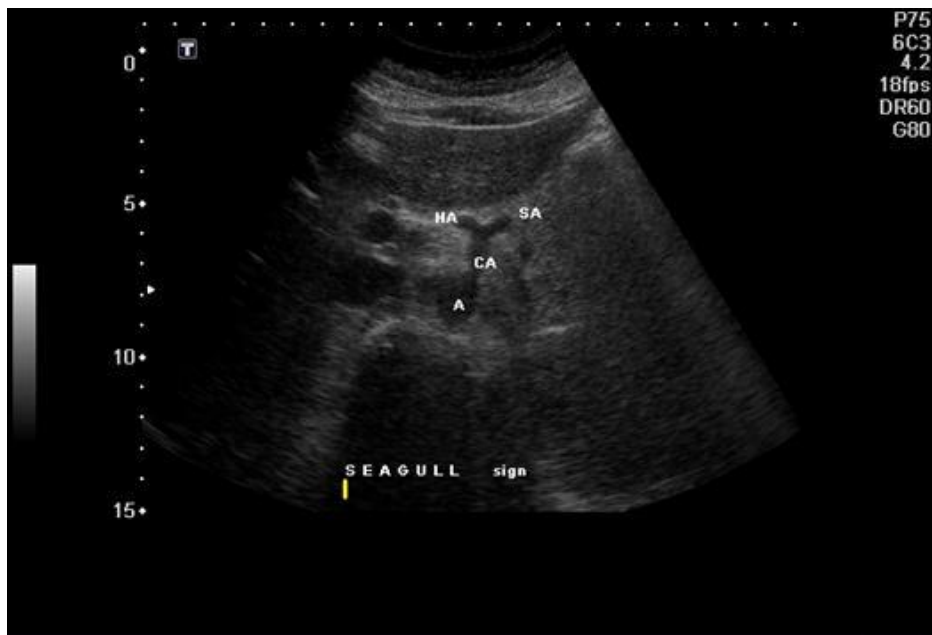
(Image V): Gray scale & spectral Doppler shows normal diameter and a bidirectional flow of the MPV after meal in normal young Sudanese Chap.



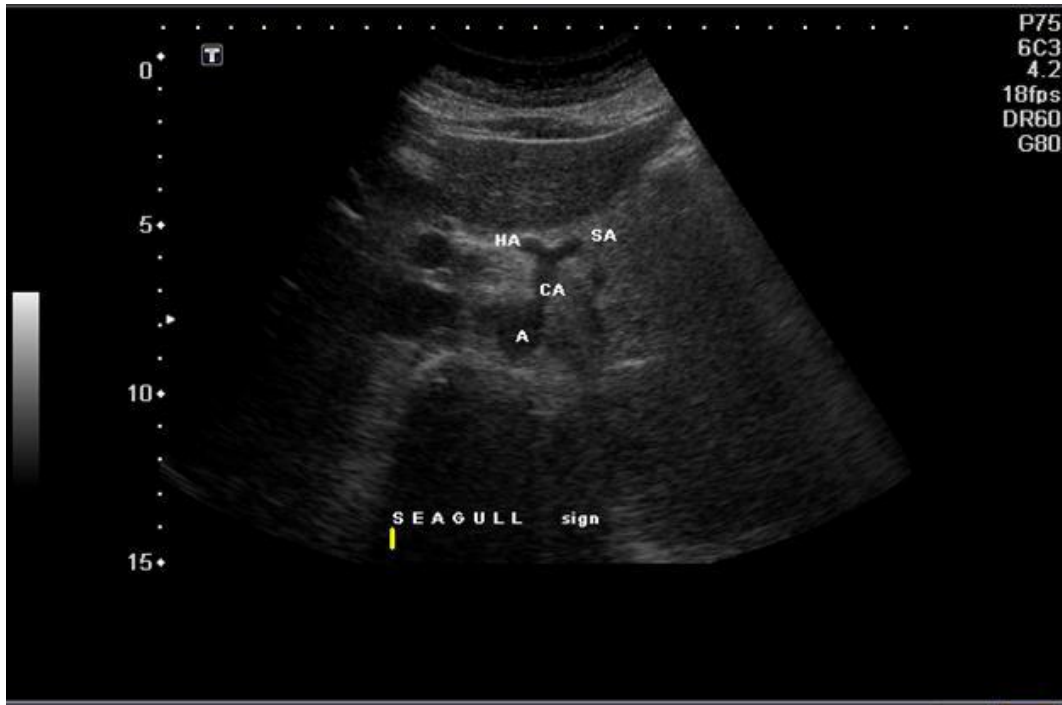
(Image VI): Normal PV in young female.



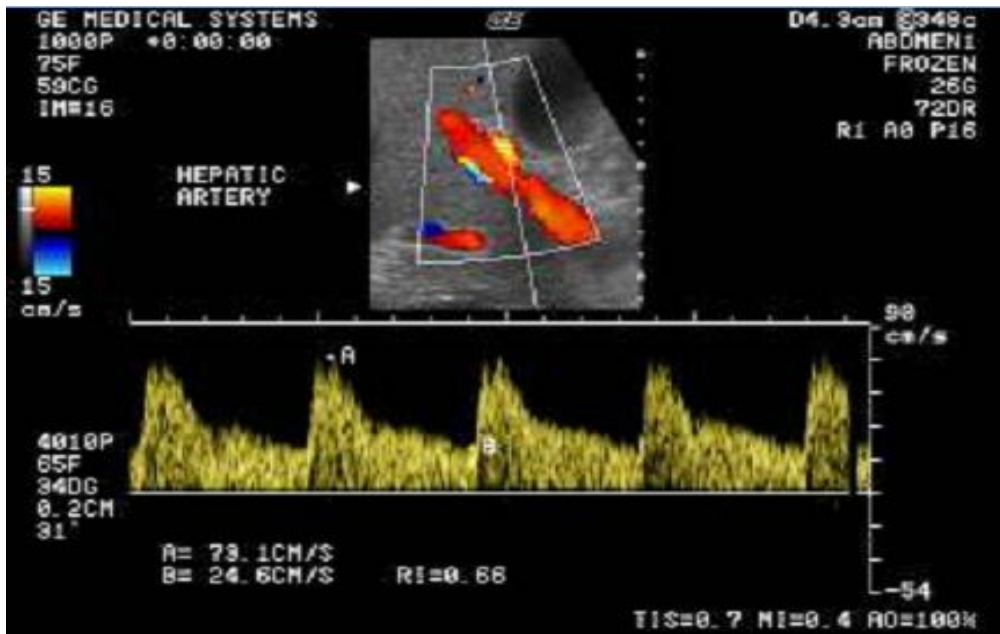
(Image VII): Gray scale US shows the PV diameter in a female (12.8 mm).



(Image VIII): Normal mid-transverse gray scale study in the pancreatic area shows the Seagull sign; the hepatic artery (HA) & the splenic artery (SA).



(Image IX): Normal young patient celiac artery, branching into the hepatic and the splenic arteries (seagull sign).the best position for HA tracing.



(Image X): Normal HA spectral race.

