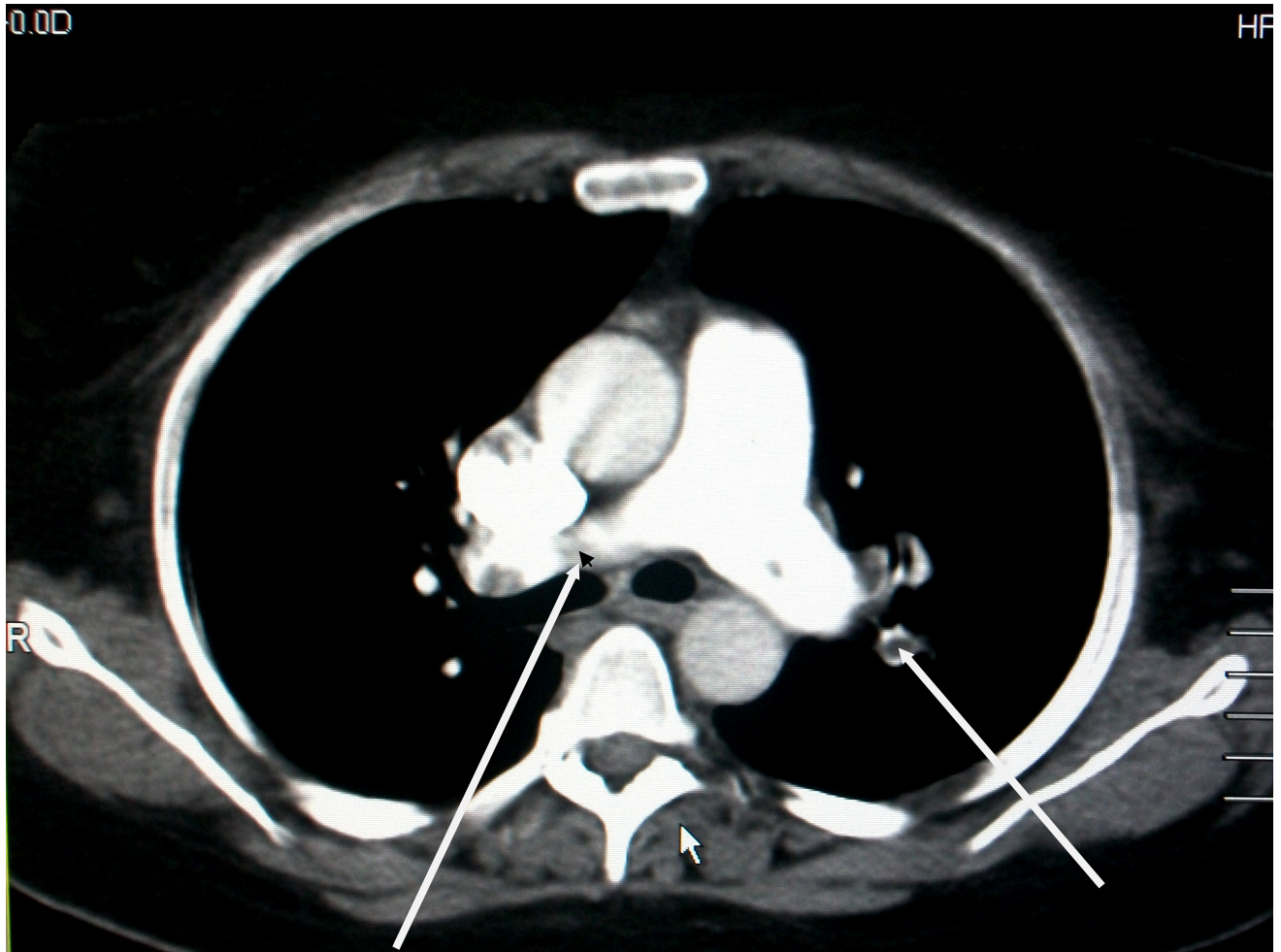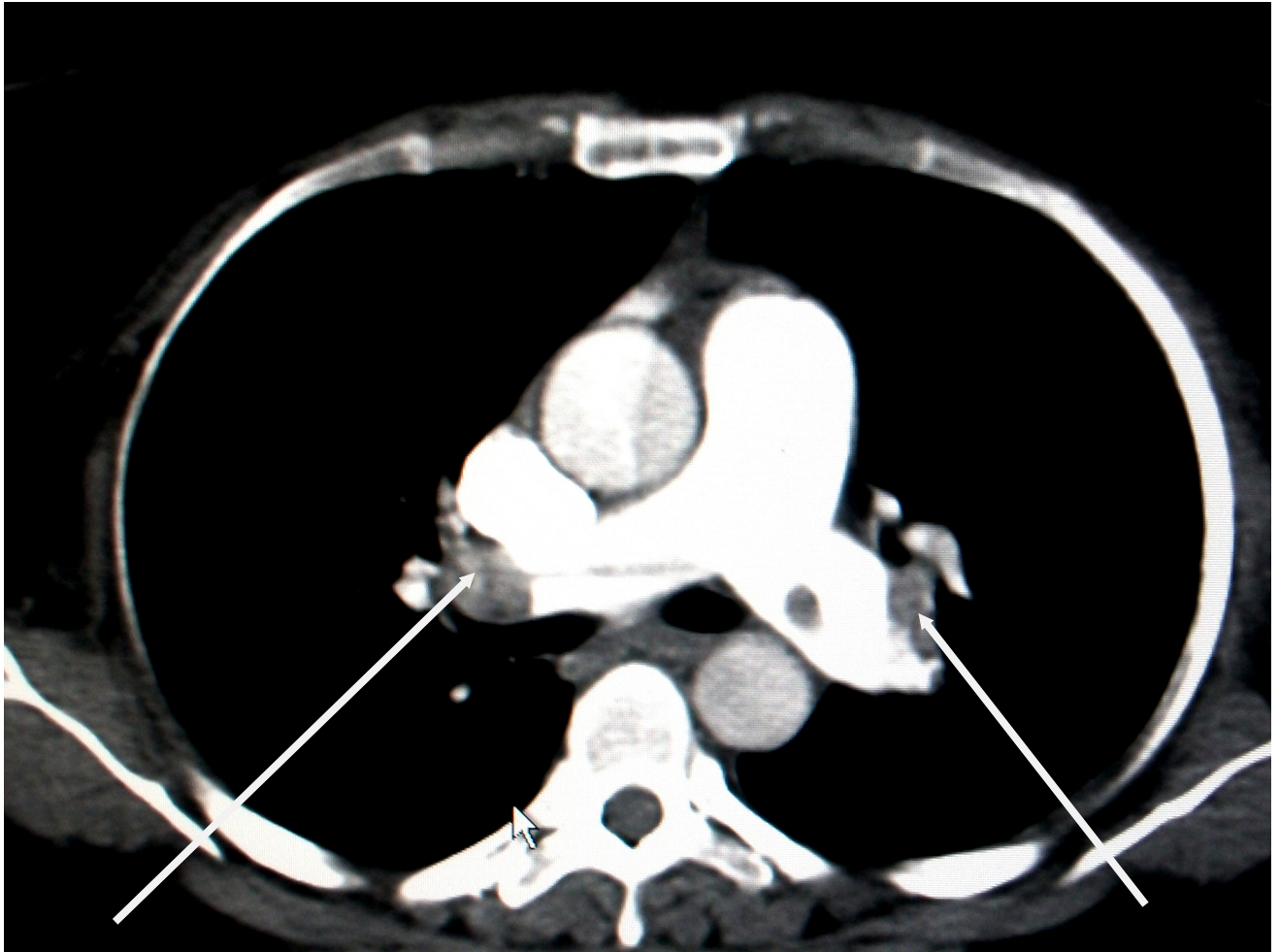


*Appendix (1)*



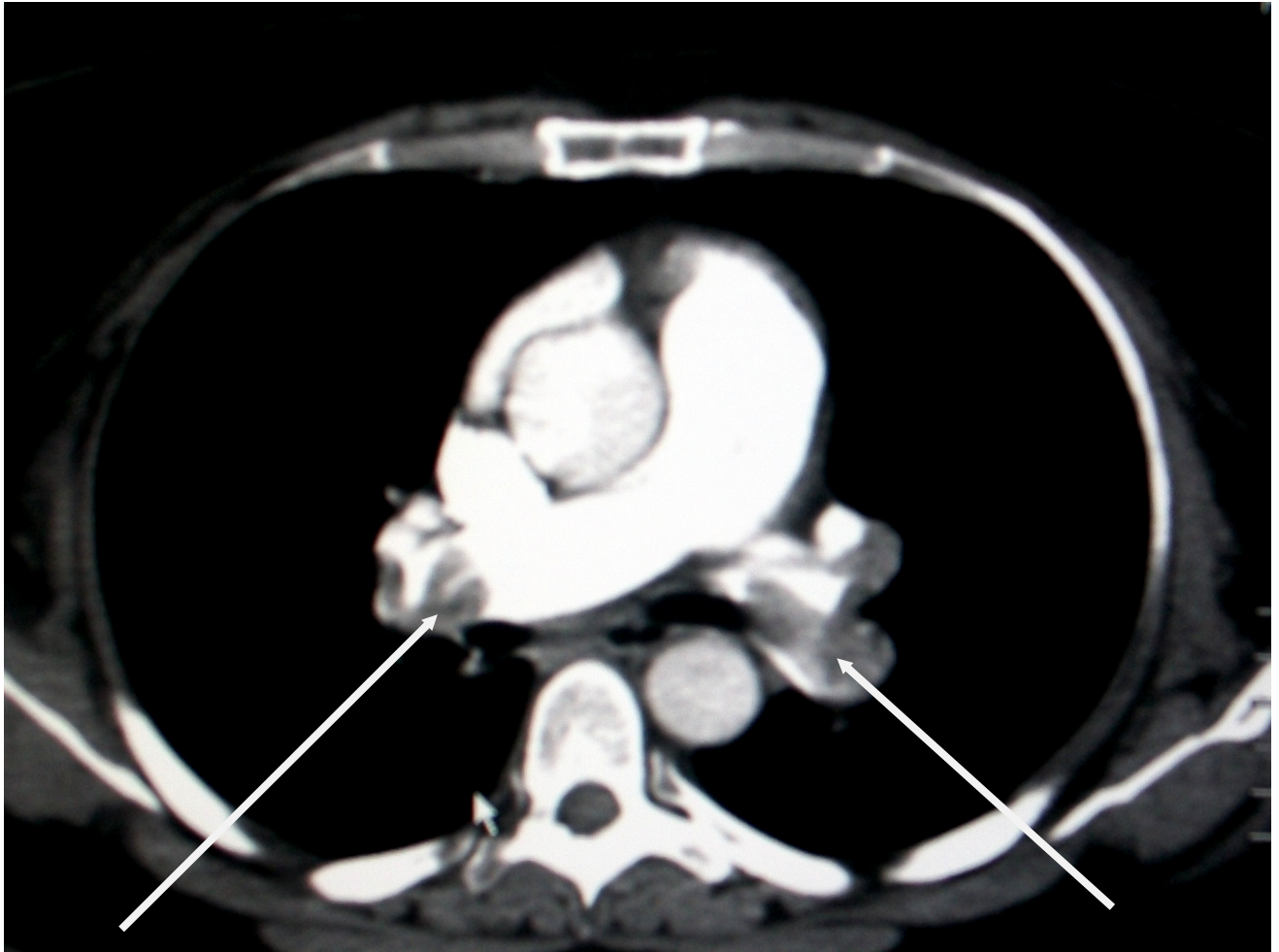
*Female 35 years old with bilateral pulmonary embolism in main (Lt) and (Rt) Pulmonary arteries*

Appendix (2)



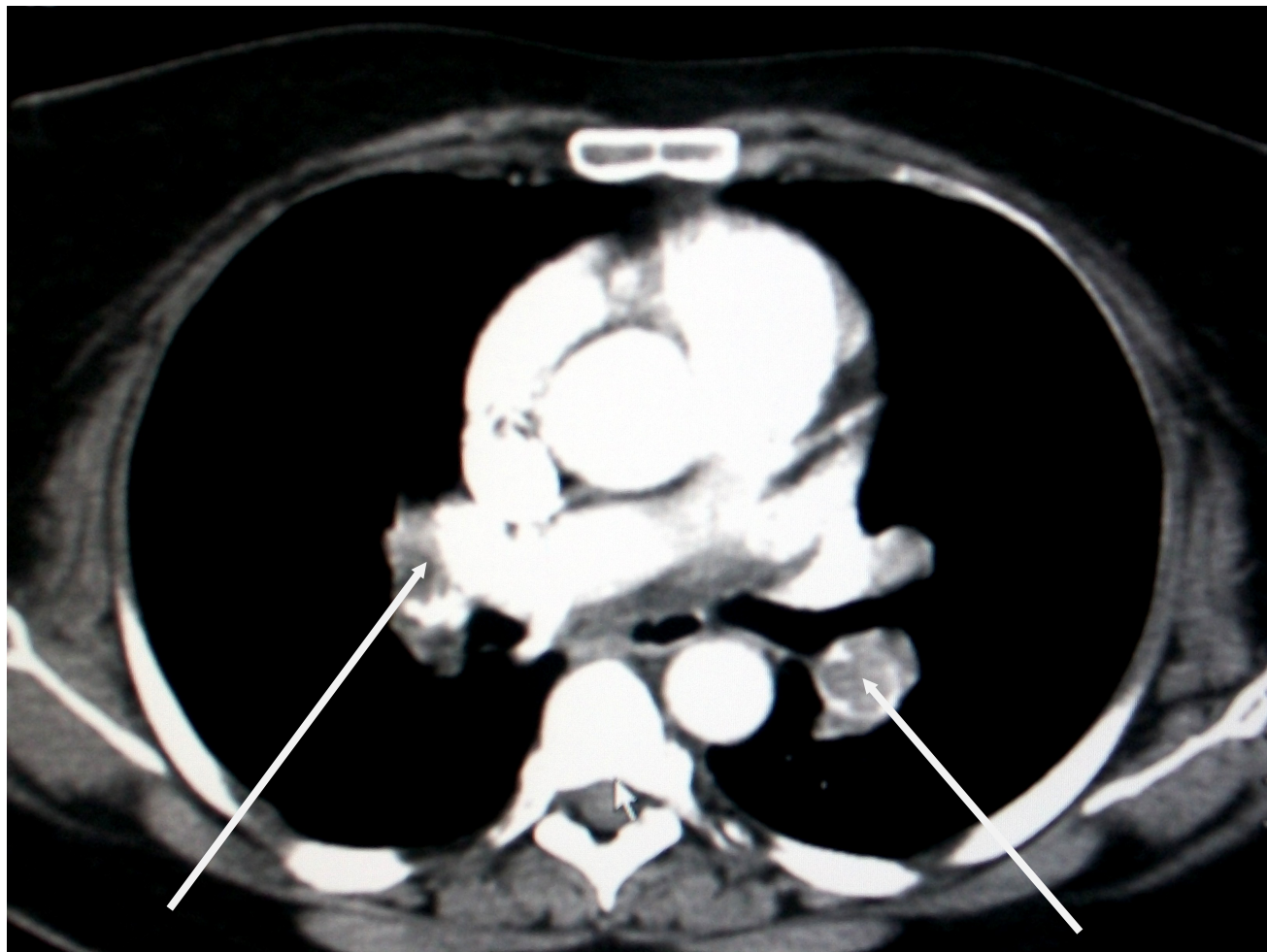*Male 61 year old with Bilateral pulmonary embolism in main (Lt) and (Rt) pulmonary arteries*

Appendix (3)



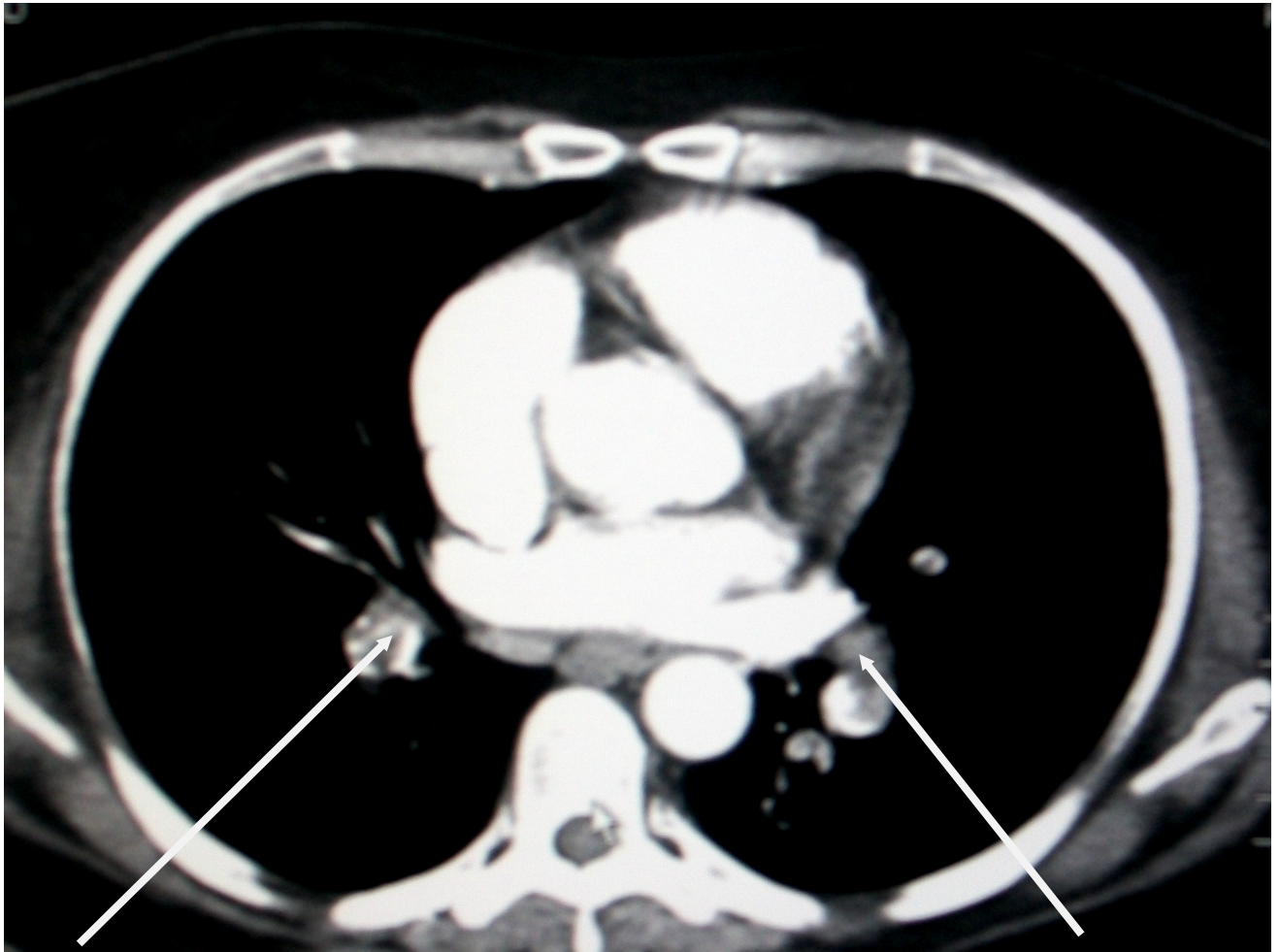
*Female 28 years old with Bilateral pulmonary embolism  
in  
(RT) and (LT) main Pulmonary arteries*

Appendix (4)



*Female 60 years old with bilateral pulmonary embolism in (Lt) and (Rt) main Pulmonary arteries*

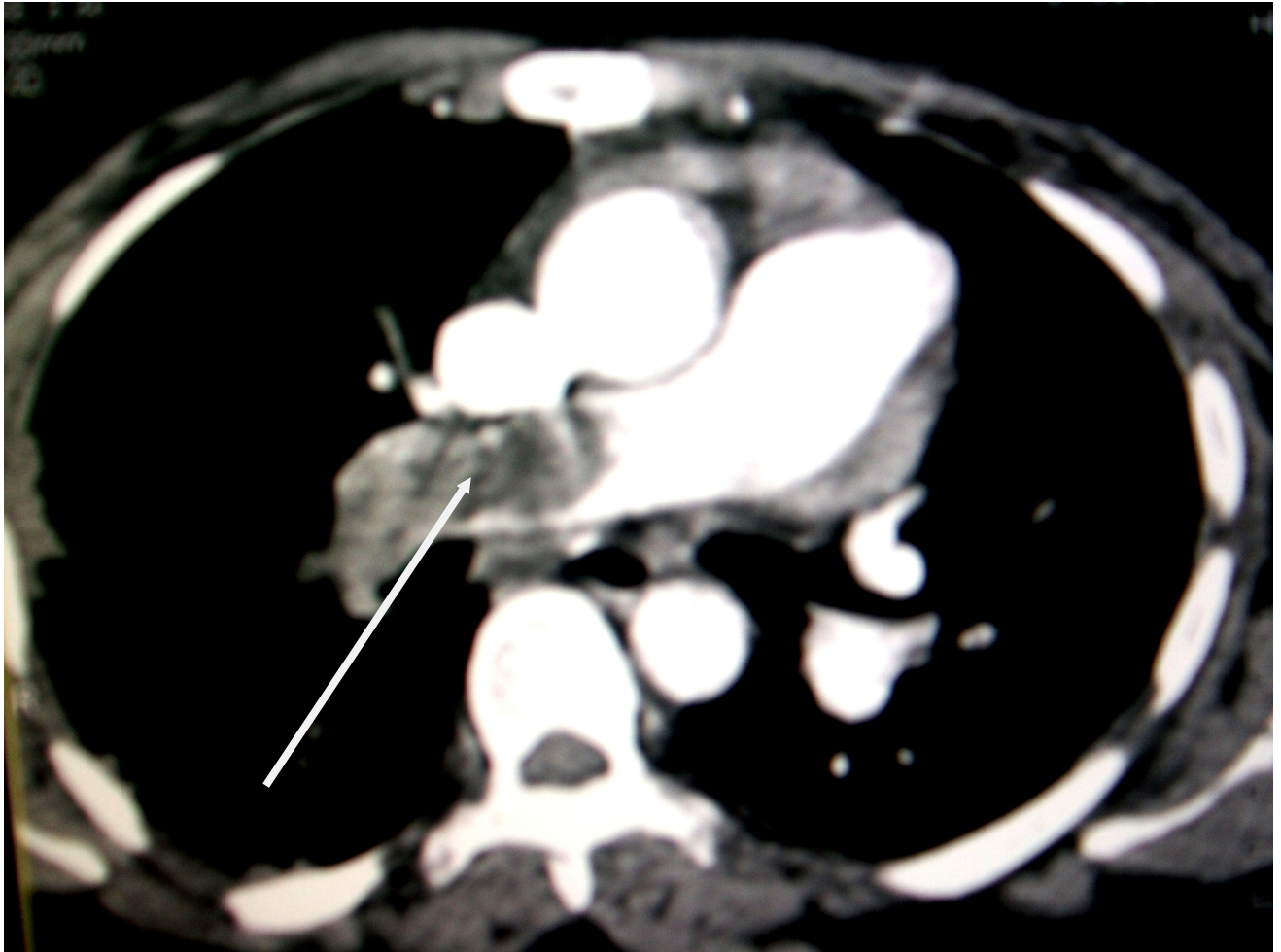
Appendix (5)



*Male 20 years old with bilateral segmental pulmonary embolism in*

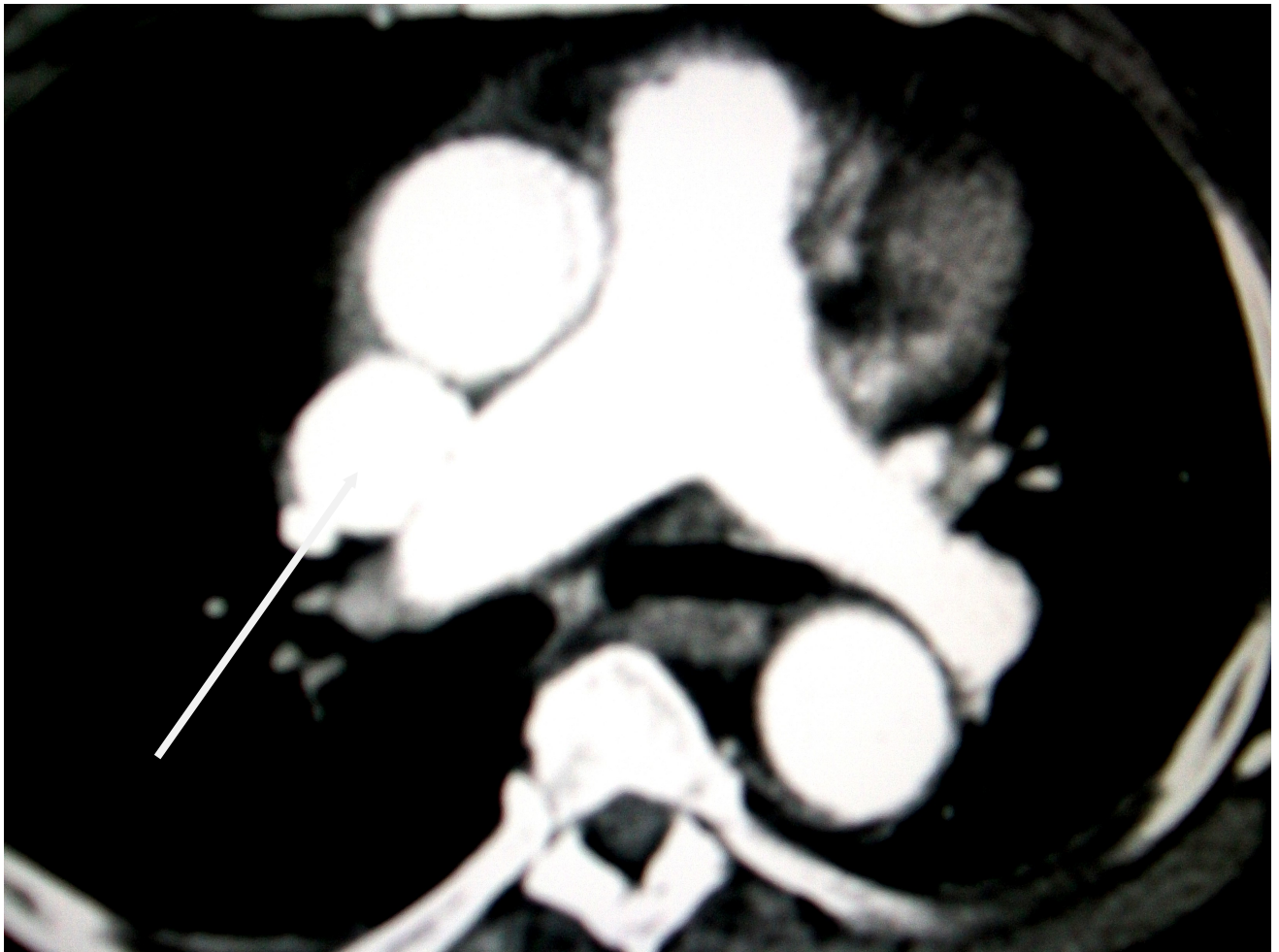*(Lt) and (Rt) Pulmonary arteries*

Appendix (6)



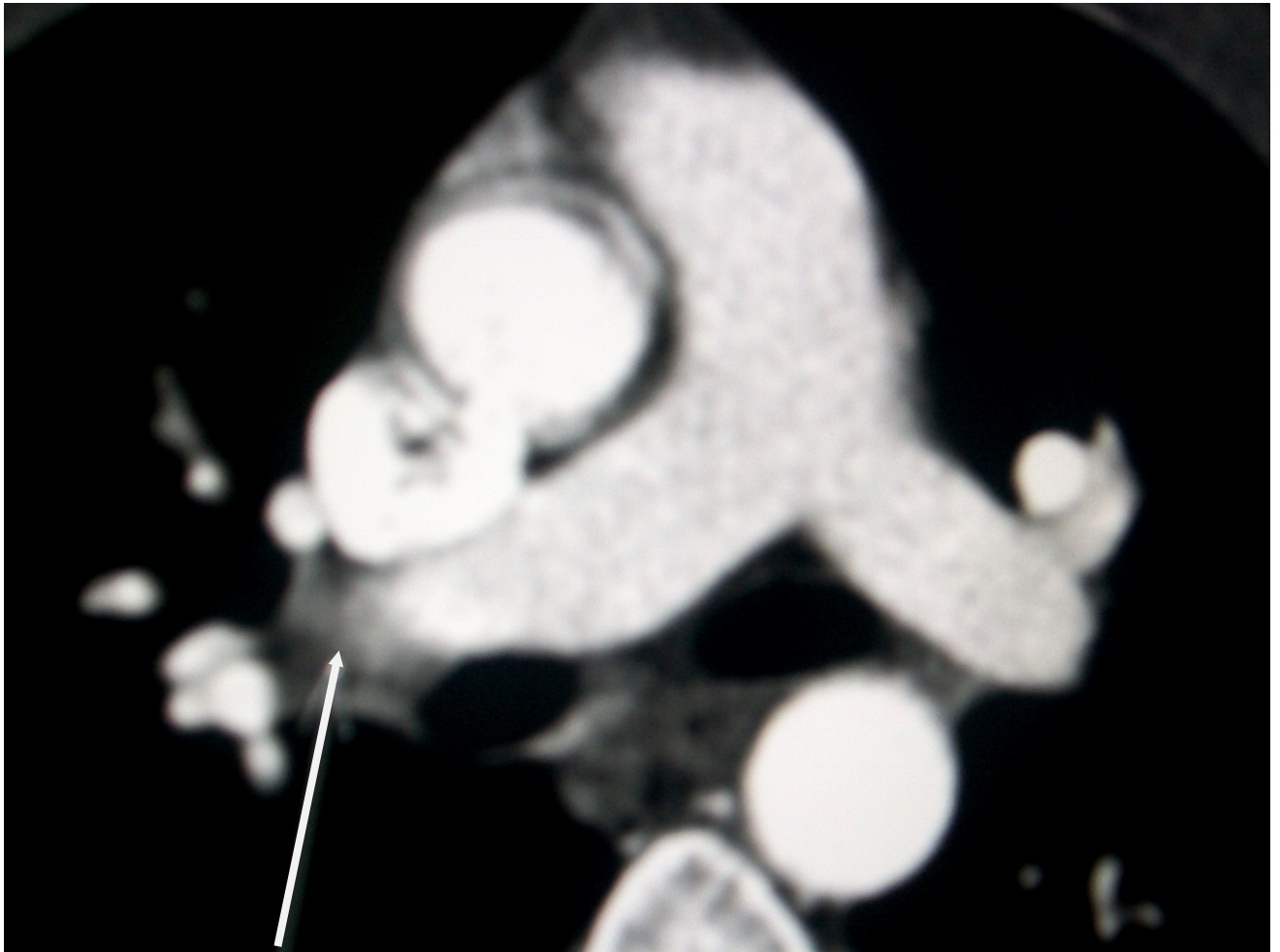
*Female 70 years old with pulmonary embolism in  
(Rt) main Pulmonary artery*

Appendix (7)



*Female 37 years with pulmonary embolism in  
(Rt) main pulmonary artery*

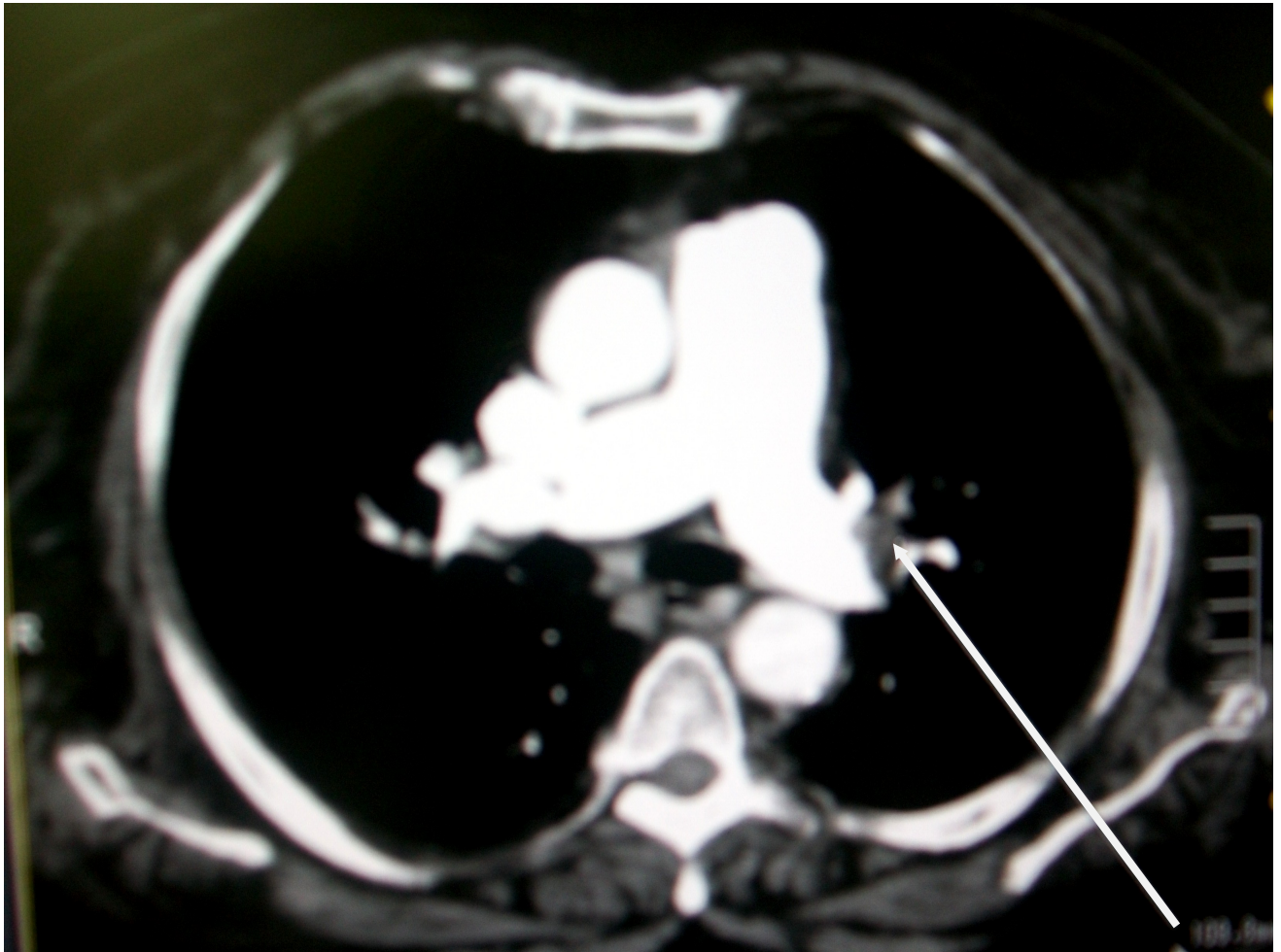
Appendix (8)



*Female 45 years old with pulmonary embolism in  
(Rt) main Pulmonary artery*

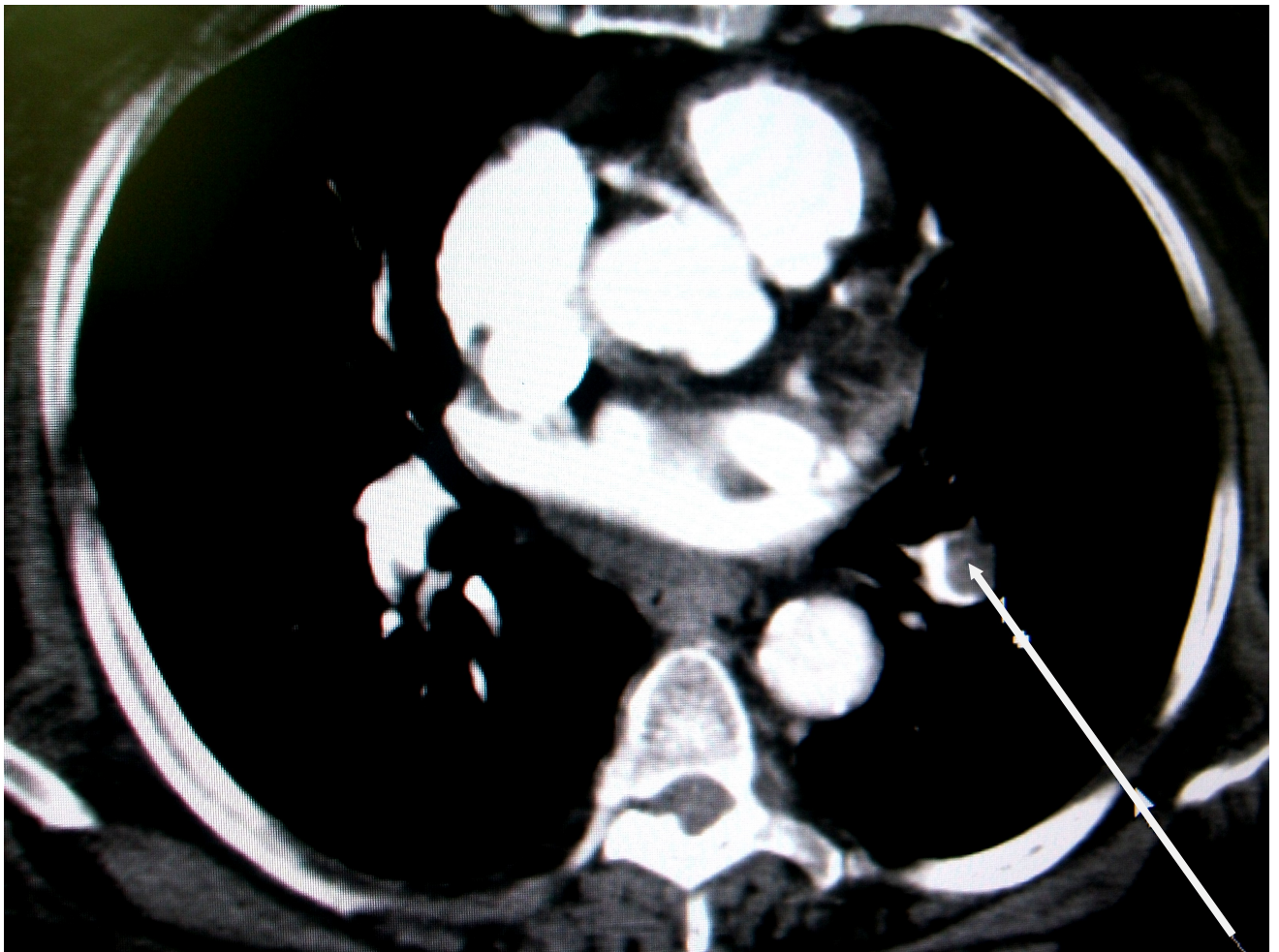


Appendix (9)



*Male 58 years old with pulmonary embolism in (Lt) main pulmonary artery*

Appendix (10)



*Female 56 years old with bilateral pulmonary embolism*  
*in*

*embolism*

*(Lt )and (Rt) segmental pulmonary*