

Chapter one

1.1 Introduction:

Vertebra bone of the neck and back provides structural support for the spine, protect and encases the spinal cord. Radiologist and orthopedic surgeons use a number of different terms when they refer to disc problems , herniated disc ruptured disc , protruded disc , prolapsed disc and slipped disc generally all mean the same things. The disc line between the end surfaces of the bony blocks (vertebrae) that make up the spine. They have a soft center with is surrounded by tough outer ring, the disc allow move most of the spine and also act as shock absorber. The nerve which run from the brain to the arm and leg lies within spinal canal. As the nerves leave the spine to go to the muscle and skin, they pass very close to back of the disc. When disc is damage the soft center may slip out (prolapsed) and pass on nerve. The usual place for such prolapsed to occur in the lower back (lumber) region or occur in the neck (cervical) region (Drake et.al,2009).

Inter vertebral disc space and disc prolapsed and most common pathology associated in the vertebral column .the lumber spine is the first common site. Spinal imaging firstly applied by plain x -ray and myelography replaced by computed tomography and recently MRI , these procedures regarding economic status of the patient and radiation protection .(Keyomars,et.al,2015).

MRI has opened new horizons in the diagnosis and treatment of many musculoskeletal diseases. It demonstrates abnormalities in the bones and soft tissue before they become evident at other imaging modalities. The exquisite soft tissue contrast resolution , noninvasive nature and multiplanar capabilities of MR imaging make it especially valuable for the detection and assessment of variety of soft tissue disorder of the ligament (e.g. sprain) tendons (tendonitis , rupture , dislocation)another soft tissue strictures (e.g. tarsal tunnel syndrome , synovial disorders) MR imaging has also been shown to be highly sensitive in the detection and staging of number for musculoskeletal infections including cellulites and osteomyelitis in addition, MR imaging is excellent for the early detection and assessment of number of osseous abnormalities such as bone contusion , stress and insufficiency fractures, osteochondral fractures, osteonecrosis and transient bone marrow edema.

The first choice in diagnosing the cervical spine disc prolapsed in the emergency x-ray department is conventional x-ray radiograph. Conventional x-ray is use full for evaluating the spinal trauma. Such as fractures,

subluxation and arthropathies such as rheumatoid arthritis , x-ray generate imaging by striking a detector that either exposes a film or in sends the image to a computer . a dense tissue the body such as bones absorbs many of x-rays and looks white on an x-ray image. Less dense tissue such as muscles and organs absorb fewer of the x-ray and look like shades of grey on an x-ray image. X -ray that passes only through air looks black on image. Claustrophobia is common problem in MRI examination room the sight of the magnet bore and unfamiliar surroundings increase their anxiety. The enclosing nature of the bore and equipment such as head coil in verify exaggerates any claustrophobic or nervous tendons (Drake et.al, 2009).

1.2 Objective:

1.2.1 General objective:

To evaluate of disc Prolapse in Lumber Spine Using MRI Images.

1.2.2 Specific Objectives:

- To detect of disc diseases by using MRI.
- To discover MRI sequence to diagnosis spine diseases.
- To correlate between the vertebral disc with patient age.
- To correlate which gender affected.(male or female).

1.3 Problem of the study:

Increased number of patients that suffering from disc prolapse in lumber spine coming to MRI department for diagnosis

1.4 Thesis lay out:

This study consisted of five chapters, chapter one is introduction and problem of the study and objective and significance of the study and thesis lay out.

Chapter two includes literature review and previous studies. Chapter three includes materials and methods. Chapter four includes data collection, results and analysis. Chapter five includes conclusion and recommendations.

Chapter two

Literature review

2.1 Anatomy

2.1.1 The Spine:

The spine is made of 33 individual bones stacked one on top of the other. Ligaments and muscles connect the bones together and keep them aligned. The spinal column provides the main support for your body, allowing you to stand upright, bend, and twist. Protected deep inside the bones, the spinal cord connects your body to the brain, allowing movement of your arms and legs. Strong muscles and bones, flexible tendons and ligaments, and sensitive nerves contribute to a healthy spine. Keeping your spine healthy is vital if you want to live an active life without back pain (Drake 2009)

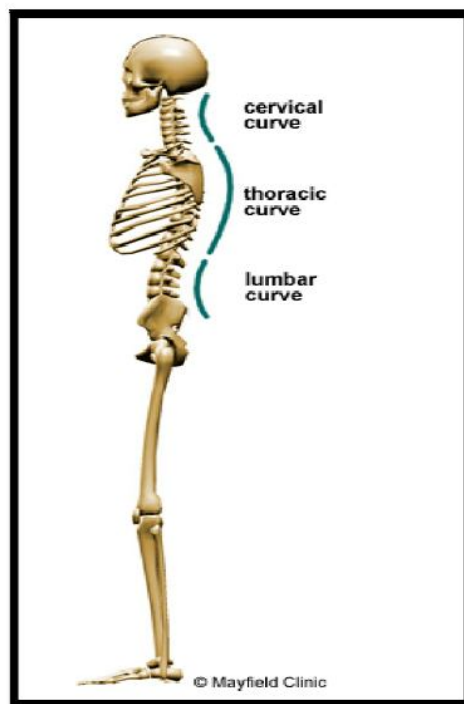


Figure 2.1: The spine has three natural curves that form an S-shape(Drake 2009)

2.1.2 The spinal curves:

When viewed from the side, an adult spine has a natural S-shaped curve. The neck (cervical) and low back (lumbar) regions have a slight concave curve, and the thoracic and sacral regions have a gentle convex curve. The curves work like a coiled spring to absorb shock, maintain balance, and allow range of motion throughout the spinal column. (Drake 2009)

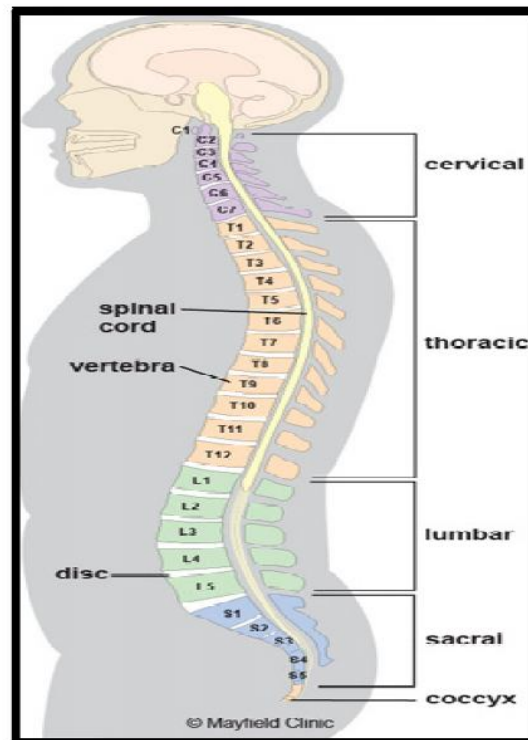


Figure 2.2: The five regions of the spinal column. (Drake 2009)

2.1.3 The vertebrae:

Vertebrae are the 33 individual bones that interlock with each other to form the spinal column. The vertebrae are numbered and divided into regions: cervical, thoracic, lumbar, sacrum, and coccyx. Only the top 24 bones are moveable; the vertebrae of the sacrum and coccyx are fused. The vertebrae in each region have unique features that help them perform their main functions. (Drake 2009)

Cervical (neck) - the main function of the cervical spine is to support the weight of the head (about 10 pounds). The seven cervical vertebrae are numbered C1 to C7. The neck has the greatest range of motion because of two specialized vertebrae that connect to the skull. The first vertebra (C1) is the ring-shaped atlas that connects directly to the skull. The second vertebra (C2) is the peg-shaped axis, which has a projection called the odontoid, that the atlas pivots around. (Drake 2009)

Thoracic (mid back) - the main function of the thoracic spine is to hold the rib cage and protect the heart and lungs. The twelve thoracic vertebrae are numbered T1 to T12. The range of motion in the thoracic spine is limited. (Drake 2009)

Lumbar (low back) - the main function of the lumbar spine is to bear the weight of the body. The five lumbar vertebrae are numbered L1 to L5. These vertebrae are much larger in size to absorb the stress of lifting and carrying heavy objects.(Drake 2009)

Sacrum- the main function of the sacrum is to connect the spine to the hip bones (iliac). There are five sacral vertebrae, which are fused together. Together with the iliac bones, they form a ring called the pelvic girdle. (Drake 2009)

Coccyx region - the four fused bones of the coccyx or tailbone provide attachment for ligaments and muscles of the pelvic floor. (Drake 2009)

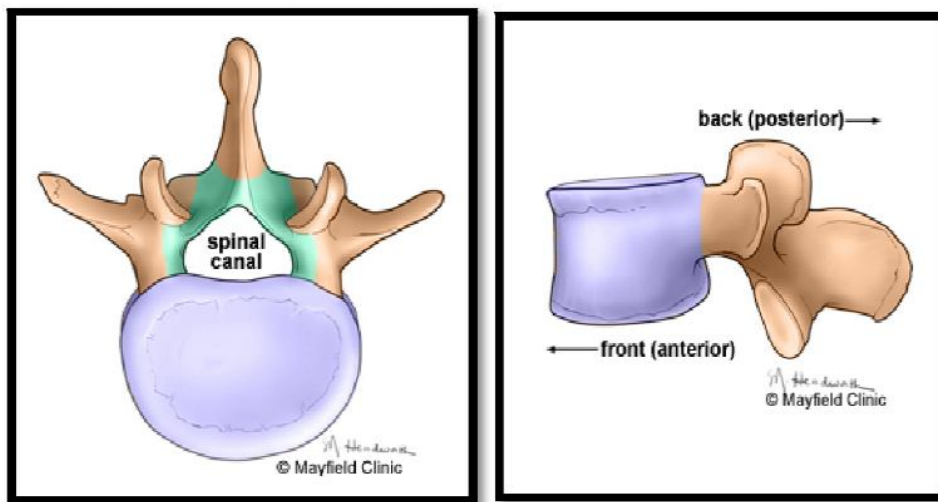


Figure 2.3: While vertebrae have unique regional features, every vertebra has three main parts: body (purple), vertebral arch (green), and processes for muscle attachment (tan). (Pansky, 1996)

2.1.4 The intervertebral discs:

Each vertebra in your spine is separated and cushioned by an intervertebral disc, keeping the bones from rubbing together. Discs are designed like a radial car tire. The outer ring, called the annulus, has criss-crossing fibrous bands, much like a tire tread. These bands attach between the bodies of each vertebra. Inside the disc is a gel-filled center called the nucleus, much like a tire tube. (Rosse 1997)

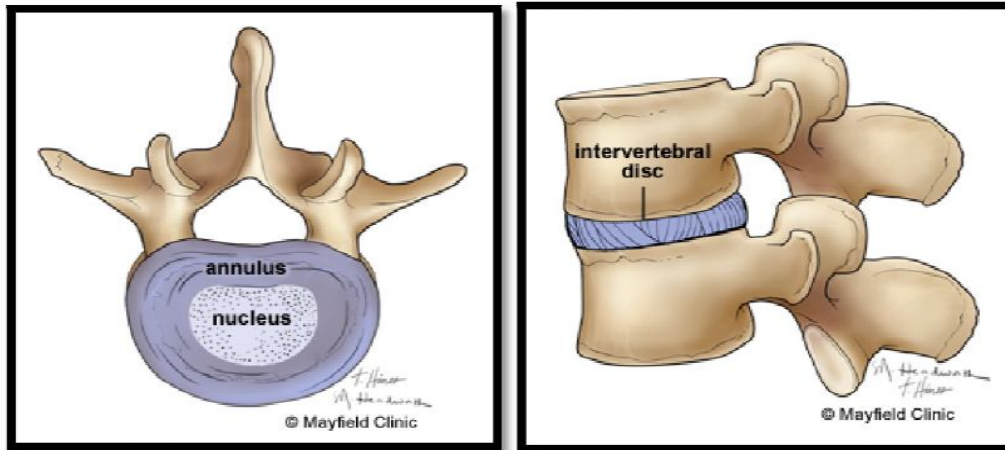


Figure 2.4: Intervertebral discs (Pansky, 1996)

2.1.5 Vertebral arch & spinal canal:

The arch is made of two supporting pedicles and two laminae. The hollow spinal canal contains the spinal cord, fat, ligaments, and blood vessels. Under each pedicle, a pair of spinal nerves exits the spinal cord and pass through the intervertebral foramen to branch out to your body. Seven processes arise from the vertebral arch: the spinous process, two transverse processes, two superior facets, and two inferior facets. (Rosse 1997)

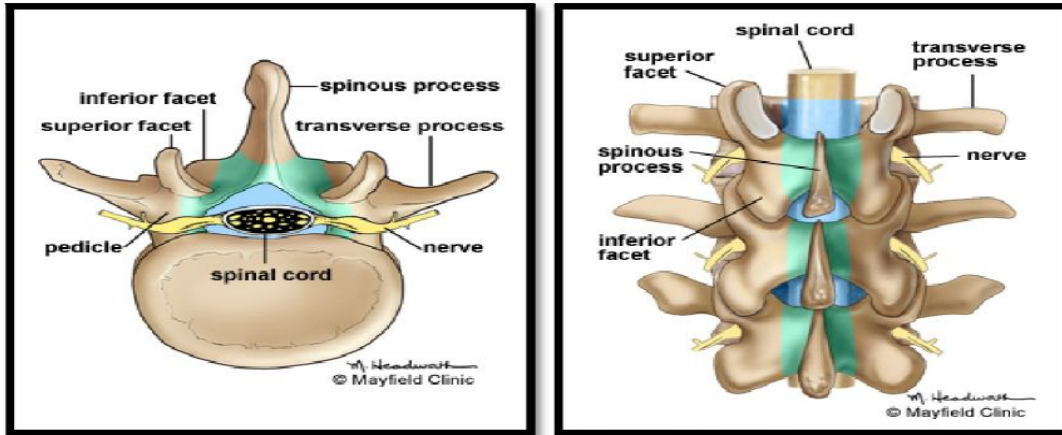


Figure 2.5: The vertebral arch (green) forms the spinal canal (blue) through which the spinal cord runs.(Pansky,1996)

2.1.6. The ligaments:

There are different ligaments involved in the holding together of the vertebrae in the column, and in the column's movement. The anterior and posterior longitudinal ligaments extend the length of the vertebral column along the front and back of the vertebral bodies. The interspinousligaments connect the adjoining spinous processes of the vertebrae. The supraspinous ligament extends the length of the spine running along the back of the spinous processes, from the sacrum to the seventh cervical vertebra. From there it is continuous with the nuchal ligament (Williams 2007)

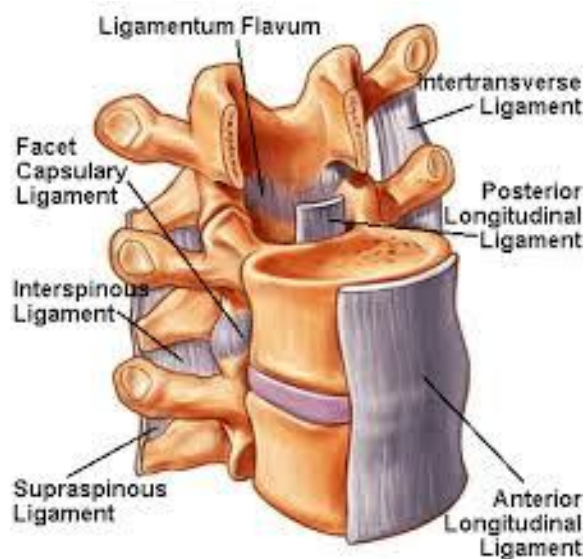


Figure 2.6: The ligamentumflavum, anterior longitudinal ligament (ALL), and posterior longitudinal ligament (PLL). (Pansky,1996)

2.1.7 The muscle:

The two main muscle groups that affect the spine are extensors and flexors. The extensor muscles enable us to stand up and lift objects. The extensors are attached to the back of the spine. The flexor muscles are in the front and include the abdominal muscles. These muscles enable us to flex, or bend forward, and are important in lifting and controlling the arch in the lower back. (Williams 2007)

2.1.8 Spinal cord:

The vertebral column surrounds the spinal cord which travels within the spinal canal, formed from a central hole within each vertebra. The spinal cord is part of the central nervous system that supplies nerves and receives information from the peripheral nervous system within the body. The spinal cord consists of grey and white matter and a central cavity, the central canal. Adjacent to each vertebra emerge spinal nerves. The spinal nerves provide sympathetic nervous supply to the body, with nerves emerging forming the sympathetic trunk and the splanchnic nerves. (Williams 2007)

The spinal canal follows the different curves of the column; it is large and triangular in those parts of the column which enjoy the greatest freedom of movement, such as the cervical and lumbar regions; and is small and rounded in the thoracic region, where motion is more limited. The spinal cord terminates in the conus medullaris and cauda equina. (Williams 2007)

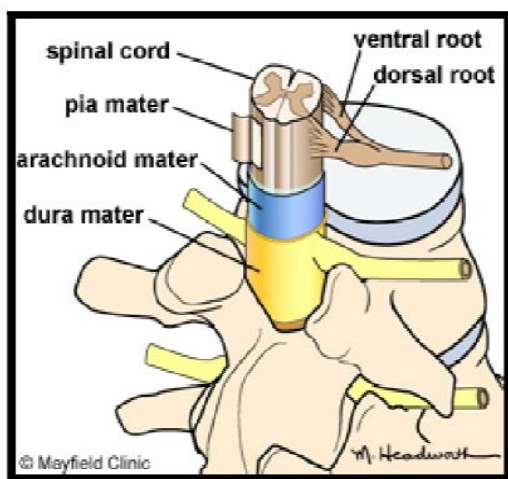


Figure 2.7: The spinal cord is covered by three layers of meninges: pia, arachnoid and dura mater. (Pansky, 1996).

2.2 Pathology

2.2.1 Annular Disc Tear:

An intervertebral disc is a strong ligament that connects one vertebral bone to the next. The discs are the shock-absorbing cushions between each vertebra of the spine. Each disc has a strong outer ring of fibers, called the annulus fibrosus, and a soft, jelly-like center, called the nucleus pulposus. The annulus is the strongest area of the disc and connects each vertebra together. (Underwood, 1996)

The annulus can tear or rupture anywhere around the disc. If it tears and no disc material is ruptured, this is called an annular tear. The outer 1/3 of the disc's annular ring is highly innervated with pain fibers. Thus, if a tear involves the outer 1/3 it may be extremely painful. This tear will heal with scar tissue over time but is more prone to future tears and injury. Studies also indicate that annular tears may lead to premature degeneration of the disc, endplates, and facet joints.(Underwood, 1996)

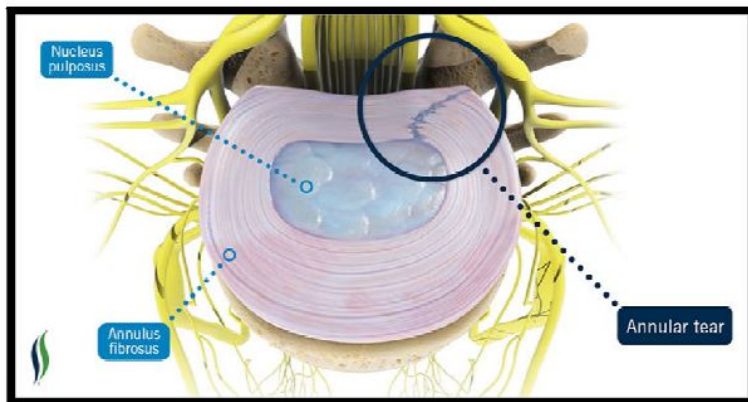


Figure2.8: Annular disc tear. (Underwood, 1996)

2.2.1.1 Types of annular tear:

The annulus fibrosus is constructed of several layers, each of which can become torn. The nature of the tear and the layers it affects will be the basis for how the Tear is categorized:

1- Radial tears — Typically caused by the natural aging process, radial tears begin at the center of the disc and extend all the way through the outer layer of the annulus fibrosus.

These tears can cause a disc to herniate, which occurs when the center nucleus of a disc extrudes through the tear to the outside of the disc. (Underwood, 1996)

2- Peripheral tears — (also known as rim lesion or transverse tear) These tears occur in the outer fibers of the annulus fibrosus and are usually brought on by traumatic injury or contact with a bone spur. Peripheral tears can lead to the degeneration or breakdown of an intervertebral disc. (Underwood, 1996)

3- Concentric tears — (also known as circumferential tears, or delaminations), the broken fibers are parallel with the borders of the intervertebral disc at some distance in between the center and edge. Tears here create spaces between adjacent concentric fibers which can fill with fluid, such as the nucleus pulposus. These tears often occur with compressive stress on older discs, which is usually caused by injury. (Underwood, 1996)

4- Horizontal tear —also known as a transverse tear), which are usually small and may represent early stages of age-related disc deformity. These are often found in conjunction with radial tears. (Underwood, 1996)

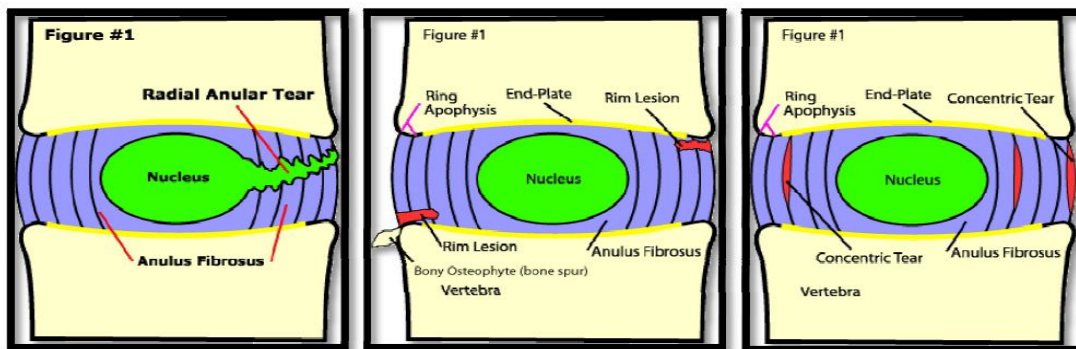


Figure 2.9: Types of annular tear(Underwood, 1996)

2.2.2 Osteophytes:

Lumbar osteophytes, also known as bone spurs, are smooth growths that form on the facet joints and/or around the vertebrae in the lower spine. Bone spurs do not always cause pain, but in some cases may compress nerves in the lower back causing symptoms of radiating pain, weakness, tingling, or numbness in the legs and feet, along with stiffness and lack of movement in the lower back. (Edward f. Goljan.1998)

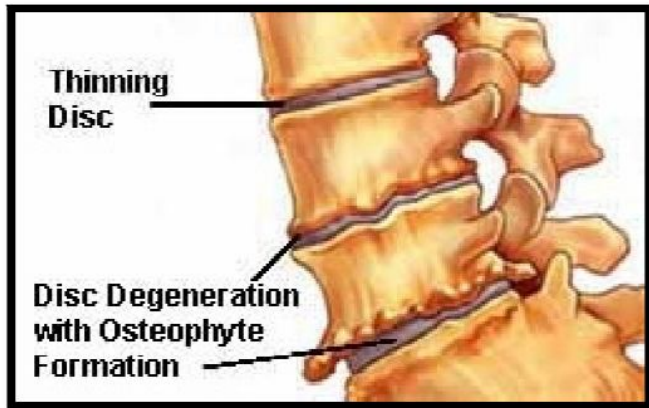


Figure 2.10: Lumbar osteophytes(Edward f. Goljan.1998)

2.2.3Ligamentumflavum thickening

Ligamentumflavum thickening was measured on the axial image, perpendicular to the spinal canal axis and parallel to the lamina, where ligamentumflavum were seen along their entire length & measurement were taken at the half length of ligamentflavum.

A mean thickness of the ligamentumflavum of 4.44 mm in the patients with the spinal canal stenosis labeled as thickened and 2.44 mm thickness in the control group. So, we had labeled a >4 mm ligamentumflavum thickening as thickened. (Edward. Goljan.1998)

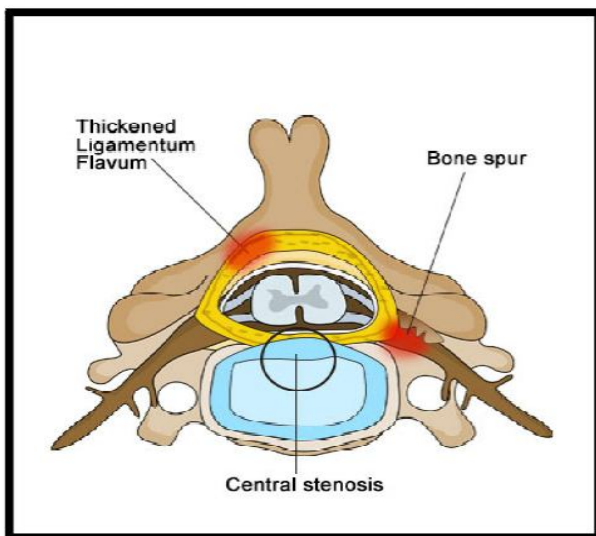


Figure 2.11:Ligamentumflavum thickening(Edward f. Goljan.1998)

2.2.4 Spondylosis:

Spondylosis is a general term for degenerative arthritic changes of the spine, or more simply arthritis. Most degenerative changes of the spine are part of the normal aging process, much like developing grey hair. Everyone is expected to have some evidence of spondylosis as they get older. Many times, patients who have spondylosis on imaging studies do not have any symptoms. In fact, more than 90% of adults over 65 show signs of arthritis. These degenerative changes most commonly occur at the vertebral body and openings for nerve roots. (Edward .Goljan, 1998)

2.2.5 Spinal Stenosis:

Spinal stenosis is the narrowing of the spinal canal. This narrowing of the spinal canal limits the amount of space for the spinal cord and nerves. Pressure on the spinal cord and nerves due to limited space can cause symptoms such as pain, numbness, and tingling. The most common reason to develop spinal stenosis is degenerative arthritis, or bony and soft tissue changes that result from ageing. Spinal stenosis is usually seen in patients over 50 years of age, and becomes progressively more severe with increased age. Spinal canal diameter less than 12 mm indicates narrowing of the canal. (Edward f. Goljan, 1998)

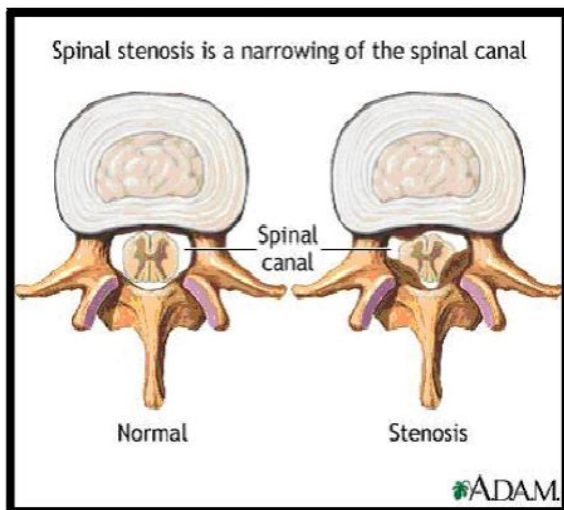


Figure 2.12: Spinal Stenosis (Edward f. Goljan.1998)

2.2.6 Herniated disc or disc prolapsed:

A herniated disc occurs when the inter vertebral disc outer fibers (the annulus are damage and the soft inner material of the nucleus pulpous protrude out of its normal space if the annulus tear near the spinal canal). This can cause mush pressure on the spinal cord and nerve root. There is also some evidence that the nucleus pulpous material cause a chemical irritation of nerve root and the chemical irritation can lead to problems thenerve function. A herniated disc is common in lumbar spine because of the all pressure it supports. Herniated lumber disc often produce sciatica, condition where the lower back pain and numbness radiation down to the back of the leg. (Underwood, 1996)

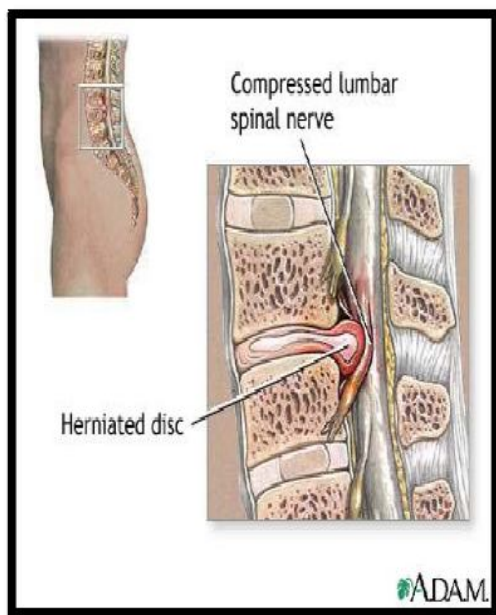


Figure 2.1: A spinal disc herniation(Underwood, 1996)

The human spine consists of alternating bonyvertebrae and intervertebral discs extending from the neck to the coccyx. The lower portion of the spine in the region of the lower is called the lumbar spine. (pansky,1996). The intervertebral discs are the ‘shock absorbers’ of the body and are composed of an outer strong fibrous membrane and an inner ‘jellylike’ nucleus giving both strength and elasticity.A disc prolapse occurs when there is a weakening in the outer membrane leading to a protrusion of the inner nucleus. This protrusion usually heads poster laterally towards the lateral parts of spinal canal which contains the nerve root. Occasionally the protrusion heads more centrally and can cause compression of the spinal cord. (Drake et.al, 2009).There is no known cause of lumber

disc prolapses. Heavy lifting and straining may exacerbate the condition. Traumatic disc prolapses may occur with localized high velocity pressure.

SIGNS AND SYMPTOM: a variety of symptoms are present with a lumbar disc prolapse may occur due to the acute disc rupture itself, and any pressure that may occur on neurological structures as a result and includes: back pain, focal neurological deficits (weakness, numbness, tingling)

2.2.7 Myelopathy:

A large or central disc prolapse may result in pressure on the spinal cord. This may result in disruption of the nerve signals to the legs and cause spastic legs, hyper-reflexes legs and difficulty walking (myelopathy). It may also result in radicular symptoms with pain shooting into the arms, torso or legs. There may also be loss of control of the bowel and bladder function. (Haughton, 2006).

2.3 Diagnosis modalities:

2.3.1 X-ray:

X-rays are effective at showing narrowed spinal channels (spinal stenosis), fractures, bone spurs (osteophytes), or osteoarthritis. On the plain films, your surgeon will be looking for vertebral alignment, scoliosis, and fracture—other spinal issues that can come along with DDD. Your surgeon may also order flexion and extension x-rays to evaluate the stability of your spine and your range of motion (how well your joints move). You'll be asked to bend forward (flexion) and backwards (extension) during these x-rays. (Schneiderman, 1987)

2.3.2. Computed tomography:

A CT scan works by shooting an X-ray beam through the body. Next, a computer is used to reformat the image into cross sections of the spine. This process is repeated at multiple different intervals, a CT scan is often used to evaluate the bony anatomy in the spine, which can show how much space is available for the nerve roots and within the neural foramina and spinal canal. CT scans should not be performed for women who may be pregnant. (Schneiderman, 1987)

2.3.3. Magnetic resonance imaging:

The most common test to diagnose a herniated disc is the MRI scan. This test is painless and very accurate. It is usually the preferred test to do (after X-rays) if a herniated disc is suspected.(Schneiderman, 1987).

2.3.4 Bone scan:

The bone scan to help your surgeon detect spinal problems such as osteoarthritis, fractures, or infections you may have a bone scan. You will have a very small amount of radioactive material injected into a blood vessel. That will travel through your bloodstream and be absorbed by your bones. More radioactive material will be absorbed by an area where there is abnormal activity, such as an inflammation. A scanner can detect the amount of radiation in all your bones and show the "hot spots " (the areas with more radioactive material) to help your surgeon figure out where the problem is.(Schneiderman, 1987)

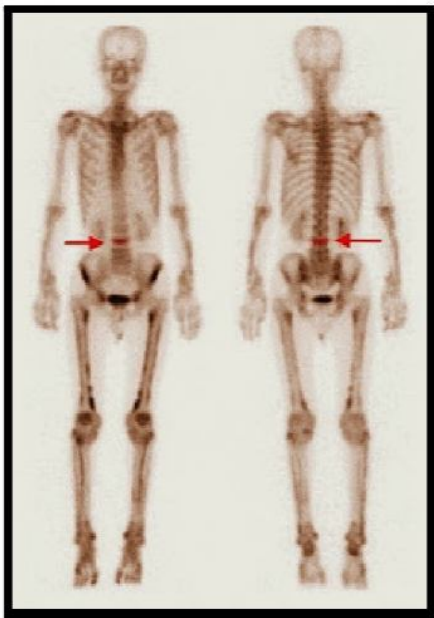


Figure 2.14: This image is a Nuclear Bone Scan of the whole body, taken from the front on the left and back on the right. An area of increased activity is seen in one of the vertebrae of the lowback (lumbar spine) (www.conciergeradiologist.com)

2.3.5 Discogram or discography:

This is a procedure that confirms or denies the disc(s) as the source of your pain. You will have a harmless dye injected into one of your discs. If there's a problem with your disc—like it's herniated—the dye will leak out of the disc. The surgeon will be able to see that on an x-ray, and that will show him/her that there's something wrong with your disc. (Schneiderman G, 1987)

2.4 Magnetic resonance imaging (MRI):

2.4.1 Principle of MRI:

The basis of MRI is the directional magnetic field, or moment, associated with charged particles in motion. Nuclei containing an odd number of protons and/or neutrons have a characteristic motion or precession. Because nuclei are charged particles, this precession produces a small magnetic moment. When a human body is placed in a large magnetic field, many of the free hydrogen nuclei align themselves with the direction of the magnetic field. The nuclei precess about the magnetic field direction like gyroscopes. This behavior is termed Larmor precession. (Pfirrmann, 2001)

In a 1.5 T magnetic field at room temperature this difference refers to only about one in a million nuclei since the thermal energy far exceeds the energy difference between the parallel and anti-parallel states. Yet the vast quantity of nuclei in a small volume sum to produce a detectable change in field. Most basic explanations of MRI will say that the nuclei align parallel or anti-parallel with the static magnetic field; however, because of quantum mechanical reasons, the individual nuclei are actually set off at an angle from the direction of the static magnetic field. The bulk collection of nuclei can be partitioned into a set whose sum spin are aligned parallel whose sum spin are anti-parallel. (Pfirrmann, 2001)

2.4.2 Equipment of MRI:

The MRI equipment consists of following components:

The magnet generates the magnetic field. Shim coils make the magnetic field homogeneous. Radio frequency coils transmit the radio signal into the body part being imaged. Receiver coils detect the returning radio signals. Gradient coils provide spatial localization of the

signals. Shielding coils produce a magnetic field that cancels the field from primary coils in regions where it is not desired. The computer reconstructs the signals into the image. The MRI scanner room is shielded by a Faraday shield. Different cooling systems cool the magnet, the scanner room and the technique room. (<https://www.mr-tip.com>)

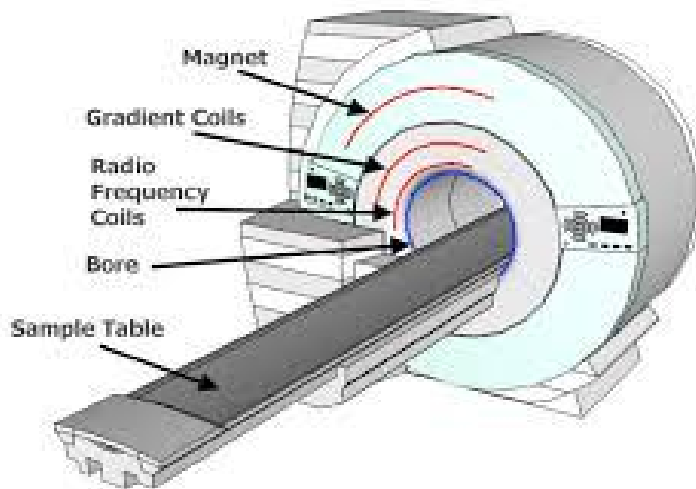


Figure 2.15: Component of MRI machine. (<https://www.mr-tip.com>)

2.4.3 Magnet:

The magnet is the largest and most expensive component of the scanner, and the remainder of the scanner is built around it. The strength of the magnet is measured in Teslas (T). Clinical magnets generally have field strength in the range 0.1–3.0 T.

Three types of magnet have been used:

1-Permanent magnet: Conventional magnets made from ferromagnetic materials.

2-Resistive electromagnet: A solenoid wound from copper wire is an alternative to a permanent magnet.

3-Superconducting electromagnet: most common type found in MRI scanners today. (Pfirrmann, 2001)

2.4.3.1 Radio frequency(RF) system

The RF transmission system consists of a RF synthesizer, power amplifier and transmitting coil. This is usually built into the body of the scanner. The power of the transmitter is variable, but high-end scanners may have a peak output power of up to 35 kW, and be capable of sustaining average power of 1 kW. The receiver consists of the coil, pre-amplifier and signal processing system. (Pfirrmann,2001)

A recent development in MRI technology has been the development of sophisticated multi-element phased array coils which are capable of acquiring multiple channels of data in parallel. This 'parallel imaging' technique uses unique acquisition schemes that allow for accelerated imaging, by replacing some of the spatial coding originating from the magnetic gradients with the spatial sensitivity of the different coil elements. However the increased acceleration also reduces SNR and can create residual artifacts in the image reconstruction. Two frequently used parallel acquisition and reconstruction schemes are sense. (Pfirrmann,2001)

2.4.3.2 Coils:

A Coil are part of the hardware of MRI machines and are used to create a magnetic field by voltage induced in the wire, coil consists of one or more loops of conductive wire, looped around the core of the coil. (Pfirrmann,2001)

Different types of MRI coils are used in MR systems:

2.4.3.2.1 Surface Coil:

Is essentially a loop of conducting material, This type of receiver coil is placed directly on or over the region of interest for increased magnetic sensitivity.(Pfirrmann,2001)

2.4.3.2.2 Volume Coil:

That surrounds either the whole body, or one specific region, such as the head or a knee. Volume coils have a better RF homogeneity than surface coils, which extends over a large area.(Pfirrmann,2001)

2.4.3.2.3 Gradient Coil:

Current carrying coils designed to produce a desired magnetic field gradient, Gradient coils in general vary the main magnetic field, so that each signal can be related to an exact location. (Pfirschmann,2001)

2.5 Technique of MRI in lumber spine

Posterior spinal coil/phased array spinal coil. Foam pads to elevate the knees. (Catherine Westbrook, 2008).

2.5.1 Equipment:

2.5.2 Patient positioning:

The patient lies supine in the couch with their knees elevated over foam pad for comfort and to flatten the lumbar curve. The coil should extend from xiphoidsternum to the bottom of the sacrum. The longitudinal alignment light lie in the midline and the horizontal one passes just below the low costal margin. (Catherine Westbrook, 2008).

2.5.3 Suggested protocol:

Sagittal T1 SE, Sagittal T2 FSE, prescribed on either side of the longitudinal light from the left to the right lateral borders of the vertebral bodies.

axial PD/T2 FSE, Angled to that they are parallel to each disc space, the lower three lumbar discs are commonly examined contrast is used for determining disc prolapses versus scar tissues. (Catherine Westbrook, 2008).

2.6 Previous studies:

Gamal Abdel Salam (2015) studied of the age related changes in the lumbar spine in Egyptian People Detected by Magnetic Resonance Image (MRI). Lumbar region is the mobile part of the vertebral column which bearing region. Unfortunately, the available data detecting the lumbar spine degenerative changes by MRI are still limited, particularly in Egypt. The present study aimed to the examination of possible age related changes in the lumbar spine in Egyptian people detected by MRI. Mid sagittal MRI scan were obtained from eighty symptomless persons (30 female's 37.5% and 50 males 62.5% of cases) between 25-70 years of age. They were divided into two groups: first group forty cases, 25-40 years (21males& 19 females) and the second group forty cases 41-70years (29 males & 11 female).

36From all samples, there were 38 normal (47.5%) and the abnormal cases were 42 (52.5%). It was found collectively that the abnormality were more in males than females and that was supplemented by x2-test (4.83) and p value (0.028). The following diseases were seen: subchondral sclerosis, osteophytes, disc degeneration, subchondral multiple small cyst, disc prolapsed and spondylolysis with variations in ages and sexes. In conclusion it was found that, the lumbar region affected early by the age and more affected in males than in females.

Ali Hassan A.Ali (2010) studied evaluation of age related changes in lumbar spine in Saudi Arabian adult population: using magnetic resonance Images, the main objective of our study was to investigate the frequency of lumbar spine degeneration in magnetic resonance images. We evaluated magnetic imaging (MRI) results from 210 patients complaining low back pain for age-related degeneration in the lumbar spine. In this study, 210 adult cases ranging between 18-90 years of age were included. The cases were classified into 3 groups: young age group (18 – 35 years old) (66 cases), middle agegroup(36 -55 years old) (75 cases)and old age group(56-90 years old) (69 cases).their MRI scans were performed in the department of radiology, King Khalid Hospital, Al kharj and studied for any age related changes. The most common feature observed in young age group was reduced signal intensity and modic type changes were more frequently seen in the old age group. Degenerative findings in the lumbar spine, suggesting degeneration, were common subjects. These results provide normative data for evaluating patients with degenerative lumbar diseases in Saudi adult symptomatic subjects.

Chapter Three

Materials and Methods

Study done in three Khartoum hospitals (Royal care),(Almoalem) (Alribat) sudan data were collected in the period from July 2018 to august 2018.

3.1. Materials:

3.1.1. Patient population:

Random samples consist of 50 patients who underwent MRI lumbar spine examination. The patients were registered (age, gender, type of examination, protocol used).

3.1.2. Machine used:

A MRI scan machine manufactured by japan company (Toshiba).

3.2. Methods:

3.2.1. MRI technique:

The patient lies supine on the couch with spinal coil extending from the top of the shoulders to the lower costal margin.

Longitudinal alignment light lies in the midline and horizontal alignment light passes through the center of the coil.

Sequences:

Alribat hospital: sagittal T1,T2 and axial T2 additional protocol coronal T1,T2

Royal care hospital: sagittal T1,T2 and axial T1,T2 coronal T1 additional protocol coronal T2

Almoalem hospital: sagittal T1,T2 and axial T1,T2 and STIR additional protocol coronal T1,T2

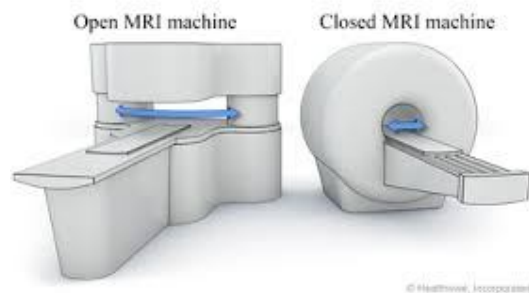


Figure 3.1: open and close MRI machines

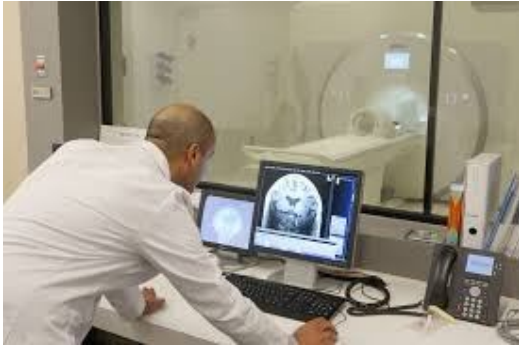

Figure3.2: MRI room control

3.2 .2 Data collection:

Data is collected from image reports and from data collection sheet that demonstrate gender, age, protocol and MRI finding.

The images were confirmed by the radiologists who were unaware of all clinical information to determined pathological finding seen.

3.2.3 Data Analysis:

The use of descriptive analytical methods using SPSS statistical program based descriptive statistics based on patients' age, gender and used protocol. And all this information were analyzed and presented in tables and figures.

3.2.4 Image Interpretation:

A disc prolapse occurs when there is a weakening in the outer membrane leading to a protrusion of the inner nucleus. This protrusion usually heads poster laterally towards the lateral parts of spinal canal which contains the nerve root. Occasionally the protrusion heads more centrally and can cause compression of the spinal cord (Drake et.al, 2009). That's clearly seen in figure below

Chapter four

Results

The MR images of 50 patients were evaluated for pathological finding, the age, gender, and protocol used. All this information was shown in the following tables and figures.

Table 4.1: distribution of patients with respect to age

Age	Frequency	per cent
Less than 30 years	2	4.0
30-40 years	11	22.0
41-50 years	12	24.0
51-60 years	11	22.0
61-70 years	9	18.0
More than 70 years	5	10.0
Total	50	100.0

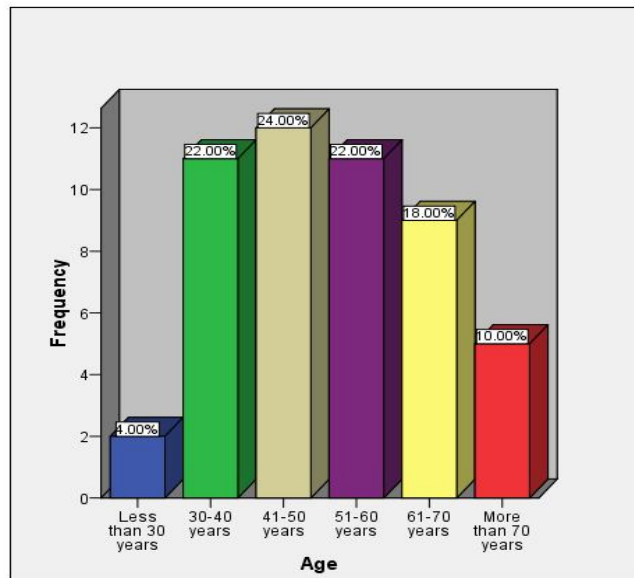


Figure 4.1: distribution of patients with respect to age

Table (4.1) and figure (4.1) show that most (24%) of participants were 41-50 years old and (22%) of them were 30-40 or 51-60 years, since (18%) of them 61-70 years, and (10%) of them were more than 70 years, while only (4%) of them were less than 30 years old, indicate that the most common age for disc prolapsed in lumbar spine was 30-60 years

Table 4.2: distribution of patients with respect to gender

Gender	Frequency	Percent
Male	29	58.0
Female	21	42.0
Total	50	100.0

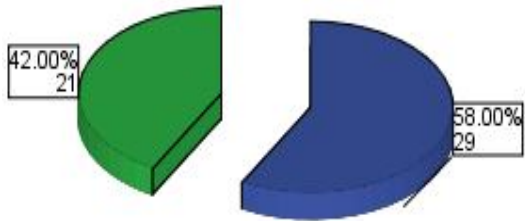


Figure 4.2: distribution of patients with respect to gender

Table (4.2) and figure (4.2) show that most (58%) of patients were males, while (42%) of them were females.

Table 4.3: distribution of patients with respect to protocol used

Protocol	Frequency	Percent
Coronal	7	14.0
Axial & sagittal	43	86.0
Total	50	100.0

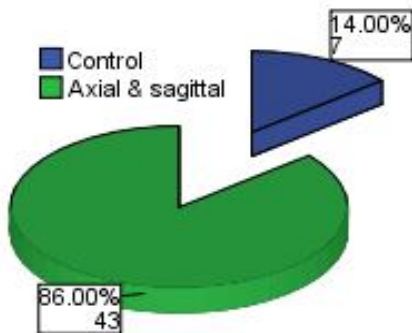


Figure 4.3: distribution of patients with respect to protocol.

Table (4.3) and figure (4.3) show that the protocol for majority (86%) of patients was axial and sagittal, while only (14%) of them were coronal

Chapter five

Discussion, conclusion and recommendation

5.1 Discussion:

The lumbar disc prolapses are the most common medical problem, the aim of this study was to assess of disc prolapse in lumbar vertebrae in Sudanese population using MRI. This study conducted on 50 patients who refer to MRI department 29 males and 21 females their age from 20-80 years old. The most indication for disc prolapsed is lower back pain.

And the mean of the age is between 41-50 (table 4.1) this result was in line with the previous studies which stated thatThe most common feature observed in young patient between(36-55).(Ali Hassan.2010).

Table 4.2 showed gender of patients, 58% of patients were males while 42% are female this result deal with (Gamal Abdel Salam. 2015) disc change are more common in male than female.

Table 4.3 show the most MRI sequences used to evaluate the disc prolapsed in lumbar region of spine. Axial and sagittal T1,T2 weighted image 86% while the used of coronal protocol 14% coronal protocol seldom using to detect the disc prolapsed.

This study was carried out to evaluation of disc prolapse inlumbar vertebrae in Sudanese population using MRI.The range of patients in this study ranged between20-80.And the mean of the age is between 41-50 (table 4.1)this result was in line with the previous studies which stated thatThe most common feature observed in young patient between(36-55).(Ali Hassan.2010)

Table 4.2 showed gender of patients, 58% of patients were males while 42% are female this result deal with (Gamal Abdel Salam. 2015) disc change are more common in male than female.

Table 4.3 show the most MRI sequences used to evaluate the disc prolapsed in lumbar region of spine. Axial and sagittal T1,T2 weighted image 86% while the used of coronal protocol 14% coronal protocol seldom using to detect the disc prolapsed.

5.2 conclusions:

In conclusion, this study has showed that MRI is the effective to demonstrate the disc prolapse in lumber vertebrae, MRI has become an attractive means for a safe, highly accurate, cost-effective diagnosis of lumber vertebrae and respects anatomically how the spinal cord is compressed and reflects the pathological changes within the spinal cord by showing a change in signal intensity of spinal cord.

The incidents of disc prolapse are common in elder patients the mean (41-50) years.

The disc prolapses are more common in male than female about (58.0%).

The sagittal and axial protocol is best to verifying the disc prolapse about (86%) of patients.

The most common symptoms in the patients are a lower back pain.

5.3 Recommendations:

- This study showed that , the sensitivity of MRI depends ,on the experience of operator so ,the radiologist and technologist should be continuously trained.
- Future studies must use large sample to support the findings.
- Technologist must be interpreted how to read MRI images if needed for other sequence or protocols to help the radiologist in evaluation of disc prolapsed in lumber vertebrae MRI.
- Requests for MRI lumbar spine must be written by experienced physician with clinical data to aid technologist in selecting proper MRI protocol.

References

- Catherine Westbrook, 1999, Hand book of MRI Technique, second edition, Blackweel science.
- Drake R, Vogl W, Mitchell AVM, Mitchell A.2009 Gray's Anatomy for Medical Students. 2nded. New York
- Edward f. Goljan, M.D.1998 Pathology. W.B.saunderscompany. 1nded
- Lippincott Williams& Wilkins, 2007 Musculoskeletal anatomy, neuroanatomy, and biomechanics of the lumbar spine. In: Wong DA, Transfeldt E, eds. Macnab's Backache.4thed. Philadelphia.
- Pansky B. 1996 Review of Gross Anatomy. 6thed. New York.
- Pfirschmann CW, Metzdorf A, Zanetti M, Hodler J, Boos N. 2001Magnetic resonance classification of lumbar intervertebral disc degeneration.Spine (Phila Pa 1976). Sep 1;26(17):1873-8. PubMed PMID: 11568697.
- Philadelphia.
- RosseC&Gaddum-Rosse P. 1997 The vertebral canal, spinal cord, spinal nerves, and segmental innervation. In: Rosse C, Gaddum-Rosse P, eds. Hollinshead's Textbook of Anatomy. 5thed. Philadelphia.
- Schneiderman G, Flannigan B, Kingston S, Thomas J, Dillin WH, Watkins RG. Magnetic resonance imaging in the diagnosis of disc degeneration: correlation with discography. SpineModic MT, Masaryk TJ, Ross JS, et al. Imaging of degenerative disk disease. Radiology 1999;168:177-86.
- Underwood, J.C.E 1996 General of systematic pathology . Churchill lwingstone.2nded New York.
- www.conciergeradiologist.com
- www.mr-tip.com
- www.wikipedia.org

B. Images:

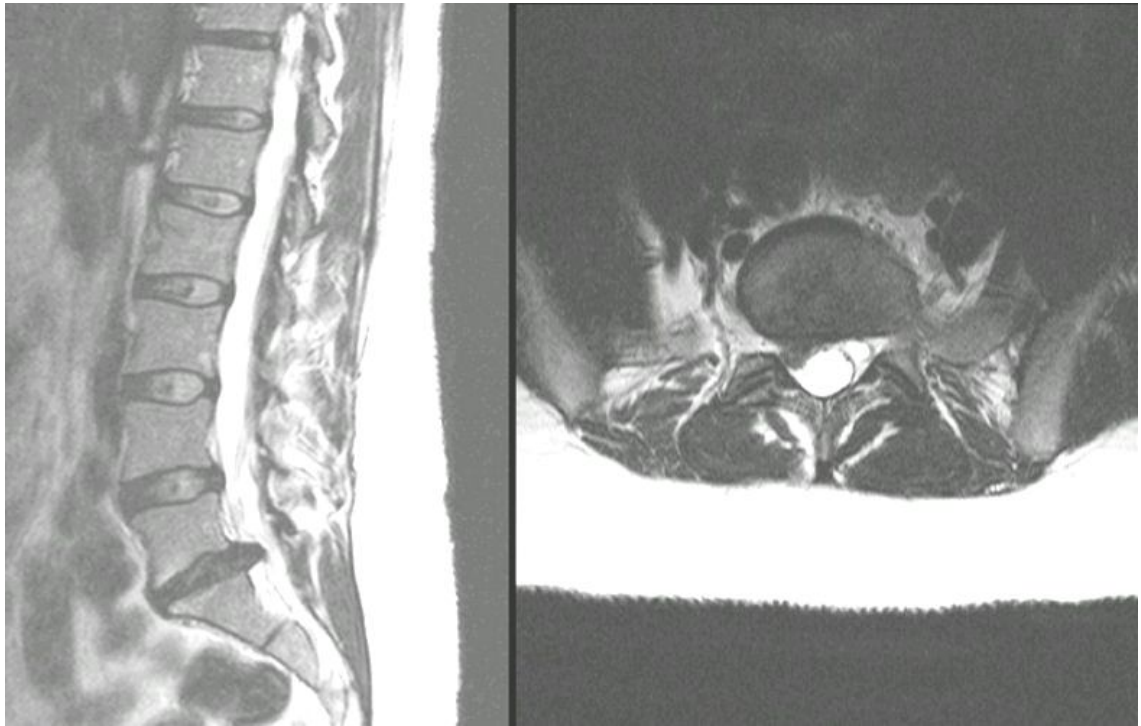


Image 1: sagittal and axial T2 Weighting MRI image with disc prolapse.

Patient have 40 years old suffering from pain in lumbar spine image clearly seen the disc prolapsed in L5-S1

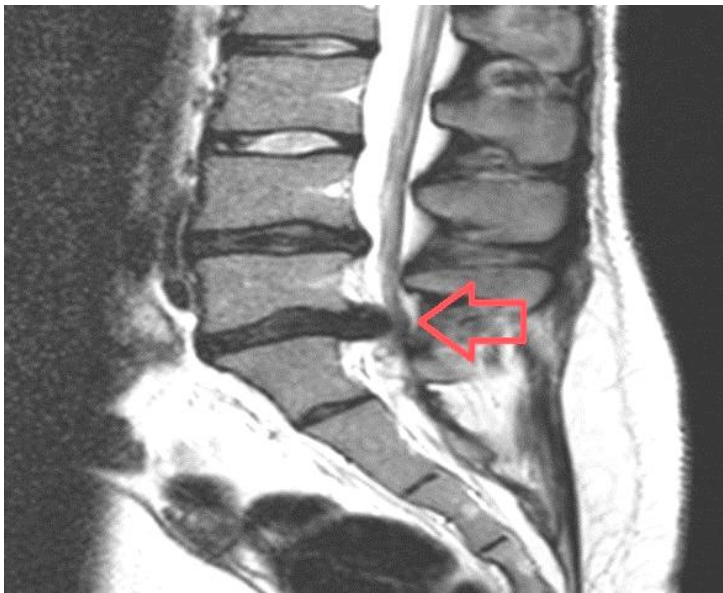


Image 2: MRI scan of the lower back showing a prolapsed disc

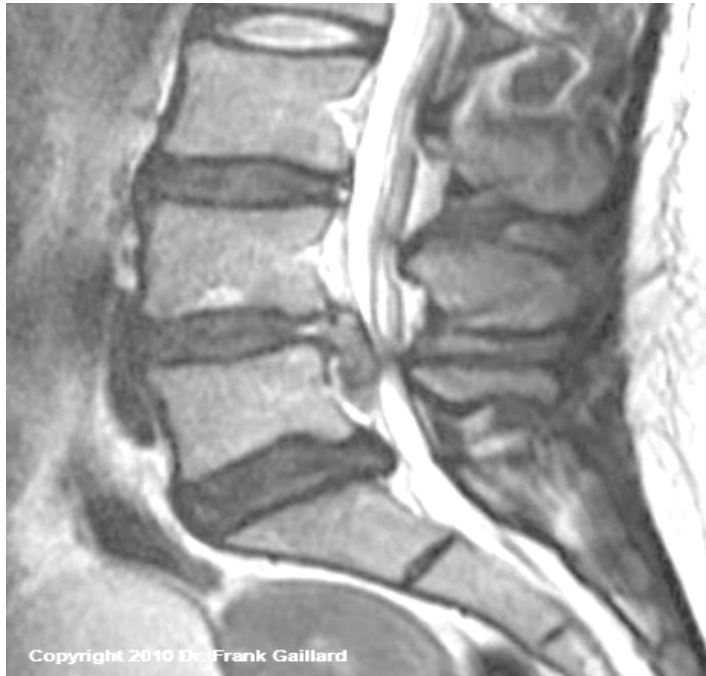

Image 3: Large L4 disc herniation.

Female patient have 45 years old complaining from back pain and the image clearly seen the disc prolapse in L4.

Also disc prolapse demonstrated part of the softer middle disc bulges through the fibrous outer ring and presses on the nerve as it leave spinal cord.

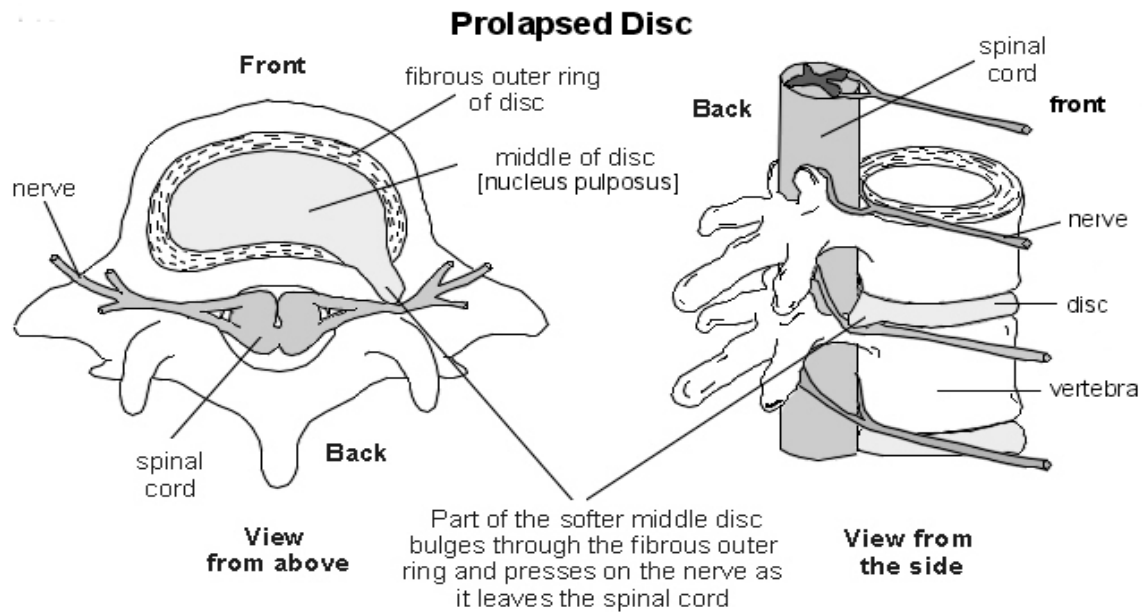


Image 4: Herniated or prolapsed disc

