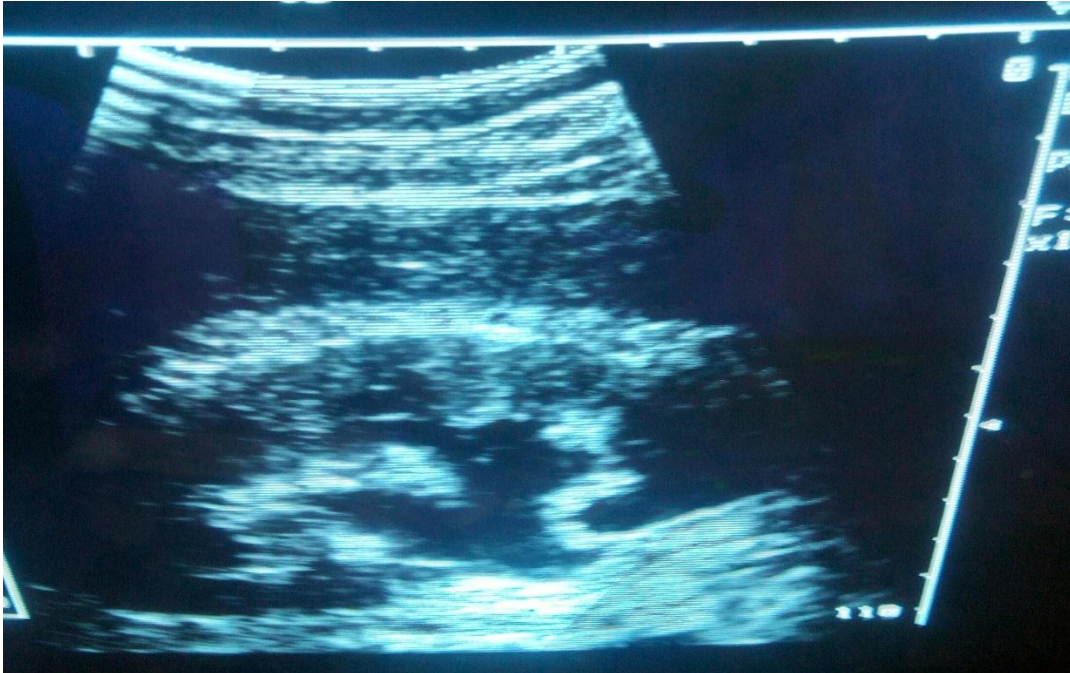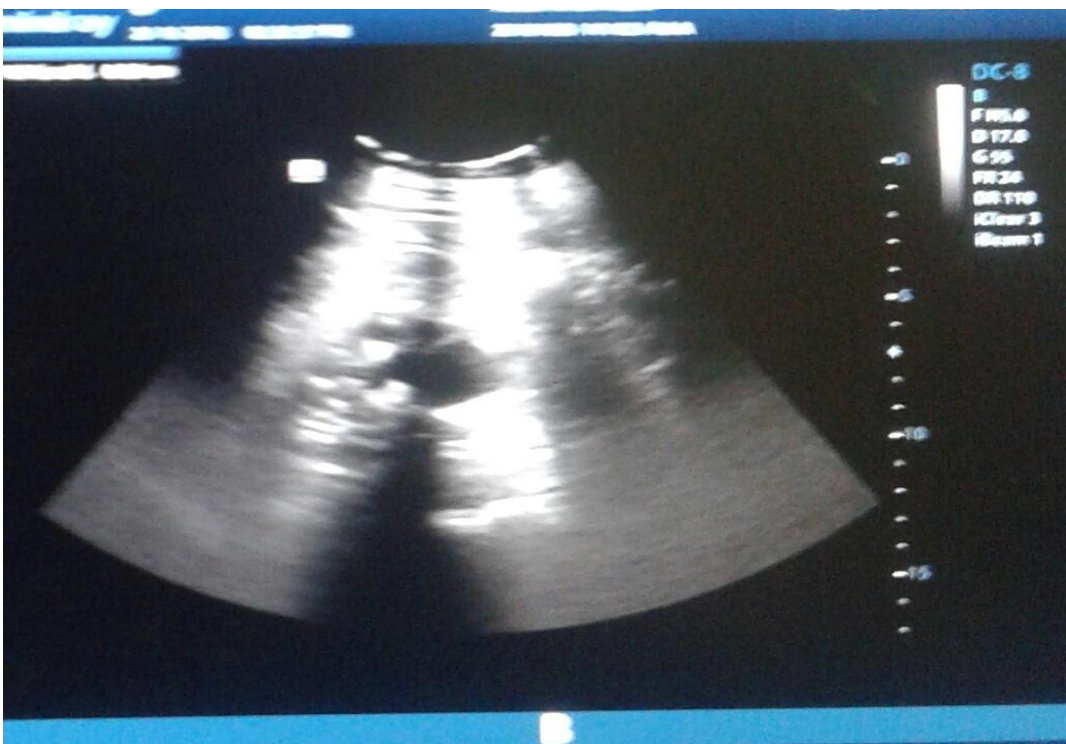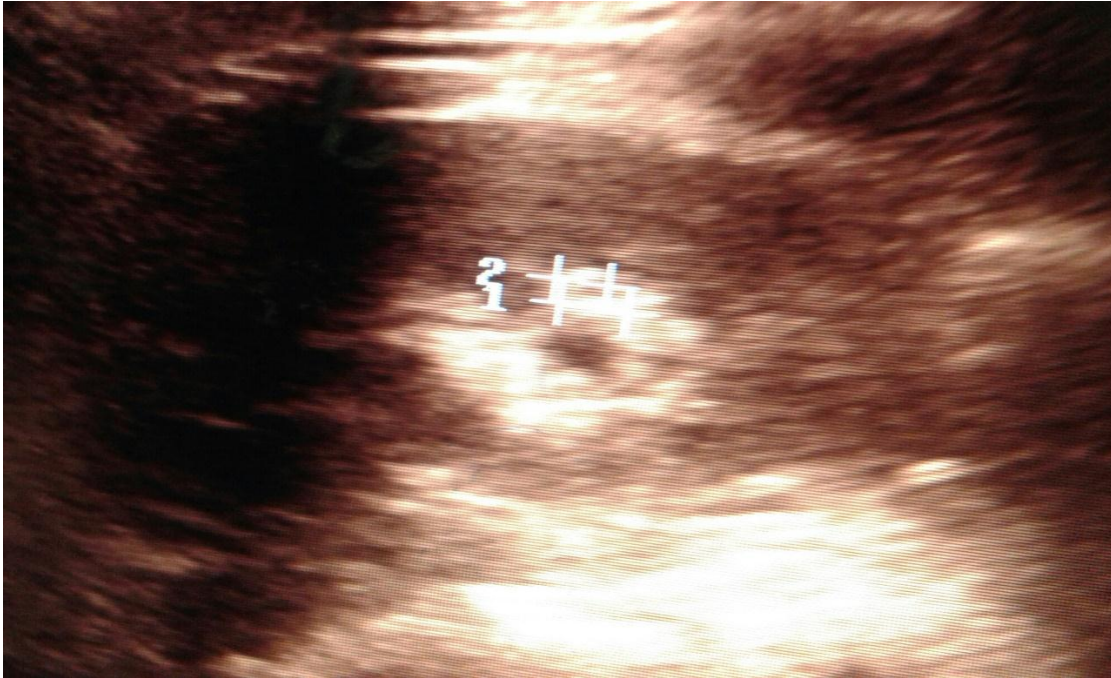


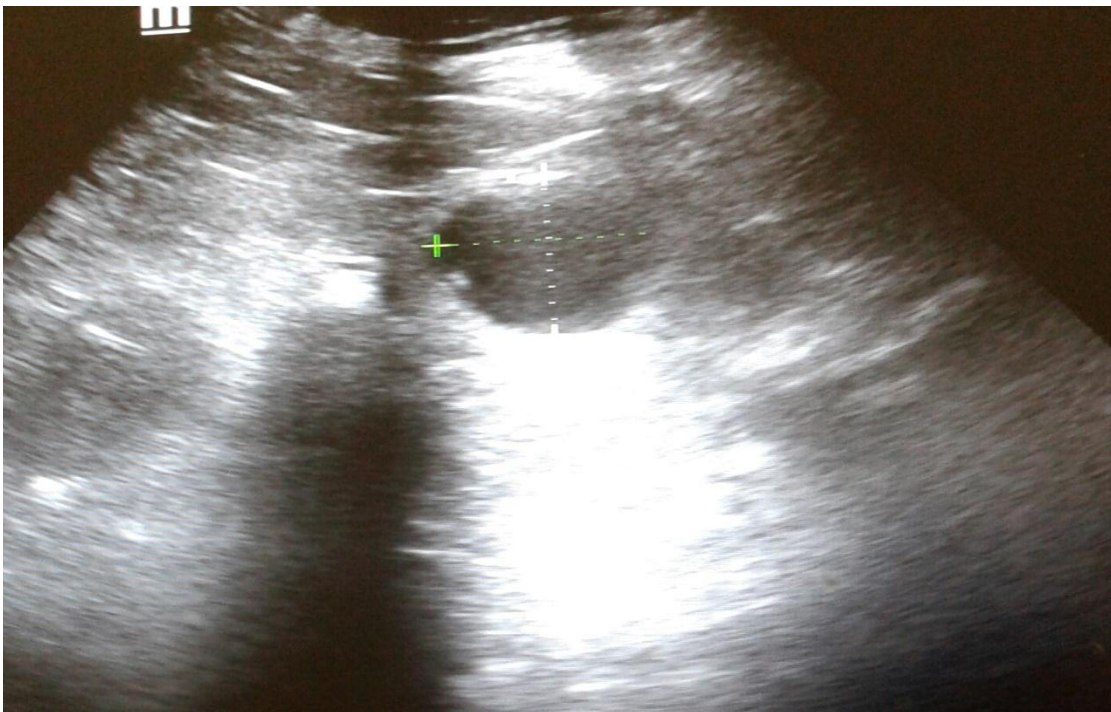
Sonogram1, 65 years old man with mild hydrohydronephrosis



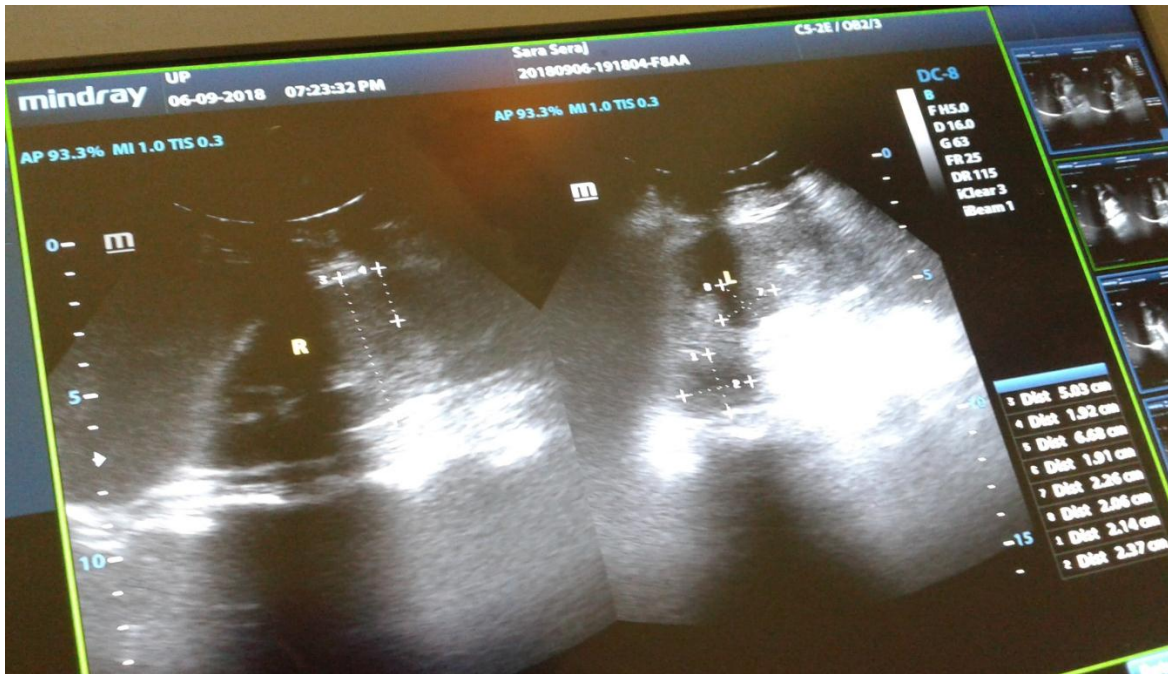Sonogram1, 35 years old woman with mid renal stone



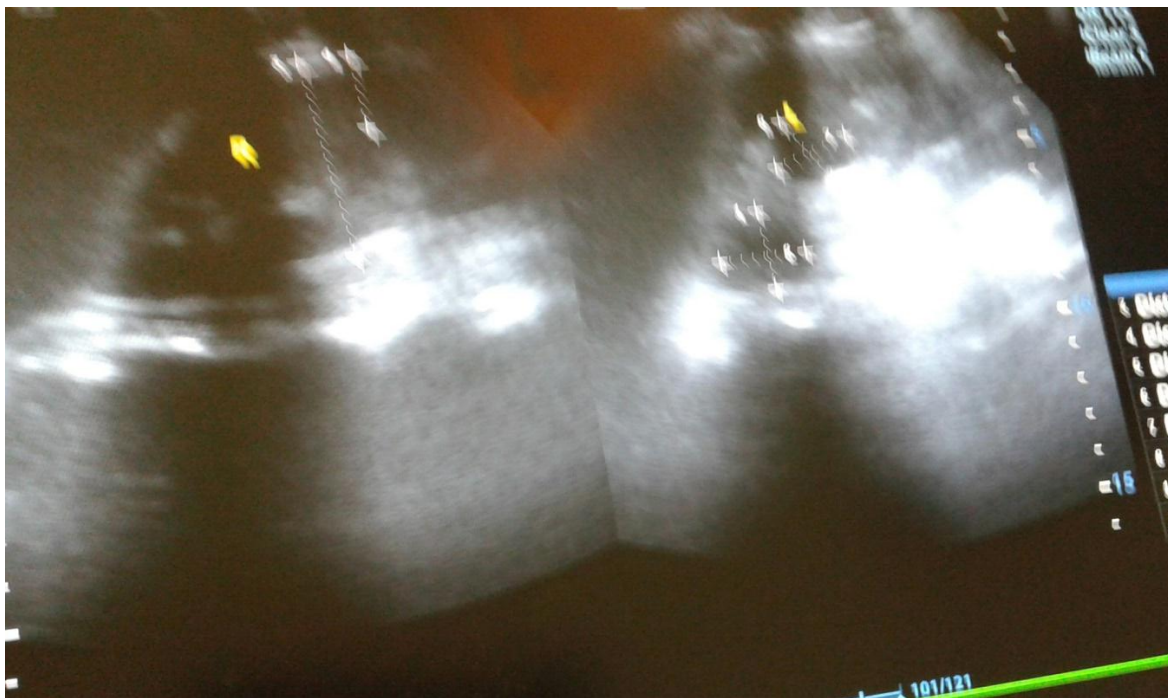Sonogram1, 45 years old woman with mid renal stone



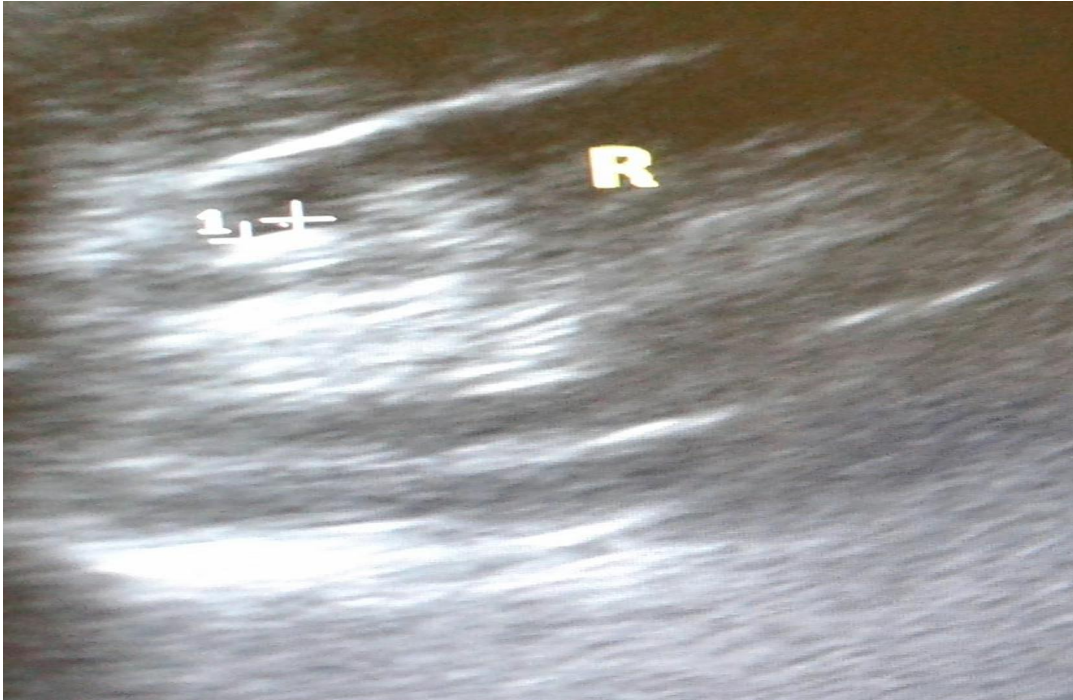
Sonogram1, 23 years old woman with simple cyst



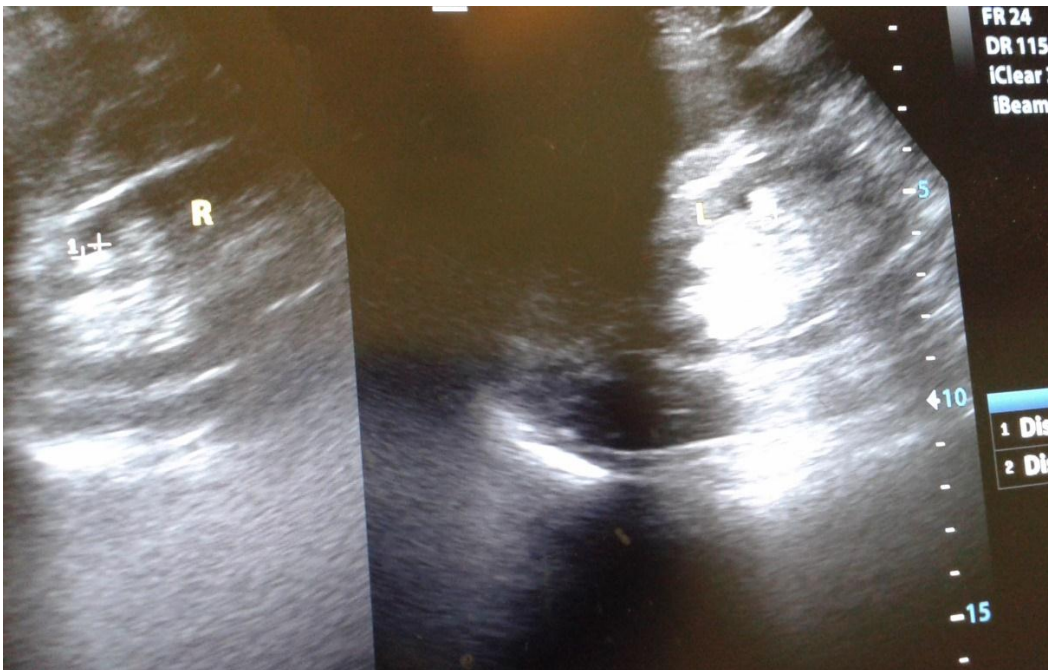
Sonogram1, 45 years old man with bilateral stone



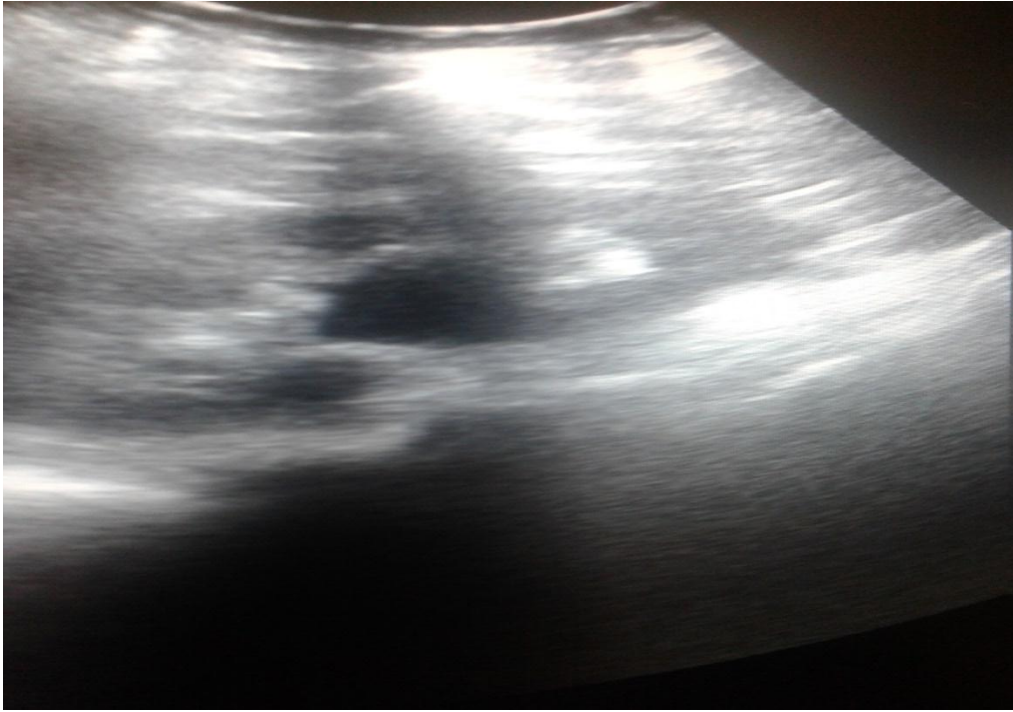
Sonogram1, 39 years old woman with chronic renal failure associated with cysts



Sonogram1, 28 years old man with renal stone



Sonogram1, 51 years old man with mid renal stone with back pressure



Sonogram1, 43 years old woman with mid renal stone with back pressure