

بسم الله الرحمن الرحيم



**Sudan University of Sciences and Technology**  
**College of Graduate Studies**



## **Evaluation of Thyroid Abnormalities using Ultrasonography and Radionuclide Scintigraphy**

**تقويم امراض الغدة الدرقية باستخدام فحوصات الموجات  
فوق الصوتية والتصوير بالنويدات المشعة**

**A Thesis Submitted for Award PhD. Degree in Nuclear Medicine Technology**

**By:**

***Amel Bushra Abakar Ahmed***

**Supervisor:**

***Dr. Mohamed Mohamed Omar***

***Co – Supervisor***

***Dr. Salah Ali Fadlalla***

**July 2018**



## Approval Page

(To be completed after the college council approval)

Name of Candidate:

Thesis title: ... *Evaluation of Thyroid Abnormalities*  
... *using ultrasonography and Radionuclide*  
... *scintigraphy* ...

Degree Examined for: ... *Ph.D* ...

Approved by:

### 1. External Examiner

Name: *Hussein A. Hassan*

Signature: *[Signature]* Date: *5-12-2018*

### 2. Internal Examiner

Name: *Ikhlas Abdelaziz Hassan Mohamed*

Signature: *[Signature]* Date: *5-12-2018*

### 3. Supervisor

Name: *Mohammed Mohammed Omer Mohamed Yousef*

Signature: *[Signature]* Date: *5-12-2018*

قال تعالى:

بسم الله الرحمن الرحيم

( اللَّهُ نُورُ السَّمَاوَاتِ وَالْأَرْضِ مِثْلُ نُورِهِ كَمِشْكَاةٍ فِيهَا مِصْبَاحٌ الْمِصْبَاحُ فِي زُجَاجَةٍ الزُّجَاجَةُ كَأَنَّهَا كَوْكَبٌ دُرِّيٌّ يُوقَدُ مِنْ شَجَرَةٍ مُبَارَكَةٍ زَيْتُونَةٍ لَا شَرْقِيَّةٍ وَلَا غَرْبِيَّةٍ يَكَادُ زَيْتُهَا يُضِيءُ وَلَوْ لَمْ تَمْسَسْهُ نَارٌ نُورٌ عَلَى نُورٍ يَهْدِي اللَّهُ لِنُورِهِ مَنْ يَشَاءُ وَيَضْرِبُ اللَّهُ الْأَمْثَالَ لِلنَّاسِ وَاللَّهُ بِكُلِّ شَيْءٍ عَلِيمٌ )

صدق الله العظيم

سورة النور، الآية (35)

# DEDICATION

*To my family who have always been my nearest and have been so close to me that I found them with me whenever I needed. It is their unconditional loves that motivate me to set higher targets.*

## ACKNOWLEDGMENT

*Thankful for Allah, and then great doctors and teachers and special thanks to my supervisor*

***Dr. Mohammed Mohammed Omer and***

*Co-supervisor **Dr Salah Ali Fadlalla** For their supporting and encouraging carry-out this study.*

*I would like to acknowledge to my colleagues who paved the way for me during data collection.*

## ABSTRACT

The main aim of this study was to evaluate the thyroid abnormalities using ultrasound and scintigraphy.

The study population consisted of 173 patients were seen by surgeons and medical doctors , were diagnosed clinically as having thyroid issues, and referred to Nuclear Medicine and Radiology Department, Fujairah hospital for thyroid scintigraphy and neck ultrasound during the period from Jan 10, 2016 to June 30, 2018. All patients Thyroid function test were done before coming to radiology department. So all results were comparing with the TFT results.

The results of this study revealed that 173 patients 86% were female (149) and 14% were male (24), their mean age was 38 years. Thyroid ultrasound scan finding normal in 6% (11 patients) and abnormal in 94 % (162 patients).thyroid nuclear medicine scan were reported as normal in 9% (16 patients) and abnormal in 91% (157 patients),most affected patient's age group ( 20 - 50) years and commonest disease is Multinodular goiter(48%),Nodules site in both examinations, thyroid scintigraphy and thyroid ultrasound 80 and 114 is Right lobe respectively.

Thyroid scintigraphy and ultrasound reached the almost same imaging findings in patients with thyroid abnormality. Ultrasonography compared to nuclear medicine scintigraphy, Ultrasound detected 93.6% (162 patients) more than nuclear medicine 90.3% (157 patients) by 3.3 % . Ultrasonography

was found to be an appropriate study in the detection of thyroid abnormality. Both US and thyroid scintigraphy have diagnosed the thyroid gland abnormality and suggested the diagnosis of others disorders in all other patients.

This study concluded that the relationship between the two studies cannot be changed and does not have a significant effect because the level and degree of sensitivity of the examination of the thyroid gland by nuclear medicine is not more sensitive and accurate than the ultrasound examination . Ultrasound has the additional advantages of being non-ionizing radiation and accurately localizes and characterizes the thyroid abnormalities. Ultrasound examination should be obtained routinely for patients with suspected thyroid diseases and scintigraphy is reserved for selected cases.

## مستخلص البحث

تهدف هذه الدراسة تقييم امراض الغدة الدرقية باستخدام فحوصات الموجات فوق الصوتية و التصوير بالنويدات المشعة لضمان تقادي التعرض غير الضروري للإشعاع

الدراسة تألفت من عدد 173 من المرضى الذين تم تحويلهم من عدد من الجراحين واطباء الباطنية بعد ان تم تشخيصهم سريريا بالإصابة بأمراض الغدة الدرقية، الي الطب النووي، وقسم الأشعة، مستشفى الفجيرة لعمل فحوصات الغدة الدرقية خلال الفترة من 10 يناير 2016 إلى 30 يونيو 2018. وقد خضع جميع المرضى لاختبار وظائف الغدة الدرقية قبل أن يأتي إلى قسم الأشعة. تم مقارنة نتائج كل ذلك مع نتائج فحص الهرمونات.

كانت نتائج فحوصات الغدة الدرقية والموجات فوق الصوتية متقاربه خاصة في وجود العقيدات وحالات التهاب الغدة . نتائج فحوصات الطب النووي بالمقارنة مع الكشف بالموجات فوق الصوتية تفوق الاخير في الكشف علي امراض الغدة الدرقية بنسبة 93.6 % (162 مريضا) أكثر من الطب النووي 90.3% (157 مريضا) بنسبة 3.3%، و لكن استطاع الفحصين تشخيص عدد من حالات الخلل في الغدة الدرقية و قدمت إقتراحات لبقية امراض الغدة الدرقية لبقية المرضى .

**الخاتمة:** بعد الانتهاء من هذه الدراسة تبين أن العلاقة بين الفحصين لا يمكن تغييرها، وليس لديها تأثير كبير لمستوى ودرجة الحساسية لفحص الغدة الدرقية. الطب النووي ليس أكثر حساسية ودقة من الفحص بالموجات فوق الصوتية. الموجات فوق الصوتية لديها مزايا إضافية وهو عدم وجود مواد مشعة والدقة في تمييز امراض الغدة الدرقية. وعليه ينبغي الحصول على الفحص بالموجات فوق الصوتية بشكل روتيني للمرضى الذين يشتبه اصابتهم بأمراض الغدة الدرقية مع الإبقاء علي فحص النويات المشعة لحالات محددة.



## List of contents

NO	Subject	Page
	الاية	i.
	Dedication	ii.
	Acknowledgement	iii.
	Abstract (English)	iv.
		v.
	Abstract (Arabic)	vi.
	Table of contents	vii.
		viii.
		ix.
	List of Tables	x.
		xi.
	List of Figures	xii.
		xiii.
	List of Abbreviations	xiv.
	Chapter one	
1.	Introduction	1
1.1	Problem of study	2
1.2	General objective of study	2
1.3	Specific objectives of the study	2
1.4	Significant of the study	2
1.5	Over view of study	3
	Chapter two (literature reviews)	
2.1	Thyroid gland Anatomy	4
2.1.1	Shape	4
2.1.2	Blood supply	6
2-1-3	Lymph drainage	9
2-1-4	Nerve supply	10

2-1-5	Variant anatomy	11
2-1-6	Histology	12
2-1-7	Embryology	14
2-1-8	Ultrastructure and Histology	15
2-2	Physiology	16
2-2-1	Iodine Uptake	17
2-2-2	etion of Thyroid Hormones	17
2-2-3	isport	17
2-2-4	radation	18
2-2-5	Regulation	18
2-2-6	Iodide sequestration	18
2-2-7	T3 and T4 production and action	19
2-2-8	Thyroid Hormone Actions	21
2-2-9	Function of the thyroid glands	22
2-3	Pathophysiology	22
2-4	Pathology	22
2-5	Ultrasounds	29
2-5-1	Basic physics Instrumentation of ultrasound	29
2-5-2	Transducer	30
2-5-3	Modes of display in ultrasonography	31
2-5-4	Real time ultrasound:	31
2-5-5	Doppler Basic	32
2-5-6	Ultrasound Artifacts	32
2-6	Nuclear Medicine	36
2-6-1	Techniques	38
2-6-2	Thyroid scan procedure	38
2-6-3	Nuclear medicine findings	39
2-6-4	Computed tomography (CT)	40

2-7	Thyroid investigations		41
2-8	Treatment		45
2-9	Previous Studies		47
		Chapter three	
3-1	Materials		53
3-2	Methods		53
		Chapter four	
4-1	Results		62
		Chapter five (Discussion)	
5-1	Discussion		83
5-2	Conclusion		89
5-3	Recommendations		90
	References		91
	Appendices		

## List of Tables

Table no	Title	Page no
4-1	Numbers of male and female patients	62
4-2	Numbers of normal and abnormal patients in each test	63
4-3	Patient's ages frequency	64
4-4	The Numbers of normal patients and patients with different thyroid disorder in each test	64
4-5	Nodules site in both tests (thyroid scintigraphy and thyroid ultrasound)	65
4-6	Thyroid size taken by both tests (thyroid scintigraphy and thyroid ultrasound)	65
4-7	Nodule site in both tests	65
4-8	Statistics of patient's ages	69
4-9	Correlation positive high relation between gender and Thyroid ultrasound 0.744, highly significant at 0.000 in level 0.01	70
4-10	Correlation positive high relation between gender and thyroid nuclear medicine	70
4-11	Correlation positive high relation between gender and nuclear medicine (nodule site)	71
4-12	Correlation negative high relation between age and thyroid nuclear medicine-	72

4-13	Negative high relation between age and thyroid nuclear medicine (nodule site)	73
4-14	Correlation negative high opposed relation between age and nuclear medicine	74
4-15	Statistics for nuclear medicine scintigraphy	74
4-16	Statistics of ultrasound (nodule site)	75
4-17	Statistics nodules sites by nuclear medicine scintigraphy	76
4-18	Statistics of nodule sites by ultrasound	77
4-19	Statistics of thyroid size	78
4-20	Statistics of thyroid size by ultrasound	78
4-21	Correlation positive relation between nuclear medicine and ultrasound	79
4-22	Patients hormones results	82

## List of figures

No of Figure	Title	Page of figure
2-1	An anterior view showing the gross anatomy of the thyroid gland and adjacent structures.	5
2-2	Transverse US image shows the homogeneous echogenicity of the normal thyroid tissue and the normal thickness of the isthmus.	2
2-3	Drawing illustrates the cross-sectional anatomy of the thyroid and adjacent soft tissue structures	6
2-4	Blood supply to the thyroid gland	7
2-5	Blood supply to the thyroid gland, thyroid Ima artery arise from brachiocephalic trunk	8
2-6	The image shows the right recurrent laryngeal nerve, right thyroid lobe reflected by forceps	8
2-7	lymphatic drainage of thyroid gland	9
2-8	Nerve supply of thyroid gland	10
2-9	The left recurrent laryngeal nerve comes from the left vagus nerve	11
2-10	Thyroid Glands Without an Isthmus	11
2-11	<a href="#">Section of thyroid gland under the microscope 1 follicles 2 follicular cells, 3 endothel cells</a>	12
2-12	Normal thyroid follicle lined by a cuboidal follicular epithelium with	13
2-13	Adenomatous nodule in a 66-year-old man	26
2-14	Ultrasound waves	30
2-15	Ultrasound transducer	31
2-16	Thyroid Gland Variations, Accessory Thyroids, Thyroglossal Duct	35
3-1	BrightView SPECT gamma camera	60
3-2	BrightView SPECT gamma camera	60

3-3	Toshiba Ultra sound machine , Aplio 400, model SSA-370A	61
3-4	Toshiba Ultra sound machine , Aplio 400, model SSA-370A	61
4-1	shows Numbers of male and female patients	63
4-2	shows the frequency of solitary nodules and multi nodules by Nuclear medicine	66
4-3	shows the frequency of normal and enlarge thyroids by ultrasound	67
4-4	age frequency of patients	67
4-5	Thyroid abnormalities frequency with ultrasound	68
4-6	Thyroid abnormalities frequency with nuclear medicine scintigraphy	68
4-7	solitary nodules and multi nodules frequency by ultrasound	69
4-8	shows statistics of nodule site in nuclear medicine	75
4-9	that shows statistics of nodule sites by ultrasound	76
4-10	shows the frequencies of thyroid size in nuclear medicine	77
4-11	shows the frequencies of solitary nodules and multi nodules in both scans (ultrasound and scintigraphy)	80
4-12	shows the frequencies of nodules sites in both scans (ultrasound and scintigraphy)	80
4-13	shows the frequencies of normal and enlarge size of thyroid gland in both scans (ultrasound and scintigraphy)	81
4-14	shows the frequencies of thyroid abnormalities in both scans (ultrasound and scintigraphy)	81

## **List of abbreviations**

RIA	Radioimmunoassay
SPSS	Statistical Package for Social Sciences
SSN	Supra Sternal Notch
TBG	Thyroxine-Binding Globulin
TFT	Thyroid Function Test
TG	Thyroglobulin
TSH	Thyroid Stimulating Hormone
TSI	Thyroid-Stimulating Immunoglobulin
T4	Thyroxine
T3	Triiodothyronine
WHO	World Health Organization
U/S	Ultrasound
NM	Nuclear Medicine
TBG	Thyroxin Binding Hormone
TSH	Thyroxin Stimulating hormone
MBq	Mega Becquerel
IV	Intravenous
FNA biopsy	Fine Needle Aspiration



MTC	Medullary Thyroid Cancer
FSH	Follicle stimulating hormone
LH	Luteinizing hormone
GH	Growth hormone
PRL	Prolactin
HPL	Human placental lactogen
TRH	Thyrotropin releasing hormone
SSN	Suprasternal notch
N G	Nodular Goiter
M NG	Multi Nodular Goiter
AMP	Adenosin Mono Phosphate
TCD	Thyroglossal duct cyst

# Chapter One

**(Introduction)**

## **Chapter one**

### **(Introduction)**

#### **I. 1 Introduction**

A thyroid disease is a medical condition impairing the function of the thyroid. Different thyroid diseases include Hashimoto's thyroiditis, hyperthyroidism and hypothyroidism. These diseases have a large range of symptoms and affect all ages. The most common thyroid disorders include Hashimoto's disease, Graves' disease, goiter, and thyroid disorders. Thyroid gland is the largest exclusively endocrine gland in the body, it lies in the neck, in front of the upper part of the trachea, the thyroid gland is butterfly shaped and sits on the trachea, in the anterior neck. It is comprised of two lobes connected in the middle by an isthmus. Inside, the gland is made up of many hollow follicles, whose epithelial cell walls (also known as follicle cells) surround a central cavity filled with a sticky, gelatinous material called colloid. The hormones secreted by the thyroid gland are essential in the process of endocrine system, the two major thyroid hormones (TH) are thyroxine (also known as tetraiodothyronine or T4) with four iodine molecules and tri-iodothyronine (T3) with, predictably, three iodine molecules. While T4 exists in greater abundance than T3 in the body- thought to be at a fifty to one ratio, T3 is considered to be ten times more active. There is much debate about the physiological difference between the two hormones. Thyroid nodules are often detected incidentally at computed tomography, magnetic resonance imaging, and positron emission tomography; however, ultrasonography (US) is the most commonly used imaging modality for characterization of these nodules. US characteristics that increase the likelihood of malignancy in a thyroid nodule include micro calcifications, solid composition, and central vascularity. Nuclear scintigraphy is commonly used for evaluation of physiologic thyroid function and for identification of metabolically active and inactive nodules.

## **1.2 Problem of the study:**

Thyroid hormones values are not reliable and accurate examination in detecting of thyroid diseases alone; there is shortness of thyroid studies facilities, lack of public awareness and patient attendance in late stages of thyroid diseases. Radiation protection is not fully applied in nuclear medicine departments on the so-called small radiation dose; some neighboring tissues to the thyroid take the same dose of the thyroid due to absence of consideration to dose. Ultrasound may play main role for follow up patients instead of nuclear medicine

## **1.3 Objectives**

### **1.3.1 General objective**

To evaluate the thyroid lesions using ultrasound and scintigraphy.

### **1.3.2 Specific Objectives of the study**

- To compare the final outcome results of Ultrasound to that of Scintigraphy and to determine if ultrasound can be the sole diagnostic study in detecting thyroid abnormalities.
- To cross-correlate nuclear medicine thyroid scintigraphy results with ultrasound imaging findings.
- Sensitivity of ultrasound and thyroid scintigraphy
- To reduce the radiation exposure to the patients by using ultrasound to provide accurate, safe and cheap test.

## **1-4 Significant of the study**

This study will provide sonographic characteristics of thyroid abnormalities which help in diagnosis of the potential candidate for nuclear scan; and therefore save patient from unnecessary radiation and other types of examinations; which might have some risk.

## **1-5 Overview of the study**

This study consisted of five chapters with chapter one is an introduction which include overview of the thyroid context, problem of the study, objectives and overview. Chapter two include background and literature review (previous study) while chapter three include material and method used for data collection and analysis. Chapter four presents the result of the study in graphs and tables and finally chapter five includes the discussion, conclusion, recommendation and references.

# Chapter Two

**(Literature Review)**

## **Chapter two**

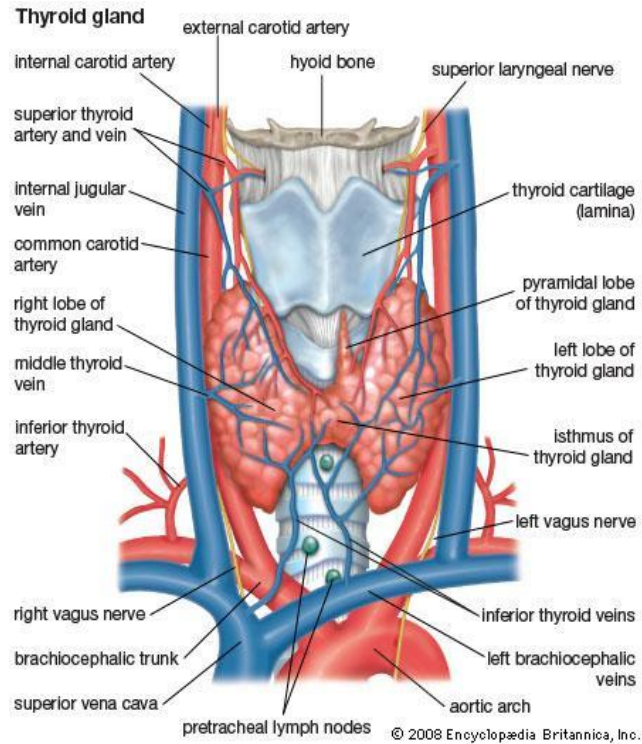
### **(Background and Literature)**

#### **2-1 Thyroid gland Anatomy:**

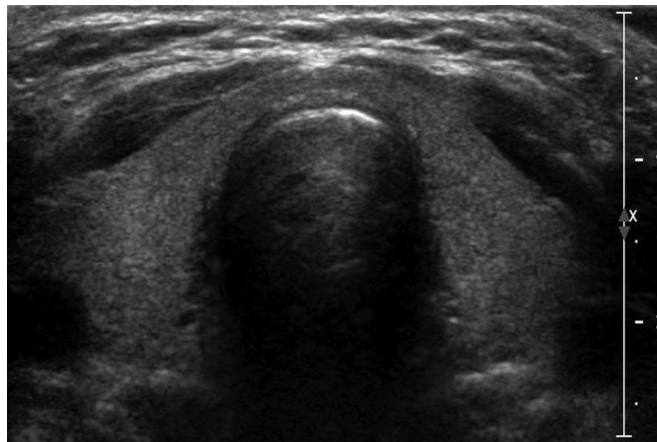
##### **2-1-1 Shape and Location:**

The thyroid is a butterfly-shaped endocrine gland located within the lower neck and is draped anteriorly around the trachea (Fig 1-2). The left and right lobes are located immediately to the left and right of the trachea, respectively, and are connected anteriorly by a thin rim of thyroid tissue known as the isthmus. The internal carotid arteries and internal jugular veins are located posterolateral to the thyroid lobes, whereas the strap muscles of the neck are located anteriorly (Kim, et al, 2002). The thyroid gland is located adjacent to the cranial trachea close to the recurrent laryngeal nerve, carotid sheath and sternohyoid and sternothyroid muscles. The Parathyroid Glands are located dorsally to, or within the thyroid gland itself (Papini, et al, 2004). Esophagus—slightly to the left of midline and posterior to the thyroid. Surrounding Musculature and Structures: Sternohyoid muscle—anterior and slightly lateral, Sternothyroid muscle—posterior to the sternohyoid and Longus colli muscle. (Charles et al (2012)).

The normal thyroid weighs approximately 15 to 25 g, with each lobe 4 to 6 cm in length and 1.3 to 1.8 cm in thickness. The isthmus measures less than 4 to 5 mm.

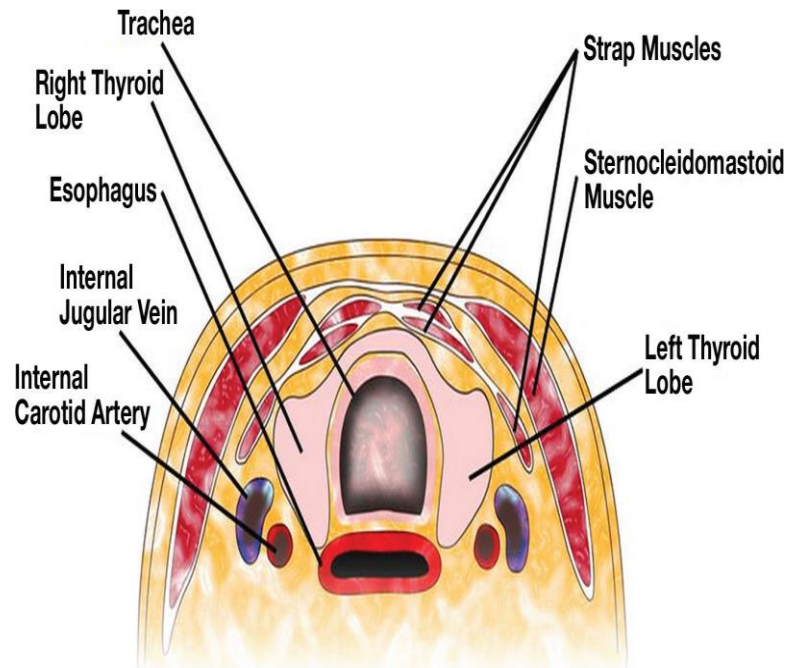


**Figure 2-1: An anterior view shows the gross anatomy of the thyroid gland and adjacent structures.**



**Figure 2-2: Transverse US image shows the homogeneous echogenicity of the normal thyroid tissue and the normal thickness of the isthmus.**





**Figure2-3: Drawing illustrates the cross-sectional anatomy of the thyroid and adjacent soft tissue structures**

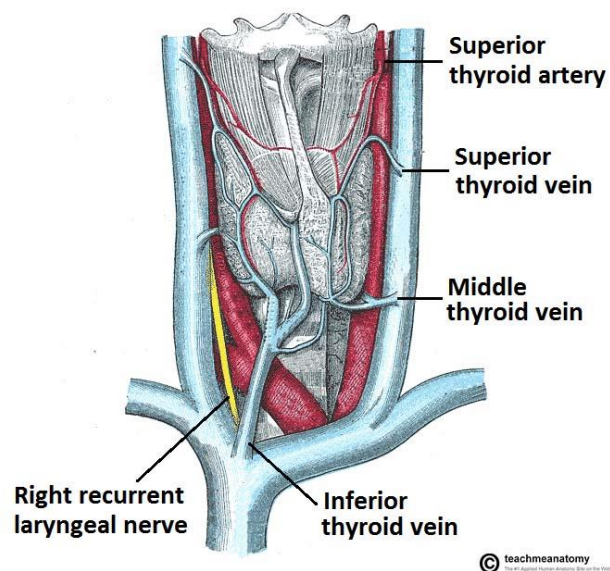
### **2-1-2 Blood Supply:**

The thyroid gland is supplied by the cranial thyroid artery which is a branch of the common carotid artery. A subsidiary supply is provided by the caudal thyroid artery. The cranial and caudal thyroid arteries are united by substantial anastomoses along their caudal edge. Venous drainage is provided by the internal jugular vein and lymph drains into the cranial deep cervical nodes.(Papini, et al,2004).

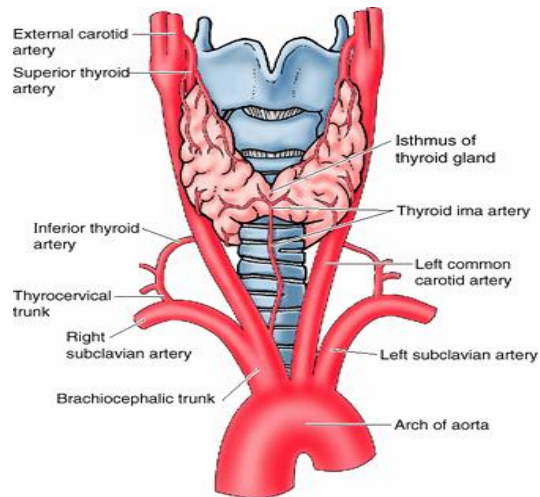
Because the thyroid gland is a hormone secreting organ, it is highly vascularized. It receives its blood supply from the superior and inferior thyroid arteries. These arteries lie between the fibrous capsule and the pretracheal layer of deep cervical fascia. The superior thyroid artery is the first branch of the external carotid artery and supplies the top half of the thyroid gland. It divides into anterior and posterior branches supplying respective sides of the thyroid. On the anterior side, the

right and left branches anastomose with each other. On the posterior side, the right and left branches anastomose with their respective inferior thyroid arteries.

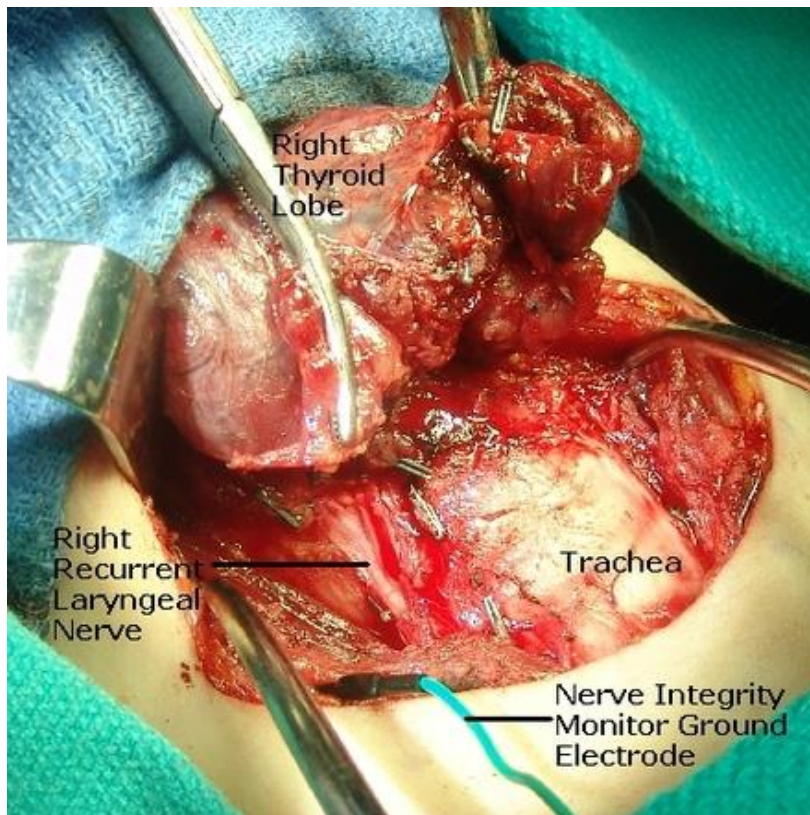
The inferior thyroid artery supplies the lower half of the thyroid and is the major branch of the thyrocervical trunk, which comes off the subclavian artery. It too divides into several branches, supplying the inferior portion of the thyroid and anastomosing posteriorly with the superior thyroid branches. There are three main veins that drain the venous plexus on the anterior surface of the thyroid. They include the superior, middle, and inferior thyroid veins, and each drains its respective portion of the thyroid. The superior and middle thyroid veins drain into the internal jugular veins, whereas the inferior thyroid veins drains into the brachiocephalic veins, behind the manubrium of the sternum. Figure(2-5)



**Figure 2-4 Blood supply to the thyroid gland**



**Figure 2-5 Blood supply to the thyroid gland, thyroid Ima artery arise from brachiocephalic trunk**

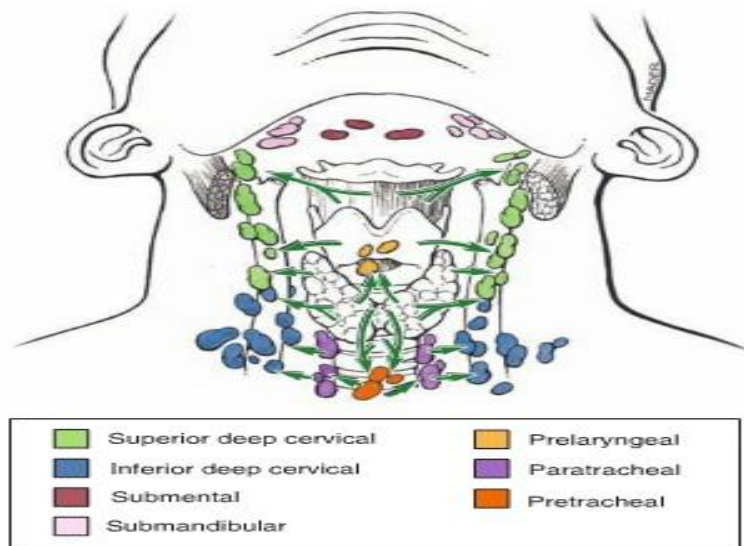


**Figure 2-6 The image shows the right recurrent laryngeal nerve, right thyroid lobe reflected by forceps**

### 2-1-3 Lymph drainage

Lymphatic drainage of the thyroid gland is quite extensive and flows multidirectionally. Immediate drainage flows first to the periglandular nodes, then to the prelaryngeal (Delphian), pretracheal, and paratracheal nodes along the recurrent laryngeal nerve, and then to mediastinal lymph nodes. ([http://fitsweb.uchc.edu/student/selectives/Luzietti/Thyroid\\_anatomy.htm](http://fitsweb.uchc.edu/student/selectives/Luzietti/Thyroid_anatomy.htm))

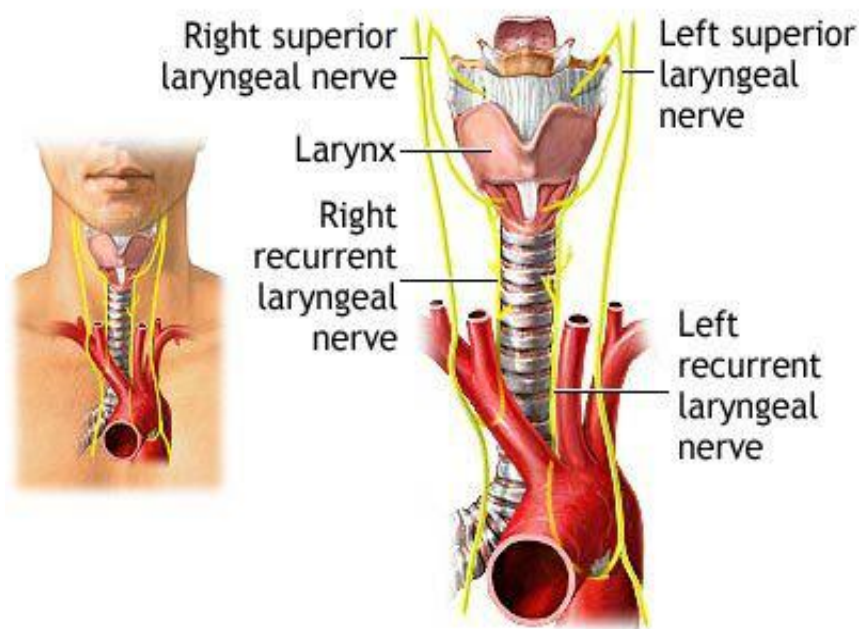
The lymphatic drainage of the thyroid gland runs in the interlobular connective tissue and then communicates with a network of lymphatic vessels. The lymphatic vessels communicate with the tracheal plexus, and pass to prelaryngeal nodes above the thyroid isthmus, and to pretracheal and paratracheal nodes. Some may drain into brachiocephalic nodes. Laterally the gland drains into deep cervical nodes. Some lymph may drain directly, without nodes, to the thoracic duct. (Burkitt, H., et, al (1996) )



**Figure 2-7 lymphatic drainage of thyroid gland**

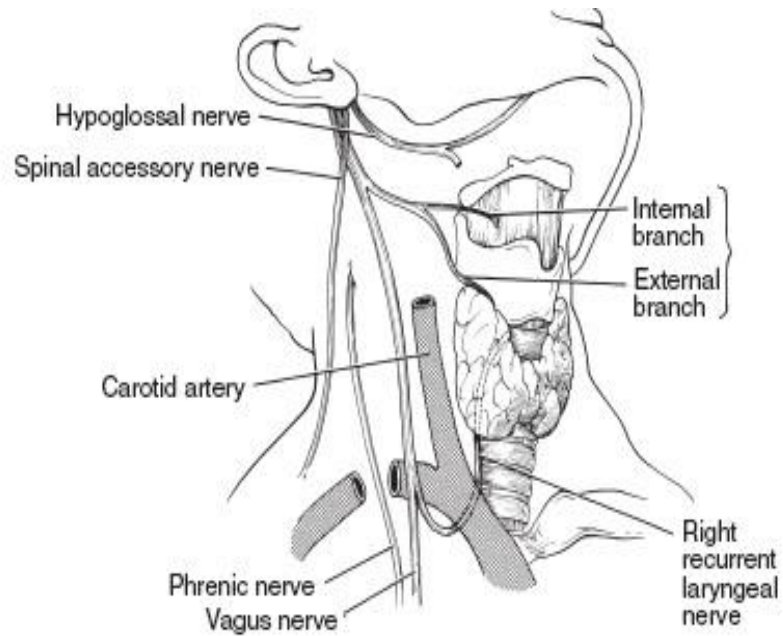
### 2-1-4 Nerve supply

The nerve supply to the thyroid gland is derived from the superior, middle and inferior cervical sympathetic ganglia. These nerve fibers are vasomotor, causing constriction of the blood vessels. The relationship of the thyroid gland and the two vagus nerve branches, the recurrent laryngeal nerve and the external branch of the superior laryngeal nerve, is of major surgical significance because damage to these nerves leads to disability in phonation or to difficulty breathing. The right recurrent laryngeal nerve arises from the vagus nerve, loops around the subclavian artery, and ascends behind the right lobe of the thyroid. It enters the larynx and innervates its intrinsic muscles, which produce the voice and close the laryngeal opening. (Standring, S. (2008))



**Figure 2-8 Nerve supply of thyroid gland**





**Figure 2-9** The left recurrent laryngeal nerve comes from the left vagus nerve, loops around the arch of the aorta, and ascends posterior to the left lobe of the thyroid, where it innervates the muscles of the larynx.

### **2-1-5 Variant anatomy**

#### **Thyroid Gland Variations**

##### **1. Thyroid Glands Without an Isthmus**



**Figure – 2-10**

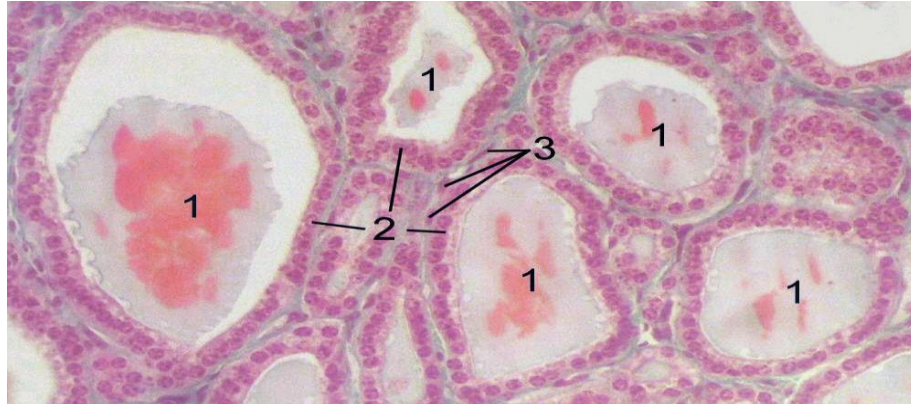
**A** thyroid gland showing bifurcation of the lower end of pyramidal process, one part going to each lateral lobe.

**B** Thyroid gland with pyramidal process attached to left lobe of gland, isthmus absent.

## 2-1-6 Histology

At the microscopic level, there are three primary features of the thyroid, first discovered by GeofferyWebsterson in 1664.( *Fawcett, Don; Jensh, Ronald (2002).*)

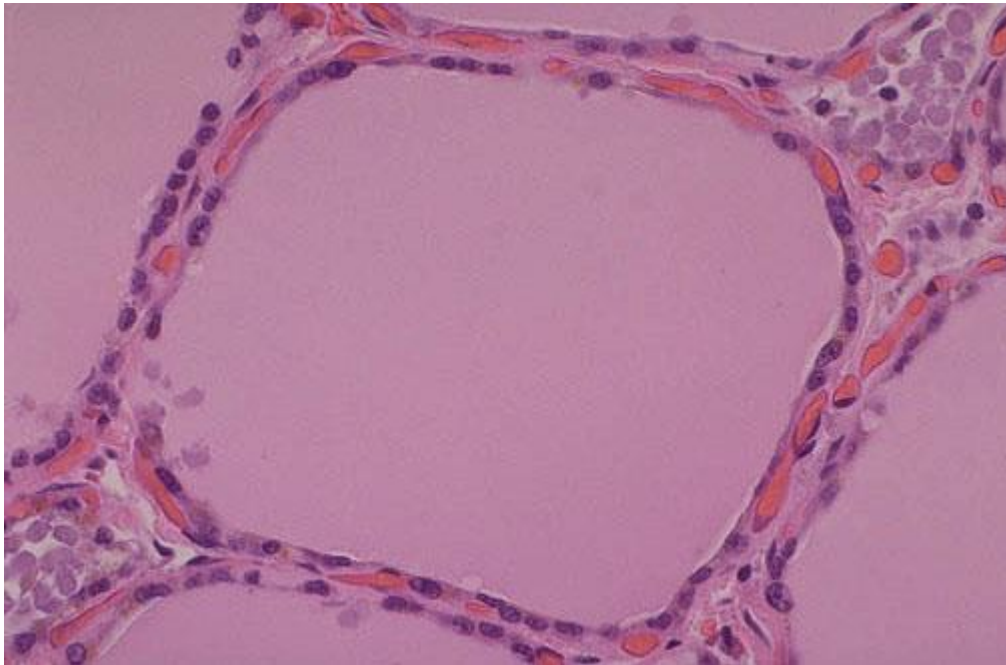### Follicles



**Figure 2-11 Section of thyroid gland under the microscope 1 follicles 2 follicular cells, 3 endothelial cells**

The thyroid is composed of spherical follicles that selectively absorb iodine (as iodide ions,  $I^-$ ) from the blood for production of thyroid hormones, and also for storage of iodine in thyroglobulin. Twenty-five percent of the body's iodide ions are in the thyroid gland. Inside the follicles, in a region called the follicular lumen, colloid serves as a reservoir of materials for thyroid hormone production and, to a lesser extent, acts as a reservoir for the hormones themselves. Colloid is rich in a protein called thyroglobulin.

Follicular cells: The follicles are surrounded by a single layer of follicular cells, which secrete  $T_3$  and  $T_4$ . When the gland is not secreting  $T_3$  and  $T_4$  (inactive), the epithelial cells range from low columnar to cuboidal cells. When active, the epithelial cells become tall columnar cells.



**Figure 2-12** This normal thyroid follicle is lined by a cuboidal follicular epithelium with cells that can add or subtract colloid depending upon the degree of stimulation from TSH (thyroid stimulating hormone) released by the pituitary gland. As in all endocrine glands, the interstitium has a rich vascular supply into which hormone is secreted (<http://library.med.utah.edu/>)

#### Parafollicular cells

Scattered among follicular cells and in spaces between the spherical follicles are another type of thyroid cell, parafollicular cells (also called "C cells"), which secrete calcitonin. .( *Fawcett, Don; Jensch, Ronald (2002).*)



### **2-1-7 Embryology**

The thyroid develops from the 1st and 2nd pharyngeal pouches at the foramen caecum in the midline in the region of tongue in the embryonic period and descends to its final position. (Weissleder R et, al (2011)) (Harnsberger HR, et, al (2006))

In the embryo, at 3–4 weeks of gestation, the thyroid gland appears as an epithelial proliferation in the floor of the pharynx at the base of the tongue between the tuberculum impar and the copula linguae at a point later indicated by the foramen caecum. The thyroid then descends in front of the pharyngeal gut as a bilobed diverticulum through the thyroglossal duct. Over the next few weeks, it migrates to the base of the neck, passing anterior to the hyoid bone. During migration, the thyroid remains connected to the tongue by a narrow canal, the thyroglossal duct.

Thyrotropin-releasing hormone (TRH) and thyroid-stimulating hormone (TSH) start being secreted from the fetal hypothalamus and pituitary at 18-20 weeks of gestation, and fetal production of thyroxine (T4) reach a clinically significant level at 18–20 weeks.[11] Fetal triiodothyronine (T3) remains low (less than 15 ng/dL) until 30 weeks of gestation, and increases to 50 ng/dL at term.[11] Fetal self-sufficiency of thyroid hormones protects the fetus against (e.g., brain development abnormalities caused by maternal hypothyroidism).[12] However, preterm births can suffer neurodevelopmental disorders due to lack of maternal thyroid hormones due their own thyroid being insufficiently developed to meet their postnatal needs. (Berbel P, et, al (2010))

While it was originally thought that the portion of the thyroid containing the parafollicular cells, also known as C cells, responsible for the production of calcitonin, are derived from neural crest, more recent research suggests that c-cells originate from pharyngeal endoderm. This is first seen as the ultimobranchial body, which begins in the ventral fourth pharyngeal pouch and joins the primordial thyroid

gland during its descent to its final location in the anterior neck. (Berbel P, et, al (2010)) (<https://en.wikipedia.org>)

### **2-1-8 Ultrastructure and Histology:**

The gland consists of varying sized follicles, which are bounded by a single layer of cuboidal epithelial cells (follicular cells} and a basement membrane, urrounding a central lumen filled with a homogenous protein rich colloid (thyrogloblin). The apical surface of the cell membranes is covered with numerous micovilli to increase surface area. The follicular cells are connected by tight junctions, and have a dense capillary network. The colloid is a store of thyroid hormones prior to secretion. The thyroid gland is the only endocrine gland to store its hormone in large quantities. In the active gland colloid is diminished and epithelial cells are tall and columnar. Within the connective tissue close to the follicles are C-cells alternatively known as parafollicularcells. They are found in clusters in the interfollicular space and are also known as clear cells as their cytoplasm doesn't stain with H and E. They secrete calcitonin, a hormone which acts to lower plasma  $Ca^{2+}$  levels.(Peccin S, et al. 2005)

## 2.2 Physiology

The thyroid is the largest exclusively endocrine gland in the body. The endocrine system is the body's communication hub, controlling cell, and therefore organ, function. A primary goal of the endocrine system is to maintain homeostasis within the organism, despite external fluctuations of any sort (Frates MC, et al. (2004). The thyroid gland produces the hormones L-thyroxine (T4) and L-triiodothyronine (T3), which regulates metabolic body processes, cellular respiration, total energy expenditure, growth and maturation of tissues, and turnover of hormones, substrates, and vitamins. The primary function of the thyroid is production of the hormones T3, T4 and calcitonin. Up to 80% of the T4 is converted to T3 by organs such as the liver, kidney and spleen. T3 is several times more powerful than T4, which is largely a prohormone, perhaps four or even ten times more active (Boron, WF.; Boulapep, EL. (2012)) .

. Hormones, which act as chemical messengers, are the mechanism for this communication. The two types of hormones secreted by the thyroid gland which are the iodine containing hormones; tri-iodothyronine(T3) and thyroxine (T4), are essential in this process, targeting almost every cell in the body (only the adult brain, spleen, testes, and uterus are immune to their effects.) Inside cells, thyroid hormone stimulates enzymes involved with glucose oxidation, thereby controlling cellular temperature and metabolism of proteins, carbohydrates, and lipids. Through these actions, the thyroid regulates the body's metabolic rate and heat production. Thyroid hormone also raises the number of adrenergic receptors in blood vessels, thus playing a major role in the regulation of blood pressure. In addition, it promotes tissue growth, and is particularly vital in skeletal, nervous system, and reproductive development (Frates MC, et al. (2004).

Follicular cells synthesize thyroglobulin in their Golgi apparatus. This is a glycoprotein consisting of 70 linked tyrosine molecules, 10% of which are iodinated, and is stored in the colloid (Peccin S, et al. 2005).

The thyroglobulin is then split to form the two amino acid derivative hormones produced in the thyroid gland which are triiodothyronine (T3) and thyroxine (T4). Thyroxine contains 4 iodine atoms, triiodothyronine contains 3. Creation of these two hormones is the only role of iodine in the body ((Peccin S, et al. 2005).

The majority (90%) of hormone produced by the follicular cells is T4. T4 can only be made in the thyroid gland. It can then be converted by other tissues into T3.

### **2-2-1 Iodine Uptake**

Iodine circulates within the blood as iodide (I<sup>-</sup>). It is actively transported into the follicular cells by an Na<sup>+</sup>/I<sup>-</sup> symport in the basal membrane. This pump concentrates iodine in the colloid at a level up to 250x greater than the plasma level. This process is known as iodide trapping. The pump is activated by thyroid stimulating hormone (TSH) a hormone from the pituitary gland (Cesur M, et al. (2006).

### **2-2-2 Secretion of Thyroid Hormones**

Colloid uptake into the follicular cells takes place by endocytosis. The intracellular vesicles containing the colloid then fuse with lysosomes, where enzymes split the thyroglobulin into T3 and T4. The hormones diffuse across the basal plasma membrane into the interstitium (they are lipid soluble hormones) (Cesur M, et al. (2006).

### **2-2-3 Transport**

Thyroid hormones are lipid soluble, thus need a transporting protein in order to travel in the blood. Half-life in the blood is 1 day for T3, 6 days for T4. 99% of thyroid hormones in circulation are bound. The primary transport protein for thyroid hormones is thyroid binding globulin (TBG). Synthesized in the liver, this protein binds 70-80% of the circulating thyroid hormones. The remainder are carried by thyroxine-binding prealbumin or albumin (Frates MC, et al. ( 2004).

#### **2-2-4 Degradation**

Only free T3 and free T4 can enter cells to exert their actions. T4 is deiodinated to T3 in many cells of the body, particularly the liver and kidneys. The thyroid secretes 90% T4, with 50% of this being deiodinated to T3. The remainder is converted to reverse T3 (rT3). This is an inactive form of T3, and so creation of it is a regulatory mechanism. More rT3 is created when the body needs to reduce the action of T3 and T4. The hormones are further deiodinated to diiodothyronine and monoiodothyronine in the liver and kidneys. Iodine is recycled or excreted in the urine (Frates MC, et al. (2004).

#### **2-2-5 Regulation**

The hypothalamus releases thyrotropin releasing hormone (TRH) which stimulates the adenohypophysis (anterior pituitary gland) to release thyroid stimulating hormone (TSH). This water soluble hormone travels in the blood to activate the thyroid gland by 5 actions: Increased endocytosis and proteolysis of thyroglobulin from colloid, increased activity of the Na<sup>+</sup>/I<sup>-</sup>-symport, increased iodination of tyrosine, increased size and secretory activity of thyroid follicular cells and increased number of follicular cells (Peccin S, et al. 2005).

#### **2-2-6 Iodide sequestration**

Iodide—the ionized form of iodine—is essential for proper thyroid function. Iodide is taken up by follicular cells through the sodium-iodide symporter (NIS) present on the basolateral membrane, which transports two sodium cations and one iodide ion into the cell. It works against the iodide concentration gradient and uses energy of sodium gradient (maintained by the sodium-potassium pump) and therefore acts by secondary active transport. Thus, NIS help to maintain a 20- to 40-fold difference in iodide concentration across the membrane. (Melmed, S; et, al (2011)). This iodide is transported

to the follicular space through the apical membrane of the follicular cell with the help of the iodide-chloride antiporter pendrin. This iodide is then oxidized to iodine and attached to thyroglobulin by the enzyme thyroid peroxidase to form the precursors of thyroid hormones. (Boron, WF.; Boulapep, EL. (2012))

### **2-2-7 T3 and T4 production and action**

Synthesis of the thyroid hormones, as seen on an individual thyroid follicular cell:

- Thyroglobulin is synthesized in the rough endoplasmic reticulum and follows the secretory pathway to enter the colloid in the lumen of the thyroid follicle by exocytosis.
- Meanwhile, a sodium-iodide (Na/I) symporter pumps iodide (I<sup>-</sup>) actively into the cell, which previously has crossed the endothelium by largely unknown mechanisms.
- This iodide enters the follicular lumen from the cytoplasm by the transporter pendrin, in a purportedly passive manner
- In the colloid, iodide (I<sup>-</sup>) is oxidized to iodine (I<sub>0</sub>) by an enzyme called thyroid peroxidase.
- Iodine (I<sub>0</sub>) is very reactive and iodates the thyroglobulin at tyrosyl residues in its protein chain (in total containing approximately 120 tyrosyl residues).
- In conjugation, adjacent tyrosyl residues are paired together.
- The entire complex re-enters the follicular cell by endocytosis.
- Proteolysis by various proteases liberates thyroxine and triiodothyronine molecules, which enters the blood by largely unknown mechanisms.

Thyroxine (T<sub>4</sub>) is synthesised by the follicular cells from the tyrosine residues of the protein called thyroglobulin (Tg). It has 123 tyrosine residues, but only 4-6 are active. Iodine is captured with the "iodine trap" by the hydrogen peroxide generated by the enzyme thyroid peroxidase (TPO)[21] and linked to the 3' and 5' sites of the benzene ring of the tyrosine residues on Tg sequentially on tyrosine residue forming monoiodotyrosine (MIT) and then diiodotyrosine (DIT) (iodination). Two DIT can couple (coupling) to form T<sub>4</sub> hormone attached to thyroglobulin releasing one alanine.

Upon stimulation by the thyroid-stimulating hormone (TSH), the follicular cells reabsorb Tg and cleave the iodinated tyrosines from Tg in lysosomes, forming free T4, DIT, MIT, T3 and traces of RT3 (in T3 and RT3 has three iodine atom while T4 has four), and releasing T3 and T4 into the blood. Deiodinase releases the sequestered iodine from MIT and DIT. Deiodinase enzymes convert T4 to T3 and RT3,[22] which is a major source of both RT3 (95%) and T3 (87%) in peripheral tissues.[23]Thyroid hormone secreted from the gland is about 80-90% T4and about 10-20% T3.

Cells of the developing brain are a major target for the thyroid hormones T3 and T4. Thyroid hormones play a particularly crucial role in brain maturation during fetal development.[24] A transport protein that seems to be important for T4 transport across the blood–brain barrier(OATP1C1) has been identified. A second transport protein (MCT8) is important for T3 transport across brain cell membranes. (Jansen J, Friesema EC, Milici C, Visser TJ (August 2005).

Non-genomic actions of T4 are those that are not initiated by liganding of the hormone to intranuclear thyroid receptor. These may begin at the plasma membrane or within cytoplasm. Plasma membrane-initiated actions begin at a receptor on the integrin  $\alpha$ V  $\beta$ 3 that activates ERK1/2. This binding culminates in local membrane actions on ion transport systems such as the Na<sup>+</sup>/H<sup>+</sup> exchanger or complex cellular events including cell proliferation. These integrins are concentrated on cells of the vasculature and on some types of tumor cells, which in part explains the proangiogenic effects of iodothyronines and proliferative actions of thyroid hormone on some cancers including gliomas. T4 also acts on the mitochondrial genome via imported isoforms of nuclear thyroid receptors to affect several mitochondrial transcription factors. Regulation of actin polymerization by T4 is critical to cell migration in neurons and glial cells and is important to brain development.

T3 can activate phosphatidylinositol 3-kinase by a mechanism that may be cytoplasmic in origin or may begin at integrin alpha V beta3.

In the blood, T4 and T3 are partially bound to thyroxine-binding globulin (TBG), transthyretin, and albumin. Only a very small fraction of the circulating hormone is free (unbound) - T4 0.03% and T3 0.3%. Only the free fraction has hormonal activity. As with the steroid hormones and retinoic acid, thyroid hormones cross the cell membrane and bind to intracellular receptors ( $\alpha 1$ ,  $\alpha 2$ ,  $\beta 1$  and  $\beta 2$ ), which act alone, in pairs or together with the retinoid X-receptor as transcription factors to modulate DNA transcription. (Bowen, R. (2000).)

### **2-2-8 Thyroid Hormone Actions**

T3 and T4 have effects on all body systems and at all stages of life. These include: Development where thyroid hormones are vital during the fetal period and the first few months after birth. Thyroid hormones also promote growth as they enhance amino acid uptake by tissues and enzymatic systems involved in protein synthesis thus promoting bone growth. They also help with metabolic actions such as carbohydrate metabolism, as thyroid hormones stimulate glucose uptake, glycogenolysis, gluconeogenesis. In fat metabolism they mobilise lipids from adipose stores and accelerate oxidation of lipids to produce energy (occurs within mitochondria), as well as increasing the size and number of mitochondria. Thyroid hormones also increase basal metabolic rate (BMR) in all tissues except brain, spleen and gonads. The results in increased heat production, increased oxygen consumption. This increased metabolic rate also results in increased utilisation of energy substrates causing weight loss. Some of thyroid hormones cardiovascular actions are to increase cardiac output, heart rate and contractility. They affect the respiratory system indirectly through increased BMR causing increased demand for oxygen and increased excretion of carbon dioxide. In the nervous system thyroid hormones are required for myelination of neurons during the



development. They also enhance the sympathetic nervous system (by increasing epinephrine receptors). Reproductive system is affected by reduced levels of thyroid hormone causing irregular cycling and decreased libido. Finally, in the alimentary system, thyroid hormone increases appetite and feed intake, increases secretion of pancreatic enzymes and increases motility (Bellantone R, et al.2004).

### **2.2.9 Function of the thyroid glands:**

The purpose of the thyroid gland is to make, store, and release thyroid hormones into the blood. These hormones, which are also referred to as T3 (lithyronine) and T4 (levothyroxine), affect almost every cell in the body, and help control the body's functions.

### **2.3 Pathophysiology**

The thyroid a butterfly –shaped gland located in the front of the neck just above the trachea. It weights approximately 15 to 20 grams in the adult human . The thyroid produces and releases into the circulation at least two potent hormones , thyroxine (T4) and triiodothyronine (T3) , which influence basal metabolic process and/or enhance oxygen consumption in nearly all body tissues. Thyroid hormones also influence linear growth, brain function including intelligence and memory, neural development , and bone development. (Larsen, 2003).

### **2.4 Pathology**

Thyroid disorder is general term representing several different diseases involving thyroid hormones and the thyroid gland . Thyroid disorder are commonly separated into two major categories, hyperthyroidism and hypothyroidism, depending on whether serum thyroid hormones levels (T4 and T3) are increased or decreased , respectively.

The thyroid gland is prone to several very distinct problems, some of which are extremely common. These problems can be broken down into those concerning the

production of hormone (too much, or too little), those due to increased growth of the thyroid, causing compression of important neck structures or simply appearing as a mass in the neck, the formation of nodules or lumps within the thyroid which are worrisome for the presence of thyroid cancer, and those which are cancerous. Each thyroid topic is addressed separately and illustrated with actual patient x-rays and pictures to make them easier to understand. The information on this web site is arranged to give you more detailed and complex information as you read further.

Thyroid goiter is a dramatic enlargement of the thyroid gland. Goiters are often removed because of cosmetic reasons or, more commonly, because they compress other vital structures of the neck including the trachea and the esophagus making breathing and swallowing difficult. Sometimes goiters will actually grow into the chest where they can cause trouble as well (Cai XJ, et al. (2006).

Hyperthyroidism means too much thyroid hormone. Current methods used for treating a hyperthyroid patient are radioactive iodine, anti-thyroid drugs, or surgery. Each method has advantages and disadvantages and is selected for individual patients. Many times the situation will suggest that all three methods are appropriate, while other circumstances will dictate a single best therapeutic option. Surgery is the least common treatment selected for hyperthyroidism (Cai XJ, et al. (2006).

Hypothyroidism means too little thyroid hormone and is a common problem. In fact, hypothyroidism is often present for a number of years before it is recognized and treated. Hypothyroidism can even be associated with pregnancy. Treatment for all types of hypothyroidism is usually straightforward.

Thyroiditis is an inflammatory process ongoing within the thyroid gland. Thyroiditis can present with a number of symptoms such as fever and pain, but it can also present as subtle findings of hypo or hyper-thyroidism (Cai XJ, et al. (2006).

Thyroid nodules are lumps that commonly arise within an otherwise normal thyroid gland. Often these abnormal growths of thyroid tissue are located at the edge of the

thyroid gland, so they can be felt as a lump in the throat. When they are large or when they occur in very thin individuals, they can even sometimes be seen as a lump in the front of the neck. Thyroid nodules increase with age and are present in almost 10% of the adult population. Autopsy studies reveal the presence of thyroid nodules in 50% of the population, so they are fairly common. 95% of solitary thyroid nodules are benign, and therefore, only 5% of thyroid nodules are malignant. The common types of the benign thyroid nodules are adenomas (overgrowths of normal thyroid tissue), thyroid cysts, and Hashimoto's thyroiditis. Uncommon types of benign thyroid nodules are due to subacute thyroiditis, painless thyroiditis, unilateral lobe agenesis, or Riedel's Struma (Wu HH, Jones JN, 2006).

facts regarding thyroid nodules

One in 12 to 15 young women has a thyroid nodule.

One in 40 young men has a thyroid nodule.

More than 95% of all thyroid nodules are benign (non-cancerous ).

Some are actually cysts, which are filled with fluid rather than thyroid tissue.

Most people will develop a thyroid nodule by the time they are 50 years old.

The incidence of thyroid nodules increases with age.

50% of 50 year olds will have at least one thyroid nodule.

60% of 60 year olds will have at least one thyroid nodule.

70% of 70 year olds will have at least one thyroid nodule.

The Features Favor a Benign Thyroid Nodule are:

Family history of Hashimoto's thyroiditis

Family history of benign thyroid nodule or goiter

Symptoms of hyperthyroidism or hypothyroidism

Pain or tenderness associated with a nodule

A soft, smooth, mobile nodule

Multi-nodular goiter without a predominant nodule (lots of nodules, not one main nodule)

"Warm" nodule on thyroid scan (produces normal amount of hormone)

Simple cyst on an ultrasound

The Following Features Increase the Suspicion of a Malignant Nodule:

Age less than 20

Age greater than 70

Male gender

New onset of swallowing difficulties

New onset of hoarseness

History of external neck irradiation during childhood

Firm, irregular, and fixed nodule

Presence of cervical lymphadenopathy (swollen, hard lymph nodes in the neck)

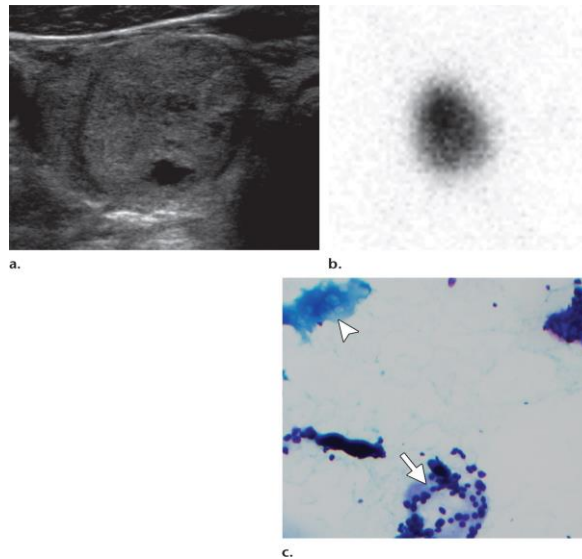
Previous history of thyroid cancer

Nodule that is "cold" on scan (shown in picture above, meaning the nodule does not make hormone)

Solid or complex on an ultrasound

Usually a fine needle aspiration biopsy (FNA) will tell if the nodule is cancerous or benign. This one test can get right to the bottom of the issue. Often an ultrasound is necessary to determine the characteristics of a thyroid nodule.

Solitary Thyroid Nodule: there are several characteristics of solitary nodules of the thyroid which make them suspicious for malignancy. Although as many as 50% of the population will have a nodule somewhere in their thyroid, the overwhelming majority of these are benign. Occasionally, thyroid nodules can take on characteristics of malignancy and require either a needle biopsy or surgical excision (Wu HH, Jones JN, 2006).



**Figure 2-13** Adenomatous nodule in a 66-year-old man (a) Transverse US image shows a predominantly solid 2.4-cm nodule with well-circumscribed margins and a surrounding halo (benign US features).b) Scintigraphic image obtained with <sup>123</sup>I shows increased uptake in a hot nodule and relative photopenia of the adjacent normal thyroid tissue. The outline of the neck is not well visualized. (c) Photomicrograph of an FNAB specimen demonstrates an adenomatous nodule. Features include groups and sheets of bland follicular cells without significant crowding (arrow), with colloid in the background (arrowhead).

Thyroid cancer is a fairly common malignancy, however, the vast majority have excellent long term survival. Thyroid cancer can occur in any age group, although it is most common after age 30, and its aggressiveness increases significantly in older patients. Thyroid cancer does not always cause symptoms; often, the first sign of thyroid cancer is a thyroid nodule.(Bellantone R, et al.2004).

Thyroid cancer types and incidences:

There are 4 main types of thyroid cancer, and some are more common than others.

Papillary and/or mixed papillary/follicular thyroid cancer: ~ 80%, Follicular and/or,

Hurthle cell thyroid cancer: ~ 15%, Medullary thyroid cancer: ~ 3%and Anaplastic

thyroid cancer: ~ 2%.

Most thyroid cancers are very curable. In fact, the most common types of thyroid cancer (papillary and follicular thyroid cancer) are the most curable. In younger patients, both papillary and follicular cancers have a more than 97% cure rate if treated appropriately. Both papillary and follicular thyroid cancers are typically treated with complete removal of the lobe of the thyroid that harbors the cancer, in addition to the removal of most or all of the other side. Medullary thyroid cancer is significantly less common but has a worse prognosis. Medullary cancers tend to spread to large numbers of lymph nodes very early on, and therefore require a much more aggressive operation than the more localized thyroid cancers, such as papillary and follicular thyroid cancer. The least common type of thyroid cancer is anaplastic thyroid cancer, which has a very poor prognosis. Anaplastic thyroid cancer tends to be found after it has spread, and it is incurable in most cases.(Bellantone R, et al.2004).

## Thyroid Pathology

Pathology Imaging By Sonography	Sonographic Characteristics
Adenomas (benign): most common nodule occurring in the thyroid; may be singular or multiple; also commonly seen in the parathyroid glands.	Well-defined round or oval mass that varies from small to very large; varied echogenicity from echogenic, isoechoic to homogenous mass with few internal echoes, resembles a cystic structure; usually solid masses, which of often have an echoic halo, created by blood and edematous tissue compressing the surrounding parenchyma; a halo may also be seen with malignant masses.
Simple cyst, usually developmental, such as thyroglossal duct (located midline anterior to the trachea and brachial cleft (located more laterally).	Anechoic, no internal echoes, smooth, thin well define walls, and increase acoustic through transmission.
Hemorrhagic cyst; usually caused by trauma or degeneration of adenoma.	Cystic mass with irregular borders that may have multiple septations or low-level internal echoes.
Acute thyroiditis; usually found in middle-age women; clinically, the thyroid is enlarged, tender, and the patient has fever.	Defuse enlargement with decrease echogenicity of the lobes; enlargement of the lobes is not symmetrical and the right lobe is usually larger.
Subacute thyroiditis	Diffuse enlargement with decrease echogenicity of the gland
Hashimoto's thyroiditis; most common case of hypothyroidism in young or middle-age women; characteristically, painless diffuse enlargement, of the thyroid gland; treatment includes thyroid hormones.	Inhomogeneous pattern with overall decrease echogenicity of the gland.
Goiter; consists with multiple adenomas and is associated with hyperthyroidism.	In its initial stage; the thyroid is enlarged and may have a normal sonographic pattern, in later stage, may have multiple discrete nodules or diffusely nodular with heterogeneous echo pattern and no normal tissue; nodes may have cystic degeneration and calcification within.
Graves' disease; an autoimmune disease characterized by thyrotoxicosis and is the most common cause of hyperthyroidism.	The thyroid is diffusely enlarged and hypoechoic with an increase vascularity identified by color Doppler.
Carcinoma-80% are papillary; patients may present with difficulty breathing and swallowing with palpable neck mass	Sonography cannot differentiate between a benign and a malignant lesion; malignancies tend to have irregular borders or are poorly defined, the sonographic apperents is varied; the mass may appear small or large, usually singular and hypoechoic; cystic degeneration and focal calcifications may be present.

Charles et al (2012)

## **2-5 Ultrasounds**

### **2-5-1 Basic physics Instrumentation of ultrasound:**

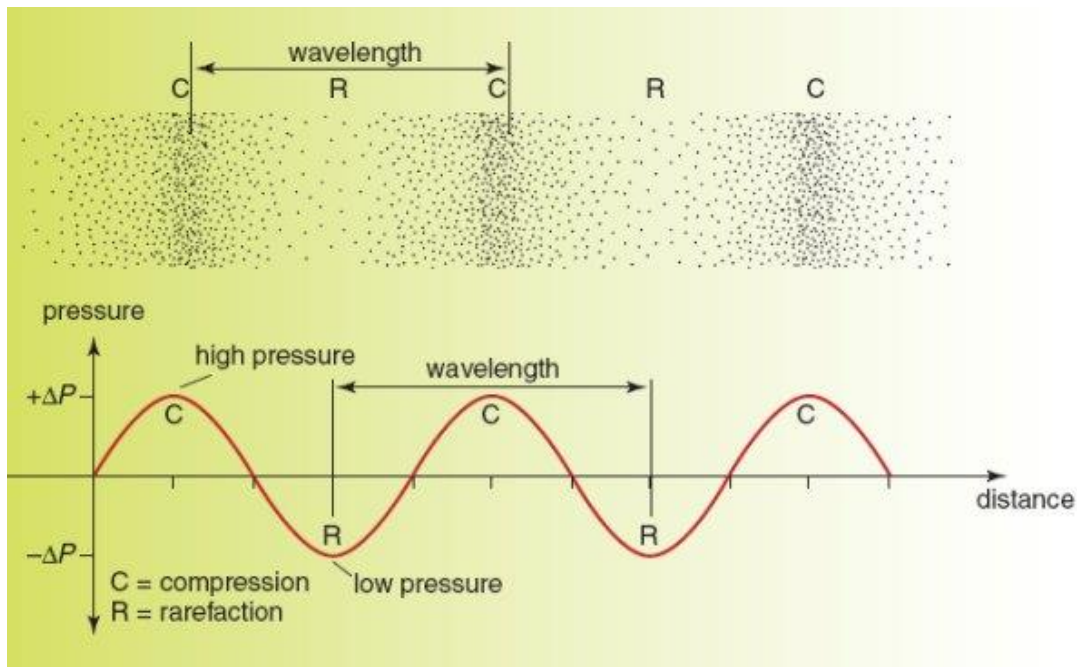
Ultrasound is energy generated by sound waves of 20,000 or more vibrations per second. Ultrasound is used in a large array of imaging tools. Often used for medical diagnostics, ultrasound uses sound waves that are far above the frequency heard by the human ear. A transducer gives off the sound waves and reflected back from organs and tissues, allowing a picture of what is inside the body to be drawn on a screen. Ultrasound can be used to look for tumors, analyze bone structure, or examine the health of an unborn baby. Diagnostic sonography is an ultrasound based diagnostic imaging technique used for visualizing subcutaneous body structures including tendons, muscles, joints, vessels and internal organs for possible pathology or lesions. A renal ultrasound is a safe and painless test that uses sound waves to make images of the kidneys, ureters, and bladder.(Crowin, Elizabeth2008)

Diagnostic ultrasound employs pulsed, high frequency sound waves that are reflected back from body tissues and processed by ultrasound machine to create characteristic images. Ultrasound is a form of mechanical energy which passes in wave form like sound waves and having a frequency waves the same type of wave as detected by the human ear, except the frequency is higher. Ultrasonic imaging uses frequencies in the range from 1 to 20 MHz at powers from 0.01 to200 mW/cm<sup>2</sup>. (Oak Brook, IL, et.al, 2000)

The ultrasound is generated and received by piezoelectric transducers. Ultrasound can be aimed in a specific direction and obeys the laws of geometric optics with regard to reflection, transmission and refraction. When an ultrasound wave meets an interface of differing echogenicity, the wave is reflected, refracted and absorbed. Only reflected sound waves (echoes) can be sensed by the transducer and processed to generate an



Image. The transducer acts as a receiver over 99% of the time.( Oak Brook, IL, et.al, 2000)



**Figure 2-14 :** Ultrasound waves.

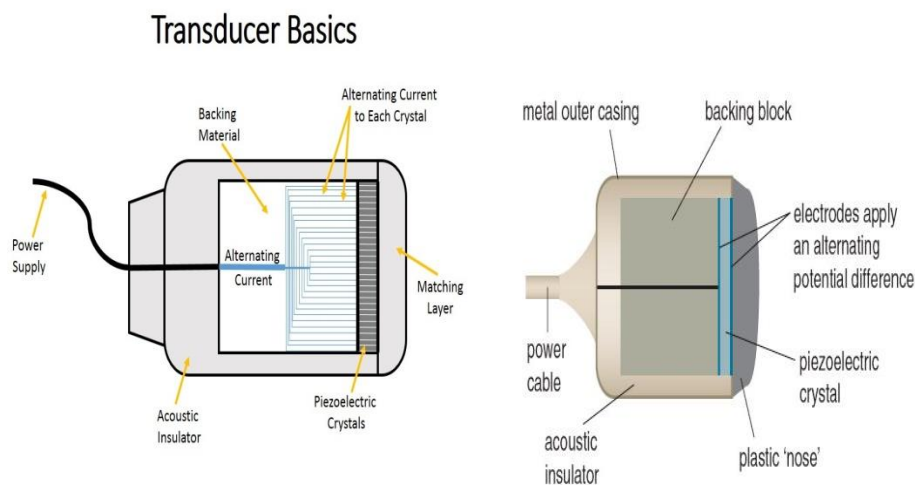
### 2-5-2 Transducer:

Transducers convert electrical energy into mechanical energy to produce ultrasound and vice versa. The part of the transducer which does this work is a piezo electric crystal. It can be synthetic or natural. They have an inherent property of vibrating when an electric current is applied and thus produce ultrasonic waves and conversely produce electric impulse when vibrated thus helping the acquisition of data for the formation of image. This effect is called "Piezoelectric effect". (TX, D. Armstrong 1996).

Quartz is a naturally occurring piezoelectric crystal. Synthetic ones are prepared from ceramics like lead zirconate and lead titanate. (Oak Brook, IL, et.al, 2000).

The range of the velocities of ultrasound in body tissues is fortunately limited, so that time of return of an echo is a reliable indication of depth. Small variations give rise to geometrical distortions (Oak Brook, IL, et.al, 2000).

Different tissues have different attenuation coefficients and this determines the quantum of reflection. This property has helped in imaging, tissue characterization and appropriate diagnosis. The greater the mismatch in acoustic impedance between two adjacent tissues the more reflective will be their boundary. (TX, D. Armstrong 1996).



**Figure2- 15** Ultrasound transducer.

### **2-5-3 Modes of display in ultrasonography**

Static imaging modes:

1-A mode. (Amplitude modulation)

2-B mode. (Brightness Modulation)

Dynamic imaging modes:

3-M mode. (Motion M-mode)

4-Real time B mode

### **2-5-3 Real time ultrasound:**

B-Scan produces a single image frame. A real time ultrasound transducer produces multiple images in a very short time i.e., at least 16 or more images (frames) per second, which gives us a impression as though we are seeing the moving structures in

real. This quick presentation of images is possible by oscillating the piezoelectric crystals (TX, D. Armstrong 1996).

#### **2-5-4 Doppler Basics**

Doppler imaging can determine the presence and the direction of blood flow. The movement of the blood cells toward the transducer compresses the sound waves and creates shorter wavelengths and higher frequencies than those emitted by the transducer and called a positive shift or red shift (W, Popper A, 2000).

The movement of the blood cells away from the transducer expands the sound waves and creates a longer wavelengths and lower frequencies than those emitted by the transducer which is called a negative shift or Blue shift (W, Popper A, 2000).

#### **2-5-4 Ultrasound Artifacts:**

Artifacts are echoes that appear on the image that do not correspond in location or intensity to actual interfaces in the patient.

They can be of two types a Good Artifacts - which are helpful and bad Artifacts - which are disturbing

Good Artifacts like Acoustic shadowing, Acoustic enhancement and Comet tail

Bad Artifacts: Refraction, Reverberation, Mirror Image artifacts, Beam width artifacts, Movement artifacts and Operator pressure artifacts.

Sonography provides important clinical information regarding the presence of a thyroid nodule, its internal consistency, and number of lesions. High-frequency transducers provide detailed depiction of the relative size, location, border, and vascularity with color Doppler sonography. There are certain parameters that the sonographer should document such as Size , Location, Borders , Internal consistency and Cervical lymphadenopathy. (Charles S. Odwin, et al (2012))

Sonographers should also be aware of certain “classic patterns” that allow characterization of thyroid nodules. These patterns can be divided with those that

require fine needle aspiration (FNA) biopsy and those that usually do not need FNA. . (Charles S. Odwin, et al (2012))

Findings usually requiring FNA include

Nodules containing micro calcifications—these are usually papillary cancers.

Hyperechoic solid nodules with coarse calcification or echogenic foci—these can also be seen in medullary and papillary cancers or rarely in benign lesions. These nodules should undergo FNA.

Solid nodule with peripheral calcifications—these are usually benign follicular adenomas but may need resection for histologic evaluation.

Nodules with edge shadowing—this may arise from a fibrous capsule of a thyroid cancer.

Findings that usually do not require FNA include:

Nodules containing echogenic foci with “ring-down” artifact—these usually correspond to condensed colloid within a benign nodule.

Nodules containing “honeycomb” pattern—these are typical of a benign colloid adenoma. • Cystic nodules are typically benign.

Multiple hypoechoic foci—these are typical of chronic lymphocytic (Hashimoto’s) thyroiditis. . (Charles S. Odwin, et al (2012))

The sonographer should also document the size, shape, and morphology of cervical lymph nodes. Abnormal findings include enlargement (>6 mm height), hypoechoic areas, and microcalcification. Papillary thyroid cancers can be associated with spread to lymph nodes. “Reactive” lymph nodes can also be seen with neck inflammation.

Sonographers may also assist in guided FNA of one or more abnormal thyroid masses.

The interested reader is referred to the article below for further discussion of the various sonographic features of thyroid nodules.( Charles S. Odwin, et al (2012))

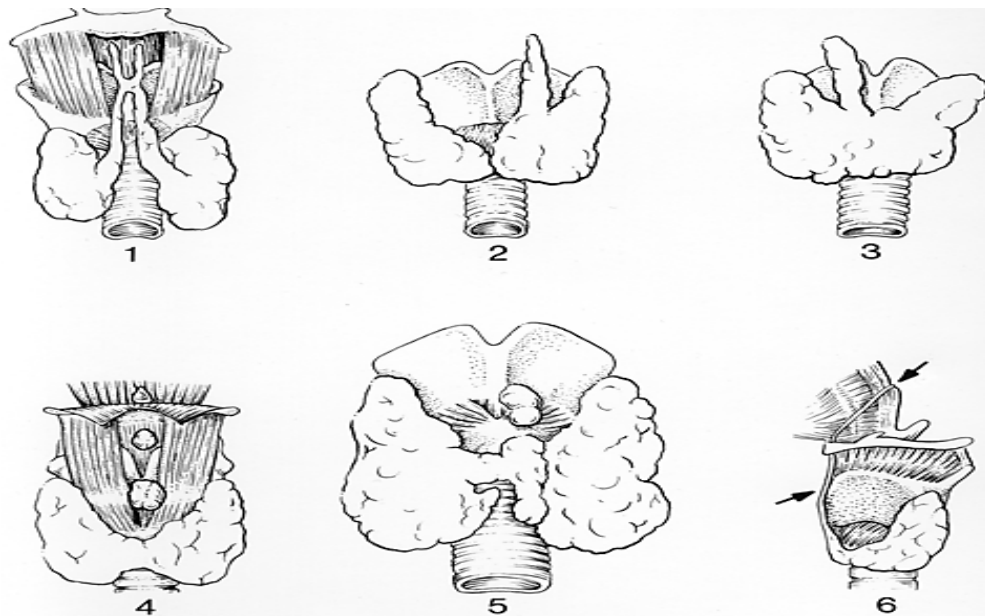
Radiographic appearance

Ultrasound

normal thyroid gland has an homogenous appearance, the capsule may appear as a thin hyperechoic line

each lobe normally measures 4:

- length: 4-7 cm
- depth: <2 cm
- isthmus measures <0.5 cm deep (*Machi J, Staren ED, (2005)*)



**Figure 2-16** Thyroid Gland Variations, Accessory Thyroids, Thyroglossal Duct

1 Absence of thyroid isthmus. Lateral lobes each have pyramidal lobes

2 Pyramidal lobe arising from the union of the left lobe at the isthmus

3 Pyramidal lobe arising from the isthmus of the gland

4 Accessory thyroids may be located on the trachea, thyroid cartilage, thyrohyoid

muscle, geniohyoid muscle, and hyoid bone, under and above the hyoid bone

5 Accessory thyroid gland on cricothyroid muscle. Pyramidal lobe reduced to left interior part of the isthmus

6 Persistent thyroglossal duct in an adult, originating at the foramen cecum of the tongue. (<http://www.anatomyatlases.org/>)

Nodules of the thyroid may or may not be cancer. Medical ultrasonography can help determine their nature because some of the characteristics of benign and malignant nodules differ. The main characteristics of a thyroid nodule on high frequency thyroid ultrasound are as follows:

Possible cancer	Benign characteristics
irregular border	smooth borders
hypoechoic (less echogenic than the surrounding tissue)	hyperechoic
microcalcifications	-
taller than wide shape on transverse study	-
significant intranodular blood flow by power Doppler	-
-	"comet tail" artifact as sound waves bounce off intranodular colloid

Ultrasonography is not always able to separate benign from malignant nodules with complete certainty. In suspicious cases, a tissue sample is often obtained by biopsy for microscopic examination.

## 2-6 Nuclear medicine

Nuclear medicine is a medical specialty involving the application of radioactive substances in the diagnosis and treatment of disease. In nuclear medicine procedures, radionuclides are combined with other elements to form chemical compounds, or else combined with existing pharmaceutical compounds, to form radiopharmaceuticals. These radiopharmaceuticals, once administered to the patient, can localize to specific organs or cellular receptors. This property of radiopharmaceuticals allows nuclear medicine the ability to image the extent of a disease process in the body, based on the cellular function and physiology, rather than relying on physical changes in the tissue anatomy. (Crowin, Elizabeth2008)

A typical nuclear medicine study involves administration of a radionuclide into the body by intravenous injection in liquid or aggregate form, ingestion while combined with food, inhalation as a gas or aerosol, or rarely, injection of a radionuclide that has undergone micro-encapsulation. Some studies require the labeling of a patient's own blood cells with a radionuclide (leukocyte scintigraphy and red blood cell scintigraphy). Most diagnostic radionuclides emit gamma rays, while the cell-damaging properties of beta particles are used in therapeutic applications. Refined radionuclides for use in nuclear medicine are derived from fission or fusion processes in nuclear reactors, which produce radionuclides with longer half-lives, or cyclotrons, which produce radionuclides with shorter half-lives, or take advantage of natural decay processes in dedicated generators, i.e. molybdenum/technetium or strontium/rubidium. The most commonly used radionuclides are technetium-99m (technetium-99m), Iodine-123, 131, Thallium-201, Gallium-67, Fluorine-18 Fluorodeoxyglucose, Indium-111 Labeled Leukocytes, Xenon-133 and Krypton-81m. (Crowin, Elizabeth2008)

S0 It is uses small amounts of radioactive material to diagnose and determine the severity of or treat a variety of diseases, including many types of cancers, heart disease, gastrointestinal, endocrine, neurological disorders and other abnormalities within the body. It is used in Nephro-Urology since 1960s. Nuclear medicine Studies offer both functional and anatomical information. (Fred A.Mettler.2012).

Nuclear scanning of the thyroid was frequently done in the past to evaluate thyroid nodules. However, use of thyroid ultrasound and biopsy have proven so accurate and sensitive, nuclear scanning is no longer considered a first-line method of evaluation.

Nuclear scanning still has an important role in the evaluation of rare nodules that cause hyperthyroidism. In this situation, the nuclear thyroid scan may suggest that no further evaluation or biopsy is needed. In most other situations, neck ultrasound and biopsy remain the best and most accurate way to evaluate all types of thyroid nodules

The limitations of General Nuclear Medicine: Nuclear medicine procedures can be time consuming. It can take several hours to days for the radiotracer to accumulate in the body part of interest and imaging may take up to several hours to perform, though in some cases, newer equipment is available that can substantially shorten the procedure time.

The resolution of structures of the body with nuclear medicine may not be as high as with other imaging techniques, such as CT or MRI. However, nuclear medicine scans are more sensitive than other techniques for a variety of indications, and the functional information gained. There are no contra indications. (Fred A.Mettler.2012)



### **2.6.1 Techniques**

2D Scintigraphy - use of internal radionuclides to create two-dimensional images, 3D SPECT - tomographic technique using gamma camera data from many projections and reconstructed in different planes and HYBRID SCAN - SPECT/CT and PET/CT.

A thyroid scan can be used to evaluate abnormalities found in a physical exam or laboratory test. The images from this test can be used to diagnose:

- lumps, nodules (cysts), or other growths
- inflammation or swelling
- an overactive thyroid, or hyperthyroidism
- an underactive thyroid, or hypothyroidism
- goiter, which is an abnormal enlargement of the thyroid
- thyroid cancer
- An RAIU evaluates the function of the thyroid gland.

Limitations for thyroid scan are: Definitive diagnosis not possible and rarely cold nodule retains its ability to trap  $Tc^{99m}O_4^-$  pertechnetate and appears as a hot nodule on the scan

#### **2-6-2 Thyroid scans procedure**

Patient lie down on an examination table for a thyroid scan. Neck is extended. With scanner or camera to take images of thyroid, usually from at least three different angles. The process takes about 30 minutes.

RAIU procedure An RAIU (The radioactive iodine uptake) is performed 6 to 24 hours after taking the radionuclide. Patients will sit upright in a chair for this test. The technologist will place a probe over patients thyroid gland, where it will measure the radioactivity present. This test takes several minutes.

Patient will return to the nuclear medicine department to have another set of readings taken 24 hours after the first test. This allows the doctor to determine the amount of thyroid hormone produced between the two tests.

Metastatic survey procedure: A metastatic survey is a type of thyroid scan. It's usually reserved for people with thyroid cancer. It can determine whether thyroid cancer has spread by detecting where the iodine is absorbed. The procedure is typically performed after thyroid surgery and ablation, or removal. It can identify pieces of the thyroid that remain after surgery.

## **2-6- Nuclear medicine findings**

A normal thyroid scan would show no abnormalities in the size, shape, and location of the thyroid gland. The thyroid will have an even green color on the image. Red spots on the image indicate abnormal growths in the thyroid. Normal results from a metastatic scan indicate an absence of thyroid tissue and no spread of thyroid cancer. An abnormal thyroid scan may show a thyroid that's enlarged or out of position, indicating a possible tumor. Abnormal measurements also may show that thyroid gland collected too much or too little of the radionuclide.

Abnormal results of a thyroid scan may also indicate:

colloid nodular goiter, which is a type of thyroid enlargement due to too little iodine

Graves' disease, which is a type of hyperthyroidism

painless thyroiditis, which can involve switching between hyperthyroidism and hypothyroidism

toxic nodular goiter, which is an enlargement of a nodule on an existing goiter  
RAIU (The radioactive iodine uptake) results

Abnormally high levels of thyroid hormone may indicate:

the early stage of Hashimoto's thyroiditis, which is a chronic swelling of the thyroid  
factitious hyperthyroidism, which is an overactive thyroid caused by taking too much  
thyroid medication

hyperthyroidism

goiter

Abnormally low levels of thyroid hormone may indicate: hypothyroidism, iodine  
overload, subacute thyroiditis, which is an inflammation of the thyroid gland caused by  
a virus and thyroid nodules or goiter.

#### **2-6-4 Computed Tomography (CT)**

CT provides exquisite anatomical details and is able differentiate between types  
of masses based on differences in their radio density. The disadvantages of CT are is  
expensive and ionizing radiation may be concern with young children or pregnant  
patient, and contrast collection and excretion relay on renal function.

## **2-7 Thyroid Investigations**

### **Blood tests**

The measurement of thyroid-stimulating hormone (TSH) levels is often used by doctors as a screening test. Elevated TSH levels can signify an inadequate thyroid hormone production, while suppressed levels can point at excessive unregulated production of hormone.

If TSH is abnormal, decreased levels of thyroid hormones T4 and T3 may be present; T4 and T3 levels may be determined with blood tests to confirm that their levels are decreased.

Autoantibodies may be detected in various disease states (anti-TG, anti-TPO, TSH receptor stimulating antibodies).

There are two cancer markers for thyroid derived cancers. Thyroglobulin (TG) for well differentiated papillary or follicular adenocarcinoma, and the rare medullary thyroid cancer has calcitonin as the marker.

Very infrequently, TBG and transthyretin levels may be abnormal; these are not routinely tested.

To differentiate between different types of hypothyroidism, a specific test may be used. Thyrotropin-releasing hormone (TRH) is injected into the body through a vein. This hormone is naturally secreted by the hypothalamus and stimulates the pituitary gland. The pituitary responds by releasing thyroid -stimulating hormone (TSH). Large amounts of externally administered TRH can suppress the subsequent release of TSH. This amount of release-suppression is exaggerated in primary hypothyroidism, major depression, cocaine dependence, amphetamine dependence and chronic phencyclidine

abuse. There is a failure to suppress in the manic phase of bipolar disorder. ( *Giannini AJ, Malone DA, Loiselle RH, Price WA (1987)*) Ultrasound

### **Radioiodine scanning and uptake**

Thyroid scintigraphy, imaging of the thyroid with the aid of radioactive iodine, usually iodine-123 (<sup>123</sup>I), is performed in the nuclear medicine department of a hospital or clinic. Radioiodine collects in the thyroid gland before being excreted in the urine. While in the thyroid the radioactive emissions can be detected by a camera, producing a rough image of the shape (a radiiodine scan) and tissue activity (a radioiodine uptake) of the thyroid gland.

A normal radioiodine scan shows even uptake and activity throughout the gland. Irregularity can reflect an abnormally shaped or abnormally located gland, or it can indicate that a portion of the gland is overactive or underactive, different from the rest. For example, a nodule that is overactive ("hot") to the point of suppressing the activity of the rest of the gland is usually athyrototoxic adenoma, a surgically curable form of hyperthyroidism that is hardly ever malignant. In contrast, finding that a substantial section of the thyroid is inactive ("cold") may indicate an area of non-functioning tissue such as thyroid cancer.

The amount of radioactivity can be counted as an indicator of the metabolic activity of the gland. A normal quantitation of radioiodine uptake demonstrates that about 8 to 35% of the administered dose can be detected in the thyroid 24 hours later. Over activity or underactivity of the gland as may occur with hypothyroidism or hyperthyroidism is usually reflected in decreased or increased radioiodine uptake. Different patterns may occur with different causes of hypo- or hyperthyroidism.

## **Biopsy**

A medical biopsy refers to the obtaining of a tissue sample for examination under the microscope or other testing, usually to distinguish cancer from noncancerous conditions. Thyroid tissue may be obtained for biopsy by fine needle aspiration or by surgery.

Needle aspiration has the advantage of being a brief, safe, outpatient procedure that is safer and less expensive than surgery and does not leave a visible scar. Needle biopsies became widely used in the 1980s, but it was recognized that accuracy of identification of cancer was good but not perfect. The accuracy of the diagnosis depends on obtaining tissue from all of the suspicious areas of an abnormal thyroid gland. The reliability of needle aspiration is increased when sampling can be guided by ultrasound, and over the last 15 years, this has become the preferred method for thyroid biopsy in North America. ([https://en.wikipedia.org/wiki/Thyroid\\_disease](https://en.wikipedia.org/wiki/Thyroid_disease)).

## **Advanced Ultrasound Technique In Thyroid Imaging**

Ultrasound elastography is a dynamic technique that estimates stiffness of tissues by measuring the degree of distortion under external pressure. Thyroid gland elastography is used to study hardness/elasticity of the thyroid nodule to differentiate malignant from benign lesions. A benign nodule is softer and deforms more easily, whereas the malignant nodule is harder and deforms less when compressed by ultrasound probe. The elastography technique utilizes external compression to differentiate malignant thyroid nodules from benign lesions. It determines the amount of tissue displacement at various depths, by assessing the ultrasound signals reflected from the tissues before and after compression. Dedicated software then provides an accurate measurement of tissue distortion and displays it visually as an elastographic image. The elastographic image (elastogram) displayed over the B-mode image in a color scale, indicates local tissue elasticity as (i) very soft in blue color for tissue with

greatest elastic strain and (ii) very hard in red color for tissue with no strain. Real-time shear elastography is a latest technique; that characterizes and quantifies tissue stiffness better than conventional elastography. Cystic lesions and calcified nodules are excluded from US elastographic evaluation. US elastography helps in characterizing a cytologically indeterminate nodule as malignant or benign with high accuracy that is almost comparable to FNAC and obviates the need of unnecessary FNA examination. The major limitation of US elastography is that it cannot assess the lesions which are not surrounded by adequate normal tissue .

Contrast-enhanced ultrasound (CE-US) is a newly developed technique that helps in characterizing a thyroid nodule. On CE-US, enhancement patterns are different in benign and malignant lesions. Ring enhancement is predictive of benign lesions, whereas heterogeneous enhancement is helpful for detecting malignant lesions. However, overlapping findings seem to limit the potential of this technique in the characterization of thyroid nodules.[Use of specific contrast (e.g. SonoVue) and pulse inversion harmonic imaging further improves the efficacy of ultrasound in diagnosing a malignant thyroid nodule. (*Vikas Chaudhary and Shahina Bano,2013*)

## **2-8 Treatment**

### **Medical treatment**

Levothyroxine is a stereoisomer of thyroxine which is degraded much slower and can be administered once daily in patients with hypothyroidism. Natural thyroid hormone from pigs is also used, especially for people who cannot tolerate the synthetic version. Graves' disease may be treated with the thioamide drugs propylthiouracil, carbimazole or methimazole, or rarely with Lugol's solution. Hyperthyroidism as well as thyroid tumors may be treated with radioactive iodine.

Percutaneous Ethanol Injections, PEI, for therapy of recurrent thyroid cysts and metastatic thyroid cancer lymph nodes is an alternative to the usual surgical method.

### **Surgery**

Thyroid surgery is performed for a variety of reasons. A nodule or lobe of the thyroid is sometimes removed for biopsy or for the presence of an autonomously functioning adenoma causing hyperthyroidism. A large majority of the thyroid may be removed, a subtotal thyroidectomy, to treat the hyperthyroidism of Graves' disease, or to remove a goitre that is unsightly or impinges on vital structures.

A complete thyroidectomy of the entire thyroid, including associated lymph nodes, is the preferred treatment for thyroid cancer. Removal of the bulk of the thyroid gland usually produces hypothyroidism, unless the person takes thyroid hormone replacement. Consequently, individuals who have undergone a total thyroidectomy are typically placed on thyroid hormone replacement for the remainder of their lives. Higher than normal doses are often administered to prevent recurrence. ([https://en.wikipedia.org/wiki/Thyroid\\_disease](https://en.wikipedia.org/wiki/Thyroid_disease))



If the thyroid gland must be removed surgically, care must be taken to avoid damage to adjacent structures, the parathyroid glands and the recurrent laryngeal nerve. Both are susceptible to accidental removal and/or injury during thyroid surgery. The parathyroid glands produce parathyroid hormone (PTH), a hormone needed to maintain adequate amounts of calcium in the blood. Removal results in hypoparathyroidism and a need for supplemental calcium and vitamin D each day. In the event the blood supply to any one of the parathyroid glands is endangered through surgery, the parathyroid gland(s) involved may be re-implanted in surrounding muscle tissue. The recurrent laryngeal nerves provide motor control for all external muscles of the larynx except for the cricothyroid muscle, which also runs along the posterior thyroid. Accidental laceration of either of the two or both recurrent laryngeal nerves may cause paralysis of the vocal cords and their associated muscles, changing the voice quality. (Gharib H, Tuttle RM, Baskin HJ, Fish LH, Singer PA, McDermott MT (2004))

### **Radioiodine therapy**

Iodine therapy with iodine-131 can be used to shrink the thyroid gland (for instance, in the case of Large goiters that cause symptoms but do not harbor cancer, after evaluation and biopsy of suspicious nodules, can be treated by an alternative therapy with radioiodine. The iodine uptake can be high in countries with iodine deficiency, but low in iodine sufficient countries. The 1999 release of recombinant human TSH, Thyrogen, in the USA, can boost the uptake to 50-60% allowing the therapy with Iodine 131. The gland shrinks by 50-60% but can cause hypothyroidism and rarely pain syndrome, which arises due to radiation thyroiditis.

([https://en.wikipedia.org/wiki/Thyroid\\_disease](https://en.wikipedia.org/wiki/Thyroid_disease)).

## **2.9 Previous Studies**

In reviewing of literature in locally and internationally there are some published studies regarding the thyroid disorders by many researchers

Sharma et al (2007) reported the Role of <sup>99m</sup>Tc-Tetrofosmin delayed scintigraphy and color Doppler sonography in characterization of solitary thyroid nodules. A study evaluated the diagnostic efficiency of Tc-Tetrofosmin scan and color Doppler in the characterization of benign and malignant solitary thyroid nodules. Fifty-two patients found to have a cold solitary thyroid nodule on Tc-Perchnetate scintigraphy were included in this study. They found that The Doppler study was able to demonstrate increased vascularity in the center of 8 of the 15 malignant nodules. Thirty-two patients harboring a benign solitary nodule showed normal or increased peripheral vascularity on Doppler study. Sensitivity, specificity, positive predictive value and negative predictive value of color Doppler were found to be 53.5, 86.4, 61.5 and 82%, respectively. Delayed Tc-Tetrofosmin scintigraphy is a highly sensitive and specific method for characterizing solitary thyroid nodules, while color Doppler has a low sensitivity but relatively high specificity in differentiating benign from malignant thyroid lesions.

Kresnik et al (2000) assessed Scintigraphic and ultrasonographic appearance in different tumor stages of thyroid carcinoma. The study was compared the Scintigraphic pattern in different tumor stages of thyroid carcinoma. They found that planar <sup>99m</sup>Tc-perchnetate scintigraphy is of little value in evaluating small thyroid nodules. In order to diagnose small thyroid nodules, ultrasonography and ultrasonographically guided FNAB should be recommended as the initial diagnostic steps in clinical routine.

Park et al (2009) assessed Sonography of thyroid nodules with peripheral calcifications. This study assessed the role of sonography (US) in the differentiation of benign from

malignant thyroid nodules with peripheral calcifications. Sixty-four thyroid nodules with peripheral calcifications that were detected on US were included in the study. Nineteen nodules (30%) were benign, and 45 nodules (70%) were malignant. They retrospectively compared the US findings of the benign and malignant nodules, including interruption, thickening ( $\geq 0.5$  mm and over more than 50% of the circumference) of calcifications, internal echogenicity, margin, and presence of cystic change, size, and shape.

Univariate and multivariate (2009) logistic regression analyses were performed. Interruption of peripheral calcifications was more common in malignant nodules (84%) than in benign nodules (53%) (OR, 7.9; 95% CI, 1.3-48.4;  $p < 0.05$ ). Thickening of the peripheral calcification was seen more frequently in malignant nodules (64%) than in benign nodules (11%) (OR, 14.7; 95% CI, 1.8-117.5;  $p < 0.05$ ). For internal echogenicity, malignant nodules (58%) were more often hypoechoic than benign nodules (OR, 23.6; 95% CI, 2.2-256.3;  $p < 0.01$ ). The mean tumor size was 1.1 cm for malignant nodules and 1.2 cm for benign nodules ( $p > 0.05$ ). There were no significant differences for the presence or absence of cystic change, size, shape, and margin between malignant and benign nodules. Interruption and thickening of peripheral calcifications and decreased internal echogenicity of a thyroid nodule with peripheral calcifications are in favor of malignancy.

Popowicz et al (2009) assessed The usefulness of sonographic features in selection of thyroid nodules for biopsy in relation to the nodule's size. The study evaluated the efficacy of selected ultrasound (US) features of thyroid focal lesions useful for establishing indications for fine-needle aspiration biopsy (FNAB) with regard to the lesion's size. US imaging features of 1141 thyroid nodules (shape, echogenicity, pattern of blood flow, presence of microcalcifications and the presence of other nodules in the thyroid) and their palpability were compared with the post-operative histopathological outcomes. The efficacy of the selected sets of the features was

assessed for small nodules (SN) $<$  or  $=$ 15 mm and large nodules (LN) $>$ 15 mm, as well as separately for nodules $<$  or  $=$ 10 mm. Logistic regression analysis showed that in SN hypoechogenicity (odds ratios, OR: 3.18), microcalcifications (OR: 19.12), solitary occurrence (OR: 3.29) and height-to-width ratio $>$  or  $=$ 1 (OR: 8.57) were independent risk factors for malignancy. The optimal set of small lesions that should be biopsied includes all lesions presenting at least one of the above-mentioned features (sensitivity 98%, specificity 44%). In the LN group, the selection criteria based on the shape of lesions and hypoechogenicity were less sensitive than in the SN group, but they allowed further reduction in the number of performed FNABs. Large nodules primarily selected for FNAB should be hypoechoic, more tall than wide or contain microcalcifications (sensitivity 84%, specificity 72%). The obtained results provide rationale for using features from the US examination in selecting both small and large nodules for FNAB. In the case of LN, the usefulness of sonographic features is less sensitive, but more specific than in the case of SN.

Gul et al (2009) assessed the role of Ultrasonographic in evaluation of thyroid nodules: comparison of ultrasonographic, cytological, and histopathological findings. A total of 3,404 nodules in 2,082 cases referred to our clinic between 2005 and 2008 were analyzed retrospectively. Considering US features of nodules, risk factors predicting malignancy were: margin irregularity as the most important predictor, hypoechoic pattern and microcalcification (Odds ratios: 63.2, 13.3, 7.03, respectively). Cytologic results of the patients were as follows: 1,718 (82.5%) benign, 196 (9.4%) suspicious, 68 (3.3%) nondiagnostic and 100 (4.8%) malignant. In histopathologic examination, they determined a malignancy rate of 7.59% (158/2082). they calculated the sensitivity of FNAB as 89.16%, specificity as 98.77%, positive predictive value as 96.10%, negative predictive value as 96.39%, and accuracy as 96.32%. In cytologic examination, the malignancy rate of subcentimetric ( $\leq$ 1 cm) nodules was higher than supracentimetric ( $>$ 1 cm) nodules (5.1% vs. 1.5%,  $P = 0.001$ ). In postoperative

histopathologic examination, although the malignancy rate of subcentimetric nodules was higher than that of supracentimetric nodules, the difference was statistically insignificant (5.5%, 4.4%, respectively;  $P > 0.05$ ). Cytologically diagnosed malignancy was detected in 4.5% of patients with multiple nodules, while it was present in 6% of patients with solitary nodule indicating no significant difference. However, postoperative histopathologic examination revealed a significantly higher malignancy rate in patients with solitary nodule compared to in patients with multiple nodules (11.7%, 6.5%; respectively,  $P < 0.001$ ). The malignancy rate of patients operated for suspicious cytology was found to be 46.15%; for nondiagnostic cytology, it was 64.29%. In conclusion, ultrasonographically, hypoechoic pattern, microcalcification and margin irregularity of thyroid nodules are important features in determining the malignancy risk. The nodule size alone still remains inadequate to exclude malignancy risk.

Sohaib et al (2007) evaluated Correlation of Single Image Tc-99m MIBI Scan and Ultrasonography with Fine Needle Aspiration Cytology (FNAC) to assess Neoplasia in Solitary “Cold” Thyroid Nodules evaluated the utility of Tc-99m labeled Hexakis2-methoxyisobutyl isonitrile (Tc-99m MIBI) in differentiating neoplastic from non-neoplastic lesions among nodules which are cold on Tc-99m Pertechnetate scan and solid or mixed on ultrasonography. Forty-nine patients, all having solitary cold nodules on Tc-99m Pertechnetate scans were included in the study. All underwent ultrasonography, Tc- 99m MIBI scan and FNAC. Ultrasound findings were categorized as solid, mixed and cystic. Anterior images of thyroid were acquired 15 minutes after intravenous injection of Tc-99m MIBI. The thyroid nodules were classified into 5 categories depending on the degree of MIBI uptake. They were; Category-1 showing intense uptake, Category -2 showing slightly higher uptake than the surrounding normal thyroid tissue, Category - 3 with uptake equal to the normal thyroid, Category -4 showing less uptake than the surrounding normal tissue and

Category -5 showing no or negligible uptake of Tc-99m MIBI. Receiver Operating Characteristic (ROC) curve was generated using Tc-99m MIBI results. FNAC revealed 10 nodules with neoplastic lesions (8 follicular and two pleomorphic), 29 with colloid goiter and 5 with benign cystic lesions. Tc-99m MIBI images revealed Categories-1,2,3,4 and 5 Scintigraphic patterns in 2,12, 11, 10 and 14 patients respectively. One patient in Category 1 and 9 in Category 2 proved to be neoplastic in nature, while none of the patients in category 3 to 5 had evidence of neoplasm on FNAC. The ROC curve revealed excellent performance of Tc-99m MIBI scan in diagnosing neoplastic lesions in the solitary cold thyroid nodules. Considering Category-1 and 2 as true positive results sensitivity, specificity, positive predictive and negative predictive values of Tc-99m MIBI scanning were found to be 100, 90, 71 and 100% respectively. Ultrasonography also had a sensitivity of 100% considering solid and cystic lesions as test positive. But specificity of US was found to be only 13%. The sensitivity and specificity of the combined results of Tc-99m MIBI scintigraphy and ultrasonography were also not found to be significantly different from those of Tc-99m MIBI scan alone (100% and 91% respectively). Hence in patients with solitary cold thyroid nodules on Tc-99m Pertechnetate study, a single Tc-99m MIBI scan can be used reliably to assess neoplastic nature of the nodule with high degree of sensitivity and specificity.

Richard and Parker, (1996), found that the work-up of thyroid nodules remains somewhat controversial. A good history, physical exam, and thyroid function tests often provide valuable clues in reaching a correct diagnosis but are non-specific. Despite difficulties with FNA, it is usually the initial procedure of choice. However, thyroid scintigraphy and ultrasound can both play useful roles in the evaluation of a nodule. Scintigraphy can be particularly useful in diagnosing a hot nodule where the

risk of malignancy is extremely low. US can be used to guide biopsies, follow the size of a nodule, and differentiate cystic from solid lesions.

Sehovic et al (2013), found that Ultrasound is a reliable method of diagnosis for selecting patients to have a cytological puncture. If thyroid scintigraphy shows warm nodules, there is no need for ultrasound guided cytological puncture. Scintigraphy, ultrasound and ultrasound guided cytological puncture are complementary methods in reliable diagnostics of nodular disease of the thyroid.

Pleśniak and Urbański(2012), found that , There is a correlation between thyroid volume obtained by US vs. PlannarSintigraphy and The impact on the outcome of the skills contractors.

Burger (2013) found that in a country with prior iodine deficiency, small nodular goiters are a frequent finding. There for thyroid scintigraphy may allow one to avoid FNAB in these circumstances.

Ahmed et al 2010 found that Both modalities revealed almost identical results. Ultrasound has the additional advantages of being non-ionizing radiation and accurately localizes and characterizes the TDC thyroglossal duct cyst.

# Chapter Three

**(Materials and Methods)**



## **Chapter three**

### **Material and methods**

In this chapter a brief descriptions of the present work is out lined. In total, 200 patients with thyroid issue underwent both thyroid scintigraphy and ultrasonography. This study was done from Jan. 10, 2016 to June. 30, 2018. The patients were referred by the pediatricians of north state of Emirates general hospitals.

### **3.1Material**

#### **3.1.1Patients**

The study population consisted of **173** patients were seen by surgeons and medical doctors as having thyroid issues, and referred to Nuclear Medicine and Radiology Department, Fujairah hospital for thyroid scintigraphy and neck ultrasound during the period from Jan. 10, 2016 to June. 30, 2018.

#### **3.1.2 Machines**

For nuclear medicine equipment &energyWindow:

- Gamma camera:large field of view
- Collimator : Low energy , high resolution, parallel hole
- Energy window: 20% window centered at 140KeV

### **3.2 Methods**

A total of 173 patients were seen by surgeons and medical doctors as having thyroid issues, and referred to Nuclear Medicine and Radiology Department, Fujairah hospital for thyroid scintigraphy and neck ultrasound during the period from Jan. 10, 2016 to June. 30, 2018.

The thyroid scintigraphy obtained 10-20 minutes after intravenous injection of 37-111MBq of sodium pertechnetate Tc-99m using a LEHR (low energy high resolution collimator-equipped gamma-scintillation camera. All thyroid scintigraphy's were interpreted by one Nuclear Medicine Physician. For ultrasound, all patients were scanned supine with their necks hyperextended using a 7.5-10-MHz transducer. All

patients underwent neck ultrasound by one expert radiologist. The data analyzed using the SPSS program.

### **3.2.1 Thyroid scintigraphy**

#### **3.2.1.1. Radiotracer**

Technetium 99m pertechnetate ( $^{99m}\text{TcO}_4^-$ ) is a used radioactive label for thyroid scanning.

National regulations may indicate different reference activities; it is suggested to scale the administered activity according to the lower one.

Injection Technique a fine Butterfly needle (gauge 23-25 according to patient's age) is recommended.

Technetium-99m is a metastable nuclear isomer of technetium-99, symbolized as  $^{99m}\text{Tc}$  that is used in tens of millions of medical diagnostic procedures annually, making it the most commonly used medical radioisotope.

Technetium-99m when used as a radioactive tracer can be detected in the body by medical equipment (gamma cameras). It is well suited to the role because it emits readily detectable 140 keV gamma rays (these are about the same wavelength as emitted by conventional X-ray diagnostic equipment), and its half-life for gamma emission is 6.0058 hours (meaning 93.7% of it decays to  $^{99}\text{Tc}$  in 24 hours). The "short" physical half-life of the isotope and its biological half-life of 1 day allows for scanning procedures which collect data rapidly, but keep total patient radiation exposure low. The same characteristics make the isotope suitable only for diagnostic but never therapeutic use.

Technetium-99m was discovered in 1938 as a product of cyclotron bombardment of molybdenum. This procedure produced molybdenum-99, a radionuclide with a longer half-life (2.75 days), which decays to  $^{99m}\text{Tc}$ . At present, molybdenum-99 ( $^{99}\text{Mo}$ ) is used commercially as the easily transportable source of medically used  $^{99m}\text{Tc}$ . In

turn, this Mo-99 is usually created commercially by fission of highly enriched uranium in aging research and material testing nuclear reactors in several countries .

### **3.2.1.2 Patient Preparation**

No preparation is need if sedation is not required, but before injection of the radiopharmaceutical:

The procedure is explained to parents and to children old enough to understand and continual communication and reassurance with explanation of each step are essential for cooperation and successful intravenous injection of the radiopharmaceutical.

Pre-sedation evaluation is necessary for sedation (An informed consent, patient preparation, and presedation evaluation are necessary for administration of sedation).

Patients may have to discontinue thyroid medication from four to six weeks before your scan. Some heart medications and any medicine containing iodine also may require adjustments.

Also patients may be asked to avoid certain foods that contain iodine for about a week before your procedure.:

- dairy products
- shellfish
- sushi
- kelp
- seaweed
- iodized salt
- seasonings that contain iodized salt

Also should refrain from using:

- antihistamines
- cough syrups
- multivitamins
- supplements containing iodine

Other drugs that could affect the results of an RAIU are:

- adrenocorticotrophic hormone (ACTH)
- barbiturates
- corticosteroids
- estrogen
- lithium
- Lugol's solution, which contains iodine
- nitrates
- phenothiazines
- tolbutamide

Patients shouldn't have any other imaging tests that use radioactive iodine for six weeks before thyroid scan. Patients may have to fast for several hours before exam. Food can affect the accuracy of the RAIU measurement.

Patients have to remove any jewelry or other metal accessories before the test. These may interfere with the accuracy of the scan.

#### **3.2.1.4 Image Acquisition**

10 to 20 minutes post-injection

Ant, Ant with marker, and Ant Oblique views

Imaging Time: 10-15 minutes

#### **3.2.1.5 Processing**

Relative function of each kidney cortical scar may have relatively sharp edges with contraction and reduced volume of the affected cortex. A. Scarring can manifest as cortical thinning, flattening, or an ovoid or wedge-shaped defect .images was reported by the nuclear medicine physician.

#### **3.1.1 Place and time of the study:**

UAE –Fujairah –Fujairah hospital –Nuclear medicine department

-time start from Jan 2016 to June 2018.

#### **3.1.2 Sample volume**

100 patients from Fujairah Hospital- UAE (different nationality) were undergoing thyroid ultrasound and Thyroid scintigraphy. The patient age vary from 23 years to 70 years old. The median age is 46.6 years.

#### **3.1.3 Duration and Study population**

A retrospective study was done in total 100 patients with thyroid abnormalities underwent both thyroid scintigraphy and ultrasonography. This study was done from Jan 2016 to June 2018. The 100 patients were referred by the medical physicians.

### **3.2 Ultrasound machine used:**

For ultrasound a high-frequency (6–15 MHz) linear transducer is used. The highest frequency is used while still allowing adequate sonographic penetration. Start by placing the transducer over the neck, then angle the beam as necessary and adjust the time gain compensation ( TGC) with adequate sensitivity setting to allow uniform acoustic pattern, thus obtaining the best image of thyroid gland.

All patients underwent standard ultrasound scan using (Toshiba, Aplio 400, model SSA-370A) ultrasound machine and the documented images had been printed and saved .

### **3-2 Methods and Techniques:**

#### **3.2.1 Patient Preparation:**

There is no preparation for this procedure.

#### **3.2.2 Patient's position:**

To visualize the thyroid gland optimally, the patient is placed in the supine position with a pillow underneath the shoulders to extend the neck slightly, allowing the head to rest on the examination table..

#### **3.2.3 Technique:**

All patients are examined in supine position with hyperextended neck, using a high frequency linear-array transducer (6 -15 MHz) that provides adequate penetration and high resolution image. Scanning is done both in transverse and longitudinal planes. Real time imaging of thyroid lesions is performed using both gray-scale and color

Doppler techniques. The imaging characteristics of a mass (viz. location, size, shape, margins, echogenicity, contents and vascular pattern) should be identified.

### **3.2.4 Examination criteria**

An acronym has shown to be didactically helpful ["SSOTM"]:

S = size

S = shape

O = outline

T = texture

M = measurement

### **3.2.5 Image analysis**

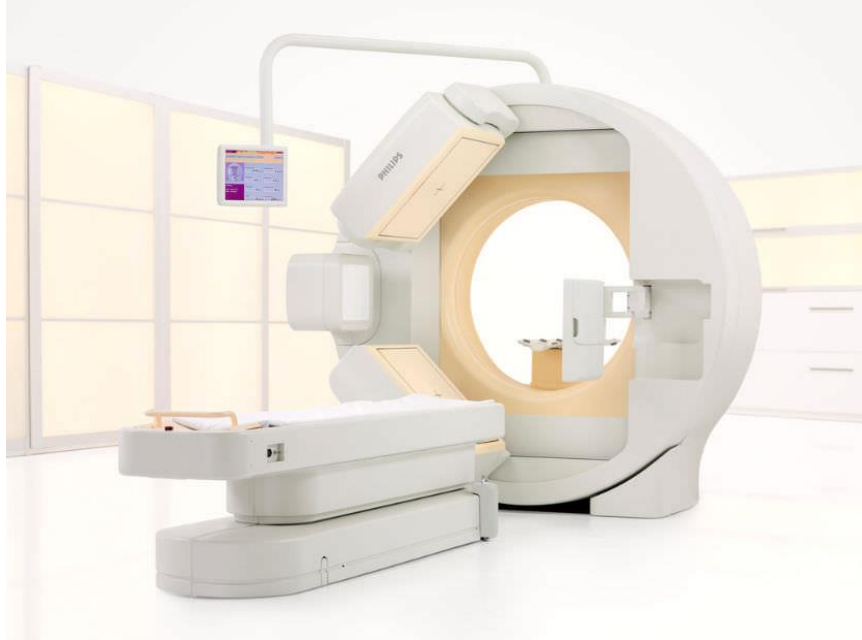Both ultrasound and FNAB were retrospectively analyzed by a radiologist.

### **3.2.6 Data analysis method:**

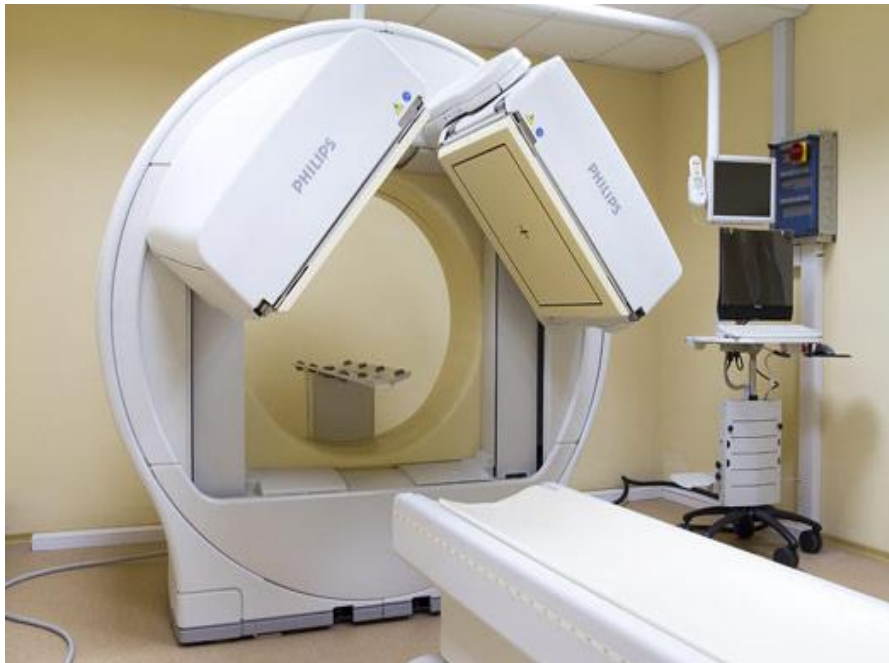By using computer program, Statistical Package for Social Sciences (SPSS), Statistical significance will be determined using chi-square test.

### **3.2.7 Ethical issue:**

Patient data was requested by clinicians.

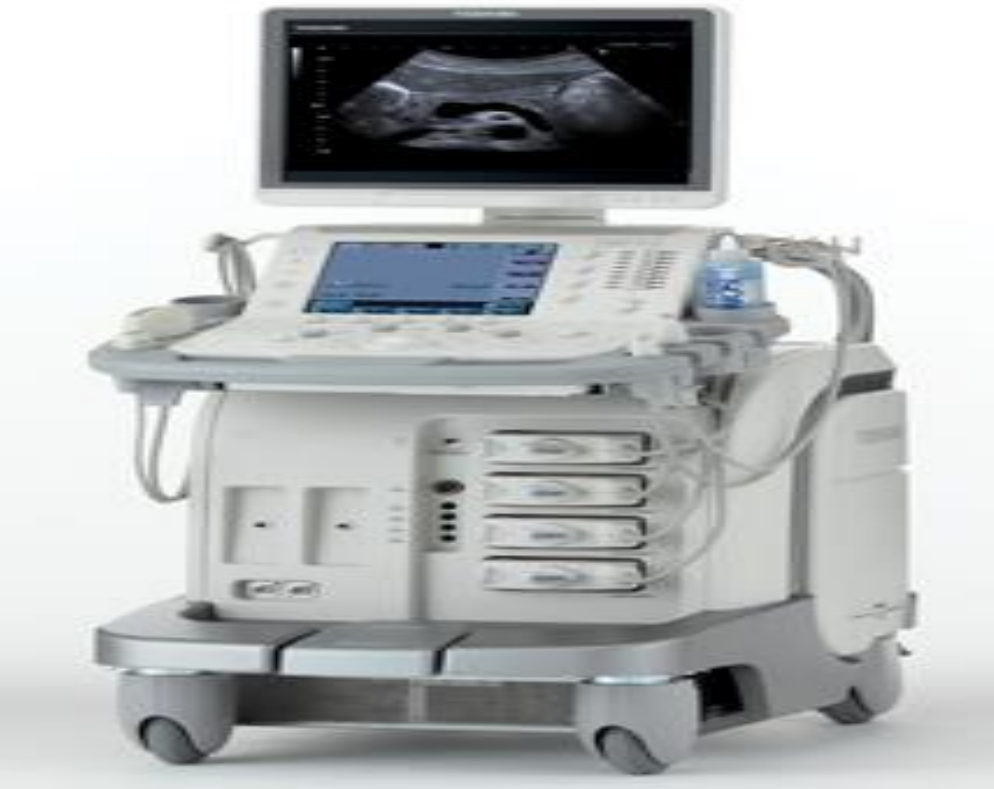

**Figure (3-1) BrightView SPECT gamma camera**



**Figure (3-2) Bright View SPECT gamma camera.**





**Figure (3-3) Toshiba Ultra sound machine , Aplio 400, model SSA-370A**



**Figure (3-4) Toshiba Ultra sound machine, Aplio 400, model SSA-370A**

# **Chapter Four**

**(Results)**

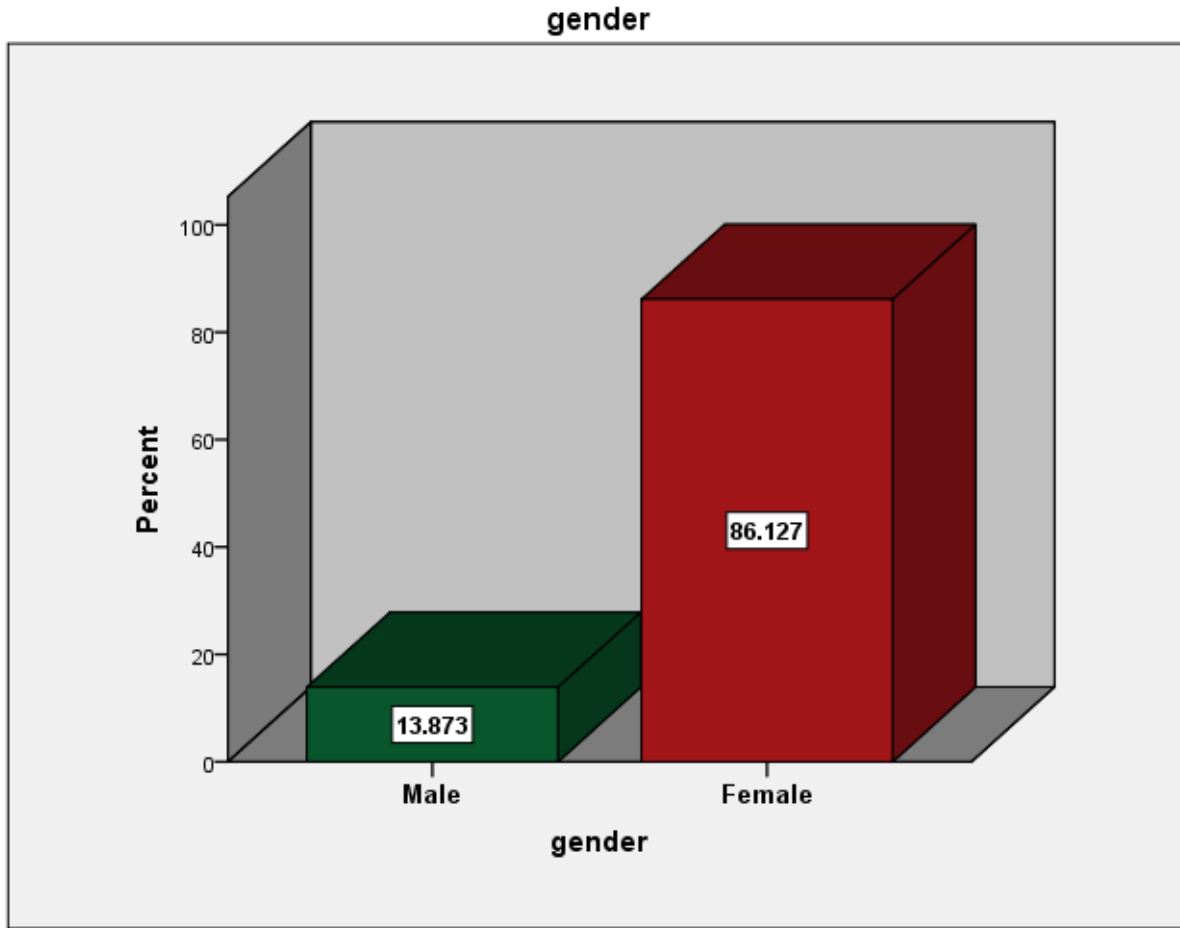
## Chapter Four

### Results

A total of 173 patients were seen by surgeons and medical doctors as having thyroid issues, and referred to Nuclear Medicine and Radiology Department, Fujairah hospital for thyroid scintigraphy and neck ultrasound during the period from Jan. 10, 2016 to June. 30, 2018. According to this study; among this 173 patients 86% were female(149) and 14% were male (24), table (4-1). The mean age of our patients was 38 years. Thyroid ultrasound scan results were normal in 6% (11 patients) and abnormal in 94 % (162 patients) table (4-2). thyroid nuclear medicine scan were reported as normal in 9% (16 patients) and abnormal in 91% (157 patients) .

**Table (4-1) Numbers of male and female patients**

Patients	Numbers
Male	24
Female	149
Total numbers	173



**Figure 4-1 shows Numbers of male and female patients**

**Table (4-2) Numbers of normal and abnormal patients in each test**

Patients	Normal	Abnormal
Ultrasound	11	162
Nuclear medicine	16	157
Total numbers	27	319

**Table (4-3) patient's ages frequency**

Age group	Numbers of patients
0 > 10	1
10 > 20	13
20 > 30	35
30 > 40	50
40 > 50	46
50 > 60	13
60 > 70	15
Total number of patients	173

**Table (4-4) The Numbers of normal patients and patients with different thyroid disorder in each test**

Thyroid disorders	Ultrasound test	NM test
Autonomous Nodule	0	2 (1.1)
nodular goiter- NTG , TNG	30 (17.3%)	30 (17.3%)
Goiter	1 (0.57)	11(6.4%)
Grave disease	15(8.7%)	13(7.5%)
Multinodular goiter	83 (48%)	43(24.8%)
Thyroiditis	25 (14.5%)	20 (11)
Thyroid nodule	2 (1.1)	2 (1.1)
Toxic multinodular goiter	3(1.73%)	21
Toxic goiter	3 (1.73%)	15 (8.7%)
Normal	11 (6.4%)	16 (9.2%)
total	173	173

**Table 4-5 Shows Nodules site in both tests (thyroid scintigraphy and thyroid ultrasound)**

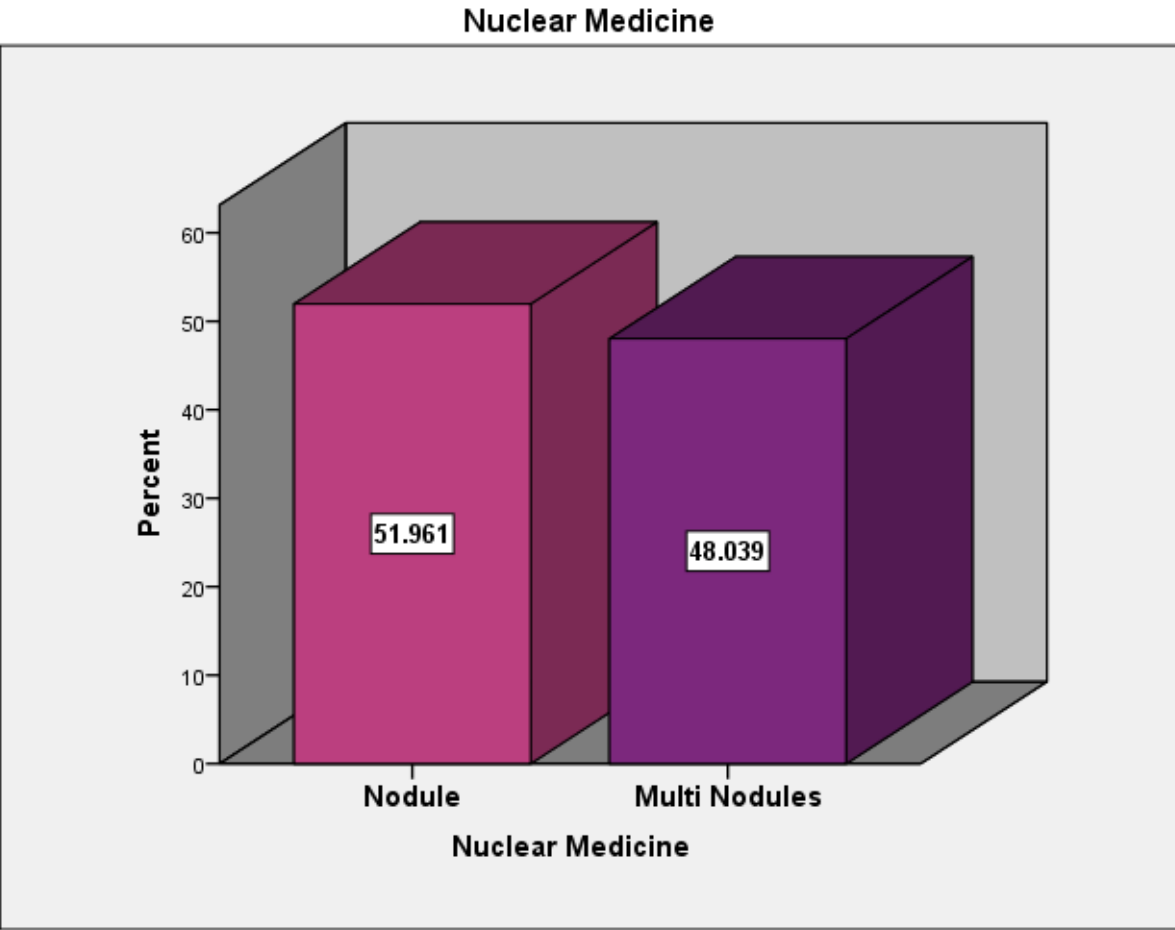
Nodule site	Nuclear medicine	Ultrasound
Lt lobe	63	118
Rt lobe	80	114
isthmus	19	22
Total	162	254

**Table 4-6 Shows Thyroid size taken by both tests (thyroid scintigraphy and thyroid ultrasound)**

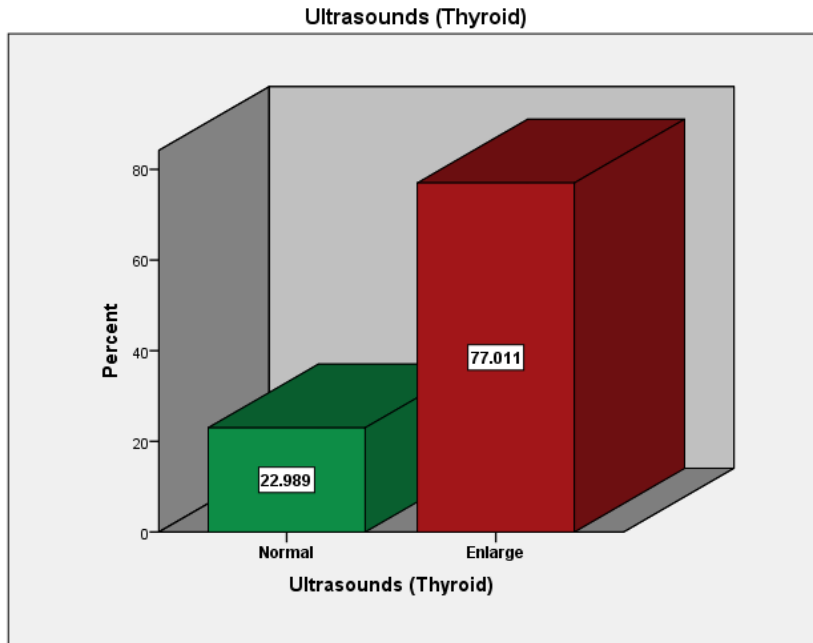
size	Nuclear medicine	Ultrasound
Normal	49 (28%)	40( 23%)
Enlarge	124 (72%)	133 (77%)
Total	173 (100%)	173 (100%)

**Table 4-7 Shows nodule site in both tests**

Nodules	Nuclear medicine	Ultrasounds
Nodule	53	26
Multi nodules	49	109
total	102	135



**Figure 4-2 shows the frequency of solitary nodules and multi nodules by Nuclear medicine**



Figures 4-3 shows the frequency of normal and enlarge thyroids by ultrasound

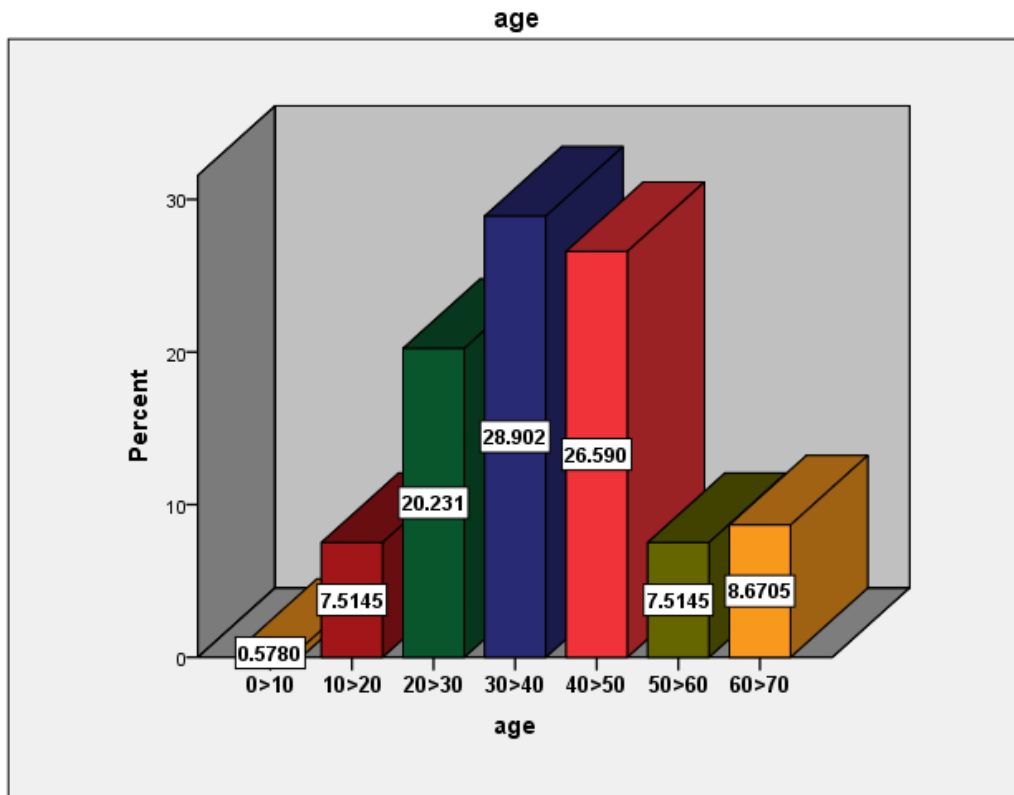
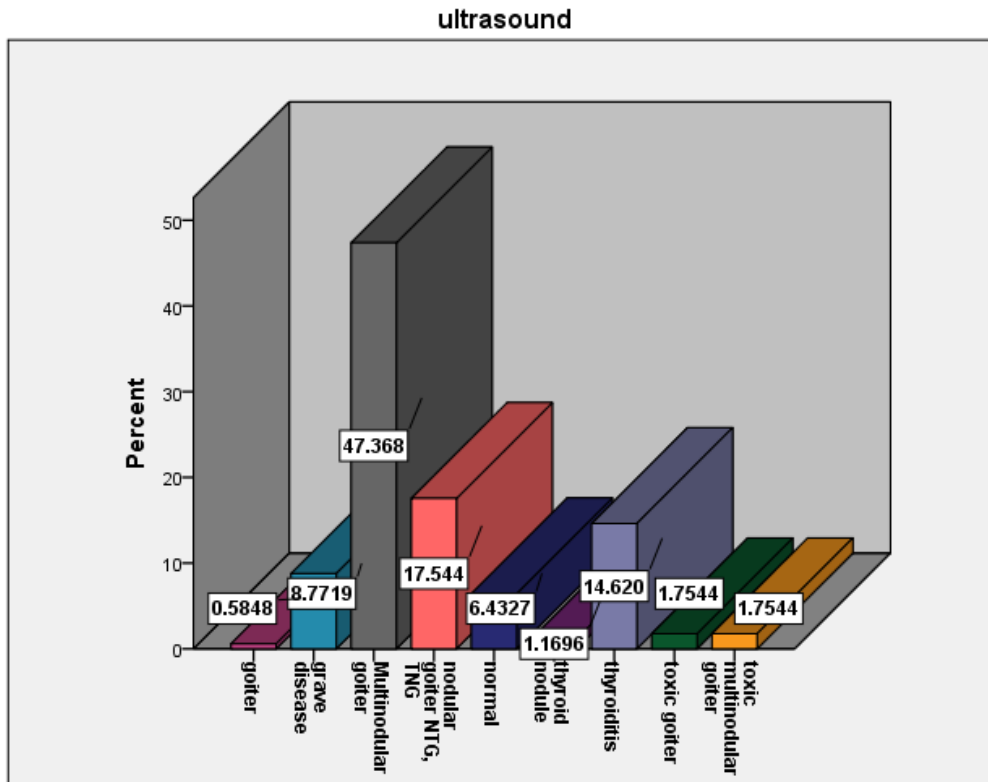
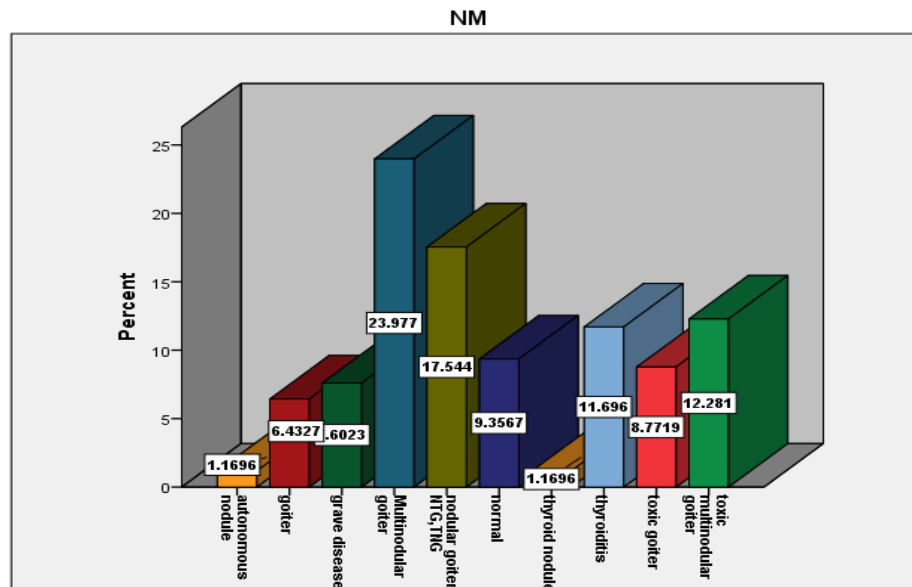


Figure 4-4 age frequency of patients

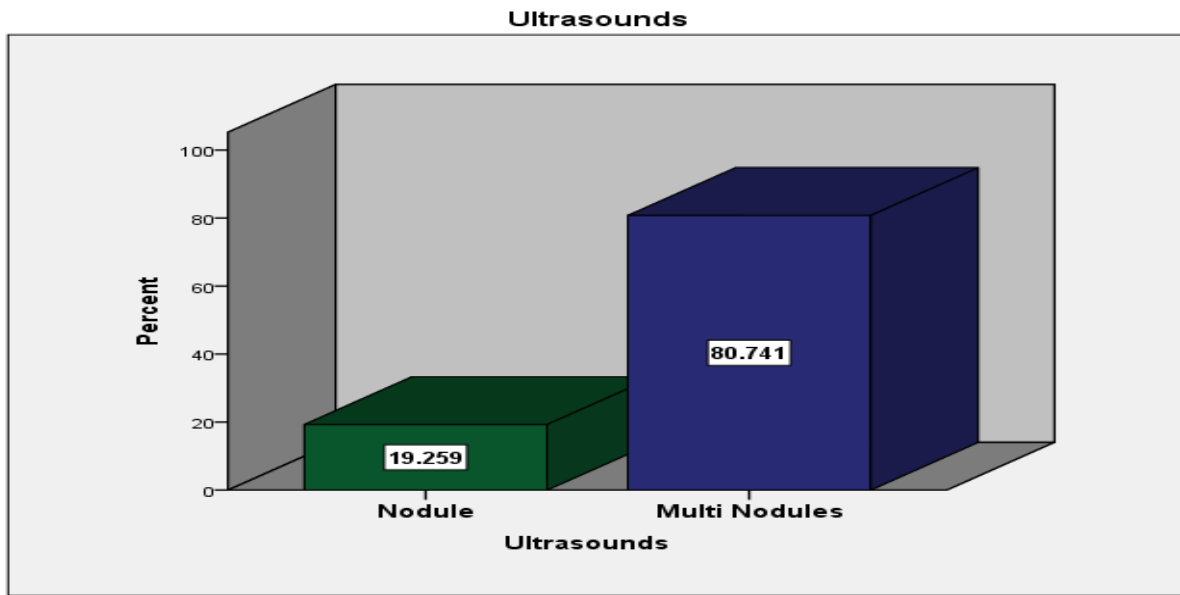




**Figure 4-5 Thyroid abnormalities frequency with ultrasound**



**Figure 4-6 Thyroid abnormalities frequency with nuclear medicine scintigraphy**



**Figure 4-7 solitary nodules and multi nodules frequency by ultrasound**

**Table 4-8 statistics of patient's ages**

Statistics			
age			
N	Valid		173
Mean			4.3064
Median			4.0000
Mode			4.00
Sum			745.00

**Table 4-9 shows correlation positive high relation between gender and thyroid ultrasound 0.744, highly significant at 0.000 in level 0.01**

Correlations			
		gender	Ultrasounds (Thyroid)
gender	Pearson Correlation	1	.744**
	Sig. (2-tailed)		.000
	N	173	173
Ultrasounds (Thyroid)	Pearson Correlation	.744**	1
	Sig. (2-tailed)	.000	
	N	173	174

\*\* . Correlation is significant at the 0.01 level (2-tailed).

**Table 4-10 shows correlation positive high relation between gender and thyroid nuclear medicine 0.638, highly significant at 0.000 in level 0.01**

Correlations			
		gender	Nuclear Medicine (Thyroid)
gender	Pearson Correlation	1	.638**
	Sig. (2-tailed)		.000
	N	173	173
Nuclear Medicine (Thyroid)	Pearson Correlation	.638**	1
	Sig. (2-tailed)	.000	
	N	173	183

\*\* . Correlation is significant at the 0.01 level (2-tailed).

**Table 4-11 shows correlation positive high relation between gender and nuclear medicine (nodule site) 0.327, highly significant at 0.000 in level 0.01**

Correlations			
		gender	Nuclear Medicine (Nodules site)
gender	Pearson	1	.327**
	Correlation		
	Sig. (2-tailed)		.000
	N	173	162
Nuclear Medicine (Nodules site)	Pearson	.327**	1
	Correlation		
	Sig. (2-tailed)	.000	
	N	162	162
**. Correlation is significant at the 0.01 level (2-tailed).			

**Table 4-12 shows correlation negative high relation between age and thyroid nuclear medicine- 0.382, highly significant 0.000 in level 0.01**

		Correlations	
		age	Nuclear Medicine (Thyroid)
age	Pearson Correlation	1	-.382**
	Sig. (2-tailed)		.000
	N	173	173
Nuclear Medicine (Thyroid)	Pearson Correlation	-.382**	1
	Sig. (2-tailed)	.000	
	N	173	183

\*\* . Correlation is significant at the 0.01 level (2-tailed).

**Table 4-13 that shows negative high relation between age and thyroid nuclear medicine (nodule site) - 0.774, highly significant at 0.000 in level 0.01**

Correlations			
		age	Nuclear Medicine (Nodules site)
age	Pearson Correlation	1	-.774**
	Sig. (2-tailed)		.000
	N	173	162
Nuclear Medicine (Nodules site)	Pearson Correlation	-.774**	1
	Sig. (2-tailed)	.000	
	N	162	162

\*\* . Correlation is significant at the 0.01 level (2-tailed).

**Table 4-14 that shows correlation negative high opposed relation between age and nuclear medicine- 0.529,highly significant 0.000 in level 0.01**

Correlations			
		age	Nuclear Medicine
age	Pearson Correlation	1	-.529**
	Sig. (2-tailed)		.000
	N	173	102
Nuclear Medicine	Pearson Correlation	-.529**	1
	Sig. (2-tailed)	.000	
	N	102	102

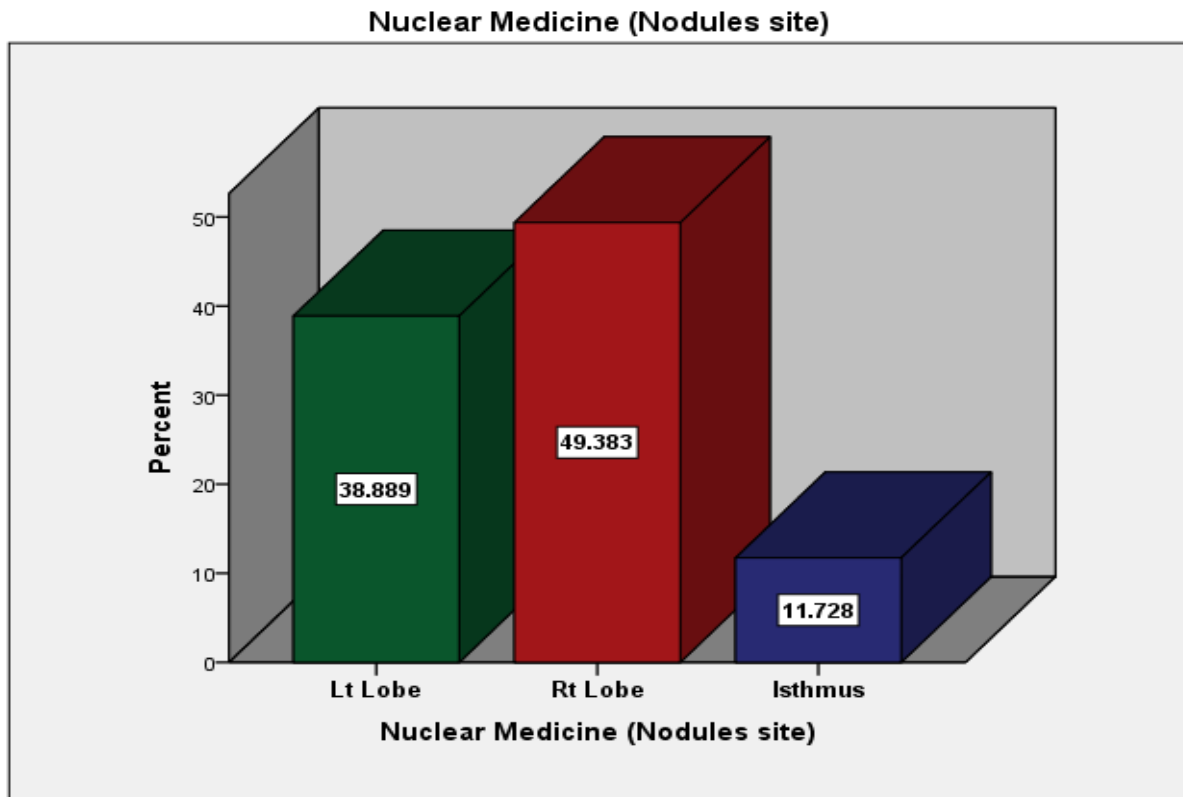
\*\* . Correlation is significant at the 0.01 level (2-tailed).

**Table 4-15 shows statistics for nuclear medicine scintigraphy**

Statistics		
Nuclear Medicine		
N	Valid	102
Mean		1.4804
Median		1.0000
Mode		1.00
Sum		151.00

**Table 4-16 statistics of ultrasound**

Statistics		
Ultrasounds		
N	Valid	135
Mean		1.8074
Median		2.0000
Mode		2.00
Sum		244.00

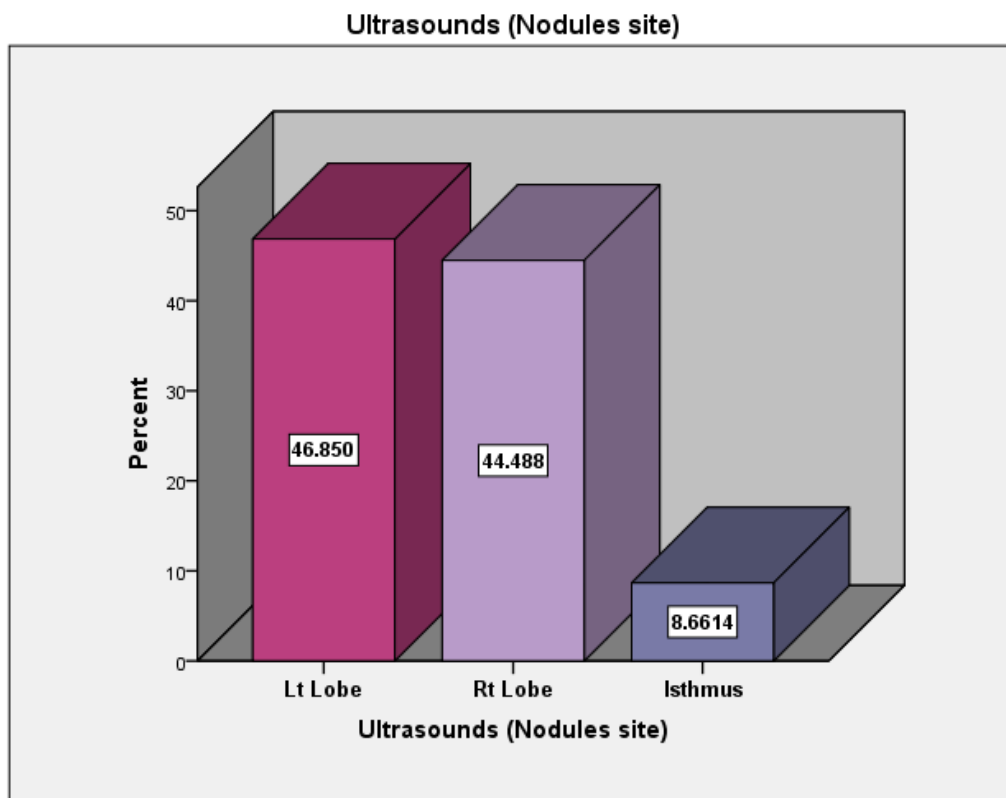


**Figure 4-8 shows statistics of nodule site in nuclear medicine**



**Table 4-17 statistics nodules sites by nuclear medicine scintigraphy**

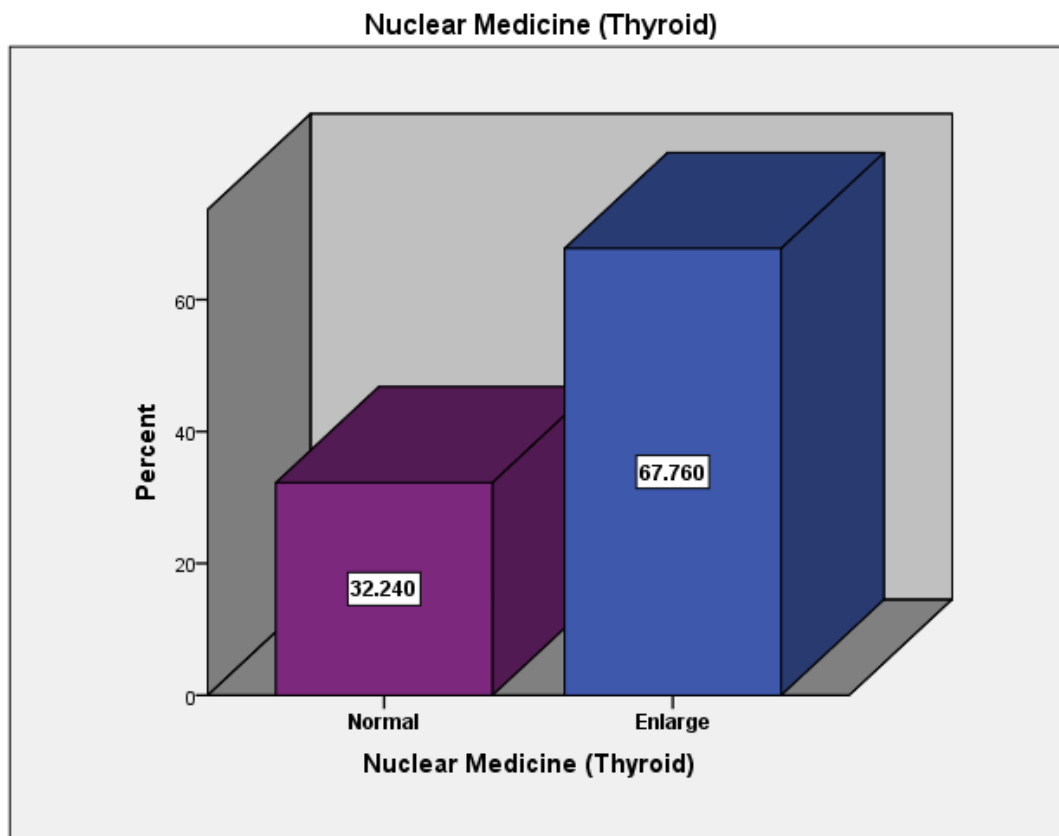
Statistics		
Nuclear Medicine (Nodules site)		
N	Valid	162
Mean		1.7284
Median		2.0000
Mode		2.00
Sum		280.00



**Figure 4-9 that shows statistics of nodule sites by ultrasound**

**Table 4-18 shows statistics of nodule sites by ultrasound**

Statistics		
Ultrasounds (Nodules site)		
N	Valid	254
Mean		1.6181
Median		2.0000
Mode		1.00
Sum		411.00



**Figure 4-10 shows the frequencies of thyroid size in nuclear medicine**

**Table 4-19 shows statistics of thyroid size**

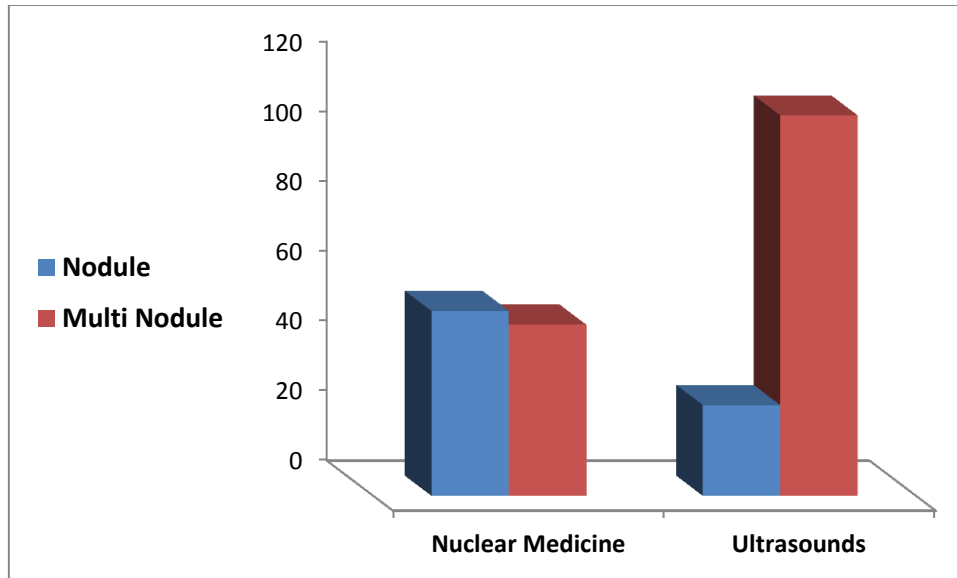
Statistics		
Nuclear Medicine (Thyroid)		
N	Valid	
		183
Mean		1.6776
Median		2.0000
Mode		2.00
Sum		307.00

**Table 4-20 shows statistics of thyroid size by ultrasound**

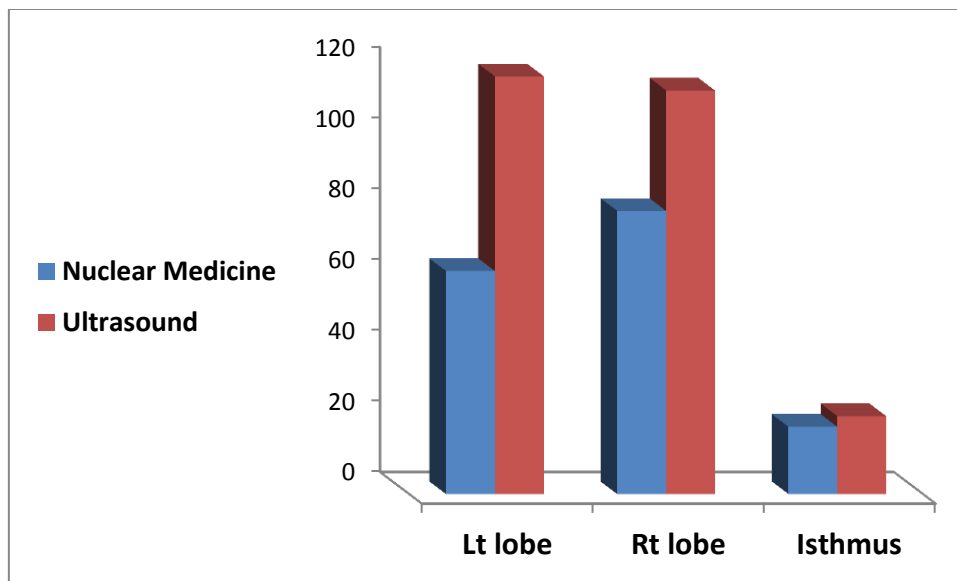
Statistics		
Ultrasounds (Thyroid)		
N	Valid	
		174
Mean		1.7701
Median		2.0000
Mode		2.00
Sum		308.00

**Table 4-21 that shows correlation positive relation between nuclear medicine and ultrasound 0.834, highly significant 0.000 in level 0.01**

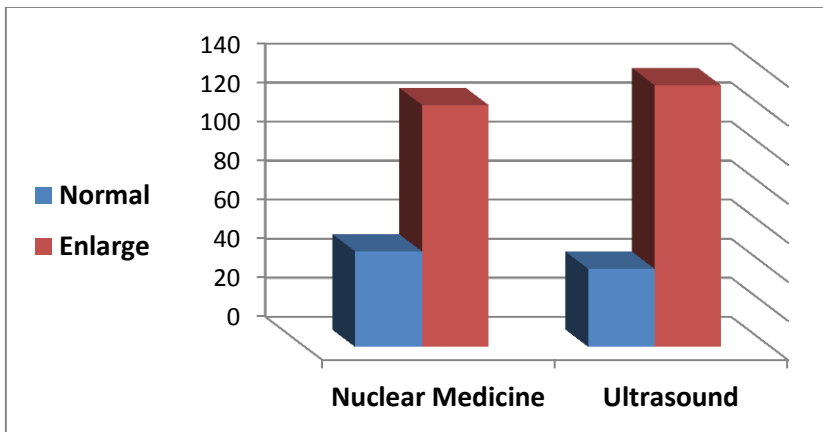
Control Variables		Correlations		
			Ultrasounds (Thyroid)	Nuclear Medicine (Thyroid)
Ultrasounds (Nodules site)	Ultrasounds (Thyroid)	Correlation	1.000	.834
		Significance (2-tailed)	.	.000
		df	0	171
	Nuclear Medicine (Thyroid)	Correlation	.834	1.000
		Significance (2-tailed)	.000	.
		df	171	0



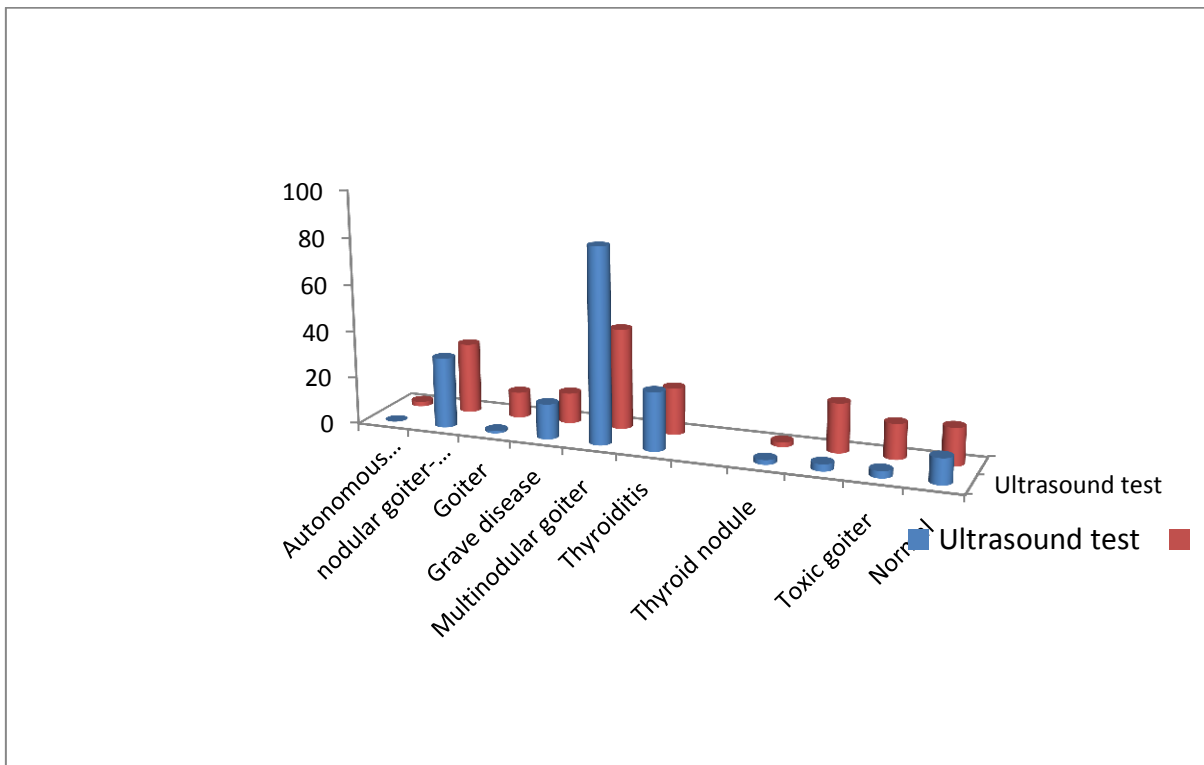
**Figure 4-11 shows the frequencies of solitary nodules and multi nodules in both scans (ultrasound and scintigraphy)**



**Figure 4-12 Shows the frequencies of nodules sites in both scans (ultrasound and scintigraphy)**



**Figure 4-13 Shows the frequencies of normal and enlarge size of thyroid gland in both scans (ultrasound and scintigraphy)**



**Figure 4-14 Shows the frequencies of thyroid abnormalities in both scans (ultrasound and scintigraphy)**

**Table 4-22 shows patients hormones results**

		Result	
Hormone	T4	T3	TSH
High	88	78	4
Low	5	3	74
Normal	80	92	95
Total	173	173	173

# **Chapter Five**

**(Discussion, Conclusion and  
Recommendations)**



## **Chapter Five**

### **Discussion, Conclusion and Recommendation**

#### **5.1 Discussion**

Thyroid US was performed by a Toshiba Ultra sound machine scanner with a 6- to 15-MHz bandwidth transducer. Compound imaging was performed with Color Doppler in all cases. Sonographic classification based on sonographic features was performed by one experienced sonographer. Size was measured as the longest diameter. Sonographic features included echogenicity, margin, calcifications, and shape, based on our previous publication. Color Doppler imaging was routinely obtained. Echogenicity was classified as hyperechogenicity, isoechogenicity, hypoechogenicity, and hetroechogenicity. When the echogenicity was similar to thyroid parenchyma, the nodule was classified as isoechogenic. Calcifications were categorized as calcifications, or none. Mixed nodules, composed of both cystic and solid portions, were classified according to the solid portion.

Nuclear medicine thyroid scan was performed by a Bright View gamma camera. Nuclear medicine classification based on distribution of the radioisotopes through the thyroid. Features were performed by one experienced nuclear medicine technologist. Size was measured as the whole diameter. The features included homogeneity, uptake, count per pixel, and area.

The study population consisted of 173 patients were seen by surgeons and medical doctors as having thyroid issues, and referred to Nuclear Medicine and Radiology Department, Fujairah hospital for thyroid scintigraphy and neck ultrasound during the period from Jan. 10, 2016 to June. 30, 2018.

Thyroid ultrasound , nuclear medicine thyroid scintigraphy and demographic data are presented in Tables and figures for this study revealed that, among this 173 patients 86% were female(149) and 14% were male (24), table (4-1).The mean age of patients

was 38 years , table (4-3). Thyroid ultrasound scan results were normal in 6.4% (11 patients) and abnormal in 93.6 % (162 patients), while thyroid nuclear medicine scan were reported as normal in 6.4 % (16 patients) and abnormal in 91% (157 patients) table (4-2).

In this study table (4-4) shows that ultrasound examination is able to detect multi nodules in 83of the patients while nuclear medicine scan is able to detect only 43 patients. However, when the nodule is solitary, the ultrasound and the nuclear medicine thyroid scan are same in detecting it. And if multi nodules are toxic, nuclear medicine is better in detecting it (21 patients)comparing to Ultrasound (3 patients). In diagnosis of Autonomous nodule nuclear scan was able to detect it while ultrasound couldn't detect it. In Graves'disease both modalities were near each other's,Ultrasound (15 patients) 8.7% and nuclear medicine (13 patients) 7.5% in detecting it. For thyroiditis ultrasound was better than nuclear medicine, (25 patients) 14.4% to (20 patients) 11%. However in diagnosis of toxic goiter nuclear medicine thyroid scan was better than ultrasound, (15 patients) 8.7% to (3 patients) 1.73%.

Table (4-5) shows the nodule sites in both tests. It was more nodules in ultrasound, in the Right lobe, Lt Lobe and isthmus, 114, 118, 22, while it was, 80, 63, 19 in the thyroid nuclear medicine scan.

Table (4-6) shows that the thyroid gland sizes if it is enlarge or not. And it was enlarge by (133 patients) 77% of patients in ultrasound, and normal in (40 patients) 23 % of all cases. In nuclear medicine thyroid scan it was enlarge in (124 patients) 72% of patients and normal in (49 patients) 28 % of all cases.

Table (4-7) shows the ability of tests, thyroid ultrasound and nuclear medicine thyroid scan, in detecting nodules. Nuclear medicine was good in detecting solitary nodules in 53 patients more than ultrasound which detected in only 26 patients. Put when patient have multiple nodules , ultrasound was best in detecting nodules in 109 patients

compare to nuclear medicine which detect nodules in only 49 patients. That means ultrasound have more sensitivity and specify than nuclear medicine in diagnosis of multi nodular goiter diseases.

Table 4-22 shows the different values of thyroid hormones for all patients which was one of the reasons for referral.

In all cases the ultrasound made the diagnosis in 93.6% (162 patients) more than nuclear medicine 90.3% (157 patients) by 3.3 %, Table (4-4).

The trend of the tables 4-9 and 4-10 showed that where are correlation between the gender and ultra sound appearance of thyroid disease (Sig P value 0.00-Correlation Coefficient = 0.327 & R<sup>2</sup> linear 0.05) strong than the relation of gender and nuclear medicine appearance of thyroid disorders ( Sig P value 0.000-Correlation Coefficient = 0.064 & R<sup>2</sup> linear 0.01 ) by tow indicator significant Correlation Coefficient and R<sup>2</sup> relation.

The trend of the table 4-11 and 4-12 showed that where are correlation between the gender and nuclear medicine ( Sig P value 0.00-Correlation Coefficient = 0.327 & R<sup>2</sup> linear 0.01 ) strong Correlation is significant at the 0.01 level (2-tailed) stronger than the relation of age and nuclear medicine appearance ( Sig P value 0.05-Correlation Coefficient= 0.00 & R<sup>2</sup> linear - 0.0382 ) by tow indicator significant Correlation Coefficient and R<sup>2</sup> linear relation .

The trend of the table 4-13 & 4-14 showed that where are correlation between the age and nuclear medicine nodule site (SigP value 0.00-Correlation Coefficient = - 0.529 & R<sup>2</sup> linear 0.00) strong Correlation is significant at the 0.01 level (2-tailed).Stronger than the relation of age and nuclear medicine nodule (Sig P value -0.00-Correlation Coefficient= -.77& R<sup>2</sup> linear -0.01) by tow indicator significant Correlation Coefficient and R<sup>2</sup> linear relation.

The trend of the table 4-21 showed that there are correlation between the Ultrasound and scan in nuclear medicine for nodule site that is relation (SigP 0.00- Correlation Coefficient = 0.83& R2linear 0.22) strong Correlation is significant at the 0.01 level This relationship can be considered the strongest among the relationships and this confirms the strong confirmation of the result of the hormone.

There are also other relationships between two study and These results are also comparable to the result of the nodule site with ultra sound study and the nuclear scan . ultra sound are more highly P value and more positive value relative to the nuclear study example for this relation is given in the following tables (4-21) . Table 4-21 that shows correlation positive relation between nuclear medicine and ultrasound 0.834, highly significant 0.000 in level 0.01.

The result of the correlation of the value R2 (bonding square) and Y value in the all graphs means the strength of the correlation between ultrasound examination and nuclear medicine of thyroid gland .

This study shows that the relationship between the two study cannot be changed because the level and sensitivity of nuclear medicine study is not more sensitive than ultra sound study that is means true positive of nuclear medicine is not sensitive more than thyroid ultra sound also that is means diagnosis did not change much as expected by the hypothesis and thus becomes the logical sequence of management of the treatment and diagnosis of thyroid by ultrasound before the nuclear thyroid scan .

Thyroid scintigraphy usually performed to document a normal thyroid and to exclude an ectopic thyroid which is the patient's only functioning thyroid tissue, and its removal will result in hypothyroidism (Davenport, M.. BMJ 1996).

However, the scintigraphy result should be interpreted in the context of anatomic and biochemical data. The thyroid scintigraphy exposes patients to ionizing radiation with longer Imaging time and requires intravenous access. It is also costly and may not be available. On the other hand the preoperative sonographic identification of a normal thyroid gland in patients with thyroglossal duct cyst confirms a source of thyroid hormone separate from the thyroglossal duct cyst and thus excludes ectopic thyroid. Routine thyroid scintigraphy is therefore not necessary if a normal thyroid gland can be identified on routine preoperative US. Because of its superficial location, thyroid gland is ideally situated for high frequency ultrasound. It is easily available, completely noninvasive, does not require sedation or intravenous access and relatively fast.

Richard Kuno, , J. Anthony Parker, October 29, 1996, agreed with the research findings, because they find that the work-up of thyroid nodules remains somewhat controversial. A good history, physical exam, and thyroid function tests often provide valuable clues in reaching a correct diagnosis but are non-specific. Despite difficulties with FNA, it is usually the initial procedure of choice. However, thyroid scintigraphy and ultrasound can both play useful roles in the evaluation of a nodule. Scintigraphy can be particularly useful in diagnosing a hot nodule where the risk of malignancy is extremely low. US can be used to guide biopsies, follow the size of a nodule, and differentiate cystic from solid lesions. (J Nuc Med 1990;31:393-99. )

Also Sehovic S1, Begic A, Juric N, Celam M, find that Ultrasound is a reliable method of diagnosis for selecting patients to have a cytological puncture. If thyroid scintigraphy shows warm nodules, there is no need for ultrasound guided cytological puncture. Scintigraphy, ultrasound and ultrasound guided cytological puncture are complementary methods in reliable diagnostics of nodular disease of the thyroid. (Med Arch. 2013;67(3):198-201.)

Also Jarosław Pleśniak and Stanisław Urbański, find that , There is a correlation between thyroid volume obtained by US vs. Planar Scintigraphy and The impact on the outcome of the skills contractors. (Pol J Radiol. 2012 Apr-Jun; 77(2): 19–21.)

Also Albert G. Burger find that in a country with prior iodine deficiency, small nodular goiters are a frequent finding. There for thyroid scintigraphy may allow one to avoid FNAB in these circumstances. ClinThroidol 2013;25:13-15.)

And finally, Ahmed E. Elmadani<sup>1</sup>, Anas A Hamdoun<sup>1</sup>, AbdAlla M. Gaber<sup>2</sup> find that both modalities revealed almost identical results which agree completely with my research findings. Ultrasound has the additional advantages of being non-ionizing radiation and accurately localizes and characterizes the TDC thyroglossal duct cyst. (Sudan Journal of Medical Sciences Volume 5, Number 4 (December 2010) , 289-294).

## **5.2 Conclusion**

This study concluded that the serial relationship between the two studies cannot be changed and does not have a significant effect because the level and degree of sensitivity of the examination of the thyroid gland by nuclear medicine is not more sensitive and accurate than the ultrasound examination. This means that the positive results obtained by the research between the level thyroid site and the size of the thyroid gland also do not have an indicator and do not have a clear effect in the logical sequence of the development and delivery of nuclear examination on the ultrasound in the stages of administration and treatment of thyroid gland. Both modalities revealed almost identical results in some lesions and different in others. Ultrasound has the additional advantages of being non-ionizing radiation and accurately localizes and characterizes the nodules and thyroiditis.

### **5.3 Recommendations**

In this study, it was not proven that the examination of the thyroid through ultrasound has a higher value than nuclear medicine completely, but Ultrasound examination should be obtained routinely for patients with suspected multi nodular goiter, thyroiditis and scintigraphy be reserved for selected cases such as graves diseases and solitary toxic nodular goiter. researchers in future can find better results by finding more cases for the sample of research



# References

## References:

- Agur AMR, et.al. (1999), Grant's Atlas of Anatomy. 10th Ed. Lippincott Williams and Wilkins. London, UK.
- Berbel P, Navarro D, Ausó E, Varea E, Rodríguez AE, Ballesta JJ, Salinas M, Flores E, Faura CC, et al. (2010). "Role of late maternal thyroid hormones in cerebral cortex development: an experimental model for human prematurity
- Boron, WF.; Boulapep, EL. (2012). Medical Physiology(2nd ed.). Philadelphia: Saunders. p. 1052
- Bowen, R. (2000). "Thyroid Hormone Receptors". Colorado State University, USA
- Burkitt, H., Quick,C. and Gatt, D. Essential surgery (1996) Edinburgh : Churchill Livingstone.
- Cai XJ, et al. (2011), Ultrasound-guided fine needle aspiration cytology in the diagnosis and management of thyroid nodules. Cytopathology ,Yonsei Med J. 52(5): 838–844.
- CappelliC,et al.( 2006 ) Thyroid nodule shape suggests malignancy. Eur J Endocrinol. 155(1):27–31.
- Charles S. Odwin, et al (2012), “LANG REVIEW, Ultrasound Examination” fourth edition, New York, USA.
- Cooper DS, et al. ( 2006), Management guidelines for patients with thyroid nodules and differentiated thyroid cancer. Thyroid. 16(2):109–142.
- Corwin, Elizabeth, 2008, Hand book of pathophysiology, 3ed Edition, Lippincott Williams & Wilkins, Ohio, USA.
- Corwin, Elizabeth, 2008, Hand book of pathophysiology, 3ed Edition, Lippincott Williams & Wilkins, Ohio, USA.
- Courtney Townsend ,R. Daniel Beauchamp, B. Mark Evers ,Kenneth L. Mattox (27 July 2004);"The17th edition of Townsend: Sabiston Textbook of Surgery represents an ... Publisher: Saunders; 17 edition London, UK
- Davenport, M. Lumps and swellings of the head and neck. BMJ 1996; 312: 368-71.
- EzzatS,et al.( 1996), Thyroid incidentalomas. Prevalence by palpation and ultrasonography. Arch Intern Med. 154(16):1838–1840.
- Fatourech V (2009). "Subclinical hypothyroidism: an update for primary care physicians".MayoClin.Journal of Medicine 18(1):30.
- Fawcett, Don; Jensch, Ronald (2002). Bloom & Fawcett's Concise Histology. New York: Arnold Publishers. pp. 257–258
- Frates MC, et al. ( 2003), Can color Doppler sonography aid in the prediction of malignancy of thyroid nodules? J Ultrasound Med ;22:127–131.

- Frates MC, et al. (2005), Management of thyroid nodules detected at US: Society of Radiologists in Ultrasound consensus conference statement. *Radiology*. 237(3):794–800.
- Gharib H, et al (2005). "Subclinical thyroid dysfunction: a joint statement on management from the American Association of Clinical Endocrinologists, the American Thyroid Association, and the Endocrine Society". Volume 90, 581–585.
- Gharib H, et al.(2006), American Association of Clinical Endocrinologists and Associazione Medici Endocrinologi medical guidelines for clinical practice for the diagnosis and management of thyroid nodules. *EndocrPract* ,12:63-102.
- Gharib H, Goellner JR.(1993), Fine-needle aspiration biopsy of the thyroid: an appraisal. *Ann Intern Med* ,118:282-9.
- Giannini AJ, Malone DA, Loiselle RH, Price WA (1987). "Blunting of TSH response to TRH in chronic cocaine and phencyclidine abusers". *J Clin Psychiatry* 48 (1): 25–6.
- GianniniAJ,et al (1987). "Blunting of TSH response to TRH in chronic cocaine and phencyclidine abusers". *J Clin Psychiatry* 48 (1): 25–6
- Goldsmith, Stanley J. (1997) "Endocrine System." In *Nuclear Medicine*, ed. D. R. Bernier et al. St. Louis, MO: Mosby.
- Gray H, Lewis WH (2000), *Gray's Anatomy of the Human Body*. 20th Ed. New York.
- Gul K, Ersoy R, Dirikoc A, Korukluoglu B, Ersoy PE, Aydin R, Ugras SN, Belenli OK, Cakir B, Ultrasonographic evaluation of thyroid nodules: comparison of ultrasonographic, cytological, and histopathological findings, *Endocrine*. 2009 Oct 27
- Gulcelik NE, et al.( 2008), Risk of malignancy in patients with follicular neoplasm: predictive value of clinical and ultrasonographic features. *Arch Otolaryngol Head Neck Surg*. 134(12):1312–1315.
- Harnsberger HR, Osborn AG, Ross J et-al. (2006). *Diagnostic and Surgical Imaging Anatomy*. Lippincott Williams & Wilkins.
- Harvey A. Ziessman, et al. 04 April 2013, *Nuclear Medicine: The Requisites*, 4th edition, USA, Philadelphia.
- <http://en.wikipedia.org/wiki/Technetium-99m>
- [http://fitsweb.uchc.edu/student/selectives/Luzietti/Thyroid\\_anatomy.htm](http://fitsweb.uchc.edu/student/selectives/Luzietti/Thyroid_anatomy.htm)
- <http://www.insideradiology>.
- <http://www.surgicalcore.org/>)
- <https://en.wikipedia.org>
- [https://en.wikipedia.org/wiki/Thyroid\\_disease](https://en.wikipedia.org/wiki/Thyroid_disease))

- J. R. Wienke, et al, (2003), “Sonographic features of benign thyroid nodules: interobserver reliability and overlap with malignancy,” *Journal of Ultrasound in Medicine*, vol. 22, no. 10, pp. 1027–1031.
- Jansen J, Friesema EC, Milici C, Visser TJ (August 2005). "Thyroid hormone transporters in health and disease"
- Jr. Fred A. Mettler, 17 Jan 2012, *Essentials of Nuclear Medicine Imaging* , 6th edition, USA , Philadelphia
- Khoo ML, Asa SL, Witterick IJ, Freeman JL,(2002), Thyroid calcification and its association with thyroid carcinoma. *Head Neck* ; 24: 651–655.[PubMed]
- Kim EK, et al.(2002), New sonographic criteria for recommending fine-needle aspiration biopsy of nonpalpable solid nodules of the thyroid. *AJR Am J Roentgenol* 178:687-91.
- Klingensmith, William C. III, Dennis Eshima, and John Goddard. (2000). *Nuclear Medicine Procedure Manual 2000-2001*. Englewood, UK
- Kresnik E, Gallowitsch HJ, Mikosch P, Unterweger O, Gomez I, Lind P, Scintigraphic and ultrasonographic appearance in different tumor stages of thyroid carcinoma, *Acta Med Austriaca*. 2000;27(1):32-5.
- Lee KY, Huang SM, Li S, Kim JM.(2009), Identification of differentially expressed genes in papillary thyroid cancers. *Yonsei Med J* ,50:60-7.
- Lim-Dunham, J.E, Feinstein KA, Yousefzadeh DK et al., Sonographic demonstration of a normal thyroid gland excludes ectopic thyroid in patients with thyroglossal duct cyst. *AJR Am J Roentgenol*, 1995; 164(6): 1489-91.
- Machi J, Staren ED.(2005). *Ultrasound for Surgeons*. Lippincott Williams & Wilkins.
- Marqusee E, et al. ( 2005), Usefulness of ultrasonography in the management of nodular thyroid disease. *Ann Intern Med*. 133(9):696–700.[PubMed]
- MazzaferriEL,et al.( 1998), Solitary thyroid nodule: diagnosis and management. *Med Clin North Am* ,72:1177-211.
- Melmed, S; Polonsky, KS; Larsen, PR; Kronenberg, HM (2011). *Williams Textbook of Endocrinology* (12th ed.). Saunders. p. 331.
- Moore, K. and Agur, A. (2007) *Essential clinical anatomy*. Philadelphia: Lippincott Williams & Wilkins.
- P.E.S Palmer, 1995, *Manual of Diagnostic Medical Ultrasound*, California USA.
- Papini E, Guglielmi R, Bianchini A, et al,(2004), Risk of malignancy in nonpalpable thyroid nodules: predictive value of ultrasound and color Doppler features. *J ClinEndocrinolMetab* ;87:1941–1946. CrossRef, Medline

- Park M, Shin JH, Han BK, Ko EY, Hwang HS, Kang SS, Kim JH, Oh YL. Sonography of thyroid nodules with peripheral calcifications, J Clin Ultrasound. 2009 Jul-Aug;37(6):324-8.
- Peccin S, de Castro JA, Furlanetto TW, et al. (2005), Ultrasonography: is it useful in the diagnosis of cancer in thyroid nodules? J Endocrinol Invest ;25:39–43. CrossRef, Medline
- Popowicz B, Klencki M, Lewiński A, Słowińska-Klencka D, The usefulness of sonographic features in selection of thyroid nodules for biopsy in relation to the nodule's size, Eur J Endocrinol. 2009 Jul;161(1):103-11. Epub 2009 Apr 17.
- Richart.S.Snell, 2005, Clinical Anatomy for Medical Student – Mosby. 8<sup>th</sup>ed, New York, USA.
- Robbins SL, Kumar V, Abbas AK et-al. Robbins and Cotran. (2010). pathologic basis of disease. W.B. Saunders Company.
- S. Bastin, et al ( 2009), “Role of ultrasound in the assessment of nodular thyroid disease: radiology—review article,” Journal of Medical Imaging and Radiation Oncology, vol. 53, no. 2, pp. 177–187.
- Sharma R, Chakravarty KL, Tripathi M, Kaushik A, Bharti P, Sahoo M, Chopra MK, Rawat H, Misra A, Mondal A, Kashyap R, Role of 99mTc-Tetrofosmin delayed scintigraphy and color Doppler sonography in characterization of solitary thyroid nodules, Nucl Med Commun. 2007 Nov;28(11):847-51.
- Sohaib M1, Saeed S1, Naseeb HK1, Hyder SW2, Correlation of Single Image Tc-99m MIBI Scan and Ultrasonography with Fine Needle Aspiration Cytology (FNAC) to assess Neoplasia in Solitary “Cold” Thyroid Nodules, World J Nucl Med 2007;6:87-91
- Solbiati L, Charboneau JW, Osti V, James EM, Hay ID. The thyroid gland. In: Rumack CM, Wilson SR, Charboneau JW, editors. Diagnostic Ultrasound. 3rd ed. Vol. 1. St. Louis, Missouri: Elsevier Mosby; 2005. pp. 735–70.
- Standring, S. (2008) Gray`s anatomy. UK.
- Stephen Nussey and Saffron Whitehead (2001) . The thyroid gland in Endocrinology:, Published by BIOS Scientific Publishers Ltd. I
- Surks MI, Hollowell JG (December 2007). "Age-specific distribution of serum thyrotropin and antithyroid antibodies in the US population: implications for the prevalence of subclinical hypothyroidism". J. Clin. Endocrinol.
- Tan GH, Gharib H. (1997), Thyroid incidentalomas: management approaches to nonpalpable nodules discovered incidentally on thyroid imaging. Ann Intern Med. 126(3):226–231.[PubMed]

- Ugurlu S, et al.(2008), Evaluation of thyroid nodules in Turkish population. Intern Med. 47(4):205–209.[PubMed]
- Vikas Chaudhary and Shahina Bano1 Indian J EndocrinolMetab. Thyroid ultrasound 2013 Mar-Apr; 17(2): 219–227
- Walter F., PhD. Boron (2003) Medical physiology: A cellular And Molecular Approach, Chapter 48, "SYNTHESIS OF THYROID HORMONES" Elsevier/Saunders, pp. 1,300 ISBN: 1-4160-2328-3
- Weissleder R, Wittenberg J, M.D. MG et-al. (2010). Primer of Diagnostic Imaging. Mosby.

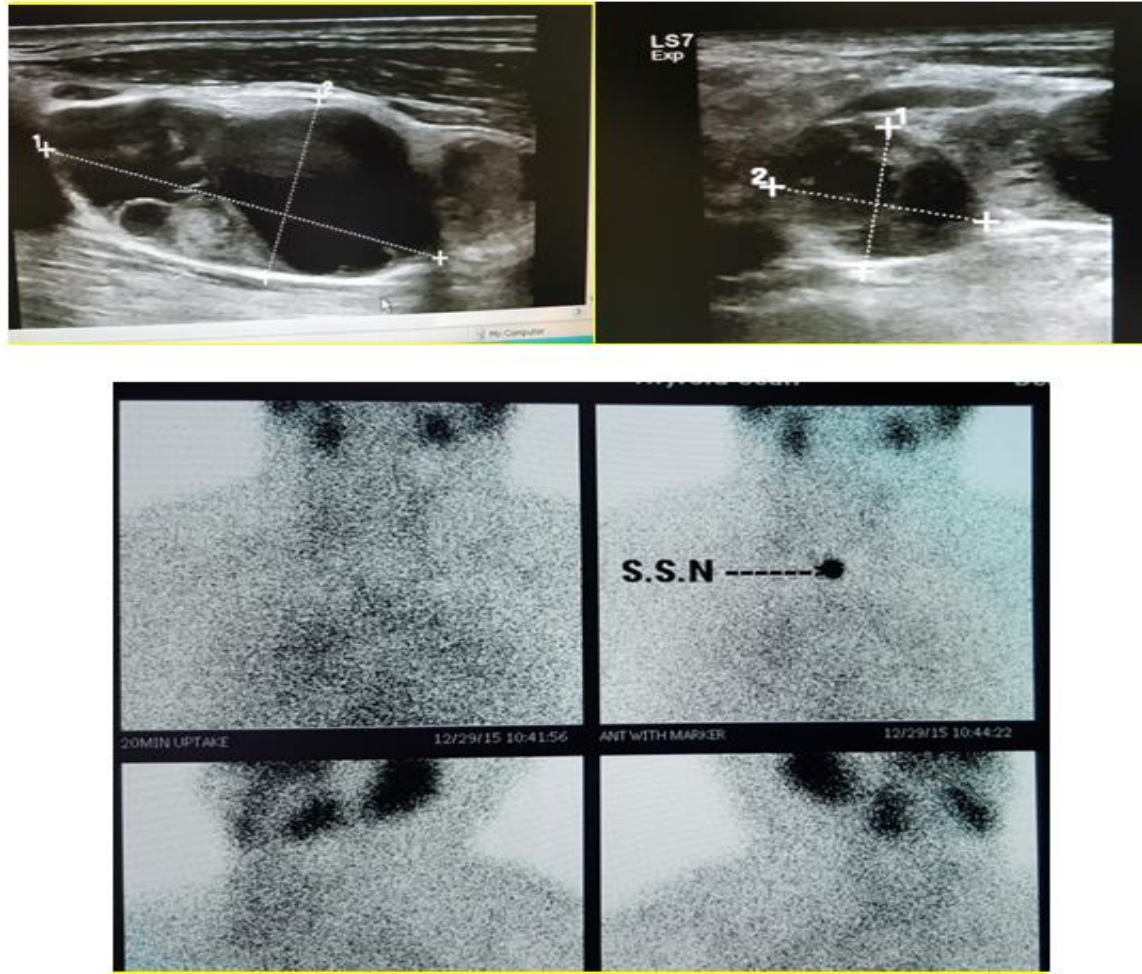
# Appendices

# **APPENDIX(A) DATA COLLECTION SHEET**

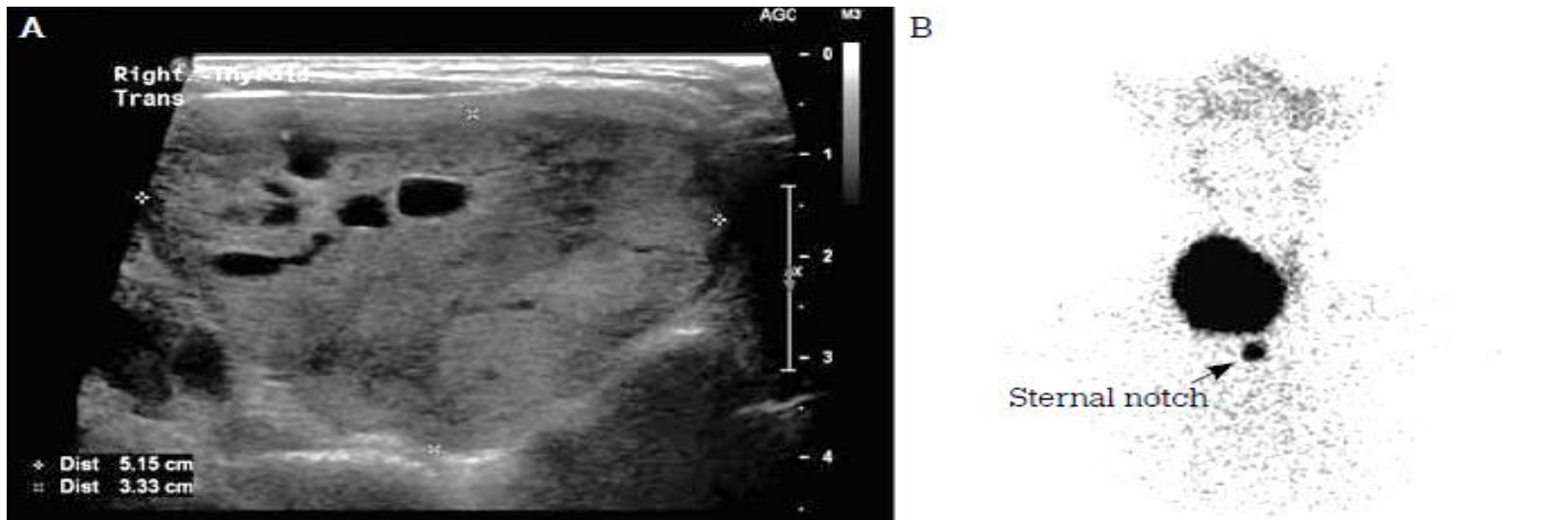




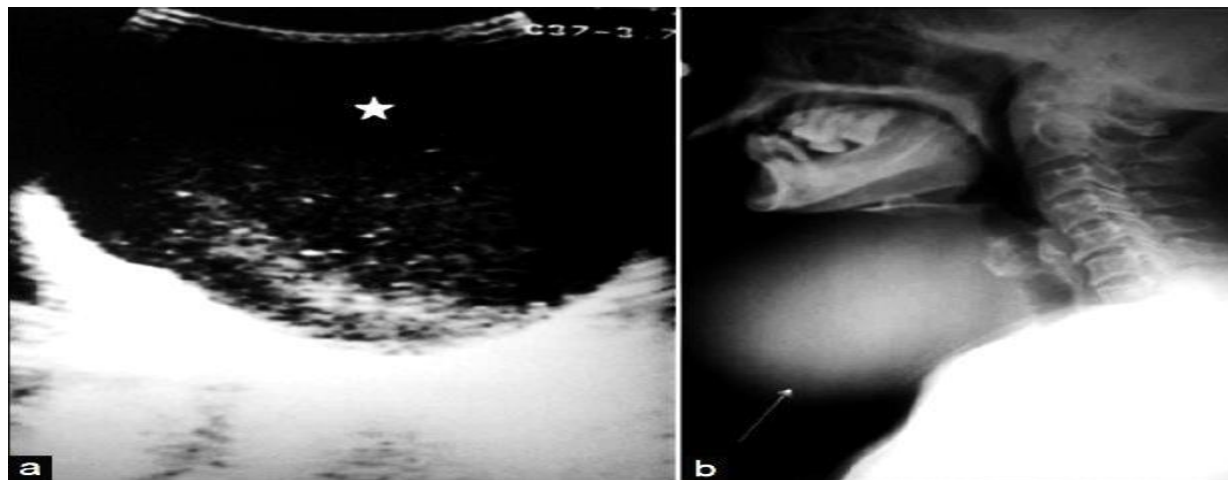
## **APPENDICIX (B) CASES**



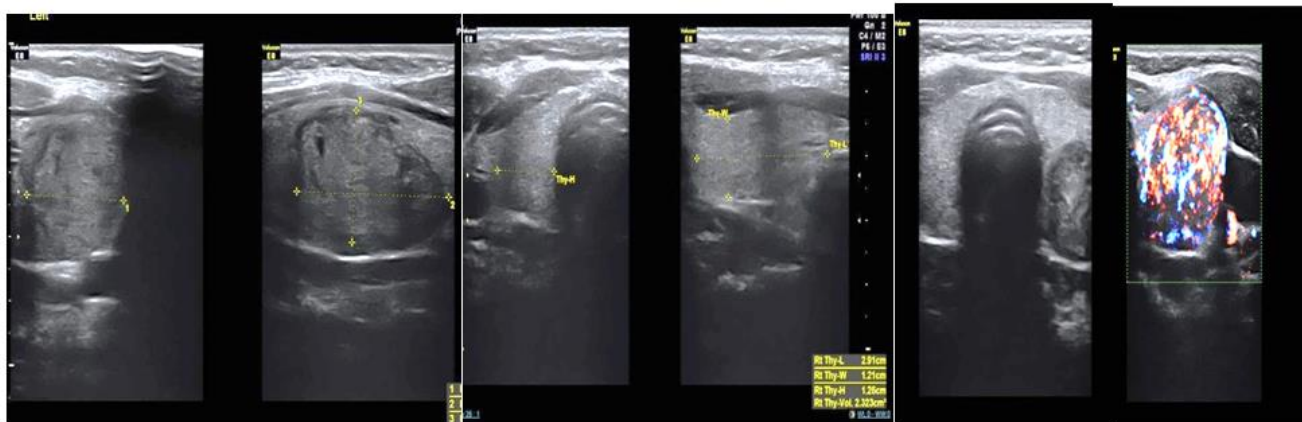
**Figure (1) Thyroid Ultrasound and thyroid scintigraphy of 70 years old man with swelling neck. High resolution planar nuclear medicine scan images show cold nodules. In Ultrasound it reported multinodular.**



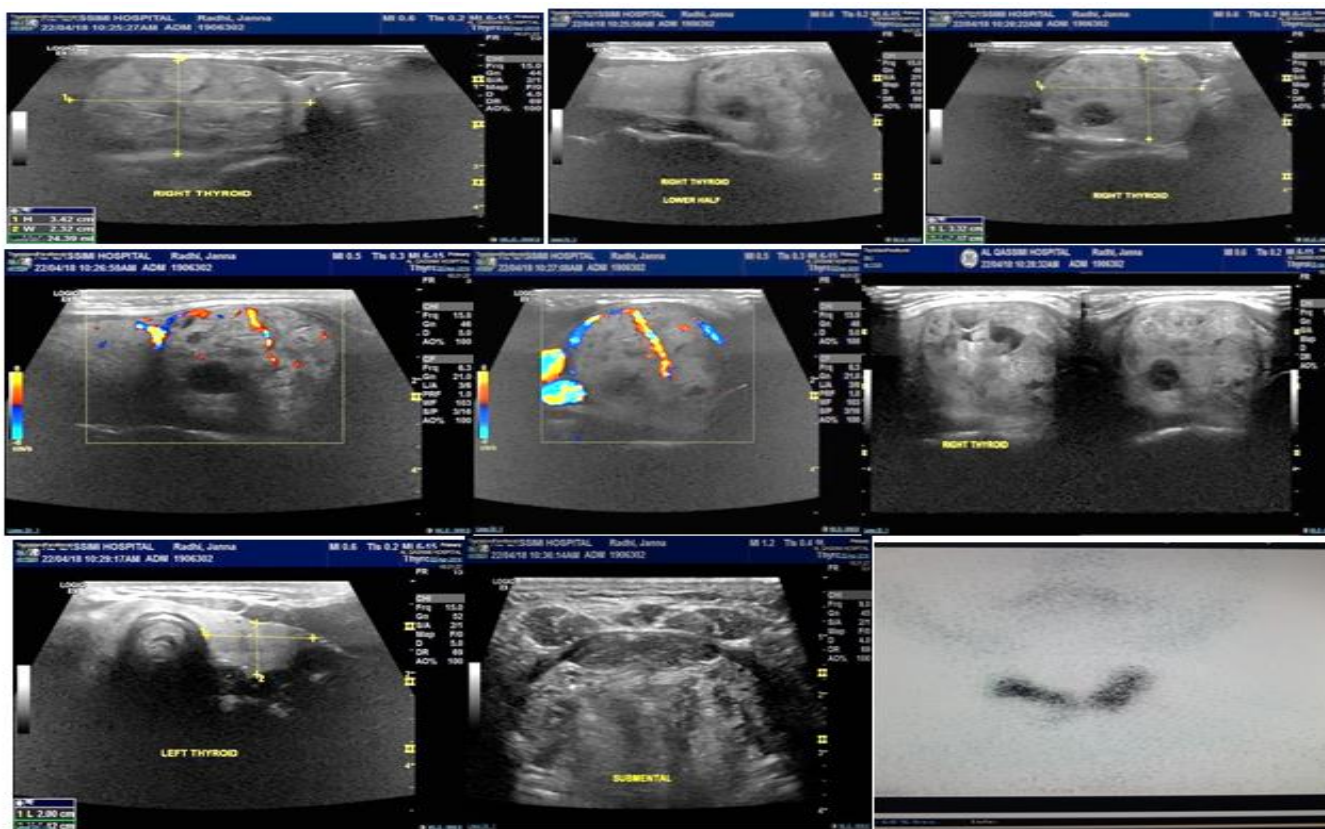
**Figure (2) Autonomous right lobe nodule. A large nodule (measuring over 5 cm in maximum dimension) was identified on ultrasound (A). The thyroid scan (B) showed it to be hyper functioning**



**Figure (3) Thyroglossal cyst in a patient who presented with midline neck swelling. Ultrasound neck (a) shows a well-defined anechoic cystic lesion with multiple low level internal echoes (asterisk) and posterior acoustic enhancement. Multiple low level internal echoes within the cyst may be due to hemorrhage or infection. X-ray neck lateral view (b) of the same patient shows large, soft tissue/cystic midline swelling (white arrow)**

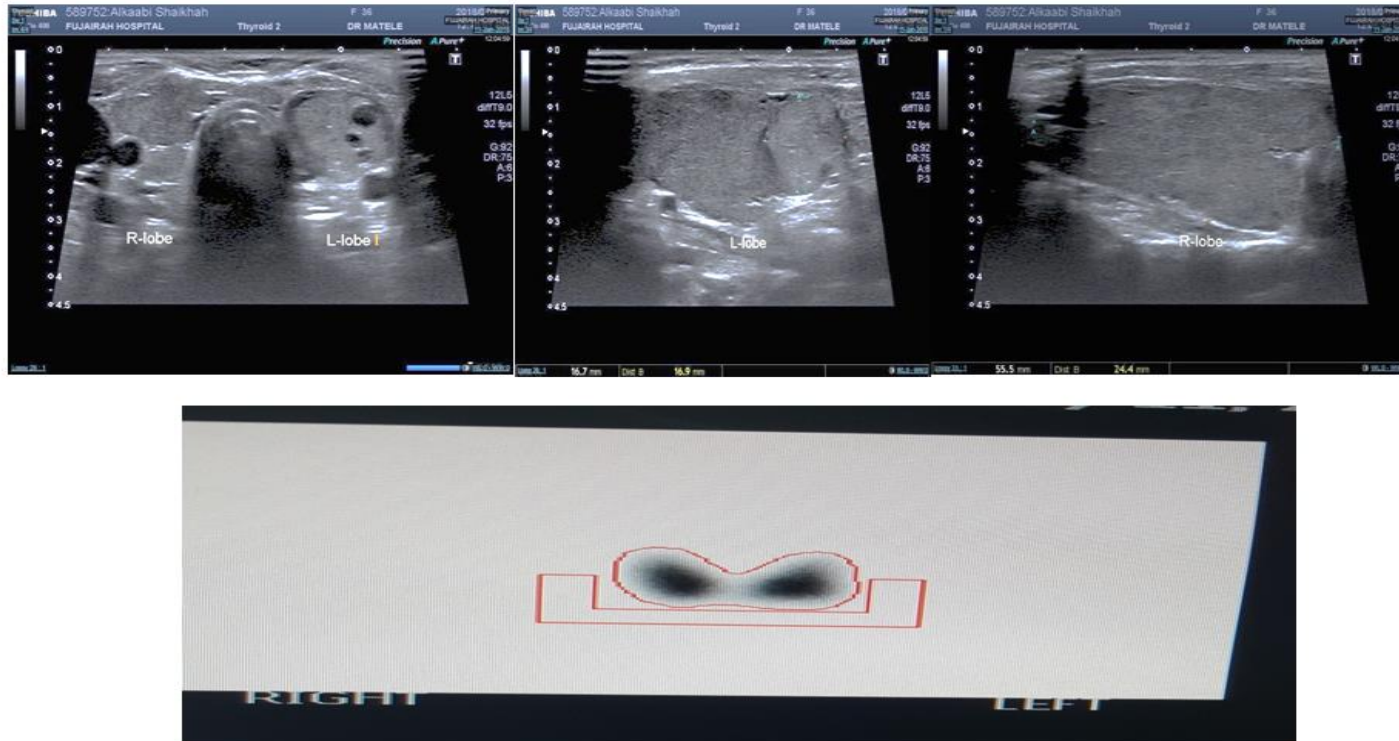


**Figure (4) 30 yrs. old lady Reason for Exam: left-sided neck swelling, ultrasound reveal The left lobe : Enlarged, occupied by a well-defined heterogeneous mass measuring about (1.9\*3\*2.1)cm showing prominent generalized vascularity and few areas of calcification. A hypoechoic halo seen surrounding it. Normal right lobe and isthmus. Few enlarged left cervical lymph nodes seen the largest at level 2 measuring about(2.5\*0.9)cm oval shaped with preserved fatty center and central vascularity. While nuclear medicine findings is Mildly Enlarged Goiter with Normal uptake values .**

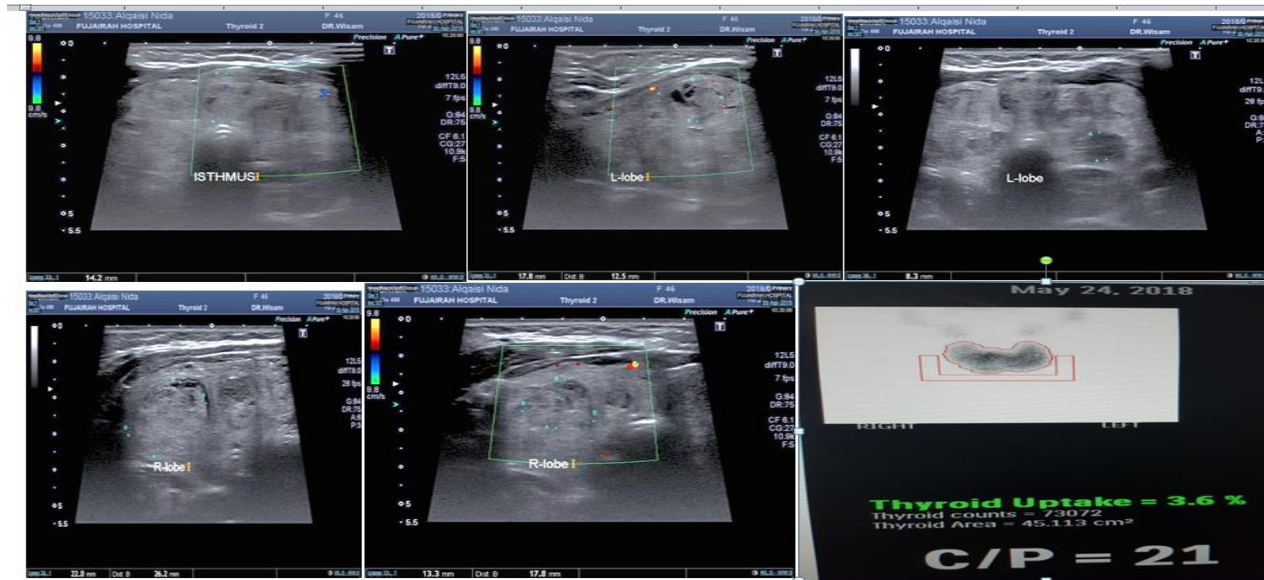


**Figure (5) 21 yrs. old female . reason for exam neck swelling; Right thyroid nodule with low TSH. Ultrasound findings right thyroid lobe inferior portion shows heterogeneous hyperechoic nodule of approximate size 3.3 x 2.5 cm with focal anechoic cystic region inside the nodule measuring 7 mm. no peripheral halo seen. no calcifications within. few submandibular nodes are observed . Nuclear med findings Cold Nodule over Right Thyroid Lobe. FNAC is suggestive.**



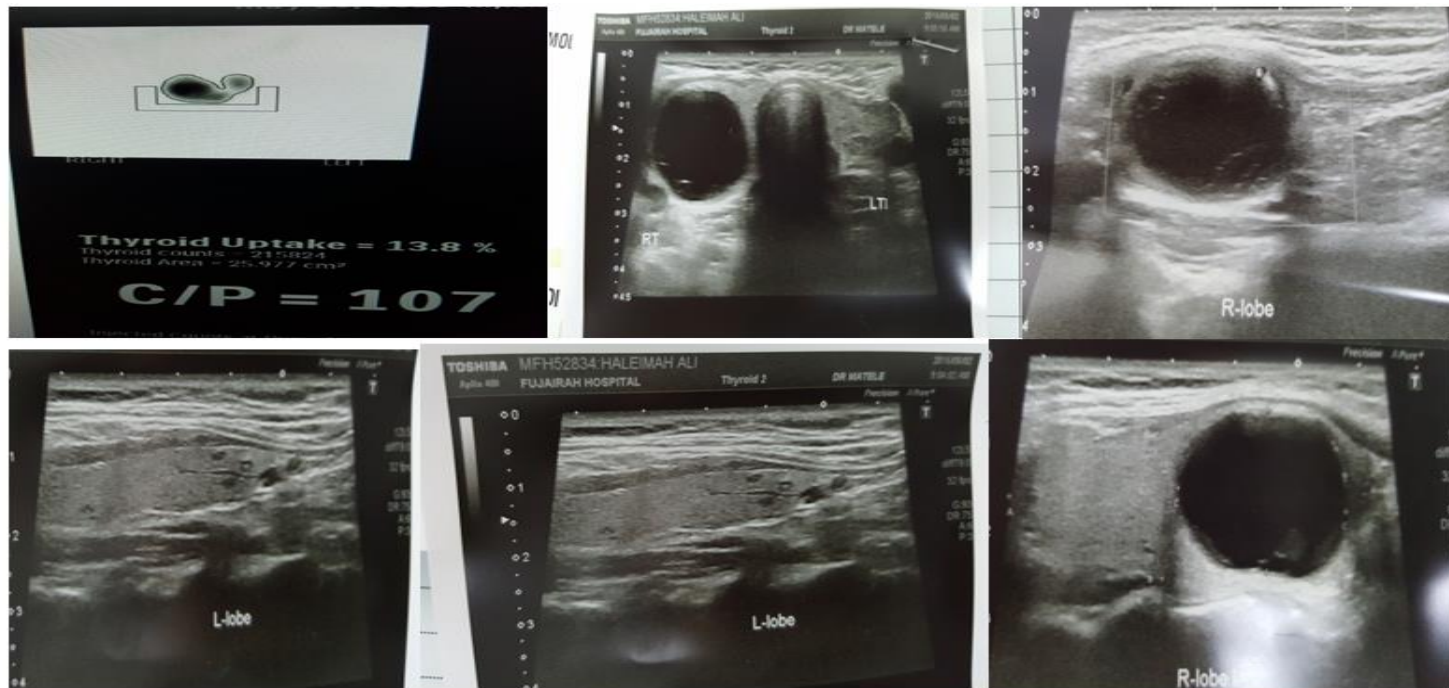


**Figure (6) 36 female patient ultrasound reveal A well-defined solid nodule is seen in the left lobe , having central cystic areas. adenoma with degeneration?. It measures 1.6 x 1.7 cms. While nuclear medicine Studies show Enlarged Thyroid Gland with Increased and Uniform Radiotracer Uptake throughout Both Thyroid Lobes Ranges: Uptake % =18.8 %(0.3-3.33 %), Counts/ Pixel=193(10-34)and Thyroid Area =28.829 cm<sup>2</sup>. Conclusion:Toxic Diffuse Goiter (Grave's Disease)**

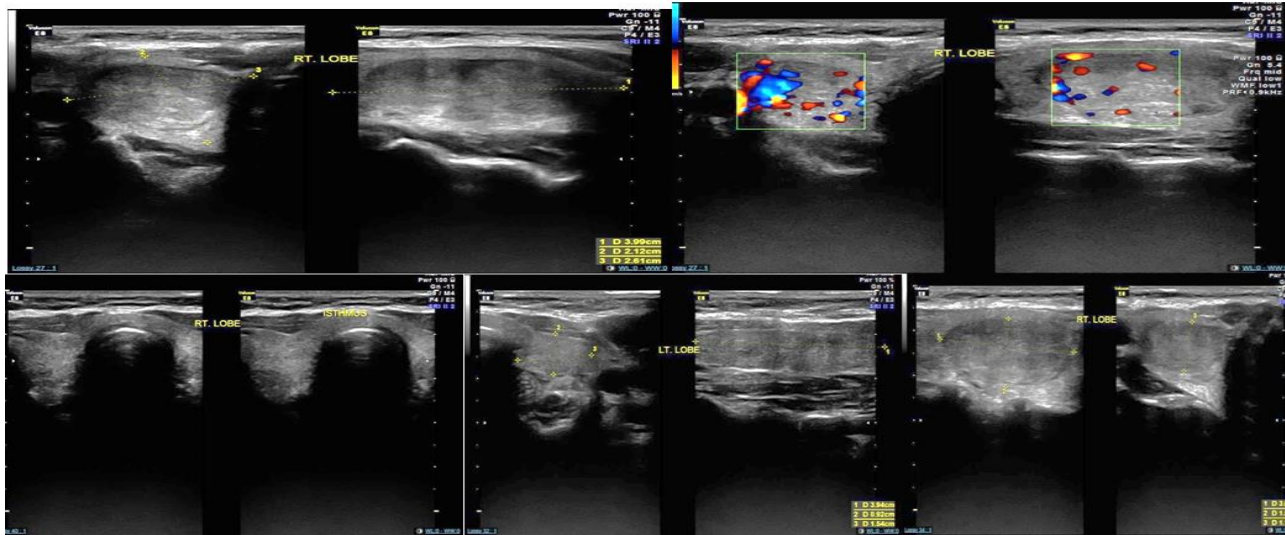


**Figure (7) 46 years old female, a case of thyrotoxicosis on irregular treat. since 2 years. The ultrasound shows -The gland is globally moderately enlarged , showing multiple various sizes nodules , that show some areas of break down, with one dominate on both lobes about 1.7 cm , with normal vascularity. that may suggest some multi-nodular goiter.-No cervical LN enlargement. While nuclear medicine Findings and Results: shows enlarged both lobes of thyroid gland which shows Non- uniform radiotracer uptake., Multiple hot and cold areas are noted in both lobes of thyroid gland Patient is a known case of hyperthyroidism and is on anti-thyroid medications. Conclusion is Toxic Multinodular Goiter**





**Figure (8) 32 female patient ultrasound Both lobes of the thyroid are mildly enlarged , right more than left. A cystic lesion with internal echoes , eccentric wall thickening and debris in the dependent portion , is seen in the right lobe. It measures 3.5 x 1.8 cm.. Pericystic increased vascularity is seen. ? hemorrhagic cyst ?? adenoma with cystic degeneration. Few tiny [ 3 to 5 mm.] hypoechoic nodules are also seen in both lobes. Rest grossly normal. While nuclear medicine Study shows Enlarged Right lobe of Thyroid Gland with evidence of high uptake. Conclusion is Toxic nodular Goiter.**



**Figure (9) 34 yrs. old female. Reason for Exam: thyroid swellings** Thyroid shows mildly enlarge right thyroid lobe measures 4x2.5x2cm. It showing well defined rounded shape solid hypo echoic nodule measures of about 2.5x1.5x1cm size and the nodule appear vascular on color Doppler study. Normal left thyroid lobe size shape and echogenicity. It is measures 3x1x1cm. Normal isthmus thickness and echogenicity , No enlarge lymph nodes seen. While nuclear medicine Study shows Enlarged Right lobe of Thyroid Gland with evidence of a well-defined Cold area at mid aspect of right Thyroid Lobe. FNAC is suggestive. Left Lobe shows normal and Uniform radiotracer uptake

- Uptake % = 0.8 % (0.3-3.33 %)
- Counts/ Pixel = 9 (10-34)
- Thyroid Area = 24.636 cm<sup>2</sup>

**Conclusion:** Cold nodule right mid thyroid Lobe. FNAC is suggestive.

## **APPENDIX(C) PUBLISHED PAPERS**

## Study of Thyroid Abnormalities using Scintigraphy

Amel Bushra. Ahmed<sup>1,2</sup>, Mohamed Yousef<sup>1,3</sup>, Salah Ali Fadhlalah<sup>1</sup>

<sup>1</sup>College of Medical Radiological Science, Sudan University of science and Technology, Sudan Khartoum

<sup>2</sup>Fujairah Hospital, Fujairah, UAE

<sup>3</sup>College of Batterjee Science College, Radiological Science, Jeddah, Saudi Arabia

Amel.Abakar@moh.gov.ae

### ABSTRACT

Radionuclide imaging is an integral part of functional evaluation of thyroid diseases. This study aimed to study thyroid abnormalities using scintigraphy, The study population consisted of 173(149 female and 24 male) patients with thyroid abnormalities, and referred to Nuclear Medicine, Fujairah hospital for thyroid scintigraphy during the period from Jan 10, 2016 to June 30, 2018. All patients Thyroid function test were done before coming to radiology department. The mean age of patients was 38 years.

The results of this study revealed that thyroid nuclear medicine scan findings as normal in 6.4 % (16 patients) and abnormal in 91% (157 patients) , Autonomous Nodule 2 (1.1),nodular goiter- NTG , TNG 30 (17.3%),Goiter11(6.4%),Grave disease13(7.5%), Multinodular goiter 43(24.8%), Thyroiditis 20 (11), Thyroid nodule 2 (1.1), Toxic multinodular goiter 21 ,Toxic goiter 15 (8.7%), Normal 16 (9.2%).

This study concluded that radionuclide methods are complementary and provide information that can help in the appropriate management of various thyroid diseases.

**Key words:** Scintigraphy, goitre, Graves' disease, thyroid nodule

### 1 Introduction

The thyroid gland is located in the neck, superior to the trachea and between the thyroid cartilage and sternal notch. The gland is relatively small, consisting of 2 lobes, each of which is approximately 2–3 cm wide by 5 cm high. <sup>[1]</sup>.

Thyroid gland has the unique ability to take up iodine — an essential component of its hormones. The phenomenon of accumulation of iodine in the thyroid gland allowed for the use of iodine isotopes in the diagnosis of thyroid disease as early as about 70 years ago, although the mechanism of iodine uptake at the molecular level has been carefully examined until the late twentieth century. In 1939, a group of scientists from the University of Berkeley documented the uptake of radioactive iodine in human thyroid for the first time. This gave rise to first therapeutic radioiodine applications in patients with hyperthyroidism and thyroid cancer <sup>[2, 3]</sup>. Nowadays, we know that the uptake of iodine in the thyroid gland is attributed to the sodium-iodide symporter (NIS), described in 1993 by Kaminsky et al <sup>[4]</sup>. The uptake of iodine by the thyroid cells is still widely used in the evaluation of thyroid function by means of

radioiodine uptake test and thyroid scintigraphy [5]. This study aimed to study thyroid abnormalities using scintigraphy

## 2 Materials and methods

A total of 173 patients were seen by surgeons and medical doctors as having thyroid issues, and referred to Nuclear Medicine and Radiology Department, Fujairah hospital for thyroid scintigraphy and neck ultrasound during the period from Jan. 10, 2016 to June. 30, 2018.

The thyroid scintigraphy obtained 10-20 minutes after intravenous injection of 37-111MBq of sodium pertechnetate Tc-99m using a LEHR (low energy high resolution collimator-equipped gamma-scintillation camera. All thyroid scintigraphies were interpreted by one Nuclear Medicine Physician. For ultrasound, all patients were scanned supine with their necks hyperextended using a 7.5-10-MHz transducer. All patients underwent neck ultrasound by one expert radiologist. The data analyzed using the SPSS program.

## 3 Nuclear medicine examination

Technetium 99m pertechnetate ( $^{99m}\text{TcO}_4^-$ ) is a used radioactive label for thyroid scanning. Injection Technique a fine Butterfly needle (gauge 23-25 according to patient's age) is recommended. Technetium-99m when used as a radioactive tracer can be detected in the body by medical equipment (gamma cameras). It is well suited to the role because it emits readily detectable 140 keV gamma rays (these are about the same wavelength as emitted by conventional X-ray diagnostic equipment), and its half-life for gamma emission is 6.0058 hours (meaning 93.7% of it decays to  $^{99}\text{Tc}$  in 24 hours). The "short" physical half-life of the isotope and its biological half-life of 1 day (in terms of human activity and metabolism) allows for scanning procedures which collect data rapidly, but keep total patient radiation exposure low. The same characteristics make the isotope suitable only for diagnostic but never therapeutic use.

## 4 Data Collection and Analysis

Data will be collected in tabulated database sheet and will be analyzed by SPSS. The data included the age, gender, US finding and Nuclear medicine scintigraphy findings

## 5 Results

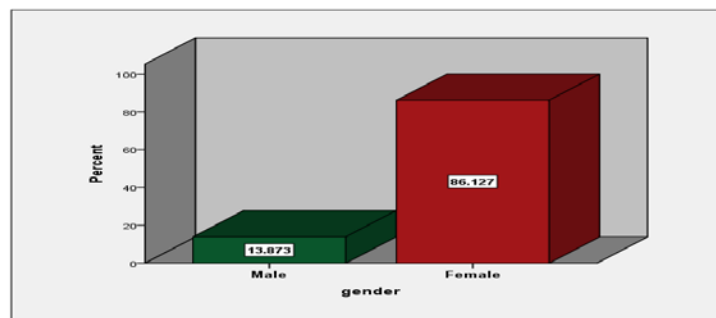


Figure 1 shows gender of the patients

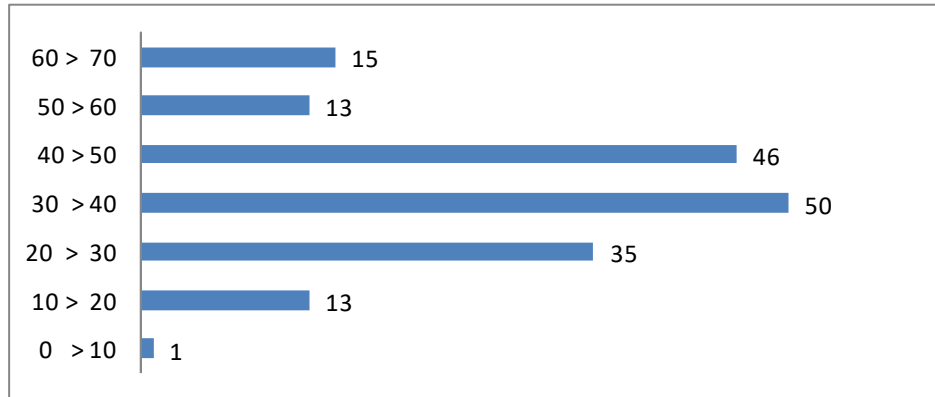


Figure 2 shows patient's ages

Table 1 shows NM findings

Thyroid disorders	Frequency
Autonomous Nodule	2 (1.1)
nodular goiter- NTG , TNG	30 (17.3%)
Goiter	11(6.4%)
Grave disease	13(7.5%)
Multinodular goiter	43(24.8%)
Thyroiditis	20 (11)
Thyroid nodule	2 (1.1)
Toxic multinodular goiter	21
Toxic goiter	15 (8.7%)
Normal	16 (9.2%)
total	173

Table 2 shows Nodules sites

Nodule site	Frequency
Lt lobe	63
Rt lobe	80
isthmus	19
Total	162

Table 3 shows Thyroid size

size	Frequency
Normal	49 (28%)
Enlarge	124 (72%)
Total	173 (100%)

## 6 Discussion

Nuclear scintigraphy is commonly used for evaluation of physiologic thyroid function and for identification of metabolically active and inactive nodules.

Nuclear medicine thyroid scan was performed by an Bright View gamma camera. Nuclear medicine classification based on distribution of the radioisotopes through the thyroid. Features were performed by one experienced nuclear medicine technologist. Size was measured as the whole diameter. The features included, homogeneity, uptake, count per pixel, and area.

The study population consisted of 173 patients were seen by surgeons and medical doctors as having thyroid issues, and referred to Nuclear Medicine and Radiology Department, Fujairah hospital for thyroid scintigraphy and neck ultrasound during the period from Jan. 10, 2016 to June. 30, 2018. All patients Thyroid function test were done before coming to radiology department. So all results were comparing with the TFT results.

nuclear medicine thyroid scintigraphy and demographic data are presented in Tables and figures for this study revealed that, among this 173 patients 86% were female (149) and 14% were male (24), fig(1). The mean age of patients was 38 years, thyroid nuclear medicine scan were reported as normal in 6.4% (16 patients) and abnormal in 91% (157 patients).

In this study table (1) shows that nuclear medicine is able to detect multi nodules in 43 patients. and if multi nodules are toxic, nuclear medicine is better in detecting it (21 patients) In diagnosis of Autonomous nodule nuclear scan was able to detect it In graves' disease nuclear medicine (13 patients) 7.5% in detecting it. For thyroiditis nuclear medicine, (25 patients) 14.4% to (20 patients) 11%. However in diagnosis of toxic goiter nuclear medicine thyroid scan was better than ultrasound, (15 patients) 8.7%

Table (2) shows the nodule sites in the Rt lobe, Lt lobe and isthmus, 80, 63, 19 in the thyroid nuclear medicine scan.

Table (3) shows that the thyroid gland size if its enlarge or not. In nuclear medicine thyroid scan it was enlarge in (124 patients) 72% of patients and normal in (49 patients) 28% of all cases.

In spite of some limitations of this, ultrasound examination plays an important role for patients in diagnosis of thyroid abnormalities, especially in thyroid nodules.

## 7 Conclusion

This study concluded that radionuclide methods can be able to provide information that can help in the appropriate management of various thyroid diseases.

## REFERENCES

- [1] Drew HH, LaFrance ND, Chen JS. Thyroid imaging studies. J Nucl Med Technol. 1987;15:79–87
- [2] Becker DV, Sawin CT. Radioiodine and thyroid disease: the beginning. Semin Nucl Med 1996; 26: 155–164.

- [3] Keston AS, Ball RP, Frantz VK, Palmer WW. Storage of radioactive iodine in a metastasis from thyroid carcinoma. *Science* 1942; 2466: 362–363.
  
- [4] Kaminsky SM, Levy O, Salvador C, Dai G, Carrasco N. The Na<sup>+</sup>/I symporter of the thyroid gland. *Soc Gen Physiol Ser* 1993; 48: 251–262.
  
- [5] Chung JK. Sodium iodide symporter: its role in nuclear medicine. *J Nucl Med* 2002; 43: 1188–1200.



## Diagnostic value of Ultrasonography and Scintigraphy in detection of Thyroid Lesions

Amel bushra. Ahmed<sup>1,2</sup>, Mohamed Yousef<sup>1,3</sup>, Salah Ali Fadlalah<sup>1</sup>

<sup>1</sup>College of Medical Radiological Science, Sudan University of science and Technology, Sudan Khartoum

<sup>2</sup>Fujairah Hospital, Fujairah, UAE

<sup>3</sup>College of Batterjee Science College, Radiological Science, Jeddah, Saudi Arabia

### Abstract

**Objective:** The present study was conducted to evaluate the thyroid gland lesions using scintigraphy and ultrasound

**Methods:** The study population included 101 patients who referred to Nuclear Medicine and Radiology Department, Fujairah hospital, Fujairah, UAE for thyroid scintigraphy and neck ultrasound.

**Results:** Ultrasound scan reported that 10% of subjects presented with normal and abnormal in 90 %, while thyroid nuclear medicine scan reported as normal in 13 % and abnormal in 87 % ,multi nodules in 49 of the patients while nuclear medicine scan is able to detect only 27 patients. For thyroiditis ultrasound better than nuclear medicine, (19 patients) 18.8% to (9 patients) 9% but for toxic multi nodular goiter nuclear medicine thyroid scan was better than ultrasound, (16 patients) 16 % to (1 patients) 1%. the ability of both modalities in detecting nodules.

**Conclusion:** Our results show that both modalities revealed almost similar results. Ultrasound has the additional advantages of being non-ionizing radiation and accurately localizes and characterizes the thyroid abnormalities. Ultrasound examination should be obtained routinely for patients with suspected thyroid diseases and scintigraphy is reserved for selected cases.

**Key Words:** Thyroid, Ultrasonography, Scintigraphy · Nodule, Diagnostic value

Date of Submission: 15-08-2018

Date Of Acceptance: 03-09-2018

### I. Introduction

Thyroid nodules are a common medical problem<sup>[1]</sup>. Although they are traditionally found as palpable masses at neck examination in patients with or without suspected thyroid disease, the apparent prevalence of non-palpable thyroid nodules (i.e. <1 cm in diameter) in the general population has recently increased, probably as a consequence of the increasing application of ultrasound<sup>[2-5]</sup>.

Thyroid nodular disease (TND) is one of the most widespread endocrine disorders. While only about 3 - 7% of the population display palpable nodules, thyroid lesions in ultrasound (US) examination are reported in a large part of population. The exact prevalence differs strongly among studies, oscilating from about 10 to about 70% of the adult population or even more in women, the elderly or patients with certain particular conditions, such as acromegaly<sup>[6-9]</sup> Most studies estimate the risk of malignancy as quite low, within the range from less than 3 to about 10%<sup>[10,11]</sup>. These facts indicate a great need for diagnostic tools allowing a reliable distinction of nodules representing a high risk of malignancy. The decision whether to conduct surgery or follow-up is taken on the basis of thyroid US together with US-guided FNAB. Power Doppler (PD) examination and elastography are additional sonographic techniques, which are believed to increase the diagnostic value of conventional US<sup>[12]</sup>.

### II. Materials and methods

A total of 101 patients referred to Nuclear Medicine and Radiology Department, Fujairah hospital for thyroid scintigraphy and neck ultrasound during the period from Jan. 10, 2016 to June. 30, 2018.

The thyroid scintigraphy obtained 10-20 minutes after intravenous injection of 37-111MBq of sodium pertechnetate Tc-99m using a LEHR (low energy high resolution collimator-equipped gamma-scintillation camera. All thyroid scintigraphy's were interpreted by one Nuclear Medicine Physician. For ultrasound, all patients were scanned supine with their necks hyperextended using a 7.5-10-MHz transducer. All patients underwent neck ultrasound by one expert radiologist. The data analyzed using the SPSS program. Scanning is done both in transverse and longitudinal planes. Real time imaging of thyroid lesions is performed using both

gray-scale and color Doppler techniques. The imaging characteristics of a mass (viz. location, size, shape, margins, echogenicity, contents and vascular pattern) should be identified.

**Data Collection and Analysis**

Data was collected in tabulated database sheet . The data included the age , gender, Us finding and Nuclear medicine scintigraphy findings

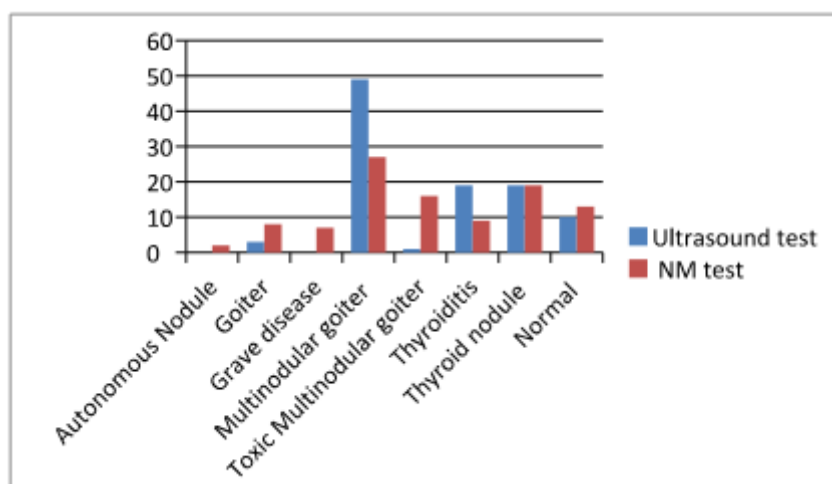
**III. Results :**

**Table (1) shows patients gender**

Patients	Numbers
Male	8
Female	93
Total numbers	101

**Table (2) shows patient’s ages**

Age group	Numbers of patients
0 > 15	5
16 > 30	26
31 > 45	44
46 > 60	20
61 > 75	5
76 > 90	1
Total	101



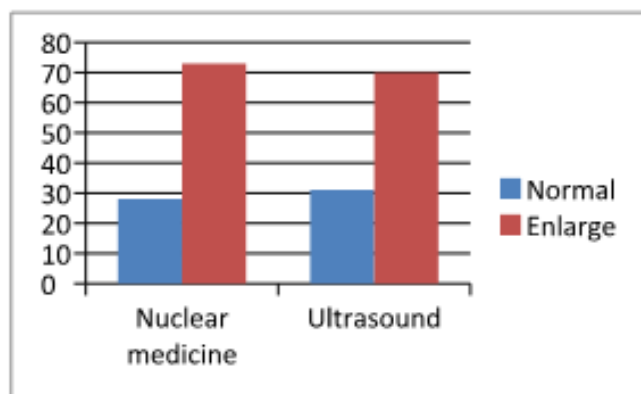
**Figure (1) shows ultrasound and nuclear medicine findings**

**Table 4 shows Nodules site in both investigations (thyroid scintigraphy and thyroid ultrasound)**

Nodule site	Scintigraphy	Ultrasound
Lt lobe	41	69
Rt lobe	49	66
isthmus	11	12
Total	101	146

**Table 5 Thyroid size in both investigations (thyroid scintigraphy and thyroid ultrasound)**

size	Nuclear medicine	Ultrasound
Normal	28 (28%)	31( 31%)
Enlarge	73 (72%)	70 (69%)
Total	101 (100%)	101 (100%)



**Figure 2 shows the thyroid gland sizes in both investigations.**

#### IV. Discussion

The study population consisted of 101 patients were referred to Nuclear Medicine and Radiology Department, Fujairah hospital for thyroid scintigraphy and neck ultrasound during the period from Jan. 10, 2016 to Jan. 10, 2018. All patients Thyroid function test were done before coming to radiology department. So all results were comparing with the TFT results.

Thyroid ultrasound, nuclear medicine thyroid scintigraphy and demographic data are presented in Tables and figures for this study revealed that, among this patients 92% were female (93) and 8% were male (8), table (1). The mean age of patients was 37.7 years, table (2). Thyroid ultrasound scan results were normal in 10% (10 patients) and abnormal in 90% (91 patients), while thyroid nuclear medicine scan were reported as normal in 13% (13 patients) and abnormal in 87% (88 patients) table (3).

In this study table (3) shows that ultrasound examination is able to detect multi nodules in 49 Of the patients while nuclear medicine scan is able to detect only 27 patients. However, when the nodule is solitary, the ultrasound and the nuclear medicine thyroid scan are same in detecting it. And if multi nodules are toxic, nuclear medicine is better in detecting it (16 patients) comparing to Ultrasound (1 patients). In diagnosis of Autonomous nodule nuclear scan was able to detect it while ultrasound couldn't detect it. In graves' disease Nuclear medicine was superior than ultrasound in detecting it, while ultrasound failed. For thyroiditis ultrasound was better than nuclear medicine, (19 patients) 18.8% to (9 patients) 9%. However in diagnosis of toxic multi nodular goiter nuclear medicine thyroid scan was better than ultrasound, (16 patients) 16% to (1 patients) 1%.

Table (5) shows the different sizes of patients thyroid glands. Which was enlarged in 73 patients (72%) in nuclear medicine and normal 28 patients (28%), while it was enlarged in 70 patients (69%) and normal in 31 patients (31%).

Table (6) shows the ability of both tests, thyroid ultrasound and nuclear medicine thyroid scan, in detecting nodules. Nuclear medicine was good in detecting solitary nodules in 25 patients more than ultrasound which detected in only 16 patients. Put when patient have multiple nodules, ultrasound was best in detecting nodules in 65 patients compare to nuclear medicine which detect nodules in only 34 patients. That means ultrasound have more sensitivity and specify than nuclear medicine in diagnosis of multinodular goiter diseases.

In all cases the ultrasound made the diagnosis in 90% (90 patients) more than nuclear medicine 87% (87 patients) by 3%, Table (3).

In spite of some limitations of this, ultrasound examination plays an important role for patients in diagnosis of thyroid abnormalities, especially in thyroid nodules.

Thyroid imaging is necessary to establish diagnosis, and it involves mainly thyroid ultrasound examination and scintiscan. Awareness of both the advantages and limitations of sonographic and scintigraphic imaging are central to the successful interpretation of their results and reasonable recommendation of these procedures for patients with thyroid diseases of different age and clinical picture.

#### V. Conclusion

Ultrasound can be able to evaluate the thyroid abnormalities especially multinodular goiter and thyroiditis. And have same ability as nuclear medicine scintigraphy in detecting solitary thyroid nodules, nodular goiter. When the ultrasound examination is performed by an experienced operator with high resolution equipment, it presents good accuracy in detecting thyroid abnormalities. Consequently, ultrasound can be used for evaluation and follow up. Thyroid scintigraphy examination would be indicated for patients with alterations in ultrasound examination or when there is a higher possibility of detecting new graves diseases or Toxic nodules because of it is his ability of making it is diagnosis.

### References

- [1]. Mandel SJ. A 64-year-old woman with a thyroid nodule, *JAMA* , 2004, vol. 292 (pg. 2632-42)
- [2]. Castro MR, Gharib H. Continuing controversies in the management of thyroid nodules, *Ann Intern Med* , 2005, vol. 142 (pg. 926-31)
- [3]. Mazzaferri EL. Management of solitary thyroid nodule, *N Engl J Med* , 1993, vol. 328 (pg. 553-9)
- [4]. Hegedus L. The Thyroid Nodule, *N Engl J Med* , 2004, vol. 351 (pg. 1764-71)
- [5]. Tan GH, Gharib H. Thyroid incidentalomas: management approaches to non-palpable nodules discovered incidentally on thyroid imaging, *Ann Intern Med* , 1997, vol. 126 (pg. 226-31)
- [6]. Tan GH, Gharib H (1997) Thyroid incidentalomas: management approaches to nonpalpable nodules discovered incidentally on thyroid imaging. *Ann Intern Med* 126: 226-231. doi:<https://doi.org/10.7326/0003-4819-126-3-199702010-00009>. PubMed: 9027275.
- [7]. Stančić J, Prpić M, Jukić T, Borić M, Kusić Z (2009) Thyroid nodularity - true epidemic or improved diagnostics. *Acta Clin Croat* 48: 413-418. PubMed: 20405636.
- [8]. Ruchala M, Szczepanek-Parulska E, Fularz M, Woliński K (2012) Risk of neoplasms in acromegaly. *Contemp Oncol (Pozn)* 16: 111-117.
- [9]. Zou S, Wu F, Guo C, Song J, Huang C et al. (2012) Iodine nutrition and the prevalence of thyroid disease after salt iodization: a cross-sectional survey in Shanghai, a coastal area in China. *PLOS ONE*. 7(7): e40718. doi:<https://doi.org/10.1371/journal.pone.0040718>. PubMed: 22911705.
- [10]. Carpi A, Rossi G, Romani R, Di Coscio G, Nicolini A et al. (2012) Are risk factors common to thyroid cancer and nodule? A forty years observational time-trend study. *PLOS ONE*. 7(10): e47758. doi:<https://doi.org/10.1371/journal.pone.0047758>. PubMed: 23118895.
- [11]. Choi YJ, Park YL, Koh JH (2008) Prevalence of thyroid cancer at a medical screening center: pathological features of screen-detected thyroid carcinomas. *Yonsei Med J* 49(5): 748-756. doi:<https://doi.org/10.3349/ymj.2008.49.5.748>. PubMed: 18972595.
- [12]. Ruchala M, Szczepanek E (2011) Thyroid ultrasound - a piece of cake? *Endokrynol Pol* 61(3): 330-344.

Amel bushra. Ahmed." Diagnostic value of Ultrasonography and Scintigraphy in detection of Thyroid Lesions". *IOSR Journal of Dental and Medical Sciences (IOSR-JDMS)*, vol. 17, no. 8, 2018, pp 47-50.