

Sudan University of Science and Technology
College of Graduate Studies

**Immunohistochemical Detection of CDX2 in Colorectal Cancer
among Sudanese Patients**

الكشف النسيجي الكيميائي المناعي عن سي دي أكس 2 في سرطان القولون والمستقيم
لدى المرضى السودانيين

A dissertation submitted for partial fulfillment for the requirements
of master degree in medical laboratory science
(Histopathology and Cytology)

By:

ALrayan Altahir Yagoub Birima
B.Sc. in Medical Laboratory Science
The National Ribat University(2014)

Supervisor:

Dr: Mohammed Siddig Abdelaziz

الآية

بسم الله الرحمن الرحيم

أَمِنَ الرَّسُولُ بِمَا أُنزِلَ إِلَيْهِ مِنْ رَبِّهِ وَالْمُؤْمِنُونَ كُلٌّ آمَنَ بِاللَّهِ وَمَلَائِكَتِهِ
وَكُتُبِهِ وَرُسُلِهِ لَا نَعْرِقُ بَيْنَ أَحَدٍ مِنْ رُسُلِهِ وَقَالُوا سَمِعْنَا وَأَطَعْنَا
عُفِّرَانِكَ رَبَّنَا وَإِلَيْكَ الْمَصِيرُ (285) لَا يَكْفُفُ اللَّهُ نَفْسًا إِلَّا وَسِعَهَا لَهَا مَا
كَسَبَتْ وَعَلَيْهَا مَا اكْتَسَبَتْ رَبَّنَا لَا تُؤَاخِذْنَا إِنْ نَسِينَا أَوْ أَخْطَأْنَا رَبَّنَا وَلَا
تَحْمِلْ عَلَيْنَا إِصْرًا كَمَا حَمَلْتَهُ عَلَى الَّذِينَ مِنْ قَبْلِنَا رَبَّنَا وَلَا تَحْمِلْنَا مَا لَا
طَاقَةَ لَنَا بِهِ وَاعْفُ عَنَّا وَارْحَمْنَا أَنْتَ مَوْلَانَا فَانصُرْنَا عَلَى
الْقَوْمِ الْكَافِرِينَ (286)

صدق الله العظيم

سورة البقرة الآيات (285-286)

Dedication

To my mother,

**A strong and gentle soul who taught me to trust in Allah,
believe in myself to reach the stars and fulfill my dreams**

To my father,

**My hero, who gave me the strength and courage to make
it through.**

To my beloved husband,

**I'm grateful for your support, your patience, and for
inspiring me to successes, help me to see the unique beauty
in imperfection .**

To my daughter,

**You are the answer to every time I looked up at the skies
and asked for a miracle .**

To my brothers ,and my sister,

Who always beside me for better and worse.

To my best friends,

Thank you for being in my life.

Acknowledgment

First of all, I am deeply grateful and thankful to (Allah) for helping and enabling me to do this work. Secondly I would like to note my gratitude to Dr. Mohammed Siddig for his supervision and advices.

This research took me almost a five month, by that time; I have met with great people who contribute in many ways came out with this projects. It is a pleasure to convey my gratitude to them all in my humble acknowledgment. Encouragement and guidance from the very early stage of this research as well as attending meetings and conferences. I'm really grateful for all of them more than they know.

Individual acknowledgment to my uncle Alzaki Mohammed Ali for his advice and support. I am grateful for the role of my colleagues in the Sudan university of Science and Technology, for their support and bright thoughts which came during scientific discussion also for their willingness in answering a lot of my questions, advice and crucial contribution.

My deep thank are extended to Ms.Nada Saleh for her advice and support also staff members of National Public Health Laboratory (Stack), also Ibn Seina hospitals for their well collaboration .Finally, I would like to thanks everyone that was important to the successful realization of this research, as well as expressing my apology to these who I could not mention personally one by one.

Abstract

This hospital based analytical retrospective case control study conducted at Ibn Sina hospital, National Public Health Laboratory (Stack) and Radiation and Isotopes Center Khartoum (RICK) and Sudan University of Science and Technology- College of Medical Laboratory Science during the period from March to July 2018. The study aimed to detect the CDX2 expression in colorectal tumors using immunohistochemistry.

Forty paraffin blocks were collected from patients previously diagnosed as colorectal tumors. 25(62.5%) samples were malignant and the remaining 15(37.5%) samples were benign.

The paraffin blocks were cut by rotary microtome then stained by immunohistochemistry method (new indirect Dako technique). The data obtained was analyzed using SPSS program version 11.5. Mean, frequency and chi square test were calculated.

The age of patients ranged between 32 to 85 years with mean age of 61 years. The study revealed that most of patients were more than 50 years representing (77.5%) 31 and the remaining 9 (22.5%) were less than 50 years.

The majority of the patients were males represented (60%) 24 and the remaining (40%)16 patients were females.

CDX2 expression showed positive result among malignant colorectal tumors in 5(12.5%) samples and negative expression in 20(50%) samples, while benign colorectal tumors showed positive result in 13(13%) samples and negative expression in 2(50%) samples. This result showed significant statistical association(P value 0.000).

The study concluded that the CDX2 expression is associated with benign colorectal tumors.

المستخلص:

أجريت هذه الدراسة المستشفوية التحليلية حالة وحالة ضابطة في مستشفى ابن سينا والمعمل القومي للصحة العامة (إستاك) و المركز القومي للعلاج بالأشعة والطب النووي وجامعة السودان للعلوم والتكنولوجيا , كلية علوم المختبرات خلال الفترة من مارس الى يوليو 2018. هدفت الدراسة لتحديد ظهور سي دي إكس 2 في أورام القولون والمستقيم باستخدام كيمياء الأنسجة المناعية.

جُمع أربعون قالب شمعي من عينات مرضى كانوا مشخصين مسبقاً بأورام القولون والمستقيم 25 (62.5%) منهم كانوا مشخصين أورام القولون الخبيثة و15 (37.5%) منهم أورام القولون الحميدة.

قطعت القوالب باستخدام المشراح الدوار وصبغت بواسطة كيمياء الأنسجة المناعية (بطريقة داكوالجديدة غير المباشرة) وتم تحليل البيانات باستخدام برنامج الحزم الإحصائية للعلوم الإجتماعية النسخة 11.5 لتحليل البيانات حسب المتوسط والتردد واختبار مربع كاي.

تراوحت أعمار المرضى بين 32 - 85 سنة بمتوسط عمر 61 سنة. أظهرت الدراسة أن معظم المرضى كانت أعمارهم أكبر من 50 سنة, وكان عددهم 31 مريضاً (77.5%) و9 مرضى (22.5%) كانت أعمارهم أقل من 50 سنة.

كان معدل الإصابة عند الذكور أعلى من الإناث ممثلاً 24 (60%) مريضاً و16 (40%) مريضاً من الإناث. وكان إفراز سي دي إكس 2 موجب الظهور مع أورام القولون والمستقيم فى 5 (12.5%) عينات وسالب الظهور فى 20 (50%) عينة بينما فى أورام القولون والمستقيم الحميدة كان موجب الظهور فى 13 (32%) عينة وسالب الظهور عينتين (50%) وكانت هنالك علاقة ذات دلالة إحصائية (القيمة الاحتمالية 0.000) .

خلصت الدراسة إلى أنه توجد علاقة ذات دلالة إحصائية بين إفراز سي دي إكس 2 وأورام القولون والمستقيم الحميدة.

List of contents

Contents	Page
الآية	VI
Dedication	VI
Acknowledgment	VI
Abstract	VI
المستخلص	VI
List of contents	VI
List of abbreviations	VI
List of tables	VI
List of microphotographs	VI
CHAPTER ONE: INTRODUCTION	
1.1 Introduction	1
1.2 Objectives	2
CHAPTER TWO: LITERATURE REVIEW	
2.1 Scientific background	3
2.2 Anatomy, physiology and histology of colorectal	3
2.3 Disorders of colon	5
2.3.1 Benign disorders	5
2.3.2 Precancerous changes of colorectal	6
2.3.3 Malignant disorders	6
2.3.3.1 Adenocarcinomas	6
2.3.3.2 Gastrointestinal stromal tumors	6
2.3.3.3 Lymphoma	6
2.3.3.4 Carcinoids	7
2.3.3.5 Sarcoma	7
2.4 Signs and symptoms of colorectal cancer	7
2.5 Risk factors of colorectal cancer	7
2.6 Diagnosis of colorectal cancer	9
2.7 Treatment of colorectal cancer	11
2.8. Tumor marker	12
2.8.1 CDX2 and its relation with colorectal	12
CHAPTER THREE: MATERIALS AND METHODS	
3.1 Materials	14
3.2 Methods	14
3.2.1 Study design	14
3.2.2 Study setting	14

3.2.3 Study samples	14
3.2.4 Immunohistochemical staining	15
3.2.5 Result interpretation	16
3.2.6 Data analysis	16
3.2.7 Ethical consideration	16
CHAPTER FOUR: RESULTS	
4 Results	17
CHAPTER FIVE: DISCUSSION	
5 Discussion	25
CHAPTER SIX: CONCLUSION AND RECOMMENDATIONS	
6.1 Conclusion	26
6.2 Recommendations	26
References	27
Appendices	32

List of abbreviations

CRC	Colorectal cancer
CDX2	Caudal type homeobox 2
ENUS	Endorectal ultrasound
MRI	Magnetic resonance imaging
IBD	Inflammatory bowel disease
UC	Ulcerative colitis
FAP	Familial adenomatous polyposis
HNPCC	Hereditary nonpolyposis colorectal cancer
GIST	Gastrointestinal stromal tumors
FOBT	Fecal occult blood test
CT	Computed tomography
UT	Ultra sound
PET	Positron emission tomography
IHC	Immunohistochemistry
DAB	3,3-diaminobenzidine tetra hydrochloride
Spss	Statistical package for social science

List of Tables

Tables	Pages
4.1: Distribution of histopathological diagnosis among the study population samples	18
4.2: Frequency of age group among the study population	19
4.3: Frequency of sex among the study population	20
4.4: Frequency of cancer grade among study samples	21
4.5: Relation between CDX2 expression and histopathological diagnosis	22

List of microphotographs

Microphotograph NO.	Title	Page
Microphotograph (4.1)	Colon tubular adenoma show negative expression of CDX2(40X)	23
Microphotograph(4.2)	Colon moderately differentiation adenocarcinoma show Positive expression of CDX2(40X)	24

CHAPTER ONE
INTRODUCTION

CHAPTER ONE

INTRODUCTION

1.1 Introduction:

Cancer of the colon is the disease characterized by the development of malignant cells in the lining or epithelium of the first and longest portion of the large intestine. Malignant cells have lost normal control mechanisms governing growth. These cells may invade surrounding local tissue, or they may spread throughout the body and invade other organ systems (Abeloff , *et al.* 2013).

Colorectal carcinoma is the most common malignancy of the gastrointestinal tract. Colorectal cancer is a major cause of morbidity and mortality throughout the world (Hagggar and Boushey, 2009).

Worldwide it is third most common cancer and the fourth most common cause of death .Countries with the highest incidence rates include Australia ,New Zealand ,Canada the United States ,and part of Africa and South America (Hagggar and Boushey, 2009).

Colorectal cancer in Sudan was found more in young age groups with a peak frequency at the fifth and sixth decades (Taha, *et al.* 2015).

Risk factor are associated with colorectal cancer include family history, hereditary (Amersi, *et al.* 2015).

Methods of colorectal cancer diagnosis include colonoscopy, computed tomography (CT or CTC), Magnetic resonance imaging (MRI), Endorectal ultrasound (ERUS) (De Rosa, *et al.* 2015).

The treatment of colorectal cancer depend on several factors, such as race, age, and stage at diagnosis (Amersi , *et al.* 2005). Surgery is the first treatment option

for early stage to provide cure, Adjuvant chemotherapy with the aim of eradicating any micrometastatic residual disease following surgery (Kordatou, *et al.* 2014).

The caudal type homeobox 2 (CDX2) genes is a homeobox gene that encodes a protein that functions as a nuclear transcriptional factor. It plays a role in regulating the development and differentiation of the embryonic intestinal epithelium by activating intestine-specific proteins (Drummond, *et al.* 1997).

Among normal adult tissues, CDX2 protein is strongly and diffusely produced in all intestinal epithelial cells, including tissue from the duodenum to the distal rectum, it has been found in intestinal metaplasia occurring in the stomach, oesophagus, gall bladder, and urinary bladder (Barros, *et al.* 2011).

Due to its relative specificity for the gastrointestinal tract, the use of anti-CDX2 antibodies has become part of the immunohistochemistry panel for carcinomas of unknown primary origin, and it is accepted as being highly sensitive for the identification of colorectal adenocarcinomas CDX2 will stain the nuclei brown (Bakaris, *et al.* 2008).

1.2 Objectives:

1.2.1 General objective:

- To detection of CDX2 in colorectal cancer among Sudanese patients .

1.2.2 Specific objective:

- To detect immunohistochemical expression of CDX2 tumor markers in colorectal tumors and correlation with histopathology diagnosis.

CHAPTER TWO
LITERATURE REVIEW

CHAPTER TWO

LITERATURE REVIEW

2.1. Scientific back ground:

Colon cancer or bowel cancer is a cancer from uncontrolled cell growth in the colon or rectum or in the appendix (Cancer Genome, 2012).

Colorectal cancer is third most common cancer among both men and women.

A colorectal cancer begins when normal cell in the lining of the colon or rectum change and grows uncontrollably forming a mass called tumor. Colorectal cancer is one of the most prevalent and incident cancer worldwide, and is one of the most deadly (Binefa, *et al.* 2014).

Colorectal cancer (CRC) is the most common cancer in the Western world. The lifetime risk for developing CRC is ~ 6%, with a 5 year survival of ~55%.

Most of patients are diagnosed with CRC above the age of 70 years (Van Wezel, *et al.* 2012).

2.2 Anatomy, physiology and histology of colorectal:

2.2.1 The large intestine:

The large intestine which is about 1.5m (5ft) long and 6.5cm (2.5inch.) in diameter in living humans and cadavers, extends from the ileum to the anus. It is attached to the posterior abdominal wall by its mesocolon, which is a double layer of peritoneum. Structurally, the four major regions of the large intestine are the cecum, colon, rectum, and anal canal (Tortora and Derrickson, 2014).

2.2.2 Cecum:

The large intestine begins in a blind pouch called the cecum. Attached to the lower end of the cecum is a tubular organ called the appendix (Thompson, 2015).

2.2.3 Colon:

The parts of the colon are either in the abdominal cavity (intraperitoneal) or behind it in the retroperitoneum. Retroperitoneal organs in general do not have a complete covering of peritoneum, so they are fixed in location. Intraperitoneal organs are completely surrounded by peritoneum and are therefore mobile Peritoneum (Schünke, *et al.* 2009).

The colon include ascending colon, descending colon and rectum are retroperitoneal, while the caecum, appendix, transverse colon and sigmoid colon are intraperitoneal, The colon has the typical histological structure as the digestive tube mucosa, submucosa, muscularis and serosa adventitia. The mucosa is lined by simple columnar enterocytes (lamina epithelialis) with long microvilli. It is covered by a layer of mucus which aids the transport of the feces. The mucosa does not contain villi but many crypts of Lieberkuhn in which numerous goblet cells and enteroendocrine cells are found. The connective tissue layer (lamina propriae mucosae) is filled with macrophages, plasma cells and other immune cells. The submucosa comprises blood vessels, lymph nodes and particularly fat tissue. The inner circular musculature of the muscularis is strongly pronounced whereas the outer longitudinal musculature is practically only found in the taeniae (Drenckhahn, *et al.* 2008).

The main task of the colon is the temporary storage and transport of the feces. Thereby it daily absorbs about 1 liter of water which leads to a thickening of the stool. Furthermore it absorbs sodium, potassium and chloride but can also secrete potassium into the lumen itself. The physiological intestinal flora is rich in anaerobic bacteria (approx. 10¹¹/g) which live in symbiosis with the human body.

They fulfill essential functions such as decomposing indigestible food ingredients (e.g. cellulose), producing vitamin K, promoting the intestinal peristalsis and supporting the immune system (Drenckhahn, *et al.* 2008).

2.2.4 Rectum:

The rectum is the final straight portion of the large intestine. The human rectum is about 12 centimetres long, and begins at the rectosigmoid junction (the end of the sigmoid colon), at the level of the third sacral vertebra or the sacral promontory depending upon what definition is used. The rectum presents three or more lateral curvatures, which correspond to transverse rectal folds in the interior of the gut. The rectum has neither mesentery nor haustra, and it has almost complete outer longitudinal muscular coat rather than teniae (Guyto and Hall, 2000).

The main function of the rectum is to act as a temporary storage site for fecal matter before it is eliminated from the body through the anal canal. The rectum holds the feces until push it out of the body, through the anal canal, by having a bowel movement (Ross, *et al.* 1994).

2.3 Disorders of colon:

2.3.1. Benign disorders:

Inflammatory bowel disease (IBD), ulcerative colitis (UC) and crohn's colitis, diverticular Disease, are at increased risk of developing colorectal cancer (CRC) , CRC risk in IBD appears to be related more to chronic inflammation of the gastrointestinal mucosa than to any clear-cut genetic predisposition. It also has another disease called hereditary syndromes of familial adenomatous polyposis (FAP) and hereditary nonpolyposis colorectal cancer (HNPCC) (Itzkowitz and Yio, 2014) .

2.3.2 Precancerous changes of colorectal:

Polyps any mass protruding arise from the mucosal layer of gastro intestinal organ. Colorectal polyps may be histologically classified as neoplastic and hyperplastic (Shussman and Wexner, 2014).Colorectal adenoma is the most frequent precancerous lesion. Adenomas classifies intotubular, tubulovillous and villous (Conteduca, *et al.* 2013).

2.3.3 Malignant disorders:

2.3.3.1 Adenocarcinomas:

The majority of colorectal cancers (CRCs) are classified as adenocarcinoma and account for about 90-95% of all colorectal cancers are adenocarcinomas and have two subtypes, mucinous and signet ring cell. The mucinous subtype comprises about 10-15% of adenocarcinomas while the signet ring cell subtype comprises less than 0.1 % of adenocarcinomas (Hugen, *et al.* 2016).

Younger patients, larger tumors, higher rates of lymph node metastasis, and peritoneal metastasis were correlated with mucinous adenocarcinoma histology when compared to non- mucinous adenocarcinoma histology (Numata, *et al.* 2012).

2.3.3.2 Gastrointestinal stromal tumors (GIST):

These are tumors that start in specialized cells in the wall of the digestive tract called the interstitial cells of Cajal. These tumors may be found anywhere in the digestive tract, although they rarely appear in the colon. Surgery is the usual treatment if the tumor has not spread (Varmus, 2010).

2.3.3.3 Lymphoma:

Lymphoma is a cancer that typically starts in a lymph node, which is part of the immune system. It can also start in the colon, rectum, or other organs (Varmus, 2010).

2.3.3.4 Carcinoids:

Carcinoids are tumors that start in special hormone, producing cells in the intestine. Often they cause no symptoms at first. Surgery is the usual treatment (Varmus, 2010).

2.3.3.5 Sarcoma:

Sarcoma tumors that start in blood vessels, muscle, or connective tissue in the colon and rectum wall (Varmus, 2010).

2.4 Signs and symptoms of colorectal cancer:

Symptoms of colorectal cancer are numerous and nonspecific. The right sided lesions, were less well defined and included vague abdominal pain, palpable abdominal mass, weight loss, anemia and occult blood in the stool. The commonest symptom for rectal mucinous carcinoma was rectal bleeding, followed by mucous discharge or “slimy stools” and rectal pain. For sigmoid mucinous carcinomas, abdominal pain or signs of intestinal obstruction were most prominent. Symptoms of sigmoid and rectal mucinous carcinomas averaged 5 months in duration, while those of right sided tumors, averaged 8 months (Daniel, *et al.* 1998).

2.5 Risk factors of colorectal cancer:

Risk factors associated with colorectal cancer include age and hereditary factors. In addition, a substantial number of environmental and lifestyle .The risk factor may play an important role in the development of colorectal cancer (Haggard and Boushey, 2009).

2.5.1 Age:

The colorectal cancer diagnosis increases after the age of 40, increases progressively from age 40, rising sharply after age 50. More than 90% of colorectal cancer cases occur in people aged 50 or older. The incidence rate is more than 50 times higher in persons aged 60 to 79 years than in those younger than 40 years (Hagggar and Boushey, 2009).

2.5.2 Inherited genetic:

Approximately 5 to 10% of colorectal cancers are a consequence of recognized hereditary conditions. The most common inherited conditions are familial adenomatous polyposis (FAP) and hereditary nonpolyposis colorectal cancer (HNPCC), also called Lynch syndrome. Genes responsible for these forms of inherited colorectal cancer have been identified. HNPCC is associated with mutations in genes involved in the DNA repair pathway, namely the MLH1 and MSH2 genes, which are the responsible mutations in individuals with (HNPCC). (FAP) is caused by mutations in the tumor suppressor gene APC (Hagggar and Boushey, 2009).

2.5.3 Nutritional practices:

Diet strongly influences the risk of colorectal cancer, and changes in food habits might reduce up to 70% of this cancer burden. Diets high in fat, especially animal fat, are a major risk factor for colorectal cancer. High meat consumption has also been implicated in the development of colorectal cancer (Hagggar and Boushey, 2009).

2.5.4 Heavy alcohol consumption:

As with smoking, the regular consumption of alcohol may be associated with increased risk of developing colorectal cancer. Alcohol consumption is a factor in the onset of colorectal cancer at a younger age, as well as a disproportionate increase of tumors in the distal colon. Reactive metabolites of alcohol such as Acetaldehyde can be carcinogenic. There is also an interaction with smoking. Tobacco may induce specific mutations in DNA that are less efficiently repaired in the presence of alcohol. Alcohol may also function as a solvent, enhancing penetration of other carcinogenic molecules into mucosal cells. Additionally, the effects of alcohol may be mediated through the production of prostaglandins, lipid peroxidation, and the generation of free radical oxygen species. The high consumers of alcohol may have diets low in essential nutrients, making tissues susceptible to carcinogenesis (Haggard and Boushey, 2009).

2.6 Diagnosis of colorectal cancer:

2.6.1 Colonoscopy:

Colonoscopy is the best choice for screening high-risk populations, as it allows simultaneous detection and removal of preneoplastic lesions. Colonoscopy is considered the standard for colon evaluation and it is time consuming. (Yee, 2002). Colonoscopy allows for greater diagnostic specificity and sensitivity compared with other types of examinations and it plays an important role in the prevention and removal of adenomatous polyps (Lee, *et al.* 2014).

2.6.2 Fecal occult blood test:

Fecal occult blood test (FOBT) screening improves detection of colorectal cancer at the first screening round (Paimela, *et al.* 2010).

2.6.3 Barium enema:

Barium enema is an equivalent option for colorectal cancer screening of the general population and high risk patients (Seth, 2000).

2.6.4 Imaging techniques:

2.6.4.1 Computed tomographyscan (CT scan):

Computed tomography is not routinely performed for detection of colon cancer, CT is useful for detect tumor into adjacent organs or distant metastases, staging, treatment planning and follow-up (Horton, *et al.* 2000). The advantages of CT are that it presents minimal risk to patients, has a short procedure time (about 10 minutes) (Yee, 2002)

2.6.4.2 Ultra sound (US):

Abdominal ultrasound presents high sensitivity and specificity in the diagnosis of colon cancer (Martinez, *et al.* 2005).

2.6.4.3 Positron emission tomography (PET) scan:

Positron emission tomography (PET) with 18F-fluorodeoxy, (FDG) is a functional imaging modality that provides mapping of glucose metabolism in the whole body and highly accurate in detecting early localized tumor recurrence with high sensitivity and specificity (Nachar, 2002).

2.6.4.4 Magnetic resonance imaging (MRI):

MRI is the recommended modality for initial staging, due to its high accuracy for the definition of localization, determining the total extension and the relationship of the tumor to the peritoneal reflection (Kekelidze, *et al.* 2013).

2.6.5 Immunohistochemistry (IHC):

Immunohistochemical stains is a method for localizing specific antigens in tissues or cells based on antigen–antibody recognition; it seeks to exploit the specificity provided by the binding of an antibody with its antigen at a light microscopic level (Dabbs, 2013). (IHC) Were became more important in determining the origin and differentiation of gastrointestinal tract tumors use many marker for this aim such as CK7, CK20, MUC1, MUC2 and MUC5AC (Wong and Chu, 2012).

2.7 Treatment of colorectal cancer:

2.7.1 Surgery:

Stage 0 colon cancer may be treated by removing the cancer cells. This is done using colonoscopy. For stages I, II, and III cancer, more extensive surgery is needed to remove the part of the colon that is cancerous. This surgery is called colon resection (Pezner, *et al.* 1999).

2.7.2 Chemotherapy:

Almost all patients with stage III colon cancer should receive chemotherapy after surgery for 6 - 8 months. This is called adjuvant chemotherapy (Pezner, *et al.* 1999).

2.7.3 Radiation:

It is usually used in combination with chemotherapy for patients with stage III rectal cancer. For patients with stage IV disease that has spread to the liver, treatments directed at the liver can be used (Pezner, *et al.* 1999).

2.7.4 The follow-up care for colon cancer:

The cancer can come back near the original site, although this is unusual. If the cancer returns, it typically does so in a distant location such as the lymph nodes, liver, or lungs. Individuals diagnosed with colorectal cancer remain at risk of their cancer returning for up to 10 years after their original diagnosis and treatment (Pezner, *et al.* 1999).

2.8 Tumor markers:

Tumor markers are substances secreted by the neoplastic cells (benign and malignant) in the body. They can be detected in circulation, urine or body fluids or/and within tumor cells. The tumor markers are macromolecules who are appearance and changes in concentration are related in certain way to the genesis and growth of the tumors in the individuals. They are classified as growth proteins, growth factors enzyme, oncofetal proteins oncogene antigens glycolipids (Proc Soc, 1997).

2.8.1 Caudal – related homologue 2(CDX2):

CDX2 is a homeobox domain-containing transcription factor that is important in the development and differentiation of the intestines. CDX2 expression is immunohistochemically detectable in normal colonic enterocytes and is retained in most, but not all, colorectal adenocarcinomas. CDX2 expression has also been documented in a subset of adenocarcinomas arising in the stomach, esophagus and ovary. CDX2 expression is clinically useful as a relatively specific marker for epithelial neoplasms of the gastrointestinal tract, particularly colon and rectum (Kaimaktchiev, *et al.* 2004).

CDX2 plays a critical role in the regulation of cell proliferation and differentiation, especially in the intestine. The loss of expression of CDX2 protein may play an important role in the tumorigenesis of colorectal cancers. Down-regulation of CDX2 may cause dedifferentiation of gastrointestinal epithelial cells (Suh, *et al.* 1996).

Homeobox gene CDX2 (13q12-13), which is exclusively expressed in adults in intestinal epithelium cells and plays an important role in epithelial cell proliferation, differentiation, and determination of cell fate in different organs along the lower gastrointestinal tract. CDX2 proteins have been shown to play a

role in the development and differentiation of epithelial cells of the small and large intestine in mammals (Bakaris, *et al.* 2008).

The CDX2 gene is expressed in all but the most distal portions of the intestinal tract during development. CDX2 acts as a transcription factor, increasing the expression of several gene products associated with mature intestinal epithelial cells. CDX2 stimulates differentiation by activating transcription of intestine-specific proteins, such as MUC2, sucrase, isomaltase and carbonic anhydrase I (Bakaris, *et al.* 2008).

CHAPTER THREE
MATERIALS AND METHODS

CHAPTER THREE

MATERIALS AND METHODS

3.1 Materials:

Archived tissue blocks obtained from samples of colorectal tumors were selected for this study.

3.2 Methods:

3.2.1 Study design:

This descriptive retrospective case control study aimed to detect the expression of CDX2 marker in colorectal tumors by using IHC.

3.2.2 Study setting:

This study is conducted in Khartoum state in Ibn Sina hospital, National Public Health Laboratory and Radiation and Isotopes Center Khartoum (RICK) during the period March to July 2018.

3.2.3 Study samples:

3.2.3.1 Sample size:

Forty paraffin block (twenty five paraffin blocks that were previously diagnosed as colorectal cancer and fifteen paraffin blocks that were previously diagnosed as benign colorectal cancer (Adenoma)),all were primarily diagnosed by haematoxylin and eosin,were included in this study the patient data were collected from patient's files.

3.2.3.2 Study technique:

3.2.3.2.1 Sample processin:

Section of 2 μ m in thickness was obtained from each formalin fixed paraffin wax embedded tissue using rotary microtome, mounted into charged slides (Thermo) then dewaxed in oven.

3.2.4 Immunohistochemical staining:

Paraffin sections were immunostained using avidin biotin technique.

Rehydration: following deparaffinization in xyalin , slides was rehydrated though descending concentration of ethanol (100%, 90%, 70%, 50%) then placed in running tap water .

Antigen retrieval: Antigen retrieval by using water bath for 30 minutes.

Blocking: Endogenous peroxidase activity blocked with 3%hydrogen peroxide (H₂O₂) for 10 minute and then washed in phosphate buffer salin (PBS) for 2 minutes.

Primary antibody: Treat with 200 MI of primary antibody CDX2 for 20 minutes at room temperature in a moisture chamber and then rinsed in phosphate buffer salin for 2 minutes.

Secondary antibody: Secondary antibody labeled with horse redish peroxidase for 20 minutes and then washed in ruining tap water for 3 minutes.

DAB chromagen: Incubation in diaminobenzidin tetrahydride to visualization of the antibody then washed in phosphate buffer salin for 1minutes.

Counter stain: Slide was counter stained with Mayer's haematoxylin and blued in running water for 5 minutes and dehydrated in 50%, 70%, 90%, absolute ethyl alcohol for each, then cleared in xyelene and mounted using DPX media.

For each run of staining, positive and negative control slides were prepared.The negative control slides prepared from the same tissue block, but incubated without primary antibody.

3.2.5 Result interpretation:

All quality control measures were adopted; positive and negative control slides were used during immunohistochemical staining. Detection of more than 5 cells with brown nucleus per one field considered as positive result.

3.2.6 Data analysis:

All patients data was obtaining result arranged in standard master sheet then were entered a computer statistical package for social science (SPSS) program version 11.5 for analysis. Frequencies mean and chi-square test values were calculated. Proportions were compared with $P > 0.05$ was considered statistically not significant.

3.2.7 Ethical consideration:

Before the study was conducted the proposal of study was ethically approved by ethical committee of Sudan University of Science and Technology and Ministry of Health Research Committee.

CHAPTER FOUR
RESULTS

CHAPTER FOUR

RESULTS

A total of 40 samples from patients with colorectal tumor were investigated by immunohistochemistry method. 25 of them were malignant colorectal tumors representing (62.5%) and the remaining 15(37.5%) were benign as indicated in table (4.1).

The age of the study population ranged between 32 to 85 years old with mean age of 61 years. Most patients were older than 50 years representing 31 (77.5%) and the remaining 9 (22.5%) were younger than 50 years as indicated in table (4.2).

The description of sex as shown in table (4.3) most patients were male representing 24 (60%) and the remaining 16 (40%) were female.

The description of tumor grade revealed well differentiated tumor in 6 (24%) patients, moderately differentiated tumor in 18 (72%) patients and poor differentiated tumor in 1 (4%) patients in table (4.4).

The description of relation between CDX2 expression and histopathological diagnosis in table (4.5) malignant colorectal tumors revealed positive expression of CDX2 in 5(12.5%) patients and negative expansion of CDX2 in 20 (50%) patients, while benign colorectal tumor showed positive expansion of CDX2 in 13 (32%) patients and negative expansion of CDX2 in 2(50%), this result showed significant statistical association (P value 0.000).

Table (4.1) Distribution of histopathological diagnosis among the study population samples:

Sample	Frequency	Percent
Adenocacinoma	25	62.5
Adenoma	15	37.5
Total	40	100

Table (4.2) Frequency of age group among the study population:

Age group (year)	Frequency	Percent
>50	9	22.5
<50	31	77.5
Total	40	100

Table (4.3) Frequency of sex among the study population:

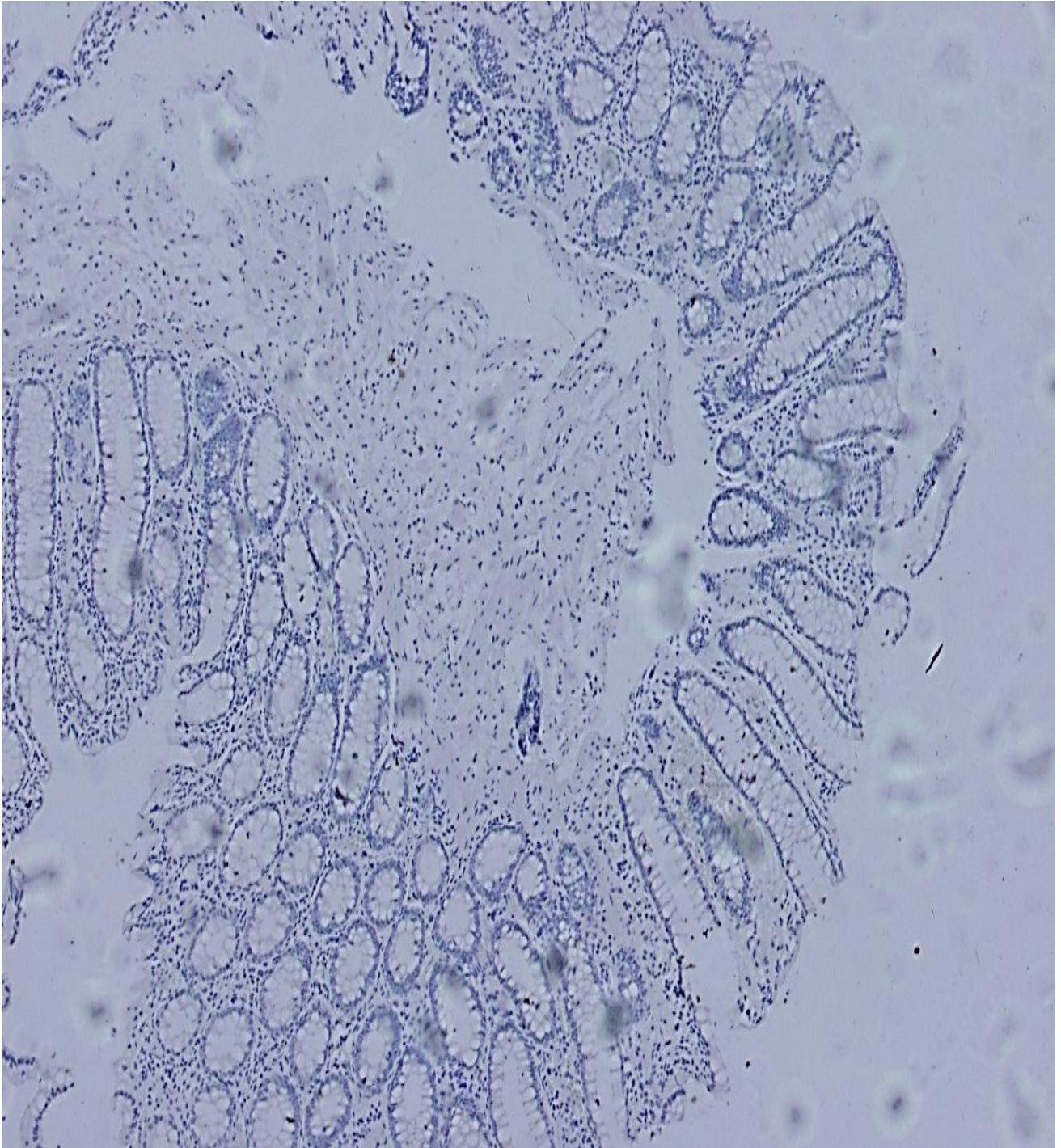
Sex	Frequency	Percent
Male	24	60
Female	16	40
Total	40	100

Table (4.4) Frequency of cancer grade among study sample:

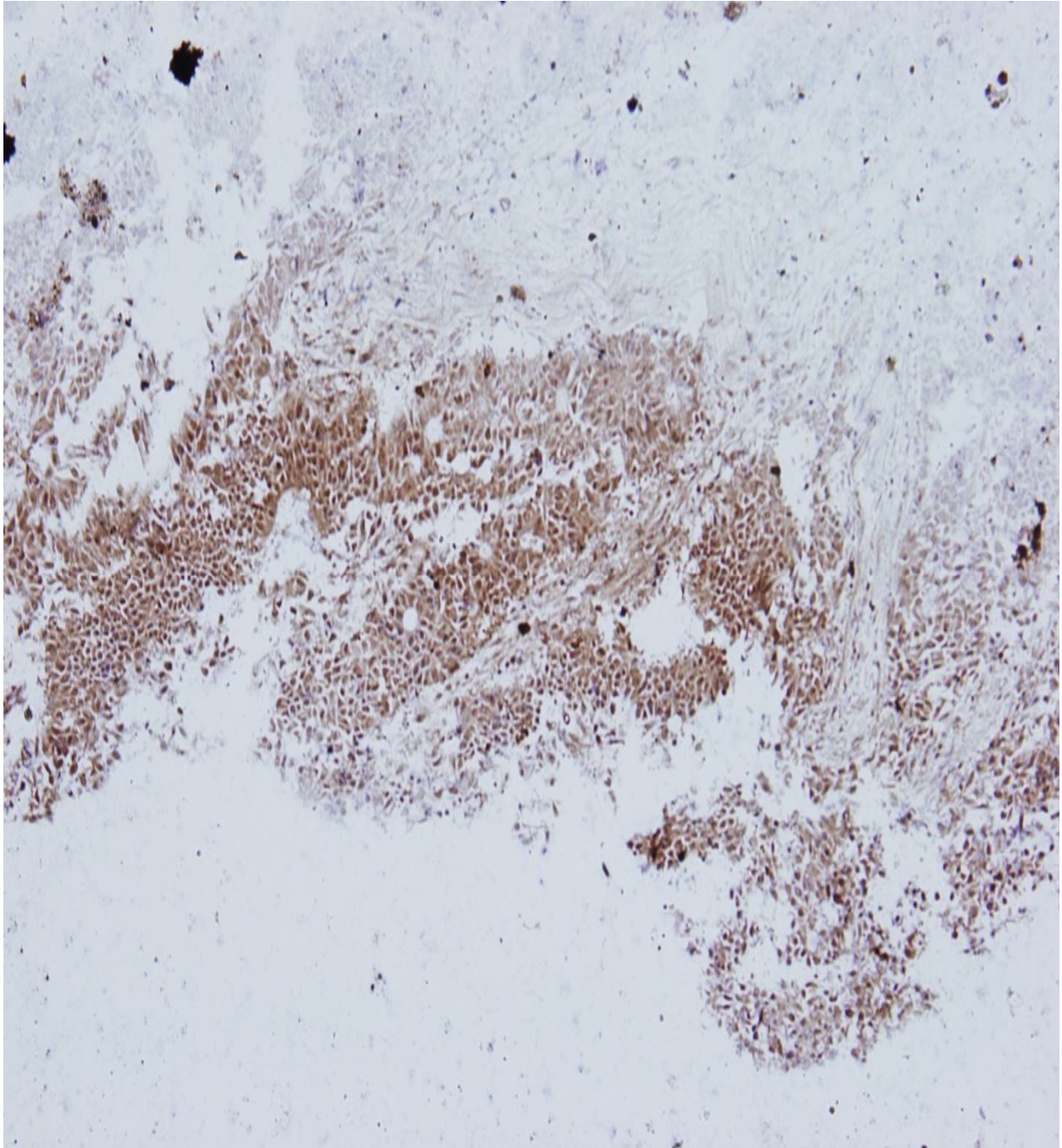
Tumor grade	Frequency	Percent
Well differentiated tumor	6	24%
Moderate differentiated tumor	18	72%
Poor differentiated tumor	1	4%
Total	25	100%

Table (4.5: Relation between CDX2 expression and histopathological diagnosis:

Expression of CDX2	Histopathology diagnosis		Total	P.value
	Positive N (%)	Negative N (%)		
Adenocarcinoma	5 (12.5%)	20 (50%)	25(62%)	0.000
Adenoma	13 (32%)	2 (50%)	15(37.5%)	
Total	18 (45%)	22 (55%)	40(100%)	



Microphotography (4.1): Colon tubular adenoma show negative expression of CDX2 (40X).



Microphotography (4.2): Colon moderately differentiation adenocarcinomas show positive expression of CDX2 (40X).

CHAPTER FIVE
DISCUSSION

CHAPTER FIVE

DISCUSSION

Colorectal cancer, commonly known as colon cancer or bowel cancer is the third most commonly diagnosed cancer starts in a small area but can spread to other parts of the body to form metastatic tumors (Hagggar and Boushey, 2009).

In this study forty samples of patients with colorectal tumor were investigated by immunohistochemical method. 25 of them were malignant colorectal tumors representing (62.5%) and the remaining 15 (37.5%) were benign.

The age of the study population ranged between 32 to 85 years old with mean age of 61 years. Most patients were older than 50 years representing (77.5%) 31 and the remaining 9 (22.5%) were younger than 50 years. These studies agree with Taha, (2015). Reported that colorectal cancer was found to affect Sudanese patients at younger age groups (43.84% was below 50 years) with a peak frequency at the fifth & sixth decades.

Regarding sex the males are more affected by colorectal cancer than females. The incidence of colorectal cancer in appear in males high than females. This study compatible with Taha (2015) there were males (50.68%) and females (49.32%) for the study with a male: female ratio of 1:1.02.

The study found present positive of CDx2 is common, with insignificant relation between CDx2 and colorectal tumor (P. value 0.000), this result disagree with Bakariss ,.et al. (2008) study which reported that CDX2 is sensitive for colorectal tumors.

CHAPTER SIX

CONCLUSION AND RECOMMENDATIONS

Chapter Six

Conclusion and recommendation

6. Conclusion and recommendation:

6.1 Conclusion:

On basis of this study we conclude:

- The age of the colorectal cancer among study population is commonly more than 52years.
- The sex of the colorectal tumor in this study commonly male.
- CDX2 expression is associated with adenomas

6.2 Recommendation:

On basis of this study we recommend the follow:

CDX2 should be used to confirm the histopathological diagnosis of benign colorectal tumors.

REFERENCES:

- Abeloff MD, Armitage JD, Niederhuber JE. Kastan MB, MckennaWG., (2013).** Abeloffs Clinical Oncology 4th ed. Philadelphia, Pa: Elsevier: 2215-2234.
- Amersi ,F. Agustin ,M. and Ko , C.Y.,(2005).** Colorectal cancer :Epidemiology , Risk factor and Health Serivces. *Clinics in colon and rectal surgery*.**18**(3):133-140.
- Barros R, Da Costa LT, Pinto-de-Sousa JP,DuluI, Noel J-N, David L ,Almeida R ., (2011) .**CDX2 autoregulation in human intestinal metaplasia of the stomach: impact on the stability of the phenotype. *Gut*.**60**: 290–298.
- Bakaris S, Cetinkaya A, Ezberci F, EkerbicerH .,(2008) .** Expression of homeodomain protein CDX2 in colorectal adenoma and adenocarcinoma. *Histology andHistopatholCellular and Molecular Biology* .**23**: 1043–1047.
- Binefa G,Rodriguez-Moranta F,Teule A,Median –HayasM.,(2014)** colorectal cancer: from prevention to personalized medicine .*World journal of Gastroenterology* .**20** (22):6786- 6808.
- Bujanda L , Cosme A, Gil I, Arenas-Mirave JI., (2010).**Malignant colorectal polyps.*World Journal of Gastroenterology*. **16** (25):3103-3111.
- Cancer Genome Atlas Network, (2012).**Comprehensive molecular characterization of human colon and rectal cancer.*Nature*.**487**: 330–337.
- Conteduca V, Sansonno D, RussiS, andDammacco F., (2013).** Precancerous colorectal lesions (Review).*International Journal of Oncology*.**43**(4):937-84.
- Dabbs D J., (2013).**Diagnostic immunohistochemistry.theranostic and genomic applications. 4th ed. Philadelphia, PA: Elsevier Health Sciences, pp1-13.
- Daniel Asymonds, Md,” and Austin I, Vickery J R, Md.,(1997).**mucinous carcinoma of the colon and rectum. *cancer***37**:1891-1900 .

Drenckhahn J. Waschke, (2008). Taschenbuch ,Auflage, Urban & Fischer Verlag, Elsevier. S.267-271

Drummond F., Putt W., Fox M. and Edwards Y.H., (1997).Cloning and chromosome assignment of the human CDX2 gene.*Annals of human Genetics.***61**(5) 393-400.

De Rosa M , Pace U, RegaD, Costabile v, DuraturoF, Izzo p, and Delrio P., (2015).Genetics ,diagnosis and management of colorectal cancer(Review). *Oncology Reports* ,**34** :1087 -1096

GlickS.,(2000). Double-Contrast Barium Enema for Colorectal Cancer Screening a Review of the Issues and a Comparison with Other Screening Alternatives .*American Journal of Roentgenology.***147**(6): 1529-1537.

Guyton AC, Hall JE., (2000). Text book of medical physiology. 10thed: 35-42.

Haggar FA ,and Boushey RP., (2009) Colorectal cancer Epidemiology :Incidence, Mortality ,Survival , And Risk factor . *Clinice in colon and Rectal Surgery.* **22**(4):191- 197 .

Hugen N, Brown G, Glynne –jones R , De will JH.W, and Nagetall ID., (2016). Advances in the care of patients with mucinous colorectal cancer, *Nature Reviews Clinical Oncology* .**13**: 361–369.

HortonKM , Abrams RA , and Fishman EK., (2000).Spiral CT ofColon Cancer: Imaging Features and Role in Management .*RadioGraphics* ,**20**(2): 419–430.

Itzkowitz SH , and Yio X.,(2014)Inflammation and Cancer. IV. Colorectal cancer in inflammatory bowel disease: the role of inflammation. *Am J PhysiolGastrointest Liver Physiol***287**: G7–G17

KekelidzeM ,D’Errico L , Pansini M , Tyndall A , &Hohmann J., (2013). Colorectal cancer: Current imaging methods and future perspectives for the

diagnosis, staging and therapeutic response evaluation. *World Journal of Gastroenterology* .**19**(46): 8502–8514.

Kaimaktchiev V, Terracciano L, Tornillo L, Spichtin H, Stoios D, Bundi M, Korcheva V, Mirlacher M, Loda M, Sauter G, and Corless C.L., (2004). The homeobox intestinal differentiation factor CDX2 is selectively expressed in gastrointestinal adenocarcinomas. *Modern Pathology* .**17**:1392- 1399.

Kordatou Z, Kountourakis P, and Papamichael D., (2014). Treatment of older patients with colorectal cancer :a perspective review .*Therapeutic Advances in Medical Oncology* .**6** (3):128 -140.

Lee S-H, Park Y-k, Lee D- J., & Kim K-M., (2014). Colonoscopy procedural skills and training for new beginners. *World Journal of Gastroenterology* .**20**(45): 16984–16995.

Martínez-Ares D., Martín-Granizo Barrenechea I., Souto-Ruzo J., Yáñez López J., Pallarés Peral, A., Vázquez-Iglesias J.L.(2005). The value of abdominal ultrasound in the diagnosis of colon cancer.*Revista española de enfermedades digestivas*.**97**(12):877-86

Nachar O.M., (2002). The role of positron emission tomography in colorectal carcinoma.*The Ochsner Journal*.**4**(3): 146–155.

Numata M, Shiozawa M, Watanabe T, Tamagawa H, Yamamoto N, Morinaga S, Watanabe K, Godai T, Oshima T, Fujii S, Kunisaki C, Rino Y, Masuda M, Akaika M., (2012). The clinicopathological features of colorectal mucinous adenocarcinoma and a therapeutic strategy for the disease.*World Journal of Surgical Oncology* .**10**(109):2-8.

Paimela H, Malila N, Palva T, Hakulinen T, Vertio H, Järvinen H., (2010) Early detection of colorectal cancer with faecal occult blood test Screening.*British Journal of Surgery* .**97**(10):1567-71.

Pezner RD, Chu D Z J, Wagman LD.,(1999). Resection with external beam and intraoperative radiotherapy for recurrent colon cancer.*Archives of Surgery* 134: 63-67.

ProcSoc, (1997).Molecular epidemiology;carcinogen-DNA adults and genetic susceptibility. *Experimental Biology and Medicine***216**(2):172-180.

ReyhanBayrak, HacerHaltas, and SibelYenidunya (2012).The value of CDX2 and cytokeratins 7 and 20 expression in differentiating colorectal adenocarcinomas from extraintestinal gastrointestinal adenocarcinomas: cytokeratin 7-/20+ phenotype is more specific than CDX2 antibody .*DiagnPathol.* 2012; 7: 9.

Ross MH, Romrell, L.J. Kaye g., (1994).Histology Textbook and Atlase. 3thed: 190-192.

Schünke E, Schulte U, Schumacher.,(2009). Prometheus – LernAtlas der Anatomie – InnereOrgane, S.36-37:226-229 .

Suh E. and Traber P.G. (1996). An intestine-specific homeobox gene regulates proliferation and differentiation. *Molecular and Cellular Biology.* 16, 619-625.

Shussman N, andWexner S D., (2014). Colorectal polyps and polyposis Syndromes.*Gastroenterology Report.***2** (1): 1-15.

TahaM O,Abdalla A A , and Mohamed RS.,(2015).Pattren and presentation of colorectal cancer in center Sudan ,a retrospective descriptive study ,2010 -2012 . *African Health Sciences.***15**(2):**576 -579.**

Thompson G S., (2015). Understanding anatomy and physiology: A visual, auditory, interactive approach. 2nd ed. Philadelphia, PA: F.A. Davis Company, pp 405- 445.

Tortora G J., and Derrickson B., (2014).Principles of anatomy and physiology. 14th ed. Danvers, MA: Wiley. P 926.

Varmus H., (2010).Stages of colon cancer.*National Cancer Institute* **101**(4):195 - 200.

Van Wezel T,Middelorp A, Wijnen J T M , MorreauH.,(2012). A review of the genetic background and tumour profiling in familial colorectal cancer . *Mutagenesis* .**27** (2):239 – 245.

Wong H H ,and Chu P., (2012).Immunohistochemical features of the gastrointestinal tract tumors. *Journalof Gastrointestinal Oncology***3**(3): 262–284.

Yee J., (2002). CT Screening for Colorectal Cancer. *RadioGraphics*.**22** (6): 1525-31.

APPENDICES

Appendices: (1)

1. Preparation of solutions and stain

Mayer's haematoxylin:

Haematoxylin 1g.

Distilled water 100g.

Potassium Alum 50g.

Sodium iodates 0.2g.

Citric acid 1g.

Chloral hydrates 50g.

The haematoxylin, potassium alum, and sodium iodate are dissolving in the distilled water by warming and stirring.

The chloral hydrate and citric acid are added, and then mixture is boiled at five minutes, then cold and filtered.

2. Ammoniated water:

Concentrated ammonia	0.05ml
----------------------	--------

Tap water	99.95ml
-----------	---------

3. Buffer reagents:

Phosphate buffer saline (PBS):

Six packets of PBS containing sodium phosphate dibasic, sodium phosphate monobasic and sodium chloride.

The PBS supplied in each packet sufficient for preparing 1 liter of phosphate buffer saline. Target retrieval solution: Citrate buffer, PH 9.0, dilution: 1:50

4. Blocker reagents:

Peroxides Blocker reagents:

Peroxides inhibitor containing hydrogen peroxide and 0.03 mol/L sodium azide. Dilution: 1:20

5. Preparation of TBE (250 ml):

Tris base 2.695 gm

Boric acid 1.376 gm

EDTA 0.186 gm

pH 8.3

6. Running buffer :

TBE 25 ml

Distilled water 225 ml

Appendix (4):

Appendix 2

quartett

LOT NO. 2030415870
Quantity 333313
6 ml

Antibody to
CDX2

Host: Rabbit

Immunogen: Synthetic peptide of human CDX2 protein

Subclass: IgG

Presentation: Diluted antibody, in buffer with < 0.1 % sodium azide.

Assay system: IHC(p,f)

Titre: Used in an avidin/biotin complex AEC/DAB system vial is sufficient for 60 slides using 100 µl per slide.

Fixatives: 1) NOTOXhisto 2) Formalin

Treatments: Staining of formalin/paraffin tissues is enhanced by boiling the tissue sections in ProTaq Antigen Enhancer I, Cat# 401602092 for 20 min followed by cooling at RT for 20 min.

Specificity: CDX2 is a caudal-related homeobox transcription factor that is expressed in the nuclei of intestinal epithelium and has a function in proliferation and differentiation of intestinal cells. This antibody detects primary and metastatic colorectal carcinomas, intestinal metaplasia of the stomach and intestinal type gastric cancer.

Reactivity: Human, others not tested.

Storage: Store at 2-8 °C. Do not use after expiration date indicated on the vial.

Errors excepted. This data sheet is a general information. The product attribute can diversify with changing Lot No as well as variations in tissue selection, tissue processing, antigen retrieval and detection systems. We do not take responsibility for any possible damage including personal injury, time or effort on economic loss caused by this product. Our warranty is limited to the price paid for the product. The product may only be used by authorized and skilled personnel. Non-application as prescribed in this data sheet leads to loss of all liability.

FOR IN VITRO USE, NOT FOR DIAGNOSTIC USE

Manufacturers:
BIOCYC GmbH & Co. KG, 1m Biotechnologiepark TGZ I, 14943 Luckenwalde; certified by
ISO 13485:2003 and AC: 2007, ISO 9001:2008; Registry number: 60018916, 60018917

Distributed by:

quartett

Schichauweg 16, 12307 Berlin, Germany
Tel.: ++49 (030) 765 925-0. Fax.: ++49 (030) 765 925-55
E-Mail: info@quartett.com Internet: www.quartett.com

Appendix (3)



DAB Substrate Kit High Contrast

REF / Cat. No.: DAB500plus 500 tests, 55 ml
DAB5000plus 5000 tests, 500 ml

Instructions for use

Intended use

DAB Substrate kit High Contrast is developed for immunohistochemical and *in situ*-hybridisation staining procedures with horse radish peroxidase (HRP). DAB (3,3'-Diaminobenzidine) leads to the formation of a brown precipitate at the location of the target antigen or target nucleic acid. The precipitate is insoluble in aqueous and organic solvents and can be observed by light microscopy.

The kit is especially useful when a high contrast between chromogen and counter stain is desired. Compared to standard DAB staining systems the DAB Substrate High Contrast kit gives a darker brown colour and a higher sensitivity.

DAB Substrate Kit High Contrast is intended for in vitro diagnostic use.

Reagents provided

REF / Cat. No. DAB500plus

3 ml DAB Chromogen (liquid DAB concentrate)
11 x 5 ml DAB Substrate Buffer High Contrast

REF / Cat. No. DAB5000plus

30 ml DAB Chromogen (liquid DAB concentrate)
500 ml DAB Substrate Buffer High Contrast

Storage and Handling

The solutions should be stored at 2-8°C without further dilution. Please store the reagents in a dark place and do not freeze them. Under these conditions the solutions are stable up to the expiry date indicated on the label. Do not use product after the expiry date.

The working solution should be prepared freshly at the day of use. Once the two reagents are combined, the resulting solution is stable for up to six hours. Excess working solution should be disposed as hazardous substance.

A positive and a negative control have to be carried out in parallel to the test material. If you observe unusual staining or other deviations from the expected results which could possibly be caused by the kit reagents please contact Zytomed Systems' technical support or your local distributor.

Precautions

Use by qualified personnel only. The DAB chromogen is hazardous to your health. Wear protective clothing to avoid contact of reagents or specimen with eye, skin or mucous membrane. In case of a reagent or specimen coming into contact with a sensitive area, wash the area with large amounts of water. Microbial contamination of the reagents must be avoided, since otherwise non-specific staining may occur.

Material safety data sheets (MSDS) are available upon request.

Reagent preparation (preparation of the working solution)

DAB500plus:

Add 5 drops of DAB Chromogen (DAB concentrate) to one bottle of DAB Substrate Buffer High Contrast and mix thoroughly.

DAB5000plus:

Add 50 µl of DAB Chromogen (DAB concentrate) to 1 ml of DAB Substrate Buffer High Contrast and mix thoroughly.

Note: Typical working concentrations are 50 µl (0.9 mg) DAB per ml substrate buffer. The colour intensity can be adjusted by decreasing or increasing the DAB concentration in the working solution. Maximum sensitivity in immunohistochemical staining can be achieved by working concentrations of about 80 µl (1.5 mg) DAB per ml substrate buffer.

Staining procedure

- 1) Rinse the slide with wash buffer after the previous incubation step.
 - 2) Apply the DAB High contrast working solution to the slide. Incubate for 5-15 minutes.
 - 3) Rinse with distilled H₂O.
 - 4) Counterstain with haematoxylin for about 30 seconds up to 5 minutes (depending on the desired staining intensity).
 - 5) Rinse with distilled H₂O.
 - 6) Blueing in tap water for at least 5 minutes.
 - 7) Dehydrate through a graded series of ethanol and clear in xylene. Mount with a permanent mounting medium.
- Note: It is also possible to mount DAB High Contrast with aqueous mounting media.

Quality control

We recommend carrying out a positive and a negative control with every staining run. The positive control permits the validation of appropriate processing of the sample. If the negative control has a positive result, this points to unspecific staining. Please refer to the instructions of the detection system for guidance on general quality control procedures.

Troubleshooting

If you observe unusual staining or other deviations from the expected results please read these instructions carefully, contact Zytomed Systems' technical support or your local distributor. Also refer to the instructions of the detection systems for guidance on general troubleshooting.

Expected results

During the reaction of the substrate with horse radish peroxidase in presence of the chromogen DAB, a brown precipitate is formed at the location of the target antigen or nucleic acid. The precipitate is insoluble in aqueous and organic solvents and can be observed by light microscopy.

Limitations of the procedure

Immunohistochemistry is a complex method in which histological as well as immunological detection methods are combined. Tissue processing and handling prior to immunostaining, for example variations in fixation and embedding or the inherent nature of the tissue can cause inconsistent results (Nadji and Morales, 1983). In some tissues endogenous peroxidase activity may cause non-specific staining. The enzyme activity should be blocked by incubation with hydrogen peroxide solution (H₂O₂ solution, Cat. No. ZUC019). The step is carried out before incubation with primary antibody but after dewaxing and rehydration.

Background staining due to endogenous biotin can be blocked through an avidin-biotin blocking step prior to the primary antibody incubation step. Inadequate counterstaining and mounting can influence the interpretation of the results.

Zytomed Systems guarantees that the product will meet all requirements described from its shipping date until its expiry date, as long as the product is correctly stored and utilized. No additional guarantees can be given. Under no circumstances shall Zytomed System be liable for any damages arising out of the use of the reagent provided.

Performance characteristics

Zytomed System has conducted studies to evaluate the performance of the kit reagents in combination with standard detection systems. The product has been found to be suitable for the intended use.

Bibliography












Elias JM "Immunohistopathology – A practical Approach to Diagnosis" ASCP Press 2003
 Nadji M and Morales AR Ann N.Y. Acad Sci 420:134-9, 1983

October 31, 2013

Rev: A1013

Doc: DBE_DAB500plus_5000plus

Explanation of the symbols on the product label:

	Bestellnummer Catalog Number Reference du catalogue		Verwendbar bis Use By Utiliser jusque		Gebrauchsanweisung beachten Consult instructions for use Consulter les instructions d'utilisation
	Chargenbezeichnung Batch Code Code du lot		Lagerungstemperatur Temperature Limitation Limites de température		Nur für Forschungszwecke For Research Use Only Pour la recherche uniquement
	In vitro Diagnostikum In Vitro Diagnostic Medical Device Dispositif médical de diagnostic in vitro		Achtung/Gefahr Warning/Danger Attention/Danger	 Hersteller / Manufacturer / Fabricant Zytomed Systems GmbH Anhaltenerstraße 16 14163 Berlin, Germany Tel: (+49) 30-804 984 990 www.zytomed-systems.de	
	Achtung/Gefahr Warning/Danger Attention/Danger		Achtung Warning Attention		