



Sudan University of Science and Technology

College of Graduate Studies



**Characterization of Malignant Breast Lesions Using
Ultrasonography and Breast Imaging Reporting and
Data System**

توصيف افات الثدي الخبيثه باستخدام التصوير بالموجات فوق الصوتية ونظام بايراد

*A thesis submitted in partial fulfillment for the requirements of M.Sc. in
ultrasound*

By:

Dalia Babiker Abduelghani Taha

Supervisor:

Dr. Ahmad Mustafa mohammed Abukonna

August 2018

الآية

بِسْمِ اللَّهِ الرَّحْمَنِ الرَّحِيمِ

قُلْ أَعُوذُ بِرَبِّ الْفَلَقِ (1) مِنْ شَرِّ مَا خَلَقَ (2) وَمِنْ شَرِّ غَاسِقٍ إِذَا وَقَبَ (3) وَمِنْ

شَرِّ النَّفَّاثَاتِ فِي الْعُقَدِ (4) وَمِنْ شَرِّ حَاسِدٍ إِذَا حَسَدَ (5)

صدق الله العظيم

سورة الفلق

DEDICATION

To my parents who scarified a lot to upbringing and educate me.

To my sisters and my brother

To those who searches and never settle for what they already have.... Thank you.

ACKNOWLEDGEMENT

I would like to express my sincere gratitude to everyone who has supported, encouraged and helped me and made it possible for me to complete this thesis. My warm thanks to all of you.

I would like to especially thank **Dr. Ahmad Mostafa Abukonna** for his great role in approving this thesis.

I also wish to thank all my colleagues especially **Dr.Wafa Fagiri** and my dearest colleagues for their valuable comments, support and suggestions.

ABSTRACT

Breast masses have become common in women; such masses may pose a potential threat to women especially when it belongs to breast cancer. Breast cancer is one of the leading causes of cancer death in women worldwide.

This is a descriptive hospital-based study, conducted at National Ribat University hospital, the study aimed to characterize Breast malignant lesions using breast Imaging Reporting and Data System (BIRAD) and ultrasonography. 71 suspected patients were enrolled in the study; all of them were scanned with ultrasound machine (Philips / Neusoft) with 10 MHZ probe. BIRADS category lesions were diagnosed in all 71 women after extensive conventional imaging work-up.

The result of the study showed that 49 patients were found to be positive after conducting histopathology examination, indicating a sensitivity of 97% and a positive predictive value of 96%. Specificity was found to be 95% and the negative predictive value was found to be 95% as well. 23 (30.99%) of participants showed no solid mass while 48 (69.01%) showed a solid mass by using Ultrasonography. 39 patients (54.93%) showed hypoechoic echo pattern, while 3 (4.23%) showed an anechoic echo pattern. Isoechoic and complex echo patterns were 1 (1.41%) and 5 (7.04%), respectively. Regarding shape; 31 (43.66%) showed irregular lesion. Furthermore, Margin of the lesions of patients was found to be speculated in 18 (25.35%), while 13 patients (18.31%) showed micro-lobulated margins.

The study indicated that the assessment of breast lesions with the use of the Breast Imaging Reporting and Data System ultrasound lexicon showed a significant diagnostic reliability for description of breast cancer.

المستخلص

أورام الثدي أصبحت شائعة لدى النساء، مثل هذه الأورام قد تعرض حياة النساء للخطر الحقيقي خصوصا لو تم تصنيفها كسرطان للثدي، حيث يعد سرطان الثدي هو المسبب الرئيسي للوفاة عند النساء على مستوى العالم.

هذه الدراسة الوصفية المستندة إلى المستشفى، والتي أجريت في مستشفى جامعة الرباط الوطني، هدفت إلى توصيف الافات الخبيثة من الثدي باستخدام تقنية الإبلاغ عن الثدي ونظام البيانات (BIRAD) والموجات فوق الصوتية. تم تسجيل 71 مريضا مشتبهها في إصابتهم؛ تم فحص كل منهم بجهاز الموجات فوق الصوتية (فيليبس/نيوسوفت) بمسبار 10ميغاهيرتز. تم تصنيف جميع المرضى بنظام BIRADS بعد عمل التصوير التقليدي واسع النطاق.

وأظهرت نتائج الدراسة أن 49 مريضا تم العثور علي نتائج إيجابية بعد إجراء فحص الأنسجة، مما يشير إلى حساسية بنسبة 97% وقيمة تنبؤية إيجابية 96%. تم العثور على خصوصية 95% وتم العثور على القيمة التنبؤية السلبية لتكون 95%. أظهر 23 (30.99%) من المرضى عدم وجود كتلة صلبة في حين أظهر 48 (69.01%) كتلة صلبة باستخدام الموجات فوق الصوتية. أظهر 39 مريضا (54.93%) نمط صدئ ناقص الصدئ، بينما أظهر 3 (4.23%) نمط صدئ للصدئ. كانت الأنماط الصخرية المعقدة والصغيرة 1 (1.41%) و 5 (7.04%) على التوالي. فيما يتعلق بالشكل أظهر 31 (43.66%) آفة غير منتظمة.

أشارت الدراسة إلى أن تقييم آفات الثدي مع استخدام نظام الإبلاغ عن تصوير الثدي (BIRAD) ونظام المعالجات بالموجات فوق الصوتية أظهر موثوقية تشخيصية كبيرة لوصف سرطان الثدي.

List of Contents

Title	Page
الآية	I
Dedication	II
Acknowledgement	III
Abstract	IV
list of contents	VI
List of tables	IX
List of figures	X
List of abbreviations	XI
Chapter One: introduction	
1.1 Background	1
1.2 Rationale	2
1.3 Study objectives	2
Chapter Two: literature review	
2.1 anatomy	4
2.2 Ultrasound anatomy of the breast	5
2.3 Ultrasound anatomy of the lymph nodes	8
2.4 Screening of the breast	9
2.5 Breast neoplasms	12
2.5.1 Risk factors	12
2.5.2 Ductal carcinoma in situ	13

2.5.3 Invasive ductal carcinoma	13
2.5.4 Ultrasound	13
2.5.5 Lobular carcinoma in situ	14
2.5.6 Invasive lobular carcinoma of the breast	14
2.5.7 Breast ultrasound	16
2.5.8 Malignant melanoma	16
2.6 Diagnosis of breast cancer	16
2.6.1 Breast imaging	17
2.6.2 Diagnostic Imaging	20
2.6.3 Prognostic indicators	22
2.7 The Breast Imaging Reporting and Data System (BI-RADS)	27
2.8 Breast cancer treatment	30

Chapter Three: Materials and Methods

3.1 Study design	32
3.2 Study area	32
3.3 Study population	32
3.4 Sample size	32
3.5 Inclusion Criteria	32
3.6 Exclusion Criteria	32
3.7 Data collection	32
3.7.1 Instrumentation and technique	32
3.7.2 Histopathology examination	33

3.8 Data storage	33
3.9 Data analysis	33
3.10 Ethical consideration	33

Chapter Four : Results

Chapter Five: Discussion , Conclusion and Recommendations

5.1 Discussion	42
5.2 Conclusion	44
5.3 Recommendations	45

References 46

Appendices

List of tables

Table No.	Title of Table	Page
Table 1	BIRADS and histopathology examination results of all breast lesions.	39
Table 2	Other associated features of breast lesions among women participated in the study.	40

List of figures

Title of Figure	Page
Age distribution	34
Size of breast lesions	34
Location of breast lesions	35
Width to height ratio of breast lesions	35
Echo patterns of US	36
Shape of breast lesions	36
Margin of breast lesions	37
Posterior acoustic shadowing	37
Vascularity of breast lesions	38
BIRADS classification of breast lesions	38
Type of malignancy of breast lesions	41

List of Abbreviations

BIRADS: Breast Imaging Reporting and Data System

US: ultrasound

BES: breast self-examination

NCCN: national comprehensive cancer network

CBE: clinical breast exam

MRI: magnetic resonance imaging

XM: X-ray mammography

DCIS: ductal carcinoma in situ

IDCs: intra-ductal carcinomas

ILCs: intra-lobular carcinomas

FNAC: fine needle aspiration

PET/CT: positron emission tomography with computed tomography

¹⁸F FDG: fluoro-deoxy-glucose

SUV: standardized uptake value

MHZ: mega-hertz

SPSS: Statistical Package for Social Sciences

Chapter One

Introduction

Chapter one

Introduction

1.1. Background

Breast masses have become common in women; such masses may pose a potential threat to women especially when it belongs to breast cancer. Breast cancer is one of the leading causes of cancer death in women worldwide.

The early diagnosis and management of breast malignant lesions is therefore important to reduce mortality. The established management of malignant breast lesions includes the triple assessment of physical examination, mammography and percutaneous biopsy (Taylor et al., 2018).

Mammography, invaluable in screening role, is not specific enough for making a definitive preoperative diagnosis. The appearance of masses in mammography is often non diagnostic. In addition, some clinically palpable masses may poorly define or not visualized at all on mammography which often requires a biopsy to rule out malignancy (Fenner et al., 2018).

The accurate diagnosis of breast lesions without resort to formal biopsy is highly desirable both for patients who can be quickly reassured or counseled and clinician who can reduce unnecessary surgery. Additionally, the cost of biopsies is also high and a large number of biopsies for benign breast abnormalities have adverse effect on women who undergo them. Therefore Ultrasound is an important safe imaging modality in assessment of malignant breast masses (Choi et al., 2018).

The use of ultrasound to examine the breast was first described in 1951 since then, the ultrasound examination is well established as an important technique for investigate of breast problem (Fenner et al, 2018).

Ultrasound has become popular even in lower level health center of developing countries, for example; in Uganda ultrasound services have become available in lower health facilities due to her decentralized health care system. At the same time, there are many training institutions training radiologist, sonographer carry out the ultrasound examination as primary investigation (Pattacini et al, 2018).

It is evident therefore that accuracy of ultrasound in evaluation breast masses and differentiate benign from malignant breast lesions needs to be documented since many clinician are requesting for it in assessing the breast masses.

1.2. Problem of the study:

Breast masses are considered common now, so biopsies are performed routinely on solid breast lesions identified clinically or on mammogram. The accurate diagnosis of breast lesions without resort to formal biopsies is highly desirable. Ultrasound could possibly provide clear criteria for determining benign and malignant lesions when it is considered as reliable accurate examination modality in detecting breast mass (low cost, available and save).

1.3. Objectives

1.3.1. General Objectives

The main purpose of this study is to characterization of malignant breast Lesion Using ultrasonography and Breast Image Reporting and Data (BIRAD) System .

1.3.2. Specific Objectives

- To determine the validity of ultrasound in assessment of the breast masses by determining the sensitivity, specificity, positive predictive value and negative predictive value.
- To analyze and study the value of various sonography features in diagnosing malignant breast tumor to improve diagnostic accuracy of ultrasound in detecting masses, these features are:
 - Size
 - Orientation
 - Shape
 - Echo density
 - Echo pattern
 - Posterior acoustic properties
 - Architecture of surrounding tissue Vascularity
- To compare and correlate the ultrasound finding with biopsy result and Breast Image Reporting and Data (BIRAD) System (I V and V).

Chapter Two

Literature Review

Chapter Two

Literature Review

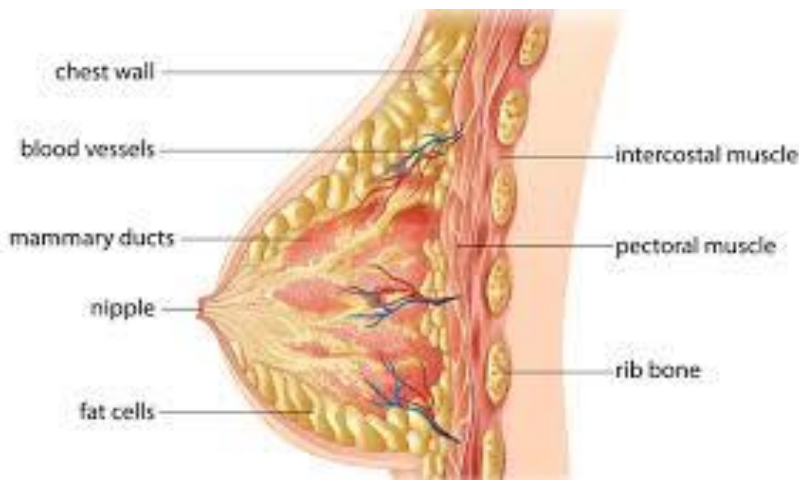
2.1. Anatomy

The breast occupies an area that extends from the third rib to the seventh rib and from the edge of the sternum to the armpit. The volume, shape and degree of development are very variable in relation to various factors such as age, gland development, and amount of fat and relative influence of endocrine stimulation. At the center of the breast there are the nipple and areola. The areola is a flat hyper-pigmented area of skin with a round or oval shape and of variable diameter, usually, between 3.5 and 6 cm. The nipple stays at center of the areola and has a variable size and shape (conical or cylindrical), at its apex, there are several small depressions that represent the outlets of the ducts. The areolar surface is irregular due to the presence of the 8-12 tubercles of Morgagni, representing sebaceous glands (Vidya and Iqbal, 2017).

The mammary gland is made of three components: glandular, adipose and fibrous tissues. Functionally, it can be considered a modified apocrine sweat gland, in relation to breast-feeding. The glandular structure is composed by 15-20 lobes arranged in clusters with an irregular radial pattern around and behind the nipple. Each lobe is an independent glandular entity made of numerous lobules, constituted by alveoli, which are the secreting units. The alveolar ducts converge into the lobular ducts which in turn converge into the milk ducts. The milk ducts, then, converge to the nipple with an ampullary dilatation, the lactiferous sinus. The stroma is composed of dense fibrous and adipose tissues that surround the entire gland and penetrate

between the lobes. It may be divided into 3 portions: a subcutaneous part that lies between the skin and the gland, an intraparenchymal portion located between lobes and lobules, and a retro-mammary portion, located behind the gland (Klock et al, 2016).

The breast parenchyma is contained by a two-layer fold of the subcutaneous superficial fascia, that may be divided in two parts: the superficial layer that covers the gland and contains fibrous septa, called Cooper's ligaments, which penetrate the gland and form the support structure of the parenchyma, and the deep layer, which covers the posterior portion of the gland and separates it from the underlying superficial fascia of the pectoralis major muscle. Cooper's ligaments are the suspensory ligaments of the breast gland and divide the parenchyma into lobes (Klock et al, 2016).



2.2. Ultrasound anatomy of the breast

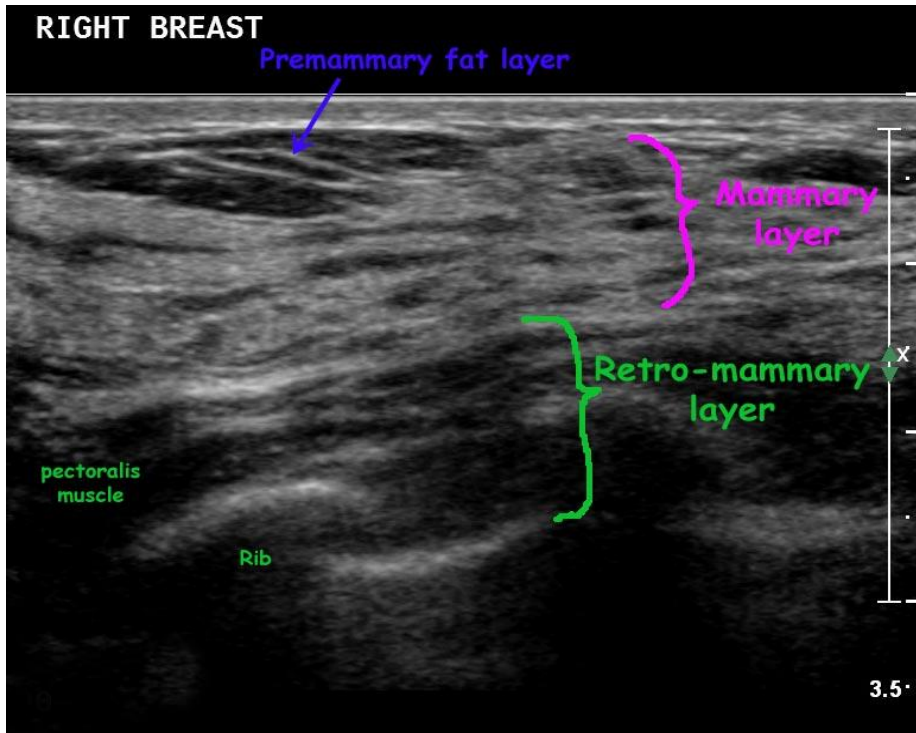
All anatomic structures of the breast can be detected by ultrasound. Starting from the skin surface going deep, four different regions may be identified: (i) the region of the skin, nipple and areola; (ii) the subcutaneous (pre-

mammary) region; (iii) the glandular region; and (iv) the retro-mammary region (Martaindale, 2018).

The skin can be seen as two hyperechoic lines separated by a hypoechoic line representing the dermis and have a variable thickness between 0.5 and 2 mm. The areola and nipple generally determine an attenuation of the acoustic signal and are hypoechoic. The nipple produces strong attenuation of the acoustic signal that partially masks the underlying structures. Under the nipple, the lactiferous ducts branch, they are anechoic or moderately echogenic tubular structures, depending on the content. They have diameter of 2-3 mm, which gradually decreases going towards the periphery. The subcutaneous region or pre-mammary region is located between the skin and the mammary fascia and contains mostly adipose tissue, which is less echogenic than the glandular tissue (Lannin, 2013).

The thickness of this fatty region can reach up to 2-3 cm. The subcutaneous fat tissue is crossed by thin hyperechoic lines, Cooper's ligaments which extend from the skin to the glandular region. The glandular region, located between the pre-mammary region and the retromammary region, has a triangular shape with the apex towards the areolar region and the base towards the pectoral muscle and is enfolded by the mammary fascia that appears as a thin hyperechoic line. The echogenicity of this region varies in relation to the percentages of glandular and adipose tissues. Fat tissue is hypoechoic, while the glandular tissue and stroma are hyperechoic. The most superficial part of this region shows some hyperechoic "pyramids" from which the Cooper ligaments, or ridges of Duret, branch (Arleo et al, 2013).

Sonographically, breasts having larger quantity of fibroglandular component are more echogenic, while predominantly adipose breasts are diffusely hypoechoic. The breast gland shows constant changes in echogenicity due to factors such as age, menstrual cycle, pregnancy and lactation. The region of Chassaignac is located behind the gland; it is made from the retromammary fat that is hypoechoic. The pectoralis major muscle is slightly more echogenic than the retromammary fat. More deeply, the ribs show attenuation of the acoustic signal and appear as hypoechoic structures, and the parietal pleura can be displayed as a hyperechoic line. The intramammary vascular network is made of arterial vessels proceeding from the deep portion of the gland to the ligaments of Cooper. The venous network follows the arterial network. Doppler techniques can be used in order to show the vessels (De Benedetto et al, 2016).



2.3. Ultrasound anatomy of the lymph nodes

Ultrasonography can be used to study the axillary lymph nodes, the internal mammary chain, located along the parasternal line from the 2nd to the 5th intercostal space, and the supraclavicular and infraclavicular lymph nodes. Lymph nodes have echogenic hilum and a hypoechoic cortex. Normal lymph nodes are oval or elongated, with a clear differentiation between the hypoechoic cortex and the hyperechoic medulla. In elderly patients, the cortex's thickness is reduced, while there is increase of fat tissue within the lymph node. In case of cortical atrophy and fatty replacement the lymph node may appear completely isoechoic and difficult to recognize. Neoplastic and metastatic lymph nodes are usually globular or round in shape, they do not show the normal cortico-medullary differentiation and may be completely hypoechoic (Jorgensen and Gotzsche, 2013).

The parameters to consider when studying lymph nodes are: the size, morphology and echogenicity. The size does not seem to be a reliable criterion for the differentiation between a benign or a malignant behavior. It is useful to calculate the ratio between the longitudinal and transverse diameters of the lymph node, defined as "roundness index". When this ratio exceeds the value of 1, the lymph node can usually be considered benign. However, beside morphology, it is important to analyze the profile of the cortex and medullary zone, as well as the vascularization. A hyperplastic lymph node is characterized by vascular signals distributed harmoniously from the hilum to the periphery (Autier and Boniol, 2013).

Inflammatory lymph nodes grow proportionately and maintain the original shape, while neoplastic lymph nodes increase disproportionately the short

axis and appear spherical. Regarding the echogenicity, the cortex of the abnormal lymph node tends to become markedly hypoechoic and even anechoic. In this case it is useful to use color Doppler to distinguish it from a cyst. This modification is typical for neoplastic infiltration, but may also occur in cases of severe inflammation. The reduction of echogenicity is a reflection of the high number of cells inside the lymph node. Other suspicious features of malignant lymph nodes are compression or eccentric displacement of the hilum, focal hilum compression, concentric compression of the hilum and complete absence of the hilum (De Benedetto et al, 2016).

2.4. Screening of the breast

Breast self- and clinical breast examination Utility of the breast self-examination (BSE) is controversial as the benefit in terms of decreased mortality has not been demonstrated ^[7]. Most clinicians encourage women to perform monthly BSE to become familiar with their normal anatomy and empower them with regards to their own healthcare. The 2013 NCCN guidelines recommend annual clinical breast examination (CBE) for women of average risk > 40 years of age as well as BSE to develop and exhibit breast self-awareness(Yim et al, 2018).

Mammography one of the most important advances in the treatment of breast cancer is early detection of non-palpable masses. In the 1960's, the first randomized control trials comparing periodic mammography screening vs clinical examination demonstrated a decreased mortality by approximately one third in the experimental group. However there is still controversy regarding mortality from breast cancer in the subset of women aged 40-49 years (Choi et al, 2018).

Contemporary randomized control trials have demonstrated the benefits from screening mammography in women aged 40 to 70 years. A 2013 Cochrane Review suggests that mortality is an outcome biased toward screening, routine mammography leads to undue stress and uncertainty in the face of false-positive results with increase in total numbers of lumpectomies and mastectomies but no decrease in mortality (Arleo et al, 2013).

Controversy surrounding mammography is related to the inherent lead time and length time biases in screening for disease. Lead time bias is an overestimation of survival among screen detected cases compared to clinically detected cases when true survival time actually remains unchanged. Length bias is an overestimation of survival time among screening-detected cases, which is caused by those slowly progressing cases that may never be clinically relevant (Morrell et al, 2018).

The 2013 NCCN guidelines recommends annual screening mammography in women ≥ 40 years of average risk and annual mammography at age 25 or individualized based on onset of cancer in proband in patients who are high risk by prediction models, known history or genetic predisposition syndrome as well as the counseling and education of risks and benefits related to participating in cancer screening (Arleo et al, 2013).

Magnetic resonance imaging Mammography remains the gold standard for breast imaging but magnetic resonance imaging (MRI) has become an important modality in the detection, assessment, staging, and management of breast cancer in selected patients. Screening MRI is more sensitive but less specific for the detection of cancer in high risk women. The sensitivity of

MRI is 0.77-0.79 compared to mammographic sensitivity of 0.33-0.39. Specificity of MRI is 0.86-0.89 compared to mammographic specificity of 0.95. In a systematic review, MRI and mammography demonstrated a combined sensitivity and specificity of 0.94 and 0.77, respectively (Martaindale, 2018).

The 2013 NCCN guidelines recommend patients who have increased (> 20%) lifetime risk of developing breast cancer undergo annual mammography and MRI starting at age 25 or an age tailored to the risk of the patient on an individual basis. MRI is valuable in the screening of select high risk patients, patients in whom breast augmentation prevents effective screening mammography, or in patients with equivocal findings on other imaging modalities (Theriault et al, 2013).

There are several studies supporting the use of adjunctive screening ultrasound in high risk patients with dense breast tissue, which imparts a substantial but accepted number of false positives. No randomized controlled trials have been conducted to evaluate the impact of screening ultrasonography on breast cancer mortality rates. Whole breast ultrasound may allow the clinician to screen for breast cancers not detected by traditional mammography; especially in dense breasts where mammographic sensitivity is lower. Single center studies have shown that the incremental detection of breast cancer by ultrasound following screening mammogram offers only marginal added benefit in women of average risk (Theriault et al, 2013).

2.5 Breast neoplasms

There are many types of breast neoplasms, which can be divided into the following broad oversimplified categories as a starting point.

- Intralobular (epithelial and stromal).
- Interlobular.
- Breast lymphoma.
- Metastasis to breast.

Intralobular and interlobular refer to the terminal duct lobular unit.

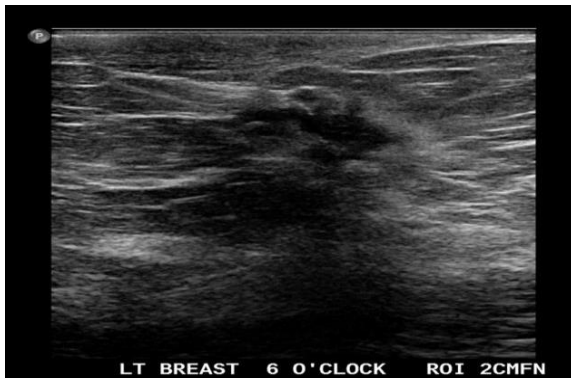
2.5.1 Risk factors

- Increasing age.
- First degree relative with breast cancer.
- Factors increasing unopposed oestrogen load.
 - Early menarche
 - Late menopause
 - Nulliparity
- Personal history of breast cancer.
- Personal history of a high-risk breast lesion:
 - atypical ductal hyperplasia
 - atypical lobular hyperplasia
- Genetic mutations.
 - *BRCA1/BRCA2* mutation
 - Li Fraumeni (p53)
 - others include Peutz Jegher, Cowden syndrome, ataxia telangiectasia

2.5.2 Ductal carcinoma in situ

Ductal carcinoma in situ (DCIS) refers to a breast carcinoma limited to the ducts with no extension beyond the basement membrane, as a result of which the disease has not infiltrated the parenchyma of the breast and the lymphatics and cannot therefore metastasize. Accounts for 25-40% of mammographically detected breast cancers. It also accounts for approximately 15-20% of all detected breast cancers.

- Up to 11% of predetermined DCIS on imaging may have an invasive component at the time a biopsy is done.
- 20-25% of DCIS revealed on core biopsy may have invasive ductal carcinoma following surgical excision.



2.5.3 Invasive ductal carcinoma

Invasive ductal carcinoma is a subset of ductal carcinoma. It is an infiltrating, malignant and abnormal proliferation of neoplastic cells in the breast tissues. It is the most frequently seen breast malignancy. Peak age of presentation is about 50 to 60 years.

2.5.4 Ultrasound

- Ill-defined lesion.
- Hypoechoic mass.

- Hyperechoic angular margin.
- Posterior acoustic shadowing.
- Ductal extension may be seen which is extension of the lesion into surrounding parenchyma.
- Dranched or speculated pattern.
- Micro-calcifications.

2.5.5 Lobular carcinoma in situ

- Lobular carcinoma in situ (LCIS) represents the next step up from atypical lobular hyperplasia (ALH) along the malignant spectrum of lobular breast carcinoma. LCIS occurs predominantly in premenopausal women with a mean age of 45 years old, approximately 10-15 years younger than the mean age when invasive breast carcinoma occurs.

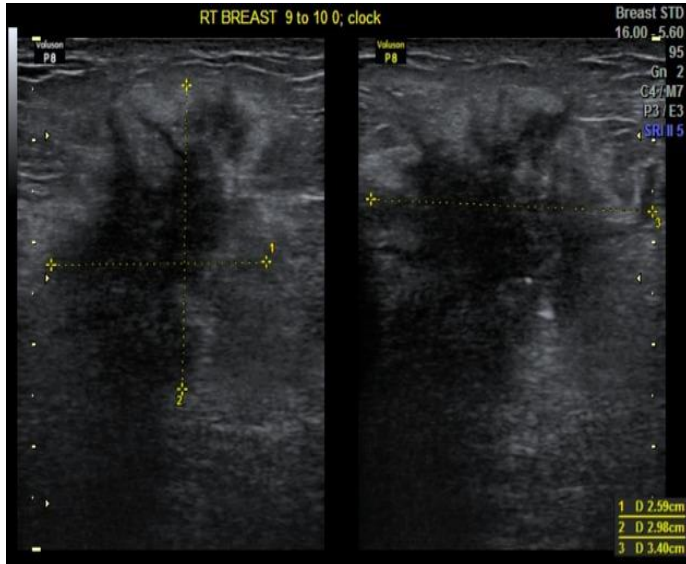
Pathology

- Like most other lobular breast pathology, LCIS originates in the terminal ductal lobular unit (TDLU). However unlike ALH, the malignant cells fill and distend the lobular acini in LCIS. Unlike invasive lobular carcinoma, they leave the basement membrane intact.
- LCIS is usually incidentally-identified histologically in breast tissue biopsied for other reasons. The exception may be pleomorphic LCIS which is a more aggressive subtype which may be associated with mammographically-detectable calcifications.

2.5.6 Invasive lobular carcinoma of the breast

Infiltrating or invasive lobular carcinoma (ILC) of the breast is the second most common type of invasive breast cancer after invasive ductal carcinoma (IDC) "not otherwise specified" (NOS).

They represent 5-10% of all breast cancer. The mean age at presentation may be higher than for IDC.



2.5.6.1 Pathology

ILC is characterised microscopically by malignant monomorphic cells forming linear invasive columns that are loosely dispersed (note: IDC is more typically a discrete mass). Loss of E-cadherin has been demonstrated. ILC frequently invades the normal tissues without invoking the vigorous desmoplastic response that usually accompanies IDC. Cells of ILC often encircle ducts, thus preserving the architecture of the ducts. These histopathologic features limit mammography in detecting ILC.

2.5.6.2 Markers

The majority of ILCs have the following receptor profile

- Oestrogen receptor: positive
- Progesterone receptor: positive
- HER2 amplification: negative

2.5.6.3 Associations

There is a greater rate of contralateral breast cancer in ILC compared with IDC with a 5-year rate of bilateral cancer of 8% (4% synchronous and 4% metachronous tumours). Radiographic features

ILC is more often multi-centric and bilateral (10-15%). Therefore imaging evaluation of the contralateral breast is crucial. There can be very subtle changes such as progressive shrinkage or enlargement or reduced compressibility of the involved breast. Imaging often underestimates the disease.

2.5.7 Breast ultrasound

The most common sonographic appearance is that of a heterogeneous, hypoechoic mass with angular or ill-defined margins and posterior acoustic shadowing. An ill-defined heterogeneous infiltrating area of low echogenicity with disproportionate posterior shadowing is one of the ILC sonographic characteristics.

2.5.8 Malignant melanoma

Malignant melanoma is a malignant neoplasm that arises from melanocytes (or cells that derive from melanocytes). Melanocytes predominantly occur in the basal layer of the epidermis and most melanomas, therefore, arise in the skin. However, melanocytes do occur in other locations and can give rise to primary melanoma in unexpected locations, e.g. primary uveal malignant melanoma

2.6. Diagnosis of breast cancer

History and physical examination the clinical history is directed at assessing cancer risk and establishing the presence or absence of symptoms indicative of breast disease. It should include age at menarche, menopausal status,

previous pregnancies and use of oral contraceptives or post-menopausal hormone replacements. A personal history of breast cancer and age at diagnosis, as well as a history of other cancers treated with radiation. In addition, a family history of breast cancer and/or ovarian cancer in a first-degree relative should be established. Any significant prior breast history should be elucidated including previous breast biopsies (Arleo et al, 2013).

After the estimated risk for breast cancer has been determined, the patient should be assessed for specific symptoms like breast pain, nipple discharge, malaise, bony pain and weight loss. Physical examination should include a careful visual inspection with the patient sitting upright. Nipple changes, asymmetry and obvious masses should be noted. The skin must be inspected for changes such as; dimpling, erythema, peau d' orange (associated with local advanced or inflammatory breast cancer). After careful inspection and with the patient in the sitting position the cervical, supraclavicular and axillary lymph node basins are palpated for adenopathy. When palpable the size, number and mobility should be ascertained. Palpation of the breast parenchyma itself is performed with the patient supine and the ipsilateral arm placed over the head. The subareolar (central quadrant) and each quadrant of both breasts are palpated systematically. Masses are noted with respect to their size, shape, location, consistency and mobility (Kelly et al, 2010).

2.6.1. Breast imaging

Conventional breast imaging, consisting of X-ray mammography (XM) and ultrasound (US), are well-established and indispensable modalities in the diagnosis and staging of breast cancer. XM is typically applied as first modality in screening programmes, aiming to detect breast disease at an

early stage. This early stage includes DCIS and small, not yet palpable, tumors. DCIS is often visible as micro-calcifications on XM. The sensitivity of XM varies over studies (20-77 %). This variation is due to the strong dependency of XM on breast density. Moreover, compared to IDCs, ILCs are harder to detect on XM (Gartlehner et al, 2013).

Ultrasound is generally applied as an adjunct to XM, particularly to assess the extent of invasive lesions and to guide aspiration biopsy and cytology fine-needle aspiration (cFNA). Furthermore Ultrasound is able to distinguish cystic from solid lesions. The complementary value of XM and U/S has been studied extensively. Many authors reported improvements in diagnostic performance when applying U/S as an adjunct to XM. Despite these improvements the diagnostic performance is still imperfect. Therefore, through the years new diagnostic strategies with newly developed imaging techniques have been investigated (Ravert and Huffaker, 2010).

In the mid-eighties, contrast-enhanced MRI was introduced as a diagnostic tool with high sensitivity to detect invasive breast lesions. The exact role of MRI in the staging of breast cancer is not yet established. Particularly, it is unclear who will benefit from a preoperative MRI and who will not (Steinbach, 2018).

Another imaging technique is positron emission tomography in combination with computed tomography (PET/CT). PET is a technique in which radiotracer compounds are injected intravenously. The most frequently used tracer in oncology, is 18-fluoro-deoxy-glucose (FDG). This is a glucose analogue labelled with radioactive Fluorine (18F). After annihilation in tissue with electrons two photons travel 180° in the opposite direction. The

photons are captured by the PET scanner and reconstructed into an overview of its distribution. Compared to normal cells tumor cells have an increased glucose metabolism. The difference in glucose uptake (thus FDG) can be visualized by PET. Hence, PET generates functional information of the tumor. FDG uptake can be quantified as “maximum standardized uptake value” (SUV_{max}). This is described as the radioactivity concentration per two- or three-dimensional region of interest. PET is generally used in combination with CT to provide anatomical information. PET/CT has proven its value in the staging and re-staging of recurrent disease. Its role in monitoring of treatment response of breast cancer is currently subject of research (Baun et al, 2018).

Through the years many investigators reported on the accuracy of both MRI and PET/CT to detect breast cancer. Particularly the relatively low specificity of these techniques is subject of research. In PET/CT inflammation and infectious tissue may result in increased FDGuptake and consequently false-positive findings.

The recently published report that addressed the accuracy (in terms of sensitivity and specificity) of non-invasive breast cancer diagnosis tests is a systematic review published by the Agency for Healthcare Research and Quality. The studied population consisted of women who were recalled after detection of a possible abnormality at standard workup (XM and/or US). For MRI, the authors analyzed 41 studies and reported a summary sensitivity for all lesions of 91.7 % (95 % confidence interval (CI): 88.5 to 94.1 %) and a summary specificity of 77.5 % (95 % CI: 71.0 to 82.9 %). For PET/CT the authors analyzed 7 studies and reported a summary sensitivity for all lesions of 83.0 % (95 % CI: 73.0 to 89.0 %) and a summary specificity of 74.0 %

(95 % CI: 58.0 to 86.0 %). The authors indicated, however, that their data had significant heterogeneities and they therefore rated the strength of the evidence as moderate to low (Chen et al., 2018).

2.6.2. Diagnostic Imaging

The initial choice of imaging should be individualized to each patient based on the age and characteristics of the lesions. Diagnostic imaging and image-guided needle biopsies play a central role in the diagnosis, treatment planning, and staging of patients with breast cancer.

2.6.2.1. Mammography

Mammography remains the mainstay in breast cancer detection. Diagnostic mammograms are performed in women who have a palpable mass or other symptom of breast disease, a history of breast cancer within the preceding 5 years, or have been recalled for additional imaging from an abnormal screening mammogram. Diagnostic mammograms include special views such as focal compression of one area of the breast tissue or magnification images. The Breast Imaging Reporting and Database System (BIRADS) is the standardized method for reporting of mammographic findings. Carcinomas present as masses, asymmetries, and calcifications. By definition, a mass is a space-occupying lesion seen in two different planes. This is distinguished from a density, which is seen only in a single plane. The shape of masses is described as round, oval, lobular, or irregular, while the margins are identified as circumscribed (with well-defined margins), indistinct, and spiculated (with densities radiating from the margins). Calcifications associated with benign disease are generally larger than those seen with malignancy and typically are coarse (round, lucent centered, or “layering” on medial lateral or lateral medial images). Clustered amorphous,

indistinct, pleomorphic (or heterogeneous), or fine, linear, or branching calcifications are more typical of carcinomas (Gartlehner et al, 2013).

2.6.2.2. MRI

Breast MRI has become an integral part of breast cancer diagnosis and management in selected patients. Current indications for breast MRI include evaluation of patients in whom mammographic evaluation is limited by augmentation (including silicone and saline implants and silicone injections), determining the extent of disease at the time of initial diagnosis of breast cancer (including identification of invasion of the pectoralis major, serratus anterior, and intercostal muscles), evaluation of inconclusive findings on clinical examination, mammography, and/or ultrasonography, screening of the contralateral breast in selected patients with newly diagnosed breast carcinoma, and asymptomatic screening of patients at very high risk of breast carcinoma (in conjunction with routine mammography) (Leung, 2018).

Other uses of breast MRI include evaluation of response to neoadjuvant chemotherapy with imaging before, during, and/or after treatment, and identification of residual disease in patients with positive margins after lumpectomy (Covington et al, 2018).

2.6.2.3. Ultrasound

The current indications for breast ultrasonography include palpable findings (including as the initial imaging test of palpable findings in patients who are younger than 30 years, pregnant, or lactating), abnormalities or suspected abnormalities on mammography or MRI, problems with breast implants, suspected underlying mass in the setting of microcalcifications or

architectural distortion on mammography, supplemental screening in women at high risk for breast cancer who are not candidates for or do not have easy access to MRI, and suspected axillary lymphadenopathy. Real-time imaging is also possible with ultrasonography, making it ideal for interventional procedures. Breast ultrasound imaging should be performed with a high-resolution real-time linear array transducer with a center frequency of at least 10 MHz, using the highest frequency with which adequate penetration of the tissue is feasible (Lieberman and Menell, 2002).

2.6.3. Prognostic indicators

2.6.3.1. Estrogen receptor and progesterone receptor status

Estrogen receptor (ER) and progesterone receptor (PR) represent weak prognostic factors for patients with breast cancer, but these receptors are the strongest predictive factors for response to endocrine therapy. ER and PR assays should be performed on all invasive breast cancers. Both ER and PR are assessed by immunohistochemistry (IHC) on paraffin sections. IHC allows assessment of the expression specifically in either invasive or in situ cancer. Positive interpretation requires at least 1% of tumor cells showing positive nuclear staining of any intensity. Receptor negative is reported if less than 1% of tumor cells show staining of any intensity. The cutoff to define positivity is 1% because patients with even 1% ER/PR-positive tumors may benefit from hormonal therapy. About 70% of all breast cancers are ER-positive and 60% to 65% of all breast cancers are PR-positive. For the patients with a “weak positive” result an Allred score helps differentiate positive from negative receptor status. The Allred score categorizes the percentage of cells (scored from 0 to 5) with the intensity (scored from 0 to

3) and adds these two scores to give a numerical score from 0 to 8. A score of 0-2 was regarded as negative and 3-8 as positive (To, 2010).

2.6.3.2. HER2 protein expression and gene amplification

HER-2/neu is a proto-oncogene that encodes for a transmembrane tyrosine kinase growth receptor, and it is involved in several regulatory pathways in breast, involving proliferation, survival, cell motility, and invasion. HER2 is usually assessed by IHC. Fluorescence in situ hybridization (FISH) assay of HER2 expression is usually performed when the evaluation by IHC is equivocal. HER2 is a prognostic factor for outcome in both node-negative and node-positive patients and is a predictive factor for response to certain therapies that target the HER-2/neu receptor such as trastuzumab (Herceptin), a monoclonal antibody targeted to the HER2 protein, and other newer anti-HER2 agents (Agnese and Russo, 2003).

Over expression/amplification is reported in 10% to 34% of invasive breast cancers. Gene over expression and amplification and surface membrane protein expression are concordant in more than 90% of cases (Agnese and Russo, 2003).

Management After a breast cancer has been diagnosed, the patient is clinically staged using the American Joint Commission on Cancer (AJCC) guidelines (Tables 2 and 3). Several landmark trials with decades of follow-up form the foundation of contemporary breast surgery. The National Surgical Adjuvant Breast and Bowel Project (NSABP) B-04 trial compared radical mastectomy (RM) to total mastectomy (TM) with or without radiation therapy in a prospective randomized fashion. In the TM arm,

axillary dissection was performed only if lymph nodes were positive (Feld et al, 2018).

The investigators reported no difference in either group with regard to disease-free survival, relapse-free survival, distant-disease-free survival, or overall survival, confirming no advantage to RM. The NSABP B-06 trial prospectively randomized women with tumors less than 4 cm to mastectomy, lumpectomy, or lumpectomy with radiation. All women had an ALND regardless of treatment assignment or nodal status; negative margins, defined as no tumor at ink, were required. The 20-year follow-up data were published in 2002; the investigators found no difference in disease-free, distant-disease-free, or overall survival between any of the treatment arms. The data did demonstrate, however, a significant reduction in local recurrence (LR) after lumpectomy with the addition of radiation therapy (39.2% vs 14.3%, $P < 0.001$) (Fisher et al, 2002).

The National Institutes of Health (NIH) issued a Consensus Conference statement in 1990 recommending BCT as the preferred surgical treatment of women with early stage breast cancer. Contraindications to BCT exist and are classified as absolute or relative. Absolute contraindications include multicentric disease (tumors in more than one quadrant of the breast), diffuse malignant-appearing calcifications, and inflammatory breast cancer, prior radiation to the chest or breast or inability to receive radiation, persistent positive margins despite appropriate attempts for breast conserving surgery, and the need for radiation during pregnancy. Skin dimpling, nipple and areolar retraction, and tumor location are not contraindications to BCT, yet these should be considered in the preoperative assessment, specifically with respect to the ability to achieve negative

margins. Achieving negative surgical margins is a hallmark of successful BCT because this is associated with a lower rate of LR. However, what constitutes a negative margin remains a matter of considerable debate. The NSABP has long defined a negative margin as “no tumor at ink” regardless of the proximity of the nearest tumor cell (Panel, 1992).

Historically, other series have argued that margins of more than 1 mm, more than 2 mm, more than 5 mm, or even more than 10 mm provide better local control. A recent meta-analysis reviewed 21 studies and 14571 patients undergoing BCT. Data demonstrate a significant increase in LR for positive margins with an odds ratio (OR) of 2.42 ($P < 0.001$) compared with negative margins. Direct comparison between different margin widths found no statistically significant improvement in local control. Although a weak trend was identified suggesting declining LR with increasing margin distance, this trend disappeared after adjustments for radiation boost treatment and endocrine therapy (Voduc et al, 2010).

Neo-adjuvant chemotherapy increases eligibility for breast-conserving surgery, especially in patients presenting with locally advanced breast cancer or in borderline cases whereby the tumor-to-breast size ratio will not allow for excision and acceptable cosmetic results. NSABP B-1840 established the efficacy of neo-adjuvant therapy randomizing women with early stage breast cancer to 4 cycles of neo-adjuvant or adjuvant doxorubicin plus cyclophosphamide. An updated analysis with more than 16 years of follow-up demonstrates no difference in overall survival, disease-free survival, or event-free survival between the two arms. Women receiving neo- adjuvant therapy had a higher rate of pathologic negative axillary lymph nodes at surgery and a higher rate of BCT (Cocciolone et al, 2018).

Radiation therapy plays a crucial role in successful BCT and has long been recognized to reduce LR risk by approximately 50%. The 2005 Early Breast Cancer Trialists' Collaborative Group's (EBCTCG) overview analyses demonstrated the influence of local control on long-term survival. With regard to BCT, the EBCTCG collectively analyzed data from 10 trials of 7300 women and found the risk of LR at 5 years to be significantly reduced from 26% after lumpectomy alone to 7% after lumpectomy with radiation therapy, an absolute reduction of 19%. The EBCTCG recently updated this data in 2011, expanding their analysis to 17 randomized trials of 10801 women undergoing breast-conserving surgery with and without radiotherapy. This meta-analysis again confirmed that radiation therapy resulted in an overall absolute reduction in LR of 15.7% at 10 years compared with those not receiving radiation (19.3% vs 35.0%, $P < 0.00001$, two-tailed); this translated into an absolute reduction in breast cancer death of 3.8% at 15 years. LR after BCT can be described as: (1) a true recurrence, one within the primary tumor bed; (2) a marginal miss, one within the same quadrant just outside of the tumor bed; and (3) an elsewhere recurrence, one in a separate quadrant of the breast. Generally, true recurrences and marginal misses account for 46% to 91% of all LRs and tend to occur earlier than elsewhere recurrences (Shen et al, 2018).

The EBCTCG demonstrates that more than 75% of all recurrences occur within 5 years. Risk factors for LR include positive margins, young age, ER-negative receptor status, larger tumor size, positive nodes, and lymphovascular invasion. Systemic therapy, especially targeted therapy, reduces the risk of LR. For example, the adjuvant trastuzumab trials demonstrate that patients receiving trastuzumab had a 50% reduction in LR.

Similarly, Mamounas and colleagues evaluated LR in estrogen receptor-positive patients enrolled in NSABP B-14 and NSABP B-20 according to the 21-gene recurrence score assay (Oncotype DX, Genomic Health, Redwood City, California, United States). At 10 years, tamoxifen significantly reduced the risk of LR in the low-risk group from 10.8% to 4.3% ($P < 0.001$). The addition of chemotherapy further reduced LR to 1.6% in that group ($P = 5.028$) (Sparano et al, 2018).

2.7. The Breast Imaging Reporting and Data System (BI-RADS)

Sonography has emerged as the most important adjunct to mammography in the diagnosis of breast diseases. Furthermore, many authors have proposed that sonography screening in patients with mammographically dense breasts might have benefits. Increased use of breast sonography necessitates a standardized method for lesion characterization, description, and reporting (Lieberman and Menell, 2002).

In 2003 the American College of Radiology (ACR) established the BI-RADS lexicon for sonography. BI-RADS provides a categorization system for sonography features including shape, margins, lesion boundary, orientation, echogenicity, posterior acoustic characteristics, and associated features. Thus, the final assessment and associated recommendations are based on analysis of multiple features (Radiology, 2012).

The term breast density refers to the relative amount of radiopaque epithelial and stromal tissue elements compared with the amount of radiolucent fatty elements seen at mammography. Different parenchymal density patterns were first described by Leborgne in 1953 and were subsequently classified in 1976 by Wolfe as possible risk factors for breast cancer. Since its

inception, the (BI-RADS) lexicon has classified mammographic density into four categories, with the percentage of each tissue density in the general screening population estimated as follows: 10% of women have breasts that are almost entirely fatty, 40% have scattered areas of fibroglandular density, 40% have heterogeneously dense breasts, and 10% have extremely dense breasts. The 4th edition of the BI-RADS lexicon created quartiles for each of the four density categories (<25% glandular, 25 – 50% glandular, 51 – 75% dense, and >75% dense, respectively) in an attempt to distribute the population more equally among the categories; however, these quartiles proved to make very little difference and were removed from the BI-RADS 5th edition. As noted in the BI-RADS 5th edition, there is very little difference between the tissue patterns, and likely the risk for malignancy, in women toward the denser end of the “scattered areas of fibroglandular density” pattern and women at the less dense end of the “heterogeneously dense” category (Radiology, 2012).

Breast density affects mammographic screening in two primary ways: breast density has a masking effect on underlying cancers and also is an independent risk factor for breast cancer (Radiology, 2012).

It is well established that mammographic sensitivity decreases with increasing density, largely as a function of the superimposition of overlapping radiopaque dense breast tissue on an underlying cancer when the three-dimensional breast is imaged in a two-dimensional plane. The language of the BI-RADS lexicon accounts for this by wording the dense tissue patterns as “the breasts are heterogeneously dense, which may obscure small masses” and “the breasts are extremely dense, which lowers the sensitivity of mammography”. The decrease in mammographic sensitivity

with increasing tissue density was established by using film-screen mammography. In two separate Breast Cancer Surveillance Consortium (BCSC) reports of film-screen mammography, mammographic sensitivity decreased from a level of 85.7%–88.8% in patients with almost entirely fatty tissue to 62.2%–68.1% in patients with extremely dense breast tissue (Radiology, 2012).

The relative risk of breast density is much smaller than that of other major risk factors for breast cancer, such as age, family history, reproductive history, and genetic mutations. However, because mammographically dense breasts are relatively common (approximately 50% of the screening population), some authors have proposed that the risk factor of density alone contributes far more cancer risk to the population than other much stronger but less common risk factors, such as a significant family history or known deleterious genetic mutations such as BRCA mutations (Lieberman and Menell, 2002).

Breast density itself is an independent risk factor for breast cancer, although the degree to which it is an independent risk factor is debated among experts and is highly controversial. Breast density as a risk factor seems intuitive because density refers to the amount of epithelial and stromal elements of the breast, and breast cancers most commonly arise in epithelial cells. A greater amount of epithelial tissue in the breast indicates a greater chance that cancer may arise in one of the epithelial cells. Some researchers propose that breast density may increase the risk for breast cancer by up to six times, and breast density is often reported to cause a fourfold increase in the risk for breast cancer in women with dense breasts (Radiology, 2012).

2.8. Breast cancer treatment

The next step after the diagnosis and staging is the selection of a treatment plan. The choice of treatment strongly depends on the stage of the disease, specific tumor characteristics (e.g., grade, type and subtype), patient's characteristics (e.g., age and physical condition) and prognosis. The patient's preferences are also taken into account. A treatment plan is generally based on national guidelines and discussed in a multidisciplinary meeting of breast cancer specialists (surgeons, radiologist, radiation oncologists, pathologists, nurse practitioners, medical oncologists, etc.).

The treatment of breast cancer consists of loco-regional and systematic treatment. Local or regional treatment affects the site of the primary tumor and its surrounding. This is done with surgery and radiotherapy. Surgery depends on the stage of the disease and varies from removal of the tumor only to removal of the whole breast with adjacent lymph nodes.

After surgery, radiotherapy is typically applied to the whole breast or thoracic wall, and, when indicated, to the adjacent lymph node regions. The procedure of limited surgery to excise the tumor and postoperative radiotherapy is termed "breast-conserving therapy" (BCT). The value of radiotherapy as an adjunct to surgery to achieve long-term local control has been proven in large randomized controlled trials (RCTs) (Kreike et al., 2008).

Systemic treatment is given in selected patient groups and includes chemotherapy, endocrine therapy or targeted-therapy. Several chemotherapy regimens are applied clinically or are being tested in large trials. Endocrine therapy is applied in ER-positive tumors but not in tumors with negative

hormonal receptor status, e.g., triple-negative tumors. Target-therapy is treatment that targets specific properties of the tumor that are not overexpressed in normal cells. For example, HER2-positive tumors are treated with targeted HER2-therapy (e.g., trastuzumab and pertuzumab).

Traditionally, systemic therapy is given after surgery and radiotherapy. This procedure is termed “adjuvant systemic therapy”. Over the last 2 decades, however, neoadjuvant chemotherapy (NAC), also referred to as ‘preoperative’ or ‘primary systemic therapy’, has steadily become an accepted treatment strategy. During NAC the systemic therapy is given as first treatment, i.e., before surgery (Cocciolone et al., 2018).

NAC has several advantages. First, by reducing the size of the tumor, it may allow breastconserving surgery (BCS) instead of mastectomy in about 16% to 37% of all patients. Second, NAC offers an excellent platform for translational research, because the molecular characteristics of breast cancer can be directly related to chemo-sensitivity. Third, monitoring of the treatment effect with imaging during NAC enables adaptations of the treatment in case of an unfavourable tumor response (Cocciolone et al., 2018).

There is emerging evidence that pathological complete response (pCR) after treatment in triple-negative and HER2-positive tumors is associated with better disease-free survival rates. Therefore, achieving pCR is an important aim of NAC. Accurate monitoring of treatment response may increase the efficacy of systemic therapy by adapting the regimen based on imaging findings (Shah et al., 2003).

Chapter Three

Materials and Methods

Chapter Three

Materials and Methods

3.1. Study design

Descriptive cross sectional study in Kartoum, Sudan.

3. 2. Study area

Study was conducted in national Ribat hospital.

3. 3. Study population

Participants of this study were patients visiting the hospitals for breast radiological investigations.

3. 4. Sample size

Seventy one women were recruited to the study after their approval, 48 suspected and 23 known breast cancer patients under treatment.

3.5. Inclusion Criteria

Ladies who were selected had to comply the followings:

- Female over 35 years old
- Female that had presented with breast malignant lesion either in clinical examination or with mammogram.

3.6. Exclusion Criteria

Ladies younger than 35 years old we excluded as screening mammography is only recommended to start at age of 35 years old.

3.7. Data collection

3.7.1. Instrumentation and technique

Ultrasound machine (Philips / Neusoft) with 10 MHZ probe with facility of computerized reporting system were used. After mammogram done the

patient send to sonographic room. The patient lying supine and raise both hand over the head .the scan technique done by high frequency transducer (8-10 Hz), radial scan pattern (clock-face). The scan begins at 12 o'clock in a sagittal plan, and then the probe rotating around the nipple .there is also scan the axillary and supraclavicular areas.

3.7.2. Histopathology examination

Histopathology examination was conducted for all patients with BIRADS IV&V grade lesions.

3.8. Data storage

All data collected during the study was stored in personal computer, data collecting sheets and the US Images were also stored and saved.

3.9. Data analysis

The Data was arranged in tables, and analyzed by highly computerized statistical program (SPSS) version 13.

3.10. Ethical consideration

Permission of both patients and US Department of National Ribat Hospital prior of conducting the study, patient personal information was kept confidential.

Chapter Four

Results

Chapter Four

Results

4.1 Results:

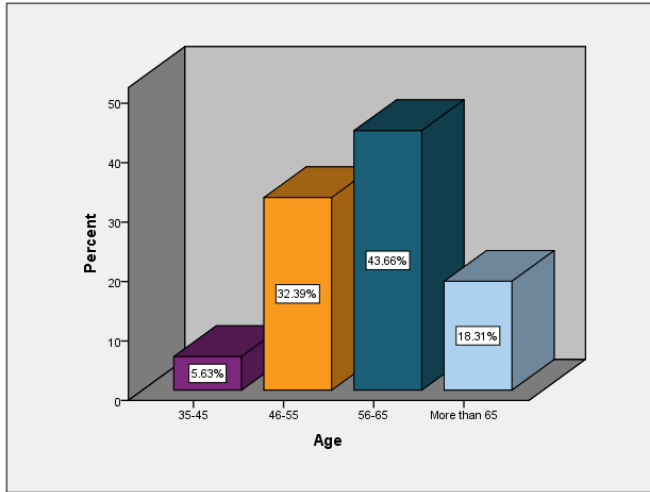


Fig 1: Age wise distribution of suspected women participated in the study.

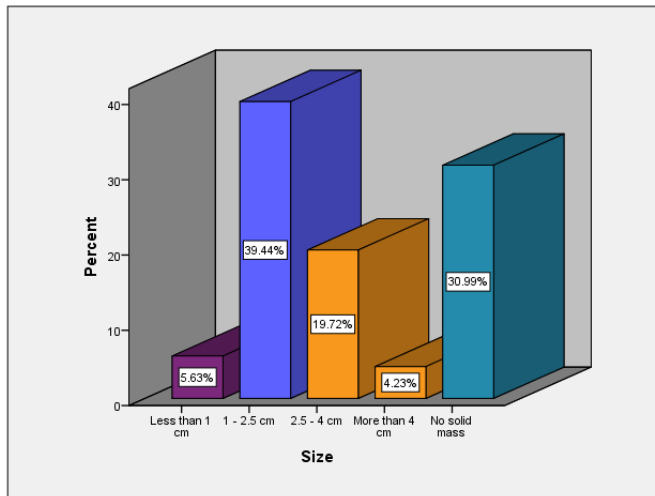


Fig 2: Size of breast lesions among women participated in the study.

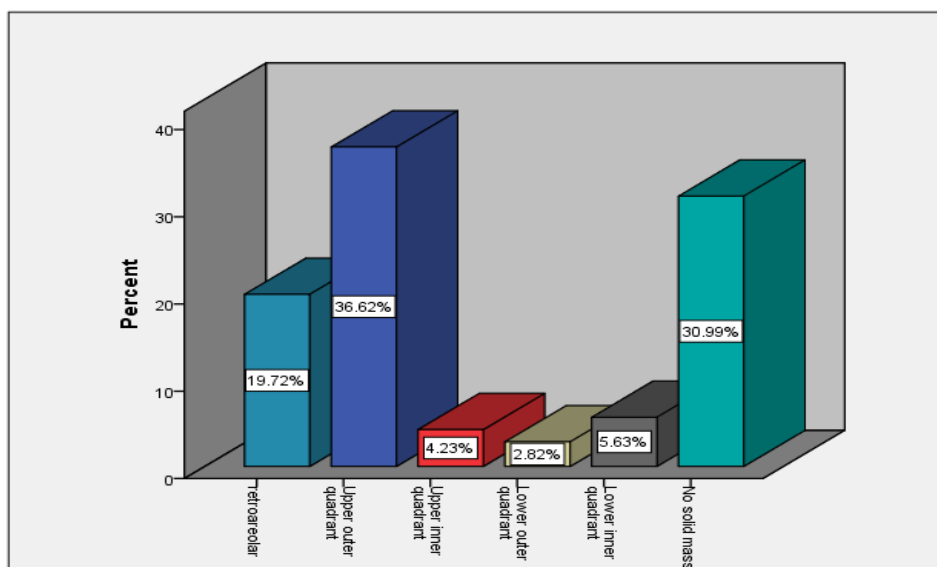


Fig 3: Location of breast lesions among women participated in the study.

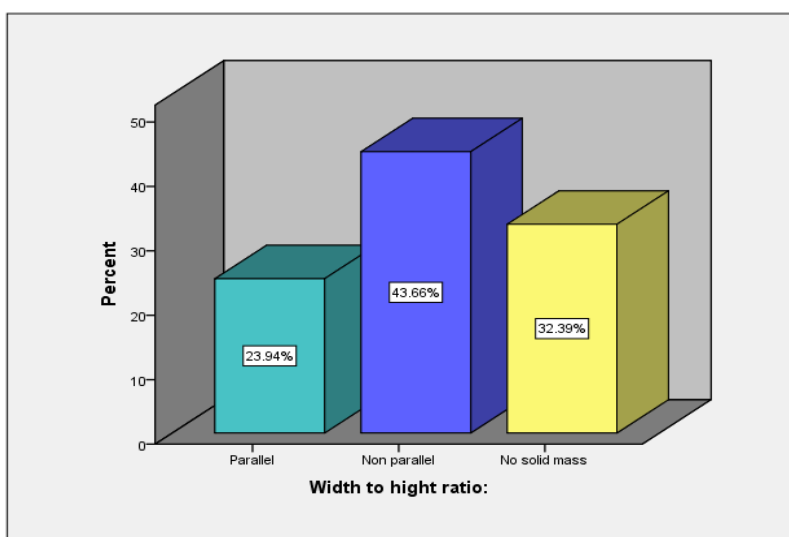


Fig 4: Width to height ratio of breast lesions among women participated in the study.

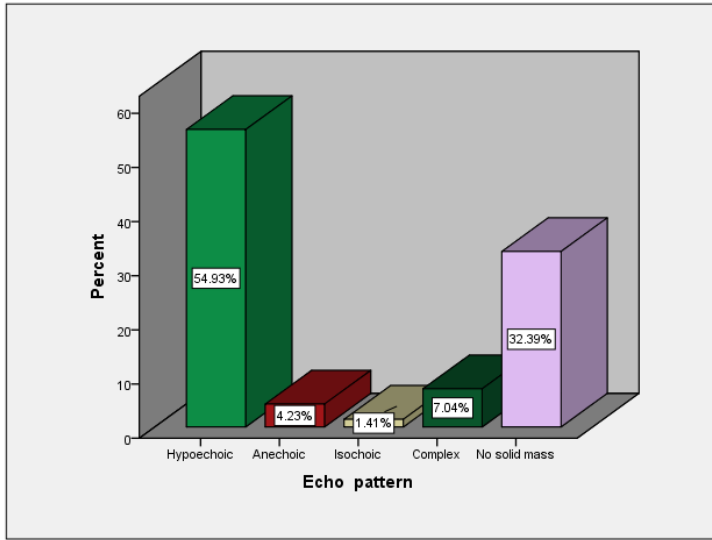


Fig 5: Echo patterns of US among suspected women participated in the study.

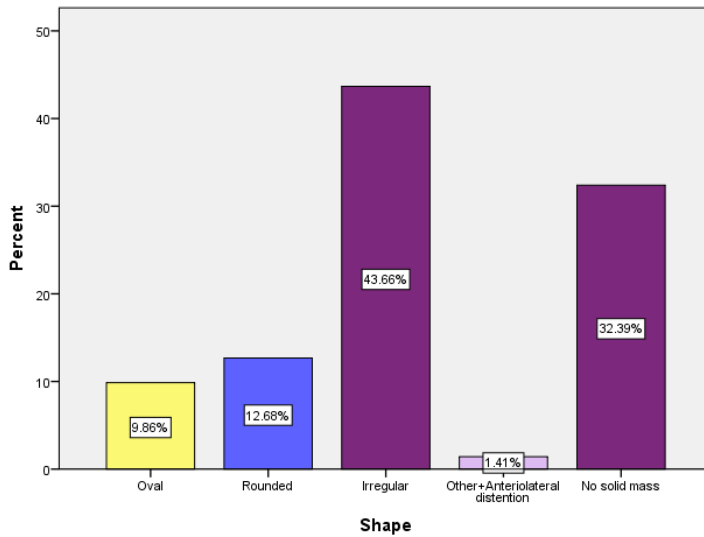


Fig 6: Shape of breast lesions among women participated in the study.

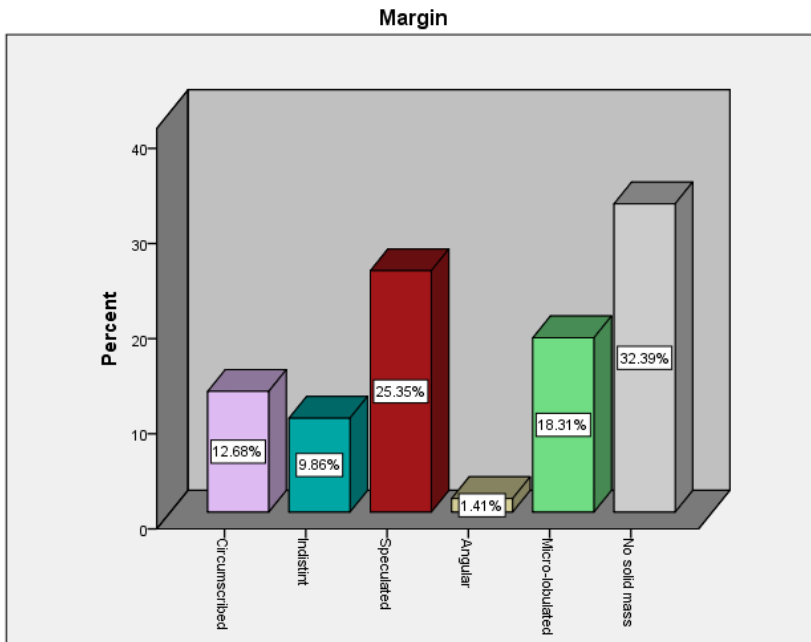


Fig 7: Margin of breast lesions among women participated in the study.

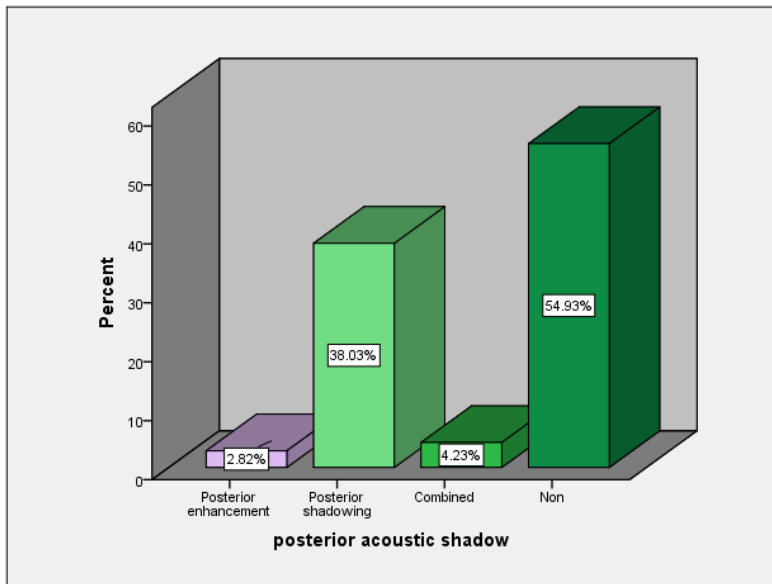


Fig 8: Posterior acoustic shadowing among women participated in the study.

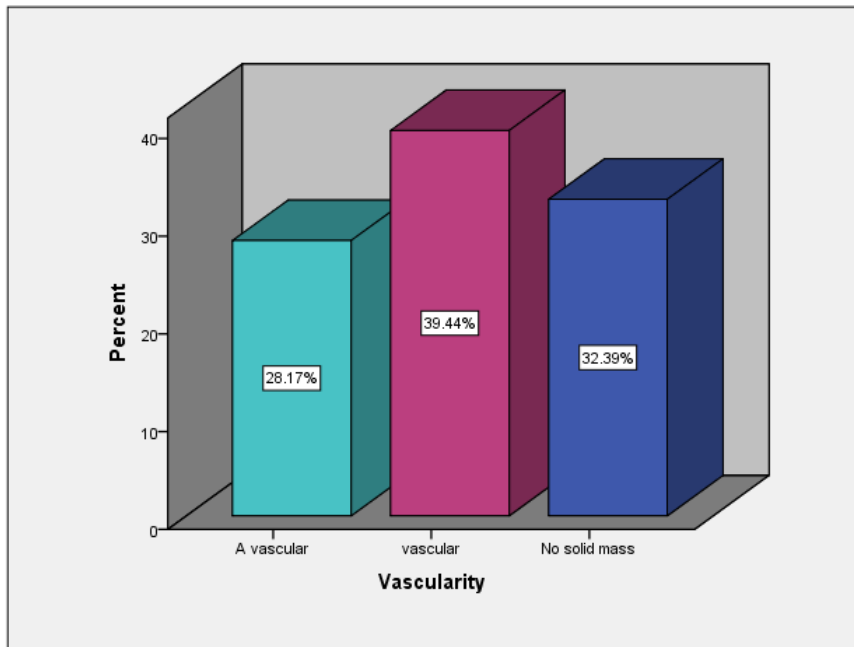


Fig 9: Vascularity of breast lesions among women participated in the study.

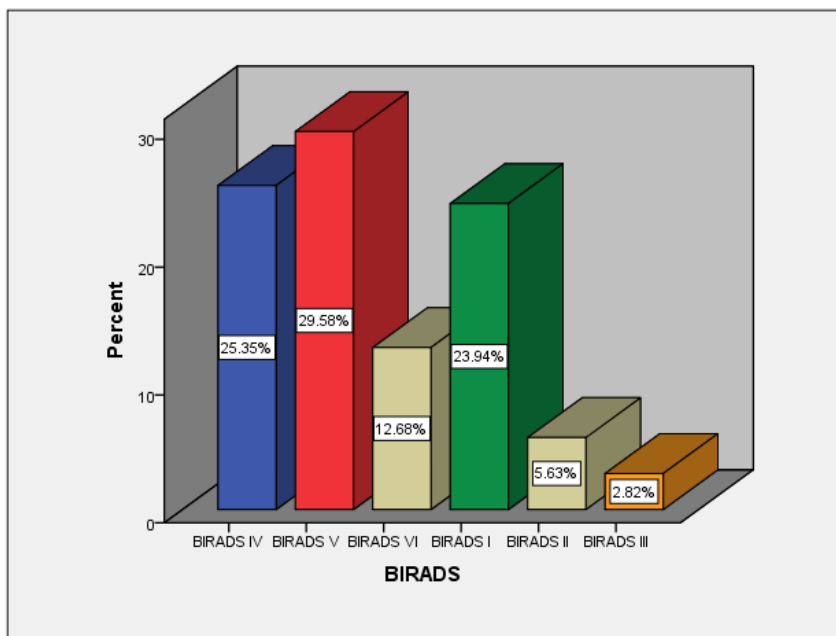


Fig 10: BIRADS classification of breast lesions among women participated in the study.

Table 1: BIRADS and histopathology examination results of all breast lesions

Histopathology result	BIRADS						Total
	BIRADS IV	BIRADS V	BIRADS VI	BIRADS I	BIRADS II	BIRADS III	
Intra ductal carcinoma	12	16	6	0	0	2	36
Invasive mucinous carcinoma	2	0	0	0	1	0	3
Invasive ductal carcinoma	1	0	0	0	0	0	1
Intra ductal papillomatosis	2	0	0	0	0	0	2
Intra ductal hyperplasia	1	0	0	0	0	0	1
Malignant melanoma	0	1	0	0	0	0	1
Negative histopathology for cancer	0	2	0	17	3	0	22
Invasive lobular carcinoma	0	2	2	0	0	0	4
Invasive medullary carcinoma	0	0	1	0	0	0	1
Total	18	21	9	17	4	2	71

Table 2: Other associated features of breast lesions among women participated in the study.

Histopathology result	any other associated features							Total
	Axillary lymph-nodes	Calcification	Non	Other	Ductal dilatation	Axillary lymph-nodes and others	Axillary lymph-nodes, Calcification and others	
Intra ductal carcinoma	10	4	15	2	0	3	2	36
Invasive mucinous carcinoma	0	1	2	0	0	0	0	3
Invasive ductal carcinoma	0	0	1	0	0	0	0	1
Intra ductal papillomatosis	1	0	0	0	1	0	0	2
Intra ductal hyperplasia	0	0	1	0	0	0	0	1
Malignant melanoma	0	0	1	0	0	0	0	1
Negative histopathology for cancer	2	0	18	2	0	0	0	22
Invasive lobular carcinoma	0	0	2	0	0	1	1	4
Invasive medullary carcinoma	0	0	0	0	0	1	0	1
Total	13	5	40	4	1	5	3	71

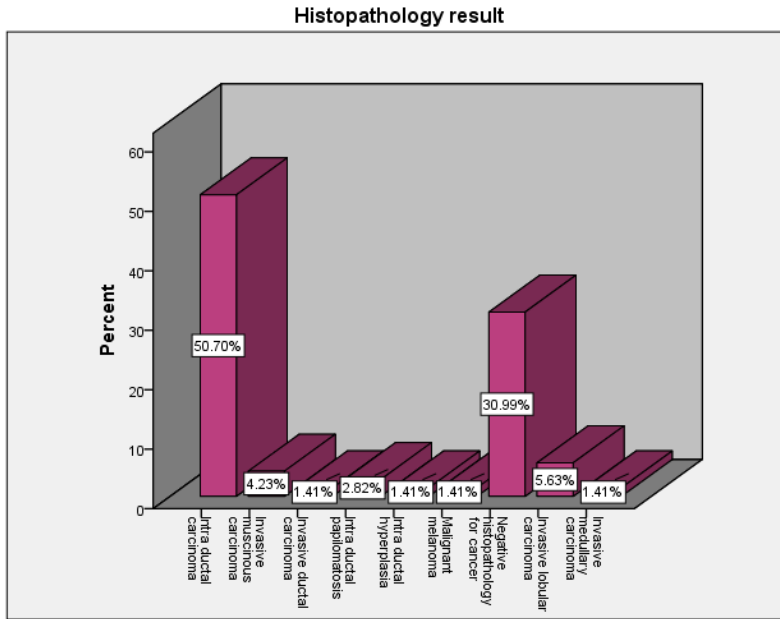


Fig 11: Type of malignancy of breast lesions among women participated in the study.

Chapter Five
Discussion, Conclusion and
Recommendations

Chapter Five

Discussion, conclusion and Recommendations

5.1. Discussion

In this prospective study, the 71 participated women in the study were screened by US. BIRADS category lesions were diagnosed in all 71 women after extensive conventional imaging work-up. However, BIRADS category 4&5 lesions were detected in 39 women. Among the 39 BIRADS category 4&5 lesions, 37 were true positive as indicated by the result of histopathology examination.

The use of imaging to resolve equivocal breast imaging findings has become a delicate task with the advent of minimally invasive biopsy. Imaging guided biopsy, especially with vacuum assistance, offers high accuracy. The reported false-negative rate for imaging guided biopsy is low overall. However, it is reported to be as high as 9% for 14-gauge core biopsy ^[64]. Although the time consuming histopathology examination, the high diagnostic accuracy that is achievable with core biopsy, together with the widespread availability of such procedures, means that there is little tolerance for false-negative results of the work-up of possibly malignant screening findings. It is well known, however, that imaging findings classified as BI-RADS category 4 & 5 cover a wide range of malignancy rates; the current BI-RADS lexicon specifies a likelihood of malignancy of greater than 2% to less than 95% and recommends tissue sampling as the single acceptable management option (D'Orsi, 2013).

In the worst-case scenario (ie, findings that reflect the lower boundary of this range), this means that invasive tissue sampling may be recommended for a patient even though the likelihood of a benign result could be as high as 97%.

The present study indicated that the assessment of breast lesions with the use of the BI-RADS US lexicon shows a significant diagnostic reliability for description of breast cancer.

5.2. Conclusion

The present study indicated that the assessment of breast lesions with the use of the BI-RADS US lexicon shows a significant diagnostic reliability for description of breast cancer.

5.3. Recommendations

- Radiologist working in women breast imaging should use BIRADS scoring system to reduce the confusion in imaging interpretation.
- For women with dense breasts tissue but no additional risk factors, US may be useful as an adjacent to mammography for incremental cancer detection, but the balance between increased cancer detection and the increased risk of a false positive examination should be considered in the decision.
- Further researches with larger sample size are appreciated to support this finding.

References:

- AGNESE, V. & RUSSO, A. 2003. A gene-expression signature as a predictor of survival in breast cancer. *Women's Oncology Review*, 3, 123.
- ARLEO, E. K., DASHEVSKY, B. Z., REICHMAN, M., BABAGBEMI, K., DROTMAN, M. & ROSENBLATT, R. 2013. Screening mammography for women in their 40s: a retrospective study of the potential impact of the U.S. Preventive Service Task Force's 2009 breast cancer screening recommendations. *AJR Am J Roentgenol*, 201, 1401-6.
- AUTIER, P. & BONIOL, M. 2013. Effect of screening mammography on breast cancer incidence. *N Engl J Med*, 368, 677.
- BAUN, C., FALCH, K., GERKE, O., HANSEN, J., NGUYEN, T., ALAVI, A., HOILUND-CARLSEN, P. F. & HILDEBRANDT, M. G. 2018. Quantification of FDG-PET/CT with delayed imaging in patients with newly diagnosed recurrent breast cancer. *BMC Med Imaging*, 18, 11.
- CHEN, Z., FU, F., LI, F., ZHU, Z., YANG, Y., CHEN, X., JIA, B., ZHENG, S., HUANG, C. & MIAO, W. 2018. Comparison of [(99m)Tc]3PRGD2 Imaging and [(18)F]FDG PET/CT in Breast Cancer and Expression of Integrin alphavbeta3 in Breast Cancer Vascular Endothelial Cells. *Mol Imaging Biol*.
- CHOI, K. S., YOON, M., SONG, S. H., SUH, M., PARK, B., JUNG, K. W. & JUN, J. K. 2018. Effect of mammography screening on stage at breast cancer diagnosis: results from the Korea National Cancer Screening Program. *Sci Rep*, 8, 8882.
- COCCIOLONE, V., CANNITA, K., TESSITORE, A., MASTROIACO, V., RINALDI, L., PARADISI, S., IRELLI, A., BALDI, P. L., SIDONI, T., RICEVUTO, E., DAL MAS, A., CALVISI, G., COLETTI, G., CICOZZI, A., PIZZORNO, L., RESTA, V., BAFILE, A., ALESSE, E. & FICORELLA, C. 2018. Neoadjuvant chemotherapy in breast cancer: a dose-dense schedule in real life and putative role of PIK3CA mutations. *Oncotarget*, 9, 27380-27396.
- COVINGTON, M. F., YOUNG, C. A. & APPLETON, C. M. 2018. American College of Radiology Accreditation, Performance Metrics, Reimbursement, and Economic

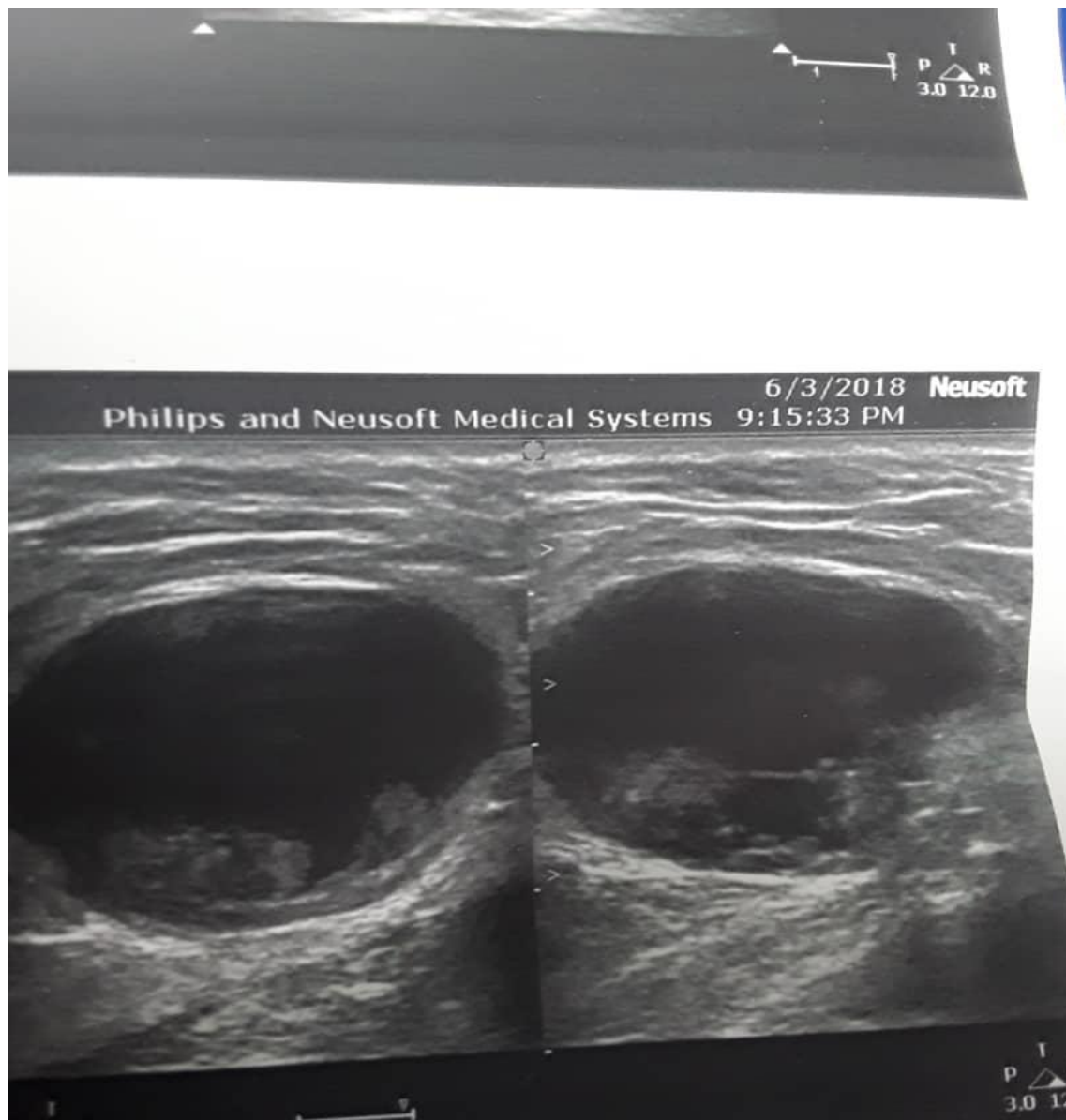
- Considerations in Breast MR Imaging. *Magn Reson Imaging Clin N Am*, 26, 303-314.
- D'ORSI, C. J. 2013. *ACR BI-RADS atlas: breast imaging reporting and data system*, American College of Radiology.
- DE BENEDETTO, D., ABDULCADIR, D., GIANNOTTI, E., NOR, J., VANZ, E. & CAPACCIO, L. 2016. Radiological anatomy of the breast. *Ital J Anat Embryol*, 121, 20-36.
- FELD, S. I., FAN, J., YUAN, M., WU, Y., WOO, K. M., ALEXANDRIDIS, R. & BURNSIDE, E. S. 2018. Utility of Genetic Testing in Addition to Mammography for Determining Risk of Breast Cancer Depends on Patient Age. *AMIA Jt Summits Transl Sci Proc*, 2017, 81-90.
- FENNER, L., KASSNER, A., BERLIN, C., EGGER, M. & ZWAHLEN, M. 2018. Trends in the use of mammography for early breast cancer detection in Switzerland: Swiss Health Surveys 2007 and 2012. *Swiss Med Wkly*, 148, w14603.
- FISHER, B., JEONG, J.-H., ANDERSON, S., BRYANT, J., FISHER, E. R. & WOLMARK, N. 2002. Twenty-five-year follow-up of a randomized trial comparing radical mastectomy, total mastectomy, and total mastectomy followed by irradiation. *New England Journal of Medicine*, 347, 567-575.
- GARTLEHNER, G., THALER, K., CHAPMAN, A., KAMINSKI-HARTENTHALER, A., BERZACZY, D., VAN NOORD, M. G. & HELBICH, T. H. 2013. Mammography in combination with breast ultrasonography versus mammography for breast cancer screening in women at average risk. *Cochrane Database Syst Rev*, 4, CD009632.
- JORGENSEN, K. J. & GOTZSCHE, P. C. 2013. Effect of screening mammography on breast cancer incidence. *N Engl J Med*, 368, 677-8.
- KELLY, K. M., DEAN, J., COMULADA, W. S. & LEE, S.-J. 2010. Breast cancer detection using automated whole breast ultrasound and mammography in radiographically dense breasts. *Eur Radiol*, 20, 734-742.
- KLOCK, J. C., IUANOW, E., MALIK, B., OBUCHOWSKI, N. A., WISKIN, J. & LENOX, M. 2016. Anatomy-Related Breast Imaging and Visual Grading

- Analysis Using Quantitative Transmission Ultrasound. *Int J Biomed Imaging*, 2016, 7570406.
- KREIKE, B., HART, A. A., VAN DE VELDE, T., BORGER, J., PETERSE, H., RUTGERS, E., BARTELINK, H. & VAN DE VIJVER, M. J. 2008. Continuing risk of ipsilateral breast relapse after breast-conserving therapy at long-term follow-up. *International Journal of Radiation Oncology* Biology* Physics*, 71, 1014-1021.
- LANNIN, D. R. 2013. Effect of screening mammography on breast cancer incidence. *N Engl J Med*, 368, 678.
- LEUNG, J. W. T. 2018. Breast MR Imaging in Era of Value-Based Medicine. *Magn Reson Imaging Clin N Am*, 26, xiii-xiv.
- LIBERMAN, L. & MENELL, J. H. 2002. Breast imaging reporting and data system (BI-RADS). *Radiologic Clinics*, 40, 409-430.
- MARTAINDALE, S. R. 2018. Breast MR Imaging: Atlas of Anatomy, Physiology, Pathophysiology, and Breast Imaging Reporting and Data Systems Lexicon. *Magn Reson Imaging Clin N Am*, 26, 179-190.
- MORRELL, S., GREGORY, M., SEXTON, K., WHARTON, J., SHARMA, N. & TAYLOR, R. 2018. Absence of sustained breast cancer incidence inflation in a national mammography screening programme. *J Med Screen*, 969141318775766.
- PANEL, N. I. O. H. C. D. 1992. Consensus statement; treatment of early stage breast cancer. *J Natl Cancer Inst Monogr*, 11, 1-5.
- PATTACINI, P., NITROSI, A., ROSSI, P. G., IOTTI, V., GINOCCHI, V., RAVAIOLI, S., VACONDIO, R., BRAGLIA, L., CAVUTO, S. & CAMPARI, C. 2018. Digital Mammography versus Digital Mammography Plus Tomosynthesis for Breast Cancer Screening: The Reggio Emilia Tomosynthesis Randomized Trial. *Radiology*, 172119.
- RADIOLOGY, A. C. O. 2012. American College of Radiology BI-RADS® ATLAS and MQSA: frequently asked questions (updated: DRAFT 11/29/12). *Reston: American College of Radiology*.

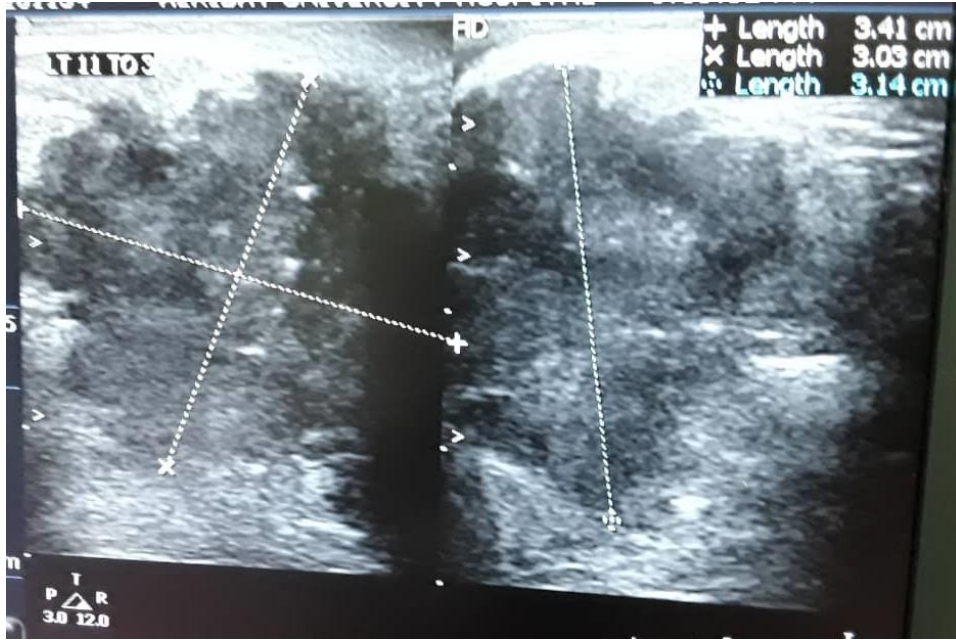- RAVERT, P. K. & HUFFAKER, C. 2010. Breast cancer screening in women: An integrative literature review. *Journal of the American Academy of Nurse Practitioners*, 22, 668-673.
- SHAH, V. I., RAJU, U., CHITALE, D., DESHPANDE, V., GREGORY, N. & STRAND, V. 2003. False-negative core needle biopsies of the breast: an analysis of clinical, radiologic, and pathologic findings in 27 consecutive cases of missed breast cancer. *Cancer: Interdisciplinary International Journal of the American Cancer Society*, 97, 1824-1831.
- SHEN, H., MU, C., WU, X., ZHOU, X., WOLFRAM, J., SHEN, J., ZHANG, D., MAI, J., XIA, X., HOLDER, A. M., FERRARI, M. & LIU, X. 2018. Chemotherapy sensitizes therapy-resistant cells to mild hyperthermia by suppressing heat shock protein 27 expression in triple negative breast cancer. *Clin Cancer Res*.
- SPARANO, J. A., GRAY, R. J., MAKOWER, D. F., PRITCHARD, K. I., ALBAIN, K. S., HAYES, D. F., GEYER, C. E., JR., DEES, E. C., GOETZ, M. P., OLSON, J. A., JR., LIVELY, T., BADVE, S. S., SAPHNER, T. J., WAGNER, L. I., WHELAN, T. J., ELLIS, M. J., PAIK, S., WOOD, W. C., RAVDIN, P. M., KEANE, M. M., GOMEZ MORENO, H. L., REDDY, P. S., GOGGINS, T. F., MAYER, I. A., BRUFISKY, A. M., TOPPMEYER, D. L., KAKLAMANI, V. G., BERENBERG, J. L., ABRAMS, J. & SLEDGE, G. W., JR. 2018. Adjuvant Chemotherapy Guided by a 21-Gene Expression Assay in Breast Cancer. *N Engl J Med*, 379, 111-121.
- STEINBACH, L. S. 2018. Breast MR Imaging. *Magn Reson Imaging Clin N Am*, 26, xi-xii.
- TAYLOR, R., GREGORY, M., SEXTON, K., WHARTON, J., SHARMA, N., AMOYAL, G. & MORRELL, S. 2018. Breast cancer mortality and screening mammography in New Zealand: Incidence-based and aggregate analyses. *J Med Screen*, 969141318776039.
- THERIAULT, R. L., CARLSON, R. W., ALLRED, C., ANDERSON, B. O., BURSTEIN, H. J., EDGE, S. B., FARRAR, W. B., FORERO, A., GIORDANO, S. H. & GOLDSTEIN, L. J. 2013. Breast cancer, version 3.2013. *Journal of the National Comprehensive Cancer Network*, 11, 753-761.

- TO, N. 2010. American Society of Clinical Oncology/College of American Pathologists Guideline Recommendations for Immunohistochemical Testing of Estrogen and Progesterone Receptors in Breast Cancer. *Arch Pathol Lab Med*, 134, E1-E25.
- VIDYA, R. & IQBAL, F. M. 2017. Breast anatomy: Time to classify the subpectoral and prepectoral spaces. *Clin Anat*, 30, 434-435.
- VODUC, K. D., CHEANG, M. C., TYLDESLEY, S., GELMON, K., NIELSEN, T. O. & KENNECKE, H. 2010. Breast cancer subtypes and the risk of local and regional relapse. *Journal of clinical oncology*, 28, 1684-1691.
- YIM, H., HA, T., KANG, D. K., PARK, S. Y., JUNG, Y. & KIM, T. H. 2018. Change in microcalcifications on mammography after neoadjuvant chemotherapy in breast cancer patients: correlation with tumor response grade and comparison with lesion extent. *Acta Radiol*, 284185118776491.

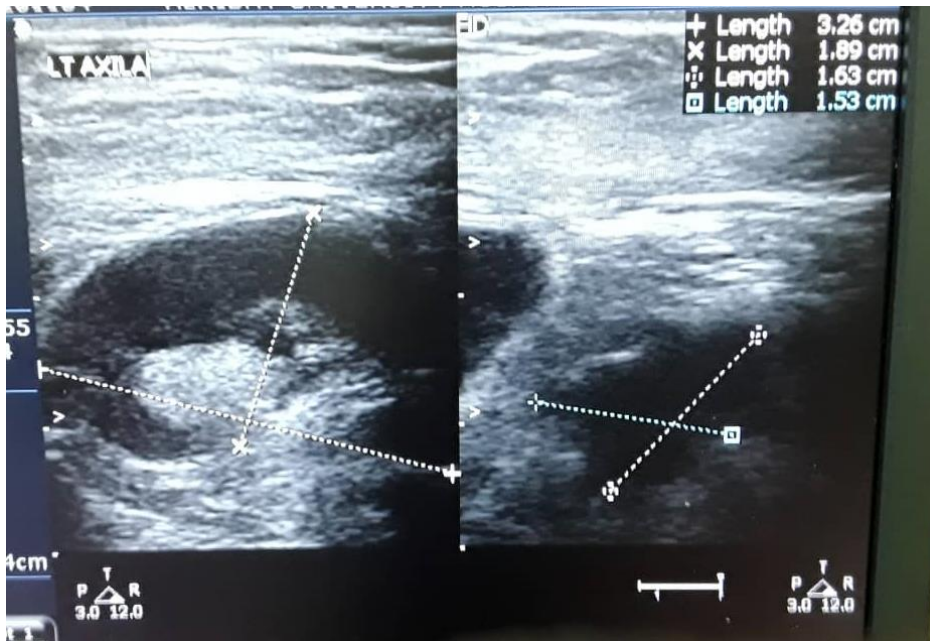
Appendix



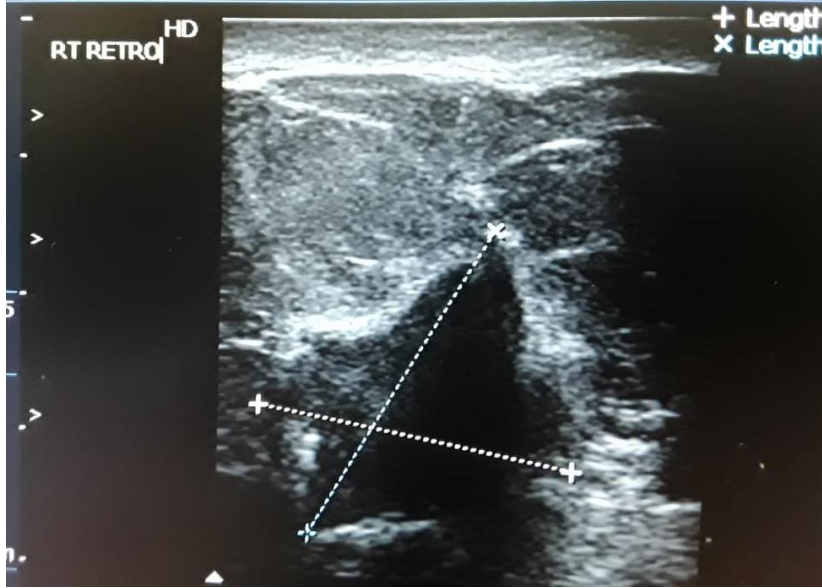
Case 1 : 55 year old female, Rt. Breast well defined oval shape smooth margin hypoechoic lesion wider than taller with solid hyperechoic mural component that was vascular on color flow (BIRADS IV), pathology: large ductal papilloma.



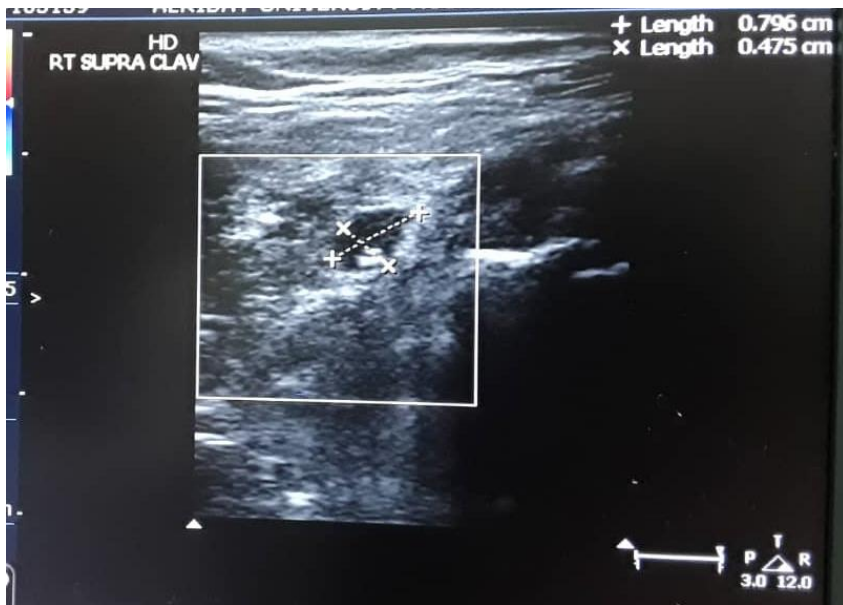
Case 2 : 45 years old female left breast solid mixed echogenicity irregular margin mass surrounded by hyperechoic rim of desmoplastic reaction & showing internal calcification, left axilla shows enlarged nodes with displaced and replaced hilum (BIRADS V), pathology IDC.

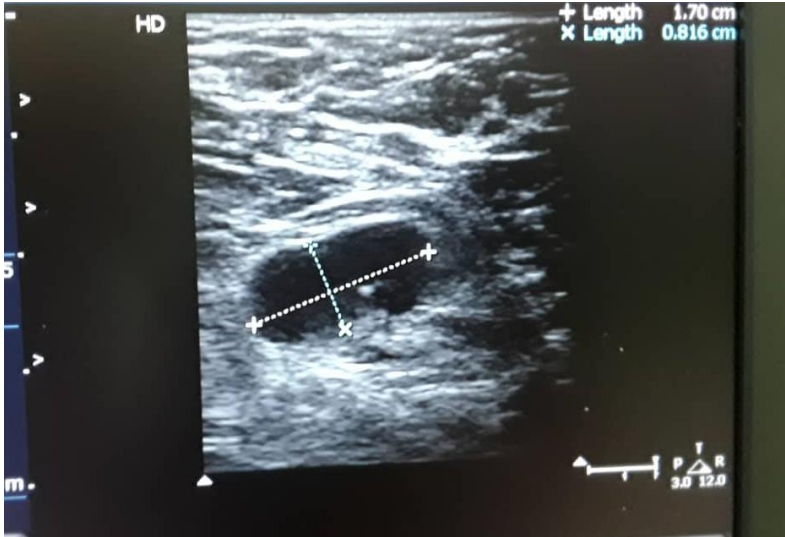


Case 2 : Same patient left axilla lymph-nodes .



Case 3 : 50 years old female right breast lump US: star shape hypoechoic solid hypo-vascular mass casting heavy posterior shadow and surrounded by desmoplastic reaction,





scanning of right axilla & right supraclavicular regions show infiltrated lymph nodes (BIRADS V), pathology IDC.