

بِسْمِ اللَّهِ الرَّحْمَنِ الرَّحِيمِ
**Sudan University of Science
& Technology**
College of Graduate Studies

**A Thesis Submitted for Partial Fulfillment of
the Requirement for the MSCD in Diagnostic
Radiology**

**Assessment the Facet Joint of Lumbar
Spine in Degenerate Disc Patient Using
MRI**

تقييم المفصل المشترك للعمود الفقري القطني في مرضى
الأقراص المنحلة باستخدام التصوير بالرنين المغناطيسي

Prepared by:
Yaseen Mohamedalnoun Awad Alnoun

Supervisor:
Dr/ Hussain Ahmed Hassan

2018
Dedication

**I dedicate this research to my
Loving parents for
Their worm love, care and support
To my brother and sisters for
Their care and encouragement
To all teachers
Who advising and taught me
My friends and colleagues for
Their support and encouragement
And to everyone
Help me to complete this research**

Acknowledgement

Firstly I thanks Allah for everything and for giving me power to finish this work successfully. I would like to express my deepest gratitude thanks to my supervisor Dr. Hussain ahmed hassan for his guidance . I would like to thank the MRI department staff of Medical Modern Center and Ribat University Hospital for their cooperation in complete practical part of the study . I also need to thank for all those who provided me the possibility to complete this work.

. Abstract

This study was done to assess the facet joint of lumbar spine in degenerate disc patients using Magnetic Resonance Imaging MRI. The patients which are Sudanese population those come to Ribat University Hospital and Modern Medical Center, at the period between December 2017 to March 2018. Study was done by finding the relationship between lumbar spine facet joint osteoarthritis and degenerative disc disease DDD of lumbar spine and finding the correlation between lumbar spine facet joint osteoarthritis and age, gender, body mass index BMI. Poor details about the lumbar spine facet joints within the MRI reports with degenerate disc patients, however the facet joints disorders are one of the main reasons of lower back pain, although degenerate disc disease may be a reason of facet joint osteoarthritis .This problem facing every patient with lower back pain and degenerate disc disease. MRI examinations were performed in Ribat University Hospital and Modern Medical Center for 50 Sudanese patients to study lumbar spine region. The data was collected through data collection sheet and analyzed using SPSS. The results find that acute and chronic degenerative disc disease DDD always have a relationship with facet joint osteoarthritis, However mild degenerative disc disease DDD rarely have a relationship with facet joint osteoarthritis. The detected ages were from 21 to 77, the most affected ages were between 21-49 years with percentage of 65%. Both genders were detected, however the majority of the affected patient were female with percentage of 54%. In body mass index BMI the scale begins with 22cm²/kg to 30cm²/kg, but the most frequented value was 27 and 28 with percentage of 22% and 20%.

المستخلص

أجريت هذه الدراسة لتقييم المفصل الجانبي للعمود الفقري القطني في مرضى الأقرص المتحللة باستخدام التصوير بالرنين المغناطيسي التصوير بالرنين

المغناطيسي. للمرضى الذين هم من السكان السودانيين الذين يأتون إلى مستشفى جامعة الرباط والمركز الطبي الحديث ، في الفترة ما بين ديسمبر 2017 وحتى مارس 2018. وقد أجريت الدراسة عن طريق العثور على العلاقة بين التهاب المفاصل العظمي المفصلي القطني ومرض القرص التنكسية للعمود الفقري القطني والعثور على العلاقة بين العمود الفقري القطني وهشاشة العظام المفصلي المشترك والعمر والجنس ومؤشر كتلة الجسم. التفاصيل الضئيلة حول مفاصل العمود الفقري القطني ضمن تقارير التصوير بالرنين المغناطيسي مع مرضى الأقراص المتحللة ، في حين ان اضطرابات المفاصل الجانبية هي واحدة من الأسباب الرئيسية لألم أسفل الظهر ، و على الرغم من أن مرض القرص المتدهور قد يكون سبباً في التهاب المفاصل في المفصل الصدغي. هذه المشاكل تواجه كل المرضى بالأم أسفل الظهر ومرض القرص المنحل . أجريت فحوصات التصوير بالرنين المغناطيسي في مستشفى الرباط الجامعي والمركز الطبي الحديث ل 50 مريضا سودانيا لدراسة منطقة العمود الفقري القطني. تم جمع البيانات من خلال ورقة جمع البيانات وتحليلها باستخدام SPSS. وجدت النتائج أن مرض القرص التنكسية الحاد والمزمن دائما ما يكون لها علاقة مع هشاشة العظام مشتركة ، ومع ذلك مرض القرص التنكسي المعتدل نادرا ما يكون له علاقة مع داء المفاصل وهشاشة العظام مشتركة. كانت الاعمار المستقصي من 21 إلى 77 ، وكان الاعمار الأكثر إصابة بين 21-49 سنة بنسبة 65٪. كلا الجنسين كان مستقصي عنه في دراسه ، ولكن غالبية المرضى المصابين كانوا من الإناث بنسبة 54٪. و في مؤشر كتلة الجسم BMI ، يبدأ المقياس من 22 kg / cm² إلى 30 kg / cm² ، لكن القيمة الأكثر تردداً كانت 27 و 28 بنسبة 22٪ و 20٪.

List of contents

Topic	Page number
Holey Quran	I

Dedication	II
Acknowledgement	III
English abstract	IV
Arabic abstract	V
Table of contents	VI
List of figures	VII
List of tables	VIII
List of charts	VIII
List of abbreviations	IX

Chapter One **Introduction**

Topic	Page number
1-1.Introduction	1
1-2.Problem of study	3
1-3.Objective of study	3
1-4.Significant of study	3
1-5.Overview of study	4

Chapter Two **Literature Review**

Topic	Page number
2-1.Literature Review	5
2-1-1.Anatomy and Physiology of Lumbar spine	5
2-1-2.Pathology of Lumbar spine and facet joint	22
2-1-3.Lumbar spine Imaging	35
2-2.Previous study	41

Chapter Three **Material and Method**

Topic	Page number
3-1.Material	43
3-2.Method	44

Chapter Four **Results**

Topic	Page number
4-1.Results	46

Chapter Five **Discussion**

Topic	Page number
5-2.Discussion	54
5-2.Conclusion	55
5-3.Recommendations	55
5-4.References	56

List of figures

Name	Page number
Figure 2-1: Lumbar Vertebra	6
Figure 2-2 : Scottie Dog.	7
Figure 2-3: Lower Spine, Anterior View	8
Figure 2-4: Lumbar Vertebral Joints	9
Figure 2-5: Lumbar Intervertebral Discs	10
Figure 2-6 : Lumbar Spine Anterolateral View	11
Figure 2-7 : Lumbar Spinal Ligaments, Lateral View.	12
Figure 2-8: Lumbar Spinal Muscles	13
Figure 2-9: Spinal Cord	18
Figure 2-10:Spinal Nerves	21
Figure 2-11: Degenerative disc diseases	24
Figure 2-12: Bulging disc and herniated disc	25
Figure 2-13 : Herniated disc	26
Figure 2-14: Spinal arthritis	27
Figure 2-15 : Sagittal STIR image shows loss of disc height	28
Figure 2-16: compression fracture	29
Figure 2-17:Sagittal T2WI demonstrates heterogeneous marrow signal with areas of high and low signal that both correspond to metastatic deposit.	31
Figure 2-18: T1 signal and enlargement of the L3 posterior elements low	33
Figure 2-19:Heterogenous low T2 signal within L3 vertebral body	33
Figure 2-20.MRI schematic diagram	38
Figure 4-1. show age distribution among the study sample	46
Figure 4-2. show gender distribution among the study sample	47
Figure 4-3. Show BMI distribution among the study sample	48
Figure 4-4. Show Facet joint osteoarthritis among	49

the study sample	
Figure 4-5. Show the relationship between the Facet joint osteoarthritis and age among the study sample	50
Figure 4-6. Show the relationship between the Facet joint osteoarthritis and gender among the study sample	51
Figure 4-7. Show the relationship between the Facet joint osteoarthritis and BMI among the study sample	51
Figure 4-8: Piechart explain affected patient by age	52
Figure 4-9: Piechart explain affected patient by gender	52
Figure 4-10: Piechart explain affected patient by BMI	53
Figure 4-5. Show the relationship between the Facet joint osteoarthritis and age among the study sample	49
Figure 4-6. Show the relationship between the Facet joint osteoarthritis and gender among the study sample	50
Figure 4-7. Show the relationship between the Facet joint osteoarthritis and BMI among the study sample	51
Figure 4-8: Piechart explain affected patient by age	51

List of table

Name	Page number
Table 4-1. shows age distribution among study sample.	46
Table 4-2. shows gender distribution among study sample.	47
Table 4-3. shows BMI distribution among study sample.	48
Table 4-4. shows Facet joint osteoarthritis among study sample.	49
Table 4-5. shows the relationship between the Facet joint osteoarthritis and age ,gender ,BMI and DDD among study sample.	50

List of abbreviations

Abbreviation	
AAF	Anterior Annulus Fibrosis

ALL	Anterior Longitudinal Ligament
BMI	Body Mass Index
CTL	Cervical-Thorothic-Lumbar
CSF	Cerebro Spinal Fluid
CT	Computed Tomography
DDD	Degenerative Disc Disease
DLSD	Degenerative Lumbar Spine Disease
FOV	Field Of View
FSE	Fast Spin Echo
GRE	Gradient Echo
IAP	Inferior Artercular Process
ISL	Inferior Spinous Ligament
LBP	Lower Back Pain
LCS	Lumbar Canal Stenosis
L1	First Lumbar vertebra
L2	Second Lumbar vertebra
L3	Third Lumbar vertebra
L4	Fourth Lumbar vertebra
L5	Fifth Lumbar vertebra
MRI	Magnetic Resonance Imaging
NMR	Nuclear Magnetic Resonance
PLL	Posterior Longitudinal Ligament
RF	Radio Frequency
SAP	Superior Artercular Process
SPSS	Statistical Package for Social Sciences
S1	First sacrum vertebra
SE	Spin Echo
T1	Longitudinal relaxation time
T2	Transvers relaxation time
TR	Time of Repeat
TE	Time to Echo
2D	Two Dimension

Chapter One

Chapter One

1-1.Introduction:

The facet joints or (zygapophysial joints, zygapophyseal, apophyseal, or Z-joints) are a set of synovial, plane joints between the articular processes of two adjacent vertebrae. There are two facet joints in each spinal motion segment and each facet joint is innervated by the recurrent meningeal nerves (Aestin 2012).

Lumbar facet joint osteoarthritis is a challenging condition affecting up to 15% of patients with chronic low back pain. The onset of lumbar facet joint pain is usually insidious, with predisposing factors including spondylolisthesis, degenerative disc pathology, and old age. Despite previous reports of a “facet syndrome,” the existing literature does not support the use of historic or physical examination findings to diagnose lumbar zygapophysial joint pain. The most accepted method for diagnosing pain arising from the lumbar facet joints is with low-volume intraarticular or medial branch blocks, both of which are associated with high false-positive rates. Standard treatment modalities for lumbar zygapophysial joint pain include intraarticular steroid injections and radiofrequency denervation of the medial branches innervating the joints, but the evidence supporting both of these is conflicting. In this article, the authors provide a comprehensive review of the anatomy, biomechanics, and function of the lumbar zygapophysial joints, along with a systematic analysis of the diagnosis and treatment of facet joint pain (Steven P. Cohen, M.D.,* Srinivasa N. Raja, M.D 2007).

Degenerative disc disease (DDD) is an exceedingly common entity in the spine, encountered with increasing frequency throughout life and becoming almost universal in late adulthood to a varying degree. It is related to a combination biomechanical stresses and genetic predisposition which alter the metabolic and structural integrity of the intervertebral disc. These changes, in turn, modify the ability of the intervertebral disc to sustain and transmit forces, and subsequently, compensate for these alterations (or not) in a variety of ways, leading to billions of dollars in healthcare services and lost productivity every year due to associated morbidity from these conditions (Dr Bruno Di Muzio ,Dr Matt Skalski 2016).

Below is a list of conditions that are frequently considered degenerative of lumbar spine in nature, and their reported incidence is given in both asymptomatic and symptomatic adult populations:

- Disc bulge: asymptomatic 10% to 81%, symptomatic 22% to 48%
- Disc protrusion: asymptomatic 3% to 63%, symptomatic 0% to 79%
- Disc extrusion: asymptomatic 0% to 24%, symptomatic 1% to 55%
- Disc sequestration: 0% in asymptomatic subjects

- Reduction in signal intensity of the disc: asymptomatic 20% to 83%, -symptomatic 9% to 86%
- Disc narrowing: asymptomatic 3-56%, symptomatic 15-53%
- Annular tears (high intensity zones): asymptomatic 6-56%, symptomatic 15%
- Schmorl node: asymptomatic 8-19%, symptomatic 6-79% (Dr Bruno Di Muzio ,Dr Matt Skalski 2016).

MRI (an abbreviation of magnetic resonance imaging) is an imaging modality that uses non-ionizing radiation to create useful diagnostic images. MRI was initially called Nuclear Magnetic Resonance Imaging after its early use for chemical analysis. The "Nuclear" was dropped off about 25 years ago because of fears that people would think there was something radioactive involved, which there is not (Dr Dan J Bell and Dr Jeremy Jones 2009).

NMR was discovered simultaneously by two physicists, Felix Bloch and Edward Mills Purcell, just after the end of World War II. Bloch trained in quantum mechanics and was involved with atomic energy and then radar counter-measures. At the end of the war, he returned to his earlier work in the magnetic moment of the neutron. Purcell was involved with the development of microwave radar during the war then pursued radio waves for the evaluation of molecular and nuclear properties. They received the Nobel Prize in Physics in 1952 for this discovery (Dr Dan J Bell and Dr Jeremy Jones 2009).

MRI, the use of NMR to produce 2D images was accomplished by Paul Lauterbur, imaging water, and Sir Peter Mansfield who imaged the fingers of a research student, Dr Andrew Maudsley in 1976. Maudsley continues to make a significant contribution to MRI R&D today. Raymond Damadian obtained human images a year later in 1977. Lauterbur and Mansfield received the Nobel Prize in Physiology or Medicine in 2003 for their development of MRI (Dr Dan J Bell and Dr Jeremy Jones 2009).

An MRI scanner consists of a large, powerful magnet in which the patient lies. A radio wave antenna is used to send signals to the body and then receive signals back. These returning signals are converted into images by a computer attached to the scanner. Imaging of almost any part of your body can be obtained in any plane (Dr Dan J Bell and Dr Jeremy Jones 2009).

1-2.Problem of study:

Poor details about the facet joints within the MRI reports with patient of lower back pain , However the facet joints disorders are one of the main reasons of lower back pain.

1-3.Objective of study:

1-3-1.General Objective:

Assessment the Facet Joint of Lumbar Spine in Degenerate Disc Patient Using Magnetic Resonance Imaging

1-3-2.Specific Objective:

- To find the relationship between lumbar spine facet joint osteoarthritis and degenerative disc disease DDD of lumbar spine.
- To correlate lumbar spine facet joint osteoarthritis with age.
- To correlate lumbar spine facet joint osteoarthritis with gender.
- To correlate lumbar spine facet joint osteoarthritis with body mass index BMI.

1-4.Significant of study:

This study highlighted on study of lumbar spine degenerative disc disease and lumbar spine facet joints osteoarthritis using magnetic resonance imaging in order to find the relationship between lumbar spine facet joint osteoarthritis and disk degeneration of lumbar spine and to assess lumbar spine facet joint osteoarthritis according to patient (age, gender, body mass index).

1-5.Overview of study:

The study will fall into five chapters, Chapter one consists of

introduction, problem of the study, objectives, and the overview of the study. Chapter two includes the literature review, Chapter three detailed the material and methods. Chapter four includes the presentation of the results, Chapter five include the discussions ,conclusion,recommendations and finally References .

Chapter Two

Chapter Two

2-1. Anatomy and Physiology of Lumbar spine:

2-1-1. Bones:

The lumbar vertebrae, numbered L1-L5, have a vertical height that is less than their horizontal diameter. They are composed of the following 3 functional parts:

- 1-The vertebral body, designed to bear weight.
- 2-The vertebral (neural) arch, designed to protect the neural elements.
- 3-The bony processes (spinous and transverse), which function to increase the efficiency of muscle action.

The lumbar vertebral bodies are distinguished from the thoracic bodies by the absence of rib facets. The lumbar vertebral bodies (vertebrae) are the heaviest components, connected together by the intervertebral discs. The size of the vertebral body increases from L1 to L5, indicative of the increasing loads that each lower lumbar vertebra absorbs. of note, the L5 vertebra has the heaviest body, smallest spinous process, and thickest transverse process (Stephen Kishner, Maxim Moradian, Jan K Morello, Thomas R Gest, 2017).

The intervertebral discal surface of an adult vertebra contains a ring of cortical bone peripherally termed the epiphysial ring. This ring acts as a growth zone in the young while anchoring the attachment of the annular fibers in adults. A hyaline cartilage plate lies within the confines of this epiphysial ring (Stephen Kishner, Maxim Moradian, Jan K Morello, Thomas R Gest, 2017).

Each vertebral arch is composed of 2 pedicles, 2 laminae, and 7 different bony processes (1 spinous, 4 articular, 2 transverse) , joined together by facet joints and ligaments (Stephen Kishner, Maxim Moradian, Jan K Morello, Thomas R Gest, 2017).

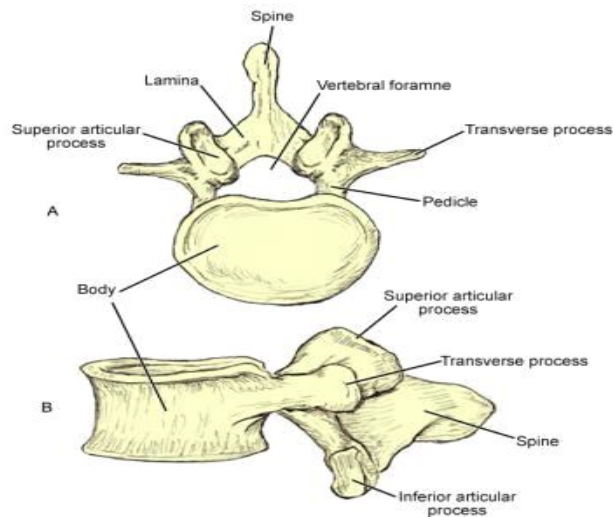


Figure 2-1: Lumbar Vertebra
(Eva et al,2012)

Lumbar vertebrae are characterized by massive bodies and robust spinous and transverse processes. Their articular facets are oriented somewhat parasagittally, which is thought to contribute the large range of anteroposterior bending possible between lumbar vertebrae. Lumbar vertebrae also contain small mammillary and accessory processes on their bodies. These bony protuberances are sites of attachment of deep lumbosacral muscles (Stephen Kishner, Maxim Moradian, Jan K Morello, Thomas R Gest, 2017).

The pedicle, strong and directed posteriorly, joins the arch to the posterolateral body. It is anchored to the cephalad portion of the body and function as a protective cover for the cauda equina contents. The concavities in the cephalad and caudal surfaces of the pedicle are termed vertebral notches (Stephen Kishner, Maxim Moradian, Jan K Morello, Thomas R Gest, 2017).

Beneath each lumbar vertebra, a pair of intervertebral (neural) foramina with the same number designations can be found, such that the L1 neural foramina are located just below the L1 vertebra. Each foramen is bounded superiorly and inferiorly by the pedicle, anteriorly by the intervertebral disc and vertebral body, and posteriorly by facet joints. The same numbered spinal nerve root, recurrent meningeal nerves, and radicular blood vessels pass through each foramen. Five lumbar spinal nerve roots are found on each side (Stephen Kishner, Maxim Moradian, Jan K Morello, Thomas R Gest, 2017).

The broad and strong laminae are the plates that extend posteromedially from the pedicle. The oblong shaped spinous processes are directed posteriorly from the union of the laminae.

The 2 superior (directed posteromedially) and inferior (directed anterolaterally) articular processes, labeled SAP and IAP, respectively, extend cranially and caudally from the point where the pedicles and laminae join. The facet or zygapophyseal joints are in a parasagittal plane. When viewed in an oblique projection, the outline of the facets and the pars interarticularis appear like the neck of a Scottie dog (Stephen Kishner, Maxim Moradian, Jan K Morello, Thomas R Gest, 2017).

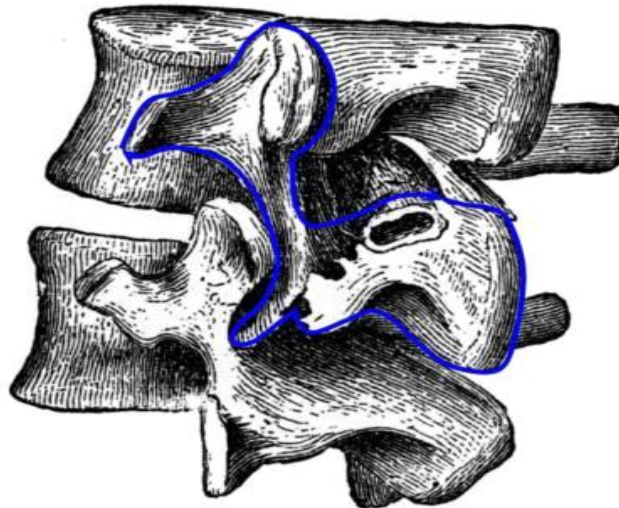


Figure 2-2 : Scottie Dog.
(Stephen Kishner, MD, MHA2017)

Drawing of 2 lumbar segments viewed from an oblique angle. The outline of the facets and the pars interarticularis has the appearance of the "neck" of a Scottie dog.

Between the superior and inferior articular processes, 2 transverse processes are projected laterally that are long, slender, and strong. They have an upper tubercle at the junction with the superior articular process (mammillary process) and an inferior tubercle at the base of the process (accessory process).

These bony protuberances are sites of attachments of deep back muscles. The lumbar spine has an anterior, middle, and posterior column that is pertinent for lumbar spine fractures (Stephen Kishner, Maxim Moradian, Jan K Morello, Thomas R Gest, 2017).

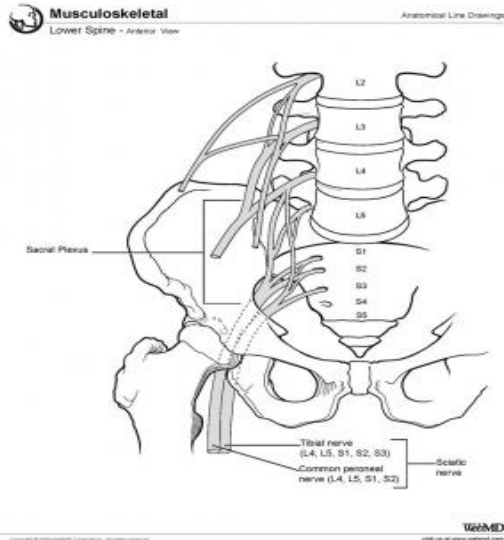


Figure 2-3: Lower Spine, Anterior View.
 (Stephen Kishner, MD, MHA2017)

2-1-2.Lumbar Vertebral Joints:

The mobility of the vertebral column is provided by the symphyseal joints between the vertebral bodies, formed by a layer of hyaline cartilage on each vertebral body and an intervertebral disc between the layers.

The synovial joints between the superior and inferior articular processes on adjacent vertebrae are termed the facet joints (also known as zygapophysial joints or Z-joints). They permit simple gliding movements (Stephen Kishner, Maxim Moradian, Jan K Morello, Thomas R Gest, 2017).

The movement of the lumbar spine is largely confined to flexion and extension with a minor degree of rotation (see the image below). The region between the superior articular process and the lamina is the pars interarticularis. A spondylolysis occurs if ossification of the pars interarticularis fails to occur (Stephen Kishner, Maxim Moradian, Jan K Morello, Thomas R Gest, 2017).

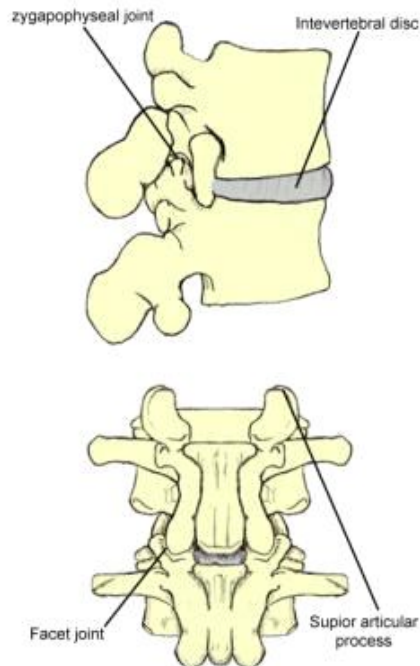


Figure 2-4: Lumbar Vertebral Joints
(Stephen Kishner, MD, MHA2017)

The 3-joint complex is formed between 2 lumbar vertebrae. Joint 1: Disc between 2 vertebral bodies; Joint 2: Left facet (zygapophyseal) joint; Joint 3: Right facet (zygapophyseal) joint (Stephen Kishner, Maxim Moradian, Jan K Morello, Thomas R Gest, 2017).

2-1-3. Lumbar Intervertebral Discs:

Discs form the main connection between vertebrae. They bear loading during axial compression and allow movement between the vertebrae. Their size varies depending on the adjacent vertebrae size and comprises approximately one quarter the length of the vertebral column (Stephen Kishner, Maxim Moradian, Jan K Morello, Thomas R Gest, 2017).

Each disc consists of the nucleus pulposus, a central but slightly posterior mucoid substance embedded with reticular and collagenous fibers, surrounded by the annulus fibrosus, a fibrocartilaginous lamina. The annulus fibrosus can be divided into the outermost, middle, and innermost fibers. The anterior fibers are strengthened by the powerful anterior longitudinal ligament (ALL). The posterior longitudinal ligament (PLL) affords only weak midline reinforcement, especially at L4-5 and L5-S1, as it is a narrow structure attached to the annulus. The anterior and middle fibers of the annulus are most numerous anteriorly and laterally but deficient posteriorly, where most of the fibers are attached to the cartilage plate (Stephen Kishner, Maxim Moradian, Jan K Morello, Thomas R Gest, 2017).

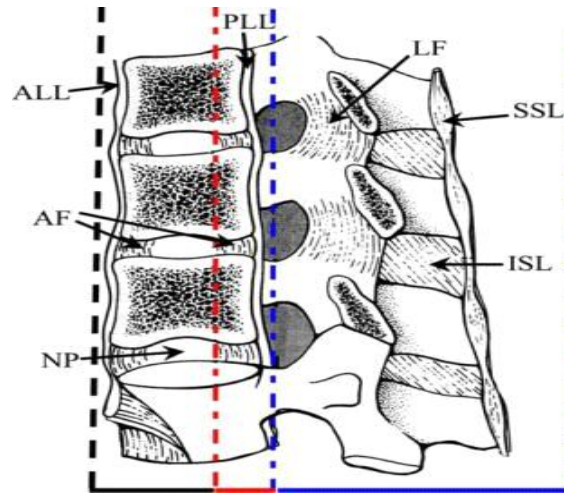


Figure 2-5: Lumbar Intervertebral Discs
(Stephen Kishner, MD, MHA2017)

Lateral drawing of the 3 spinal columns of the thoracolumbar junction. The anterior column (black dotted line) includes the anterior spinal ligament, the anterior annulus fibrosus (AAF), the intervertebral disc, and the anterior two thirds of the vertebral bodies. The middle column (red dotted line) includes the posterior aspect of the vertebral bodies, the posterior annulus fibrosus, and the posterior longitudinal ligament (PLL) (Stephen Kishner, Maxim Moradian, Jan K Morello, Thomas R Gest, 2017).

The posterior column (thick blue dotted line) includes the entire spine posterior to the longitudinal ligament (thick blue dotted line). ALL = anterior longitudinal ligament; ISL = interspinous ligament; LF = ligamentum flavum; NP = nucleus pulposus; SSL = supraspinous ligament (Stephen Kishner, Maxim Moradian, Jan K Morello, Thomas R Gest, 2017).

The annular fibers are firmly attached to the vertebral bodies and are arranged in lamellae. This annular arrangement permits limiting vertebral movements, reinforced by investing ligaments (Stephen Kishner, Maxim Moradian, Jan K Morello, Thomas R Gest, 2017).

2-1-4. Lumbar vertebral ligaments:

The ALL covers the ventral surfaces of lumbar vertebral bodies and discs. It is intimately attached to the anterior annular disc fibers and widens as it descends the vertebral column. The ALL maintains the stability of the joints and limits extension (Stephen Kishner, Maxim Moradian, Jan K Morello, Thomas R Gest, 2017).

The PLL is located within the vertebral canal over the posterior surface of the vertebral bodies and discs. It functions to limit flexion of the vertebral column, except at the lower L-spine, where it is narrow and weak.

The supraspinous ligament joins the tips of the spinous processes of adjacent vertebrae from L1-L3. The interspinous ligament interconnects the spinous processes, from root to apex of adjacent processes. Sometimes described together as the interspinous/supraspinous ligament complex, they weakly resist spinal separation and flexion (Stephen Kishner, Maxim Moradian, Jan K Morello, Thomas R Gest, 2017).

The ligamentum flavum (LF) bridges the interlaminar interval, attaching to the interspinous ligament medially and the facet capsule laterally, forming the posterior wall of the vertebral canal. It has a broad attachment to the undersurface of the superior lamina and inserts onto the leading edge of the inferior lamina. Normally, the ligament is taut, stretching for flexion and contracting its elastin fibers in neutral or extension. It maintains constant disc tension (Stephen Kishner, Maxim Moradian, Jan K Morello, Thomas R Gest, 2017).

The intertransverse ligament joins the transverse processes of adjacent vertebrae and resists lateral bending of the trunk.

The iliolumbar ligament arises from the tip of the L5 transverse process and connects to the posterior part of the inner lip of the iliac crest. It helps the lateral lumbosacral ligament and the ligaments mentioned above stabilize the lumbosacral joint (Stephen Kishner, Maxim Moradian, Jan K Morello, Thomas R Gest, 2017).

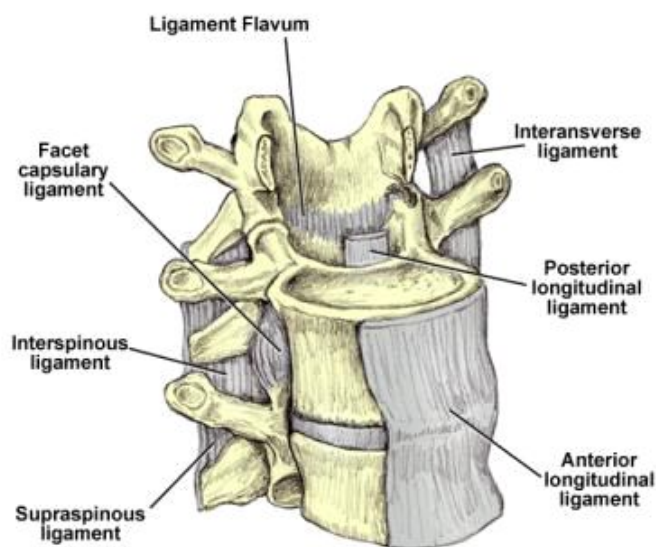


Figure 2-6 : Lumbar Spine Anterolateral View
(Stephen Kishner, MD, MHA2017)

Anterolateral view of the lumbar spine demonstrating the multiple ligaments of the lumbar spine. These ligaments include the following: ligamentum flavum (LF), anterior longitudinal ligament (ALL), posterior longitudinal ligament (PLL), intertransverse ligament, interspinous ligament, supraspinous ligament, and facet capsular ligament (Stephen Kishner, Maxim Moradian, Jan K Morello, Thomas R Gest, 2017).

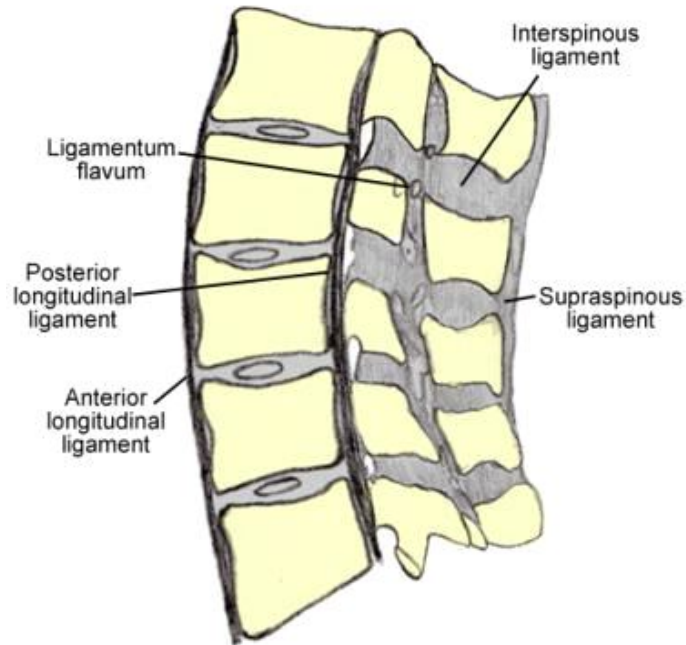


Figure 2-7 : Lumbar Spinal Ligaments, Lateral View.
(Stephen Kishner, MD, MHA2017)

2-1-5. Lumbar Spine Musculature:

Four functional groups of muscles govern the lumbar spine and can be divided into extensors, flexors, lateral flexors, and rotators. Synergistic muscle action from both the left and right side muscle groups exist during flexion and extension of the L-spine (Stephen Kishner, Maxim Moradian, Jan K Morello, Thomas R Gest, 2017).

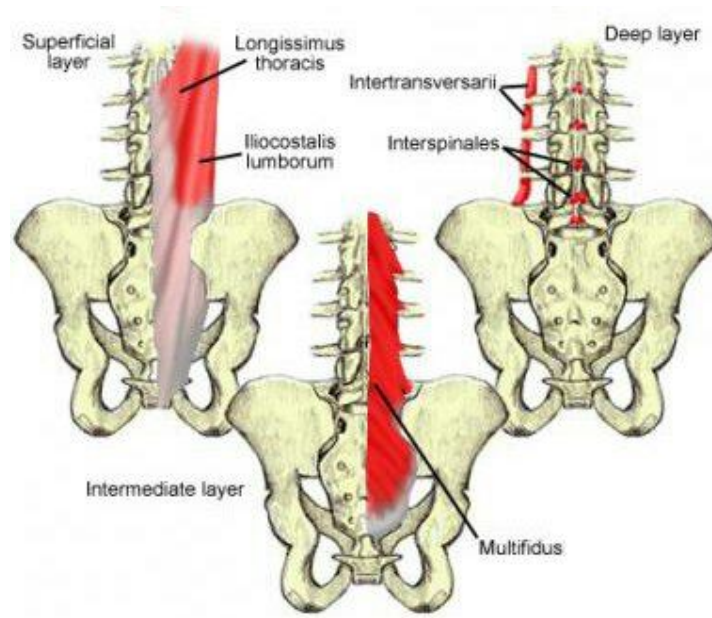


Figure 2-8: Lumbar Spinal Muscles
(Stephen et al, 2015)

The extensor muscles are arranged in 3 layers. The largest group of intrinsic back muscles and primary extensor is the erector spinae (or sacrospinalis). In the lower L-spine, the erector spinae appears as a single muscle. At the upper lumbar area, it divides into 3 vertical columns of muscles (iliocostalis, longissimus, spinalis). Located posterolateral to the vertebral column, they have a common origin from a thick tendon that is attached to the sacrum, the lumbar spinous processes, and the iliac crest. The iliocostalis is the most lateral, and the spinalis (smallest muscle) is the most medial. The longissimus (largest muscle) inserts on to the skull base, whereas the iliocostalis inserts onto the angles of the ribs and transverse processes of the lower cervical vertebrae. As these muscles ascend up the vertebral column, they divide regionally depending on where the muscle attaches superiorly (Stephen Kishner, Maxim Moradian, Jan K Morello, Thomas R Gest, 2017).

A 3-layered fasciculated muscle, the transversospinal muscle group, lies deep to the erector spinae and originates on the mamillary processes in the lumbar spine. In the sacrum, it originates from the laminar area just medial to the posterior sacral foramina, from the tendinous origins on the erector spinae, and the medial surface of the posterior superior iliac spine (PSIS). Each fascicle is directed superomedially toward the inferior and medial margin of the lamina and adjacent spinous process. The superficial layer attaches from 3-4 levels above, the intermediate layer attaches 2 levels above, and the deep layer attaches 1 level above. The transversospinal muscle group acts both as an L-spine extensor and a

rotator (Stephen Kishner, Maxim Moradian, Jan K Morello, Thomas R Gest, 2017).

A multitude of small, segmental muscles are the deepest layer of the lumbar extensors. They can be divided into 2 groups, both innervated by the dorsal rami of spinal nerves. The levatores costarum are not typically present in the lumbar spine. The second group contains the interspinales and intertransversarii. The interspinales consists of short fasciculi attached between the spinous processes of contiguous vertebrae. The intertransversarii consist of 2-3 slips of muscles, which pass between adjacent transverse processes. They are postural stabilizers and increase the efficiency of larger muscle group action (Stephen Kishner, Maxim Moradian, Jan K Morello, Thomas R Gest, 2017).

2-1-5-1. Forward flexors:

Flexors of the L-spine are divided into an iliiothoracic (extrinsic) group and a femorospinal (intrinsic) group. The iliiothoracic group is made up of the abdominal wall muscles: rectus abdominis, external abdominal oblique, internal abdominal obliquus, and the transversus abdominis. The femorospinal group is made up of the psoas major and iliacus muscles. The psoas major originates from multiple areas: the anterior surface and lower border of transverse processes of L1-L5, from the bodies and discs of T12-L5. It inserts on to the lesser trochanter of the femur and is innervated by direct fibers of the lumbar plexus (L1-L3). Its primary action is hip and trunk flexion (Stephen Kishner, Maxim Moradian, Jan K Morello, Thomas R Gest, 2017).

2-1-5-2. Lateral flexors:

True lateral flexion is normally a combination of side bending and rotation. Normally, side bending is brought about by ipsilateral contraction of the oblique and transversus abdominal muscles and quadratus lumborum. Of these, only unilateral contraction of the quadratus lumborum can bring about pure lateral flexion and elevation of the ilium, whereas bilateral contraction produces some lumbar extension. The quadratus lumborum is attached below to the iliolumbar ligament and to the adjacent part of the iliac crest above the lower anterior surface of the 12th rib and to the apexes of the L1-4 transverse processes (Stephen Kishner, Maxim Moradian, Jan K Morello, Thomas R Gest, 2017).

2-1-5-3. Rotators:

Rotation of the lumbar spine is brought about by the unilateral contraction of muscles that follow an oblique direction of pull; the more oblique the course, the more important the rotational effect. Most of the extensors and lateral flexors follow an oblique course and produce

rotation when their primary component has been neutralized by antagonist muscle groups (Stephen Kishner, Maxim Moradian, Jan K Morello, Thomas R Gest, 2017).

The transversospinal muscle group, innervated by the dorsal rami of spinal nerves, is deep to the erector spinae muscle and runs obliquely (superomedially) from the transverse processes to the spinous processes. As a group, they act to extend the vertebral column. But, when contracted unilaterally, they cause the trunk to rotate in the contralateral direction. They are divided into 3 groups: the semispinalis, multifidus, and rotatores lumborum muscles. The rotatores lumborum are small, irregular, and variable muscles connecting the superoposterior part of the transverse process of the vertebra below to the inferolateral border of the lamina of the vertebra above (Stephen Kishner, Maxim Moradian, Jan K Morello, Thomas R Gest, 2017).

2-1-6. Lumbar Spine Vasculature:

2-1-6-1. Arterial:

Lumbar vertebrae are contacted anterolaterally by paired lumbar arteries that arise from the aorta, opposite the bodies of L1-L4. Each pair passes anterolaterally around the side of the vertebral body to a position immediately lateral to the intervertebral canal and leads to various branches. The periosteal and equatorial branches supply the vertebral bodies. Spinal branches of the lumbar arteries enter the intervertebral foramen at each level. They divide into smaller anterior and posterior branches, which pass to the vertebral body and the combination of vertebral arch, meninges, and spinal cord, respectively.

These arteries give rise to ascending and descending branches that anastomose with the spinal branches of adjacent levels. Nutrient arteries from the anterior vertebral canal travel anteriorly and supply most of the red marrow of the central vertebral body. The larger branches of the spinal branches continue as radicular or segmental medullary arteries, distributed to the nerve roots and to the spinal cord, respectively (Stephen Kishner, Maxim Moradian, Jan K Morello, Thomas R Gest, 2017).

Up to age 8 years, intervertebral discs have a good blood supply. Thereafter, their nutrition is dependent on diffusion of tissue fluids through 2 routes: (1) the bidirectional flow from the vertebral body to the disc and vice versa and (2) the diffusion through the annulus from blood vessels on its surface. As adults, the discs are generally avascular structures, except at their periphery (Stephen Kishner, Maxim Moradian, Jan K Morello, Thomas R Gest, 2017).

2-1-6-2. Venous:

The venous drainage parallels the arterial supply. Venous plexuses are formed by veins along the vertebral column both inside and outside the vertebral canal (internal/epidural and external vertebral venous plexuses). Both plexuses are sparse laterally but dense anteriorly and posteriorly. The large basivertebral veins form within the vertebral bodies, emerge from the foramen on the posterior surfaces of the vertebral bodies, and drain into the internal vertebral venous plexuses, which may form large longitudinal sinuses. The intervertebral veins anastomose with veins from the cord and venous plexuses as they accompany the spinal nerves through the foramen to drain into the lumbar segmental veins (Stephen Kishner, Maxim Moradian, Jan K Morello, Thomas R Gest, 2017).

2-1-7. Vertebral Canal:

The tubular vertebral canal contains the spinal cord, its meninges, spinal nerve roots, and blood vessels supplying the cord, meninges, vertebrae, joints, muscles, and ligaments. Both potential and real spaces intervene between the spinal cord, meninges, and osseoligamentous canal walls. The canal is enclosed within its column and formed by the juxtaposition of the vertebral foramen, lined up with one another in series. The vertebral bodies and discs make up the anterior wall (with the PLL draped over it), whereas the laminae and ligamentum flavum border the canal posteriorly. Laterally, spinal nerves and vessels travel through the intervertebral foramen (Stephen Kishner, Maxim Moradian, Jan K Morello, Thomas R Gest, 2017).

2-1-8. Meninges and Related Spaces:

The meninges consist of 3 layers: the pia, arachnoid, and dura mater. Together, they enhance the protection of the spinal cord and roots. The dura is the most superficial but resilient layer. The pia and arachnoid, together termed the leptomeninges, are frail. The spinal cord, roots, and nerve rootlets are closely invested by the pia. The dura and arachnoid together form a loose sheath (termed dural/thecal sac) around these structures, separated from the canal walls by the epidural space (Stephen Kishner, Maxim Moradian, Jan K Morello, Thomas R Gest, 2017).

2-1-8-1. Spinal dura mater:

The dura is composed of tough, longitudinal, collagen fiber bundles interwoven with circular elastic fibers. The external surface is rough and blends with loose connective tissue in the epidural space. The internal surface, facing into the subdural space, is smooth and covered by a layer of mesothelium. Inferiorly, the dural sac ends at the sacral canal, usually at S2-S3 (sometimes S1).

The dura continues caudally as a fibrous thread named the filum terminale externum or coccygeal ligament, which blends with the PLL over the coccyx. The dural sac sends sleeve-like projections into the intervertebral foramen, where the dura blends with the epineurium of the spinal nerves. Connective tissue slips in the foramen anchor the dural sleeves so that they can protect the spinal nerve roots from being stretched during L-spine movements. In addition to these tetherings, the dura is attached in places to the PLL (Stephen Kishner, Maxim Moradian, Jan K Morello, Thomas R Gest, 2017).

2-1-8-2.Epidural space:

The epidural (peridural/extradural) space terminates inferiorly at the sacral hiatus, where it is sealed by the posterior sacrococcygeal ligaments. The nerve roots transverse the space as they extend into the intervertebral foramen. The entire space is occupied by loose connective tissue with variable fat content, providing padding around the dural sac and spinal cord and acting as a form to hold the thin internal vertebral plexus of veins open. The vertebral venous plexus is embedded in the epidural loose connective tissue, sometimes transmitting large amounts of blood (Stephen Kishner, Maxim Moradian, Jan K Morello, Thomas R Gest, 2017).

2-1-8-3.Leptomeninges:

The pia and arachnoid are delicate membranes composed of loose connective tissue and separated from one another by the subarachnoid space. A layer of mesothelium covers all leptomeningeal surfaces bathed by cerebrospinal fluid (CSF).

The arachnoid mater lines the entire dural sac and extends into the dural sleeves. It also sends trabeculae across the subarachnoid space to the pia, facilitating CSF mixing. Along the posterior midline, the trabeculae form a well-defined subarachnoid septum. Inferiorly, it lines the dural sac within the sacral canal and ends on termination of the sac at the S2 vertebral level.

The pia mater provides support for the vasculature and nerves in the subarachnoid space. It adheres intimately to the spinal cord. The pia forms a separate sheath for each nerve rootlet and root as far laterally as the foramen, blending with the epineurium. Caudally, the pia continues as the thin filum terminale internum. After reaching the lower end of the dural sac, the filum becomes enclosed within the filum terminale externum and continues to the coccyx (Stephen Kishner, Maxim Moradian, Jan K Morello, Thomas R Gest, 2017).

2-1-8-4.Subarachnoid space:

The spinal subarachnoid space is spacious in the lumbar spine, and below the level of L2 it is termed the lumbar cistern. Its CSF content (20-35 mL) is only a fraction of the total CSF volume (120-150 mL). The lower third of the arachnoid sac contains only the filum terminale internum and the cauda equina, which contains lumbar, sacral, and coccygeal nerve roots that hang like a horse's tail form the lower part of the spinal cord (conus medullaris) as they leave the vertebral canal below the lower third of the arachnoid sac (Stephen Kishner, Maxim Moradian, Jan K Morello, Thomas R Gest, 2017).

2-1-9.Spinal Cord:

Other than the brain, the spinal cord is one of the 2 anatomic components of the central nervous system (CNS). It is the major reflex center and conduction pathway between the brain and the body. As noted earlier, the spinal cord normally terminates as the conus medullaris within the lumbar spinal canal at the lower margin of the L2 vertebra, although variability of the most caudal extension exists(Stephen Kishner, Maxim Moradian, Jan K Morello, Thomas R Gest, 2017).

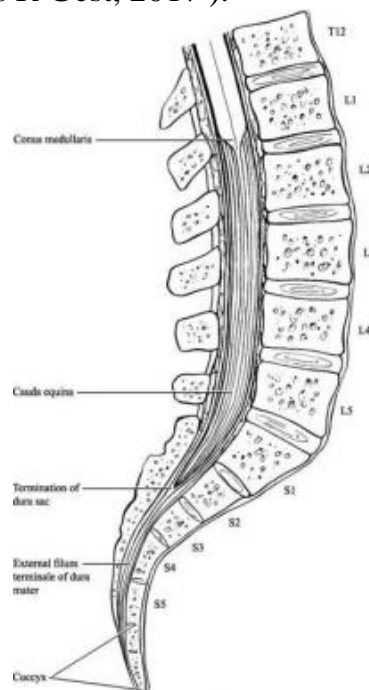


Figure 2-9: Spinal Cord
(Stephen Kishner, MD, MHA2017)

Illustration demonstrating the relevant anatomy of the caudal equine region. In a cadaveric study of 129 cadaveric specimens, the spinal cord terminated at L2 in 60%, L1 in 30%, and L3 in 10% of specimens. Differential growth rates in the spinal cord and the vertebral canal are the cause of these disparities. Exceptions also include patients with

congenital spinal deformities known as spine bifida. In such patients, the conus medullaris can be displaced downward to the middle or lower lumbar spine (Stephen Kishner, Maxim Moradian, Jan K Morello, Thomas R Gest, 2017).

2-1-10.Spinal Nerves and Roots:

All lumbar spinal nerve roots originate at the T10 to L1 vertebral level, where the spinal cord ends as the conus medullaris. A dorsal or posterior (somatic sensory) root from the posterolateral aspect of the spinal cord and a ventral or anterior (somatic motor) root from the anterolateral aspect of the cord join in the spinal canal to form the spinal nerve root. The roots then course down through the spinal canal, forming the cauda equina, until they exit at their respective neural (intervertebral) foramina as a single pair of spinal nerves. Thus, the lumbar nerve roots exit the spinal canal at a lower level than where they arise (Stephen Kishner, Maxim Moradian, Jan K Morello, Thomas R Gest, 2017).

Since early in development, these roots proceed independently toward their respective foramen, traversing the subarachnoid space within the dural sac/sleeves. They pierce the dura separately before they blend with each other at the foramen. In the lateral portion, they travel in the dural sleeve. There may be separate dural sleeves around the posterior and anterior roots for a given spinal nerve, or the 2 sleeves may be fused. Each root is bathed by CSF from a separate arachnoid sheath around it. The dural sleeves in the lumbar region are longer and travel in a more inferolateral route upon exiting (Stephen Kishner, Maxim Moradian, Jan K Morello, Thomas R Gest, 2017).

Cell bodies of the motor nerve fibers are located in the ventral or anterior horns of the spinal cord, whereas those of the sensory nerve fibers are in a dorsal root ganglion (spinal ganglion) at each lumbar and sacral level. Dorsal root ganglia (DRG) tend to be located within the neural foramina and are, therefore, not strictly speaking within the lumbar canal. However, at the low lumbar (and sacral), levels, the DRG tends to reside proximal to the neural foramina, within the spinal canal, as found in 11-38% of cases at L5 and 71% at S1. The dorsal root ganglia are attached to the margins of the intervertebral foramina (Stephen Kishner, Maxim Moradian, Jan K Morello, Thomas R Gest, 2017).

2-1-10-1.Exit levels of spinal nerves:

Lumbar spinal nerves exit the vertebral canal by passing inferior to the pedicles of the corresponding vertebrae since early in development. In the lumbar region, the first division of the spinal nerve takes place within the

intervertebral foramen, resulting in the posterior and anterior (dorsal and ventral) rami. The posterior rami pass posteriorly, skirting the articular processes at that level, whereas the anterior rami proceed laterally to supply the body wall and the lower limbs (Stephen Kishner, Maxim Moradian, Jan K Morello, Thomas R Gest, 2017).

2-1-10-2.Relations of the roots and spinal nerves:

In the lumbar vertebral canal, the posterior and anterior roots of a given nerve (enclosed in their dural sacs) cross the intervertebral disc that is located above the pedicle below which the nerve exits. For example, the L2 nerve roots cross the disc between L1 and L2 vertebrae before reaching the appropriate foramen, below the pedicle of the L2 vertebra (Stephen Kishner, Maxim Moradian, Jan K Morello, Thomas R Gest, 2017).

2-1-10-3.Innervation of the lumbar spine structures:

Lumbar spinal nerves give off one or more recurrent meningeal branches, known as the sinuvertebral nerves. These branches originate from the autonomic nervous system, paravertebral plexuses, and overlying muscles distal to the DRG. The sinuvertebral nerves reenter the vertebral canal and carry with them sensory and sympathetic efferent fibers. Similar to the spinal branches of lumbar arteries, each nerve divides into ascending and descending branches to supply the periosteum, PLL, and outer anular laminae (Stephen Kishner, Maxim Moradian, Jan K Morello, Thomas R Gest, 2017).

The ALL is richly innervated by nerve fibers from the sympathetic system. The sinuvertebral nerves are also sensory to the meninges and the walls of the vertebral venous plexuses. They furnish the vasomotor fibers that regulate blood flow in the arteries and internal vertebral venous plexuses.

The sinuvertebral nerves extend to communicate with branches from radicular levels both above and below the level of entry, as well as the contralateral side, making it difficult to localize pain from involvement of these nerves (Stephen Kishner, Maxim Moradian, Jan K Morello, Thomas R Gest, 2017).

Anatomically, the ventral and dorsal (anterior and posterior) rami arise from the spinal nerve, just as it exits the foramen. The ventral primary ramus participates in the formation of the lumbosacral plexus and also provides a few nerve endings to the adjacent superficial annulus fibrosus of intervertebral discs. Otherwise, discs are considered non-innervated

structures (Stephen Kishner, Maxim Moradian, Jan K Morello, Thomas R Gest, 2017).

The dorsal primary ramus divides into medial, intermediate, and lateral branches just after it gives off an ascending facet branch to the dorsal aspect of the joint immediately above. The intermediate and lateral branches course laterally on the transverse process and supply the erector spinae muscles. Each medial branch of the posterior primary ramus participates in the innervation of 3 facet joints: one branch innervates the facet joint above the level, the second branch innervates at that level, and the third branch descends caudally to the level below (Stephen Kishner, Maxim Moradian, Jan K Morello, Thomas R Gest, 2017).

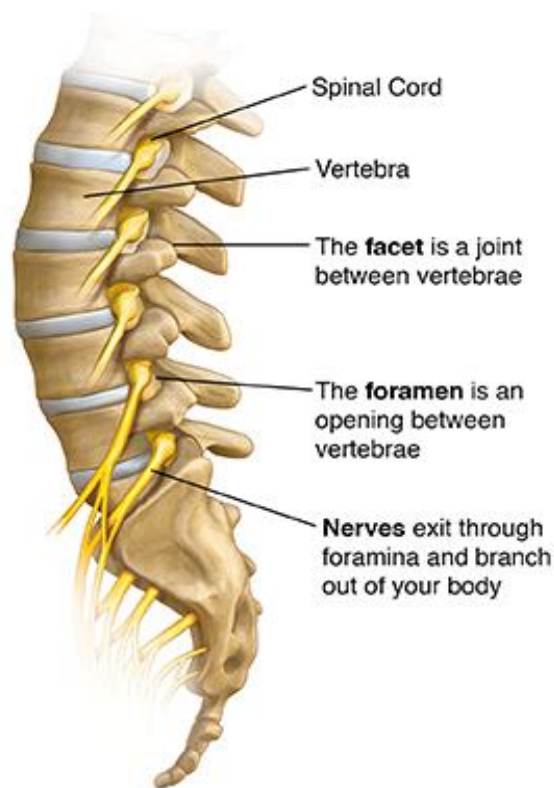

Figure 2-10: Spinal Nerves
(Yardley et al2015)

Innervation of the facet joints; dorsal ramus innervation (medial and lateral branches). MAL23 = mamillo-accessory ligament bridging the mammillary and accessory processes of L2 and L3; Z-joint = zygapophyseal joint (Stephen Kishner, Maxim Moradian, Jan K Morello, Thomas R Gest, 2017).

2-2.Pathology of Lumbar spine and Facet joint:

2-2-1.Lumbar spine:

There are several common potential sources and causes of back pain : these include spinal disc herniation and degenerative disc disease or isthmic Spondylolisthesis ,osteoarthritis (degenerative joint disease) and lumbar spinal stenosis , trauma, cancer, infection , fracture and inflammatory disease.(Stewart G Eielson, 1999- 2011)

2-2-1-1.Developmental Abnormalities:

Developmental abnormalities are not uncommon, occurring in an estimated 1 in 1,000 live births. These anomalies may range from nothing more serious than an unfused spinous process to a severe form of spinal dysraphism, usually with multiple associated abnormalities.

Other anomalies include hemivertebrae, congenital fusions, both of which often result in scoliosis, and cervical ribs. Among the plethora of associated findings are neurologic abnormalities such as hydrocephalus and urinary tract problems. Because of advancements in medical, surgical, and rehabilitation therapy, patients with severe spinal abnormalities can survive into adulthood and lead productive lives.

More common are segmentation anomalies occurring in the lumbar region and producing. (Clinical Radiology The Essentials. fourth edition)

Either lumbarization of S1 or sacralization of L5 .This terminology can be a source of confusion and some have recommended the use of the term transitional lumbosacral vertebra. If surgery or radiation therapy is to be performed, it is important for the correct level to be identified. Therefore, it is imperative that radiographs be obtained to accompany all vertebral CT and MR studies.(Clinical Radiology The Essentials. fourth edition)

Large defects are associated with spinal cord abnormalities and may lead to a variety of muscular abnormalities and lack of bladder or bowel control. In many cases a slight dimpling of the skin or a tuft of hair over the vertebral defect indicates the site of the lesion. Large defects in the lumbar or cervical spine may be accompanied by herniation of the meninges (meningocele), or of the meninges and a portion of the spinal cord or nerve roots (myelomeningocele). A patient with a meningocele may be asymptomatic. Other malformations associated with a meningocele are clubfoot, gait disturbances, and bladder incontinence. The myelomeningocele has associated neurologic deficits at and below the site of protrusion.(comprehensive Radiographic Pathology-fifth edition)

2-2-1-2.Lumbar Spinal Stenosis:

Lumbar spinal stenosis (LSS) is any narrowing in the lumbar spinal canal or lateral recess. It can be developmental, congenital, or acquired. This article discusses acquired degenerative lumbar spinal stenosis. Lumbar spondylosis refers to degenerative changes of the lumbar spine. Facet joint hypertrophy, thickening and bulging of the ligamentum flavum , outward bulging of the intervertebral disc, and disc degeneration, or degenerative Spondylolisthesis, are all manifestations of lumbar spondylosis. These degenerative changes may cause a reduction in the sagittal diameter of the spinal canal, commonly referred to as (central canal stenosis). The normal horseshoe-shaped spinal canal becomes a flattened triangular shape . Lateral recess stenosis also is a result of hypertrophy of the facet joints, loss of disc space height, posterolateral bulging of the disc, or degenerative Spondylolisthesis. There can be central canal stenosis in the absence of lateral recess stenosis (Fritz et al. 1998; Best, 2002; Gunzburg & Szpalski, 2003).

Spine extension (bending backward) causes posterior disc bulging and bulging of the ligamentum flava, which Results in further narrowing of the central and lateral canals. To compensate, a forward-flexed posture alleviates some of the narrowing caused by the hypertrophied ligamentum flavum and facets.(J Neurosci Nurs. 2005)

2-2-1-3.Degenerative disc disease:

As a normal sequel of aging, disc degeneration begins early in life due to loss of hydration resulting in disc height loss and diffuse bulging.Degenerative lumbar spine disease (DLSD) includes spondylotic (arthritic) and degenerative disc disease of the lumbar spine with or without neuronal compression or spinal instability. DLSD is common. Patients with DLSD often present with range of symptoms such as, lumbar back pain ,sciatica and claudication . In symptomatic patients, a significant proportion of symptoms are due to bony, discal or ligamentous compression of neural elements at the spinal canal or nerve root exit foramina. Cauda equina syndrome due to compression of the cauda equina by a herniated central lumbar disc is a specific condition requiring emergency neurosurgical attention .In terms of aetiology, in most patients DLSD is the result of "normal" wear and tear associated with the aging process or overuse. Other causes include a congenitally narrowed spinal canal, genetic predisposition to early disc disease, trauma, infection, inflammation and rarer conditions such as ossification of the posterior longitudinal ligament.

DLSD due to normal aging process can be divided into:

Spondylatic degenerative change:

2-2-1-3-1.Spondylolysis:

In spondylolysis, a crack or stress fracture develops through the pars interarticularis, which is a small, thin portion of the vertebra that connects the upper and lower facet joints. Most commonly, this fracture occurs in the fifth vertebra of the lumbar (lower) spine, although it sometimes occurs in the fourth lumbar vertebra. Fracture can occur on one side or both sides of the bone.

The pars interarticularis is the weakest portion of the vertebra. For this reason, it is the area most vulnerable to injury from the repetitive stress and overuse that characterize many sports. Spondylolysis can occur in people of all ages but, because their spines are still developing, children and adolescents are most susceptible. (American Academy of Orthopaedic Surgeons. AAOS.1997-2017)

2-2-1-3-2.. Spondylolisthesis:

spondylolysis can weaken the vertebra so much that it is unable to maintain its proper position in the spine. This condition is called Spondylolisthesis.

In Spondylolisthesis, the fractured pars interarticularis separates, allowing the injured vertebra to shift or slip forward on the vertebra directly below it. In children and adolescents, this slippage most often occurs during periods of rapid growth—such as an adolescent growth spurt.

Doctors commonly describe Spondylolisthesis as either low grade or high grade, depending upon the amount of slippage. A high-grade slip occurs when more than 50 percent of the width of the fractured vertebra slips.

forward on the vertebra below it. Patients with high-grade slips are more likely to experience significant pain and nerve injury and to need surgery to relieve their symptoms. (American Academy of Orthopaedic Surgeons.AAOS.1997-2017).

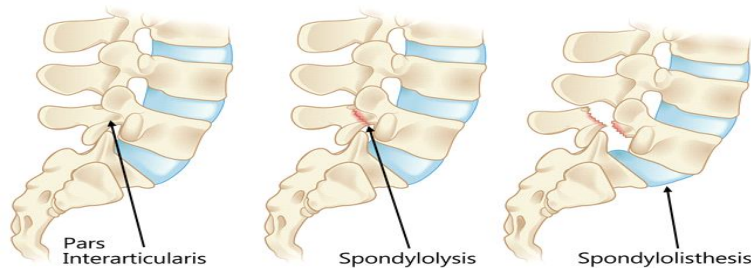


Figure 2-11: Degenerative disc diseases
(©AAOS.2017)

2-2-1-4. Bulging Disc:

A Bulging Disc occurs when the tough outer fibers of the spinal disc weaken and stretch allowing the “jelly center” of the disc to “bulge” outward . A Disc bulge is generally considered the first step toward a more serious problem called a Herniated Disc . A Herniated Disc is similar to a Disc Bulge except that the outer layers of the disc actually weaken to the point of tearing . (Irvine Family Health Center Spinal Decompression , 2006- 2010)

The majority of symptoms caused by a Bulging Disc are related to irritation of spinal nerves . These nerves exit the spine through small holes called foramen . The spinal disc are located next to these nerve passageways . The bulging of the disc material caused by a Bulging Disc can “ pinch” these nerves creating a variety of uncomfortable and sometimes debilitating symptoms. (Irvine Family Health Center Spinal Decompression , 2006- 2010)

A disc bulge in the low back can causes low back pain or numbness, Tingling, burning pain or weakness in the legs or feet .Sharp pain along the back of the legs is often referred to as sciatica . (Irvine Family Health Center Spinal Decompression 2006- 2010)

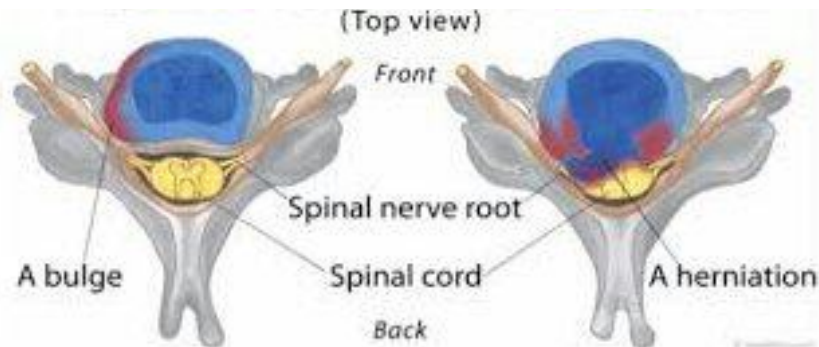


Figure 2-12: Bulging disc and herniated disc
(©2017 eHealthStar)

2-2-1-5. Herniated Disc:

Spinal disc herniation, also known as a slipped disc, is a medical condition affecting the spine in which a tear in the outer, fibrous ring of an intervertebral disc allows the soft, central portion to bulge out beyond the damaged outer rings. Disc herniation is usually due to age-related degeneration of the outer ring, known as the annulus fibrosus, although trauma, lifting injuries, or straining have been implicated as well. Tears are almost always postero-lateral (on the back of the sides) owing to the presence of the posterior longitudinal ligament in the spinal canal (Gerald L. Burke. 2013).

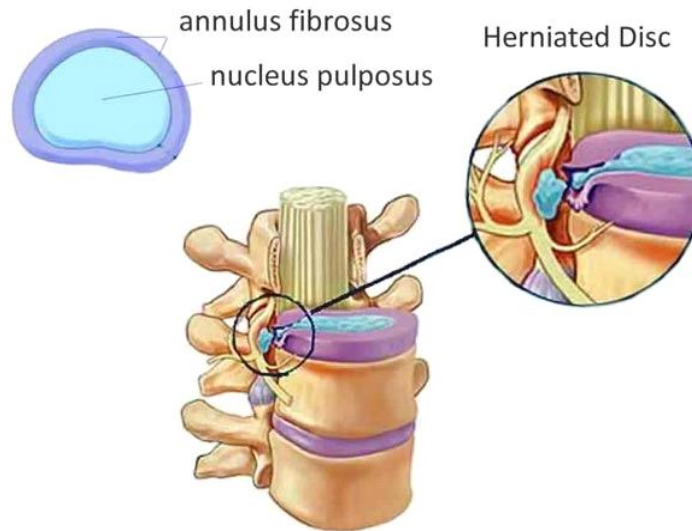


Figure 2-13 : Herniated disc
 (©1999-2017 Vertical Health, LLC)

This tear in the disc ring may result in the release of chemicals causing inflammation, which may directly cause severe pain even in the absence of nerve root compression.

Disc herniations are normally a further development of a previously existing disc protrusion, a condition in which the outermost layers of the annulus fibrosus are still intact, but can bulge when the disc is under pressure. In contrast to a herniation, none of the central portion escapes beyond the outer layers. Most minor herniations heal within several weeks. Anti-inflammatory treatments for pain associated with disc herniation, protrusion, bulge, or disc tear are generally effective. Severe herniations may not heal of their own accord and may require surgery. The condition is widely referred to as a (slipped disc), but this term is not medically accurate as the spinal discs are firmly attached between the vertebrae and cannot “slip” out of place. (Gerald L. Burke. 2013)

2-2-1-6. Infectious spine diseases:

2-2-1-6-1.Arthritis:

The word “arthritis” translates to “inflammation of a joint.” So, spinal arthritis, literally means inflammation of the facet or spinal joints.

Spinal arthritis is one of the common causes of back pain. Spinal arthritis is the mechanical breakdown of the cartilage between the aligning facet joints in the back portion (posterior) of the spine that quite often leads to mechanically induced pain. The facet joints (also called vertebral joints or zygapophyseal joints) become inflamed and progressive joint degeneration creates more frictional pain. Back motion and flexibility decrease in proportion to the progression of back pain induced while standing, sitting and even walking.(2016 Centered Health and Wellness)

Over time, bone spurs (small irregular growths on the bone also called osteophytes) typically form on the facet joints and even around the spinal vertebrae. These bone spurs are a response to joint instability and are nature's attempt to help return stability to the joint. The enlargement of the normal bony structure indicates degeneration of the spine. Bone spurs are also seen as a normal part of aging and do not directly cause pain, but may become so large as to cause irritation or entrapment of nerves passing through spinal structures, and may result in diminished room for the nerves to pass (spinal stenosis). (2016 Centered Health and Wellness)

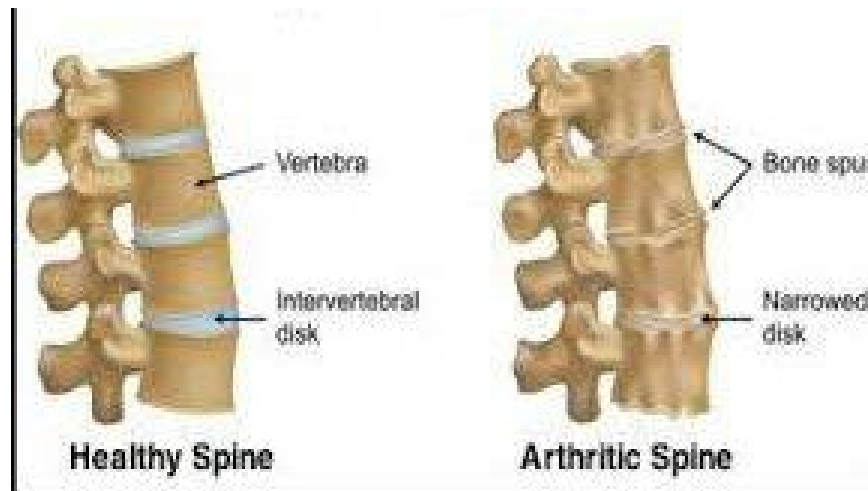


Figure 2-14: Spinal arthritis
 (© 2016 Centered Health and Wellnes)

2-2-1-6-2. Tuberculous Osteomyelitis:

Tuberculous osteomyelitis (which is rare today) most commonly involves the thoracic and lumbar spine. Pott's disease (tuberculosis of the spine) occurs in the midthoracic spine and thoracolumbar region. Irregular, poorly marginated bone destruction within the vertebral body is often associated with a characteristic paravertebral abscess, an accumulation of purulent material that produces a fusiform soft tissue mass about the vertebra. The spread of tuberculous osteomyelitis causes narrowing of the adjacent intervertebral disk and the extension of infection and bone destruction across the disk to involve the adjacent vertebral body. Unlike bacterial infection, tuberculous osteomyelitis is rarely associated with periosteal reaction or bone sclerosis (Mosby, Inc., an affiliate of Elsevier Inc., 2012).

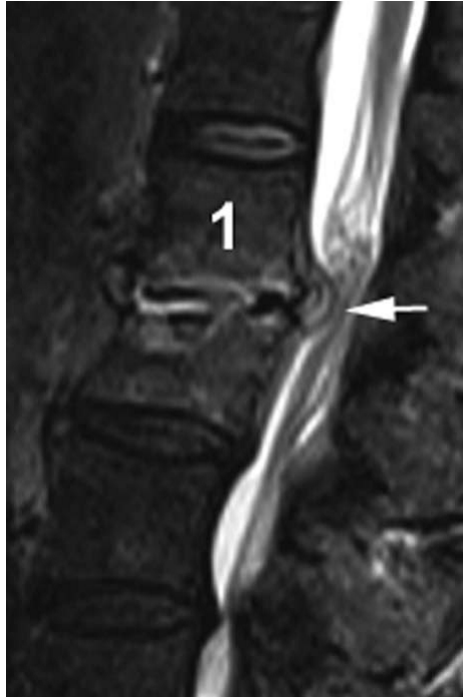

Figure 2-15 : Sagittal STIR image shows loss of disc height
 (©Mjorter at Dutch Wikipedia . 2007)

2-2-1-7.Spinal injury:

The spinal cord contains the nerves that carry messages between your brain and body. The cord passes through your neck and back. A spinal cord injury is very serious because it can cause loss of movement (paralysis) below the site of the injury spinal cord injury may be caused by Bullet , stab wound Traumatic injury to the face, neck, head, chest, or back (for example, a car accident),Diving accident. Electric shock Extreme twisting of the middle of the body, Landing on the head during a sports injury, Fall from a great height. (American Collage of Surgons , 1997)

2-2-1-8. Trauma to the spinal column:

Fractures occur when internal or external forces on the vertebrae exceed their structural strength. Common causes are vehicle accidents, sports, violence, and falls. Fractures can be further classified into two more groups: minor and major. When a posterior column element, such as the facet joint, is fractured it is "minor" because that structure is not vital to the stability of the spine. On the other hand, if the vertebral body is fractured (middle or anterior column), it is "major" because the stability of the spine may be at risk or damage to the spinal cord may occur. Vertebral body fractures may be further termed as stable or unstable. If a fracture is unstable, the bone fragments can damage the spinal cord and immediate intervention is necessary (Gray. Henry ,1977).

2-2-1-8-1.Compression fractures:

As the name implies, compression fractures occur from excessive axial forces disrupting the continuity of the anterior column of the vertebral body. Osteoporosis is a leading precursor to compression fractures because of the vertebrae's lower ability to support a load. A missed step or even a cough can result in a compression fracture. People often accept back pain as a normal part of aging. Repeated compression fractures can result in the loss of six inches or more in height. Another common cause of compression fracture is trauma, such as a fall. Click on the button below to witness a sudden vertical impact to the vertebral column. Often, vertebral compression

fractures eventually heal on their own. Aspirin and other nonsteroidal anti-inflammatory drugs (NSAIDs) can be taken to relieve pain. More aggressive techniques include vertebroplasty, the injection of bone cement into the vertebra to stabilize it. Kyphoplasty is similar, but the vertebra is first expanded to near normal height and then stabilized with cement or mechanical devices. (Gray's 2005).

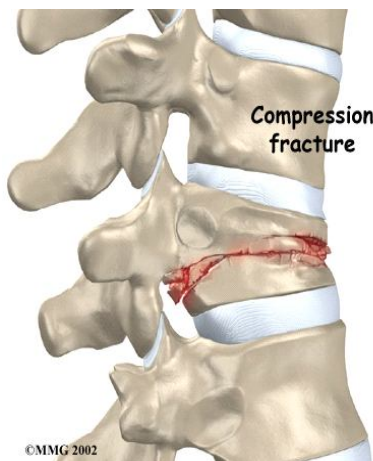


Figure 2-16: compression fracture
(©MMG2002)

2-2-1-8-2.Burst fractures:

Burst fractures usually occur from severe trauma such as a vehicle accident or a fall. Burst Fxs are more dangerous than compression Fxs for two reasons. The anterior and middle columns of the vertebral body are broken into several fragments, which are more likely to cause spinal cord injury. Since the vertebral body has lost its structural integrity, the spinal column is less stable. If the burst Fx does not impinge on the spinal cord, it may be treated non-surgically. However, if there are loose fragments or nerve injury, surgery is usually performed. The spine can be accessed anteriorly, posteriorly, or both. Loose fragments may be moved into a better position or removed. The spine may be reduced (elongated) for alignment. The fragments may be stabilized with screws and other

mechanical means. In severe cases, the entire Fx vertebral body is removed and the adjacent vertebrae fixed in place with rods and screws. A bone-conductive reinforcement structure replaces the vertebra. (Gray's 2005).

2-2-1-8-3. Flexion-distraction fracture:

This type of fracture is sometimes called a "Chance" fracture. It was often caused by lap seat belts without shoulder restraints in cars. The initial collision can cause extreme flexion of the vertebral column, soon followed by the distraction of the rebound. In this fracture, all three columns of the vertebral body can fail and there may be injury to bone, ligaments and discs as well as other internal injuries. Chance fractures are inherently unstable and require immediate intervention. These fracture types represent about 10% of lumbar spine fractures. The posterior column may be damaged by rupture of the spinus process or posterior longitudinal ligament, or both (Gray's 2005).

2-2-1-8-4. Stable versus unstable fractures:

If only the anterior column is damaged, as in the case of most wedge and compression fractures, the fracture is considered stable. When both the anterior and middle columns are involved, the fracture may be considered more unstable. When all three columns are involved, the fracture is by definition considered unstable, because of the loss of the integrity of the vertebra and posterior stabilizing ligaments.

Stable fractures do not pose a threat to the spinal cord. Unstable fractures endanger the spinal column and, depending on circumstances, may require immediate surgical intervention. (Gray's 2005).

2-2-1-9. Hyperlordosis of the spine:

Lordosis describes the natural curvature of the lumbar spine, but Hyperlordosis is a pathologically exaggerated lumbar curvature, commonly called "swayback". Hyperlordosis is usually accompanied by the pelvis tilting abnormally forward, often causing an exaggerated protrusion of the buttocks. Symptoms may include pain and numbness if the nerve trunks are compromised. . (Gray's 2005).

Typically, the condition is attributed to weak back muscles or a habitual hyperextension, such as in pregnant women, men with excessive visceral fat, and some dance postures. Hyperlordosis is also correlated with puberty. Treatment for hyperlordosis isn't required unless it may progress, causes pain, or compromises nerves. Initially analgesics and anti-inflammatory medication are administered. . (Gray's 2005).

Physical therapy to build strength, flexibility, and increase range of motion is common. The reduction to ideal body mass index is

recommended. In adolescents, bracing may be applied to control progression. In severe cases with neurological involvement, surgery should be considered. This typically involves a fusion of L4-L5 and L5-S1. This is a younger person's disease, often associated with overtraining in active sports. There is also a hereditary correlation to weakness in the pars region, suggesting a genetic component. (Gray's 2005).

2-2-1-10. Tumors of the spine:

here are three common types of spinal tumors that can cause back pain: vertebral column tumors, intradural - extramedullary tumors, and intramedullary tumors (Mosby, Inc., an affiliate of Elsevier Inc., 2012).

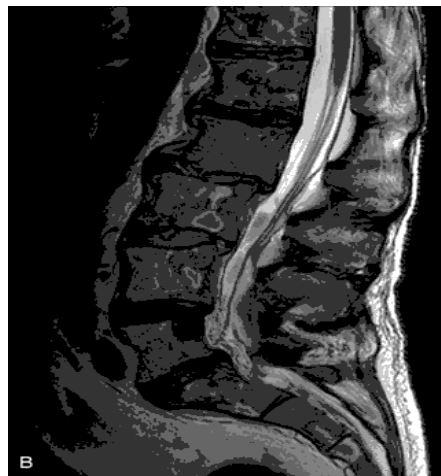

Figure 2-17 :Sagittal T2WI demonstrates heterogeneous marrow signal with areas of high and low signal that both correspond to metastatic deposit. (Website <http://clinicalgate.com> 2015)

2-2-1-10-1. Primary tumors:

These tumors occur in the vertebral column, and grow either from the bone or disc elements of the spine. They typically occur in younger adults. Osteogenic sarcoma (osteosarcoma) is the most common malignant bone tumor. Most primary spinal tumors are quite rare and usually grow slowly (John., 2014).

2-2-1-10-2. Metastatic tumors:

Most often, spinal tumors metastasize (spread) from cancer in another area of the body. These tumors usually produce pain that does not get better with rest, may be worse at night, and is often accompanied by other signs of serious illness (such as weight loss, fever/chills/shakes, nausea or vomiting).

- In women, spinal tumors most frequently spread from cancer that originates in the breast or lung.
- In men, spinal tumors most frequently spread from cancer that originates in the prostate or lung. (Mosby, Inc., an affiliate of Elsevier Inc., 2012)

2-2-1-10-1.Intradural-Extramedullary Tumors :

Intradural-Extramedullary (inside the dura) tumors grow within the spinal canal (under the membrane that covers the spinal cord) but outside of the nerves. Usually these tumors are benign and slow growing. However, they can cause symptoms of pain and weakness.

Most of these spinal tumors are:

- Meningiomas that occur in the membranes surrounding the spinal cord and are usually benign but may be malignant. These tumors are more common in middle age and elderly women.
- Nerve sheath tumors (schwannomas and neurofibromas) that arise from the nerve roots that come off the spinal cord. Again, this type of tumor is usually benign and slow growing, and it may be years before any neurological problems occur (Mosby, Inc., an affiliate of Elsevier Inc.,2012).

2-2-1-10-2.Intramedullary Tumors:

Intramedullary tumors grow from inside the spinal cord or inside the individual nerves and often arise from the cells that provide physical support and insulation for the nervous system (glial cells). These tumors occur most often in the cervical spine (neck). They tend to be benign, but surgery to remove the tumor may be difficult.

The two most common types of intramedullary tumors are astrocytomas and ependymomas (Mosby, Inc., an affiliate of Elsevier Inc.,2012).

2-2-1-11.Paget's Disease:

Paget's disease (osteitis deformans) is one of the most common chronic metabolic diseases of the skeleton. Destruction of bone, followed by a reparative process, results in weakened, deformed, and thickened bony structures that tend to fracture easily. The disease, seen most commonly during middle life, affects men twice as often as women and has been reported to occur in about 3% of all persons older than 40 years. Although the destructive phase often predominates initially, there is more frequently a combination of destruction and repair in the pelvis and weight-bearing bones of the lower extremities. The reparative process may begin early and may be the prominent feature, often involving multiple bones. Paget's disease affects particularly the pelvis, femurs, skull, tibias, vertebrae, clavicles, and ribs (Mosby, Inc., an affiliate of Elsevier Inc.,2012) .

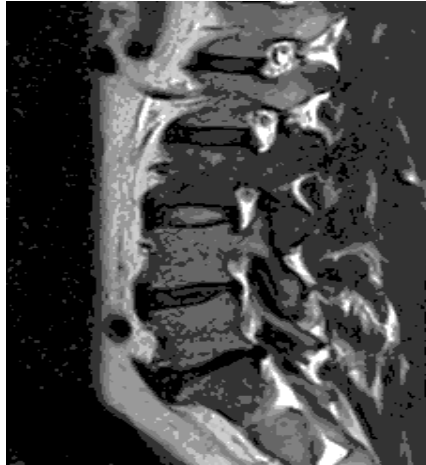

Figure 2-18:T1 signal and enlargement of the L3 posterior elements low
Website <http://clinicalgate.com> 2015)

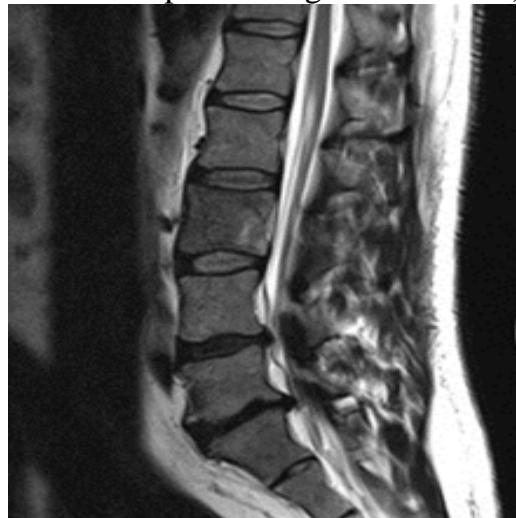

Figure 2-19 Heterogenous low T2signal within L3 vertebral body
Website <http://clinicalgate.com> 2015)

2-2-2.Facet joint:

Like in all synovial lined joints, arthrosis is a continuum between loss of joint space narrowing, loss of synovial fluid and cartilage and bony overgrowth. High grade cartilage necrosis arises quite rapidly in facets (Gellhorn et al. 2012).

Facet arthrosis or degenerative facet disease is the most frequent form of facet pathology. It is mainly a disease affecting the elderly population, present in virtually everyone after the age of 60 and in varying degrees affecting the majority of adults, suggesting that facet arthrosis has a major role in neck pain and back pain in the elderly population (Gellhorn et al. 2012).

Degenerative facet disease in many cases already begins before the age of 20. There is no gender preference. It is probably related to mechanical loading, minor repetitive trauma and/or a form of predisposition (Gellhorn et al. 2012).

Symptoms and signs are very specific and can be variably progressive. Most commonly it gives rise to a mechanical type of neck or back pain, but it can also be asymptomatic. Studies have shown that facet joints are clinically important spinal pain generators and patients with symptomatic facet joints can benefit from specific interventions. The symptoms are frequently aggravated by extension and alleviated by flexion, with pain not irradiating below the knee. There is a poor correlation between pain and the extent of degeneration (Gellhorn et al. 2012).

Mechanical stress is exacerbated in facets that are more horizontal in a sagittal plane, typically at the L4-L5 level (Gellhorn et al. 2012).

In imaging studies more and more the emphasis lies on the visualization of inflammation of the facet joint and the surrounding soft tissues. It is believed that this inflammation is the cause of local, i.e. non-irradiating, pain. Not all changes are inflammatory, especially bony overgrowth is a protective reaction to inflammation, diminishing inflammatory response. However bony overgrowth can be an important cause of neuroforaminal narrowing, giving rise to irradiating pain (Gellhorn et al. 2012).

Degenerative spondylolisthesis is a displacement of one vertebra relative to another in the sagittal plane. In many cases it is related to facet joint arthrosis and failure of the motion segment. Listhesis occurs as a result of subluxation of the facet joint, related to important and progressive loss of cartilage and articular remodeling (Gellhorn et al. 2012).

A more sagittal joint orientation might lessen the amount of anterior restraint that the facet joints are able to supply to the vertebral column simply because there is less of a bony barrier in the sagittal plane. This lack of restraint can result in anterior slippage of the superior vertebra in the motion segment. Spondylolisthesis therefore often occurs at L4-L5, the same level that is most often affected by arthrosis. This can narrow the spinal canal and the neuroforamina (Gellhorn et al. 2012).

Septic facet arthritis or pyogenic facet arthritis is a completely different and rare entity. It can give rise to similar imaging findings as degenerative disease, usually with more inflammation and a more aggressive course. The isolated form should always raise suspicion of tuberculosis or an iatrogenic

ic cause. In some cases it is secondary to infection of the discs and/or vertebrae (spondylodiscitis) (Gellhorn et al. 2012).

2-3. Lumbar spine Imaging :

2-3-1. Computerized Tomography (CT):

CT scan, commonly referred to as a CAT scan, is a type of X-ray that produces cross-sectional images of a specific part of the body. In the case of a lumbar spine CT scan, your doctor can see a cross-section of your lower back. The scanning machine circles the body and sends images to a computer monitor, where they are reviewed by a technician (William Morrison, MD Brian Krans 2016).

The lumbar portion of the spine is a common area where back problems occur. The lumbar spine is the lowest portion of your spine. It's made up of five vertebral bones. Below the lumbar spine is the sacrum and below the sacrum is the coccyx (tailbone). Large blood vessels, nerves, tendons, ligaments, and cartilage are also part of the lumbar spine (William Morrison, MD Brian Krans 2016).

A CT scan is one of many imaging tests your doctor may use to investigate problems with your spine. This includes pain due to injuries, disease, or infection (William Morrison, MD Brian Krans 2016).

Other reasons your doctor might order a lumbar CT scan include:

- Back pain accompanied by fever
- Birth defects affecting the spine
- A herniated disk
- Infection
- Injury to the lower spine
- Low back pain
- Multiple sclerosis
- Osteoarthritis
- A pinched nerve
- Problems controlling the bladder
- Signs of cancer
- Spinal surgery preparation
- Weakness, numbness, or other problems with your legs

CT scan is not the same as an MRI. An MRI of the lumbar spine shows the bones, disks, and spinal cord. MRIs can also show the spaces between the vertebral bones that nerves pass through (William Morrison, MD Brian Krans 2016).

2-3-2. Conventional X-ray:

lumbosacral spine X-ray, or lumbar spine X-ray, is an imaging test that helps your doctor view the anatomy of your lower back.

The lumbar spine is made up of five vertebral bones. The sacrum is the bony “shield” at the back of your pelvis. It’s located below the lumbar spine. The coccyx, or tailbone, is located below the sacrum. The thoracic spine sits on top of the lumbar spine. The lumbar spine also has:

- Large blood vessels
- Nerves
- Tendons
- Ligaments
- Cartilage

X-ray uses small amounts of radiation to view your body’s bones. When focusing on the lower spine, an X-ray can help detect abnormalities, injuries, or diseases of the bones in that specific area. According to the Mayo Clinic, a lumbar spine X-ray can show whether you have arthritis or broken bones in your back, but it can’t show other problems with your muscles, nerves, or disks (William Morrison, MD Brian Krans 2017) .

Your doctor could order a lumbar spine X-ray for a variety of reasons. It can be used to view an injury from a fall or accident. It can also be used to monitor the progression of a disease like osteoporosis or to determine if a treatment you’re having is working (William Morrison, MD Brian Krans 2017) .

An X-ray is a useful test for many conditions. It can help your doctor understand the cause of chronic back pain or view the effects of injuries, disease, or infection. Your doctor may order a lumbar spine X-ray to diagnose:

- Birth defects that affect the spine
- Injury or fractures to the lower spine
- Low back pain that's severe or lasts for more than four to eight weeks
- Osteoarthritis, which is arthritis affecting the joints
- Osteoporosis, which is a condition that causes your bones to thin
- Abnormal curvature or degenerative changes in your lumbar spine, such as bone spurs
- Cancer

2-3-3.Magnetic resonance imaging (MRI) :

2-3-3-1.MRI physics:

Magnetic resonance imaging (MRI) is a medical imaging procedure that uses strong magnetic fields and radio waves to produce cross-sectional images of organs and internal structures in the body. Because the signal detected by an MRI machine varies depending on the water content and local magnetic properties of a particular area of the body, different tissues or substances can be distinguished from one another in the study image. MRI can give different information about structures in the body than can be obtained using a standard x-ray, ultrasound, or computed tomography (CT) exam. An MRI exam of a joint can provide detailed images of ligaments and cartilage, which are not visible using other study types. In some cases, a magnetically active material (called a contrast agent) is used to show internal structures or abnormalities more clearly. (Pooley, 2005).

Many MR systems are commercially available, each possessing different features and capabilities that are often difficult to evaluate and compare objectively. Many of these features are based on the operating software provided by the manufacturer, but certain hardware components are common to all systems. The major components are the computer and image processing systems, a magnet system, a gradient system, a radiofrequency system, and a data acquisition system (Pooley, 2005).

In most MRI devices, an electric current is passed through coiled wires to create a temporary magnetic field around a patient's body. (In open-MRI devices, permanent magnets are used.) Radio waves are sent from and received by a transmitter/receiver in the machine, and these signals are used to produce digital images of the area of interest. Using MRI scans, physicians can diagnose or monitor treatments for a variety of medical conditions, including: Abnormalities of the brain and spinal cord, Tumors, cysts, and other abnormalities in various parts of the body, Injuries or abnormalities of the joints, Certain types of heart problems, Diseases of the liver and other abdominal organs, Causes of pelvic pain in women, Suspected uterine abnormalities in women undergoing evaluation for infertility.

MRI does not use ionizing radiation. There are no known harmful side-effects associated with temporary exposure to the strong magnetic field used by MRI scanners. There are important safety concerns to consider before performing or undergoing an MRI scan: The magnet may cause pacemakers, artificial limbs, and other implanted medical devices that contain metal to malfunction or heat up during the exam, Any loose metal object may cause damage or injury if it gets pulled toward the magnet, If

a contrast agent is used, there is a slight risk of an allergic reaction. MRI contrast agents can cause problems in patients with significant kidney disease, Dyes from tattoos or tattooed eyeliner can cause skin or eye irritation, Medication patches can cause a skin burn, The wire leads used to monitor an electrocardiogram (ECG) trace or respiration during a scan must be placed carefully to avoid causing a skin burn and Prolonged exposure to radio waves during the scan could lead to slight warming of the body (Pooley,2005).

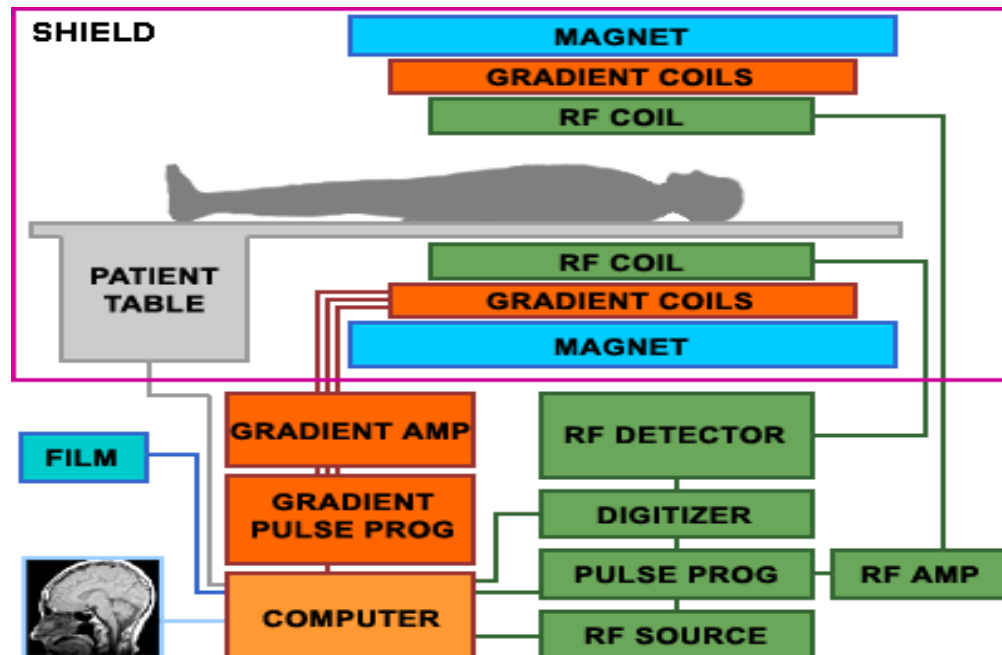


Figure 2-20.MRI schematic diagram
(Pooley, 2005)

MRI is widely used now to visualize the spinal column and its contents. T1- and T2-weighted images give information about morphology and integrity of discs and vertebrae, the intervertebral foramina and facet joints, and an outline of the spinal cord. The vertebrae have a low-signal outer rim surrounding the high-signal cancellous bone. The basivertebral veins are seen in the posterior midline of the vertebral body. (Malcolm, 2002)

A very simplified pulse sequence is a combination of RF pulses, signals and intervening periods of recovery. TR and TE. A pulse sequence consists of several time periods: The repetition time (TR) is the time from the application of one RF pulse to the application of the next RF pulse for each slice and is measured in milliseconds (ms). The TR determines the amount of longitudinal relaxation that is allowed to occur between the end of one RF pulse and the application of the next. TR thus determines the amount of T1 relaxation that has occurred when the signal is read. The echo time (TE) is the time from the application of the RF pulse to the

peak of the signal induced in the coil and is also measured in (ms). The TE determines how much decay of transverse magnetization is allowed to occur. TE thus controls the amount of T2 relaxation that has occurred when the signal is read. (Catherine Westbrook, etal –2011)

To demonstrate either T1, proton density or T2 contrast, specific values of TR and TE are selected for a given pulse sequence. The selection of appropriate TR and TE weights an image so that one contrast mechanism predominates over the other two. A T1 weighted image is one where the contrast depends predominantly on the differences in the T1 times between fat and water (and all the tissues with intermediate signal). Because the TR controls how far each vector recovers before the slice is excited by the next RF pulse, to achieve T1 weighting the TR must be short enough so that neither fat nor water has sufficient time to fully return to B0. If the TR is too long, both fat and water return to B0 and recover their longitudinal Magnetization fully. When this occurs, T1 relaxation is complete in both tissues and the differences in their T1 times are not demonstrated. TR controls the amount of T1 weighting. For T1 weighting the TR must be short. (Catherine Westbrook, etal –2011)

A T2 weighted image is one where the contrast predominantly depends on the differences in the T2 times between fat and water (and all the tissues with intermediate signal). The TE controls the amount of T2 decay that is allowed to occur before the signal is received. To achieve T2 weighting, the TE must be long enough to give both fat and water time to decay. If the TE is too short, neither fat nor water has had time to decay, and therefore the differences in their T2 times are not demonstrated. TE controls the amount of T2 weighting. For T2 weighting the TE must be long. (Catherine Westbrook, etal –2011)

A proton density image is one where the difference in the numbers of mobile hydrogen protons per unit volume in the patient is the main determining factor in forming image contrast. Proton density weighting is always present to some extent. To achieve proton density weighting, the effects of T1 and T2 contrast must be diminished so that proton density weighting can dominate. A long TR allows both fat and water to fully recover their longitudinal magnetization and so diminishes T1 weighting. A short TE does not give fat or water time to decay and so diminishes T2 weighting. In any image, the contrast due to the inherent proton density together with T1 and T2 mechanisms occur simultaneously and contribute to image contrast. To weight an image so that one process is dominant, the other processes must be diminished. (Catherine Westbrook, etal –2011)

2-3-3-2.MRI Technique:

2-3-3-2-1.Patient Positioning:

The patient lies supine on the examination couch with their knees elevated over a foam pad, for comfort and to flatten the lumbar curve so that the spine lies nearer to the coil. The coil should extend from the xiphister- num to the bottom of the sacrum for adequate coverage of the lumbar region. The patient is positioned so that the longitudinal alignment light lies in the midline, and the horizontal alignment light passes just below the lower costal margin, which corresponds to the third lumbar vertebra.(Catherine Westbrook. – 2008)

2-3-3-2-2.Suggested Protocol:

-Sagittal/coronal SE/FSE T1 or coherent GRE T2* Acts as a localizer if three-plane localization is unavailable.

-Sagittal SE/FSE T1

-Sagittal SE/FSE T2 or coherent GRE T2*

-Axial/oblique SE/FSE T1/T2 or coherent GRE T2* (Catherine Westbrook. – 2008)

2-3-3-2-3. Additional Sequences:

-Axial/oblique or Sagittal SE/FSE T1 With contrast for determining disc prolapse versus scar tissue in failed back syndrome, and for some tumours.

-Coronal SE/FSE T1 For cord tethering or alternative view of conus when sagittals are inconclusive.

-Axial/oblique FSE T2 For arachnoiditis. (Catherine Westbrook. –2008)

2-3-3-3. Patient Considerations:

Many patients are in severe pain especially if they are suffering from a prolapsed lumbar disc. Make the patient as comfortable as possible with pads supporting their knees in a slightly flexed position. Small pads placed in the lumbar curve often help to alleviate sciatica and other types of back pain. Due to excessively loud gradient noise associated with some sequences, ear plugs must always be provided to prevent hearing impairment. (Catherine Westbrook. – 2008)

2-3-3-4. Contrast Usage:

Contrast is used to distinguish disc prolapse from scar tissue post-operatively in failed back syndrome.Contrast is also invaluable to visualize suspicious lesions in the conus. (Catherine Westbrook. – 2008).

2-4.Previous studies:

Atsushi Fujiwara Kazuya Tamai Minoru Yamato Howard S. An Hiroyuki Yoshida Koichi Saotome Akira Kurihashi (1999) studied the role of MRI in assessing facet joint osteoarthritis is unclear. By developing a grading system for severity of facet joint osteoarthritis on MRI, the relationship between disc degeneration and facet joint osteoarthritis was determined. The accuracy of MRI in assessing facet joint osteoarthritis against CT was 94%. Under 40 years of age, the degree of disc degeneration varied among individuals. Over the age of 60, most of the discs were markedly degenerated. Under 40 years of age osteoarthritic changes in facet joints were minimal. Over the age of 60, variable degrees of facet joint osteoarthritis were observed but some facets did not show osteoarthritis. No facet joint osteoarthritis was found in the absence of disc degeneration and most facet joint osteoarthritis appeared at the intervertebral levels with advanced disc degeneration. Disc degeneration is more closely associated with aging than with facet joint osteoarthritis. The present study supports the hypothesis that "disc degeneration precedes facet joint osteoarthritis", and also supports the concept that it may take 20 or more years to develop facet joint osteoarthritis following the onset of disc degeneration.

James Rankine Email author Paul Harwood Peter V. Giannoudis (2011) studied degenerative arthritis of the lumbar facet joints that has failed to respond to analgesia and conservative measures. As degenerative disease usually affects multiple joints within the lumbar spine, these injections should be reserved for patients with identified focal pathology on imaging and low back pain which if unilateral should match the site of pathology on imaging.

Beaman DN , Graziano GP , Glover RA , Wojtys EM , Chang V (1993) studied sixteen adult human lumbar spine facet joints were harvested from patients undergoing various lumbar spine procedures. Diagnoses included degenerative disc disease, adult spinal deformity, facet joint degenerative arthritis, and degenerative spondylolisthesis. Facet joints were processed for routine hematoxylin and eosin staining. Immunohistochemical analysis was performed using a monoclonal antibody to substance P. All facets grossly exhibited evidence of degenerative disease, including cartilage surface irregularity and fibrillation. Histological examination of facets obtained from patients with degenerative spinal conditions demonstrated erosion channels extending through the subchondral bone and calcified cartilage into the articular cartilage. Immunostaining showed the presence of substance P-positive nerve fibers within these erosion channels, and also within

marrow spaces. The presence of substance P nerve fibers within subchondral bone of degenerative lumbar facet joints implicates this type of joint in the etiology of low back pain.

Chapter Three

Chapter Three

Materials and Methods

3-1. Materials:

3-1-1. Patients:

50 patients in both gender , different age and body mass index undergo MRI test for lumbar spine. These patients comes complaining of lower back pain and lumbar spine disease .

3-1-2. Study Design:

Observation study –hospital and medical center based study

3-1-3. Area of study:

Sudanese population

3-1-4. Place of study:

- Ribat University Hospital.
- Modern Medical Center.

3-1-5. Duration of study;

From September 2017 to January 2018

3-1-6. Inclusion criteria:

Patients with back pain and disease of lumbar spine

3-1-7. Exclusion criteria:

Normal patients

3.1.8. Machines used:

In the present study, MRI machines were used:

3-1-8-1. Ribat University Hospital:

Machine : Siemens closed MRI machine
Power :1.5 tesla
Coil : Posterior spinal coil
Magnet : superconductive with helium cooling
Machine : Neusoft open MRI machine
Power :0.35 tesla
Coil : Body coil
Magnet : superconductive with helium cooling

3-1-8-2 . Modern Medical Center:

Machine : General electric close MRI machine
power:1.5 Tesla
Coil :Posterior spinal coil
Magnet : superconductive with helium cooling

3-2.Methodes:

3-2-1. Patient position:

The patient lies supine on the examination couch with their knees elevated over a foam pad, for comfort and to flatten the lumbar curve so that the spine lies nearer to the coil. The coil should extend from the xiphisternum to the bottom of the sacrum for adequate coverage of the lumbar region. The patient is positioned so that the longitudinal alignment light lies in the midline, and the horizontal alignment light passes just below the lower costal margin, which corresponds to the third lumbar vertebra. .(Hand book of MRI Technique Third Edition).

3-2-2.Technique:

MRI of the lumbar spine was performed with multiplane imaging and multiweighted sequences.

The following sequences were obtained:

3-2-2-1.Modern Medical Center:

Axial T1 (TR)/(TE)500/1ms, the matrix size 446x512, FOW300X300, slice thickness 5mm, and (FSE) sequence.

Sagittal SE/FSE T1(TR)/ (TE) 500/10 msec. the matrix size was 334x512, FOW300x300, slice thickness 5 mm , and (SE)sequence.
Axial SE/FSE T2 (TR)/ (TE) 3500/120 msec.the matrix size was 390x512, FOW 250x250, slice thickness 5 mm.

3-2-2-2.Ribat University Hospital:

Sagittal SE/FSE T1 (TR)/ (TE) 500/10 msec. the matrix size was 334x512, FOW300x300, slice thickness 5 mm , and (SE)sequence.
Sagittal SE/FSE T2 (TR)/ (TE) 3500/120 msec. the matrix size was 390x512, FOW 250x250, slice thickness 5 mm.
Axial/oblique SE/FSE T2 (TR)/ (TE) 3500/120 msec. the matrix size was 390x512, FOW 250x250, slice thickness 5 mm.

3-2-3.Data collection:

The data were collected by data collection sheets include the DDD, Facet joint osteoarthritis, Age, Gender, Length and weight. Then calculate BMI from Length and weight. Data sheet were collected from Modern Medical Center and Ribat University Hospital .

3-2-4.Data analysis:

The data collected from the cases of patient and entered to SPSS windows software .

3-2-5.Evaluation and image interpretations:

Cases were evaluated by different consultant radiologist with different experiences and practice.

Chapter Four

Chapter Four

Results

Table 4-1. shows age distribution among study sample.

Age groups	Frequency	Percent
21-35	14	28.0
36-49	14	28.0
50-63	11	22.0
64-77	11	22.0
Total	50	100.0

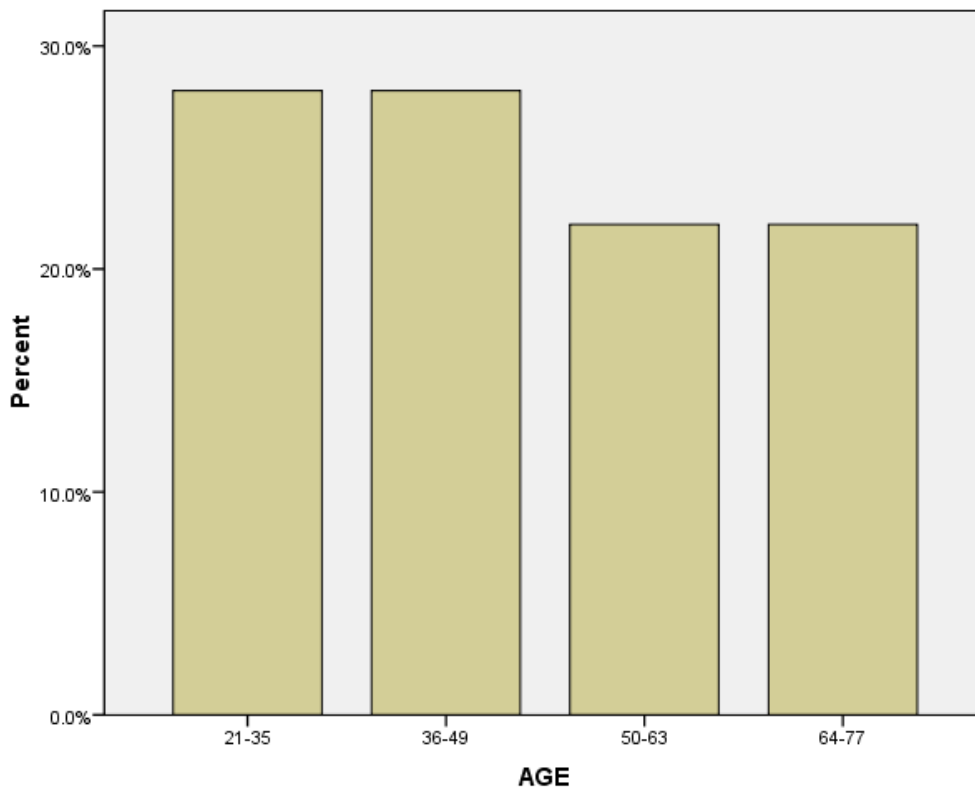


Figure 4-1. Show age distribution among the study sample

Table 4-2. shows gender distribution among study sample.

Gender	Frequency	Percent
Female	27	54.0
Male	23	46.0
Total	50	100.0

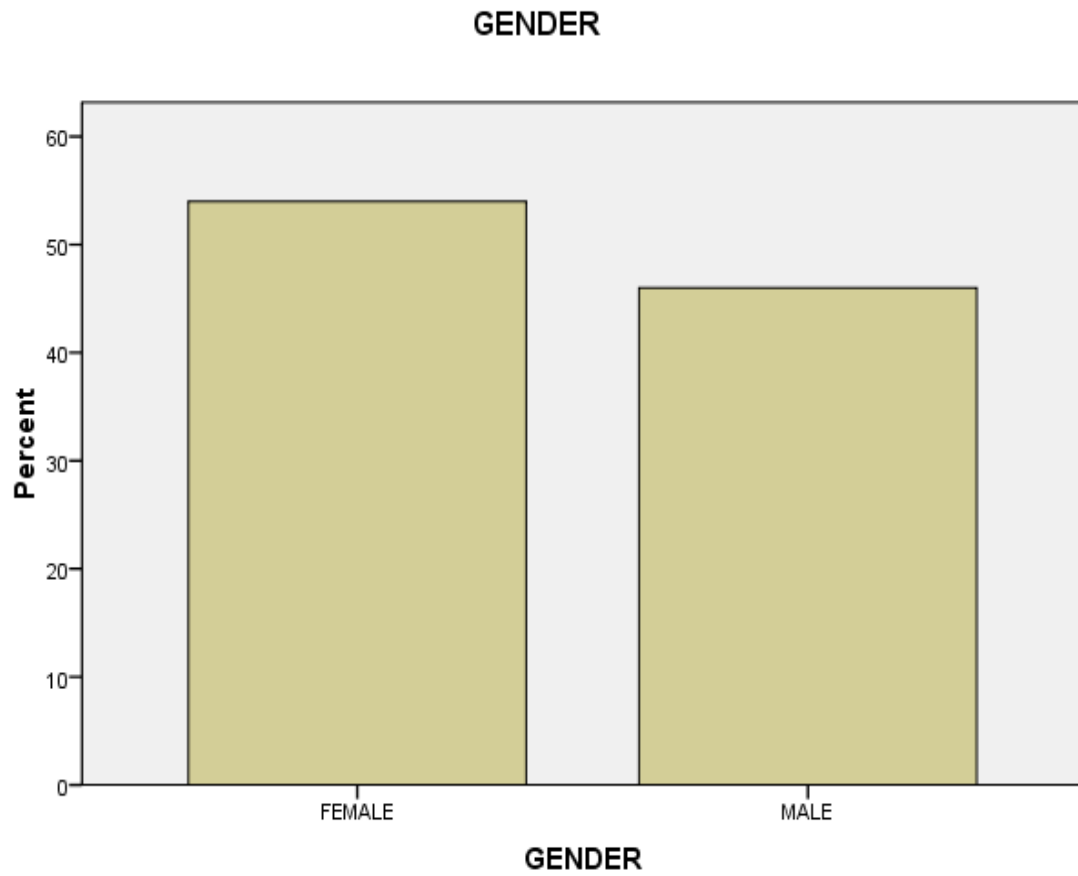


Figure 4-2. Show gender distribution among the study sample

Table 4-3. Shows BMI distribution among study sample.

BMI	Frequency	Percent
22	1	2.0
23	5	10.0
24	4	8.0
25	4	8.0
26	6	12.0
27	11	22.0
28	10	20.0
29	8	16.0
30	1	2.0
Total	50	100.0

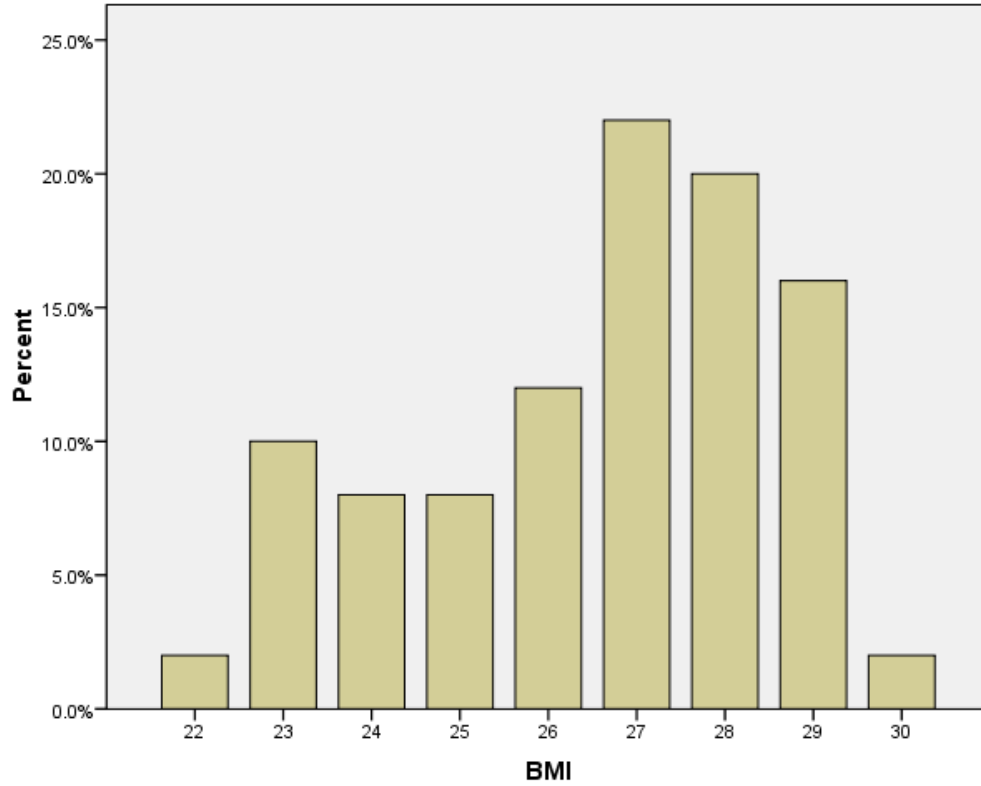


Figure 4-3. Show BMI distribution among the study sample

Table 4-4. Shows Facet joint osteoarthritis among study sample.

Facet joint osteoarthritis	Frequency	Percent
Negative	14	28.0
Positive	36	72.0
Total	50	100.0

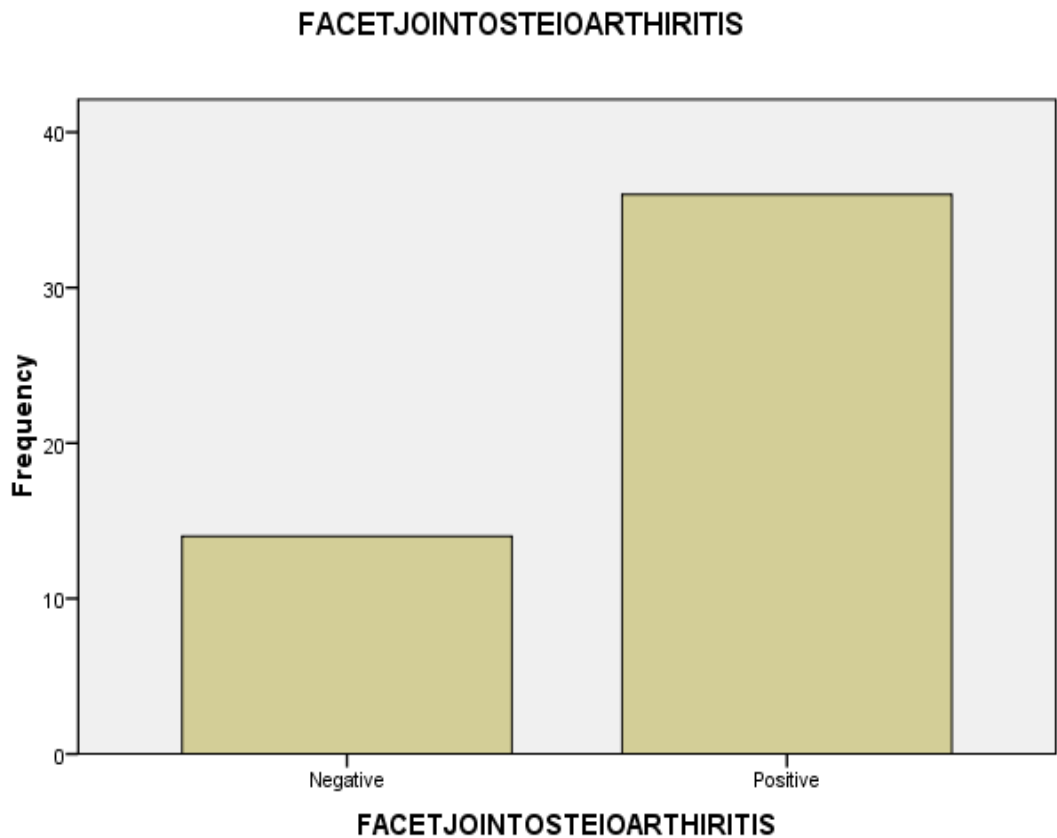


Figure 4-4. Show Facet joint osteoarthritis among the study sample

Table 4-5. Shows the relationship between the Facet joint osteoarthritis and age ,gender ,BMI and DDD among study sample

Facet joint osteoarthritis		AGE	GENDER	BMI	DDD
Negative	Frequency	14	14	14	14
	Percent	24.6%		26.3%	
Positive	Frequency	36	36	36	36
	Percent	75.4%		73.7%	
Total	Frequency	50	50	50	50
	Percent	100.0%		100.0%	

Figure 4-5. Show the relationship between the Facet joint osteoarthritis and age among the study sample

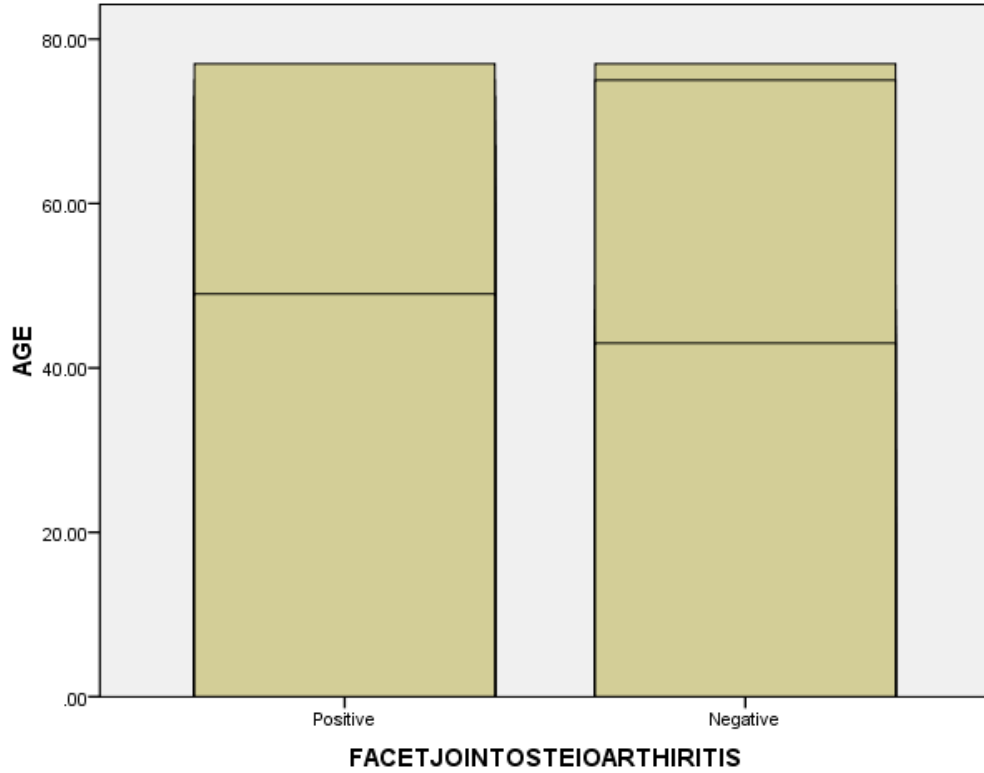


Figure 4-6. Show the relationship between the Facet joint osteoarthritis and gender among the study sample

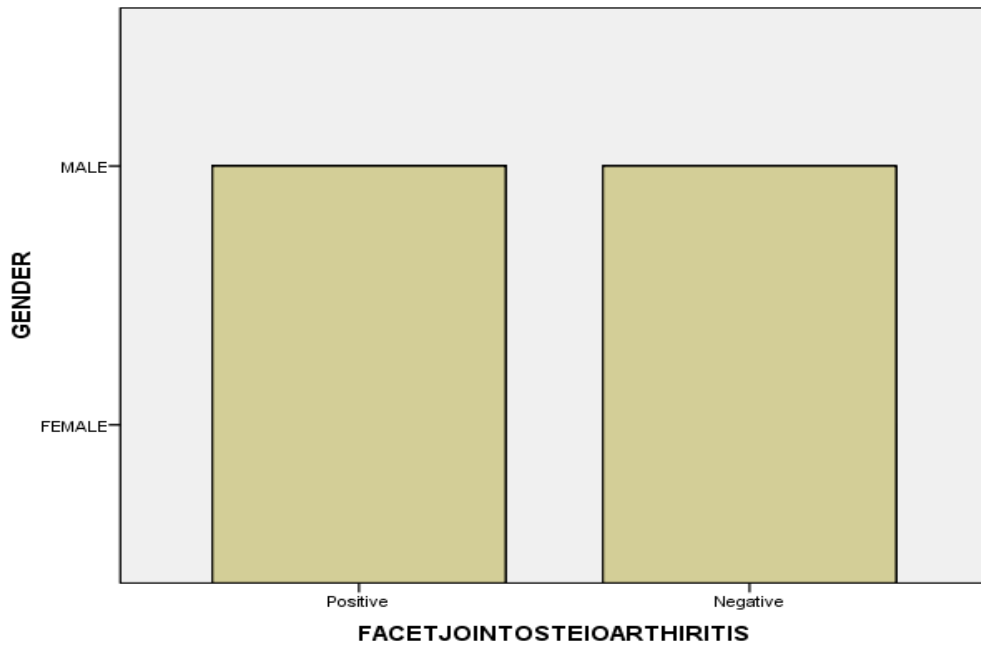


Figure 4-7. Show the relationship between the Facet joint osteoarthritis and BMI among the study sample

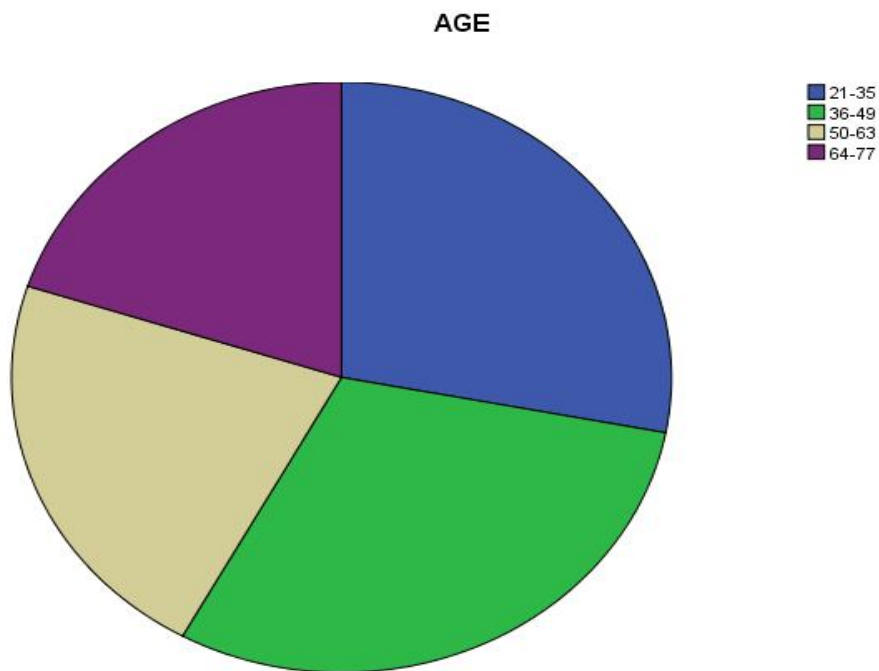
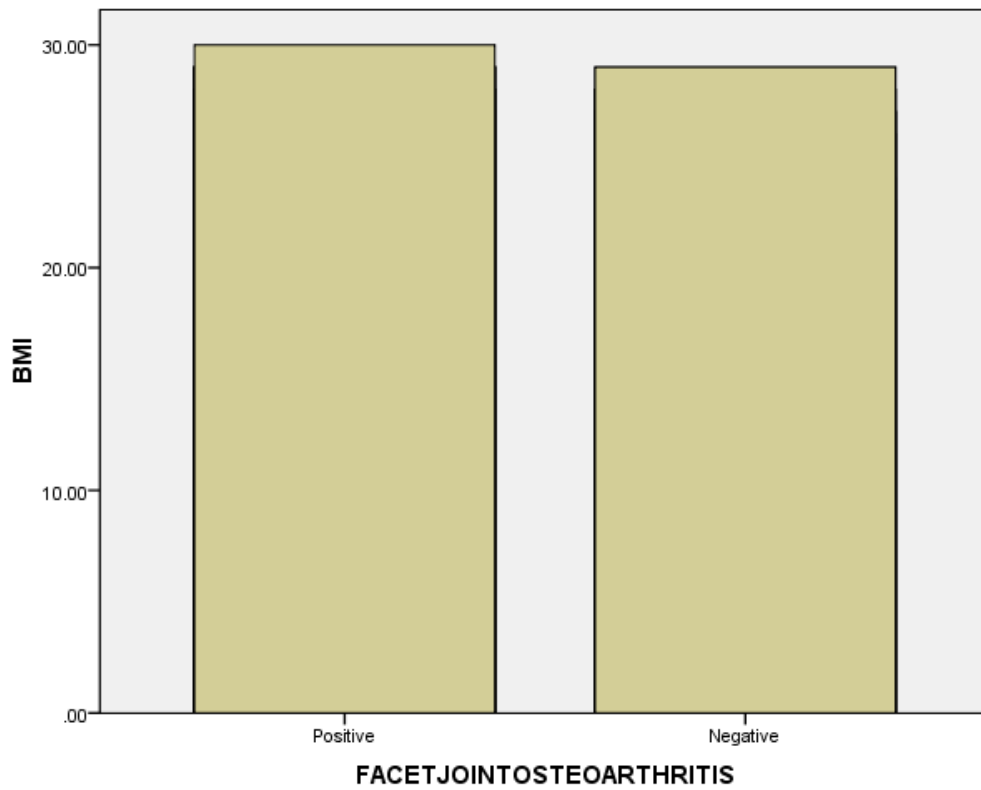


Figure 4-8: Pie chart explain affected patient by ages

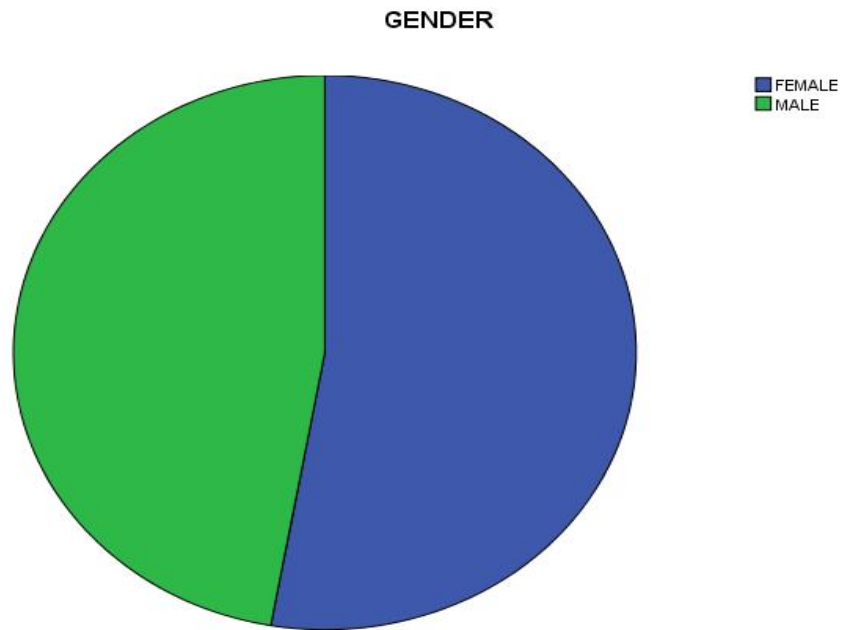


Figure 4-9: Pie chart explain affected patient by gender

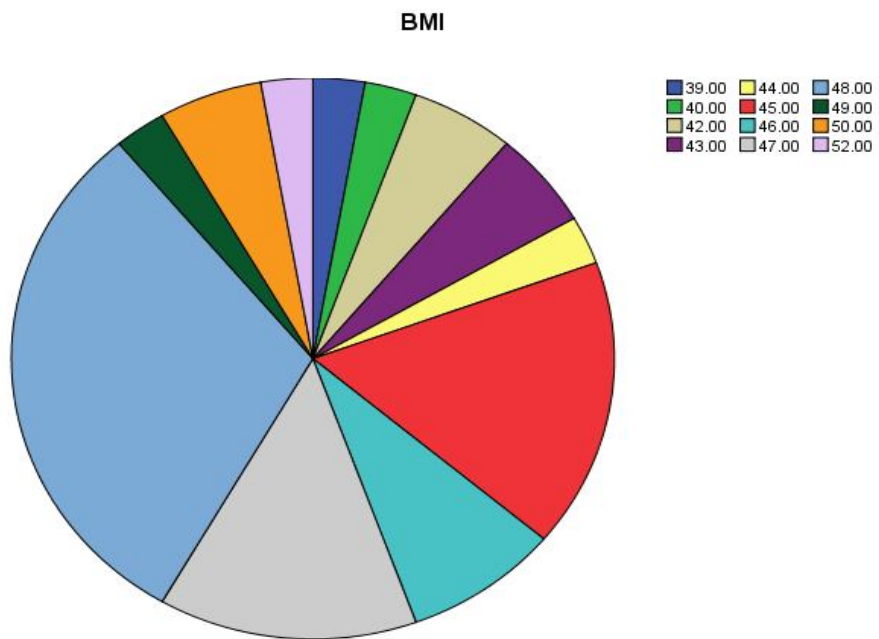


Figure 4-10: Pie chart explain affected patient by BMI

Chapter Five

Chapter Five

4-1.Discussion:

Accurate anatomic descriptions of vertebral anatomy are necessary for the diagnosis of various spinal diseases. In this study, MRI was used, which is considered the mainstay imaging investigation in patients suspected with lumbar spine disease.

Diagnose of lumbar spine facet joint osteoarthritis obtained from axial section of lumbar spine. The researcher found from result of images ,collected data from reports and patient that :

Table 4-1 and Figure 4-1 shows age group distribution among study sample. Table 4-2 and Figure 4-2 shows gender distribution among study sample. Table 4-3 and Figure 4-3 shows BMI distribution among study sample. Table 4-4 and Figure 4-4 Shows Facet joint osteoarthritis among study sample. Table 4-5 and Figure 4-5 shows Facet joint osteoarthritis among study sample.

Study showed that there a liner relationship between the Facet joint osteoarthritis and age, gender, BMI and DDD among study sample as described in table 4-6 from this researcher found that 24.6% of patient not affected and 75.4% affected according to age as described also in chart4-6. And 14 patient of both gender were not affected and 36 patient of both gender were affected as described also in chart 4-7. While 26.3% of patient not affected and 73.7% affected according to BMI as described also in chart 4-8. Also found that 14 DDD patients were not affected and 36 DDD patient were affected.

Also study found that:

Facet joint osteoarthritis affect wide range of ages from 21 to 77 as described in chart 4-10. Facet joint osteoarthritis more females than male as described in chart 4-1. Facet joint osteoarthritis affected people of BMI from 22 to 30cm²/kg as described in chart 4-12. Facet joint osteoarthritis mainly affect patient of DDD.

5-2. Conclusion:

- Facet joint osteoarthritis affect wide range of ages but most affected a people who's of age up to 45 years old.
- Facet joint osteoarthritis affects females more than males.
- Facet joint osteoarthritis affects people of BMI 27cm²\kg mostly.
- Patient with acute and chronic DDD were mostly affected with facet joint osteoarthritis according to reports collected.

5-3. Recommendations:

The researcher recommended for the following:

- The technologist should pay more attention and write more about facet joint of lumbar spine in their reports.
- More research should be done using a large samples of people for further assessment.
- Testing the suggested clinical diagnosis and patients with lumbar spine facet joint osteoarthritis from this research.

References:

- Aestin 2012. The facet joints or zygapophysial joints, zygapophyseal, apophyseal, or Z-joints definition .
- Bruno Di Muzio ,Dr Matt Skalski 2016. Degenerative disc disease (DDD)
- Centered Health and Wellness 2016. Arthritis
- Dan J Bell and Dr Jeremy Jones 2009. MRI
- Stephen Kishner, Maxim Moradian, Jan K Morello, Thomas R Gest, 2017 . Anatomy and physiology
- Fritz et al. 1998; Best, 2002; Gunzburg & Szpalski, 2003,J Neurosci Nurs. 2005 Lumbar Spinal Stenosis
- American Academy of Orthopaedic Surgeons. AAOS.1997-2017. Degenerative disc disease , Spondylolysis ,Spondylolisthesis
- Irvine Family Health Center Spinal Decompression , 2006- 2010. Bulging Disc
- Atsushi Fujiwara Kazuya Tamai Minoru Yamato Howard S. An Hiroyuki Gerald L. Burke. 2013. Herniated disc
- Mosby, Inc., an affiliate of Elsevier Inc.,2012. Tuberculous Osteomyelitis
- American Collage of Surgons , 1997.Spinal injury
- Gray. Henry ,1977. Trauma to the spinal column
- Gray's 2005.Compression fracturesBurst fractures , Flexion-distraction fracture Stable versus unstable fractures , Hyperlordosis of the spine
- Mosby, Inc., an affiliate of Elsevier Inc.,2012. (comprehensive Radiographic Pathology-fifth edition)
- Gellhorn et al. 2012. Facet joint disease
- Pooley,2005. Malcolm ,2002.Catherine Westbrook, etal -2011. MRI physics Catherine Westbrook. – 2008 . MRI Technique
- James RankineEmail authorPaul HarwoodPeter V. Giannoudis (2011) studied degenerative arthritis of the lumbar facet joints that has failed to respond to analgesia and conservative measures
- Beaman DN , Graziano GP , Glover RA , Wojtys EM , Chang V (1993) studied sixteen adult human lumbar spine facet joints were harvested from patients undergoing various lumbar spine procedures.
- Steven P. Cohen, M.D., Srinivasa N. Raja, M.D 2007. Lumbar facet joint osteoarthritis definition
- Stewart G Eielson, 1999- 2011The several common potential sources and causes of back pain (Clinical Radiology The Essentials. fourth edition), (comprehensive Radiographic Pathology-fifth edition) Developmental Abnormalities
- William Morrison, MD Brian Krans 2016.Computerized Tomography
- Yoshida Koichi Saotome Akira Kurihashi (1999) studied the role of MRI in assessing facet joint osteoarthritis

Appendix

Appendix A

MRI Report

Date: \ \
Age :

Patinent's Name:
Ref,Doctor:

Precedure :Lumbar spine MRI

Protocol: Sagittal T1,Sagittal T2& AxialT2

Report:

Conclusion:

Dr :.....

Consultant Radiologist

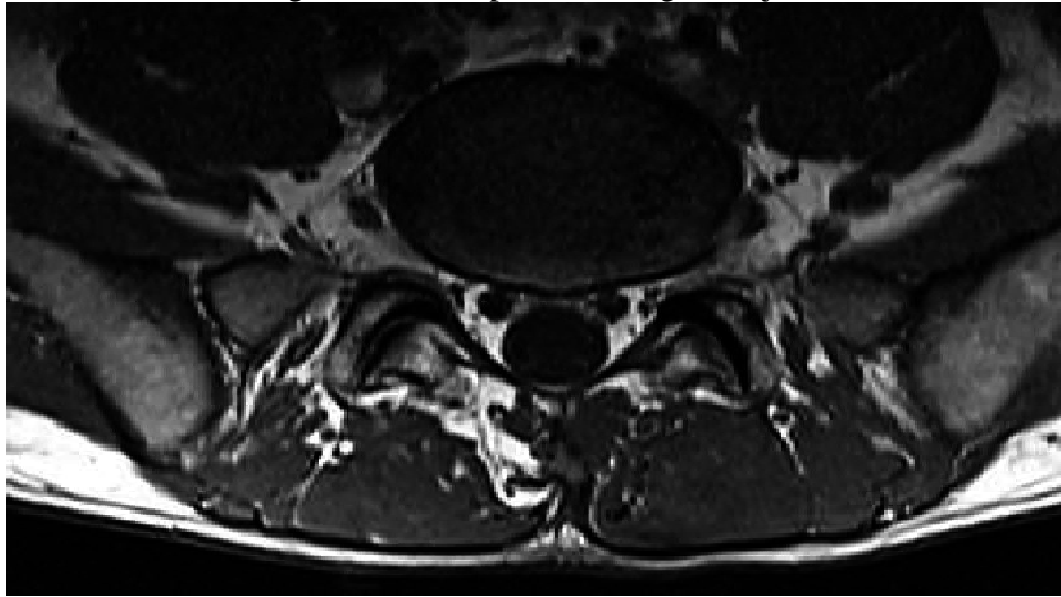
Appendix B
Data Collection Sheet

NO	DDD	Facet joint osteoarthritis	Gender	Age	Length	Weight
1						
2						
3						
4						
5						
6						
7						
8						
9						
10						
11						
12						
13						
14						
15						
16						
17						
18						
19						
20						
21						
22						
23						
24						
25						
26						
27						
28						
29						
30						
31						
32						
33						
34						
35						

.....						
50						

Appendix C

Axial T2 MRI image of lumbar spine showing facet joint osteoarthritis



Saittal T2 MRI image of lumbar spine showing multible DDD within lumbar spine discs

