

Sudan University Sciences and Technology
College of Graduate Studies

**Study of Lung Lesion Using High Resolution Computed
Tomography**

**دراسة امراض الرئه باستخدام الاشعه المقطعيه
المحوسبه فائقه الدقه**

*A thesis Submitted for Partial Fulfillment of the Requirement of MSc.
Degree in Diagnostic Radiologic Technology*

Prepared by: **Sabla Ahmed Abd Elhalim Elhaj**

Supervisor: **Dr. Asma Ibrahim Ahmed Elamin**

2017

الاية

بِسْمِ اللَّهِ الرَّحْمَنِ الرَّحِيمِ

قال تعالى:

قُلْ لَوْ كَانَ الْبَحْرُ مِدَادًا لِكَلِمَاتِ رَبِّي لَنَفَدَ الْبَحْرُ
قَبْلَ أَنْ تَنْفَدَ كَلِمَاتُ رَبِّي وَلَوْ جِئْنَا بِمِثْلِهِ مَدَدًا

صدق الله العظيم

الكهف الاية (109)

DEDICATION

TO THE SOUL OF MY FATHER

TO MY BELEVED KIND MOTHER

TO MY FAMILY

TO ALL KNOWLEDGE SEEKERS

I DEDICATE THIS WORK

ACKNOWLEDGMENT

First of all, I thank of Allah the almighty for helping me to complete this project, I would like to express my deep gratitude to my supervisor Dr. Asma Ibrahim Ahmed who's Encouragement, guidance and support for understanding of subject.

Abstract

The study was a retrospective study of Lung lesion using High Resolution CT . this study was conducted in Khartoum stat of Sudan in Yastabshroon hospital and Dar Eleilaj hospital from October 2016 to February 2017 ,the problem of the study was the overlapped of pathology with dense structures and when there is a very small lesion which difficult to demonstrate on radiography .also lack of knowledge of HRCT ,the study was aimed to demonstrate the HRCT of chest is the most accurate noninvasive imaging method of evaluating lung disease and has improved our understanding of the patterns and pathology of many pulmonary diseases ,the data was collected from 55 patients classified and analyzed using SPSS .The study found the most common clinical indication is cough (29.1%), the result was showed that the HRCT can diagnosis the most common causes of cough from TB (31.25%) , The most common finding in HRCT is normal result (21.8%).and males 32 (58.2%) were more affected than females 23(41.8%) the most age group affected was (53.5-65.5) with high percentage (25.5%) and the study conclude that there were main role of HRCT in diagnostic lungs disease ,all patient with the chest disease should undergo HRCT in order to detect the morphology and function of the lungs . the study was recommended that HRCT to detect lung disease in symptomatic patient with a normal chest radiograph .

المستخلص

هذه دراسة وصفية لدراسة امراض الرئة باستخدام الاشعة المقطعية المحوسبه فائقه الدقه تمت هذه الدراسة في ولايه الخرطوم بالسودان في كل من مستشفى يستبشرون ومستشفى دار العلاج في الفترة من اكتوبر 2016 حتي فبراير 2017 وتكمن مشكله الدراسه في التطابق ما بين الاجزاء التشريحيه الكثيفه والاعتلالات الدقيقه في صور الاشعه الروتينييه ,وايضا لقله الاحاطه المعرفيه بالاشعه المقطعيه المحوسبه فائقه الدقه .وقد هدفت الدراسه لتوضيح اهميه الاشعه المقطعيه المحوسبه عاليه الدقه في تشخيص امراض الرئه .وقد تم جمع البيانات من 55 مريض صنفتم وحللت نتائجهم باستخدام التحليل الاحصائي العلمي وقد وجدت الدراسه ان الكحة هي اكثر الاعراض السريرية (29.1%) وكان اكثر المسببات للكحة هو السل الرئوى بنسبة (31.25%) اظهرت لاشعة المقطعية المحوسبه عاليه الدقه ان الطبيعي هو الاكثر شيوعا (21.8%). عدد المرضى من الذكور 32 (58.2%) ومن الإناث 23 (41.8%) وكان اكثر افراد العينة من الفئة العمرية (55.5-65.5 سنة).

واظهرت هذه الدراسة ان الاشعة المقطعية المحوسبه فائقه الدقه هي افضل وسيلة تشخيصية للكشف عن امراض الرئة .واوصت هذه الدراسة ان المرضى الذين يشتكون من اعراض امراض الرئة ولم تبين الاشعة الروتينية المرض ان يجرو فحص الاشعة المقطعية المحوسبه فائقه الدقة .

Table of Contents

الاية	I
DEDICATION	II
ACKNOWLEDGMENT	III
Abstract	IV
الملخص	V
List of Abbreviation	IX
Chapter one: Introduction	
1.1 Introduction:	1
1.2 Problem of study:-	2
1.3 Objectives:-	2
1.3.1. General objectives:	2
1.3.2. Specific objective:	2
1.4 Thesis outlines:-	2
Chapter two Theoretical background	
2.1 Anatomy of lungs:-.....	4
2.1.1 The apex of the lung:-	5
2.1.2 The base of the lung:-.....	5
2.1.3 The root of the lung:-	5
2.1.4 The hilum of the lung:-.....	5
2.1.5 Lobes and fissures of the lung:-	5
2.1.6 Surfaces of the lung:-	6
2.1.6.1 The costal surface of the lung:-	6
2.1.6.2 The mediastinal surface of the lung:-	6
2.1.6.3 The diaphragmatic surface of the lung:-	6
2.1.7 Borders of the lung:-	6
2.1.8 Vessel of the lung:.....	7
2.2 PHYSIOLOGY:-.....	8

2.2.1 Function of respiratory system:-	8
2.2.2 Pulmonary ventilation:-.....	8
2.3 Lung pathology:-.....	9
2.3.1 Pediatric lung diseases:-	9
2.3.2 Adult respiratory distress syndrome (Diffuse Alveolar Damage):-.....	10
2.3.2.1 Desquamative interstitial pneumonitis (DIP):-	11
2.3.2.2 Lymphocytic interstitial pneumonitis (LIP):.....	11
2.3.2.3 Bronchiolitis literals organizing pneumonia (BOOP):	11
2.3.2.4 Tuberculosis:	11
2.3.2.5 Pulmonary edema:-	12
2.3.2.6 Lung cancer:.....	12
2.3.2.7Asthma:-	12
2.3.2.8 Emphysema:	13
2.3.2.9 Chronic bronchitis:-	13
2.3.2.10 Bronchiectasis:-.....	14
2.3.2.11 Bronchionlitisobliterans:-.....	14
2.3.2.12 Pulmonary fibrosis:-.....	14
2.3.2.13 Interstitial lung disease (I L D):-.....	15
2.3.2.14 Pleural Effusion:-	16
2.3.2.15 Consolidation:-	16
2.4 Imaging modalaties:	16
2.4.1 Type of chest CT scans:	16
2.4.2 High-resolution chest CT scan:.....	17
2.4.3 Spiral chest CT scan:.....	17
2.4.4 HRCT:-	17
2.4.5 HRCT technique:.....	19
2.4.6 Clinical indication for HRCT:.....	20

2.5 Previous studies:.....	22
Chapter Three: Materials & Methods	
3.1 Materials:.....	24
3.1.1 Area and Duration of the study :	24
3.1.2 Sampling:	24
3.1.3 Machine used:	24
3.2 Method:	24
3.2.1 Technique used:.....	24
3.2.2 Study design:	24
3.2.3 Data collection:	24
3.2.4 Data analysis method:	25
3.2.5 Inclusion and Exclusion Criteria:.....	25
3.2.6 Ethical Consideration:.....	25
Chapter four Result	
Results	26
Chapter Five Discussion, Conclusion and Recommendation	
5.1 Discussion	34
5.2 Conclusion:.....	36
5.3 Recommendations:	37
References	38
Appendix:	41

List of Abbreviation

ARDS	Adult respiratory distress syndrome
BOOP	Bronchiolitis literals organizing pneumonia
BPD	Broncho pulmonary dysplasia
Co2	Carbon dioxide
COP	Cryptogenic organizing pneumonia
CT	Computed tomography
DIP	Desquamative interstitial pneumonitis
HMD	Hyaline membrane disease
HRCT	High resolution computed tomography
ILD	Interstitial lung disease
LIP	Lymphocytic interstitial pneumonitis
O2	Oxygen
Po2	Partial pressure of oxygen
SOB	Shortness of breath
TB	Tuberculosis

Chapter one

Chapter one

1.1 Introduction:

High resolution computed tomography is a technique introduced in mid 1980 s result of significant improvement in the CT process and in computers. The technical aspects of high resolution CT have been described by a number of workers. There is no general agreements among investigations are possible in obtaining on optimal study. Quantification of the various morphological features of lungs diseases is possible from HRCT images and diseases. .(vined .1993)

High resolution computed tomography of chest is the most accurate non invasive imaging method of evaluating lung disease and has improved our understanding of the patterns and pathology of many pulmonary diseases. It gives us detailed images as we see when we look at a gross pathological specimen. Lungs are very important organs in the body, and as responsible of gases exchange and providing the body with oxygen which the body depend on. Diseases affecting the small airways of the lungs are difficult to detect by traditional diagnostic tests. Wide spread involvement is needed before symptoms and abnormalities on pulmonary function testing or chest radiograph become apparent. .(vined .1993)

Quantification of the various morphological features of lungs diseases is possible from HRCT images and diseases. HRCT usually involves sampling 1mm sections of lung at 10-15mm intervals, and examination on high spatial resolution algorithm with wide window width. HRCT is imaging modality of choice for the morphological assessment of lungs diseases with expellant spatial resolution. The trade-off in increased sensitivity and specificity of HRCT over chest radiography is related to radiation dose which is higher. However, conventional spiral computed tomography[CT] has an even higher radiation burden than HRCT. The use of low does [50ma-0,75]limited 1mm slices every

[10- 20mm]HRCT is inspiration with three expiratory supplementary scans , allows accurate assessment of the present and extent of diffuse lung diseases at dose equivalent to approximately 10-15 chest radiographs This compares to dose for volumetric chest CT [which acquires of whole spiral volume of lung].(vined .1993)

1.2 Problem of study:-

Chest radiography demonstrated most of chest pathology , but the main problem arise when there an overlapped of pathology with dense structures and when there is a very small lesion which difficult to demonstrate on radiography. Also lack of knowledge of HRCT

1.3 Objectives:-

1.3.1. General objectives:

The main objective of this study is study of lung lesion by high resolution computed tomography.

1.3.2. Specific objective:

To identify importance of high resolution computed tomography in diagnosing lungs disease.

To prove that lung pathologies can only be ruled out using the HRCT in modality of choice.

1.4 Thesis outlines:-

This study consists of five chapters, Chapter one, which is an introduction, deals with theoretical frame work of the study. It presents the statement of the study problems, objectives of the study, it also provides on outlines of the thesis.

Chapter two includes theoretical background material for thesis, and literature review (previous studies).

Chapter three deals with material and method used to evaluate diagnostic accuracy of HRCT of lungs disease.

Chapter four deal with (result) data presentation,
Chapter five discusses the data (discussion), analysis, conclusion,
recommendation, reference and appendix.

Chapter Two

Chapter two

Theoretical background

2.1 Anatomy of lungs

The lungs are the organs of respiration. They are large, conical shaped structures that extend up to or slightly above the level of the first rib at their apex And down to the dome of the diaphragm in their wide concave shaped bases. Two prominent angles can be identified at the medial and lateral edges of the lung bases. The medial angle is termed the cardiophrenic sulcus, and the lateral angle is termed the costophrenic sulcus the lungs are divided into lobes by thin structures called fissures the right lung has three lobes (superior {upper}, middle, and inferior} lower. (Snell,2000)

Whereas the left lung {upper}, middle, and inferior {lower}, whereas the left lung has just superior (upper) and inferior (lower) lobes. The left lung has large notch on its medial surface called the car disc notch on the medial surface of the lunge is on open in termed the haulm .the opening acts as a passage for main stem bronchi, blood vessels, lymph vessels, and nerves to enter the lung.(] . (Snell,2000)

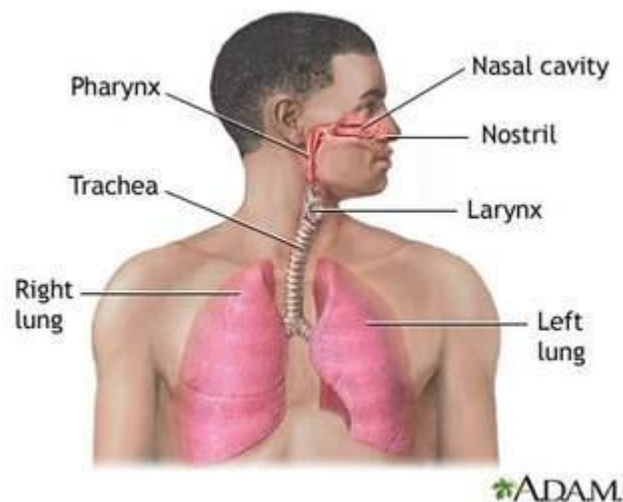


Figure 2.1 Internal anatomy of chest (martini et al 20006)

2.1.1 The apex of the lung:-

The round, tapered superior end or apex of the lung extends through the superior thoracic aperture into the root of the neck. Here, it lies in close contact with the dome formed by cervical pleura, called the capsule of the pleura. (Snell.,2000)

2.1.2 The base of the lung:-

This is the concave diaphragmatic surface of the lung, which is related to the dome of the diaphragm. The base of the right lung is deeper because the right dome rises to a more superior level. Its inferior border is thin and sharp where it enters the costodiaphragmatic recess. (Snell, 2000)

2.1.3 The root of the lung:-

The root serves as the attachment of the lung and is the highway for transmission of the structures entering and leaving the lung at the hilum. It connects the medial surface of the lung to the heart and trachea and is surrounded by the reflection of the parietal to the visceral pleura. (Snell.,2000)

2.1.4 The hilum of the lung:-

This is where the root is attached to the lung. It contains the main bronchus, pulmonary vessels, lymph vessels, bronchial vessels, lymph vessels and nerves entering and leaving the lung. (Snell.,2000)

2.1.5 Lobes and fissures of the lung:-

The lung is divided into lobes by fissures. The right lung has horizontal and oblique fissure, where the left lung has only one the oblique fissure. The left lung is divided into upper and lower lobe by a deep oblique fissure. The right lung is divided into upper, middle, and lower lobes by horizontal and oblique fissures, the horizontal fissure separates the upper and middle lobes and oblique fissure separates the lower from middle and upper lobes. The upper lobe is smaller than in the left lung, and the middle is wedge shaped. (Snell.,2000)

2.1.6 Surfaces of the lung:-

Each lung has three surfaces [costal, mediastinal, and diaphragmatic], which are named according to their relationships:

2.1.6.1 The costal surface of the lung:-

This surface is large, smooth, and convex. It is related to the costal pleura, which separates it from the ribs, their costal cartilages, and the innermost intercostals muscles. The posterior part of this surface is related to the thoracic vertebrae because of this area of the lung is sometimes referred to as the vertebral of the costal surface. (Snell.,2000)

2.1.6.2 The mediastinal surface of the lung:-

This medial surface is concave because it related to the middle mediastinum containing the pericardium and heart.

(Snell.,2000)

2.1.6.3 The diaphragmatic surface of the lung:-

This deeply concave surface often referred to as the base of the lung, rests on the convex dome of the diaphragm. The concavity is deeper in the right lung because of the higher position of the right dome. Laterally and posterior the diaphragm position surface is bounded by thin sharp margin that projects into the cost diaphragmatic recess of pleura. (Snell.,2000)

2.1.7 Borders of the lung:-

Each lung has three borders: anterior, posterior and inferior:

The anterior border of the lung:

This border is thin and sharp and overlaps the pericardium. There is an indentation in the anterior border of the left lung, called the cardiac notch. In each lung the anterior border separates the costal surface from the mediastinum surface.

The posterior border of the lung:-

This border is board and rounded and lies in the deep concavity at the side of the thoracic region of the vertebral Colum, called Para vertebral gutter. 8

The inferior border of the lung:-

This border circumscribes the diaphragmatic surface of the lung and separates the diaphragmatic surface from the costal surface. (Snell.,2000)

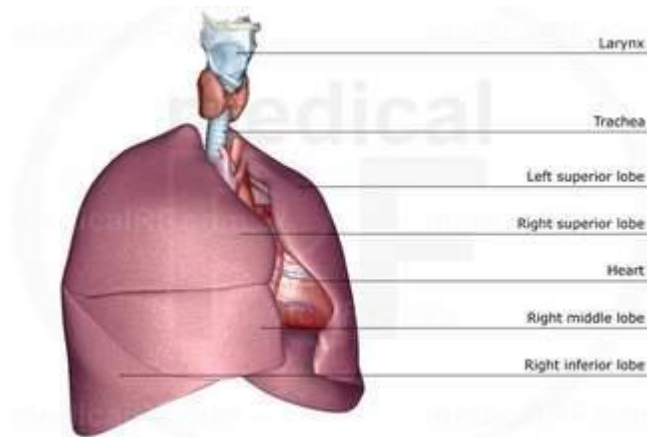


Figure 2:2 anatomy of lung (martini et al (2006))

2.1.8 Vessel of the lung:

2-1-8-1 Venous drainage of the lung:-

The pulmonary veins carry oxygenated blood from the lungs to the left atrium of the heart. Beginning in the pulmonary capillaries, the veins unite into the larger and larger vessels that run mainly in the interlobular septa. A main vein drains each bronchopulmonary segment, usually on the anterior surfaces of the corresponding bronchus. The two pulmonary vein on each side. Superior and inferior ones open in to the posterior aspect of the left atrium. The superior right pulmonary vein drains the superior and middle lobe of the left lung. The right and left inferior pulmonary veins drain the respective inferior lobes.(Snell,2000)

2.2 Physiology:-

2.2.1 Function of respiratory system:-

Through breathing and exhalation, the respiratory system facilitates the exchange of gases between the air and the blood and the blood and the body cells. The respiratory system also helps us to smell and create sound. (Tortora,1987)

2.2.1.1 Respiration:-

The principal purposes of respiration are to supply the cells of the body with oxygen and remove the carbon dioxide produce by cellular activities. They three basic processes of respiration are pulmonary ventilation, external respiration, and internal respiration. (Tortora,1987)

2.2.2. Pulmonary ventilation:-

Pulmonary ventilation [breathing] is the process by which gasses are exchange between atmosphere and lung alveoli. (Tortora,1987)

2.2.2.1 Mechanism of inspiration:-

Contraction of aspiratory muscles, expansion of the chest, reduction of intra pleural pressure, expansion of the lung, reduction of intra pulmonary pressure and then air move in to the lung. (Tortora,1987)

2.2.2.2 Mechanism of expiration:-

Relaxation of insoiratory muscles, increased intrapleural pressure, recoil of the lungs s to the expiratory position, increased intra alveolar pressure and then move out of the lung. (Tortora,1987)

2.2.2.3 External respiration:-

It result in the conversion of deoxygenated blood (more co₂ than o₂) coming from the heart to oxygenated blood (more o₂ than co₂) resulting to the heart. The po₂ of alveolar air is 105mmHg. The po₂ of deoxygenated blood is 40mmHg. As the result of different in po₂ oxygen diffuse from alveoli in to the

deoxygenated blood unit equilibrium is reached and the pO_2 of the new deoxygenated blood is 105mmHg.

The pCO_2 of alveoli air is 40mmHg. The pCO_2 of deoxygenated blood is 45mmHg. As the result of this different of the pCO_2 , CO_2 diffuses from deoxygenated blood to the alveoli unit equilibrium is reached pO_2 and pCO_2 arriving the lungs are the same in alveolar air. (Tortora,1987)

2.2.2.4 Internal respiration:-

As soon as external respiration is completed, oxygenated blood leaves the lungs through the pulmonary veins and returns to the heart. From here it is pumped from the left ventricle into the aorta and through the systemic arteries to tissue cells. The exchange of the oxygen and carbon dioxide between tissue and blood capillaries and tissue cells is called internal respiration.

(Tortora,1987)

2.3 Lung pathology:-

2.3.1 Pediatric lung diseases:-

2.3.1-1 Hyaline membrane disease (HMD) or respiratory distress syndrome (RDS):-

Main etiological factors include prematurity with relative lack of surfactant, oxygen toxicity and barotraumas. Prophylactic and therapeutic use of surfactant has dramatically decreased morbidity and mortality; grossly the lungs are red, consolidated and hypercrepitant; the microscopic hallmark is the formation of pink, cellular membranes lining the terminal and respiratory bronchioles and alveolar ducts. These are formed by necrosis of epithelium, exudation of plasma proteins, and, if there is hemorrhage, fibrin; hyaline membranes are only seen in the live born, and are well –developed by 12-24hrs. By 36-48 hours the reparative phase begins and the membranes are either completely resolved with

minimal squealed or there is varying degree of fibrosis and loss of alveoli (BPD).(Bokulic,1994)

2.3.1-2 Bronchopulmonary dysplasia (BPD):-

This is divided into acute, reparative and healed phase. The main features are bronchiolar and interstitial fibrosis of more damaged acini; these patients have limited pulmonary reserve and develop repeated infections. There is often significant pulmonary hypertension which leads core pulmonale. (Bokulic,1994)

2.3.1-3 Pulmonary hyoplasia:-

Unilateral or more often bilateral defective development of lung which is fatal, the lung weight is less than normal and there are fewer alveoli than expected for gestational age; causes include prolonged 12

oligohydraminos (renal agenesis, rupture of membrane), decreased intrathoracic space (renal cystic diseases, diaphragmatic hernia), and decreased breathing movements (anencephaly, muscular-skeletal disorder)).(Bokulic,1994)

2.3.2 Adult respiratory distress syndrome (Diffuse Alveolar Damage):-

ARDS is the end result of acute alveolar injury caused by a variety of insults and probably initialed by different mechanism. The initial injury is to either the capillary endothelium or alveolar epithelium. There is increased capillary permeability, interstitial and then alveolar edema, fibrin exudation and formation of hyaline membranes. Organization and scarring follows; the capillary defect is produced by an interaction of inflammatory cells and mediators, including leucocytes, cytokines, oxygen radicals, complement and arachidonate metabolites, that damages the endothelium and allow fluid and proteins to leak. End toxin, neutrophils and macrophages may also play key roles in the pathogenesis of ARDS. (Ieslie,2004)

2.3.2.1 Desquamative interstitial pneumonitis (DIP):-

The lung architecture is preserved with minimal to moderate interstitial fibrosis; most air spaces are filled by macrophages with fine granular pigment; the above finding are uniform throughout the lung; may cases of DIP progress with increasing fibrosis and eventually are distinguishable from UIP. . (Ies li,.2004)

2.3.2.2 Lymphocytic interstitial pneumonitis (LIP):

There is intense infiltrate of interstitial diffusely; the infiltrate is composed of lymphocytes, plasma cell and histolytic, which are polyclonal; LIP may represent early grade well-differentiated lymphoma. LIP is associated with autoimmune diseases. . (Ieslie,2004)

2.3.2.3 Bronchiolitis literals organizing pneumonia (BOOP):

Also known as "cryptogenic organizing pneumonia" in the British literature, this disease is characterized by granulation tissue plugs. With the lumen of small airways and extending into alveolar ducts and alveoli .mason bodies are rounded balls of myxomatous (bluish) connective tissue that form intraluminal polyps within bronchioles and air space, the diagnosis of idiopathic BOOP should only may be made after careful consideration of clinical and radiological features since the histological picture of BOOP can be seen in several condition e.g. . Pulmonary infection, organization DAD, obstruction, hypersensitivity pneumonia, drug reaction . (Ieslie,2004)

2.3.2.4 Tuberculosis:

The histological hallmark is cossetting granulomata with langhan, s type giant cells. The granuloma is a rounded collection of macrophages and lymphocytes containing multinucleated giant cells, the nuclei of which are arranged at the periphery in a horse-shoe shape; Acid bacilli can sometimes be demonstrated by the Zehil-Neelson stain on tissue has a much high incidence of large areas of

case ting necrosis. Otherwise, primary and secondary TB is histological similar. (Lynch,1990)

2.3.2.5 Pulmonary edema:-

Pulmonary edema is a condition caused by excess fluid in the lungs. This fluid collects in the numerous air sacs in the lungs, making it difficult to breathe.

In the most cases, heart problems cause pulmonary edema. But fluid can accumulate for other reasons, including pneumonia, exposure to certain toxins and medications, trauma to the chest wall, and exercising or living at the high elevations.

Pulmonary edema that develop suddenly (acute pulmonary edema) is a medical emergency requiring immediate care. (Lynch,1990)

2.3.2.6 Lung cancer:

Lung cancer is a type of cancer that begins in the lungs. Lung cancer is leading cause of cancer death, claims more lives each year than do colon, prostate, ovarian and breast cancers combined.

People who smoke have the greatest risk of lung cancer. The risk of lung cancer increases with the length of time and number of cigarettes smoked. If you quit smoking, even after smoking for many years, you can significantly reduce your chances of developing lung cancer. Lung cancer typically doesn't cause signs and symptoms in its earliest stages. Sign and symptoms of lung cancer typically occur only when the disease is advanced. Sign and symptoms may include coughing up blood, even a small amount, shortness of breath, chest pain, wheezing, loss of weight, bone pain and headache. (Lynch,1990).

2.3.2.7 Asthma:-

Asthma is chronic disease involving the airways in the lungs. These airways, or bronchial tubes, allow air to come in and out of the lungs. If you have asthma your airways inflamed. They become even more swollen and muscles around the

airways can tighten when something triggers your symptoms. This makes it difficult for air to move in and out of the lungs, causing symptoms such as coughing, wheezing, shortness of breath and chest tightness.

People with family history of allergies or asthma are more prone to developing asthma. Many people with asthma also have allergies. This is called allergic asthma. Occupational asthma is caused by inhaling fumes, gases, dust, or other potentially harmful substances while on the job. (Ieslie,2004)

2.3.2.8 Emphysema:

This is defined as abnormal, permanent enlargement of air spaces distal to the terminal bronchioles, due to destruction of alveolar walls and without fibrosis. It is classified as follows:

- centriacinar emphysema involves primarily the respiratory bronchioles and is the most common type. It is the type seen in cigarette smokers.
- Panacea emphysema involves the entire acinus. It is one-twentieth as common as centriacinar emphysema. It is the type seen in alpha 1- antitrypsin deficiency.
- Parietal emphysema involves the distal part of the lobule. Extensive involvement of the lung is rare. Some cases of spontaneous pneumothorax may be due to this type of emphysema,
- Irregular emphysema is associated with scarring and has no particular relationship to the acinus.
- Bulbous emphysema, by definition, is composed of lesion greater than 1cm. in diameter, and can be associated with any type of emphysema.
- A bleb is a localized pocket of interstitial emphysema, typically sub pleural, with no destruction of lung tissue. (Ieslie,2004)

2.3.2.9 Chronic bronchitis:-

These histological features are chronic inflammation of bronchi with hyperplasia of goblet cells and mucous glands. The Reid index measures the gland to wall

ratio (normally glands are one_ third of wall thickness as measured from epithelial basement membrane to cartilage).

(Ieslie,2004)

2.3.2.10 Bronchiectasis:-

The airways are abnormally and permanently dilated with variable amount of mucus and inflammation. Superimposed infection may be present e.g., aspergillosis.

- In cystic fibrosis the changes are diffuse often with green yellow mucous impaction.
- In kartagener, s sundrome, lack of dieninarms in cilia can be seen by electron microscopy.
- Post-infectious bronchiectasis may be localized or diffuse depending on location and extent of primary disease.(Lynch,1990).

2.3.2.11 Bronchionlitisobliterans:-

This is afibrosing disease of small airways which are defined as less then 2mm.hn diameter. There is luminal obstruction by inflammatory and fibrotic changes. (Lynch,1990).

2.3.2.12 Pulmonary fibrosis:-

Pulmonary fibrosis is one of a family of related interstitial lung diseases that can result in lung scarring. Tissue deep in the lungs becomes thick, stiff and scarred. The scarring is called fibrosis. As the lung tissue becomes scarred, it interferes with a person ability to breathe.

In some cases, the cause of pulmonary fibrosis can be found. But most cases of pulmonary fibrosis have no known cause. These causes called idiopathic pulmonary fibrosis.

In pulmonary fibrosis the tissue inside and between the air sacs in the lungs becomes scarred. When the scarred forms, the tissue become stiff and thicker.

This makes it harder for oxygen to pass through the walls of the air sac into the bloodstream. Once the lung tissues become scarred, the damage cannot be reversed. (Lynch,1990).

2.3.2.13 Interstitial lung disease (I L D):-

Interstitial lung disease is a general category that includes many different lung conditions. All interstitial lung diseases affect the interstitium, a part of the lungs' anatomic structure.

The interstitium is a lace-like network of tissue that extends throughout both lungs. The interstitium provides support to the lungs' microscopic air sacs (alveoli). Tiny blood vessels travel through the interstitium, allowing gas exchange between blood and the air in the lungs. 18

Normally, the interstitium is so thin it can't be seen on chest x-ray and ct scans.

Interstitial lung disease causes thickening of interstitium. The thickening can be due to inflammation, scarring, or extra fluid (edema). Some forms of interstitial lung disease are short lived; others are chronic and irreversible. (Lynch,1990).

Some of the types of interstitial lung disease include:-

Interstitial pneumonia: bacteria, viruses, or fungi may infect the interstitium of the lung. A bacterium called *Mycoplasma pneumoniae* is most common cause.

Idiopathic pulmonary fibrosis:-chronic, progressive form of fibrosis of interstitium. Its cause is unknown.

Non-specific interstitial pneumonitis: interstitial lung disease that often presents with autoimmune conditions such as rheumatoid arthritis or scleroderma.

Hypersensitivity pneumonitis: interstitial lung disease caused by ongoing inhalation of dust, mold, or other irritants.

Cryptogenic organizing pneumonia (COP): Pneumonia like interstitial lung disease but without an infection present. COP is also called bronchiolitis obliterans with organizing pneumonia (BOOP)

Sarcoidosis: a condition causing interstitial lung disease along with swollen lymph nodes, and sometimes heart, skin, nerve, or eye involvement.

Asbestosis: interstitial lung disease caused by asbestos exposure. (Lynch,1990).

2.3.2.14 Pleural Effusion:-

A pleural effusion is an abnormal amount of fluid around the lung. In pleural effusion, fluid accumulates in the space between the layers of pleura. Normally, only teaspoons of watery fluid are present in the pleural space, allowing the lungs to move smoothly within the chest cavity during breathing. Numerous medical conditions can cause pleural effusion like congestive heart failure, pneumonia, liver cirrhosis, cancer pulmonary embolism.

Excessive fluid may accumulate because the body does not handle fluid properly such as liver and kidney disease. The fluid in pleural effusion also may result from inflammation.

Pleural effusion often no symptom. Symptoms are more likely when a pleural effusion is moderate or large-sized, or if inflammation is present. (Lynch,1990).

2.3.2.15 Consolidation:-

Consolidation of the lung is simply a "solidification" of the lung tissue due to accumulation of solid and liquid material in the air space that would have normally been filled by gas. It is also known as pulmonary consolidation. The most common cause of consolidation is pneumonia; inflammation of the lung as cellular debris, blood cells and exudates collects in the alveoli of the lung. (Ies li,2004)

2.4 Imaging modalities:

2.4.1 Type of chest CT scans:

A CT scanner is a large machine with a tunnel-like hole in the center. During a chest CT scan, a person lies on a table as it moves small distances at a time through the hole. An x-ray beam rotates around the body as the person moves

through the hole. A computer takes data from the x-rays and creates a series of picture, called slices, of the inside of the chest. Different types of chest CT scans have different diagnostic uses. (Lynch,1990).

2.4.2 High-resolution chest CT scan:

High- resolution CT (HRCT) scans provide more than one slice in a single rotation of the x-ray tube. Each slice is very thin and provides a lot of details about the organs and other structures in the chest. (Lynch,1990).

2.4.3 Spiral chest CT scan:

For this scan, the table moves continuously through the tunnel-like hole as the x-ray tube rotates around the individual. This allows the x-ray beam to follow a spiral path. The machines computer can process the many slices into a very detailed, three dimension (3D) pictures of the lungs and other structures in the chest. (Lynch,1990).

2.4.4 High Resolution Computed Tomography :-

Scan of the chest always include slides of the superior liver. In an oncology setting, it is not uncommon for unsuspected liver metastases to be discovered on the lowest slices of the chest CT scans. Finding unsuspected liver metastases occurs more frequently than missing significant mediastinal lesions. This is especially true in breast cancer.

Furthermore, as part of the natural history of patient with cancer, a patient who initially only needed a CT of the chest, will likely need CT of the abdomen in suspected months, and when they do, it is helpful to have comparable previous CT scan. Therefore, we believe (at the cross cancer institute) that the timing of contrast injection for chest ct scans, should be optimized for liver diagnosis, in preference to optimizing for mediastinal diagnosis (which is relatively unaffected by altering the timing of contrast injection). (Lynch,1990).

The scanning direction is superior-to-inferior, starting one or two slices above the top of the lungs. The speed of the scanner and the slice thickness used will influence the amount of time it takes to scan down to the top of the liver. When the scanning reaches the liver, it is desirable to have the time elapsed (since injection began) be in the range of 60_70 seconds, which is typically suggested for portal – venous- phase imaging. The length of the chest varies slightly with body weight, so the time it takes to scan the chest varies slightly with body weight. However, slice thickness make a difference. On our scanner, when 8mm thick slice were used, the average time to the scan the scan the chest was 17.9 second, compared to 14.3 seconds when 10mm thick slices were used. (Using a spiral scanner with 1.0secs per revolution, 1.5cm per second (1.5 pitch).) When using 8mm thick slices, it takes on average 17.9 seconds to scan the chest, plus or minus a standard deviation of 2.59 seconds. This population standard deviation indicates inter-patient variability, whereby some patients have shorter length chests, and some have longer chests. Knowing that 90% of the population is included within $+_{-1.96*}$ standard deviation, i.e. 5.08 seconds variability, the chest protocol was constructed with 5 seconds "padding". To put this theory into practice, the chest protocol scan delays were constructed as follows:

Step 1: using 88mm slices, it takes about 17.9 seconds to scan the average chest. To accommodate short chests, subtract 5.08 seconds. Thus 12.82 seconds is the minimum time needed to scan the chest. (Lynch,1990).

Step 2: depends on the weight group. For 64-77g, if the goal is to start scanning the top of the liver at minimum earliest of 62 seconds, subtract 12.82, and start scanning at the top of the chest after 49 seconds delay for injection. What this accomplishes is that even the short-chest patient should start liver scanning at about 62 seconds, and the average patient should start scanning the liver about 67 seconds. (Lynch,1990).

Step 3: repeat step 2 for each weight category, substituting the desired minimum scan delays to start liver scanning in to the formula. (Lynch,1990).

2.4.5 HRCT Technique:

To understand the advantages of HRCT, it is necessary to discuss the technique currently in use for obtaining high quality thin-section images of the lung parenchyma. HRCT relies on the use of thin collimation and image reconstruction with a high spatial frequency algorithm. In most scanner system, 1 to 1.5 mm collimation can be obtained and should be used routinely for HRCT. Five to eight slices with thin collimation should be obtained at different anatomic levels of the lung. Currently, there is no standard recommendation with regard to the use of a 1 cm, 2 cm, or 3 cm intersection gap. Scanning should be performed using a field of view large enough to encompass both lungs (35-40 cm). Retrospective targeting of the image reconstruction to a single lung or an even smaller portion of the pulmonary parenchyma increases spatial resolution, but, in most cases, does not add additional information. For 23 image photography, one should keep in mind that larger images are generally much easier to read. We, therefore, use a 6 on 1 format. It should be emphasized that although the manner in which images are photographed does not affect the actual spatial resolution of an image, the use of proper settings for window level and width is important for accurate interpretation. Currently, there are no "correct" window settings for image photography. Nevertheless certain window setting have gained acceptance throughout the radiological community. It is advantageous to use a double window with one window setting at -450/1,500 hounsfield units and a "lung density" window of -700/1,000 hounsfield units. Choosing different window levels and widths can be advantageous for specific cases. Because numerous patients demonstrate increased densities in the dependent portion of the lung, representing hypostasis and/or atelectasis, it is

wise to evaluate patients not only in the supine position but also in the prone position to differentiate physiological densities from signs of diffuse lung disease. In general, HRCT images are obtained at full inspiration. In patients with suspected airway disease, additional ct scans should be obtained during expiration to facilitate detection of air trapping. The radiation does associated with HRCT scans is significantly less that associated with conventional CT. with HRCT, the mean skin radiation dose for scanning at 10 mm intervals is around 4 mGY, and for scanning at 20 mm intervals, around 2 mGY , respectively. (Lynch,1990).

2.4.6 Clinical indication for HRCT:

When describing the indications for HRCT, it is important to note the plain chest radiograph is an indispensable part of the diagnostic evaluation of patients with suspected lung disease. However, because of the described limitations of plain film, the use of HRCT is indicated in the following instances:

- detection of lung disease
- characterization and specification of diffuse infiltrative lung disease
- Evaluation of disease activity
- Evaluation before biopsy
- Assessment of focal lung disease

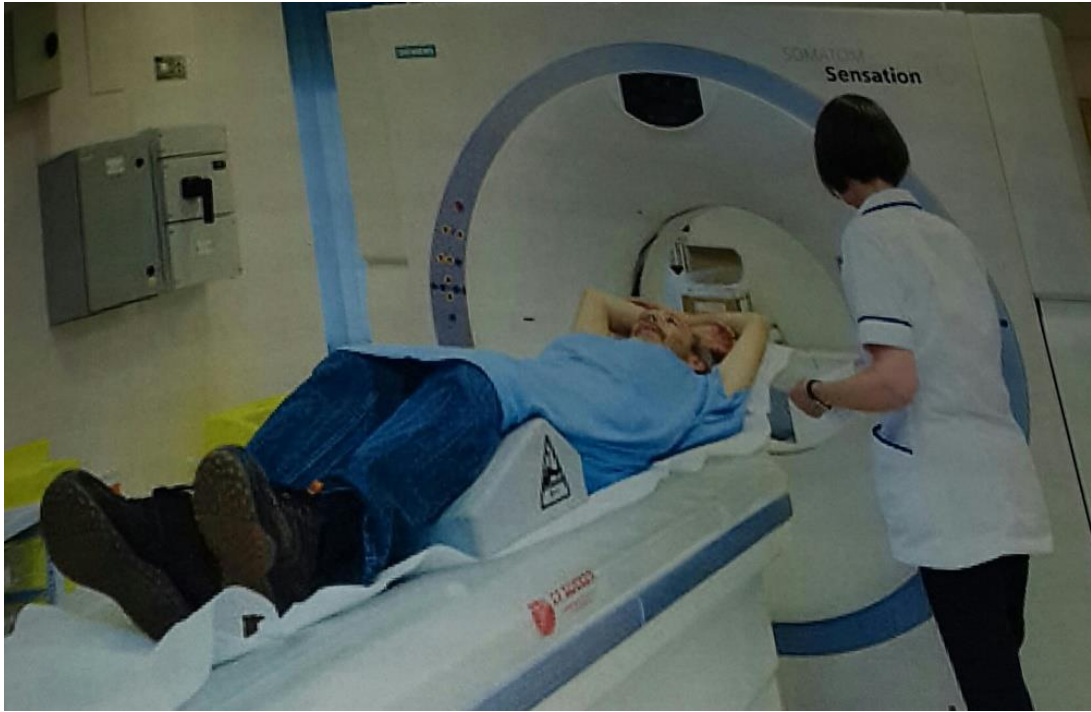

Figure 3.1 CT chest position

2.5 Previous studies:

Pingile BK et.al(2016) Role of high resolution computed tomography in evaluation of diffuse lung diseases . The aims and objectives was to study the normal anatomy of the lung with respect to secondary pulmonary lobule; to evaluate the importance of high resolution computed tomography in the diagnosis of diffuse lung diseases; to detect diffuse lung diseases in patients who had normal or questionable radiographic abnormalities with symptoms or pulmonary function tests suggestive of diffuse lung disease; to determine the site of CT guided lung biopsy for confirmation of diagnosis in suspicious diseases and to study the various patterns of diffuse lung diseases on HRCT. Methods: A total number of 50 patients with suspected or known interstitial lung disease were studied by high-resolution computed tomography (HRCT) over a period of 24 months. Results: In the current study the most common cases are of tuberculosis. Next common condition observed was idiopathic pulmonary fibrosis,12 (24%) cases out of 50 cases and most of them were having changes of end stage lung disease and had short lived history during the course of this study, followed by bronchiectasis, pulmonary edema and emphysema. Conclusions: HRCT is 16% more sensitive in detection of diffuse lung disease abnormalities than chest radiograph in our study.

Prasanna R et al (2017) Role of High Resolution Computed Tomography in Evaluation of Diffuse Parenchymal Lung Diseases The present study was undertaken to detect and study the profile of computed tomographic (CT) patterns of diffuse parenchymal lung diseases. Methodology: The present study comprised of 60 patients of DPLD. Patients were evaluated by CT scan in Department of Radio -diagnosis from October 2014 to October 2016. Pregnant women and diagnosed cases of tuberculosis (sputum positive) were excluded . Results: The most commonly identified diffuse parenchymal lung disease was idiopathic interstitial pneumonia (26.7%) followed by tuberculosis and post tubercular disease (16.7%) of the total cases. Conclusion: Diffuse parenchymal lung diseases commonly occur in the middle age, the presenting complaint being unremitting dyspnea of long duration in most of the cases. Idiopathic interstitial pneumonia forms the major group of diffuse parenchymal lung diseases in our society. The extent and distribution of disease identified on HRCT scans correlates well with the clinical impairment.

FATIH, ORS, et.al (2013) Chest x-ray has several limitation in detecting the extent of pulmonary disease in sarcoidosis. It might not reflect the degree of pulmonary involvement in patients with sarcoidosis when compared to compute tomography of the thorax. We aimed to investigation the HRCT finding of pulmonary sarcoidosis and to find out the existence of possible relations between HRCT finding and PFTs. In addition, we aimed investigate the accordance between HRCT findings and conventional chest x-ray staging of pulmonary sarcoidosis. 45 patients with sarcoidosis, six of them were female and 39 were male. Nodule, micro nodule, ground glass opacity and consolidation were the most common HRCT finding. Pulmonary sarcoidosis patients might various

pulmonary parenchyma changes on HRCT. Thorax HRCT was superior to chest x-ray in detecting pulmonary abnormalities. The degree of pulmonary involvement might closely related to the loss of pulmonary function measured by PFTs. Chest x-ray is considered to have a role in the evaluation of pulmonary sarcoidosi.

JONATHAN B, et.al (1995) these study done to assess the sensitivity of high resolution chest computed tomography (HRCT) in detecting idiopathic pulmonary fibrosis proved by biopsy specimen. To determine the degree of physiologic and pathologic abnormalities in patients with idiopathic pulmonary fibrosis who have a false-negative HRCT. All patients underwent physiologic and pathologic assessment. The result of HRCT was prospectively compared with the result of standard pulmonary functions test. Of 25 patient who had both HRCT and open lung biopsy.

In our patient's population, physiological test was more sensitive than HRCT in detecting mild abnormalities in patients with idiopathic pulmonary fibrosis proved by biopsy specimen.

P.A.de Jong, et.al (2004) for effective clinical management of cystic fibrosis lung disease it is important to closely monitor the start and progression of lung damage. The aim of this study was to investigate the ability of high resolution computed tomography (HRCT) and PFTs to detect lung disease. This study done for 48 patients had two HRCT scans in combination with PFTs 2 yrs apart. These data show that HRCT is more sensitive than pulmonary function test in the detection of early and progressive lung disease, and suggest that the high resolution computed tomography may be useful in the follow up of cystic fibrosis as an outcome measure in studies that aim to reduce lung damage.

Chapter Three

Chapter Three

Materials & Methods

3.1 Materials:

3.1.1 Machine used:

- 1 .CT machine in Yastabshroon Hospital . Toshiba scanner (Tsx-032A)Toshiba (16slice). Slice sickness (2mm).
2. CT machine in Darelelaj Hospital .Philips slice (64), slice sickness (.9), gab (.45).

3.2 Method:

3.2.1 Technique used:

Patient position: supine arms elevated above head, feet first or head first.

Topogram AP: from lung apices to below diaphragm.

Breathing: breath hold in inspiration (single breath hold).

Technical parameters: pitch 1, slice thickness2 mm (.9mm) lesions.

Filming parameters: soft tissue window and lung window.

For demonstration of lung nodules or inflammation low dose protocol without contrast enhancement is recommended.

3.2.2 Area and Duration of the study :

This study is performed in Department of Radiology in yastabshroon and dar el elaje hospitals in Khartoum state, in period from (october2016- February 2017)

3.2.3 Study design:

This study was designed to evaluate diagnostic accuracy of thin section CT of lungs disease.

3.2.4 Sampling:

This study included 55subjects were selected from patient referred chest CT, 32male (58.2%).23 female(41.8%). Age from (5-90 years)

3.2.5 Data collection:

Used data collection sheet.

3.2.6 Inclusion and Exclusion Criteria:

The study will include all patients with the CT chest.

3.2.7 Data analysis method:

The use of descriptive analytical method using SPSS statistical program based cross chart and graphs to demonstrate the possibility of the diagnosis.

3.2.8 Ethical Consideration:

There was official written permission state diagnostic centers to take the data.

No patients data were published, also the data was kept in personal computer with personal password.

Chapter four

Chapter four Result

Table (4.1) represents gender distribution

sex	Frequency	Percent
male	32	58.2%
female	23	41.8%
Total	55	100.0%

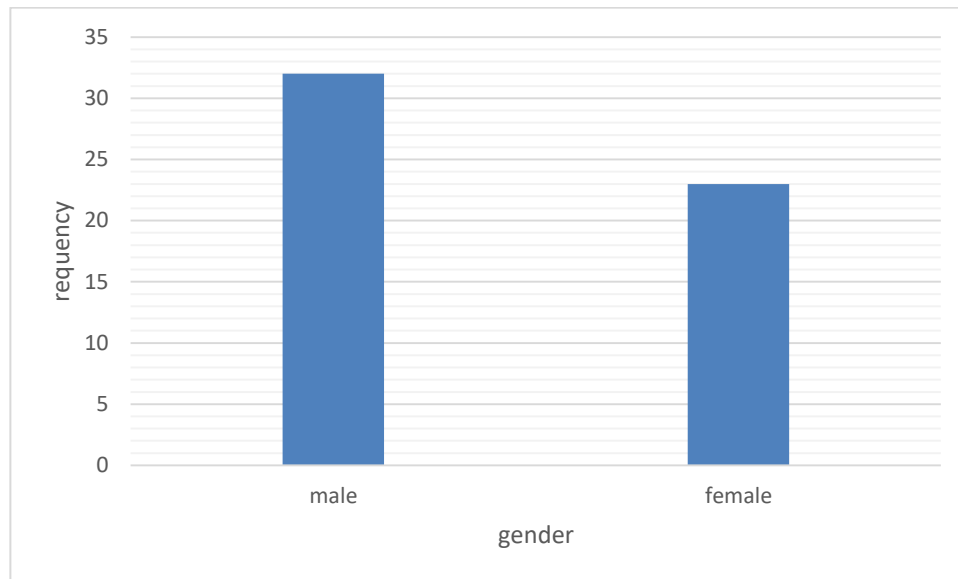


Figure (4.1) shows gender distribution

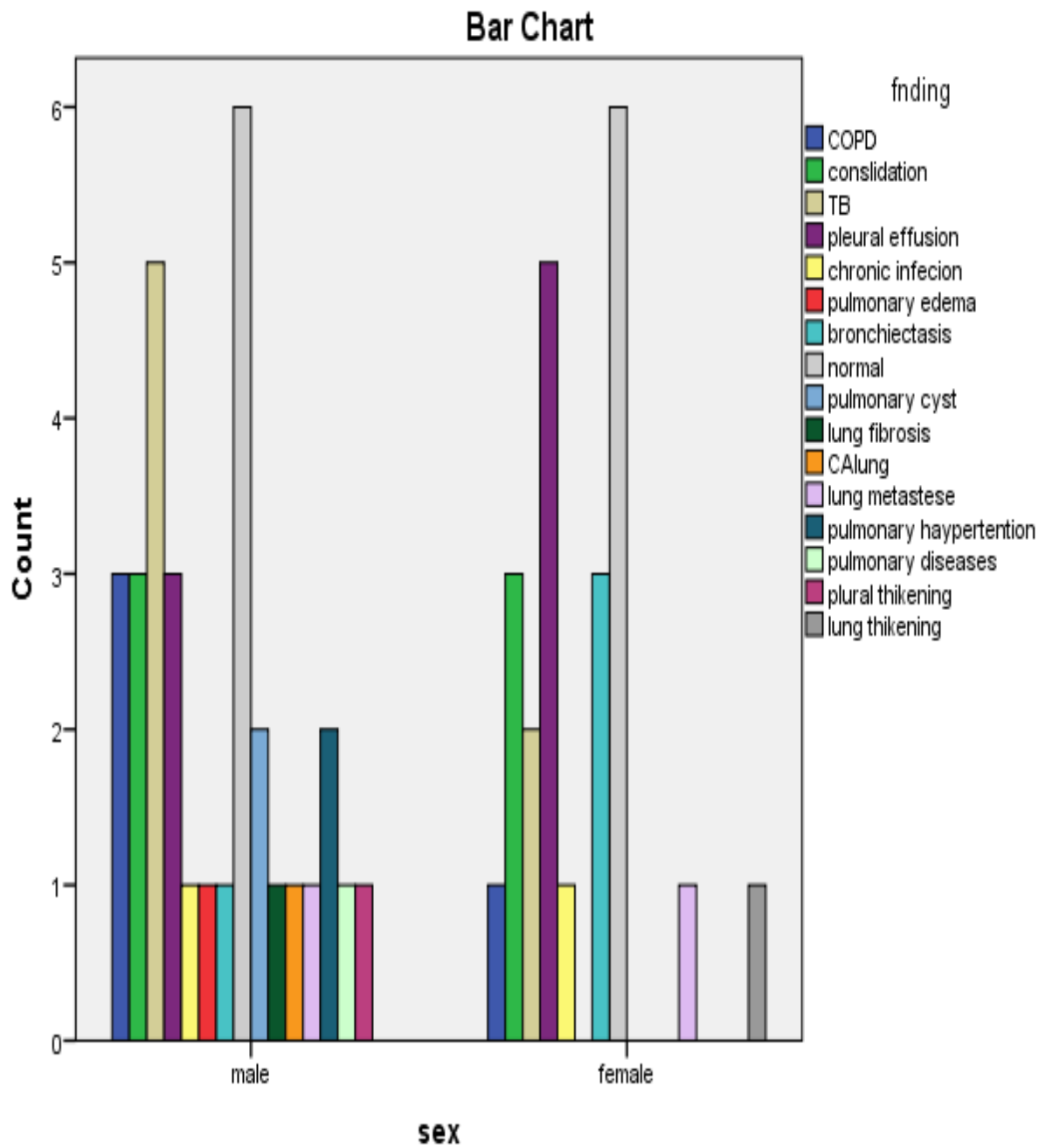


Figure (4.2) shows relationship of patient gender and CT finding

Table(4.2) Cross tabulation demonstrated distribution of frequency of age group

Age group	Frequency	Percent
5-16.5	1	1.8%
16.5-28.5	6	10.9%
29-41	9	16.4%
41.5-53.5	12	21.8%
53.5-65.5	14	25.5%
66-78	8	14.5%
78.5-90.5	5	9.1%
Total	55	100.0%

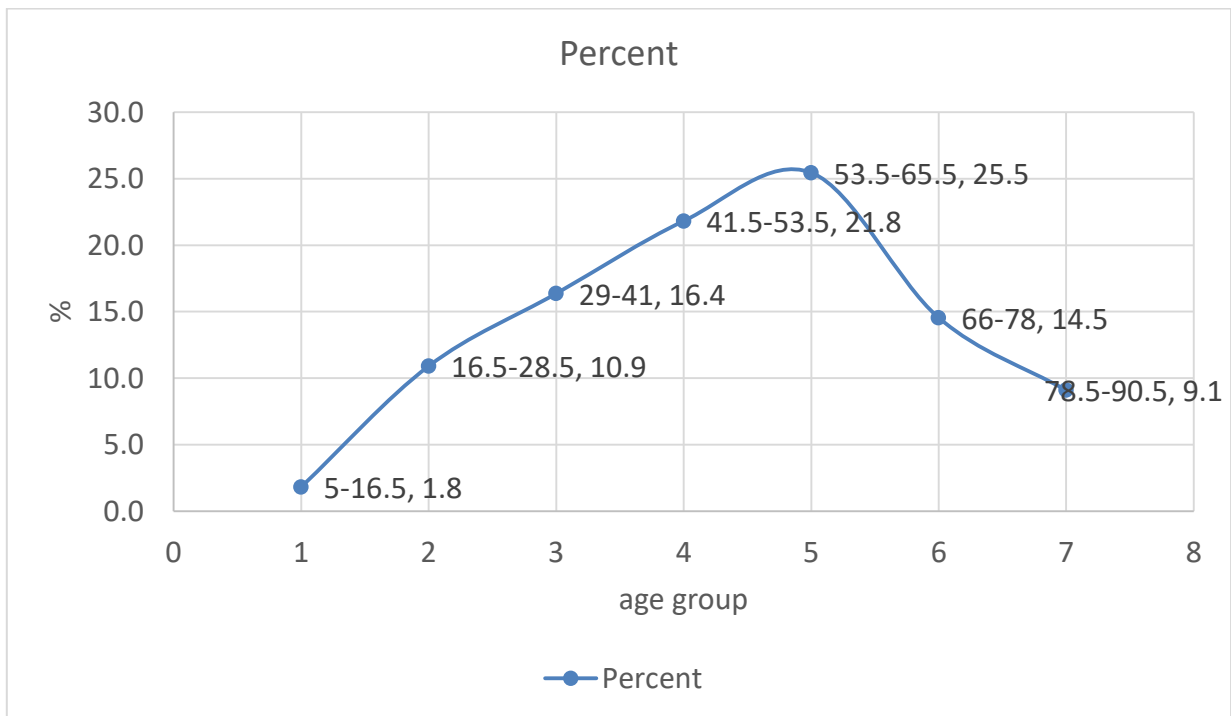


Figure (4.3) shows age group percentage

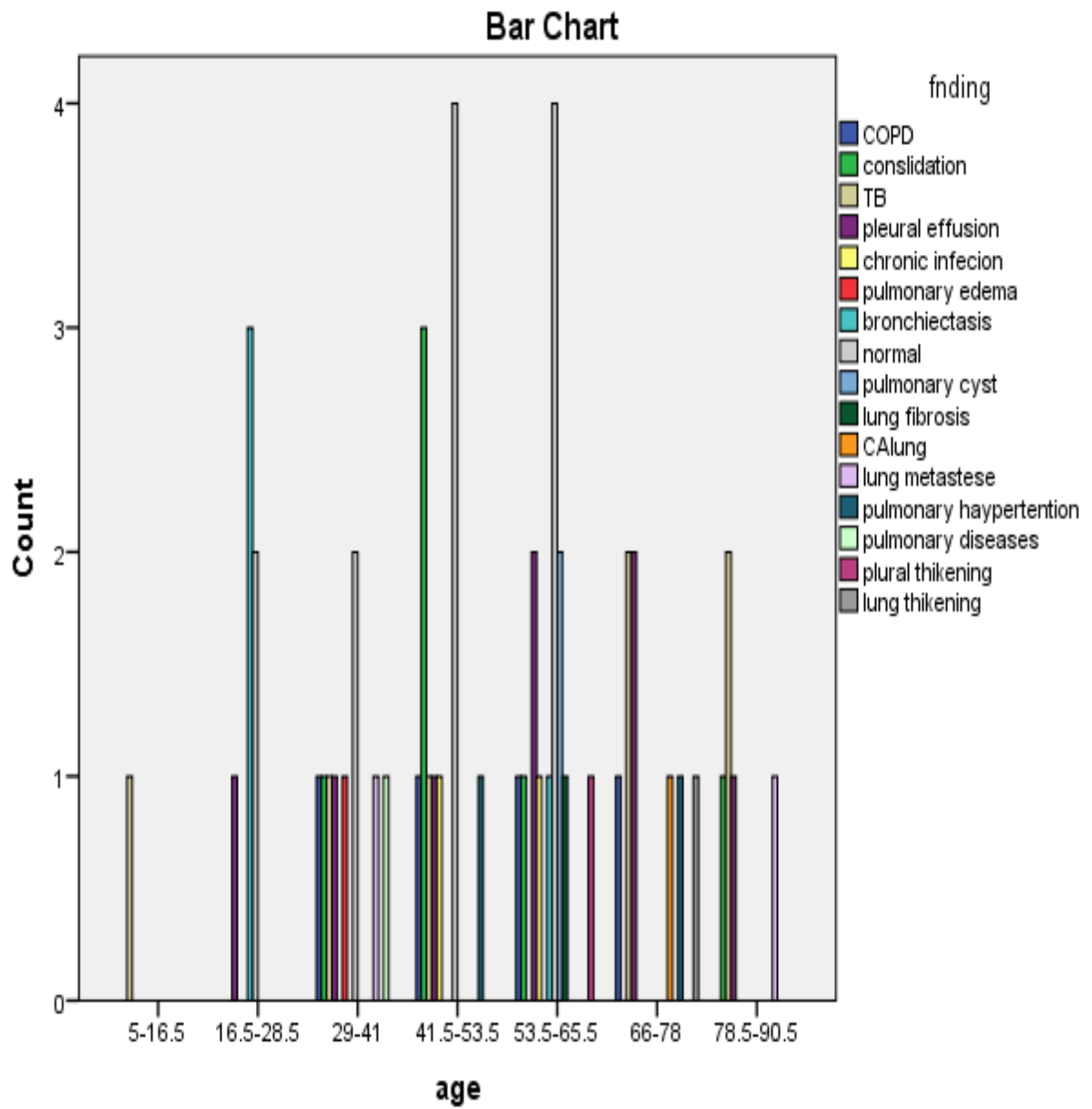


Figure (4.4) shows relationship of patient age and CT finding

Table (4.3) showed relationship of clinical history and frequency

Clinical H	Frequency	Percent
short of breath	7	12.7%
Cough	16	29.1%
chest pain	3	5.5%
Fever	4	7.3%
hemoptysis	4	7.3%
pneumonia	2	3.6%
Dyspnea	1	1.8%
small nodules	1	1.8%
infection	2	3.6%
asthma	7	12.7%
hemolysis	1	1.8%
ca lung	2	3.6%
left sided mastectomy	1	1.8%
ca breast	2	3.6%
lung fibrosis	1	1.8%
ca rectum	1	1.8%
Total	55	100.0%

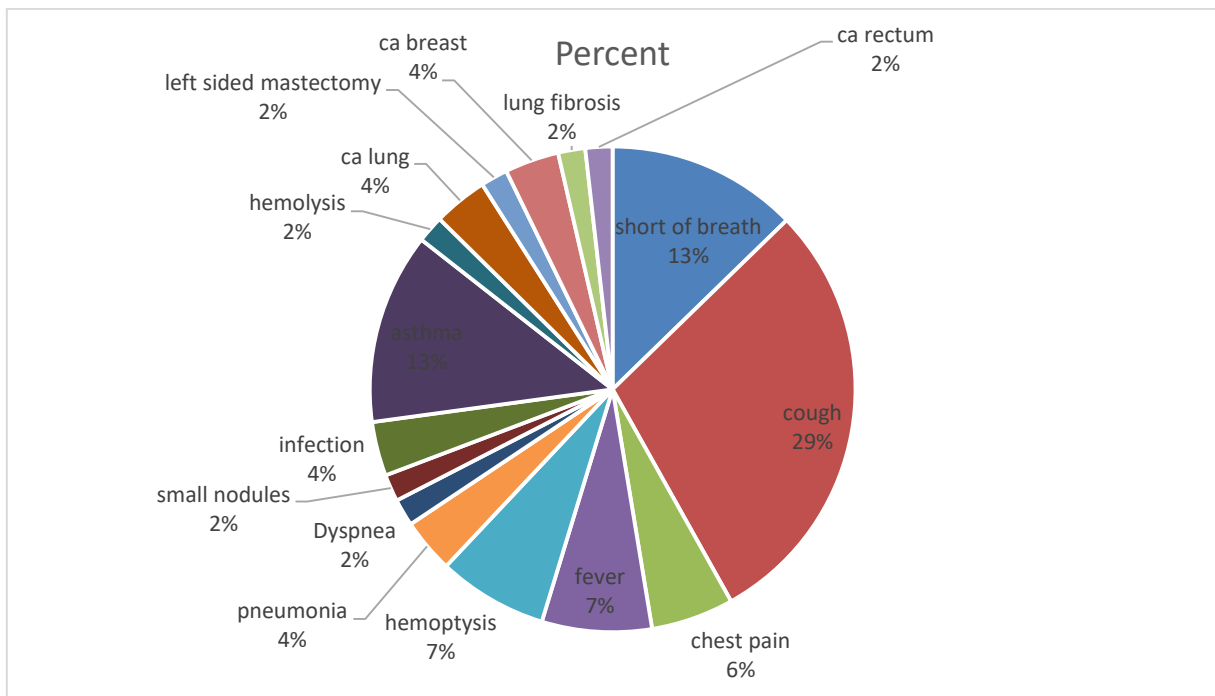


Figure (4.5) pie graph shows percentage of CT finding

Table (4.4) showed relationship of CT finding and frequency

Finding	Frequency	Percent
COPD	4	7.3%
Consolidation	6	10.9%
TB	7	12.7%
pleural effusion	8	14.5%
chronic infection	2	3.6%
pulmonary edema	1	1.8%
Bronchiectasis	4	7.3%
Normal	12	21.8%
pulmonary cyst	2	3.6%
lung fibrosis	1	1.8%
CA lung	1	1.8%
lung metastasis	2	3.6%
pulmonary hypertension	2	3.6%
pulmonary diseases	1	1.8%
plural thickening	1	1.8%
lung thickening	1	1.8%
Total	55	100.0%

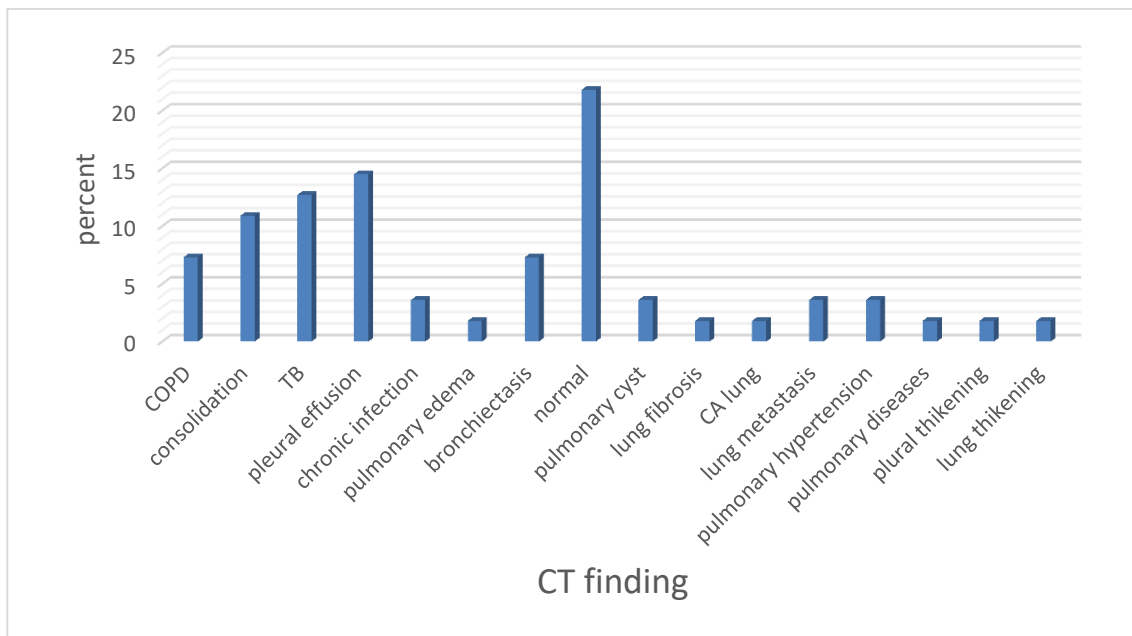


Figure (4.6) shows percentage of CT finding

Table (4.5) showed Chi-square Tests

Chi-Square Tests			
	Value	df	Asymp. Sig. (2-sided)
Pearson Chi-Square	300.877 ^a	225	0.001
Likelihood Ratio	141.908	225	1.000
Linear-by-Linear Association	9.164	1	.002
N of Valid Cases	55		

Table (4.6) Cross tabulation showed relationship of clinical history and CT finding

		clinicalH * fnding Crosstabulation																
Count		fnding																
		COPD	consolidation	TB	pleural effusion	chronic infection	pulmonary edema	bronchiectasis	normal	pulmonary cyst	lung fibrosis	CAlung	lung metastase	pulmonary hypertension	pulmonary diseases	plural thickening	lung thickening	Total
clinicalH	short of breath	1	2	0	0	0	0	0	3	0	0	0	0	1	0	0	0	7
	cough	2	3	5	0	2	0	0	3	0	1	0	0	0	0	0	0	16
	chest pain	0	0	0	2	0	0	0	1	0	0	0	0	0	0	0	0	3
	fever	0	0	1	1	0	0	0	2	0	0	0	0	0	0	0	0	4
	hemoptysis	0	0	1	0	0	0	2	0	1	0	0	0	0	0	0	0	4
	pneumonia	0	0	0	1	0	1	0	0	0	0	0	0	0	0	0	0	2
	Dyspnea	0	1	0	0	0	0	0	0	0	0	0	0	0	0	0	0	1
	small nodules	0	0	0	0	0	0	1	0	0	0	0	0	0	0	0	0	1
	infection	1	0	0	0	0	0	0	0	0	0	0	0	0	1	0	0	2
	asthma	0	0	0	1	0	0	1	3	0	0	0	0	1	0	0	1	7
	hemphysis	0	0	0	0	0	0	0	0	1	0	0	0	0	0	0	0	1
	ca lung	0	0	0	0	0	0	0	0	0	0	1	1	0	0	0	0	2
	left sided mastectomy	0	0	0	1	0	0	0	0	0	0	0	0	0	0	0	0	1
	ca breast	0	0	0	1	0	0	0	0	0	0	0	1	0	0	0	0	2
	lung fibrosis	0	0	0	0	0	0	0	0	0	0	0	0	0	0	1	0	1
	ca rectum	0	0	0	1	0	0	0	0	0	0	0	0	0	0	0	0	1
Total		4	6	7	8	2	1	4	12	2	1	1	2	2	1	1	1	55

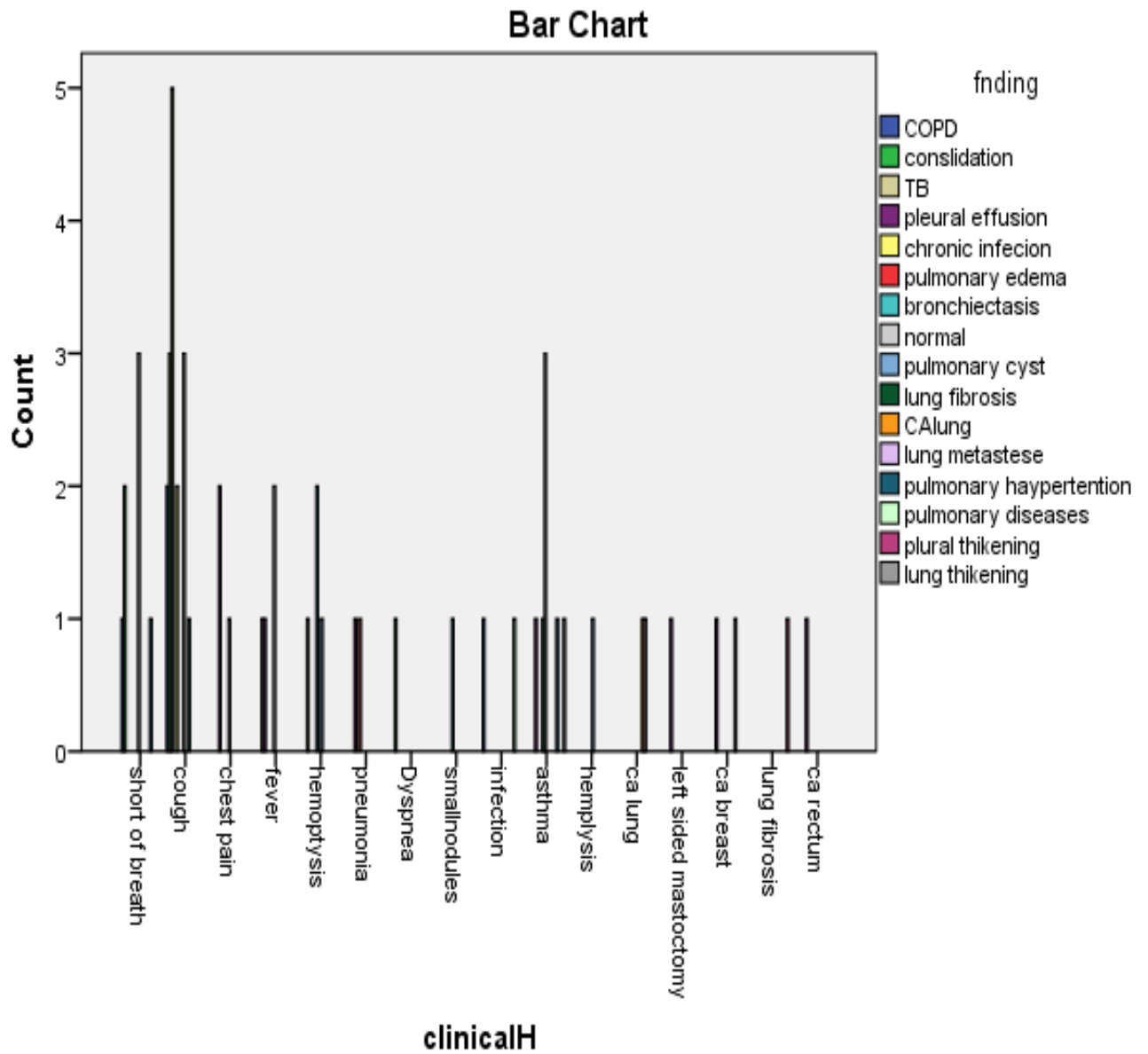


Figure (4.7) shows relationship of clinical history and CT finding

Chapter Five

Chapter Five

Discussion, Conclusion and Recommendation

5.1 Discussion

High resolution computed tomography of chest is the most accurate non invasive imaging method of evaluating lung disease and has improved our understanding of the patterns and pathology of many pulmonary diseases this result agree with FATIH. etal ORS 2013

The study aimed to evaluate the characteristic of lung disease by high resolution computed tomography.

This study is performed in Department of Radiology in yastabshroon and dar el elaje hospitals in Khartoum state, in period from (october2016- February 2017)

Population of this study were 55 samples of both gender referred chest CT as 32 males with percentage of (58.2%) and 23 females with percentage of(41.8%) .

This result finding out that male more affected with lung diseases as in table (4.1) and figure (4.1).

The most age group affected was (53.5-65.5 years) with high percentage (25.5)% as in table (4.5) and figure (4.4).

In this study beak incidence was cough and it's the most common clinical indication (29.1%) followed by shortness of breathing (12.7%) and athma (12.7%), than fever and hemoptosis (7.3%) than pain (5.5%), CA lung ,pneumonia , infection ,CA rectum, lung fibrosis, left sided mastectomy (1.2%)as in figure (2.4) and table (4.3).

The result showed that the HRCT can diagnose the most common causes of cough from TB(31.25%)as in table (4.6) and figure (4.7) this result agree with (PINGILE BK 2016)

In these study beak incidence was normal result with (12Pt) (21.8%) and plural effusion with (8Pt) (14.5%) and TB with (7 Pt) (12.7%) and consolidations with

(6Pt) (10.9%) and COPD, Bronchiectasis (4 Pt) (7.3%) and lung metastasis ,chronic infection ,pulmonary cyst ,pulmonary hypertension with (2Pt) (3.6%)and CA lung, lung fibrosis ,pulmonary edema ,pulmonary diseases, plural thickening , lung thickening with (1Pt) (1,8%) as in table (4.4) figure (4.6) this result agree with (P.A.DE JONG 2004).

These study is significant as in table (4.5) .

5.2 Conclusion:

The study concluded that there were main role of HRCT in diagnosis lungs disease . These results are very similar to these reported by previous authors. All patients with the chest disease should under go HRCT in order to detect the morphology and function of the .

HRCT is best investigation tool in detecting lung abnormalities, changing technique and using farther specialized investigation tools will produce more accurate diagnosis.

5.3 Recommendations:

- HRCT is recommended to detect lung disease in symptomatic patients with a normal chest radiograph.
- HRCT is recommended to detect or evaluate specific problems or diagnosis, such as metastatic lesions, pulmonary nodules, emphysema, bronchiectasis, and diffuse parenchymal disease.
- Continuous education is important for improving the techniques and protocols used in HRCT.

References

- Austin JHM, Muller NL, Friedman PJ, et al. Glossary for CT of the lungs: Bokulic RE, Hilman BC. Interstitial lung disease in children. *Pediatr Clin North Am* 1994;41:543-567
- Cheak FK, Sheppard MN, Hansell DM. Computed tomography of diffuse pulmonary haemorrhage with pathological correlation. *Clin Radiol* 1993;48:89-39
- CT. Pathology correlation of pulmonary tuberculosis. *Imj G, Hoh H, Ieejy Iee, ks, Han MC*. 1995; 36(3):227-85.
- Cheak FK, Sheppard MN, Hansell DM. Computed tomography of diffuse pulmonary haemorrhage with pathological correlation. *Clin Radiol* 1993;48:89-39
- DEAN M.R.E, *Basic anatomy and physiology for Radiographers 1*. Snell. RICHARDS, 2000 *Clinical Anatomy for Medical Students*, Lippincott Williams and Wilkins, 6th Edition.
- Essential of CT, *vined K, Jan Fan LL, Langston C*. Chronic interstitial lung disease in children. *pediator pulmonol* 1993;16:184-196{Medline}
- Gay SE, Kazerooni EA, Toews GB, et al. Idiopathic pulmonary fibrosis: predicting response to the therapy and survival. *Am J Respir Crit Care Med* 1998;157:1063-1072
- HANSELL, D. M. @KERR, I. H 1991. The role of high resolution computed tomography in diagnosis of interstitial lung disease. *Thorax*, 46,77-84.

Kim TS, Lee KS, Chung MP, et al. Nonspecific interstitial pneumonia with fibrosis : high-resolution CT and pathological findings. AJR 1998;171:243-248

Ies lie KO. Pathology of interstitial lung disease .clin chest Med . 2004;251(4): 657-703,v.

Lynch DA, Brasch RC , Hardy KA, Webb WR. Pulmonary disease : assessment with high resolution ultrafast CT. RADIOLOGY 1990;176:243-248

Maher TM, Wells AU, Laurent GJ. Idopathick pulmonary fibrosis : multiple causes and multiple mechanism , Eur Respir J, 2007;30(5) : 835-9

Muller NL: Computed Tomography in chronic interstitial lung disease . Radiol clin North Am 1991, 29 : 1085-1093.

Pulmonary tuberculosis : CT and pathological correlation . lee, KS, Jung KJ, Han J, Kwon OJ , Kim Ts .2000 sep.oct, 24(5): 691-8.

Recommendations of the nomenclature committee of the Fleischner society . Radiology 1996;200:327-331

Ryu JH . Classification and approach to bronchiolar disease curr opin pulmmed. 2006; 12(12):145-51.

Radiographic Pathology . 2th edition .616.07572 LINA

Sharief N, Crawford OF. Fibrosing alveolitis and desquamative interstitial pneumoniti pediater pulmonol 199; 17:359-365

Selly JM, Effmann EL, Muller NL. High-resolution CT of lung disease imaging findings. AJR 1997;168:1269-1275

Short Text book of pathology. M.D.2010 4th edition.

Tortora , Gerard ,J, Principles of anatomy and physiology1987.

William R. Hendee and E. Russell Ritenour, Medical Imaging physics , fourth Edition 2002.

William F.Ganong , 2003 Review of medical pathology, twenty fist edition.

<http://www.egh.org> > radiology info

[http:// scholar. Googel. Com](http://scholar.google.com)

[www.nhsc. hrsa. Gov.](http://www.nhsc.hrsa.gov) national health service.

Appendix:

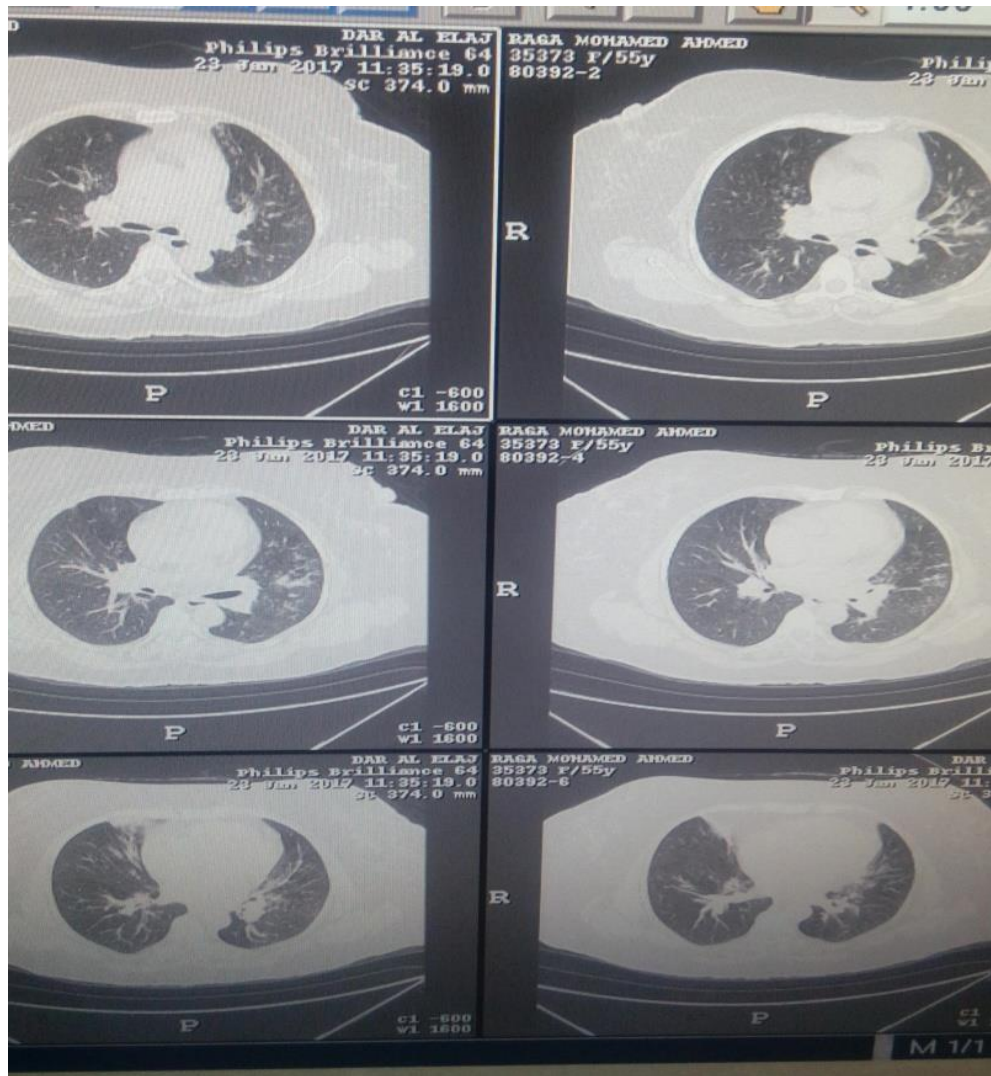


Figure 5.1 HRCT axial chest for female 55 years old show pneumonic consolidation.

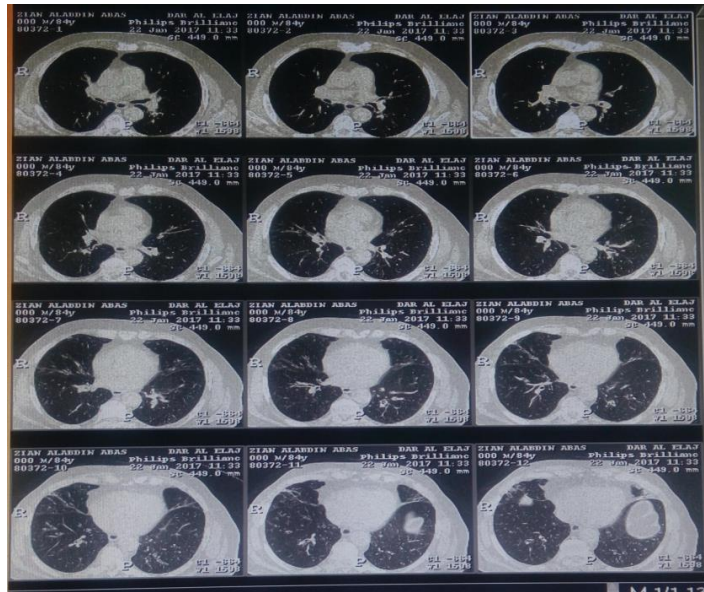


Figure 5.2 HRCT axial chest for male 40 years old show emphysematous lung.

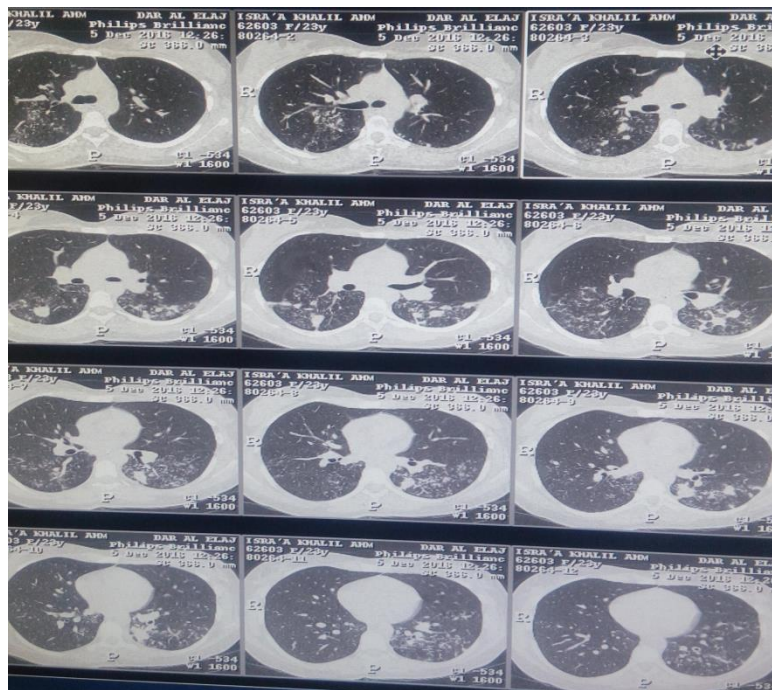


Figure 5.3 HRCT axial chest for female 23 years old show bronchiectatic change.

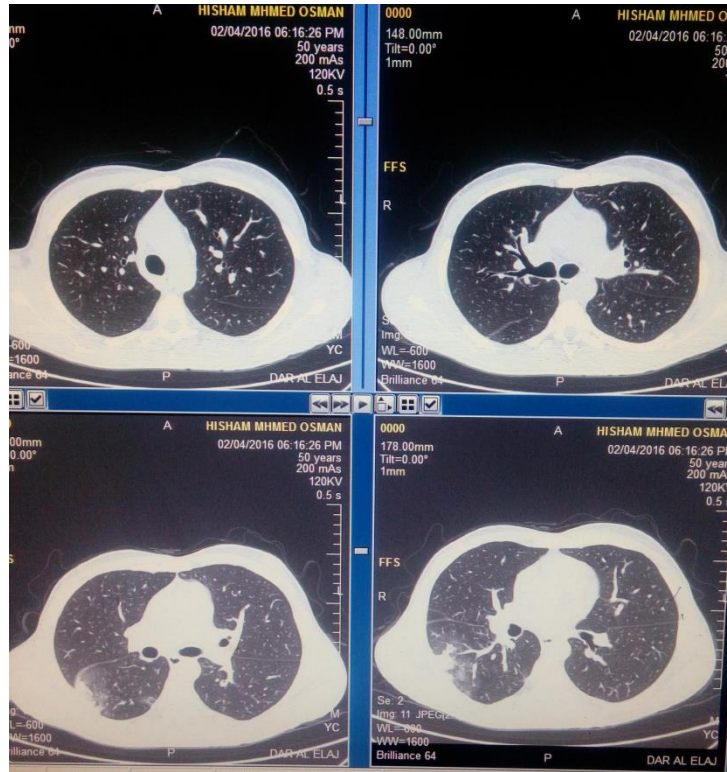


Figure 5.4 HRCT axial chest for male 50 years old show pneumonic consolidation.

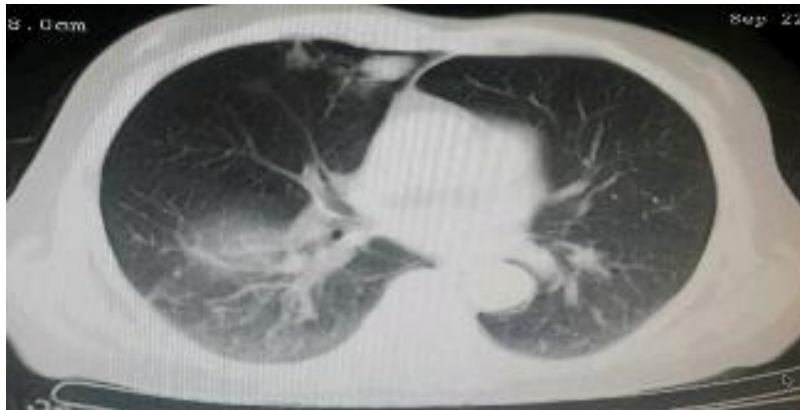

Figure 5.5 HRCT axial chest for male 60years old show TB.

