



Sudan University of Sciences and Technology
College of Graduate Studies



Measurement of Ureteric Stones using Computed Tomography

قياس حصاوي الحالب باستخدام تقنية الاشعة المقطعية

A thesis Submitted for partial fulfillment Requirements of Master degree in
Diagnostic Radiological Technology

By

Fekri Suleiman Hamad Ibrahim

Supervised

Dr.Muna Ahmed Mohamed Ahmed

2017

Chapter One

Chapter Tow

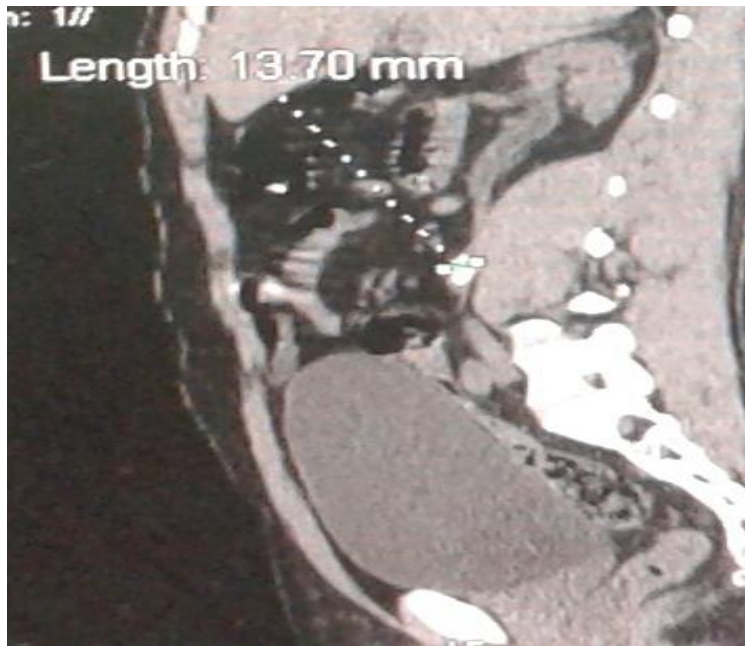Chapter Three

Chapter Four

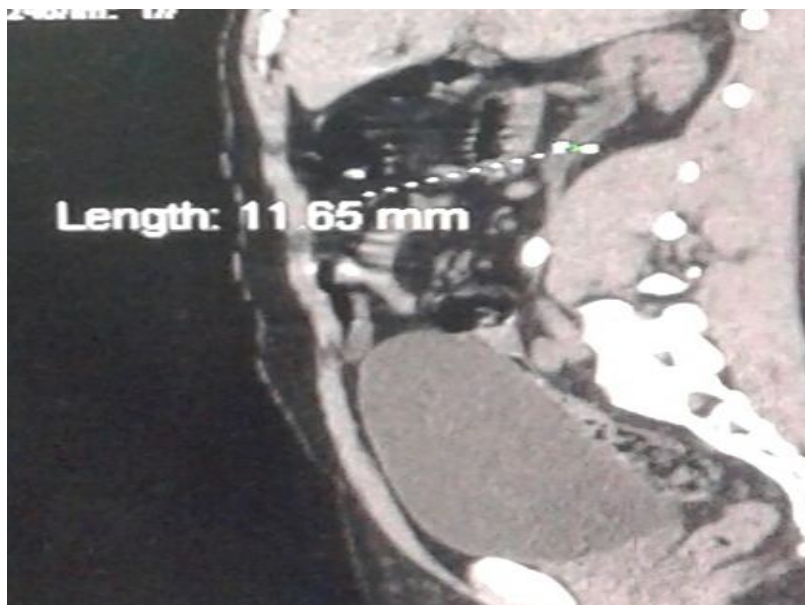
Chapter Five

Appendices

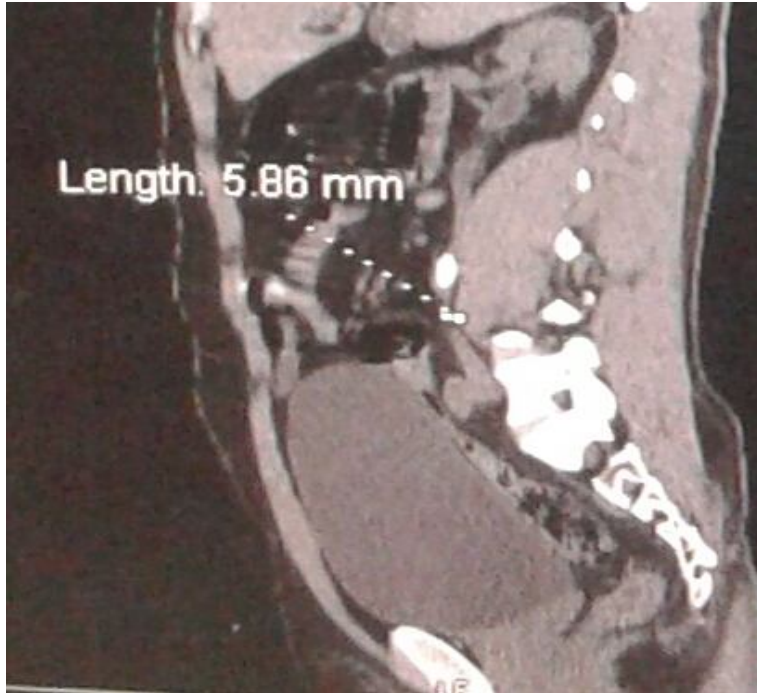
Appendix C



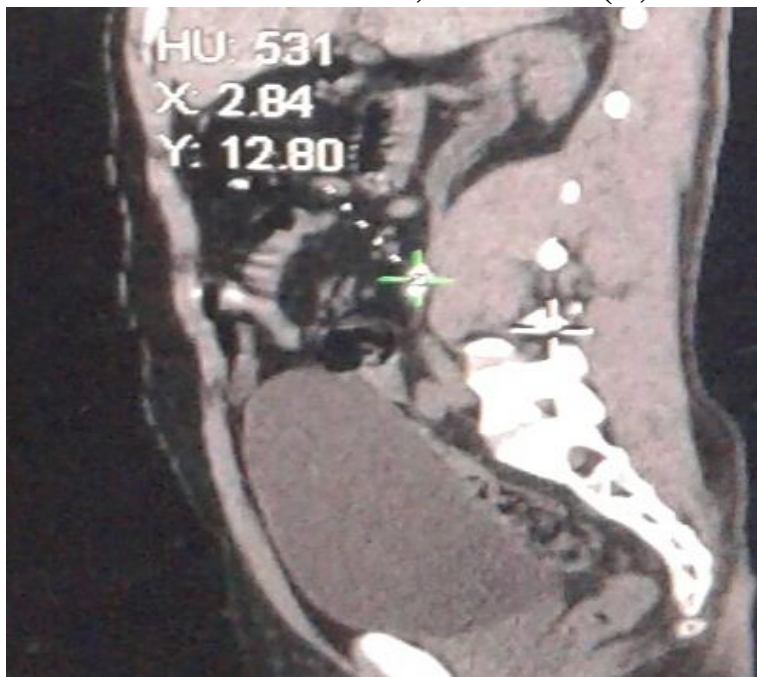Image(1) CT Scan Image, sagittal view for Male(40years),show Ureteric stone, measure(13,70mm).



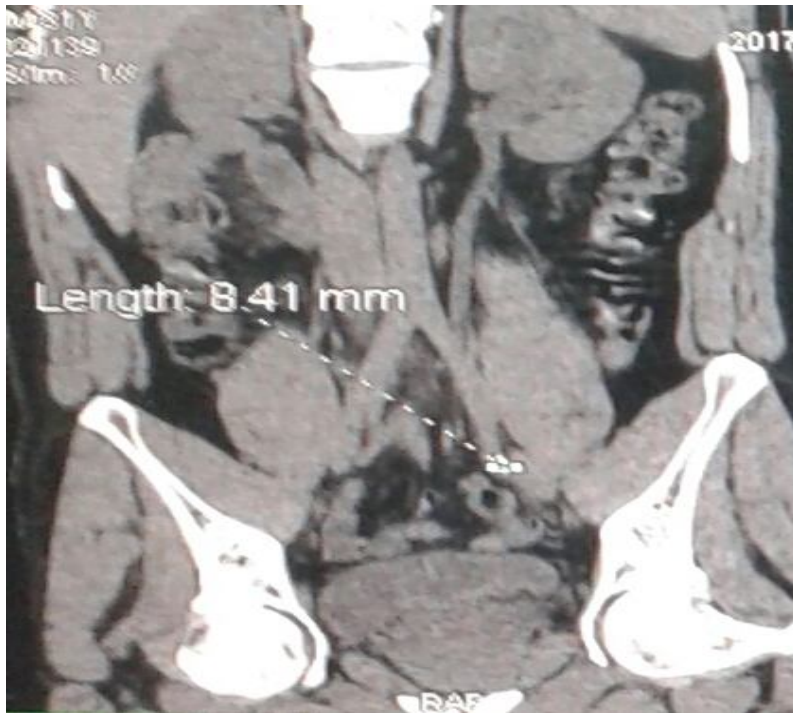Image(2) CT Scan Image, sagittal view for Male(40years),show Above Ureteric stone, measure(11,65mm).



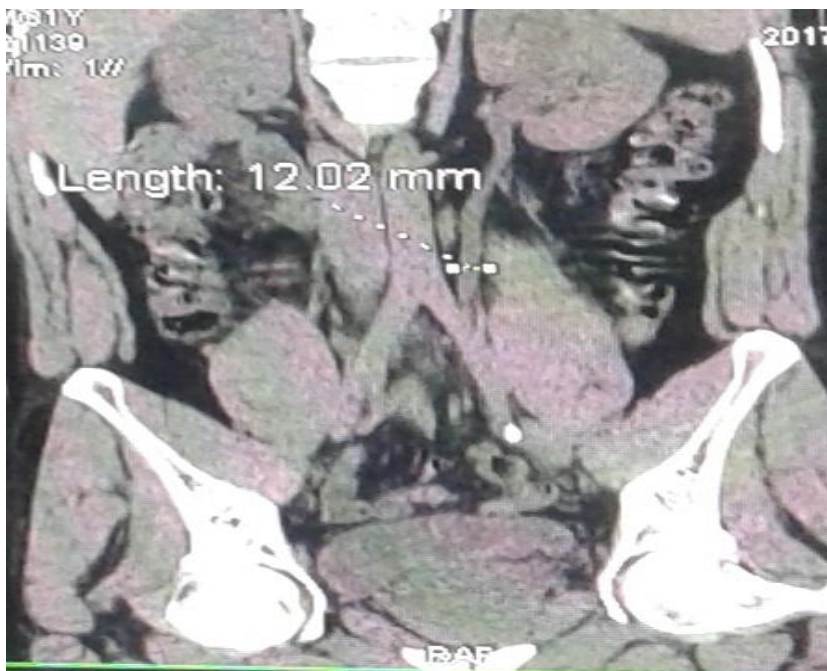
Image(3) CT Scan Image, sagittal view for Male(40years),show Below Ureteric stone, measure(5,86mm).



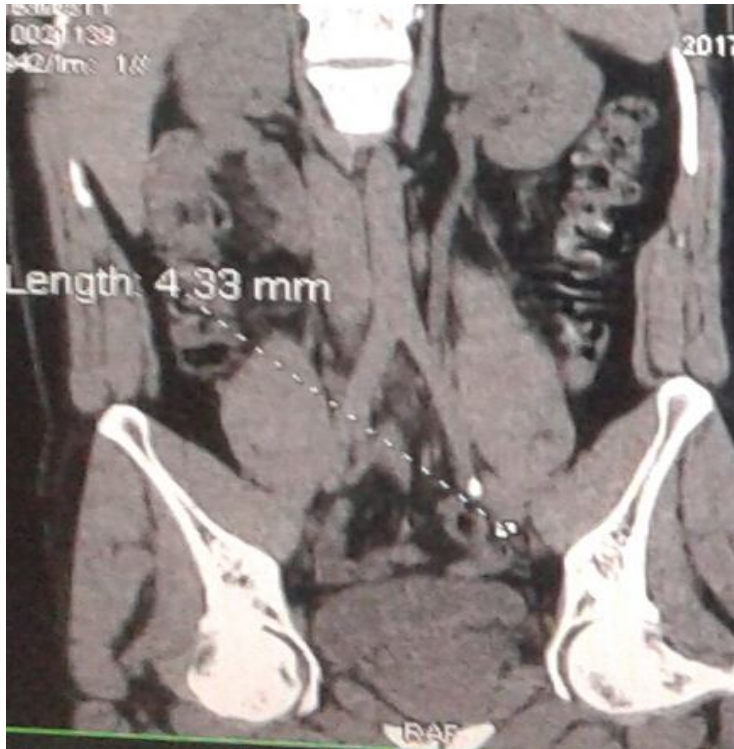
Image(4) CT Scan Image, sagittal view for Male(40years),show HU of Ureteric stone, measure(531).



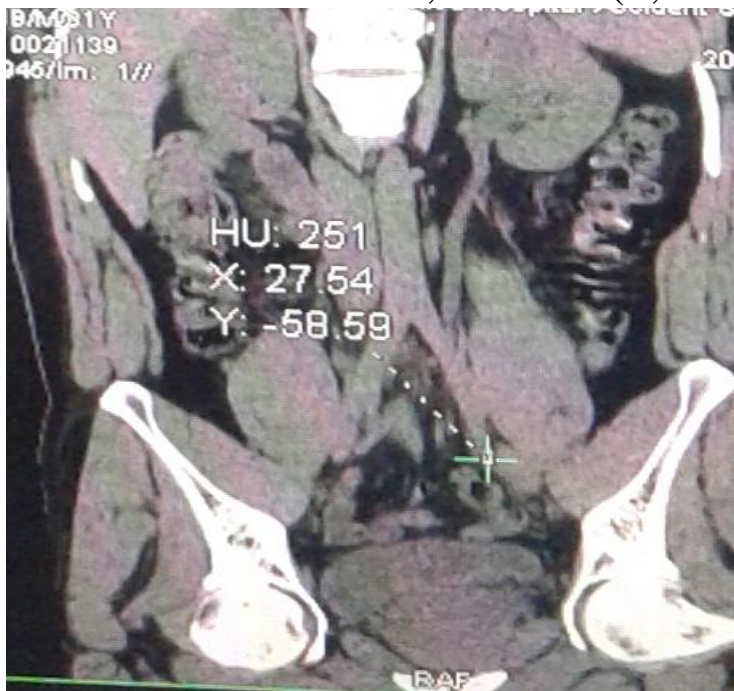
Image(5) CT Scan Image, Coronal view for Male(31years),show Ureteric stone, measure(8,41mm).



Image(6) CT Scan Image, Coronal view for Male(31years),show Above Ureteric stone, measure(12,02mm).



Image(7) CT Scan Image, Coronal view for Male(31years),show Below Ureteric stone, measure(4,33mm).



Image(7) CT Scan Image, Coronal view for Male(31years),show HU of Ureteric stone, measure(251).

Appendix A

Sudan University for Sciences and technology

College of Graduate studies

Measurement of Ureteric Stones using CT KUB

Data collection sheet

Number	Age (years)	Gender (Male- Female)	Stones Size (mm)	Width Above Ureteric Stones(mm)	Width Below Ureteric Stones(mm)	H U

Appendix B

Hounsfield Units(*HU*) for Stones

1-Radio opaque stones on CT :

- Calcium Oxalate+/- calcium phosphate 400-600HU.
- Struvite (Triple phosphate) usually opaque but variable.
- Pure Calcium phosphate 400-600HU.
- Uric acid 100-200HU .
- CystineOpague.

2-Radio lucent stones on CT:

- Indinavirstones .
- Pure matrix stones.

References

References

Arthur S. Schneider and Philip A. Szanto, 2012, BRS Pathology, 4th edition, Wolters Kluwer Health/Lippincott Williams & Wilkins, Philadelphia, Chapter 17, Page 263.

<https://www.researchgate.net> Publication. November 2013 with 9/10/2017.

<https://doi.org/10.1016/J.Urology.2009.12.015>.

<https://www.ncbi.nlm.nih.gov/pubmed>, Jendrol 2003, Dec, 17(10):847-50.

<https://doi.org/10.1097/01.Ju.000005560892669.3a>.

[https://radiopaedia.org >articles>Urolith.\(2005-2017\)](https://radiopaedia.org/articles/Urolith.(2005-2017)), Radiopaedia.org.

Lois E. Romans, 2011, computed tomography for technologists : a comprehensive text, Wolters Kluwer Health/Lippincott Williams & Wilkins, Philadelphia, Chapter 1, Pages 3-12.

Lorrie L. Kelley and Connie M. Petersen, 2007, Sectional Anatomy for Imaging Professionals, 2nd edition, Elsevier Inc, Philadelphia, Chapter 7, Page 388.

Stephanie Ryan, (e tal.), 2004, Anatomy for Diagnostic Imaging, 2nd edition, Elsevier Inc, Philadelphia, Chapter 5, Pages 194, 195, 196.

Philip Xiu,2012 ,Crash Course Pathology,4th edition, Elsevier Inc , Philadelphia, Chapter 9 ,Page176.

Richard S.Snell,2012, Clinical Anatomy By Region,9th edition , Wolters Kluwer Health/Lippincott Williams & Wilkins ,Philadelphia, Chapter 17, Page 211.

Ronald L. Eisenberg and Nancy M. Johnson,2012,Comprehensive Radiographic Pathology,5th edition, Elsevier Inc , Philadelphia, Chapter 6 ,Page 220.