



Sudan University of Science and Technology
College of Graduate Studies



Immunohistochemical Detection of CD56 in Thyroid Tumors Among Sudanese Patients

**الكشف النسيجي الكيمائي المناعي عن سي دي 56 في أورام الغدة
الدرقية لدى المرضى السودانيين**

**A dissertation submitted for partial fulfillment of the
requirements of the degree of M.Sc in Medical Laboratory
Sciences (Histopathology and Cytology)**

By:

Ala Hassan Mhmmoud Hameid

B.Sc in Medical Laboratory Sciences (Sudan University of
Sciences and Technology 2014)

Supervisor:

Dr. Abu Elgasim Abass Awad Elkareem

2018

Dedication

I dedicate this dissertation to:-

My family

My love mother

My love father

My sisters

My best friend.

Acknowledgment

Firstly I would like to thank Allah for giving me the knowledge, strength and support to complete this dissertation.

I would like to thank the supervisor Dr. Abu Elgasim Abass Awad Elkareem for this perfect supervision.

Finally I would like to thank all the staff of Sudan university of sciences and technology, college of medical laboratory sciences and every one helped me.

Abstract

This is hospital based analytical retrospective case control study conducted in Omdurman teaching hospital during the period from may 2017 to august 2017 aimed to detect CD56 in thyroid tumors among Sudanese patients.

A total of 40 formalin fixed paraffin blocks previously diagnosed as thyroid tumors were selected 20(50.0%) samples were papillary thyroid cancer, 5(12.5%) samples were follicular carcinoma, 5(12.5%) samples were follicular adenoma, 5(12.5%) samples were goiter and 5(12.5%) samples were lymphothyroiditis. One section of three micron was cut from each block and stained by immunohistochemical method (avidin biotin technique) for CD56 detection. The data obtained was analyzed using SPSS computer program version 13.

The patients ages ranged between 11 to 70 years with mean age 45 years, most of patients 27(67.5%) were less than 50 years and the remaining 13(32.5%) were above 50 years.

Patients sex revealed that 8(20%) patients were male and 32(80%) were female.

Positive expression of CD56 was detected in 5/25 samples and negative in 15/25 samples of malignant samples, while all benign samples showed positive expression 15/15 samples (P. value 0.000).

The study concluded that the expression of CD56 increase in benign thyroid tumor more than malignant thyroid tumor.

المستخلص

أجريت هذه الدراسة المستشفوية التراجعية التحليلية و الحالة الضابطة في مستشفى امدرمان التعليمي خلال الفترة من مايو 2017 إلى أغسطس 2017 لدراسة دور سي دي 56 في أورام الغدة الدرقية لدى المرضى السودانيين.

أختير أربعون قالب شمعي لهذه الدراسة مغمورة في البرافين تم تشخيصها مسبقا كعينات أورام للغدة الدرقية. كان تشخيص المرضى يشمل علي 20(50%) عينة من الورم الحليمي الخبيث للغدة الدرقية, 5(12.5%) عينات من الورم المسامي الخبيث للغدة الدرقية, 5(12.5%) عينات من الورم المسامي الحميد, 5(12.5%) عينات من ورم الغدة الحميد, 5(12.5%) عينات التهاب الغدة الليمفاوي. تم قطع القوالب بسمك ثلاثة مايكرون وصبغها بطريقة الكشف النسيجي الكيميائي المناعي باستخدام تقنية البايوتين افيدن للكشف عن سي دي 56. تم تحليل البيانات التي تم الحصول عليها باستخدام برنامج الحزم الإحصائية للعلوم الاجتماعية إصدار 13.

تراوحت أعمار المرضى بين 11 الي 70 سنة مع متوسط عمر 45 عاما, ومعظم أعمار المرضى تتركز تحت 50 عاما 27(67.5%) والباقي 13(32.5%) أعمارهم كانت فوق ال 50 عاما.

كان جنس المرضى 8(20%) منهم رجال و 32(80%) منهم نساء.

ظهر التعبير الايجابي ل سي دي 56 في 5/25 عينات و سالبا في 15/25 عينة من الأورام الخبيثة, بينما أظهرت جميع عينات الأورام الحميدة التعبير الايجابي 15/15 عينة (القيمة الاحتمالية تساوي 0.000).

وخلصت الدراسة إلي أن ظهور سي دي 56 يزداد في الأورام الحميدة للغدة الدرقية أكثر من الأورام الخبيثة.

List of contents

Subject	page
الآية	I
Dedication	II
Acknowledgement	III
Abstract	IV
المستخلص	V
List of contents	VI
List of abbreviations	VIII
List of tables	IX
List of figures	X
Chapter One	
Introduction	
1.1 Introduction	1
1.2 Objective	3
Chapter Two	
Literature Review	
2.1 Anatomy and physiology of thyroid gland	4
2.2 Abnormalities of thyroid gland	4
2.2.1 Benign neoplasms and lesions of thyroid gland	4
2.2.2. Malignant lesions of thyroid gland	5
2.2.2.1 Papillary thyroid carcinoma	5
2.2.2.2 Follicular thyroid carcinoma	5
2.2.2.3 Hurthle cell carcinoma	5
2.2.2.4 Medullary thyroid carcinoma	5
2.2.2.5 Anaplastic thyroid carcinoma	6
2.3 Signs and symptoms of thyroid cancer	6
2.4 Epidemiology of thyroid cancer	6
2.5 Risk factors of thyroid cancer	6
2.6 Diagnosis of thyroid cancer	7
2.6.1 Physical examination	7
2.6.2 Fine needle aspiration	8
2.6.3 Laboratory testing	8
2.6.4 Imaging study	8
2.6.5 Immunohistochemistry (IHC)	8
2.6.6 Tumor markers	8

2.6.6.1 CD56	8
2.7 Management of thyroid cancer	9
Chapter Three Materials and Methods	
3.1 Materials	10
3.2 Methods	10
3.2.1 Study design	10
3.2.2 Study samples	10
3.2.3 Sample processing	10
3.2.4 Staining method	10
3.2.4.1 Immunohistochemical staining	10
3.2.5 Result interpretation	11
3.2.6 Statistical analysis	11
3.2.7 Ethical considerations	11
Chapter Four Results	
4. Results	12
Chapter Five Discussion	
5. Discussion	19
Chapter Six Conclusion and Recommendations	
6.1 Conclusion	21
6.2 Recommendations	21
References	22
Appendices	29

List of abbreviations

ATC	Anaplastic thyroid carcinoma
CT	Computed tomography
CEA	Carcinoembryonic antigen
DAB	3,3-diaminobenzidine tetra hydrochloride
DPX	Distyrene plasticizer xylene
FGFR	Fibroblast growth factor receptor
FTC	Follicular thyroid carcinoma
MTC	Medullary thyroid cancer
MEN2	Multiple endocrine neoplasia type 2
NCAM	Neural cell adhesion molecule
NMTC	Non medullary thyroid cancer
PCR	Polymerase chain reaction
PTC	Papillary thyroid cancer
RTK	Receptor of tyrosine kinase
SPSS	Statistical package for social sciences

List of tables

No	Table	Page
4.1	Distribution of histopathological diagnosis among study population .	13
4.2	Distribution of age group among study population.	14
4.3	Distribution of sex among study population.	15
4.4	Relation between CD56 expression and histopathological diagnosis of thyroid tumor	16

List of figures

No	Figure	Page
4.1	Lymphothyroiditis shows positive cytoplasmic expression of CD56 (40X).	17
4.2	Papillary thyroid cancer shows negative cytoplasmic expression of CD56 (40X).	18

Chapter One

Introduction

Chapter One

Introduction

1.1 Introduction:

Thyroid cancer is cancer originating from follicular or parafollicular thyroid cells, these cell give rise to both well-differentiated cancer (papillary thyroid cancer and follicular thyroid cancer) and poorly differentiated cancer (anaplastic thyroid cancer), the C cell or parafollicular cell produces the hormone calcitonin and is the cell of origin for medullary thyroid carcinoma (Carling, *et al.* 2011).

Thyroid cancer are quite rare accounting for only 1.5% of all cancer in adult and 3% in children, the highest incidence of thyroid carcinoma in the world is among female. Of all thyroid cancer the second most common thyroid neoplasm is follicular carcinoma (Renehan, *et al.* 2008). Thyroid cancer is the sixth most common cancer in women in the united states and account for approximately 1% of all cancer cases (Pellegriti, *et al.* 2013).

The ratio between male to female of thyroid cancer in Sudan during period (2007- 2014), was 1.0:2.4 and there age range between 15-85, follicular carcinoma was 43%, papillary carcinoma was 27%, anaplastic carcinoma was 10%, medullary thyroid carcinoma was 2% (Mohamed, 2014).

The risk factors of thyroid cancer is multifactorial factors such as genetic consideration, gender, ethnic, global and health consideration (Rosai and Ackermam, 2011).

Diagnosis of thyroid cancer can be by various ways including blood test, computed tomography scan (CT scan, X ray) and obtaining tissue sample through a needle or by surgical removal of the nodule (Yeh, *et al.* 2015).

Treatment of thyroid cancer depend on the type of cancer and it is stage. Four types of treatment are used which are surgical removal, radiation therapy, hormonal therapy and chemotherapy (Nixon, *et al.* 2013).

CD56 also called neural cell adhesion molecule (NCAM), is a hemophilic binding glycoprotein expressed on the surface of neurons, glia, skeletal muscle and natural killer cell, it has a role in cell-cell adhesion (Etem, *et al.*2010).

CD56 is glycoprotein of immunoglobulin super family, at least 27 alternatively spliced NCAM mRNA are produced giving a wide diversity of NCAM isoforms (Reyes, *et al.* 1991).

CD56 is expressed at high level in normal thyroid tissue and benign follicular lesions of the thyroid, CD56 is found to be most sensitive and specific marker for differential diagnosis of thyroid nodules (Ozoline, *et al.* 2012).

Objectives:

1.1.1 General objective:

To detect CD56 in thyroid tumors among Sudanese patients and its correlation with histopathology diagnosis.

Chapter Two

Literature Review

Chapter Two

Literature Review

2. Literature review:

2.1 Anatomy and physiology of thyroid gland:

The thyroid gland is a butterfly shaped organ that site at the front of the neck, it is composed of two lobes; left and right, connected by a narrow isthmus, it is weights 25 grams in adult with each lobe being about 5 cm long, 3cm wide and 2cm thick, the isthmus about 1.25cm in height and width, the gland is usually large in woman and increase in size in pregnancy (Neil and Borley, 2008).

The thyroid covered by a thin fibrous capsule, which has an inner and outer layer, the last layer is continues with pretracheal fascia attaching the gland to the cricoids and thyroid cartilages (Ort, *et al.* 2007), the inner layer extrudes into the gland and forms the septae that divides the thyroid into typically four parathyroid gland, two on each side between the two layer of capsule at the back of thyroid lobes (Cuveller, *et al.* 2009).

Behind the outer wings of the thyroid lie the two carotid arteries, the trachea, larynx, lower pharynx and esophagus all lie behind the thyroid (Eills, *et al.* 2005).

2.2 Abnormalities of thyroid gland:

2.2.1 Benign neoplasms and lesions of thyroid gland:

Thyroid nodules increase with age and are present in almost 10% of the adult population. 95% of solitary thyroid nodules are benign and there are only 5% of thyroid nodules which are malignant. Common types of benign thyroid nodules are adenomas, thyroid cyst, hashimoto thyroiditis, goiter and multigoiter (Haugen, *et al.* 2015).

2.2.2 Malignant lesions of thyroid gland:

2.2.2.1 Papillary thyroid carcinoma:

PTC is the most common type of thyroid cancer, accounting 80% of cases, PTC are slow growing and differentiated cancer that develop in one or both lobes of the thyroid gland and may spread to nearby lymph nodes in neck, but is generally treatable with good prognosis (Finley, *et al.* 2004).

2.2.2.2 Follicular thyroid carcinoma:

It is the second most common type of thyroid cancer, and account for approximately one out of 10 cases. It is found more frequently in countries with an inadequate dietary intake of iodine. Follicular carcinoma is also a differentiated form of thyroid cancer, in most cases associated with a good prognosis, although it is somewhat more aggressive than papillary thyroid cancer, follicular carcinoma do not usually spread to nearby lymph node, but they are more likely than papillary cancers to spread to other organs, like the lungs or the bones (Abd El Atti and Shash, 2012).

2.2.2.3 Hurthle cell carcinoma:

It is also known as oxyphil cell carcinoma, is a subtype of follicular carcinoma, and accounts for approximately 3% of all thyroid cancers (Goldman, *et al.* 1996).

2.2.2.4 Medullary thyroid carcinoma:

It is develop from C cell in the thyroid gland, and is aggressive and less differentiated than papillary or follicular cancers. Approximately 4% of all thyroid cancers will be of the medullary subtype. These cancers are more likely to spread to lymph nodes and other organ, release high levels calcitonin and carcinoembryonic antigen (CEA), which can be detected by blood tests (Wells, *et al.* 2015).

2.3.2.5 Anaplastic thyroid carcinoma:

It is the most undifferentiated type of thyroid cancer, meaning that the ATC looks the least like normal cell of the thyroid gland, as a quickly spreads to other parts of the neck and body, it occurs in approximately 2% of thyroid cancer cases (Grunwald, 2005).

2.3 Signs and symptoms of thyroid cancer:

The thyroid carcinoma most commonly manifests as a painless non tender to palpable; sudden onset of pain more strongly associated with benign disease. The presences of hard and fixed nodules, rapid growth: ominous sign, nodular growth, palpable, solitary thyroid nodules most likely to be malignant in patients older than 60 years and in patients younger than 30 years (Yeh, *et al.* 2015).

2.4: Epidemiology of thyroid cancer:

Thyroid cancer are quite rare, accounting for only 1.5% of all cancer in adult and 3% in children, the highest incidence of thyroid carcinomas in the world is among female Chinese residents of Hawaii (Renehan, *et al.* 2008).

2.5 Risk factors of thyroid cancer:

2.5.1 Family history:

Have a first degree relative parent, brother, sister and child. (Brindel, *et al.* 2010).

2.6.2 Genetic consideration:

Recent molecular studies have described a number of abnormalities associated with the progression and differentiation of thyroid carcinoma. The estimation of P53 mutation leads to aggressive form of anaplastic thyroid carcinoma. (Moretti, *et al.* 2000).

2.5.3 Gender:

Incidence of thyroid cancer is high in woman than men by a factor of 2-3 or more, in younger the female to male ratio 4:1, in patients aged 20-45 years the female to male ratio 3:1, in older than 45 years the female to male ratio is 4:1(Renehan, *et al.* 2008).

2.5.4 Age:

Thyroid cancer is common in all age groups, increased with an age range from 15-48 years (Goldfarb and Freyer, 2014).

2.5.5 Radiation exposure:

Exposure to moderate level of radiation to the head and neck may increase the risk of papillary and follicular thyroid cancer (Imaizumi, *et al.* 2006).

2.5.6 Diet low iodine:

Iodine deficiency may induce an increasing incidence of benign thyroid condition but very high iodine intake also affects thyroid function and possibly thyroid cancer risk among dietary factor (Zimmermann and Boelaert, 2015).

2.5.7 Race:

This cancer occurs more frequently in whites than in blacks (Hall, *et al.* 2008).

2.6 Diagnosis of thyroid cancer:

2.6.1 Physical examination:

Examination of patient head and neck including thyroid gland and cervical soft tissue, indirect laryngoscopy, involvement laryngeal nerve (Benedbeak, *et al.* 1999).

2.6.2 Fine needle aspiration:

FNA is the most important diagnostic tool in evaluation thyroid nodules and should be the first intervention, the advantage of diagnosis up to 50% of repeated result in a definitive diagnosis (Mitchell, *et al.* 2007).

2.6.3 Laboratory testing:

Serum thyroid-stimulating hormone concentration is sensitive for hyperthyroidism – hypothyroidism and for evaluation of solitary thyroid nodules, serum calcitonin\pentagastrin –stimulated calcitonin level, polymerase chain reaction (PCR) assay for germline mutations in the RET proto-oncogene (Pacini, 2012).

2.6.4 Imaging studies:

It is used to evaluate patients with suspected thyroid cancer include neck ultrasonograph and thyroid radioiodine imaging (Brito, *et al.* 2013).

2.6.5 Immunohistochemistry (IHC):

IHC involves the process of selectively imaging antigens in cells of tissue section by exploiting the principle of antigen binding specifically to antigens in biological tissue. Marker that can help in differentiating benign from malignant lesions, several markers have been investigated specimens such as CK19, Galectin-3, HBME-1, CK903, CITED1, Ret oncoprotein, CD44, CyclinD1, and p27 (Prasad, *et al.* 2005).

2.6.6 Tumor markers:

2.6.6.1 CD56:

CD56 also called neural cell adhesion molecule (NCAM), is a hemophilic binding glycoprotein expressed on the surface of neurons, glia, skeletal muscle and natural killer cells, NCAM has been implicated as having role in cell-cell adhesion, neuritis outgrowth, synaptic plasticity and learning and memory (Stonenica, *et al.* 2006).

NCAM is glycoprotein of immunoglobulin superfamily, at least 27 alternatively spliced NCAM mRNAs are produced giving wide diversity

of NCAM isoforms like NCAM-120KDa (GPI anchored), NCAM-140KDa (short cytoplasmic domain), NCAM-180KDa (long cytoplasmic domain) (Reyes, *et al.* 1991).

NCAM is thought to signal to neurite outgrowth via the fibroblast growth factor receptor (FGFR) and act upon the p59fyn signaling pathway, regulates interactions between neurons and muscle (Suzuki, *et al.* 2003).

CD56 is known to be expressed in a wide variety of cell types, predominantly neural and mesenchymal origin and also in endocrine cell, CD56 normally present in follicular epithelial cells of thyroid gland and increased expression in autoimmune diseases (Langley, *et al.* 1983).

2.7 Management of thyroid cancer:

Patient with follicular neoplasm as determined with FNAB results, should undergo surgery for thyroid lobectomy for tissue diagnosis, primary treatment for papillary and follicular carcinoma (Tufano, *et al.* 2015).

The appropriate management of patient with nodal metastases may involve compartmental lymph node dissection active surveillance, radioactive iodine ablation therapy, image guided, surgical technical considerations include prior recurrences in the same or different compartments (Pacini, *et al.* 2006).

Chapter Three

Material and Methods

Chapter three

Materials and methods

3. Materials:

Archive tissue blocks previously diagnosed as thyroid neoplasms with different types were used in this study.

3.2 Methods:

3.2.1 Study design:

This is a hospital based analytical retrospective case control study aimed to detect CD56 in thyroid tumors among Sudanese patients.

3.2.2 Study samples:

Forty formalin fixed paraffin blocks of thyroid neoplasms were obtained from tissue. The malignant samples were 25 samples previously diagnosed as follow: 20(50.0%) samples were papillary thyroid cancer, 5(12.5%) samples were follicular carcinoma and the benign samples were 15 diagnosed as follow: 5(12.5%) samples were follicular adenoma, 5(12.5%) samples were goiter and 5(12.5%) samples were lymphthyroiditis. Patient identification data including age and sex was obtained from patient`s file.

3.2.3 Sample processing:

Section of 4micron in thickness was obtained from each formalin fixed paraffin wax embedded tissue using rotary microtome, mounted into charged slides (Thermo) then dewaxed in oven.

3.2.4 Staining Method:

3.2.4.1 Immunohistochemical staining:

Paraffin sections were immunostained using avidin biotin technique.

Section were put in oven at 96^oc for one hour and cleared in two changes of xylene for two minutes, then rehydrated though descending concentration of ethanol (100%, 90%, 70%, 50%) and water two minutes for each, then antigen retrieved by water bath for forty minutes, then

treated with 3% hydrogen peroxide and methanol solution for fifteen minutes, then washed in phosphate buffer saline (pH6.1) for five minutes. Then treated with CD56 primary antibody for twenty minutes, then rinsed in phosphate buffer saline. The binding of antibody detected by incubation for twenty minutes with biotin followed by fifteen minutes with strepto-avidin (Thermo Kit), then the sections were washed in three changes of phosphate buffer saline, then treated with substrate and 3,3 diaminobenzidine tetra hydrochloride (DAB) chromogen for seven minutes, then washed in phosphate buffer saline, then counter stained in Mayer`s haemtoxylin for one minute, then washed and blued in running tap water, then dehydrated through ascending concentration of ethanol (50%, 70%, 90%, 100%) then cleared in xylene and mounted in DPX mountant (Bancroft and Marilyn, 2008).

3.2.5 Result interpretation:

All quality control measures were adopted during sample staining for immunohistochemical results assessment. Positive and negative controls were used to confirm the result. Presence of five cells cytoplasmic stained brown per field consider as positive result.

3.2.6 Statistical analysis:

Data were analyzed using SPSS version 13 computer program. Frequencies, mean and chi-square test values were calculated.

3.2.7 Ethical considerations:

Hospital administration agreement were taken ethically for archive samples and patients data collection.

Chapter Four

Results

Chapter Four

Results

4.Result:

Forty blocks previously diagnosed with thyroid neoplasm, were used in this study. The study samples selected as follow: 20(50.0%) samples were papillary thyroid cancer, 5(12.5%) samples were follicular carcinoma, 5(12.5%) samples were follicular adenoma, 5(12.5%) samples were goiter and 5(12.5%) samples were lymphothyroiditis (table 4.1). The patient ages ranged between 11-70 years with mean age 27 years, most of patients 27(67.5%) were less than 50 years and the remaining 13(32.5%) were above 50 years (table 4.2). The patients sex revealed that 8(20%) patients were males and 32(80%) were females (table 4.3). Positive expression of CD56 among study samples were 25/40 samples. Positive expression of CD56 was found among benign thyroid tumor 15/15 samples and in malignant samples the expression was 10/25 samples, while the negative expression of CD56 among study samples was 15/40 samples, most negative expression of CD56 was found among papillary thyroid cancer 15/20 (P. value 0.000) (table 4.4).

Table(4.1) : Distribution of histopathological diagnosis among study population:

Type of study samples	Histopathological diagnosis	Frequency	Percent
Malignant	Papillary thyroid cancer	20	50%
	Follicular thyroid cancer	5	12.5%
Benign	Goiter	5	12.5%
	Follicular adenoma	5	12.5%
	Lymphothyroiditis	5	12.5%
	Total	40	100%

Table (4.2) : Distribution of age group among study population:

Age group (years)	Frequency	Percent
Less/equal 50 years	27	67.5%
More than 50 years	13	32.5%
Total	40	100.0%

Table (4.3) : Distribution of sex among study population:

Sex	Frequency	Percent
Males	8	20%
Females	32	80%
Total	40	100%

Table (4.4) : Relation between CD56 expression and histopathological diagnosis of thyroid tumor:

Histopathological diagnosis	Expression of CD56		Total	P.value
	Positive	negative		
Malignant	10(25.0%)	15(37.5%)	25(62.5%)	0.000
Benign	15(37.5%)	0(0.0%)	15(37.5%)	
Total	25(62.5%)	15(37.5%)	40(100%)	

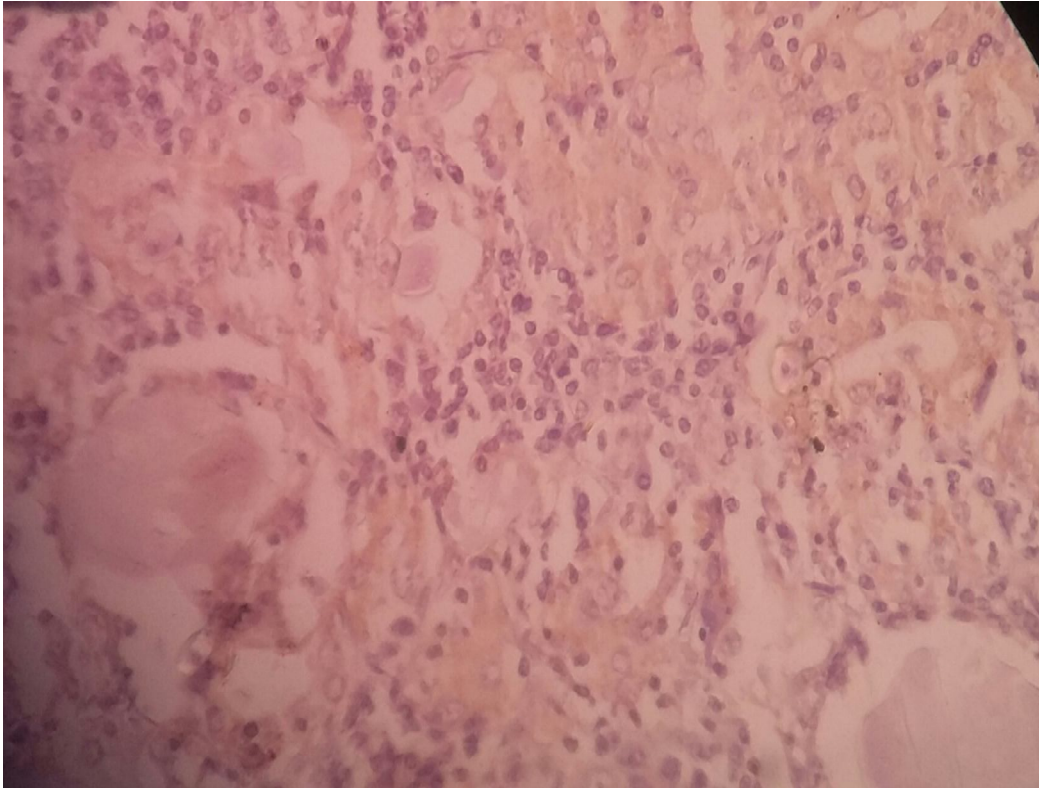


Figure (4.1) : Lympho thyroiditis shows positive cytoplasmic expression of CD56 (40X).

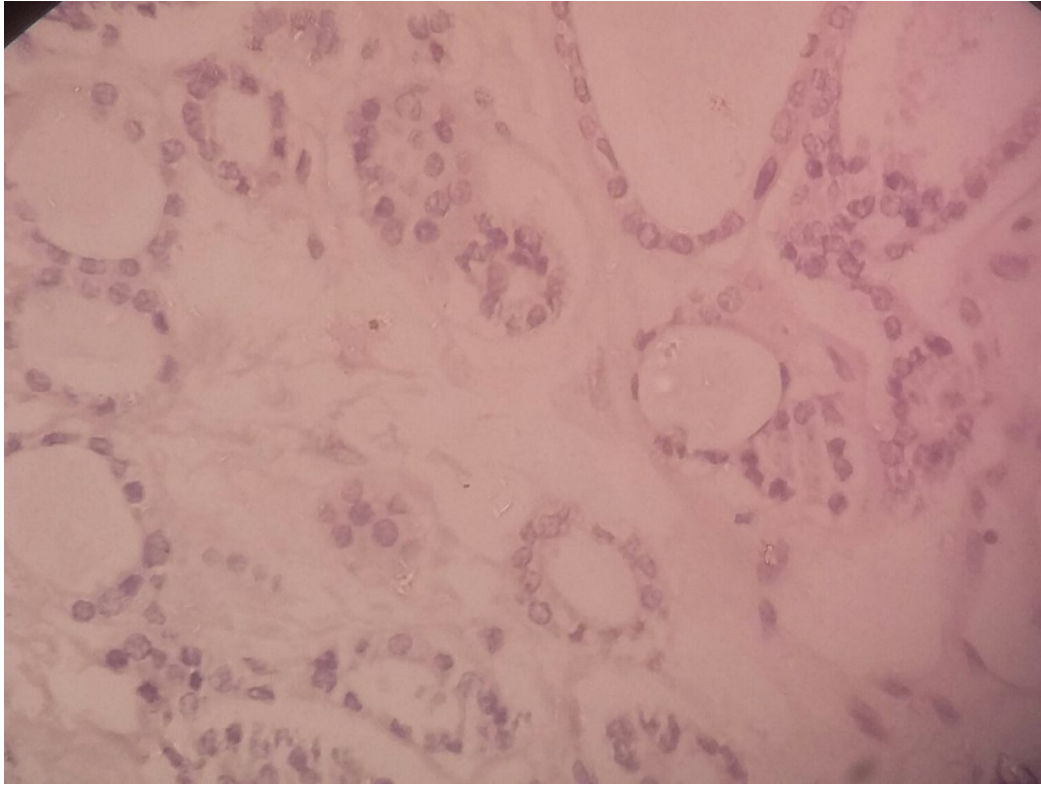


Figure (4.2) : Papillary thyroid cancer shows negative cytoplasmic expression of CD56 (40X).

Chapter five

Discussion

Chapter Five

Discussion

5. Discussion:

The present study aimed at immunohistochemical staining for detection of CD56 in thyroid tumor among Sudanese patients.

Regarding the age of the patients the study revealed that most of patients were less than 50 years. This result is compatible with Rosai *et al.* (2011), who reported that thyroid cancer is more common in young and middle aged adults. The mean age at diagnosis is 40 years.

The study revealed that most of patients were females, the females/males ratio was 4:1. This result agrees with Topliss (2004), who reported that the females to males ratio of patients was 2.9:1.

The positive expression of CD56 in benign thyroid as well as in follicular carcinoma was (100%). This result showed a significant relation between CD56 expressions and histopathological diagnosis of thyroid neoplasms (P. value 0.000). That means our results of the CD56 expression among examined thyroid cases, showed a marked characteristic of full expression within all benign cases (goiter, lymph thyroiditis and follicular adenoma) in addition to all cases of follicular carcinoma, while such reactivity was missing within papillary cancer cases examined at this study, however five cases showed strong positive cytoplasmic staining. This finding has been found in agreement with Etem *et al.* (2010), who reported that a significant reduction of CD56 expression in PTC cases and more than 10% of tumor cells were positive for this marker. Also compatible with Park *et al.* (2009), they reported that there was no staining with CD56 in 92.5% of PTC cases, they found strong staining only in one case of PTC.

On other hand not compatible with El Demellawy *et al.* (2008), who reported that 100% negativity in PTC cases and 100% positivity in other benign lesions.

Chapter Six

Conclusion and Recommendations

Chapter Six

Conclusion and recommendations

6. Conclusion and recommendations:

6.1 Conclusion:

On basis of this study we conclude the follow:

- The age of the thyroid cancer among study group is commonly less than 50 years.
- Most histological type of thyroid cancer – in the study samples – is papillary thyroid cancer.
- CD56 positive expression is associated with benign thyroid tumor.

6.2 Recommendations:

On basis of this study we recommend the follow:

- Further study should be done for expression of CD56 in thyroid cancer with large sample size.

References

References

Abdelatti,R.M. and Shash,L.S. (2012). Potential diagnostic utility of CD56 and claudin-1 in papillary thyroid carcinoma and solitary follicular thyroid nodules, *Journal of Egypt National Cancer Institute*, **24**:175-84.

Bancroft,J.D. and Marilyn,G. (2008).Theory and practice of histological techniques, 6th edition, London, New York, Oxford Philadelphia, St Louis Sydney Toronto, PP.423-538.

Benedbaek,F.N., Perrild,H. and Hegedus,L. (1999). Diagnosis and treatment of the solitary thyroid nodule, *European Surgical Clinical Endocrinal*, **50**(3):537-63.

Brito,J.P., Morris,J.C. and Montori,V.M. (2013). Zealous imaging has increased detection and treatment of low risk tumors, *Thyroid Cancer Journal*, **347**:14706.

Brindel,P., Doyon,F. and Bourgain,C. (2010). Family history of thyroid cancer and the risk of differentiated thyroid cancer, French, Polynesia, **20**:393-400.

Carling,T., Undelsman,R., Devita,V.T., Lawrence,T.S., Rosenbers,S.A. (2011). Devita Hellman and Rosenberg's cancer : *Principles and practice of oncology*, 9th edition, Philadelphia, Lippincott, PP. 1457-1472.

Cuveller,P., Biet,A., Boute,P., Lande,M., Strunski,V. (2009). Anatomical and surgical experiences, *The Journal of Laryngology and Otology*, **123**(7):768-71.

Eldemellawy,D., Nasr,A.L., Baby,S., Alowami,S. (2009). Diagnostic utility of CD56 immunohistochemistry in papillary carcinoma of the thyroid, *pathology Research Practical*, **205**(5):303-309.

Etem,H., Ozekinci,S., Mizrak,B., Senturk,S. (2010). The role of CD56 in follicular neoplasms of the thyroid, Turk, *Journal of pathology*, **26**:238-242.

Eills,H., Susan,G.S. and Henvy,D. (2005). Gray's anatomical basis of clinical practice, ST Louis, Elsevier, Churchill, living stone, PP. 538-539.

Finley,D.J., Arora,N., Zhu,B., Gallagher,L., Fahey,T.J. (2004). Third molecular profiling distinguishes papillary carcinoma from benign thyroid nodules, *Journal Clinical Endocrinol*, **89**:3214-23.

Goldfarb,M. and Freyer,D.R. (2014). Comparison of secondary and primary thyroid cancer in adolescents and young adults, *Cancer Journal*, **120**(8):1155-61.

Goldman,N.D., Coniglio,J.U. and Falk,S.A. (1996). Thyroid cancer, papillary, follicular and Hurthle cell, *Otolaryngology Clinical North America*, **29**(4):593-609.

Grunwald. (2005). National cancer database in the US states that the 14% 10years survival for anaplastic thyroid cancer was over estimated, P. 10.

Hall,P., Adami,H.O., Hunter,D., Johnson,T.L., Liloyd,R.V., Thor,A. (2008). Thyroid cancer :expression of Ras oncogene p21 antigen in normal and proliferative thyroid tissues, *Text book of Cancer Epidemiology*, 2sd edition, PP. 504-519.

Haugen,B.R., Alexander,E.K. and Bible,K.C. (2015). Thyroid association management guidelines for adult patients with thyroid nodules and differentiated thyroid cancer, *Thyroid cancer*, **26**(1):1-133.

Imaizumi,M., Usa,T., Tominaga,T., Neriishi,K., Akahoshi,M., Nakashima,E. (2006). Radiation dose response relationships for thyroid nodules and autoimmune thyroid diseases in Hiroshima and Nagasaki atomic bomb survivors 55-58 years after radiation exposure, *American Cancer Journal*, **295**(9):1011-22.

Langley,K.O., Aletsee-Ufrecht,M.C., Grant,N. and Gratzl,M. (1983). Expression of the neural cell adhesion NCAM in endocrine cells, *Journal Histochem Cytochem*, **37**:781-91.

Mitchell, Richard,S., Kumar, Vinay, Abbas, Abuk, Fausto and Nesion. (2007). Robbins Basic pathology, 8th edition, Philadelphia, Saunders, 2973-7.

Mohamed,A.E. (2014). Goiter is endemic in Sudan and thyroidectomy is daily practice in most surgical lists across the community, *Cancer Research*, 3063-74.

Moretti,F., Nanni,S. and Pontecorvi,A. (2000). Molecular pathogenesis of thyroid nodules and cancer, *Baillieres Best Practical Research Clinical Endocrinol*, **14**:517-539.

Nixon,I.J., Ganly,I., Patel,S.G., Palmer,F.L., Dilorenzo,M.M., Grewal,P.K. (2013). The result of selection use of radioactive iodine on survival and on recurrence in the management of papillary thyroid cancer based on memorial Sloan, *Kettering cancer center risk group stratification*, **23**(6):683-94.

Neil,R. and Borley. (2008). Grasy's anatomy the anatomical basis of clinical practice, 40th edition, London, Livingstone, PP. 462-4.

Ort, Bruce,B.L. and Victoria. (2007). *Elsevier`s integrated anatomy and embryology*, Philadelphia, Elsevier, 3165-9.

Ozoline,A., Naburts,Z., Strumfa,I., Volanska,G., Stepanovs,K. and Gardovskis,J. (2012). Immunohistochemical expression of CD56 in the differential diagnosis of thyroid nodules, *Kaunas*, **48**:507-14.

Pacini,F. (2012). Thyroid cancer: ESMO clinical practice guideline for diagnosis, treatment and follow up, *Annals of Oncology*, **21**:214-19.

Pacini,F., Schlumberger,M. Dralle,H., Elisei,E., Smit,J.W., Wiersinga,W. (2006). European consensus for the management of patient with differentiated thyroid cancer of follicular epithelium, *European Journal Endocrinol*, **154**:787-803.

Park,W.Y., Jeong,S.M., Lee,J.H., Kang,H.J., Sin,D.H., Choi,K.U. (2009). Diagnostic value of decreased expression of CD56 protein in papillary carcinoma of the thyroid gland, *Basic Applied Pathology*, **2**:63-68.

Prasad,M.L., Pellegata,N.S., Huang,Y., Nagaraja,H.N., Chapelle,A., Kloos,R.T. (2005). Galectin-3, fibronectin-1, CITED-1, HBME1 and cytokeratin-19 immunohistochemistry is useful for the differential diagnosis of thyroid tumors, *Molecular Pathology*, **18**:48-57.

Pellegriti,G., Frasca,F., Regalbuto,C., Squatrito,S., Vigneri.R. (2013). Worldwide increasing incidence of thyroid cancer: update on epidemiology and risk factor, *Journal Cancer Epidemiology*, **2013**:965212.

Rehman,A.G., Tyson,M., Egger,M., Heller,R.F., Zwahlen,M. (2008). Body mass index and incidence of cancer a systematic review and meta-analysis of prospective observational studies, *Lancet Journal*, **371**(9612):569-78.

Reyes,A.A., Smail,S.J., Akeson,R. (1991). At least 27 alternatively spliced forms of the neural cell adhesion molecules mRNA are expressed during rat heart development, *Molecular and cellular biology*, **11**(3):1654-61.

Rosai,J. and Ackerman,L.V. (2011). Rosai and Ackerman`s surgical pathology, 10th edition, Elsevier Mosby, PP.504-5014.

Stonenica,L., Senkov,O., Gerardy-schanhn,R., Weinhold,B., Schachner,M., Dityatev,A. (2006). In vivo synaptic plasticity in the dentate gyrus of mice deficient in the neural cell adhesion molecule NCAM or its polysialic acid, *The European Journal of Neuroscience*, **23**(9):2255-64.

Suzuki,M., Angafa,k., Nakayama,J., Fukuda,M. (2003). Polysialic acid and mucin type o-glycan on the neural cell adhesion molecule differentially regulate myoblast fusion, *The Journal of Biological Chemistry*, **278**(49):49459-68.

Topliss,D. (2004). The ignorant in pursuit of the impalpable, *Clinical Endocrinology*, Oxford, **60**:18-20.

Tufano,R.P., Clayman,G. and Hetter,K.S. (2015). Management of recurrent ,persistent nodal disease in patient with differentiated thyroid cancer: a critical review of the risks and benefits surgical intervention versus active surveillance, *Thyroid Cancer*, **25**(1):15-27.

Wells,S.A., Asa,S.L. and Dralle,H. (2015). Revised American thyroid association guidelines for the management of medullary thyroid carcinoma, *Clinical Oncology*, **25**(6):567-610.

Yeh,M.W., Baver,A.J. and Bernet,V.A. (2015). American thyroid association statement on preoperative imaging, *Thyroid Cancer Surgery*, **25**(1)3-14.

Zimmermann,M.B., and Boelaert,K. (2015). Iodine deficiency and thyroid disorders, *Lancet Diabetes Endocrinology*, **3**:286-95.

Appendices

Appendices

Instrument and Material:

Instrument:

Disposable gloves.

Rotary microtome.

Microtome Knives.

Coplin jars.

Oven .

Staining racks.

Coated slides.

Water path.

Cover glass.

Dako pen.

Humidity chamber.

Materials:

Mayer`s haemtoxylin .

Xylene.

Ethyl alcohol (absolute,90%,70%,50%).

Distilled water.

Peroxidase blocker .

Primary antibody (CD56).

Secondary antibodies (biotinylated secondary antibody).

3.3 di amino benzidine tetra hydrochloride in substrate buffer .

DPX mounting media.

Phosphate (PH 7.4) component:

Solution A(0.2 M sodium di hydrogen orthophosphate, 3.12g di sodium hydrogen orthophosphate, 100 ml DW).

Solution B (0.2 M sodium di hydrogen orthophosphate, 2.83g di sodium hydrogen orthophosphate, 100ml DW)(9.5ml from solution A +40.5ml solution B).

Citrate buffer(PH6.8) component:

Solution A(0.2M sodium di hydrogen orthophosphate, 2.83g di sodium hydrogen orthophosphate, 100ml DW).

Solution B (2.1g citric acid, 100ml DW)(27.7ml from solution A+22.8ml from solution B).

Mayer`s haematoxlin component :

Haematoxlin powder	1 gm
Potassium alum or ammonium alum	50gm
Sodium iodate	0.2gm
Citric acid	1 gm
Chloral hydrate	50gm
Distilled water	1000ml
Ammoniated water:	
Concentrated ammonia	0.05ml
Tap water	99.95 ml