



## Extracorporeal Septoplasty in Correction of Deviated Nose via Closed Septorhinoplasty Approach.

Salim Hussain Ibrahim

M. B. Ch. B /D.L.O/ F.I.C.M.S.(ENT)

Tikrit University /Medical College -Iraq

\*Corresponding Author: E. mail :drsalimh@yahoo.com

Article history: Received: July 2017

Accepted: August 2017

### Abstract :

Extracorporeal septoplasty (ECS) is a surgical approach for correction of severe septal deviation. This is a retrospective case study to find the percentage, nasal septal pathology, and outcomes of ECS among patients with deviated nose treated by primary closed septorhinoplasty at Salah-Elden governorate in Iraq during six years period. The percentage of indication for ECS in correction of a deviated nose was (22.6 %, 26 out of 115 patients). The nasal septal pathology was mainly in the anterior part, in cottle's area I, pathology was found in all (26 patients,100%) and in cottle's areas II and III was (92.3%).

The neoseptum with the spreader grafts was fixed dorsally by two transcutaneous sutures and caudal septum fixed into groove between medial crura and to the anterior nasal spine. Patient and surgeon satisfaction regarding the cosmetic outcomes were very good in (22 patients, 80.8%), while excellent functional outcomes happened in (25 patient, 96.2%) who get relief of nasal obstruction.

**KEYWORD:** Septal deviation, Cottle's septal areas, Nasal trauma.

© 2017 Sudan University of Science and Technology, All rights reserved

### INTRODUCTION

The deviated nose commonly associated with nasal septal deviation as the dictum said 'As the septum goes, so the nose goes'<sup>1</sup>, resulting in external nasal deformities and nasal obstruction affects patient's quality of life<sup>2</sup>. The septal correction play important role in straighten the nose and improve nasal respiration. There are no standard surgical approach to correct all types of septal deviations. The history of surgical approaches for nasal septal correction as follows. The submucosal resection of quadrilateral cartilage as promoted by Freer<sup>3</sup> and Killian<sup>4</sup> was standards operation for correction of septal deviation until 1960s, but it frequently cause nasal saddling, retraction columella and septal perforation. Cottle at 1963 gives more delicate procedure of endonasal septoplasty, were

reconstruction of nasal septum instead of resection and to deal with function and cosmetics in one procedure<sup>5</sup>. Goodman at 1973 introduced the open approach septoplasty<sup>6</sup>.The extracorporeal septoplasty (ECS) first described by King and Ashley in 1952<sup>7</sup> and Perret1958<sup>8</sup> they suggest removal of the whole septum bony and cartilaginous parts, straighten and reimplemented. Since then, Gubisch 1995<sup>9,10</sup>, Most SP 2006<sup>11</sup>, they simplified technique but still relied on a reconstructed septum of the original cephalocaudal length that had to be fixated to the anterior nasal spine itself after drilling a hole. Matt A. Wilson, et al. 2011 reported new technique via external approach said no need to fixed the neoseptum to nasal spine<sup>12</sup>. Other authors have discussed their different techniques of extracorporeal septoplasty and outcomes. .

The aim of this work is to find the incidence, the septal pathology, surgical approach and outcomes of extracorporeal septoplasty (ECS) in the correction of deviated nose via closed approach septorhinoplasty.

### Patients and methods

A retrospective case study of (26) patients with deviated nose underwent extracorporeal septoplasty (ECS) for nasal septal correction from a total of (115) patients underwent primary closed (endonasal) approach septorhinoplasty, in Salah-Elden governorate, Iraq, during the period from June 2010-June 2016. Male patients were (16, 61.5%) and females were (10 patients, 38.5%). Age range from 17- 42 year (mean age was 25 years old).

Preoperative evaluation including detailed history, full ENT examinations, including inspection of external nose, diagnostic nasal endoscopy, and photographs in four standard views was done for all patients.

The patients were classified according to the type of external nasal deviation into three groups.

- 1.C-shape deviation.
- 2.S-shape deviation.
- 3.Generalized deviation to one side.

The septal pathology classified according to Cottle's classification of septal areas (1960) (Figure 1), by preoperative nasal endoscope and nasal findings during the operation which gives more details about nasal septal deviation. The septal pathology either deviation, spur or dislocation.

Follow up of the patients for a minimum period of 6 months, by Photographic and endoscopic assessment, and questionnaire the patient about nasal airway patency and patient's satisfaction regarding cosmetic outcomes.

### The preparation and fixation of the neoseptum

The insertion of the neoseptum usually as last step of septorhinoplasty. The removed deviated nasal septum has been straightened

by smoothing of sharp edges of the cartilage by a blade or crushing. The nasal spurs were straighten by removal stripe of cartilage (wedge resection) then fixed by suturing or use stenting graft taken from septal cartilage or bony perpendicular plate of ethmoid bone.

Spreader grafts taken from septal cartilage were sutured by 6/0 nylon to upper border of the septum bilaterally. The neoseptum fixed dorsally by two transcutaneous U shape suture (Figure 3). The caudal septum fixed into groove between medial crura "Tongue in groove" technique suture with 3/0 vicryl suture and to anterior nasal spine or maxillary crest periostium with permanent suture 3/0 nylon. For more fixation 2-3 transmucosal suture done using 3/0 vicryl suture. Dorsal irregularities may occurs especially in thin nasal skin at rhinon treated by as dorsal on-lay graft using the cartilage excised from cephalic resection of lateral crus of lower lateral cartilage when tip plasty indicated. Insert plastic splint and light anterior nasal pack, finally Plaster of Paris (POP) cast applied. The anterior nasal pack removed after 24 hr, POP removed after 10 days, both plastic splint and transcutaneous sutures removed after 14 days.

### RESULTS

During six years period, twenty-six patients required extracorporeal septoplasty from a total (115) patients with deviated nose underwent primary closed approached septorhinoplasty (22.6 %).

All (26) patients (100%) underwent extracorporeal septoplasty presented complaining from nasal obstruction seeking for cosmetic and functional improvement. History of nasal trauma were in (23 patients, 88.5%).

The decision for ECS was made in (14 patients , 54%), the decision had been taken during the surgery in (8) patients due to preoperative septal findings which show that it difficult to get stable and straight septum by standard endonasal septoplasty, while in the rest (6) patients the decision

was taken during surgery due to septal collapse. In the other (12 patients, 46%) of the total (26) ECS were planned before surgery (Table 1) and (Figure 2).

Extracorporeal septoplasty was done for (15 patients, 22%) with C-shape nasal deviation, (10 patients, 9%) with S-shape deviation, and (5 patients, 14%) with generalized nasal deviation to one side (Table 2).

Endoscopic and operative findings shows that (21 patients, 81.5%) have impacted septal deviation to one side and severe septal angulations, that contacts the lateral nasal wall, and not separated from the turbinate by vasoconstrictors according to Cottle's classification<sup>13</sup>, and (5 patients, 18.5%) with obstructed type of septal deviation. The septal deviations were commonly in cephalo-caudal direction in (22 patients, 85%). According to Cottle's areas of the septal pathology, the researcher found the following:

Area I: Vestibular area, all patients (26 patients, 100%) have caudal dislocation, common to right side (17 patients, 65.4%).

Area II: Valvular area, in (24 patients, 92.3%) common to left side in (17 patients, 70.8%).

Area III: Attic area, in (24 patients, 92.3%) commonly to left (16 patients, 66.7%).

Area IV: Lower mid portion of the septum, in (15 patients, 57.7%). Right sided in (9 patients, 60%)

Area V: Posterior turbinate area, in (2 patients, 7.7%) one for sides (Table 3).

Very good cosmetic results were found in (21 patients, 80.8%) both the surgeon and patient were satisfied by the results, three patients (11.5%) with reasonable results, were the patient is satisfied but not the surgeon as minor dorsal irregularities present, Poor cosmetic outcomes were in two patients (7.7%) in early cases whose done by the author, there are dorsal irregularity and deviation (Table 4).

Best cosmetic outcomes occurs in C-shape nasal deviation, where the good results were present in (86.8%)(Figure 4), then generalized deviation in (80%) (Figure 3) and S-shape deviation (67%) (Figure 5).

Relieve of nasal obstruction in (5 patients, 96.2%), (1 patient, 3.8%) with C-shape nasal deviation have gotten a nasal obstruction due to recurrence of deviation.(Table 4).

No septal abscess, no septal perforation, no intranasal adhesion were reported.

## DISCUSSION

The nasal trauma especially in childhood is the cause of deviated nose and sever septal deviation, because either the patient not treated at that time or ill-treated which means that the treatment includes only correction of the fractured nose ( external deformities) without correction to the septal pathology, which usually neglected and later on leads to recurrence of the external nasal deviation, septal deviation and dislocation or spur formation resulting in nasal obstruction<sup>1,14</sup>. This study found that all (26 patients, 100%) underwent extracorporeal septoplasty complaining from nasal obstruction, and (23 patients, 88.5%) have history of nasal trauma. In the patients without history of nasal trauma, the septal deviation was attributed to unrecognized birth trauma or early childhood trauma that disrupt the growth centers of the septum and resulting in marked abnormal development that manifest itself at puberty.(TerKonda and Sykes)<sup>15</sup>.

Extracorporeal septoplasty was done for patients with severe septal deviations, (14 patients, 53.8%) who they have deformities in three septal areas, and (12 patients, 46.2%) have deformities in four septal areas mainly in the anterior nasal septal parts (cottle's areas I, II, and III), these areas usually need to be corrected more conservatively unlike the posterior nasal septal areas (Cottle's areas IV and V) where we can remove much of cartilage and bone

without affecting the nasal shape and dorsal nasal support. Many studies were agree with our findings, like Gubisch W<sup>9</sup> and André Vuyk et al.<sup>16</sup>, they used ECS for correction of severely deviated caudal septum. A study done by Most SP<sup>11</sup> who use ECS for anterior septal reconstruction. Another study done by Matt A. Wilson, Steven R.<sup>12</sup>, they select ECS technique for correction of a C- or cup-shaped septum and/or the septum came off the nasal spine at an angle of greater than 30° in the axial plane, using external septorhinoplasty approach.

The endonasal septoplasty was regarded as a standard approach for correction of deviated septum<sup>12</sup>, in our study, it has been done in (89 patients, 77.4%) with deviated nose (Table 2). The endonasal septoplasty may be inadequate for correction of impacted nasal septal deviation especially with cephalocaudal septal deviations or spur that may need more radical septal surgery includes maximal septal cartilage resection with aggressive cross hatching. This may cause weakening and instability of the nasal dorsum and even collapse of the nasal septum during the operation or post operatively.

Intraoperative septal collapse occurs in (6 patients, 5.2%) and regarded as an indication for ECS. It occurs during correction of the severe deviated nasal septum in deviated nose where complete freeing of the cartilaginous septum from all its' attachments are needed, inferiorly (from maxillary crest and nasal floor), posteriorly (from vomer and perpendicular plate of ethmoid bones) and superiorly from upper lateral cartilage, this especially happen with high septal deviation in the Key stone area of nasal septum at the rhinion causing an increased risk of septal collapse.

The surgical approach used in this study is closed (endonasal) septorhinoplasty which is challenging, time-consuming procedure and associated with difficulties in fixation of the resected cartilage and in realignment

of nasal dorsum<sup>17</sup>, but with practice, it gives good cosmetic and functional outcomes. Tasca I, Compadretti GC<sup>17</sup> use ECS for correction of the anterior markedly deviated nasal septum via an endonasal approach. Other authors as Gubisch since 1996 used an open approach<sup>14</sup>, as he found that open approach superior to the endonasal approach for the improved visualization because it provides a precise dissection and replantation. Other authors not agree about the use of ECS in the management of deviated nose via external (open) approach septorhinoplasty like Hossam and foda<sup>18</sup>, they believes that if the cartilage can be straightened outside the nose it can also be straightened in situ without compromising its' structural role in dorsal and tip support as external rhinoplasty approach provides an excellent exposure of dorsal and caudal parts of the nasal septum, allowing the most complex corrective maneuvers for septal deviation to be conducted with ease under vision.

Basically extracorporeal septoplasty involved in the removal of all the nasal septum<sup>9,11</sup>, but removal of all the nasal septum is not always indicated, as the parts of the septum to be removed is depends on the extent of the septal deviation. It is important to avoid key stone area disruption and its' attachments between the cartilage and the perpendicular plate of ethmoid bone at the rhinion which is always must be preserved to eliminate the risk of a step deformity leads to visible notch at the rhinion especially in thin skin<sup>19</sup> where dorsal irregularity is a common complications, The author use the cartilage that removed from lateral crus of lower lateral cartilage to cover the notching at rhinion with success. The spreader grafts used for straighten the septum and prevent collapse of nasal valve and to get wide nasal valve, (96.2%).of patients have gotten functional improvement by improving nasal patency. Spreader graft also straighten the middle third and reduce the incidence of inverted V deformity<sup>19</sup>.

Major complications occurs in (3 patients, 11.5%),two patients of them, 7.7% get obvious dorsal irregularity and deviation , and in one patient , 3.8% gets nasal obstruction with recurrence of deviation to one side. Gubisch in 2005 has been used ECS procedure for the marked deviated septum and he report 14 postoperative complications : 13% of such complications occurred, with 12 patients while, 11% of patients complaining of dorsal irregularities and in 2 patients (2%) noting recurrent septal deviation<sup>10</sup>. Ghaisas,&Parab,et.al.<sup>20</sup> have done a retrospective study of 112 patients who underwent extracorporeal septoplasty, the complications like septal perforation, bleeding, aesthetic complications were only happened in (9%) of patients.

## CONCLUSION

The use of extracorporeal septoplasty (ECS) for correction of deviated nose via closed approach septorhinoplasty get a good cosmetic and functional outcomes. The percentage of the indications for ECS in correction of deviated nose via closed septorhinoplasty was 22.6 %. ECS has been indicated when standared endonasal septoplasty found to be inadequate for correction of septal deviation. It is commonly indicated in 60% of cases with S-shape nasal deviation. The nasal septal pathology were mainly in the anterior nasal septum in the (Cottle's areas I, II and III.). The cosmetic outcomes were very good in (80.8%) of patients. and 96.2% of patients have gotten an excellent functional outcomes through relief of nasal obstruction.

## REFERENCES

1. Wolfgang Gubisch \_ VikasSinha. Extracorporeal septoplasty–how we do it at marienhospitalstuttgartgermany. Indian J. Otolaryngol. Head Neck Surg.(January-March 2008) 60:16–19.

2.Pastorek NJ, Becker DG. Treating the caudal septal deflection. Arch Facial Plast Surg. 2000;2(3):217-20.

3.Freer O. The correction of deflections of the nasal septum with minimum of traumatism. JAMA 38:636–692, 1902.).

4. Killian G. DiesubmukoseF Ensterresektion der Nasenscheiderwand. Arch Laryngol Rhinol (Berl) 16:326, 1904

5.Adrian F von Olphen .The septum. MichaelGleeson.Scott-Brown's otorhinolaryngology,Headand neck surgery. sevenedition.Edward Arnold (publishers). 2008;P:1569-1581.

6.Goodman WS.External approach to rhinoplasty. canadian journal of otolaryngology. 1973;2:207-210.)

7. King ED, Ashley FL. The correction of the internally and externally deviated nose. *PlastReconstrSurg (1946)*. 1952;10(2):116-120

8. Perret P, Correction chirurgicale des nezdevics. Pract Otorhinolaryngology (Basel) 1958;20:115-124.

9.Gubisch W. The extracorporeal septum plasty: a technique to correct difficult nasal deformities. *PlastReconstr Surg*. 1995;95(4):672-682.

10.Gubisch W. Extracorporeal septoplasty for the markedly deviated septum. *Arch Facial Plast Surg*. 2005;7(4):218-226.

11.Most SP. Anterior septal reconstruction: outcomes after a modified extracorporeal septoplasty technique. *Arch Facial Plast Surg*. 2006;8(3):202-207

12.Matt A. Wilson, MD; Steven R. Mobley, MD.Extracorporeal Septoplasty Complications and New Techniques.Arch Facial Plast Surg. 2011;13(2):85-90.

13.V.Familiar Carrasco,S.ManchevaManeva,etal.Nasal septum anatomy and deviations: beyond

straight and flat. European Society of Radiology  
 /www.myESR.org.DOI:10.1594/ecr  
 2015/C-1810.

14 .Wolfgang Gubisch, M.D.Twenty –five years experience with extracorporeal septoplasty. facial in plastic surgery/volume 22, number 4 ,2006.

15.TerKondaRP,SykesIM.Repairing the twisted nose.OtolaryngologyClin North Am.1999;32:53-64.

16.André RF, Vuyk HD. Reconstruction of dorsal and/or caudal nasal septum deformities with septal battens or by septal replacement: an overview and comparison of techniques. Laryngoscope. 2006;116(9):1668-73.

17.Tasca I, Compadretti GC, Losano T, Boccio C, Lijdens Y (2016) Nasal Valve Stabilization in Extracorporeal Septoplasty. J Oto Rec Surg 2(1):112.Doi: <http://dx.doi.org/10.19104/jors.2016.112>.

18.HossamM. T. Foda.The role of septal surgery in management of the deviatednose *Plast.Reconstr.Surg*.115:406,2005.

19. Martyn Mendelsohn. Srtiaight the crooked middle third of the nose. *Arch Facial Plast .Surg*. 2005;7:74-80.

20. Ghaisas, Parab, et al. Role of Extracorporeal Septoplasty in Deviated Noses. Indian Journal of Otolaryngology and Head & Neck Surgery September 2015, Volume 67, Issue 3, pp 205–20

**Table 1:Types and percentages of septoplasty in deviated nose.**

Endonasal septoplasty	Extracorporeal septoplasty No. 26(22.6%)			Total
	Planned ECS	Per operative decision		
		Difficult for endonasal septoplasty	Due to Septal collapse	
89(77.4%)	12(10.4%)	8(7%)	6(5.2%)	115(100%)

**Table2 :The percentage of endonasal septoplasty and extracorporeal septoplasty according to the types of deviated nose.**

Type of deviated nose	Total No.(%)	Endonasal septoplasty(%)	Extracorporeal septoplasty(%)
C-shape	69 (60 %)	54(78%)	15(22%)
S-shape	10 (9%)	4(40%)	6(60%%)
Generalized deviation	36(31%)	31(86%)	5(14%)
Total	115(100%)	89(77.4%)	26(22.6%)

**Table 3: Septal pathology in cases of extracorporeal septoplasty, according to Cottle's classification of septal deformities. areas, and the side.**

Septal area	Left side	Right side	total
Area I	9 (34.6%)	17 (65.4%)	26 (100%)
Area II	17 (70.8 %)	7 (29.2%)	24 (92.3 %)
Area III	16 (66.7%)	8 (33.3%)	24 (92.3%)
Area IV	6 (40%)	9 (60%)	15 (57.7%)
Area V	1(50%)	1 (50%)	2 (7.7%)

\*No patient with septal perforation . All the patients had septal deviations involved multiple Cottle's areas as follows:

Area I,II,III = (11 patients) (42.3%).

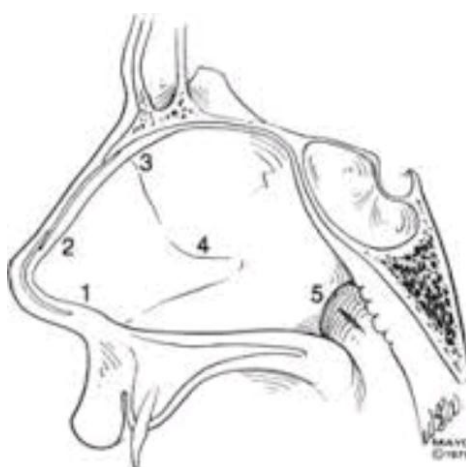
Area I,II,III,IV = (10 patients) (38.5%).

Area I,II,IV = (3 patients) ( 11.5%).

Area I,III,IV,V = (2 patients) (7.7%).

**Table 4: Outcomes of extracorporeal septoplasty in deviated nose.**

Type of deviated nose	Extra-corporeal septoplasty	Cosmetic results			Functional results	
		Good results	Reasonable	Poor results	Patent nose	Unilateral nasal obstruction
C-shape	15	13(86.6%)	1(6.7%)	1(6.7%)	14(93%)	1(6.7%)
S-shape	6	4 (67%)	1(16.5%)	1(16.5%)	6(100%)	0
Generalized deviation	5	4 (80%)	1(20%)	0	5(100%)	0
Total	26	21(80.8%)	3(11.5%)	2(7.7%)	25(96.%)	(3.8%)



**Figure 1 : Cottle's classification of areas of the nasal septum.**

Area 1(I): Vestibular area (caudal septum).

Area 2(II): Valvular area (nasal valve).

Area 3(III): Attic area (superior mid-portion of the septum).

Area 4(IV): Lower mid-portion of the septum.

Area 5(V): Posterior turbinate area (remaining posterior region).

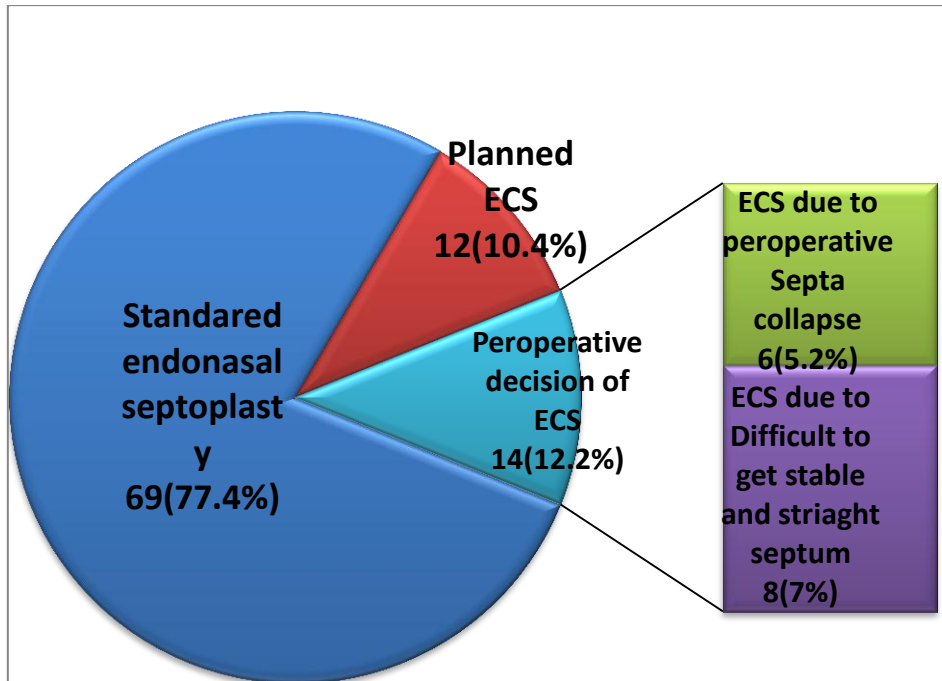
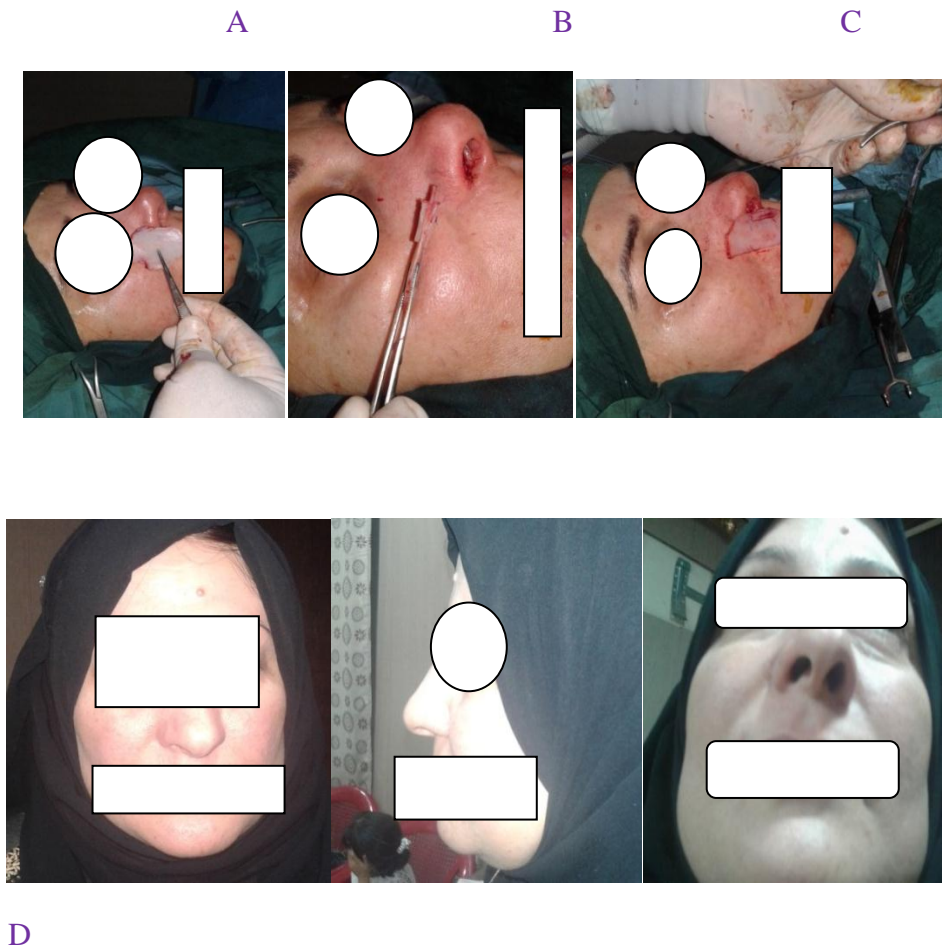
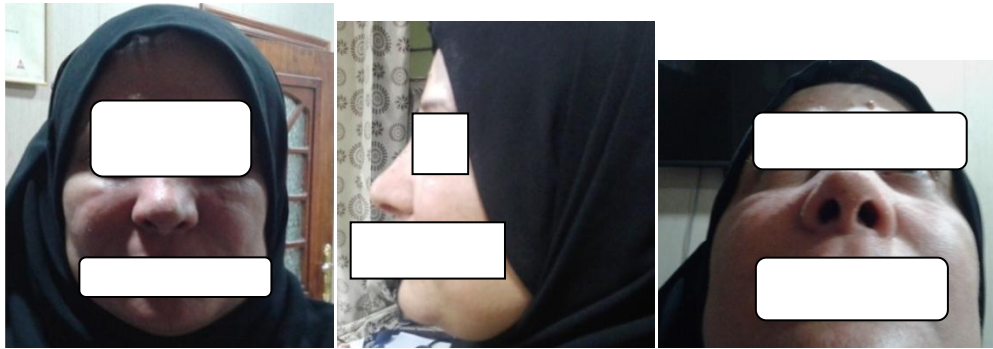

Figure 2 :Types of septoplasty in correction of deviated nose



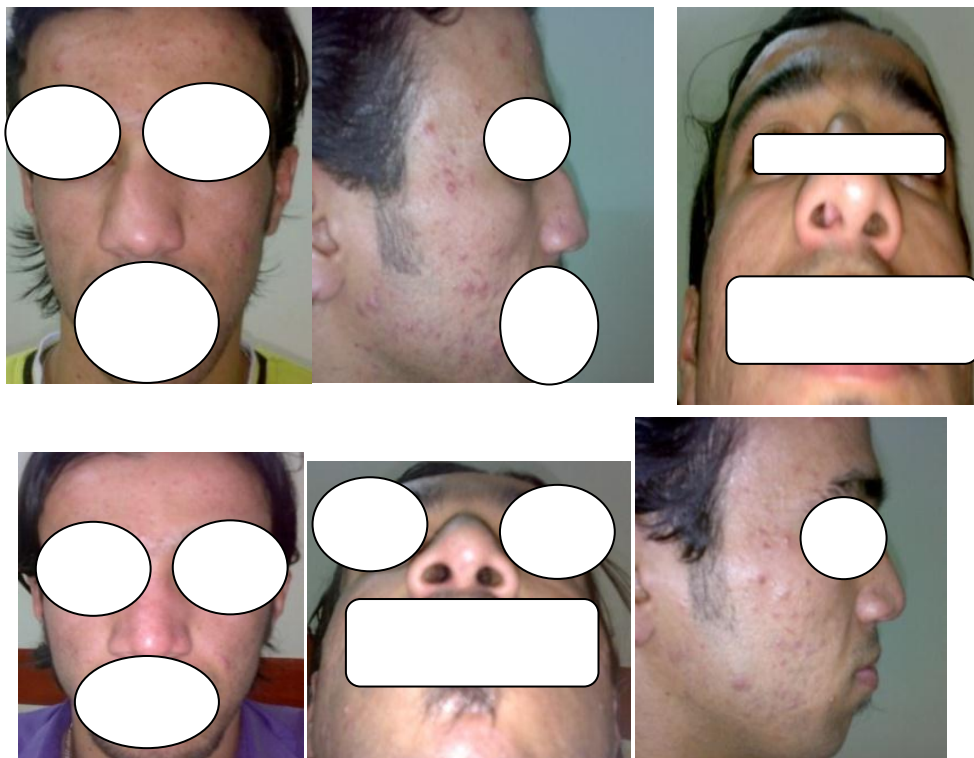




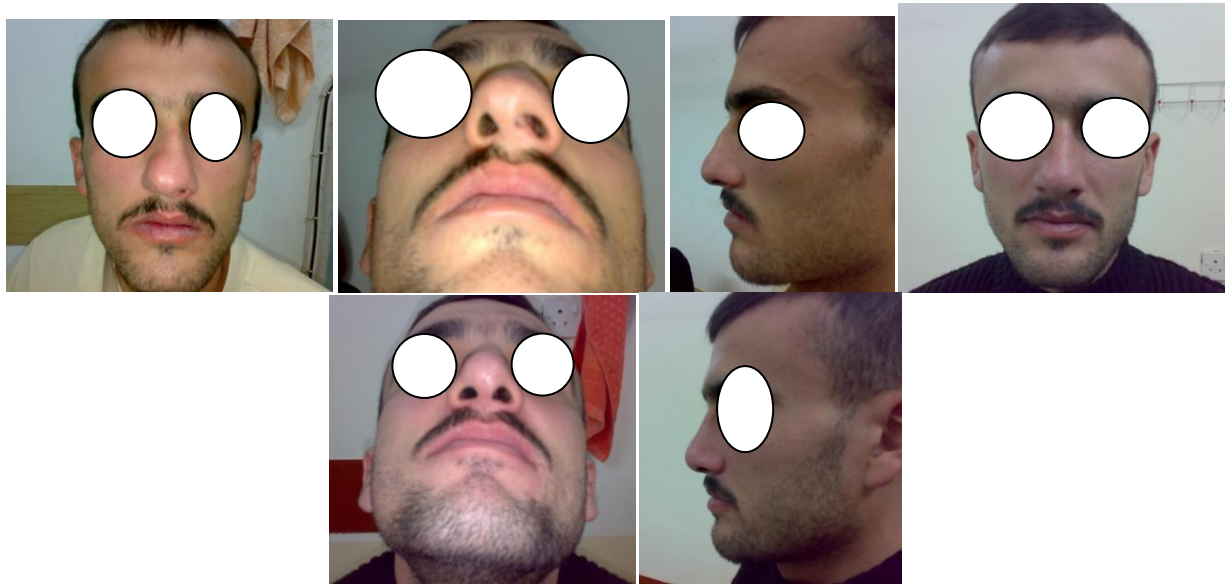E

**Figure 3: 45 years old female with generalized deviation of the nose to left side . Extracorporeal septoplasty done for septal correction :**

- (A)The septum extracted.
- (B)Spreader graft sutures to the neoseptum(white arrows).
- (C)Two transcutaneous sutures before insertion of the neoseptum (white arrows)
- (D) Preoperative photographs(frontal, lateral, and basal views).
- (E) post operative photographs.



**Figure 4: Patient with C-Shape nasal deviation with obvious caudal dislocation . Septal correction was done by extracorporeal septoplasty.pre and post operative photograph .**



**Figure 5 : Patient with S-shape nasal deviation, septal correction was done by extracorporeal septoplasty. Preoperative and postoperative photograph.**