

بسم الله الرحمن الرحيم

**Sudan University of Science and Technology
College of Animal Production**

**Department of Fisheries and Wildlife Science
(Graduation Project)**

**A survey of Internal parasites of Dorcos gazelle (Gazella dorcas)
in Kuku Zoo**

مسح للطفيليات الداخلية لغزال الدوركاس

**Thesis submitted in partial fulfillment of the Requirements of
the Degree of Bachelors (honors) fisheries and Wildlife science.**

By:

-Fatma Mohammed Abdo Al Salam.

-Maaza salih Yhya Ali.

Supervisor:

Prof: Ali Saad Mohammed

2017

الاستهلال

قال تعالى:

(كأنهم حمر مستنفرة ، فرت من قسورة)

صدق الله العظيم

سورة المدثر (50-51).

DEDICATION

We dedicate this work to our:

Father

Mothers

Specially our Husbands

Brothers ...

Sisters

Teachers

And our friends...

ملخص الدراسة:

اجريت الدراسة الراهنة لغزل والتعرف على بعض الطفيليات الداخلية في غزال الدوكاس ، هذا الحيوان العاشب المحفوظ تحت الاسر في حديقة كوكو للحيوانات ، وتم فحص عينات براز الغزال في معمل الطفيليات بكلية الطب البيطري والانتاج الحيواني بجامعة السودان للعلوم والتكنولوجيا بطريقة المسحة البسيطة المباشرة واتشف بيوض الديدان الاسطوانية منها.

Trichuris Trichura , Nematode

بعد كل الفحوصات المعملية اتضح ان هنالك ديدان اسطوانية فقط بينما لا توجد ديدان مفلطحة ولا شريطية ، هذه الدراسة اوضحت ان الاصابة بالديدان الاسطوانية اعلى من غيرها.

Table of contents:

contents	Page No.
الاستهلال	B
Dedication	C
ملخص الدراسة	D
Abstract	F
Chapter One: Introduction	1
Chapter: Two: Literature Review	3-4
Chapter : Three: Material and methods	6
Chapter Four: Results	8-11
Chapter Five: Dissection	13
Conclusion and Recommendation	15
References	17-19

Abstract:

A surveillance was carried out in Kuku zoo by examining faecal specimens of dorcas gazelle for detection of parasitic eg. The method used direct smear. The prepared slide of the faecal specimen was mounted under microscope lens (x10). The results have shown low infestation by detecting eggs of a nematode species and tracheas species in 16 out of the 64 smears (25% each)

Chapter One

Introduction

Chapter one

Introduction:

A surveillance was conducted for identification of internal parasites of dorcas gazelle *Gazellea dorcas* in Kuku Zoo , college of Animal production and Technology, Sudan University of Science and Technology.

Faecal specimens from four individuals of dorcas gazelle (males + females). The faecal material was collected at 8:00 hours, on daily basis , for a duration of 8 consecutive days.

Direct smears were prepared from the faeces which was moistened by normal saline and the material was spread on a microscopic slide and examined under (x10 lens) microscope. 8 smears were made daily, so we have a total number of (8x8) smears for the whole period.

Objectives:

1-The main objective was to see whether dorcas gazelle infested by internal parasites.

2-To identify the species of parasites in case of their presence.

Chapter Two
Literature Review:

Chapter Two

Literature Review:

Dorcas gazelle considered as belonging to the small antelopes and known as desert gazelle.

The the length of dorcas gazelle (from head to base of tail) is (90-110 cm), height (55-65cm) and weight (15-20kg), and can run with an average speed. (48-96km/h) , (Murray , 1934).

The female gives birth to a single offspring in (5-6 months). Its life span is about (12.5 years) and 17 years in captivity , the dorcas gazelle can survive without need to water (Mubarak, 1986).

Parasites play a major role in the lives of the animals with effects ranging from negative impacts on the host population size to evaluating of host behaviors to combat parasite and in the wild , animals might have a natural resistance to infection or live mutually with their parasites (Brokovicova and change in environment and living conditions from freedom to captivity influences the animals , ecology and might increase the susceptibility to parasitic infection . many of these animals are exotic to the geographical location of the parts and zoo gardens where they are kept a number of species of animals in close proximity provides opportunity for the transmission of diseases or parasites to species which would not normally come in contact with such pathogens (Moudgil and single, 2013). Severe parasites can lead to blood loss, tissue damage , spontaneous abortion, congenital malformations and death (A dedokun et al . 20025; Emikpe et al , 2002; Despomimier 2003; Emikpe et al ; 2007).

Another possibility of parasite transmission is where animals are moved from one enclosure to another without proper parasite treatment. Mixing different species brings additional risks of parasitic infections (Gooseenesa et al , 2005) zoologist garden staff members have also been reported to play an important role in the transmission of

parasite amongst animals in zoos, though tier shoes clothes hands , food or with working tools (A detunje 2014.pyrhnsfr smf z,ptrmol rkr. 2014) carnivorous animals act as definitive hosts for many intestinal parasites, some of which are responsible for several zoonotic diseases like onylostomosis echinococcosis, gnathostomosis and toxocorosis .

Avergaour (1997) , further suggested close intervention between humans and carnivores as reasons for endemicity of these zoonotic parasite in adequate information on diseases and parasites of zoo animals is a major limiting factor in the management of zoological gardens . investigations into prevalence geographical distribution systematic and biology of parasites of zoo animals are important for planning and control of parasitic thence , the need for a regular program of gastroint estinal parasite surveillance and measures of control based on correct diagnosis effective treatment and proper prophylaxis to ensure sound health of zoo animals, this study aims to establish the profile of gastra-intestinal parasites in carnivores in three zoos in Nigeria.

Chapter Three

Materials and methods:

Chapter Three

Materials and methods:

A study for investigation of internal parasites of dorcas gazelle was conducted in Kuku Zoo the study period extended for 8 day (11/10-20/10).

Kuku zoo is situated in the premises of animals production and technology college at Hillet Kuku, Sharq Elnil locality , Khartoum state . the area of Kuku zoo is about 10 hectares, many wild animal are kept in the zoo . the study was conducted on 4 dorcas gazelle the gazells are kept in cage with the dimention 3x3x2 m.

The cage is constructed of cement floor, wire sides congaed dizine for the roof there are water basin and food containers.

Direct smear:

The Methodology faecal material (20) was spread on an a microscopic slide . few drops of water dialifed were added to the smear and mixed well the debris were prepared from different point of the focal specimen to have abroode chance for ova detection.

Chapter Four

Results:

Chapter Four

Results:

The Nematode detected in the faeces were Nematode sp.

Nematode fined percent ($\frac{16}{64} \times 100 = 25\%$)

Trichuris Fined percent ($\frac{16}{64} \times 100 = 25\%$)

A total of 64 specimens were examined (8×8) out of these specimens only 16 eggs (out of 64) a nematode were detected (plate-2) also 16 specimers were detected out of the 64 examined (plate 1-3) there fore the rate of infection was $\frac{16}{64}$ (25%) for each of the nematode and trichuris species

Table shows the results of parasitic ova discovered daily. The percentage of positive smears was (-%) of the total.

Most of fecal specimens were negative, showing no ova. Only two parasitic ova were seen in some of the smears. They were ova of a nernatode and trichuris species.

Table (1) parasitic ova Identified in dorcas |Gazelle of Kuku Zoo:

Nematods Species	
Days	
11/10	+
12/1	+
13/10	-
14/10	-
15/10	-
17/10	-
18/10	-

(-) : No fined Nematode

(+) : Fined Nematode

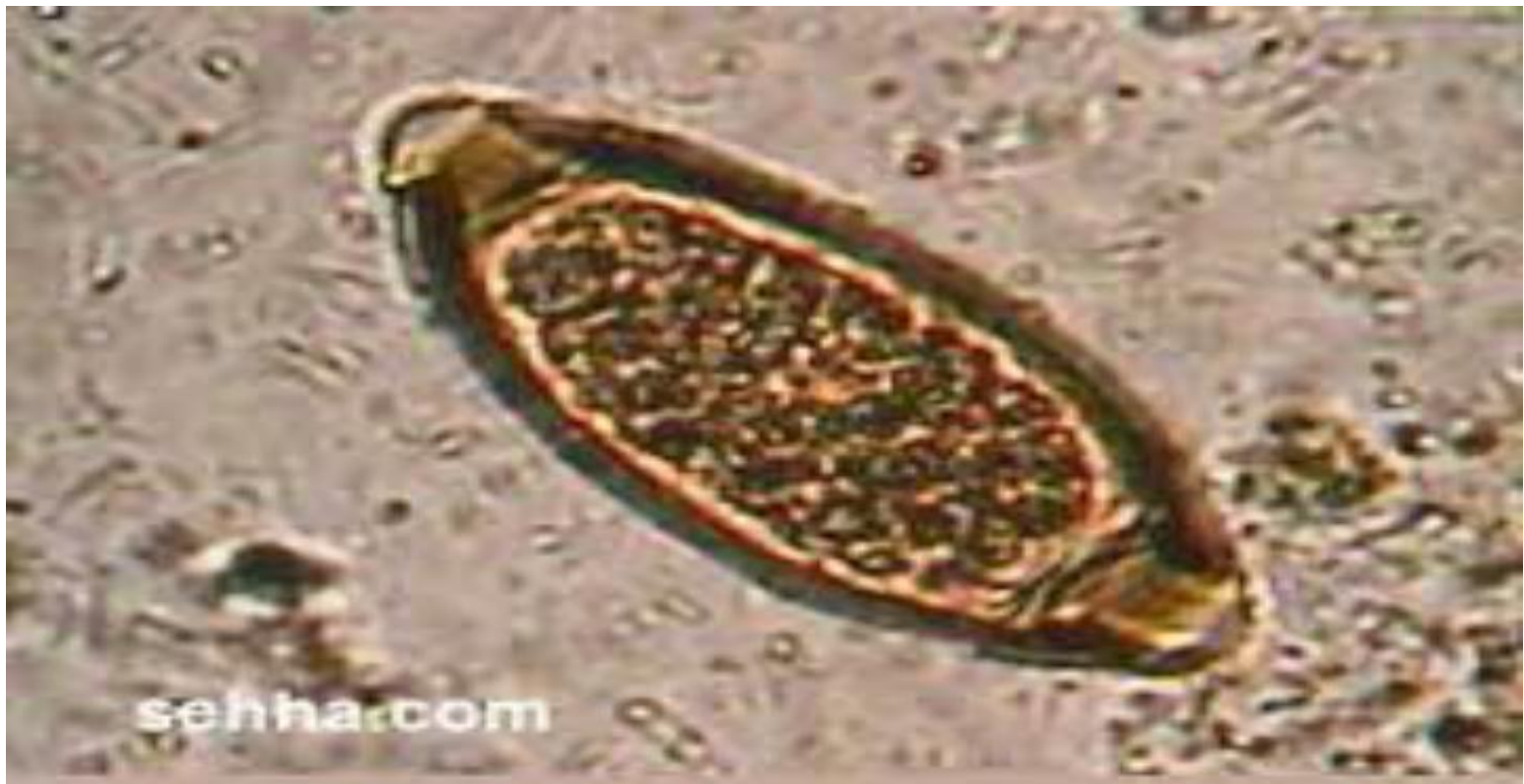

Plate: 1 Trichurs sp Egg

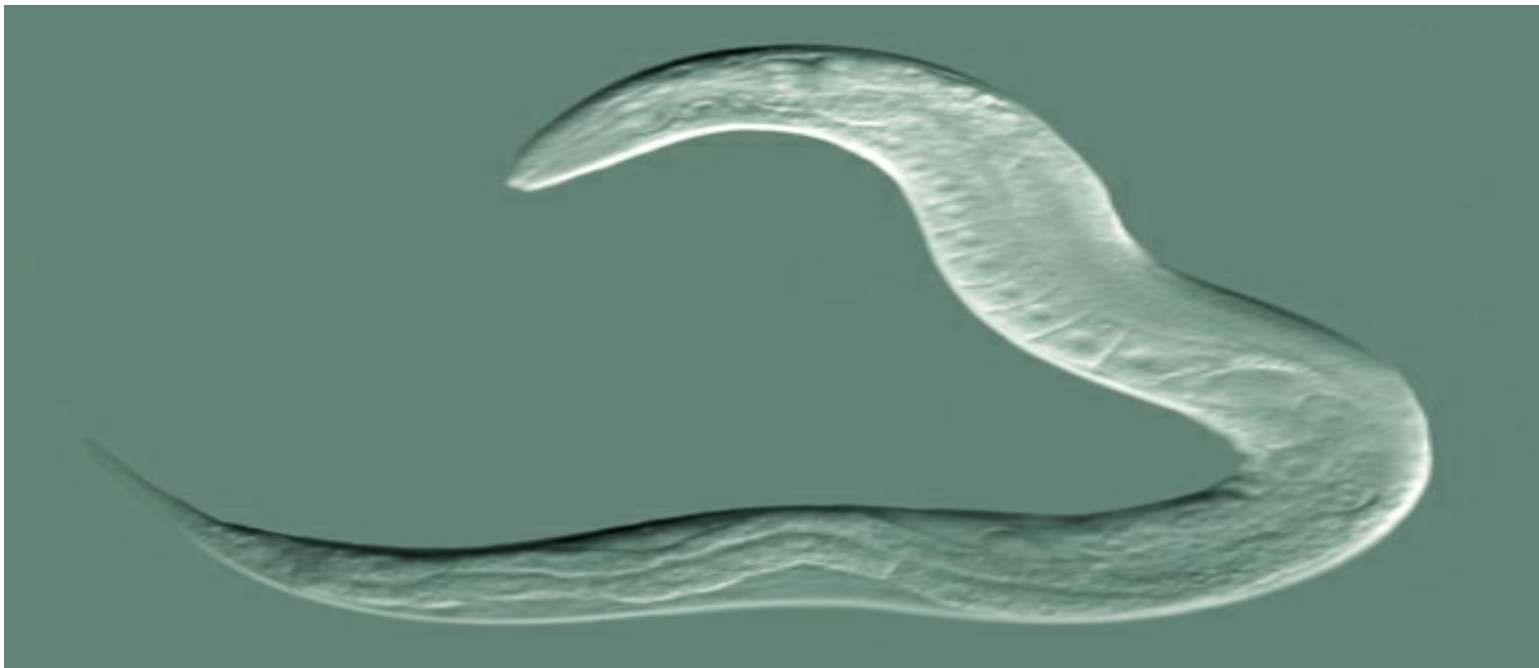


Plate2 : Nematode



Chapter Five

Discussion

Chapter Five

Discussion

The present study has been conducted for detection of internal parasites of dorcas gazelle by direct smear method. The results obtained have shown infection rate with parasiteic eggs (25%) for the detected species: a nematode and a trichuris species. such as result might indicate that there was no close interaction between dorcas gazelle and humans (Avergram, 1977). Another reason for such a low infestation rate might be due to the smaller number of the examined individuals (4 individuals) which is not expected to reflect the situation very well to give a true picture of infection, these four individuals of dorcas gazelle were kept in the cages since thes were first introduced into the zoo (Goosensa et al., 2005) and they were not moved to other cages, also, the neighboring cages were not occupied by any pertinent herbivore which were expected to transmit eggs in the feed.

**Conclusion and
Recommendation:**

Conclusion and Recommendations

It is recommended that further research should be done for detecting the presence or absence of internal parasites by using more sophisticated technique as faecal floatation and sedimentation and other techniques.

Since there are some wildlife farms , keeping dorcas gazelle, there is need to broaden research in internal parasites of dorcas gazelle by examining the faecal gazelle.

References:

References:

- Murray, E. Davids (California) zoo and wildlife medicine.
- Mulbarak, S.M (1986). Some effects of water deprivation on dorcas gazelle (*G. dorcas*) in Sudan. MSc. Tthesis (university of Khartoum).
- Schontz and Kromer. 1995; Estomi and hossaini 1998).
- Goosensa et al ; 2005.
- Adetunji 2014; Otegbade, and Morenikeji 2014)
- Abdul Rasoul K.|S (1979) . the epidemiology of Tarascoriasis and a scsriosis in wild comirores in ph. D. thesis University of Coli of Herbevors colifornia- Davis, USA.
- Bereridge. W.I.B. (1934): Foot rot in sheep skin penetration of strongyloides larvae as predisposing factor. Austrodian veterinary Journal 10: 43-51.
- Dunn, A.M (1979) veterinary Helminthology . 2nd ed. William Heinmann, London.
- Dslami. A.R Rahbori. S. and Nikbin. S. (1980) Gastro intestinal nematroodes of gazelle , *Gazella subgutturosa*, in Iran. Veterinary pourasitology 7: 75-78.
- Flbihori. S. and Kawasmeh. Z.A. (1980) Occurrence and seasonal variation of some gostra. Intestinal helminthes of the duromedory comelus dromedorius in Saudi Arbia, proceeding of the Saudi Biological society 4= 297-304.
- Hussein H.S and Mohammed O.B.(1992) , *Evmeria wheemi* Sp.n. (Apicomplexa = Eimeaildoe, from the Arabian sand gazelle, *Gazella subgutturosou morica* (*Artiodsctyla*; 13 ovidse I. in Saudi Arabia Jaournal of the Helminthological society of Washington 59: 190-194.

- Kock, 19.A. (1986) Entaric nematode infection in the Thomson. Gazelles, *Gazella thomsoni* at whipsnode pork, the Zoological society of London. *Journal of zoo animal medicine* 17; 61-64.
- Mohammed O.B. (1997) parasites of Arabican gazelles. In the *Gazalles of Arabia* (Edited by Habibi, K.A Abuzinood. A.H. and Nader, I.A) Newc D, Riyadh, Publication No 29 –pp. 192-207.
- Mohammed O.B. (1992) : studies on the gastrointestinal parasites of some Arabian gazelles. Thirteenth annual meeting of the Saudi Biological society (Abstract) king Soud University , college of Agriculture and veterinary medicine p. 98.
- Mohammed O.B (2000) . revealance identity and phylogeny of sorcocystis parasites from gazelles in Saudi Arabia . phb thesis, Kingston University . UK.
- Mohammed O.B and Hussain , H.S (1992) *Emeria idmii* sp. 2. (Apicomplexa = Eimeriidse) from the Aribian mountsin gazelle, *Gazella gazelle*, Saudi Aribia *Journal of the helminthological society of Washington* 59; 120-124.
- Mohammed O.B and Hussein , H.S (1994). The antibody prevalence of toxoplasmosis in arabian gazelles and armyx in Saudia Arabia , *journal of wildlife diseases* 30; 360-362.
- Mohammed , o.B. and Flamong , J.R. B (1961) experimental infection of Arabian aand gazelle *Gazella*. *Subgutturosa momicawith Emieria wheemi* *Journal of parasitology* 82-35-357
- Mohammed O.B. Daries A.S. H ussin. H.S and Daszak, p. (2000) sorcocysties infections in gazelles at king Khalid wildlife esearch conter , Saudi Arabia , veterizoy, research 146; 218-221.

-Soutlsky. E.J.L. (1982) Helminths, arthropods and protozoa of Pamesticated animals 7 ed, Billiemic and tindou . London.

-Tumer, J.H. (1959) experimental stronguloidiasis in sheep and goats . sirgle infections . American Journal of veterinary research 20; 102-110.

-w/iesmon J. and Jansen, J. (1981) some trichstrorgy lidage

(Newmatode) from Gazella gazelle and Gazella thomsoni in Seraelion 2005, proceedings of the British society for parasetology.