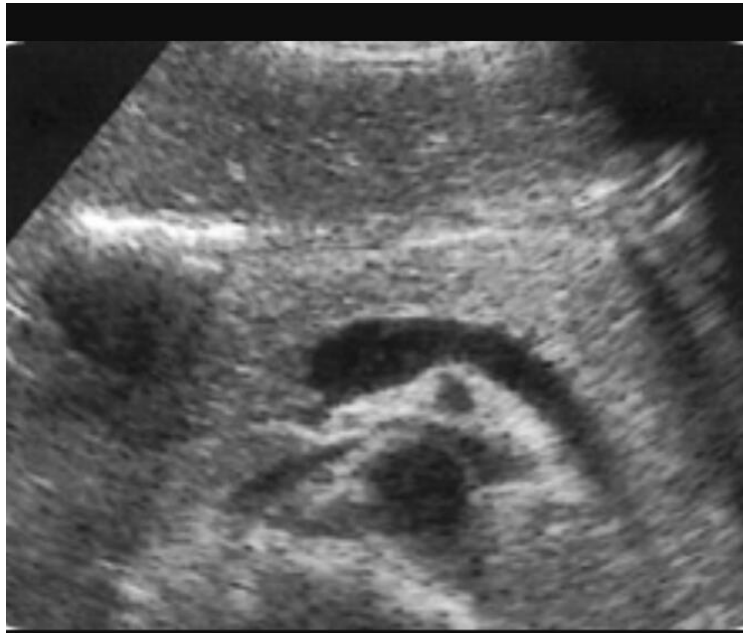
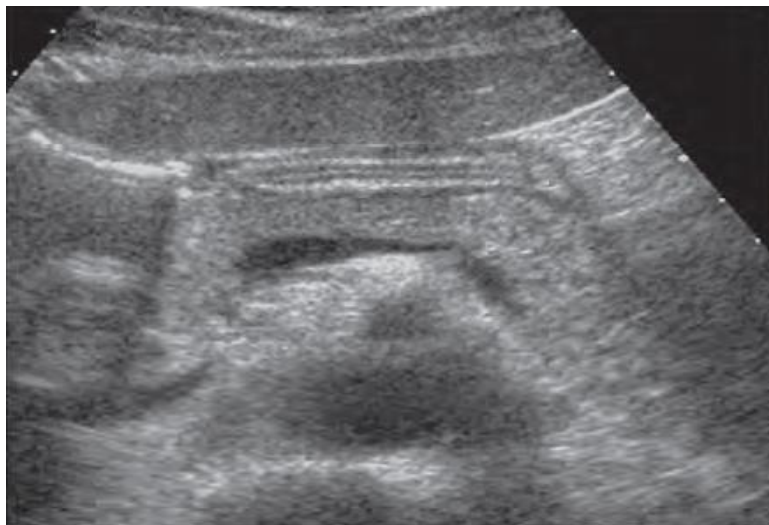

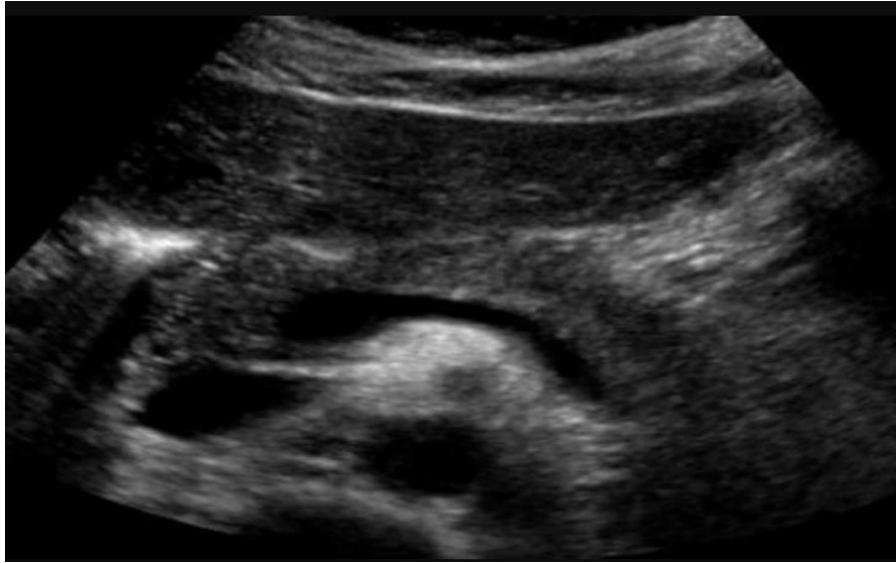Appendices (A)



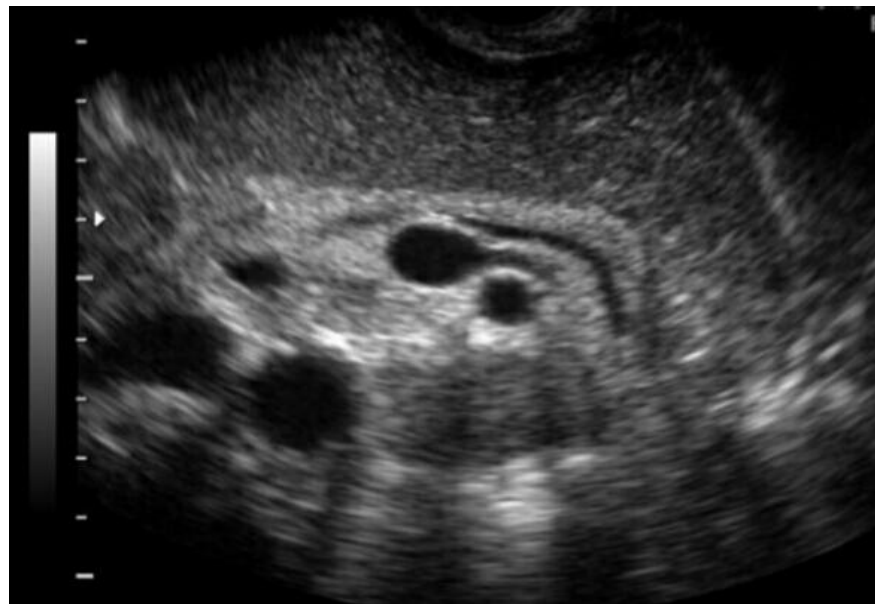Appendix (A-1) Ultrasound image transverse image for Female diabetic patient have 32 years old show normal parenchymal echogenicity and normal size.



Appendix (A-2) Ultrasound image Transverse image for Female patient have 28 years old show normal pancreas in parenchymal echogenicity and size.



Appendix (A-3) Ultrasound image transverse image for Female patient have 38 years old show hypoechoic smooth regular out line of pancreas.



Appendix (A-4) Ultrasound image transverse image for male patient have 55years old with hyperechoic paryncema of pancreas.

