

Chapter one

Introduction

1.1. Introduction:

Prostate enlargement with BPH is a common cause of lower urinary tract symptoms (LUTS) in older men. BPH affects about 50% of men over age 60 years and over 90% over age 70. The weight of the gland in a young man is approximately 20 g. From age 50, the doubling time of prostate weight is approximately 10 years. Prostates weighing more than 40 g are generally considered enlarged in older men. The etiology of BPH is unclear but probably related to hormonal changes with aging. The process results in hypertrophy and hyperplasia of the fibrous, muscular, and glandular elements, primarily affecting the transition and peri urethral zones. Also called prostatism and bladder outlet obstruction, LUTS can relate to increases in prostate size and muscular tone, both of which result in urethral constriction. Symptoms include frequency, nocturia, weak stream, hesitancy, intermittence, incomplete emptying, and urgency. Symptoms are quantified using the American Urological Association (AUA) symptom index. (Rumak et al 2011).

Prostate size correlates poorly with urinary obstruction, and a large prostate is often seen in asymptomatic patients, whereas other patients with severe voiding difficulties caused by prostatic obstruction may have small glands. Also, remember that urinary dysfunction is multifactorial and can arise from abnormalities of the central nervous system, spine, bladder, prostate, and urethra. Patients with urinary dysfunction need evaluation of all these systems, not only the prostate. Investigation of the patient with symptoms of prostatism is best done transvesically. Transvesical ultrasound can adequately assess prostate size, identify median lobe enlargement, and evaluate bladder volume and postvoid residual, bladder wall character, trabeculation, diverticula, tumors,

and calculi, as well as evaluate the kidneys and ureters for hydronephrosis and masses. (Rumak et al 2011).

1.2. Problem of study:

Lack of previous studies regarding in urinary bladder volume pre and post micturation sudan therefore this study was evaluate the volume of prostate relative to bladder volume in order to improve the management of such cases.

1.3. Research Objectives:

1.3.1. General objective:

To evaluate the urinary bladder in patient with benign prostatic hyperplasia using ultrasonography.

1.3.2. Specific objective:

1. To measure the volume of prostate, urinary bladder volume pre and post micturation in patient with BPH.
2. To determine bladder wall thickness.
3. To correlate urinary bladder volume pre and post micturation with prostate volume.
4. To correlate prostatic volume with patient age .

1.4. Overview of the study:

This study consists of five chapters. Chapter one contains introduction, problem, objectives and overview of the study. Chapter two deals with literature review including theory behind the study and previous work conducted in field of research. Chapter three contains methodology of the

study (material and methods). Chapter four contains results. Chapter Five consist of discussion conclusion and recommendation in addition to reference and appendix.

Chapter two

Literature review

2.1. Anatomy

2.1.1 Prostate anatomy:

2.1.1.1. Embryology of the prostate:

In the 4th week of gestation, the urogenital septum divides the cloaca into two parts the rectum posteriorly and the primitive urogenital sinus anteriorly. In the 5th week, the distal portions of the Wolffian canal and the Mullerian canal attach to the posterior aspect of the primitive urogenital sinus (Fig.2.1), to form an elevation called Mullerian tubercle. The tubercle divides the primitive urogenital sinus into vesico-urethral canal superiorly and definitive urogenital sinus inferiorly. The Wolffian canal forms the vas deferens, the ampulla of the vas and the seminal vesicle. The Mullerian canal regresses to form the utricule. Formation of the prostate begins at the 10th week of gestation by proliferation of the epithelium of the posterior urethra around the orifices of the Wolffian canal, to surround the urethral circumference. The prostatic glands formed anterior to the urethra regress and are replaced by fibro muscular stroma. The secretory function of the glands starts about the 13th week of gestation. (Yousef and Naryana 1982).

2.1.1.2. Gross Anatomy of the prostate:

The term “prostate” was originally derived from the Greek word “prohistani”, meaning “to stand in front”, and has been used to describe the organ located in front of the urinary bladder. The prostate is conical in shape with its long axis directed inferiorly and anteriorly.

The shape and size of the prostate may vary with age. The prostate of an adult man measures 20 – 25 gms in weight. The base of the prostate is

directed superiorly and in contact with the bladder base. The apex is directed inferiorly and in contact with the external sphincter above the deep fascia of the urogenital membrane. The anterior border is separated from the symphysis pubis and pubic bones by the retro pubic space. The trapezoid area is an extra prostatic area of anatomic weakness. It may be involved by carcinoma extending through the inferior neuro-vascular pedicle. This area bounded by the prostate proximally, the recto urethral is muscle distally, the membranous urethra anteriorly and the rectum posteriorly the prostate is related to the rectum and is separated from it by the Denoviller's fascia which extends superiorly, behind the seminal vesicles up to the peritoneal reflection .At each postero lateral aspect of the prostate, the hypo gastric pelvic fascia contains the neurovascular bundle of the prostate, seminal vesicles and bladder neck. (Wasserman NF, 2006)

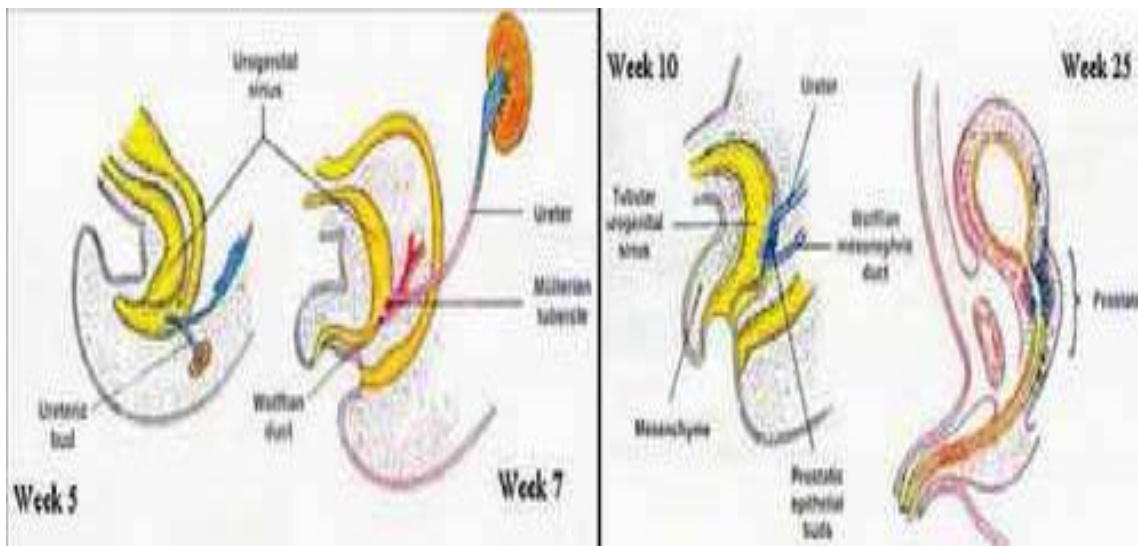


Fig (2-1) the embryological origin and development of the prostatic urethra and the prostate (Delmas, 1991)

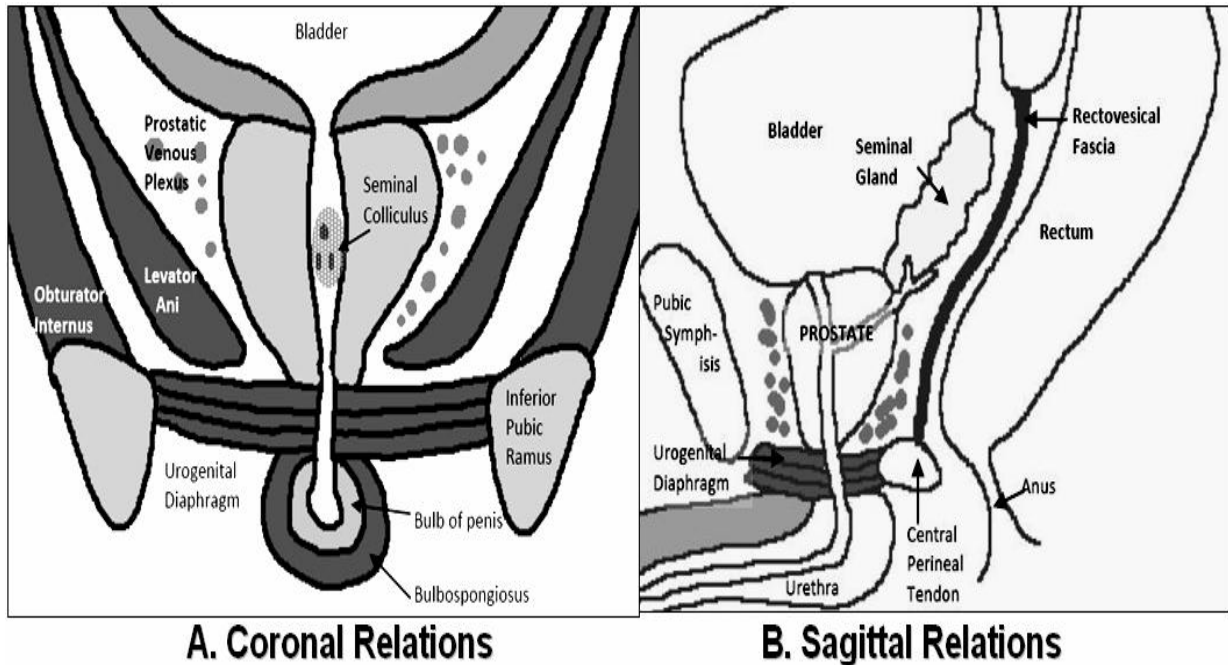


Fig (2-2) Relations of the prostate in the coronal (A) and sagittal planes (B) .
 (Hricak H, et al 2007)

2.1.1.3. The distal seminal tract:

It is formed of two seminal vesicles, ampulla of the vasa differentia and ejaculatory ducts. The seminal vesicle is a cystic structure, measuring about 35 mm in length and 15 mm in width. It is related anteriorly to the urinary bladder and posteriorly to the therectum. The ampulla of the vas is located medial to the seminal vesicle. The vassal ampulla joins the seminal vesicle to form the ejaculatory duct. Each duct enters the base of the prostate, passes through central zone to end in the urethra below the utricle. (Youssef and Naryana (1982).

2.1.1.4. Lobar concept of intra prostatic anatomy:

In 1912, lowly demonstrated the first detailed description of the anatomy of the prostate. This traditional concept which is no longer used, divided the prostate into lobes: an anterior, posterior, middle and two lateral lobes. This

method has been used to identify the prostate and prostatic disease for about 60 years. The anterior lobe was situated from the anterior margin of the gland to the level of the prostatic urethra. The middle lobe was a small area between the proximal prostatic urethra and the ejaculatory ducts. This lobe extends from the base of the prostate to the level of verumontanum. The posterior lobe was situated posterior to the ejaculatory ducts and extends to the posterior margin of the gland. The two lateral lobes extend from the lateral margin of the gland bilaterally toward the middle part of the gland. None of these lobes has clearly defined medial margin. (Benson MC, et al 1992).

2.1.1.5. Zonal concept of intra prostatic anatomy:

The understanding of the gross and microscopic anatomy of the prostate has changed during the past few decades. Since 1965, a zonal concept of anatomy has evolved initially developed by McNeal and then modified over about three decades. The prostate is best considered to be a fusion of different glandular regions contained within a discontinuous capsule (McNeal, 1968, 1988). The prostate is composed of four glandular regions and a non-glandular region which is the anterior fibromuscular stroma (Fig.2. 3). The fibromuscular stroma (FMS) is the anteromedial portion of the gland is devoid of glandular tissue. This region is generally considered to be of less clinical significance. The peripheral zone (PZ) comprises the largest portion of the glandular prostate in young man (70%). (Benson MC, et al 1992).

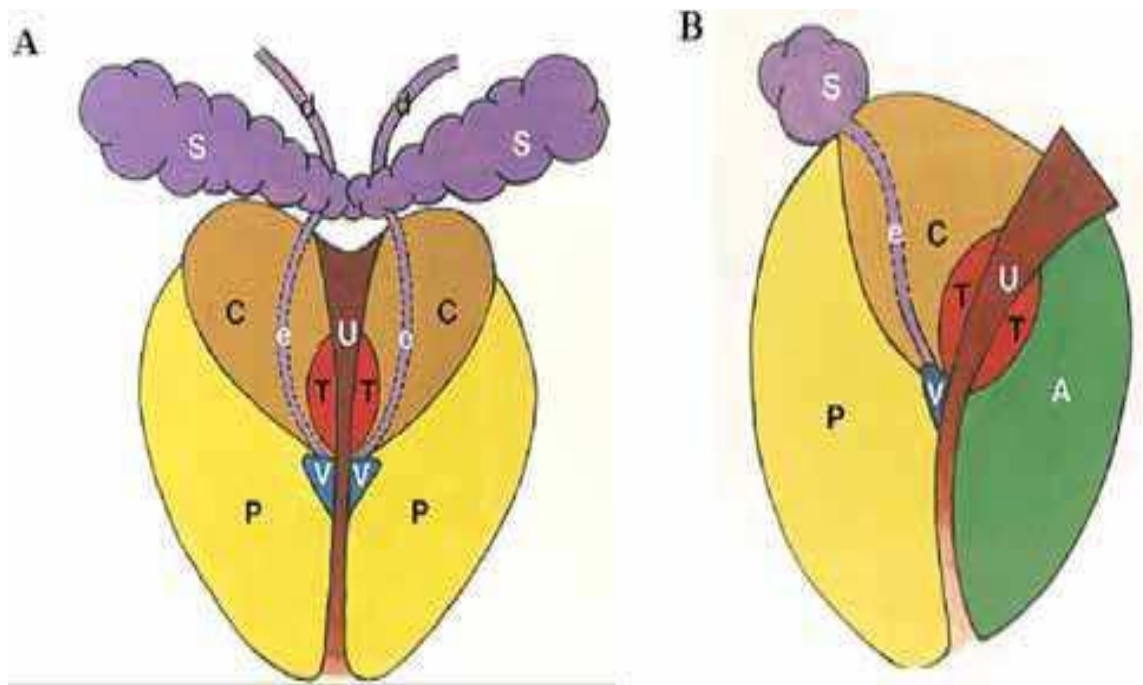


Fig (2-3) Zonal anatomy of the prostate in coronal and sagittal planes.
 (Benson MC, et al ,1992)

The figure showing the central zone (C), peripheral zone (P), transition zone (T) and anterior fibromuscular stroma (A). It also shows the distal seminal tract formed of the ampulla of the vas deference (d) which joins the Seminal vesicle (S) to form ejaculatory duct (e) which opens at verumontanum (v). The PZ is situated posteriorly, postero-laterally and a thin layer of this tissue also extends up laterally and antero-laterally. Distal to the verumontanum, the PZ often surrounds the urethra and occupies the apical region of the prostate. The transition zone (TZ) is situated on both sides of the proximal prostatic urethra and comprises only 5 to 10% of the glandular tissue in the non-hyperplastic prostate. The surgical capsule is an interface between the PZ and TZ. In the aging prostate where the TZ can show marked glandular hyperplasia and may constitute the majority of prostatic glandular elements. The peri-urethral glandular zone (PUG) consists of mucosal glands in the

prostatic urethra itself and represents only a tiny fraction of the glandular prostate. This zone may become hyperplastic with age to form the “median lobe” which may obstruct the bladder neck. The central zone (CZ) is cone-shaped with its base forms the base of prostate, bordering the urinary bladder and seminal vesicles and its apex is at the verumontanum. The CZ forms about 25% of the glandular prostatic tissue. The CZ surrounds the ejaculatory ducts throughout their entire courses in the prostate. The site where the ejaculatory ducts enter the CZ is devoid of prostatic capsule. The extra prostatic space invaginates around the ejaculatory ducts down to the verumontanum forming the “invaginated extra prostatic space”. If the ejaculatory ducts are invaded by carcinoma, the tumor will have a ready “highway” to the seminal vesicles and extraprostatic space. (Benson MC, et al, 1992).

2.1. 2. Urinary bladder anatomy:

2.1.2.1. Development of the Bladder:

In the seventh gestational week the urorectal septum fuses with the cloacal membrane, dividing it into a ventral urogenital sinus and a dorsal rectum. The bladder develops from the urogenital sinus. Initially, the bladder is continuous with the allantois, which eventually becomes a fibrous cord called the urachus, the adult median umbilical ligament. As the bladder enlarges, the distal portion of the mesonephric ducts is incorporated as connective tissue into the bladder trigone. At the same time, the ureters come to open separately into the bladder. In infants and children the bladder is an abdominal organ; it is not until after puberty that it becomes a true pelvic structure. (Devin Dean, 2005).

2.1.2.2. Adult urinary bladder: The bladder is positioned in the pelvis, inferior and anterior to the peritoneal cavity and posterior to the pubic bones.

Superiorly, the peritoneum is reflected over the anterior aspect of the bladder. Within the bladder, the ureteric and urethral orifices demarcate an area known as the trigone; the urethral orifice also marks the bladder neck. The bladder neck and trigon eremainconstant in shape and position; however, the remainder of the bladder will change shape and position depending on the volume of urine within it. Deep to the peritoneum covering the bladder is a loose, connective tissue layer of sub serosa that forms the adventitial layer of the bladder wall. Adjacent to the adventitia are three muscle layers: the outer (longitudinal), middle (circular), and internal longitudinal layers. Adjacent to the muscle, the inner most layer of the bladder is composed of mucosa.

The bladder wall should be smooth and of uniform thickness. The wall thickness depends on the degree of bladder distention. (Devin Dean .2005).

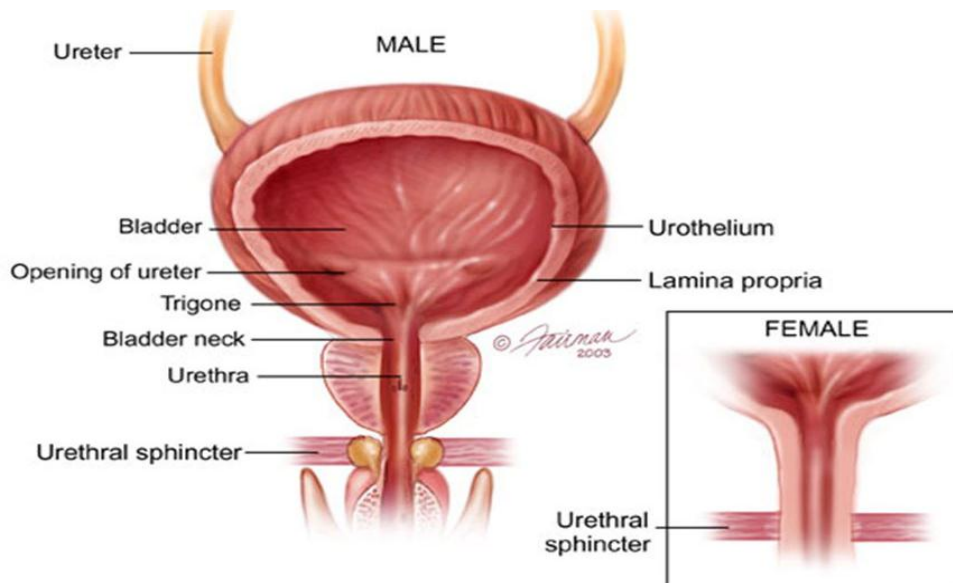


Fig (2-4) male urinary bladder-anatomy (www.jouefct.com)

2.1.3. Male urethra anatomy:

2.1.3.1. Gross Anatomy of male urethra:

The posterior male urethra forms from the urogenital sinus .This sinus derive from the endoderm-derived cloaca, which is separated from the anorectal canal by the growth of the urorectal septum in the fourth week of gestation.

The spongy urethra is formed after the seventh week by tabularization of the urethral folds along the urethral groove under the influence of dihydrotestosterone. The most distal portion of the urethra is likely formed by invagination of an epithelial tag at the distal end of the genital tubercle.

The male urethra originates at the bladder neck and terminates at the urethral meatus on the glans penis. It is roughly 15-25 cm long in the adult and forms an "S" curve when viewed from a median sagittal plane in an upright, flaccid position (see the image below). The male urethra is often divided into 3 segments on the basis of its investing structures: prostatic urethra, membranous urethra, and spongy (or penile) urethra.

2.2. Physiology:

2.2.1. Prostate physiology:

The prostate produces a thin, milky fluid containing citric acid and acid phosphate that is added to the seminal fluid at the time of ejaculation. The smooth muscle, which surrounds the glands, squeezes the secretion into the prostatic urethra. The prostatic secretion is alkaline and helps neutralize the acidity in the vagina.(Kundra V,et al 2007).

2.2.1.1. Prostate laboratory Tests:

Serum Acid Phosphatase Test This test is used to identify metastases of the prostate gland. The normal gland and a carcinoma of the prostate is both rich in acid phosphatase. However, only small amounts of this enzyme are found in the serum if the gland is normal or if the carcinoma has not metastasized. Therefore, in the proper clinical setting, an elevated serum acid phosphatase level indicates metastases from the prostate gland. If the tumor has metastasized to bone there will also be a high alkaline phosphatase level reflecting increased osteoclastic activity (in addition to the elevated serum acid phosphatase).(Benson MC, et al 1992).

Prostate-Specific Antigen (PSA) is a glycoprotein produced exclusively by the prostate gland; when elevated the possibility of prostate cancer exists. The higher the elevation, the more likely a cancer exists and that it has spread. About 97% of men with normal prostate glands without hyperplasia have PSA levels under 4 ng/ml. "PSA can be elevated by virtually any abnormality affecting the prostate, whether benign or malignant including BPH, atrophy, inflammation, infarction and manipulation.(Benson MC, et al 1992).

2.2.1.2. Correlation of the zonal anatomy and prostatic diseases:

With the development of cross sectional – imaging studies like ultrasound and magnetic resonance imaging (MRI), the zonal concept of anatomy becomes useful technique to apply because the different areas can be definite. The zonal concept of anatomy is also useful because it incorporated a clearer understanding of the development of disease. The origin of prostatic disease was poorly understood under Lowsley's concept of lobar anatomy. It was previously thought that cancer only arises in the posterior lobe and BPH develops predominantly in the lateral and, to a lesser degree in the median lobe. It is now understood that the prostate cancer develops in the acinar tissue predominantly the peripheral prostate. Although the PZ is three times larger in volume than the CZ, prostate cancer develops seven times more often in the PZ. It was shown that about 50% of cancer arises in the anterior half of the prostate, including all those cancers from the TZ (20% of the total), CZ (10%) and anteriorly situated portions of the PZ. In contrast, BPH develops exclusively from the central gland, approximately 95% from the TZ and 5% from the per urethral glandular tissue. Prostatitis starts mainly in the PZ similar to the prostatic cancer. (Benson MC, et al 1992).

2.2.2. Urinary bladder physiology:

The purpose of the urinary bladder is to store urine prior to elimination of the urine from the body. The bladder also expels urine into the urethra by a process called micturition (also known as urination). Micturition involves the actions of both voluntary and involuntary muscles. Lack of voluntary control over this process is referred to as incontinence.

2.2.3. Male urethra physiology:

The urethra is the passageway through which urine is discharged from the body. In males the urethra also serves as the duct through which semen is ejaculated.

2.3. Prostate pathology:

2.3.1.1. Benign Prostatic Hyperplasia (BPH):

Some authors refer to benign prostatic hyperplasia as benign prostatic hypertrophy and also shorten it to BPH. Prostatic volume can be calculated by using the following formula: Prostate Volume = L x W x H x 0.523

Normal prostatic volume is 20 cc which is equivalent to 20 grams. In older men 40 grams is considered enlarged. BPH is a common disorder believed to be due to an endocrine imbalance which usually begins in the 5th decade and continues throughout life. Enlargement occurs in the per urethral TZ and usually compresses the CZ and thins the PZ so that most of the gland appears involved. The term inner gland is often used to describe the enlarged TZ and indistinguishable CZ.¹Clinical symptoms are difficulty in starting, maintaining and stopping the flow of urine. There may also be frequency and nocturia. The clinical significance of BPH relates to the degree of obstruction of the prostatic urethra which can lead to infections and bilateral hydronephrosis. BPH elevates the PSA but at a much lower rate than carcinoma.(Eri, L. M,et al . 2001)

Sonographically BPH is demonstrated as an enlarged prostate (>40g); the inner gland is hypoechoic and inhomogeneous compared to the PZ; multiple hyperechoic nodules are often present in the inner gland; nodules frequently undergo cystic degeneration and calculi form along the surgical capsule. A post transurethral resection prostate appears thin with a preserved PZ and a

scant or absent inner gland. The urethra is widened into a funnel shape with the widest portion at the bladder base. (Eri, L. M., 2001)

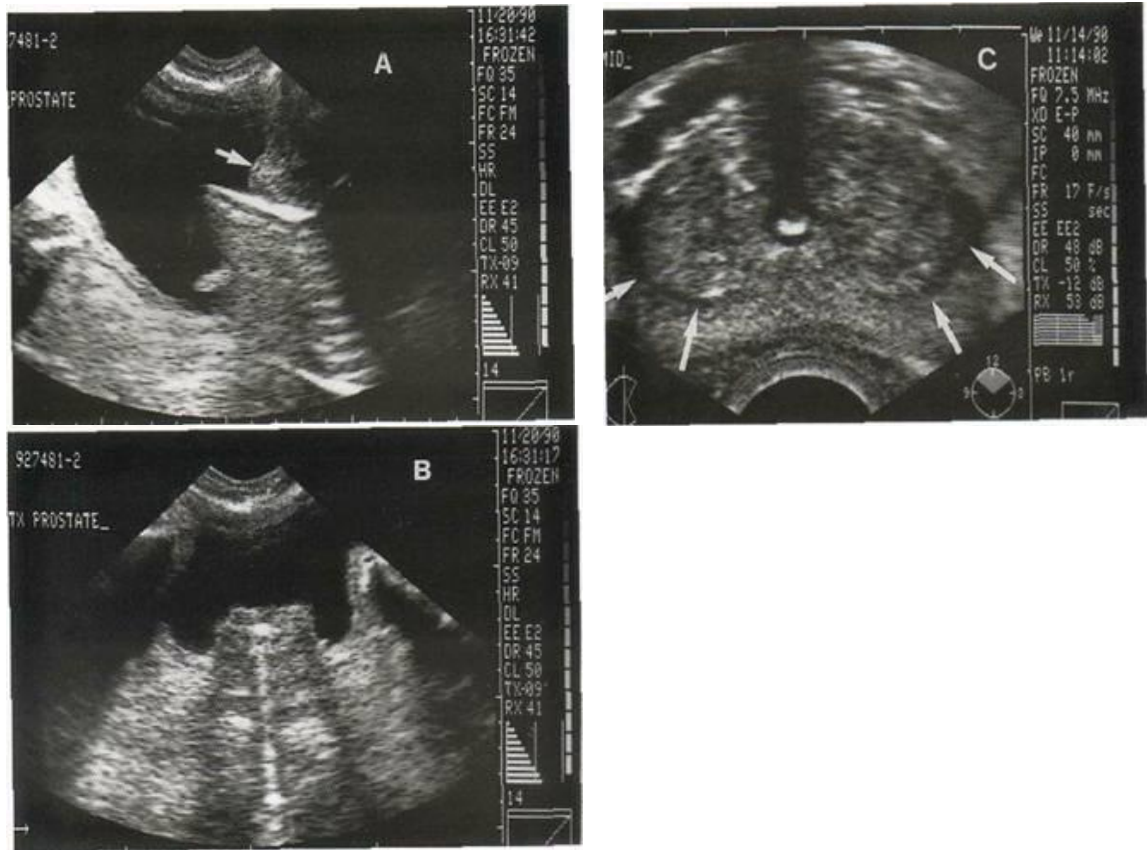

Fig (2-5) A, B, C shows benign prostatic hypertrophy in an 83 year old. The patient has a bladder outlet obstruction secondary to the BPH and required a urethral stent. (Devin Dean .2005).

A longitudinal transvesical bladder and prostate scan. The more anterior portion of the enlarged prostate (arrow) is shown encroaching on the bladder lumen. The highly echogenic urethral stent degrades the remainder of the prostate image. B Transverse transvesical bladder and prostate scan. The enlarged prostate gland is shown projecting into the bladder lumen. A long portion of the echogenic urethral stent is demonstrated.

C Axial TRUS scan demonstrates an enlarged gland that is wider posteriorly than the sector image. The hypoechoic boundary (arrows) between the inner gland and peripheral zone is well demonstrated.

The urethral stent is readily identified. (Devin Dean .2005).

2.3.1.2. Prostatitis:

The majority of cases of acute prostatitis are due to ascending infections caused by E coli. Catheterizations, cystoscopies and urethral dilatations also frequently result in acute prostatitis. Chronic prostatitis may follow the acute form but in the majority of cases no causative organism is identified and no previous acute state has been noted. Clinically, both acute and chronic forms are associated with low back pain, dysuria, frequency and urgency. Sometimes the prostate is enlarged and tender. Fever may be noted with the acute form. Frequently chronic prostatitis is asymptomatic and results in repeated urinary tract infections by constant seeding of the bacteria.

Sonographically prostatitis appears as a moderately enlarged gland with focal hypoechoic or hyperechoic areas, with poor margination, in the peripheral prostate. This appears sonographically similar to prostatic malignancy. The prostate may also appear normal. Color and power Doppler imaging demonstrates marked hyper-vascularity. Prostatic calculi may be small, large, single or in clusters and are characteristically seen near the urethra. A thickened, irregular prostatic capsule is common. (Eri, L. M. et al 2001).

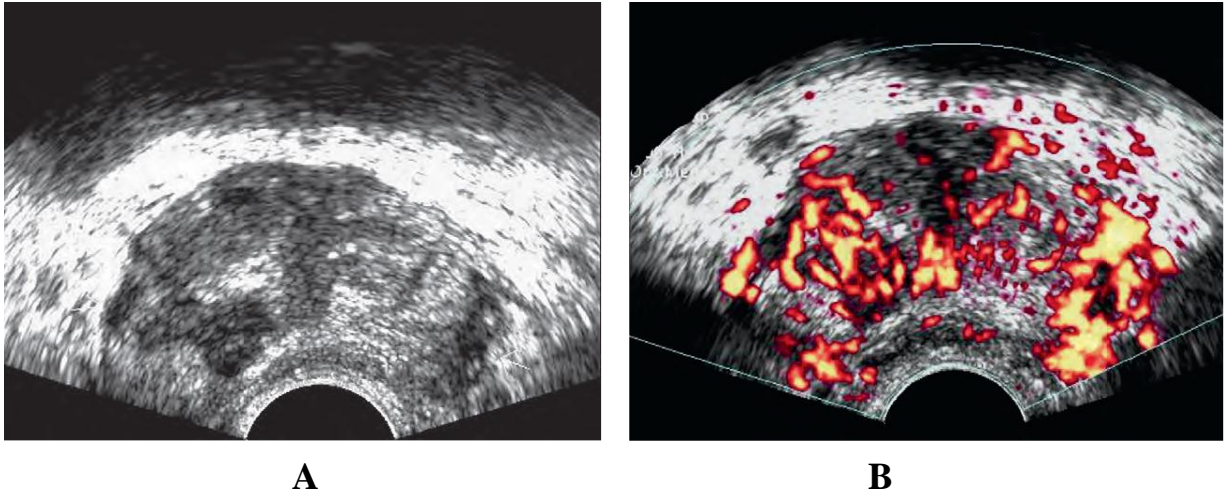


Fig (2-6) shows prostatitis A, Biopsy-proven non acute inflammation. Multiple geographic hypoechoic areas on both sides B, Power Doppler ultrasound demonstrates increased vascularity in area of inflammation.

2.3.1.3. Granulomatous prostatitis:

Can form hypoechoic masses that feel and look like cancer. Men with bladder cancer are a special group if they have been treated with BCG instillation. Reflux of BCG into the prostate can cause inflammatory granulomatous masses that mimic prostate cancer or metastatic bladder cancer and require biopsy for clarification.(Eri, L. M. et al 2001)

2.3.1.4. Prostatic Abscess:

Acute prostatitis may be complicated by a prostate abscess. Aspiration of the abscess guided by TRUS, combined with appropriate antibiotics, is an effective treatment.

Sonographically the abscess appears as a mixed lesion within the parenchyma. Color and power Doppler imaging demonstrates the surrounding prostatic parenchyma as markedly hyper-vascular and the abscess as avascular.(Eri, L. M.,et al . 2001)

2.3.1.5. Prostatic Cysts:

Congenital - Mullerian duct cysts are derived from the embryologic mullerian ducts and most commonly are located lateral to midline at the level of the verumontanum. Utricle cysts are derived from another embryological structure called the utricle. This is a small blind sac extending from the posterior urethra at the level where the ejaculatory ducts enter the prostatic urethra. Utricle cysts are located in the midline near the verumontanum. Utricle cysts are associated with other genitourinary abnormalities such as unilateral renal agenesis and cryptorchidism. Many authors use the terms utricle cyst and Mullerian duct cyst interchangeably while others believe they are separate entities. (Babaian RJ, et al 2000).

Sonographically most utricle cysts are tube shaped and <1 cm in length. They may fill with urine and empty with voiding. Mullerian duct cysts are often large and extend beyond the prostate and present as cystic pelvic masses.

2.3.1.6. Prostatic Cancer:

Prostate cancer is the most common cancer among men and second only to lung cancer as a cause of death, the incidence has steadily increased over the past 35 years. The risk appears to increase rapidly after 50 years of age. African-American men have an increased incidence compared to white men. There is also a higher incidence in men with a strong personal family history of the disease. The most common form is an adenocarcinoma. Local invasion involves the seminal vesicles and pelvic side walls. Metastatic spread is via the lymphatics and bloodstream, frequently involving the axial skeleton. Serum acid phosphatase and PSA levels are elevated with advanced prostatic cancer.

Location of Cancer 70% is in the peripheral zone; 20% in the transition zone and 10% in the central zone.

Sonographically 70% of cancers are seen as hypoechoic lesions in the peripheral zone. Unfortunately these sonographic appearances are also similar to prostatitis, fibrosis and infarction. 30% are isoechoic, blend with the surrounding gland and can only be detected by appreciating glandular asymmetry, capsular bulging and areas of attenuation. The occasional cancer is hyperechoic. (Eri, L. M et al . 2001)

2.3.1.7. Prostate Biopsies:

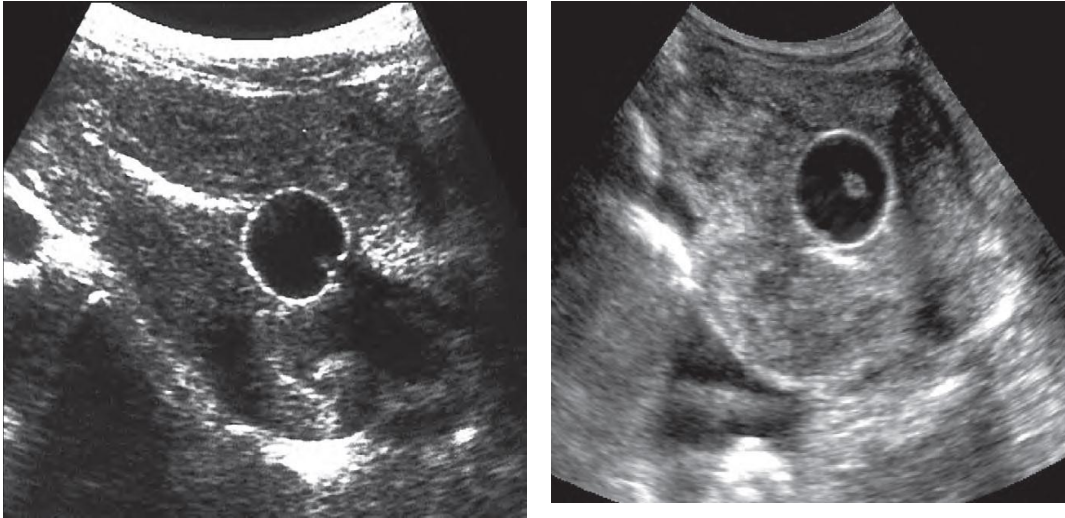
Any lesion considered suspicious by digital rectal, US examination or elevated PSA levels is biopsied.⁶ Ultrasound guided prostate biopsy is performed with a trans-rectal approach. Five to 8 MHz “end fire” transducer. Needle guidance systems clamp on to the side of the probe and electronic guide lines show the needle path. Frequently an automatic biopsy gun with 18 gauge needles is used enabling core biopsy specimens to be obtained.⁷ Core biopsies obtain tissue samples rather than the smaller cytologic (cell) samples and therefore may yield more information. “The goal of biopsy is to maximize the diagnostic yield. The most effective biopsy template to achieve this goal is presently the subject of much investigation and debate. (Eri, L. M et al . 2001)

2.3.2. Bladder pathology:

2.3.2.1. Bladder Wall Thickening:

The bladder wall is thickened when it exceeds 4 mm in diameter with the bladder distended.

Diffuse wall thickening may be caused by inflammation, muscle hypertrophy or neoplasia, Focal wall thickening is most commonly caused by inflammation or neoplasia. (Devin Dean .2005).



A

B

Fig (2.7) diffuse bladder wall thickening. Two patients presenting with urinary retention. A, Interstitial cystitis. Diffuse transitional cell carcinoma in second patient. Both sonograms show marked circumferential bladder wall thickening after Foley catheterization. Cystoscopy and biopsy are required for differentiation.(Devin Dean .2005)

2.3.2.2. Cystitis:

The most common cause of cystitis is from the E. coli bacteria which ascend the urethra to enter the urinary bladder. Since females have a shorter urethra and its opening is close to the anus, this type of infection is more common in females. Cystitis may also be caused by radiation and chemotherapy.

Any interference with bladder emptying can predispose the bladder to infection. Bladder urine is sterile but stasis of urine is associated with bladder infections. Once bacteria are introduced into the obstructed bladder (eg. via cystoscopy) and the urine is not able to be flushed out or controlled by the bladder wall, the infection gets established. Bladder catheterization is

a frequent cause of cystitis. Cystitis may be associated with prostatic disease in adult males. Symptoms include: urgency, frequency, dysuria, incontinence, nocturia, low backache and suprapubic discomfort.

Sonographic Appearances Cystitis may be acute or chronic, focal or diffuse. Acute cystitis is usually associated with a normal bladder wall. Chronic cystitis, when diffuse, is associated with diffuse wall thickening. Focal forms of chronic cystitis “may produce localized wall thickening or a polypoid mass. The mass may be sonographically similar to an epithelial neoplasm. Intraluminal inflammatory debris is commonly present with chronic cystitis.

Chronic cystitis associated with focal wall thickening containing cystic areas of fluid is called bullous cystitis. Bullous cystitis is characteristic of catheter-induced chronic cystitis. (Devin Dean .2005)

Purulent cystitis is a form of cystitis in which pus is mixed with the urine. Pus urine fluid levels may be demonstrated. The pus flows to the lowest part (ie. The most dependent part). Emphysematous cystitis is the presence of air in the bladder wall or lumen caused by infections from gas forming organisms. Patients with diabetes, chronic bladder outlet obstruction or chronic infections are most vulnerable. The bladder wall is thickened and highly echogenic. If the gas bubbles are large enough, there will be acoustic shadowing. (Devin Dean .2005)

2.3.2.3. Neurogenic Bladder:

The detrusor muscle of the bladder and the internal and external urethral sphincters are controlled by the brain. Trauma or lesions interfering with the related neurologic control result in a bladder that cannot function properly known as neurogenic bladder.

The patient is usually catheterized and routinely evaluated as these patients are prone to infection, stone formation and upper urinary tract obstruction. “If neurogenic bladder dysfunction is not properly diagnosed and treated, rapid deterioration of renal function may occur. Sonographically neurogenic bladder results in bladder wall thickening, trabeculations (marked irregularity of the luminal surface of the bladder) and incomplete bladder emptying. (Devin Dean .2005)

2.3.2.4. Bladder Diverticula:

A bladder diverticulum is a pouch-like herniation of the mucosa through a weak area of the muscle wall. Bladder diverticula may be congenital or acquired and they are most often detected in patients with prostatic enlargement and long standing bladder outlet obstruction. Urine collects in these pouches and this often leads to infection.

Sonographically, diverticula appear as fluid-filled masses projecting from the wall of the bladder. Always try to demonstrate the connection between the bladder and the diverticulum called the neck. A narrow opening can interfere with emptying of the diverticulum, resulting in urinary stasis and infection. This can change the echogenicity of the urine filling a diverticulum and thereby obscure its true cystic character. Stones, blood, and transitional cell carcinomas can arise within diverticula. Generally filling the bladder to capacity opens the neck of the diverticulum. Color or power Doppler during bladder compression has demonstrated bidirectional urine flow between a diverticulum and the bladder. is an example of urine flow at the neck of a diverticulum. “If the neck is not visible, a diverticulum is

indistinguishable from a pelvic cyst, abscess, or other pelvic fluid collection. (Devin Dean .2005)

2.3.2.5. Bladder Calculi:

The calculi may originate in the bladder or the kidneys. Bladder calculi characteristically develop in the presence of urine stasis, chronic infection or prolonged use of an indwelling catheter. Calculi are often irritating to the bladder wall and may cause cystitis. They rarely obstruct the bladder neck.

Sonographically, they are highly echogenic focal mobile structures that produce shadows. (Devin Dean .2005).

2.3.2.6. Foley Catheter:

The catheter walls are seen as two highly echogenic lines and the balloon have highly echogenic walls with an anechoic interior. The patient may have an incompletely filled bladder resulting in bladder walls that are thick and irregular which is normal for partially filled bladders. (Devin Dean .2005).

2.3.2.7. Bladder Neoplasm:

Transitional cell carcinoma (TCC) of the bladder involves the mucosal lining. It is the most frequent primary malignancy of the bladder (90%). The Patient usually presents with painless hematuria.

TCC may be papillary or non-papillary (smooth). Papillary forms are attached to the mucosa by a stalk, are slow to infiltrate, late to metastasize and generally more benign. Non papillary TCC's are usually solitary, smooth areas of mucosal thickening, and are invasive high grade

malignancies .Other bladder neoplasms are most often metastases from adjacent rectal, prostate, uterine and ovarian carcinoma.

Sonographically, smooth or papillary TCC's appear as hypoechoic soft tissue masses which project into the bladder lumen. Invasive tumors are associated with focal or diffuse wall thickening. Intraluminal blood clots may be present. Dilatation of the ureter and collecting system result from TCC involvement of the ureteral bladder opening. The presence of flow on color or power Doppler distinguishes tumor and clot. is an example of a small TCC with central blood flow. (Devin Dean .2005).

2.3.2.8. Bladder Neck Obstruction:

Calculi, transitional cell carcinoma, prostatic hypertrophy, prostatic carcinoma, urethral strictures, ectopic ureterocele and posterior urethral valves can obstruct the bladder outlet causing the bladder walls to become diffusely hypertrophied and trabeculated, and if untreated, will result in dilated ureters and bilateral hydronephrosis. Caudal angulation of approximately 15 degrees is necessary to demonstrate the urethra using the transabdominal approach. (Devin Dean .2005).

2.3.2.9. Posterior Urethral Valves (PUV):

This is a congenital disorder involving the prostatic portion of the urethra. Incomplete regression of the mesonephric ducts causes exaggerated folds of the posterior urethral mucosa and ultimately various degrees of partial or intermittent obstruction .PUV may be detected prenatally in the fetus, neonate or older infant.

Sonographically, typical findings include a trabeculated bladder with an elongated, dilated posterior urethra, which establishes the diagnosis of PUV. The differential diagnosis includes neurogenic bladder and prune-belly syndrome, but distinguishing features are that although the bladder neck is dilated in these conditions, the posterior urethral dilatation is unique to PUV. Trans perineal sonography may demonstrate a linear echogenic valve leaflet traversing the dilated posterior urethra. PUV is frequently the cause of bilateral hydronephrosis and should be suspected when male infants present with bilateral hydronephrosis. The clinical outcome depends on the duration and severity of urinary tract obstruction. A normal neonatal kidney has prominent renal pyramids and a cortex that exceeds the normal echogenicity of the liver. Absence of corticomedullary differentiation correlated with later renal insufficiency is 45% of patients. Therefore PUV may be associated with dilated renal calyces and an overall highly echogenic kidney.(Devin Dean .2005)

2.3.3. Male Urethra pathology:

2.3.3.1. Voiding Disorder:

Patients who have acquired a spinal injury are prone to bladder dysfunction and urinary tract complications. Voiding cysto urethro sonography or voiding urethra sonography may be performed using transrectal US to assess bladder urethral dysfunction

2.3.3.2. Urethral Stones:

Most urethral stones are renal or bladder calculi, however, stones may originate in the urethra in patients with urethral strictures or diverticula who have chronic urinary stasis or infection. An echogenic focus with distal shadowing is shown in the urethra or diverticulum.(Devin Dean .2005)

2.3.3.3. Prostatic Obstruction of the Urethra:

Bladder outlet obstruction in men is a blockage that slows or stops urine flow out of the bladder. Bladder outlet obstruction can cause urine to back up in your system, leading to difficulty urinating and other uncomfortable urinary symptoms.

Possible causes of bladder outlet obstruction might include:

1. Enlarged prostate, also known as benign prostatic hyperplasia (BPH) this is the most common cause of bladder outlet obstruction in men.
2. Scarring of the urinary channel (urethra) or bladder neck, as a result of injury or surgery.
3. Use of certain medications, including antihistamines, decongestants or drugs to treat overactive bladder.
4. Bladder stones
5. Prostate cancer. (Devin Dean .2005).

2.4. Techniques and approaches of prostatic and urinary bladder ultrasonography:

Ultrasonography is firmly established diagnostic tool in prostatic imaging. Recent development in US technology has led to significant improvements in image quality, consistency and resolution. Additionally, dynamic scanners, color flow imaging and real time imaging have allowed appreciation of blood flow, reduced examination time and improved quality of the image. These advances combined with the portability, relative low cost and lack of risks of iodinated contrast media and irradiation have made US one of the most useful modality in evaluation of the prostate. Many approaches can be used to image the prostate as trans-abdominal, trans-urethral, trans-perineal and trans-rectal US. The common two approaches are trans-abdominal and trans-rectal ultrasound.(Benson MC, et al 1992).

2.10. Trans-abdominal ultrasound:

Transabdominal US of the prostate is nearly universally available and provides excellent anatomic information using the urine-filled bladder as an acoustic window. Prostate size, weight, shape and intravesical extent can be determined. Caudal angulation of the transducer to accommodate the pubic bone is often required. The normal prostate appears as a homogenous, round or ovoid structure with uniform low level echoes. The intra glandular zonal anatomy cannot be visualized (Fig. 2.7). The relation between the prostate, bladder and seminal vesicles can be demonstrated .(Benson MC, et al 1992).

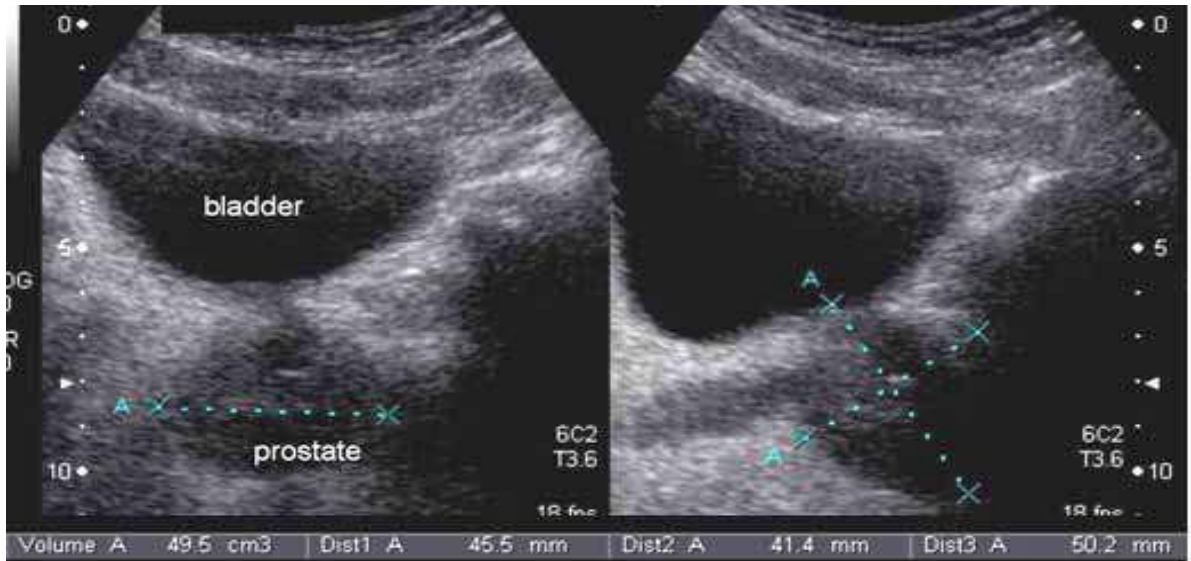


Fig (2.8) Transabdominal US of a moderately enlarged prostate in axial and sagittal planes.

2.4.2. Transrectal ultrasound (TRUS):

In 1963, Takahashi and Ouchi were the first to describe the use of TRUS to evaluate the prostate. The first clinically applicable images of the prostate obtained with TRUS were described in 1967, they used a 3.5 MHz transducer, which at that time was considered to be state of the art, to obtain images that were clinically meaningful. As US technology has become more refined, the use of TRUS in the evaluation of prostatic disease has increased. By the mid-1980s. It had become a standard diagnostic instrument of the urologists and radiologists.

Most investigators today prefer equipment using hand-held transducers

which are available in frequencies ranging from 3.5 MHz up to 10 MHz with the optimum frequency being around 7.0 MHz. Trans-rectal probes are available in different Sizes and shapes with diameters ranging from 1.2 to 2 cm.

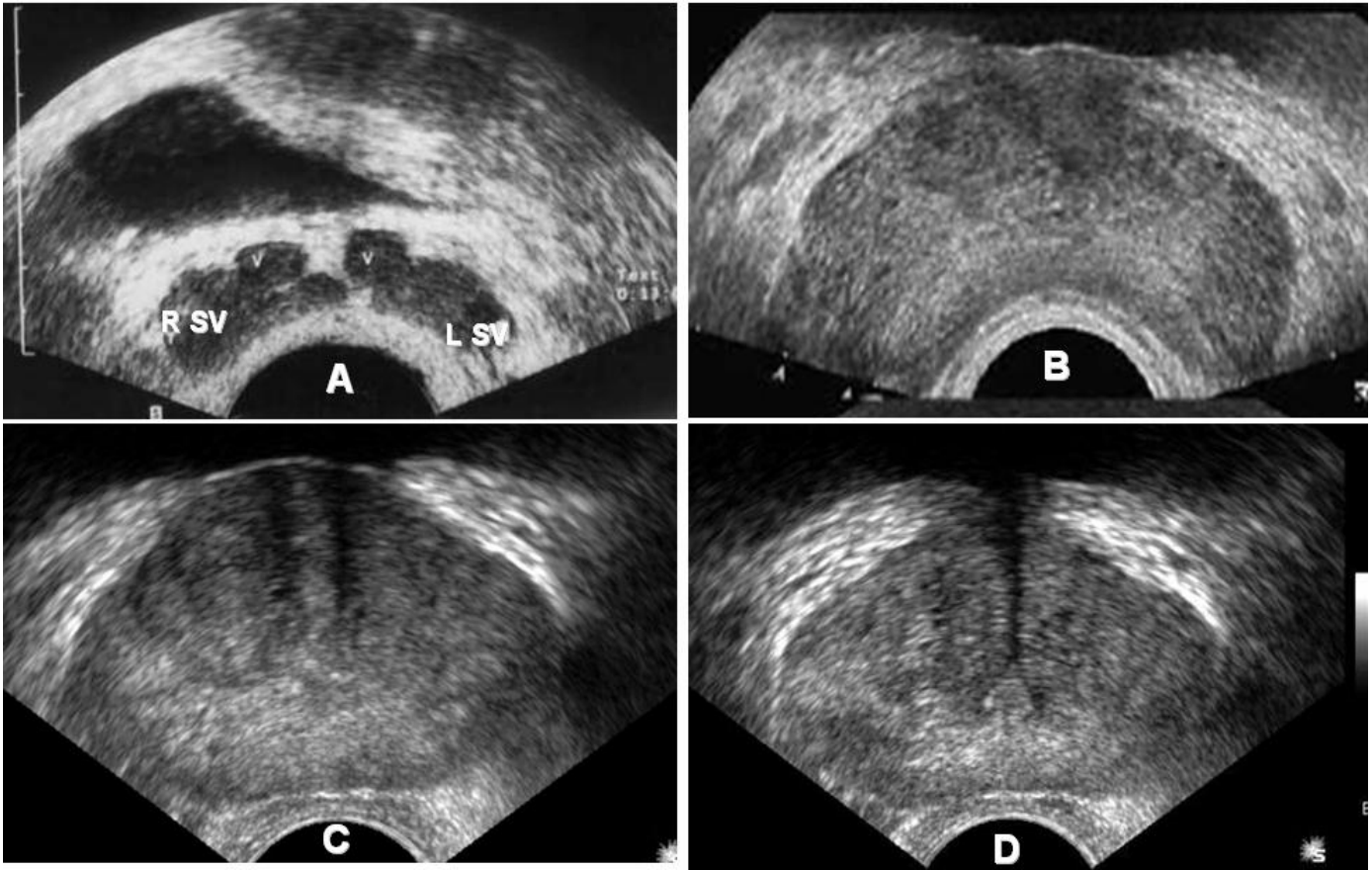


Fig (2.9) TRUS axial images. (A) the level of distal seminal tract; showing seminal vesicle (SV) and vasal ampulla (V), (B) level of prostate base, (C) level of mid gland and (D) level of verumontanum showing its appearance as tour Eiffel.

2.4.3. Techniques and approaches of urinary bladder:

The bladder should be full enough to enable visualization of the prostate and seminal vesicles in the male and the uterus and vagina in the female. It is important to have the correct degree of bladder fullness since too little fluid may not provide the window necessary for adequate pelvic scanning.

A bladder that is too full can compress or displace structures so they are not visualized. An overfull bladder can also create the appearance of pathology.

The distended urinary bladder should have smooth, thin, medium level echogenic walls (approximately 3 mm thick) and contain no echoes, with the exception of the normal jets of urine as the ureters empty into the bladder. In the partially filled state, the bladder is collapsed and the walls, with the exception of the trigone area, are thrown into folds. The sonographic appearances of a partially filled bladder are thickened (up to 6 mm), irregular walls encircling an echo lucent interior. Therefore, to assess wall thickness, the bladder should be reasonably distended. (Devin Dean .2005)

Adult Bladder Volume Measurement “Quantification of the overall bladder volume is important in patients who have urinary retention. Attempts to measure the various dimensions of the bladder and then derive volume measurements have met with limited success. So far, none of these methods produces an exact volume but the final product may be satisfactory for clinical use. (Devin Dean .2005)

The lack of accuracy has been attributed to the variations in bladder shape secondary scan technique for obtaining bladder volume to filling, transducer frequency, and inability to image the anterior aspect of the bladder base. Because the operator controls the scan plane during real time studies, variations in the plane chosen for measurements may affect results. The normal volume may be up to 500 ml without major discomfort.

$$V = (H \times W \times D) \times 0.523$$

The sagittal image provides the craniocaudal distance (H) and the AP distance (D). The transverse image at its widest dimension provides the width (W). (Devin Dean .2005).

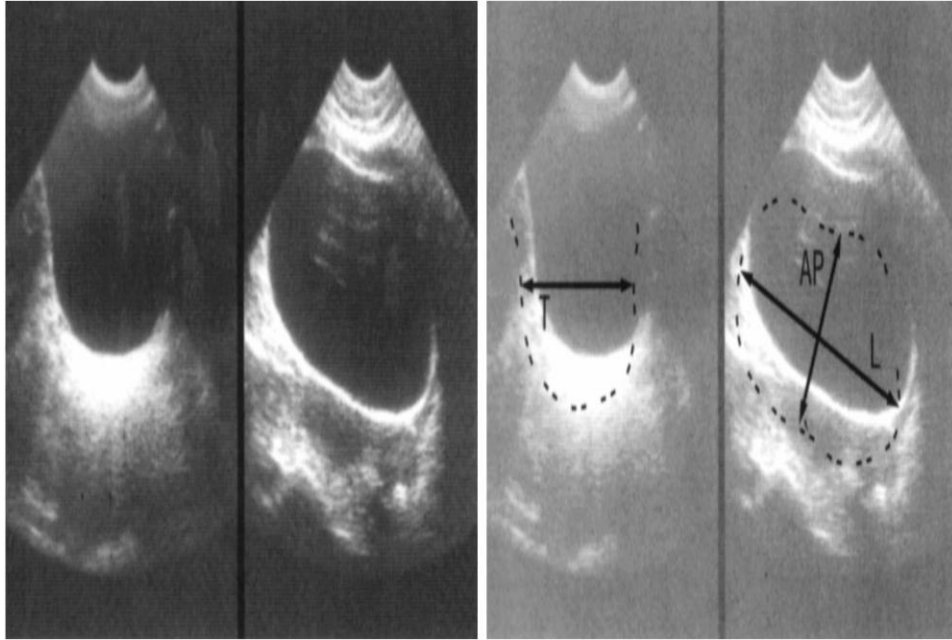


Fig (2.10) shows Bladder volume measurement, The transverse image provides thickness (T) and sagittal image provides antroposterior dimension (AP) and length (L). (Palmer 1995).

2.5. Previous studies :

In the Study of Shi-jun Zhangetal conducted from November 2009 to June 2010 Weifang community in shangahi, china to select 1000 men aged 40 – 70 years from electoral rolls.

All participants' were invited to receive prostate measurement by TRUS with 6MHZ scanning probe, prostate width was measured on an axial image. The study showed that larger prostate volume and TVZ were positively associated with increased age and the mean TVZ per age group increased at a rate faster than TPV. especially after the age 60 years. The TVZ and TVL had a higher correlation with IPSS, indicating a link between prostate size and symptoms of BPH. Using width, Height and length growth rate equations, the mean size of prostate could be calculated in any man aged 40-70 years. These equations and models can early diagnosis of BPH.

Study done by McNeill SA,etal (2008) in there population of men with lower urinary tract symptoms suggestive of benign prostatic hyperplasia, the post void residual urine (PVR) volume and bladder capacity were related to the baseline Qmax (maximum flow rate) .Alfuzosin significantly reduced the PVR volume compared with placebo, and this effect was more marked in patients with a high PVR volume at baseline. Acute urinary retention occurred mainly in patients with a PVR volume greater than 100 mL and was less frequent in patients taking alfuzosin than in those taking placebo.No relation was found between post void residual urine volume and age.

Study done by w.j. kirkels et al (1995) objectives to study the prevalence symptoms of pro-statism in the community and correlation between these

symptoms and age, prostate volume, flow rate and residual urine volume, the data were collected about 502 men aged between 55 and 74 years, the result detailed 12% of men's had global perception of their voiding function and 82% had no voiding complaints. The result concluded that the parameters used to characterize BPH should be considered independently because no predictions about the values of a certain parameter can be made by knowing one of the other parameter value.

Study done by Oliver .W.Hakeuberg ,etal(2000) the men with mild lower urinary tract symptoms (LUTS) and clinical benign prostatic enlargement (BPE) (n = 150; mean age, 66.4).. There were a weak negative correlation with bladder volume ($r = -0.12$, $P < 0.003$) and a weak positive correlation for BWT and age for both men ($r = 0.12$, $P < 0.014$) and women ($r = 0.17$, $P < 0.013$). Mean A small increase in BWT with age is seen for both genders, and BWT tends to be greater in men than in women. Men with LUTS and BPE show a moderate increase in BWT. Adjustments for bladder volume are for practical purposes negligible, although there is a small decrease in BWT with increasing volume.

Chriopherkolman, etal (2006) objective was measured by transrectal ultrasonography in 477 randomly selected community dwelling white men as part of a baseline urological evaluation. The distribution of post-void residual was highly skewed with a median of 9.5 ml, and 25th and 75th percentiles equal to 2.5 and 35.4, respectively. There was a significant correlation of post-void residual with prostate volume ($r_s = 0.24$, $p < 0.001$). The odds of post-void residual greater than 50 ml. were 2.5 times greater for men with prostate volume greater than 30 ml. than those with smaller prostates. Men with enlarged prostate volume or post-void residual greater

than 50 ml. However, a somewhat stronger relationship was found between residual urine and prostate volume.

Chapter three
Material and method

3.1. Materials:

3.1.1. Machine:

In this study using ultrasound machines (mindray) which contain curvilinear probe have a frequency from 3.5 to 5 MHZ, and ultrasound imaging system a B mode capabilities was used and ultrasound gel was applied to the transducer to prevent any attenuation or artifact and thermal paper printer was used .a data collection sheet was used to collect the data and to number the patient.

3.1.2. Inclusion Criteria:

Any patient attending the in that period motioned his age above 49 years and had prostate enlargement (BPH).

3.1.3. Exclusion Criteria:

Any patient had age under 49 years, with no enlarged prostate, residual prostate also urethral catheterization.

3.2. Methods:

The study conduct in in Sharg Alneel hospital in Khartoum stats , From December 2016 to February 2017.this study population in a selected way a total of fifty five male ,age above 49 years were selected to be the sample unit in this study .

3.2.3. Ultrasound techniques of prostate and urinary bladder:

The examination begins with the patient supine in supine position. Scans are performed in sagittal and transverse plane from the anterior approach with tilting the probe caudal using the full bladder as acoustic windows Trans-abdominal ultrasound as well. The highest frequency transducer permitting adequate penetration is used the usually in the 3 to 5 MHz rang .a convex probe is used and acoustic gel is applied.

3.2.4. Measurement of prostate volume:

Was taken by measuring transverse and depth diameter in transverse plane, in sagittal plane was taken in longitudinal diameter.

Volume of prostate = transverse diameter X depth diameter X longitudinal diameter multiply 0.52.

3.2.5. Measurement of urinary bladder volume:

Was taken by measuring transverse and depth diameter in transverse plane in sagittal plane was taken longitudinal diameter (www.cancer.gov)

Volume of urinary bladder = transverse diameter X depth diameter X longitudinal diameter multiply 0.52 to give us volume of urine: pre micturition =full urinary bladder, post micturition = residual urine.

3.2.6. Data collection:

The data would be collected by clinical data collection sheet which designed by the researcher to include all variables of the study.

- Age.
- Ultrasound finding.

3.2.7 Data storage:

Patient data sheet was kept in local cabin and all data was storage in personal computer.

3.2.8. Data analysis:

It was analyzed by statistically package for social sciences SPSS.

3.2.9. Ethical clearance:

-The procedures of the scanning with ultrasound will be explained to the patient and the purpose of incorporating his data in the study, where written consent will be acquired in case of agreement.

-Permission from the hospital and the department will be granted.

-Data will be collected from different patient with maintain privacy and confidentiality.

Chapter Four

Results

4.1. Results

Table(4-1) the frequency distribution of patient ages (percentage of patient according the age

age	Frequency	Percent
50-55	4	7.3
55-60	6	10.9
60-65	13	23.6
65-70	11	20.0
70-75	10	18.2
75-80	11	20.0
Total	55	100.0

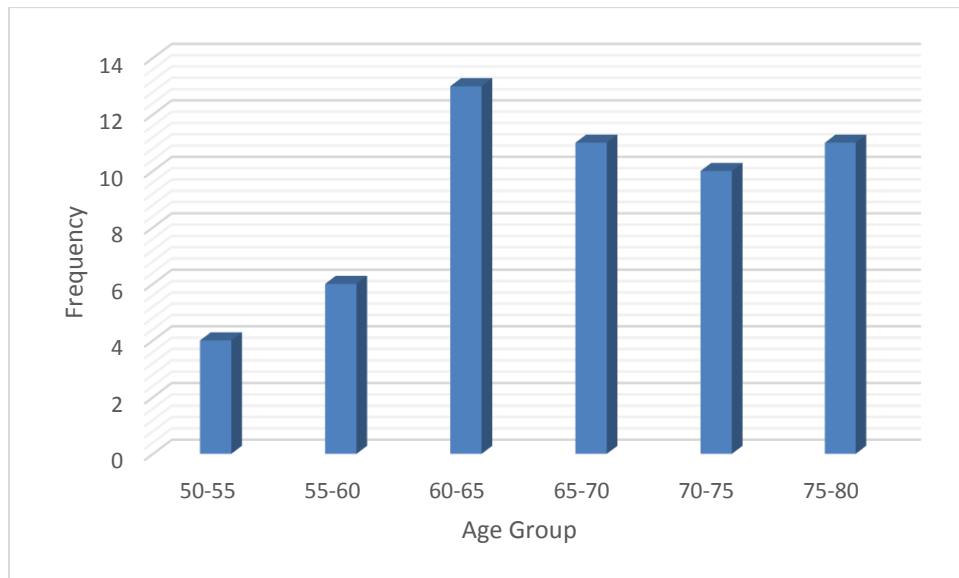


Figure 4-1 the frequency destruction of patient age

Table (4-2) shows frequency distribution of urinary bladder wall thickness

urinary bladder thickness	frequency	Percent
normal	52	94.5%
increased	3	5.5%
total	55	100.0%

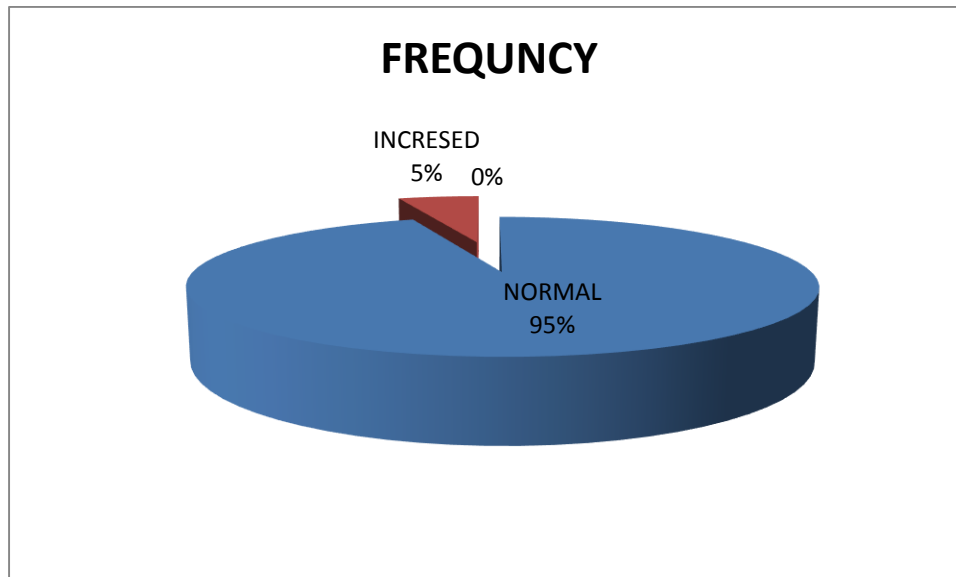


Fig (4-2) pie graph shows percent of normal urinary bladder wall thickness and urinary bladder with increased wall thickness

Table (4-3) Statistical measurement for patient related variable and bladder volume

	Min	Max	Mean	Std. Deviation
Age	50.0	80.0	66.382	8.3366
length	157.0	188.0	174.345	6.5637
Weight Kg	56.0	105.0	76.964	9.9181
Urinary bladder volume pre micturition	94.0	663.0	300.078	151.4992
Urinary bladder volume post micturition	1.0	385.0	76.802	76.9626

Table (4-4) represent the measurement of prostate (minimum, maximum, mean and Std. Deviation for length, width, height and volume of prostate

	Mini mum	Maximum	Mean	Std. Deviation
Prostate length	3.0	7.1	5.324	0.9849
Prostate width	3.6	6.8	5.225	0.7412
Prostate height	3.3	8.4	5.335	1.0386
Prostate volume	33.3	200.6	83.133	36.6499

Table(4-5) the mean volume of urinary bladder pre micturition (bladder capacity) and post micturition (residual urine), pre micturition =300 ml

And the post micturition =76.8

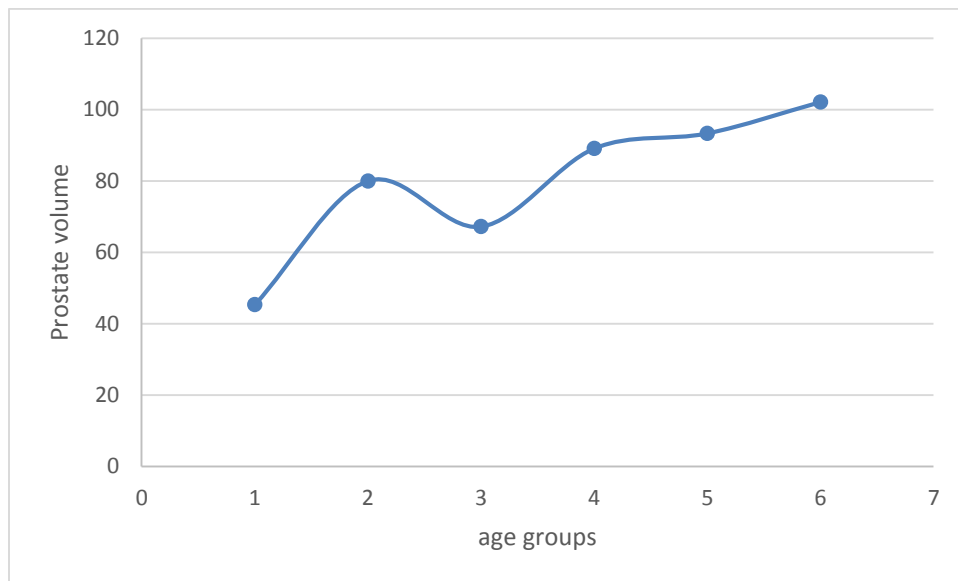
Paired Samples Statistics				
		Mean	N	Std. Deviation
Pair	Urinary bladder volume pre micturation	300.078	55	151.4992
	Urinary bladder volume post maturation	76.802	55	76.9626

Table (4-6) Paired Samples T Test demonstrate a significant difference in urine volume for patient with prostatic enlargement before and after micturition at p-value (0.000) (CL=95%, p=0.05)

Paired Samples Test						
		Paired Differences			T	Sig. (2-tailed)
		Mean	Std. D	Std. Error Mean		
Pair	Urinary bladder volume pre micturition – Urinary bladder volume post micturition	223.3	131.1	17.8	12.6	0.000

Table(4-7)the correlation between the prostatic volume and age

Group Statistics				
	Age	N	Mean	Std. Deviation
Prostate volume	50-54.5	4	45.350	7.9702
	55-59.5	6	80.017	60.8582
	60-64.5	13	67.215	17.9386
	65-69.5	11	89.109	36.9421
	70-74.5	10	93.350	42.6044
	75-80	11	102.18	23.4853
Total		55		



Figure(4-3) scatter plot diagramme show a linear relationship between the prostate volume and age

Table (4-8) correlation between urinary bladder volume post micturition and patient age

Group Statistics				
	age	N	Mean	Std. Deviation
UB volume post Micturation	50-54.5	4	90.250	105.8816
	55-59.5	6	35.500	14.1810
	60-64.5	13	89.077	102.7525
	65-69.5	11	69.327	58.7998
	70-74.5	10	97.200	83.4556
	75-80	11	68.864	65.4798
	Total	50	Strong at p=0.233	

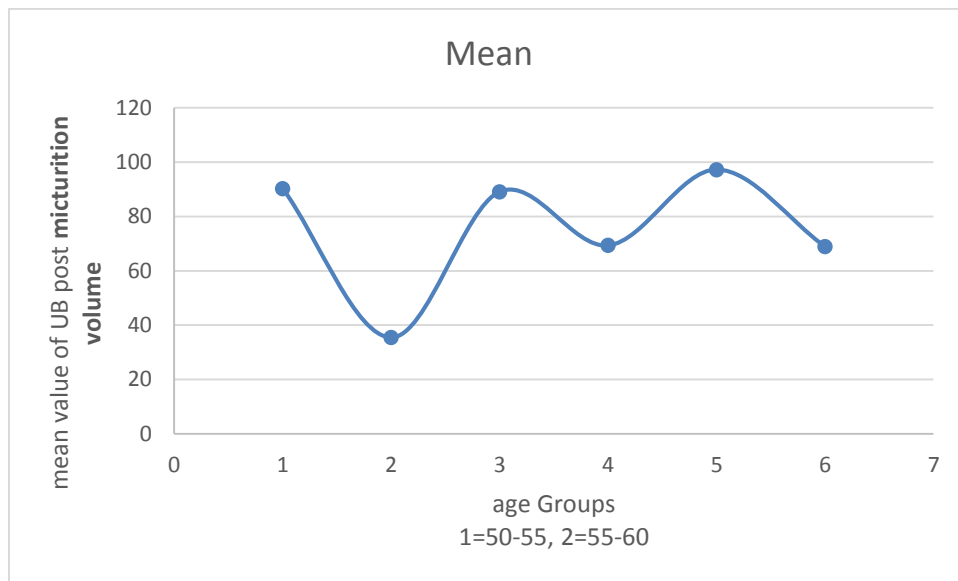


Figure (4-4) a scatter plot diagramme shows strong relationship urinary bladder volume post micturition and patient age

Table(4-9) the mean and standard deviation of urinary bladder volume pre and patient age

	age	N	Mean	Std. Deviation
Urinary bladder volume pre micturition	50-54.5	4	446.750	130.8673
	55-59.5	6	330.167	148.7769
	60-64.5	13	303.462	136.6849
	65-69.5	11	289.682	168.8769
	70-74.5	10	318.000	138.2904
	75-80	11	220.436	151.6735

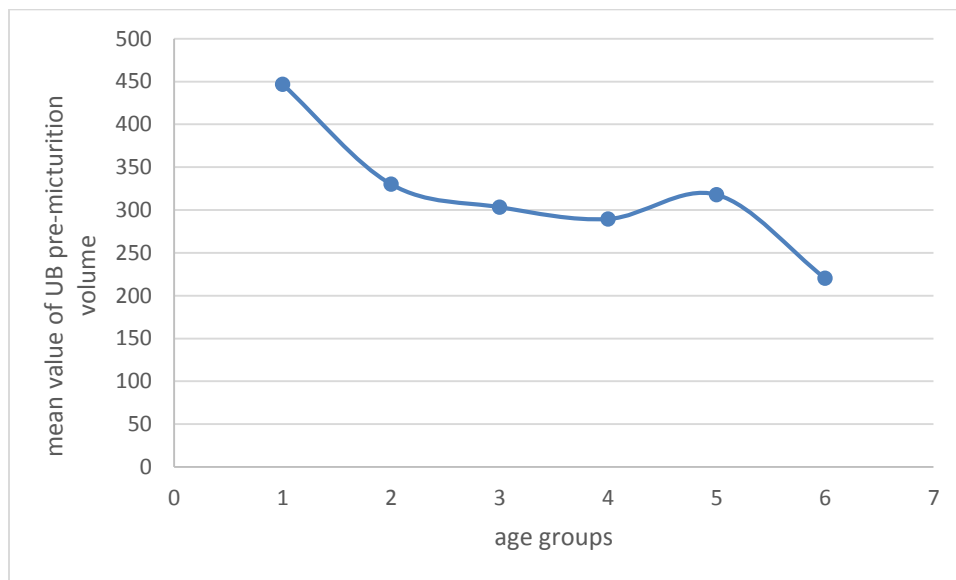
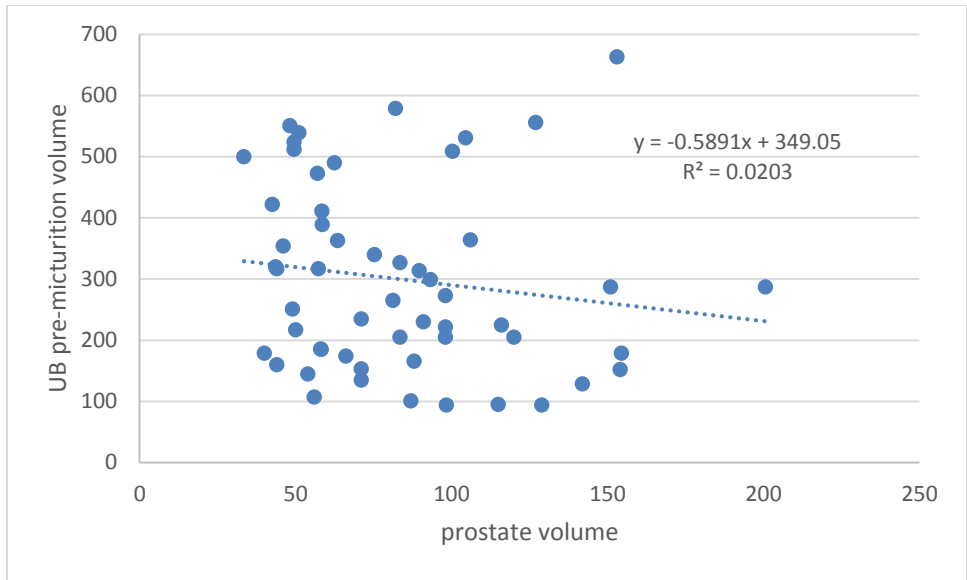


Figure (4-5) A, scatter plot diagramme shows A significant inverse relationship was demonstrated that when the prostate volume increase by one ml the pre micturition volume decreased by 0.6 ml



Figure(4-5) B, scatter plot diagramme shows A significant inverse relationship was demonstrated that when the prostate volume increase by one ml the pre micturition volume decreased by 0.6 ml

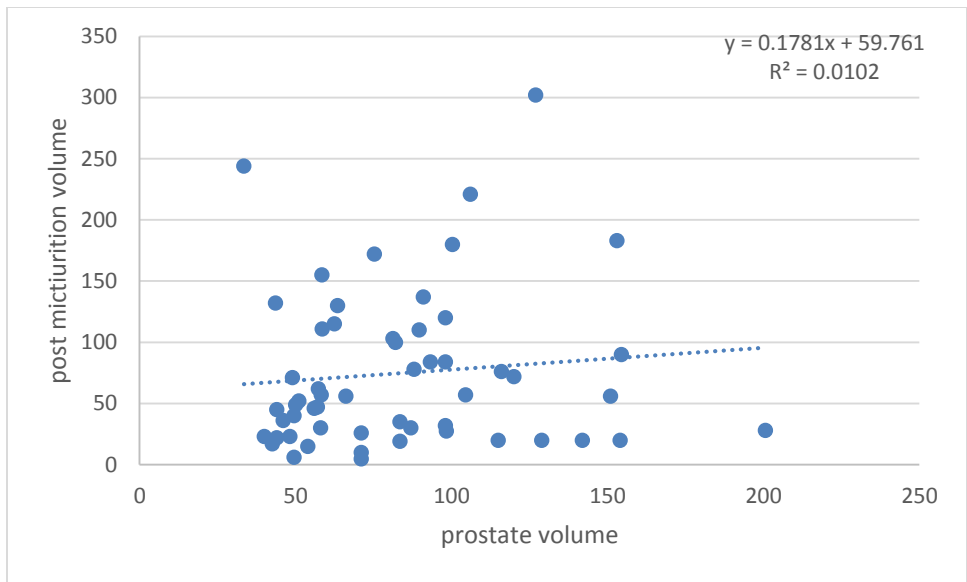


Figure (4-6) a scatter plot digramme shows a linear relationship between the prostate volume and urinary bladder post micturition, when the prostate volume increased by the urinary bladder post micturition

Chapter five

(Discussion, conclusion and recommendation)

5.1. Discussion:

Prostate pathologies are very common in clinical practice and are expected to affect most men at some time during their life. They are associated with increased morbidity and mortality in older men. These pathologies include benign prostatic hyperplasia (BPH) which occurs in elderly men, It can lead to various symptoms of urinary tract obstruction and consequently severe impairment of urine flow. Other prostatic disorders include carcinoma which is the second most common malignancy in adult males. The main objective of this study is to assess the urinary bladder in prostatic patient

Regarding to table(4-1) figure (4-1) the percentage of patient according the age; the high percent is 23 in age group between 60-65.

Regarding to table(4-2) figure (4-2) the urinary bladder wall thickness increased in 5.5% and other was normal.

Concerning to table (4-3) (4-4) show the mean Age of the 55 patients from minimum age was 50 years to maximum age 80 and the mean age is = 66 also the study showed the mean prostate volume in 55 sample from minimum 33.3ml to maximum 200.6 ml and the mean is = 83ml.

Also the study showed the marital status of the 55 patients and it's found that 100% of the patients were married and there wasn't significant relation between Prostate volume increases with marital status according to the past studies.

Also the study showed prostate homogeneity with increased volume in the 55 patient and it was found that 97 % homogenous echo-texture, 3% was heterogeneous echo-texture.

Also the study showed other sonographic appearance related with prostate enlargement and it was found that 87.3% was normal. 9.1 % with calcifications, 3.6% with focal cysts.

Regarding table (4-5) (4-6) show significant difference in urine volume for patient with prostatic enlargement before and after maturation the mean volume of urinary bladder pre maturation =300 that is mean there difficult to full bladder to normal capacity in elder patient men and whom with BPH due that a result from dirtous muscles and this result agree previous study with Oliver .W.Hakeuberg ,etal(2000)(Men with LUTS and BPE show a moderate increase in BWT. Adjustments for bladder volume are for practical purposes negligible, although there is a small decrease in BWT with increasing volume) ,and the mean volume of urinary bladder post maturation =78 that is mean there is residual urine in patient with BPH and elder men this result agree with Chriopher kolman ,et al(2006).

Table (4-7) figure (4-3) show correlation between the prostatic volume and age and there was positive significant association between age progress and Prostate volume increase and the more effected in age between 60-64.5 this result agree with Shi-jun Zhangetal(2009).

Table (4-9) figure (4-4) show the mean and standard deviation of urinary bladder volume pre maturation and patient age

Figure (4-5) A, B shows a significant inverse relationship was demonstrated that when the prostate volume increase by 1 ml the pre micturition volume decreased by 0.6 ml.

5.2. Conclusion:

The study concluded that Benign prostatic hypertrophy was found in male above 49years ,while the men age increased benign prostatic hypertrophy increased, while the prostate volume increases post micturition urinary bladder volume (residual urine)increased, there was relationship between volume of urinary bladder pre and post micturition and benign prostatic hypertrophy was case increased in urinary bladder wall thickness.

5.3. Recommendations:

1. Further studies should be done with large sample size and different variables.
2. routine check-up, follow up must be used to help diagnosis, treatment and control of benign prostatic hypertrophy so it's the gold standard modality in evaluation of prostatic size.
3. The easy and safe way to diagnosis benign prostatic hypertrophy, prostatic classification and residual urine as well is ultrasound.
4. Transrectal ultrasonography as high sensitivity and specificity in visualisation of prostate.
5. The TAS method had a limitation in defining anatomical zones of the prostate, TRS is better in defining anatomical zones and to describe the site of the increase in the prostate so TRS is recommended for future research.
6. Community education will be obtained in patients who have prostate diseases to be evaluated by TRS and to obtain this method to be the first choice in Sudan to evaluate prostate diseases and biopsies.

References:

- Abou Yousef M and Naryana AS (1982). Tran rectal ultrasound in the evaluation of the prostatic size. J. Clin ultrasound. 10: 275-278.
- Abou Yousef M M and Naryana AS (1982). Tran rectal ultrasound in the evaluation of the prostatic size. Ultrasound. 10: 275-278.
- Athanasiou A, Tardivon A, Tanter M, Sigal-Zafrani B, Bercoff J, Deffieux T, Gennisson JL..
- Babaian RJ, et al. (2000). A comparative analysis of sextant and an extended 11-core multisite directed biopsy strategy; 163:152-157.
- Babaian RJ, Toi A, Kamoi K, Troncoso P, Sweet J, Evans R, Johnston D, Chen M. (2000). A comparative analysis of sextant and an extended 11-core multisite directed biopsy strategy. J Urol; 163:152-157.
- Bahn DK, et al, (2002). Targeted
- Bax J, Cool D, et al (2008). Mechanically assisted 3D ultrasound guided prostate biopsy system; 35(12):5397-410.
- Benson MC, et al (1992). Prostate specific antigen density: a means of distinguishing benign prostatic hypertrophy and prostate cancer; 147:815-9.
- Benson MC, Whang IS, Pantuck A, Ring K, Kaplan SA, Olsson CA, et al (1992). Prostate specific antigen density: a means of distinguishing benign prostatic hypertrophy and prostate cancer. J Urol; 147:815-9.
- Brandes D. (1984) prostate gland embryology, anatomy and histology and function.
-
- Carol M. Rumak, et al (2011), Diagnostic Ultrasound part two, 4th Edition Mosby.
- Devin Dean. (2005). Abdominal ultrasound part two, 1st Ed, burwin institute of diagnostic ultrasound.
- Eri, L. M., et al. The effect of bicalutamide on prostate histology. Prostate. (2001) ; 46: 275-80
- Eri, L. M., Svindland, A., Tveter, K. J. The effect of bicalutamide on prostate histology. Prostate. 2001 Mar 1; 46: 275-80
- <http://emedicine.medscape.com/article/1972482-overview#a2>

Jun 29, 2016 Author: Noah S Schenkman, MD; Chief Editor: Thomas R Gest, PhD

- P.E.S.palmer 1995 .manual of diagnostic ultrasound university of California, World Health Origination Geneva, 152,153.
- www.jouefct.com , April 2,2017.

Appendices

