



SUDAN UNIVERSITY OF SCIENCE &
TECHNOLOGY
FACULTY OF GRADUATE STUDIES



Study of Liver in Bilharziasis Patients by ultrasound using
Image Pattern Recognition

دراسة الكبد لمرضي البلهارسيا عن طريق الموجات فوق الصوتية باستخدام
التعرف علي نمط الصورة

*A thesis Submitted for fulfilment of requirement of the PhD
Degree in Diagnostic Ultrasound*

by:

Safaa Abd-Elrahman Mohamed Elhassan

Supervisor:

Prof. Dr. Elsafi Ahmed Abdullah

2017

بِسْمِ اللَّهِ الرَّحْمَنِ الرَّحِيمِ

قَالَ تَعَالَى:

﴿ وَإِذَا مَرِضْتُ فَهُوَ يَشْفِينِ ﴾ ٨٠

صدق الله العظيم

الشعراء: ٨٠

Dedication

To the soul of my grandmother.

To my beloved and blessed parent who did everything for me.

To my sisters who were support and encouraged me .

To my fiancé for his patience, encouragement and continues support .

To all my staff members through all levels of education. To all my colleagues with respect and admiration.

Acknowledgement

First I am grateful to Allah as he helped me to gain knowledge to finish this research. He also gave me health and patience to overcome the difficulties. So I am thankful to him all my life.

I would like to express my great fullness to my main supervisor prof. Alsafi Abdulla for his close supervision .

Secondly my thanks also to my co-supervisor prof. Mohamed Elsfadel for his academic support and guidance throughout this study . He opened canals between me and him to contact at any time.

I should not forget my colleague Dr. murtada Elshaj saiad who helped in data collection in Elmanages in his own clinic .

At last I thank my colleagues who helped me to finished my research.

المستخلص

أجريت هذه الدراسة الانية التحليلية والوصفية في بلدة المناقل في الفترة من 2014 إلى 2017. وكان الهدف الرئيسي من هذه الدراسة هو دراسة الكبد في مرضى البلهارسيا باستخدام الموجات فوق الصوتية والتعرف على نمط الصورة. واستبعدت الدراسة جميع المرضى المصابين بأمراض الكبد الأخرى. اتبعت الدراسة البروتوكول الدولي لاجراء الموجات فوق الصوتية للكبد. تم جمع البيانات، تصنيفها، تحليلها باستخدام برنامج الحزمة الإحصائية للدراسات الاجتماعية. وأظهرت نتائج الدراسة أن المرضى الذكور كانوا الاكثر (58%) مقابل (42%) من الإناث، وكان معظم الأعضاء المتضررة هو الطحال ووجد في حوالي (64%) من المرضى. وأظهرت الموجات فوق الصوتية للكبد أن معظم المرضى لديهم قياسات غير طبيعية في القطر الوريد البابي ، والجانبية، (58%) توسع الوريد البابي (36%) وجود جانبيات. وأظهرت الكبد أن هناك (22%) انخفاض في الحجم، (23%) زيادة، (34%) نقصان في الصدي، (24%) زيادة في الصدي و (51%) نسيج غير متجانس. في الختام يمكن توصيف درجة تليف الكبد باستخدام الموجات فوق الصوتية بموضوعية بدقة (81.1%) وبأستخدام التحليل النسيجي كانت الدقة (94.7%) والحساسية (90.6%) و النوعية (90.1%) باستخدام معادلة التمييزية الخطية.

Abstract

This prospective, analytic, and descriptive study was performed in the Elmanageltown in the period from 2014 to 2017. The main aim of the study was to study the liver in the Bilharziasis patient using Ultrasound and image pattern recognition. The study excluded all patients known other liver disease. The study followed international scanning guideline and protocol to perform liver ultrasound. The data was collected, classified, analyzed using SPSS. The results of the study showed that the male patients were dominant (58%) versus (42%) females, most affected organ was the spleen and was found in about (64%) of patient with enlarge spleen. Liver ultrasound of sample showed that most of the patients developed abnormal portal vein findings in diameter, collateralas (58%) dilated portal vein (36%) presence of collateral. The liver showed that there is (22%) decrease in size, (23%) increase, (34%) hypoechoic, (24%) hyperechoic and (51%) heterogeneous texture. In conclusion liver cirrhosis can be grade using ultrasound objectively with an accuracy of (81.1%) and with the aid of texture analysis accuracy was (94.7%), sensitivity (90.6%) and specificity of (90.1%) using linear discriminant equation.

LIST OF TABLES

Table	Name	Page No
2-1	Modified hepatic activity index	44
4-1	Frequency distribution of patients according to gender	65
4-2	Frequency distribution of patients according to marital status	66
4-3	Frequency distribution of patients according to occupation	67
4-4	Frequency distribution of patients according to liver texture	68
4-5	Frequency distribution of patients according to liver echogenicity	69
4-6	Frequency distribution of patients according to cirrhosis grade of liver	70
4-7	Frequency distribution of patients according to spleen size	71
4-8	Frequency distribution of patients according to present of ascites	72
4-9	Frequency distribution of patients according to portal vein changes	73
4-10	Frequency distribution of patients according to present of collateral	74
4-11	Frequency distribution of patients according to liver size	75
4-12	cross-tabulation table show the relation between marital status and cirrhosis grade in percentage	76
4-13	cross-tabulation table show the relation between texture and cirrhosis grade as percentage	76
4-14	cross-tabulation table show the relation between echogenicity and cirrhosis grade as percentage	77

4-15	cross-tabulation table show the relation between spleen size and cirrhosis grade.	77
4-16	cross-tabulation table show the relation between ascites and cirrhosis grade as percentage	78
4-17	cross-tabulation table show the relation between portal vein and cirrhosis grade as percentage	78
4-18	cross-tabulation table show the relation between collateral and cirrhosis grade as percentage as percentage.	79
4-19	cross-tabulation table show the relation between liver size and cirrhosis grade as percentage	79
4-20	the mean and standard deviation patient age and liver volume for different liver cirrhosis grade	80
4-21	Analysis of Variance table for significance test between age and volume with the liver grade, which shows inconclusive results	81
4-22	confusion matrix show the classification accuracy using linear discriminant analysis and ultrasound findings as input function	83
4-23	confusion matrix showed a correct percentage of cross match results in the diagonal line with the off diagonal matrix gives the miss classification percentage	84

LIST OF FIGURES

Figure	Name	Page No
2-1	The life cycle of schistosom	11
2-2	show anterior view of the liver.	30
2-3	shows posterior-inferior surface of the liver	32
2-4	shows eight segment of the liver	34
2-5	shows three hepatic veins	35
2-6	The gallbladder	49
3-1	Rt medioclavicular line scan of liver	60
3-2	Intercostal scan plane	61
3-3	Sub-costal scan of liver	61
3-4	transverse scan of Lt lobe	62
4-1	Pie graph of percentage distribution of patients according to gender	65
4-2	Pie graph of percentage frequency distribution of patients according to marital status	66
4-3	Pie graph of frequency distribution of patients according to occupation	67
4-4	Pie graph of frequency distribution of patients according to liver texture	68
4-5	pie graph of frequency distribution for patients according to liver echogenicity	69
4-6	Pie graph of frequency distribution for patients according to cirrhosis grade of liver	70
4-7	Pie graph of percentage distribution of patients according to spleen size	71
4-8	pie graph of percentage distribution of patients according to present of ascites	72
4-9	Distribution of patients according to portal vein changes	73

4-10	pie graph of frequency distribution of patients according to present of collateral	74
4-11	pie graph of percentage distribution of patients according to liver size	75
4-12	bar graphs show the distribution of average age in respect to cirrhosis grade	80
4-13	bar graph show the distribution of liver volume in respect to liver cirrhosis grade	81
4-14	scatter plot show the classification of liver cirrhosis grade as classification center using linear discriminant function	82
4-15	scatter plot show the centroid for the class and the distribution of classes around the classification center according to classification function	83
4-16	error bar plot for the textural features (A) mean, (B) variance, (C) skewness, (D) Kurtosis, (E) energy and (F) entropy for liver cirrhosis grade 0, 1, 2 and 3	87

LIST OF CONTENTS

Topic	page No
Quran.....	I
Dedication.....	II
Acknowledgment.....	III
Abstract (Arabic).....	IV
Abstract (English).....	V
List of tables.....	VI
List of figures.....	VIII
List of contents.....	X
List of abbreviation.....	XV

CHAPTER ONE

1-1Introduction.....	1
1-3 Problem of the study.....	2
1-4Objectives.....	2
1-4-1 General Objective.....	2
1-4-2 Specific Objectives.....	2

1-5Hypothesis.....	3
1-6Significance of the study.....	3
1-7 Over view of the study	3

CHAPETR TWO

2-1Schistosomiasis.....	5
2-1-1 Synonyms and related keywords.....	5
2-1-2Background.....	5
2-1-3Definition.....	6
2-1-4Geographical distribution and epidemiology.....	6
2-1-5 Life cycle.....	7
2-1-6Clinical features.....	11
2-1-7History.....	13
2-1-8Laboratory diagnosis.....	16
2-1-9Physiopathology of schistosomiasis.....	18
2-1-10Pathology Associated with Infection by Other Species of Schistosoma.....	20

2-1-11	Complications.....	22
2-1-12	Prognosis.....	22
2-1-13	Medical/Legal Pitfalls.....	23
2-1-14	Special Concerns.....	23
2-1-15	Treatment.....	24
2-1-16	Frequency.....	25
2-1-17	Mortality/Morbidity.....	26
2-1-18	Lab Studies.....	28
2-1-19	Imaging Studies.....	29

Liver

2-2.	Anatomy.....	30
2-2-1	Relations.....	32
2-2-2	Blood supply.....	34
2-2-3	Lymphatic	36
2-3.	Physiology.....	36
2-4.	Pathology.....	38
2-4-1	Cirrhosis.....	38

2-4-2	Fatty	infiltration	
(Steatosis).....			39
2-4-3	Lymphoma of the liver.....		41
2-4-4	Viral	hepatitis	
.....			42
2-4-4-1	Acute hepatitis		43
2-4-4-2	Chronic hepatitis		43
2-5	clinical feature		45

Gall bladder

2-7.	Anatomy.....		48
2-7-1	Blood supply.....		49
2-7-3	Lymphatic		50
2-7-4	Development.....		50
2-8.	Physiology.....		50
2-9.	Pathology.....		51
2-9-1	Benign	Polypoid	lesions
.....			51
2-3	Background studies		52

CHATER THREE

3-1	Study Population sampling and study area.....	59
3-2	Study design and duration.....	59

3-3 Technique	59
3-4 Inclusion criteria of the study cases.....	62
3-5 Exclusion criteria.....	62
3-6 Study variables	62
3-7 Date collection instrument.....	63
3-8 Data processing and analysis.....	63
3-9 Limitation of this study.....	64
3-10 Ethics issue	64

CHAPTER FOUR

Results.....	65
--------------	----

CHAPETR FIVE

5-1 Discussion.....	88
5-2 Conclusion	93
5-3 Recommendations	94

References

Appendix

Chapter One

Introduction

1-1 Pattern Recognition:

PR is the task of automatically detecting patterns in datasets and using them to characterize new data. PR is a form of machine learning, which itself is a field within artificial intelligence. Machine learning can be divided into two major groups. In supervised learning, or PR, a computer system is trained using a set of pre-defined classes, and then used to classify unknown objects based on the patterns detected in training. In unsupervised learning there are no classes defined a priori, and the computer system subdivides or clusters the data, usually by using a set of general rules. An example of supervised learning is automatic detection of protein localization, in which the computer system is trained using images of probes for known sub-cellular compartments (Ljosa et al 2010). An example of unsupervised learning is clustering an expression profiling microarray experiment into groups of genes with similar expression patterns (Colelho Lp et al 2010).

Other approaches to PR include semi-supervised learning, which uses pre-defined classes to find new similarity relationships and define new groups, and reinforcement learning, in which decisions are improved iteratively based on a feedback mechanism and specified reward criteria. In this educational article we focus on the application of supervised learning to automated analysis of microscopy image datasets (Gooding AR et al 2008).

1-2 Bilharziasis :

Schistosomiasis has been recognized since the time of the Egyptian pharaohs . The worms responsible for the disease were eventually discovered in 1851 by Theodore Bilharz, a young German pathologist, from whom the disease took its original name, Bilharziasis . The disease is indicated either by the presence of blood in the urine or , in the case of intestinal Schistosomiasis, by initially atypical symptoms which can lead to serious complications involving the liver and spleen (Lutz et al 2006). People are infected by contact with water used in normal daily activities such as personal or domestic hygiene and swimming, or by professional activities such as fishing , rice cultivation and irrigation(Gerie et al 1978) .

1-3 Problem of the study

Ultrasound is operator depended and diagnosis of the changes in the liver is difficult and similar in appearance and this technique to assess the changes in liver and grading of liver cirrhosis in an objective method.

1-4 OBJECTIVES

1-4-1 General Objective

To study the liver in the Bilharziasis patient using Ultrasound and image pattern recognition.

1-4-2 Specific Objectives

- To measure the size and volume of the liver.
- To find the echo texture and echogenicity of the liver.

- To measure the size of the spleen.
- To find the status of ascites and collateral
- To extract first order statistical feature from liver ultrasound images affected by Bilharziasis
- To grade the cirrhosis of the liver using visual perception finding, linear discriminant analysis for ultrasound finding and texture analysis
- To find the accuracy, sensitivity and specificity of classification accuracy.

1-5 HYPOTHESES

Ultrasound is an effective modality in evaluation of Liver diseases.

1-6Significance of the study

Sudan is one of the endemic countries of schistosomiasis and effect Mostly the children and young adults, and this is the age of learning And productive there for it's very important to use all modalities to Asses the disease and prevent the Complications and also there need of Provide authorities information and guidance aimed to promoting andprotective health then controllingdisease.

1-7Over view of the study

This study is concerned the study of liver in the Bilharziasis patient using Ultrasound and image pattern recognition in order to grade the cirrhosis of the liver, it falls into five chapters. Chapter one is an introduction, which include introductory notes on image pattern recognition and Bilharziasis, as well as statement of the problem and study objectives. While Chapter two included a comprehensive scholarly literature reviews concerning the

previous studies. Chapter three deals with the methodology, where it provides an outline of material and methods used to acquire the data in this study as well as the method of analysis approach. While the results were presented in chapter four, and finally Chapter five include discussion of results, conclusion and recommendation followed by references and appendices.

Chapter Two

2-1 Schistosomiasis

2-1-1 Synonyms and related keywords:

bilharzias is, parasitic trematodes, human schistosomiasis, *Schistosoma haematobium*, *S.haematobium*, *Schistosoma mansoni*, *S.mansoni*, *Schistosoma japonicum*, *S.japonicum*, *Schistosoma mekongi*, *S.mekongi*, *Schistosoma intercalatum*, *S.intercalatum*, schistosomes (J-Richter et al 1992).

2-1-2 Background:

Schistosomiasis (i.e., bilharzias) is a human disease syndrome caused by infection from one of several species of parasitic trematodes of the genus *Schistosoma*. Schistosomiasis is a major source of morbidity and mortality for developing countries in Africa, South America, the Caribbean, the Middle East, and Asia. Tourism to and immigration from endemic areas can result in schistosomiasis cases presenting anywhere in the developed world.

Most human schistosomiasis is caused by *Schistosoma haematobium*, *Schistosoma mansoni*, or *Schistosoma japonicum*. Less prevalent species such as *Schistosoma mekongi* and *Schistosoma intercalatum* also may cause systemic human disease. Less importantly, other schistosomes with avian or mammalian primary hosts can cause severe dermatitis in humans (eg, swimmer's itch secondary to *Trichobilharzia ocellata*) (G.Gerie et al 1978).

2-1-3 Definition

Schistosomiasis or bilharzias is a disease affecting many people in developing countries. In the form of 'acute' schistosomiasis, it is sometimes referred to as snail fever and cutaneous schistosomiasis may sometimes be commonly called swimmer's itch. In certain African communities the process of overcoming schistosomiasis is an important rite of passage. Although it has a low mortality rate, schistosomiasis can be very debilitating. (Bilharzia, or bilharzias, is the eponym for schistosomiasis in many countries, after Theodor Bilharz, who first described the cause of urinary schistosomiasis in 1851 (G.Gerie et al 1978).

2-1-4 Geographical distribution and epidemiology

The disease is found in tropical countries in Africa, Caribbean, eastern South America, east Asia and in the Middle East. *Schistosoma mansoni* is found in parts of South America and the Caribbean, Africa, and the Middle East; *S. haematobium* in Africa and the Middle East; and *S. japonicum* in the Far East. *S. mekongi* and *S. intercalatum* are found focally in Southeast Asia and central West Africa, respectively. An estimated 207 million people have the disease, 120 million symptomatic. A few countries have eradicated the disease, and many more are working towards it. The World Health Organization is promoting efforts working towards this goal. In some cases, urbanization, pollution, and/or consequent destruction of snail habitat has reduced exposure, with a subsequent decrease in new infections. The most common way of getting schistosomiasis in developing countries is by wading or swimming in lakes, ponds and other bodies of water which are infested with the snails (usually of the *Biomphalaria*, *Bulinus*, or

Oncomelania genus) that are the natural reservoirs of the *Schistosoma* pathogen (Klootzek 1992).

2-1-5 Life cycle

Schistosomiasis life cycle

Schistosomes have a typical trematode vertebrate-invertebrate lifecycle, with humans being the definitive host. The life cycles of all five human schistosomes are broadly similar: parasite eggs are released into the environment from infected individuals, hatching on contact with fresh water to release the free-swimming miracidium. Miracidia infect fresh-water snails by penetrating the snail's foot. After infection, close to the site of penetration, the miracidium transforms into a primary (mother) sporocyst. Germ cells within the primary sporocyst will then begin dividing to produce secondary (daughter) sporocysts, which migrate to the snail's hepatopancreas. Once at the hepatopancreas, germ cells within the secondary sporocyst begin to divide again, this time producing thousands of new parasites, known as cercariae, which are fork-tailed free-swimming larvae approximately 1 mm in length. The cercariae survive in freshwater up to 48 hours, during which time they must attach to human skin or to that of another susceptible host mammal or die (H.Elmasri 2003).

Cercariae emerge daily from the snail host in a circadian rhythm, dependent on ambient temperature and light. Young cercariae are highly motile, alternating between vigorous upward movement and sinking to maintain their position in the water. Cercarial activity is particularly stimulated by water turbulence, shadows and human skin chemicals. Penetration of the

human skin occurs after the cercaria have attached to and explored the skin. The parasite secretes enzymes that break down the skin's protein to enable penetration of the cercarial head through the skin. As the cercaria penetrates the skin it transforms into a migrating schistosomulum stage (Kloetzek 1992).

The newly transformed schistosomulum may remain in the skin for 1-2 days before locating a post-capillary venule; from here the schistosomulum travels to the lungs where it undergoes further developmental changes necessary for subsequent migration to the liver. Eight to ten days after penetration of the skin, the parasite migrates to the liver sinusoids. *S. japonicum* migrates more quickly than *S. mansoni*, and usually reaches the liver within 6-8 days of penetration. Juvenile *S. mansoni* and *S. japonicum* worms develop an oral sucker after arriving at the liver, and it is during this period that the parasite begins to feed on red blood cells. The nearly-mature worms pair, with the longer female worm residing in the gynaecophoric channel of the male. Adult worms are about 10 mm long. Worm pairs of *S. mansoni* and *S. japonicum* relocate to the mesenteric or rectal veins (H.Elmasri 2003).

S. haematobium schistosomula ultimately migrate from the liver to the perivesical venous plexus of the bladder, ureters and kidneys through the hemorrhoidal plexus (H.Elmasri 2003).

Parasites reach maturity in 6-8 weeks, at which time they begin to produce eggs (H.Elmasri 2003).

Adult *S. mansoni* pairs residing in the mesenteric vessels may produce up to 300 eggs per day during their reproductive lives. *S. japonicum* may produce up to 3000 eggs per day. Many of the eggs pass through the walls of the blood vessels, and through the intestinal wall, to be passed out of the body in faeces. *S. haematobium* eggs pass through the ureteral or bladder wall and into the urine. Only mature eggs are capable of crossing into the digestive tract, possibly through the release of proteolytic enzymes, but also as a function of host immune response, which fosters local tissue ulceration (J-Richter et al 1992).

Up to half the eggs released by the worm pairs become trapped in the mesenteric veins, or will be washed back into the liver, where they will become lodged. Worm pairs can live in the body for an average of four to five years, but may persist up to 20 years (H.Elmasri 2003).

Trapped eggs mature normally, secreting antigens that elicit a vigorous immune response. The eggs themselves do not damage the body. Rather, it is the cellular infiltration resultant from the immune response that causes the pathology classically associated with schistosomiasis (G.Gerie et al 1978).

The geographic distribution and pathophysiology of schistosomiasis reflect the unique life cycle of these parasites. Schistosomiasis infect particular species of susceptible freshwater snails in endemic areas. The infected snails release cercariae, which are fork-tailed free-swimming larvae approximately 1 mm in length. The cercariae survive in freshwater up to 48 hours, during which time they must attach to human skin or to that of another susceptible host mammal or die (Hanan E.mohamed 1990).

Cercariae attach to human hosts utilizing oral and ventral suckers. They then migrate through intact skin to dermal veins and, over the next several days, to the pulmonary vasculature. During this migration, the cercariae metamorphose, shedding tails and outer glycocalyxes while developing double-lipid-bilayer teguments that are highly resistant to host immune responses (Homeida et al 2002) .

The organisms, now called schistosomula, incorporate host proteins, including major histocompatibility complexes (MHCs) and blood group antigens, in their integuments. Their metabolism shifts to glycolysis. The worms then migrate through the pulmonary capillaries to the systemic circulation, which carries them to the portal veins where they mature. Within the portal vasculature, male and female adults pair off, with the thin female entering and remaining in the gynecophoric canal of the stockier 8-mm male worm. Together they migrate along the endothelium, against portal blood flow, to the mesenteric (*S. mansoni*, *S. japonicum*) or vesicular (*S. haematobium*) veins where they begin to produce eggs (Homeida et al 2002).

The eggs, which are highly antigenic and can induce an intense granulomatous response, migrate through the bowel or bladder wall to be shed via feces or urine. During this time (approximately 10 d) they begin to mature into miracidia. Eggs that are not shed successfully may remain in the tissues or be swept back to the portal circulation (from the mesenteric vessels) or to the pulmonary circulation (from the vesicular vessels via the inferior vena cava [IVC]) (Homeida et al 2002).

The free-swimming miracidia that are shed into freshwater survive 2-3 weeks, during which time they must infect a susceptible snail to complete the life cycle. Within the infected snail, 2 generations of sporocysts multiply, mature into free-swimming cercariae, and exit the snail to seek a human host and begin a new cycle (Homeida et al 2002).

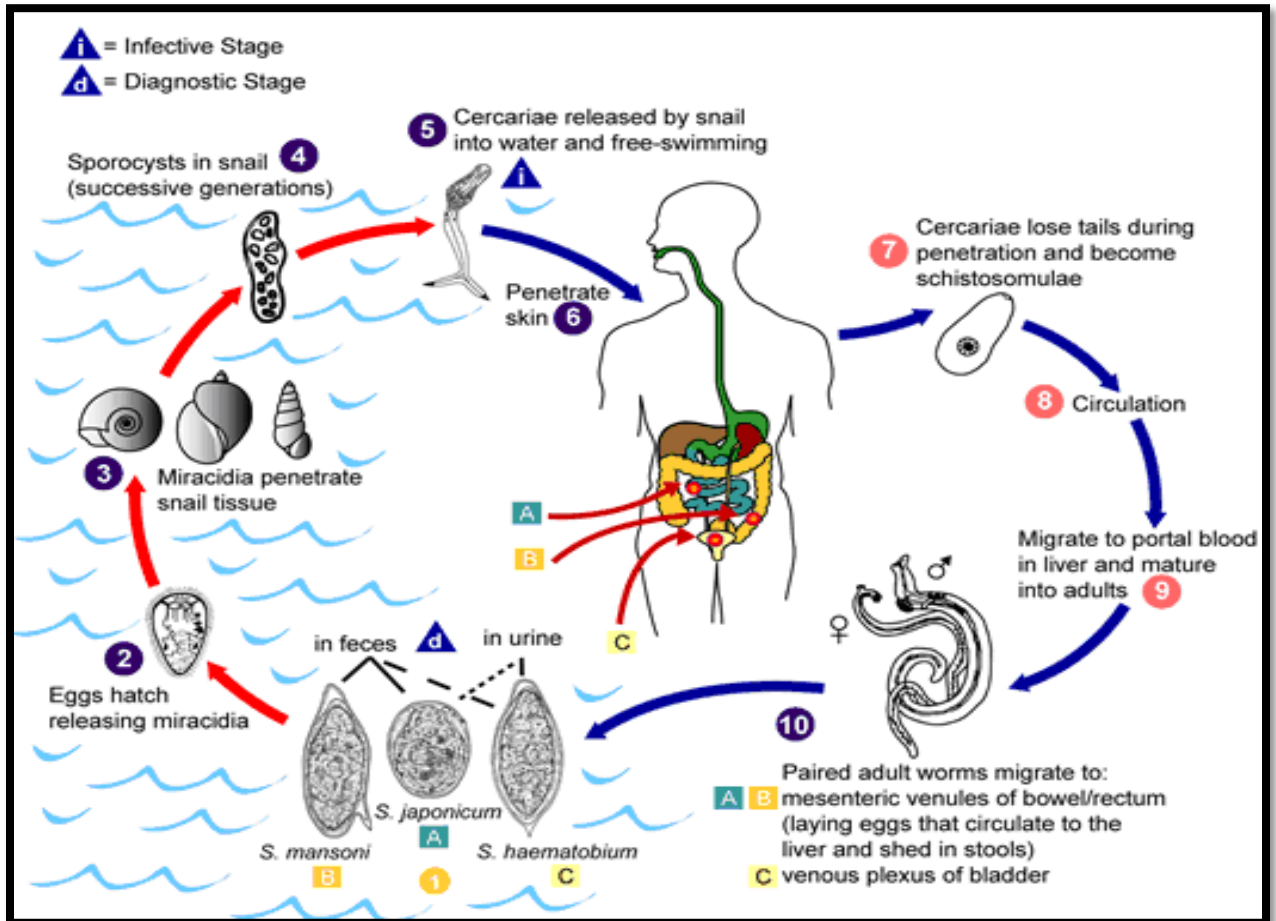


Fig: (2-1). The life cycle of schistosom

2-1-6 Clinical features

Many infections are subclinically symptomatic, with mild anemia and malnutrition being common in endemic areas. Acute schistosomiasis

(Katayama's fever) may occur weeks after the initial infection, especially by *S. mansoni* and *S. japonicum*. Manifestations include (Williman et al 1992):

- Abdominal pain
- Cough
- Diarrhea
- Eosinophilia - extremely high white blood cell count.
- Fever
- Fatigue

Hepatosplenomegaly - the enlargement of both the liver and the spleen (Williman et al 1992).

Occasionally central nervous system lesions occur: cerebral granulomatous disease may be caused by ectopic *S. japonicum* eggs in the brain, and granulomatous lesions around ectopic eggs in the spinal cord from *S. mansoni* and *S. haematobium* infections may result in a transverse myelitis with flaccid paraplegia. Continuing infection may cause granulomatous reactions and fibrosis in the affected organs, which may result in manifestations that include (Williman et al 1992):

- Colonic polyposis with bloody diarrhea (*Schistosoma mansoni* mostly);
- Portal hypertension with hematemesis and splenomegaly (*S. mansoni*, *S. japonicum*);
- Cystitis and ureteritis (*S. haematobium*) with hematuria, which can progress to bladder cancer;
- Pulmonary hypertension (*S. mansoni*, *S. japonicum*, more rarely *S. haematobium*);

Glomerulonephritis; and central nervous system lesions (Williman et al 1992).

2-1-7History:

Patients with acute schistosomiasis (Katayama fever) present several weeks after contact with infested water. Obtaining a careful travel history, including drinking water sources and recreational activities, is important. Symptoms are likely secondary to immune complex formation following egg deposition in tissues; the illness resembles serum sickness (Williman et al 1992).

- Fever
- Headache
- Malaise
- Arthralgias/myalgias
- Cough
- Bloody diarrhea
- Right upper quadrant (RUQ) pain

Patients with symptomatic chronic schistosomiasis may present months to years after primary exposure. A complete lifelong travel history is important for diagnosis. Many patients do not have a history of acute schistosomiasis. Many patients have few or mild symptoms. Individuals with symptoms may present with nonspecific complaints reflecting their level of infection, the

primary location of egg production for the schistosomal species involved (eg, mesenteric, bladder wall), the extent of hepatosplenic involvement, the extent of cardiopulmonary involvement, and the presence of ectopic sites (eg, CNS) (Williman et al 1992).

- Bloody diarrhea
 - Abdominal pain, RUQ pain, cramping
 - Hematemesis (with portal hypertension)
 - Ascitis (with portal hypertension)
 - Hematuria, dysuria
 - Vulvar or perianal lesions
 - Dyspnea on exertion (with pulmonary hypertension)
 - Fatigue (with pulmonary hypertension)
 - Cough (with pulmonary hypertension)
 - Palpitations (with pulmonary hypertension)
 - Atypical chest pain (with pulmonary hypertension)
 - Seizures and/or mental status changes (with cerebral involvement)
- Paralysis (with spinal cord involvement) (Williman et all 1992).

Physical: Physical findings vary with the stage of illness, worm burden, worm location, and end-organ involvement.

1- Acute schistosomiasis:

- Fever
- Hepatosplenomegaly
- RUQ tenderness
- Urticaria (occasional)
- Lymphadenopathy (Jain et al 1994) .

2- Chronic schistosomiasis:

- Hepatosplenomegaly
- Abdominal tenderness
- Heme-positive stool and/or bloody diarrhea
- Ascitis
- Pedal edema (with right heart failure)
- Seizures, focal neurologic signs, and/or altered mental status (with cerebral infection)
- Paralysis (with spinal core involvement)

- Vulvar or perianal lesions, which may be hypertrophic, ulcerated, or fistulous (Lesions may mimic sexually transmitted diseases.) (Jain et al 1994).

Causes: Most human schistosomiasis is caused by *S haematobium*, *S mansoni*, or *S japonicum*. Less prevalent species, such as *S mekongi* and *S intercalatum*, also may cause systemic human disease (Jain et al 1994).

Other Problems to be considered:

Cirrhosis

Pulmonary

hypertension

Co-infection

with

malaria

Co-infection

with

HIV

Co-infection with hepatitis B or hepatitis C (Jain et al 1994).

2-1-8Laboratory diagnosis

Microscopic identification of eggs in stool or urine is the most practical method for diagnosis. The stool exam is the more common of the two. For the measurement of eggs in the feces of presenting patients the scientific unit used is epg or eggs per gram. Stool examination should be performed when infection with *S. mansoni* or *S. japonicum* is suspected, and urine examination should be performed if *S. haematobium* is suspected. Eggs can be present in the stool in infections with all *Schistosoma* species (Guton 1986).

The examination can be performed on a simple smear (1 to 2 mg of fecal material). Since eggs may be passed intermittently or in small amounts, their

detection will be enhanced by repeated examinations and/or concentration procedures (such as the formalin-ethyl acetate technique). In addition, for field surveys and investigational purposes, the egg output can be quantified by using the Kato-Katz technique (20 to 50 mg of fecal material) or the Ritchie technique (Guton 1986).

Eggs can be found in the urine in infections with (recommended time for collection: between noon and 3 PM) and with *S. japonicum* na *S. intercalatum*. Detection will be enhanced by centrifugation and examination of the sediment. Quantification is possible by using filtration through a Nucleopore membrane of a standard volume of urine followed by egg counts on the membrane. Investigation of *S. haematobium* should also include a pelvic x-ray as bladder wall calcification is highly characteristic of chronic infection (Jain et al 1994).

Recently a field evaluation of a novel handheld microscope was undertaken in Uganda for the diagnosis of intestinal schistosomiasis by a team led by Dr. Russell Stothard who heads the Schistosomiasis Control Initiative at the Natural History

Museum, London. His report abstract may be found here.

Photomicrography of bladder in *S. haematobium* infection, showing clusters of the parasite eggs with intense eosinophilia.

Tissue biopsy (rectal biopsy for all species and biopsy of the bladder for *S. haematobium*) may demonstrate eggs when stool or urine examinations are negative.

The eggs of *S. haematobium* are ellipsoidal with a terminal spine, *S. mansoni* eggs are also ellipsoidal but with a lateral spine, *S. japonicum* eggs are spheroidal with a small knob.

Antibody detection can be useful in both clinical management (e.g., recent infections) and for epidemiologic surveys (Jain et al 1994).

2-1-9 Physiopathology of schistosomiasis

2-1-91 Acute phase of infection

Acute schistosomiasis (i.e., Katayama fever) is a serum sickness–like illness that develops after several weeks in some, but not most, individuals with new schistosomal infections. It may correspond to the first cycle of egg deposition and is associated with marked peripheral eosinophilia and circulating immune complexes. It is most common with *S japonicum* and *S mansoni* infections and is most likely to occur in heavily infected individuals after primary infection. Symptoms usually resolve over several weeks, but the syndrome can be fatal. Early treatment with cidal drugs may exacerbate this syndrome and necessitate concomitant glucocorticoid therapy (Curry et al 1995) .

Mild maculopapular skin lesions may develop in acute infection within hours after exposure to cercariae. Significant dermatitis is rare with the major human schistosomal pathogens, probably because the invading and developing cercariae are minimally immunogenic. However, abortive human infection with schistosomal species that rely on other primary hosts may cause marked dermatitis or swimmer's itch. This self-limited process may

recur more intensely with subsequent exposures to the same species (Curry et al 1995) .

This phase of the infection is often asymptomatic, but when symptoms do occur they include fever, nausea, headache, an irritating cough and, in extreme cases diarrhea accompanied with blood, mucus and necrotic material. These symptoms, if present, last from a few weeks, to several months. It is not as commonly associated with *S. mansoni* infections compared with those of *S. japonicum* (Curry et al 1995) .

2-1-9-2Chronic phase of infection

Pathology of chronic schistosomiasis, which is far more common than the acute form of the infection, results from egg-induced immune response, granuloma formation, and associated fibrotic changes. Although cercarial and adult worms are minimally immunogenic, schistosomal eggs are highly immunogenic and induce vigorous circulating and local immune responses. (Eggs may require an intense immune response to aid their migration through the body.) (Curry et al 1995) .

Egg retention and granuloma formation in the bowel wall (usually *S mansoni* or *S japonicum*) may cause bloody diarrhea, cramping, and, eventually, inflammatory colonic polyposis. Patients with heavy bowel wall involvement have an increased rate of recurrent salmonella infection, generally with positive blood cultures and negative stool cultures (Curry et al 1995) .

Unshed eggs, which are swept back to the portal circulation, lodge there and induce granulomatous reactions in the portal tracts. Heavy infestations are

more likely to produce hepatic disease. Eventually, severe fibrosis in a characteristic pipe stem pattern may occur. Although hepatocellular function is spared, periportal fibrosis can lead to portal hypertension with the usual possible sequelae, including splenomegaly, ascitis, esophageal variceal bleeding, and development of Porto systemic collaterals. Through these collaterals (or directly from the IVC in the case of bladder wall schistosomiasis), eggs can reach the pulmonary circulation. The resulting pulmonary granulomatosis and fibrosis can lead to pulmonary hypertension and frank cor pulmonale with a high mortality rate. Co-infection with hepatitis B or hepatitis C can accelerate hepatic dysfunction and raise the risk for hepatocellular carcinoma beyond that seen with hepatitis alone (Curry et al 1995) .

Egg retention and granuloma formation in the urinary tract (*S haematobium*) can lead to hematuria, dysuria, bladder polyps and ulcers, and even obstructive uropathies. *S haematobium* infection also is associated with an increased rate of bladder cancer, usually squamous cell rather than transitional cell (Curry et al 1995) .

2-1-10 Pathology Associated with Infection by Other Species of Schistosoma

S. japonicum Infection

The primary cause of pathology here is a granulomatous reaction to egg trapped in the liver, and both the acute and chronic aspects of the disease are similar to that of *S. mansoni* infections, although the acute disease Katayama fever, is more common here than for *S. mansoni* . The chronic stage of the

disease may also be more severe, owing to the greater egg output and longevity of *S. japonicum* females compared with those of *S. mansoni* (J-Richter et al 1992).

S. haematobium Infection

Adult parasites are found in small venules around the bladder and ureter, with the majority of egg deposition in the tissues of these organs, as eggs pass through the bladder wall, to leave the body in the urine. The disease cause is chronic in nature, with the most frequently affected organ being the urinary bladder, where calcification of eggs trapped in the tissues often occurs. The disease is characterised by blood in the urine (**hematuria**), hence the infection is often referred to as '**Urinary Schistosomiasis**'. Cancer of the bladder is an important complication of infection with *S. haematobium*. Eggs may be deposited in the liver, often in high numbers, and granuloma formation may occur, but this is much less severe than with *S. mansoni* (Kooetzek 1992) .

Minor species S. Intercalatum infection

This is diagnosed by the presence of terminally spined eggs in the faeces, (the other terminally spined schistosomes eggs, those of *S. haematobium*, are only found in the urine). Blood may be seen in the faeces, and diarrhea may occur. However the portal hypertension . seen in *S. mansoni* infections has not been reported, and infections are often asymptomatic. *S. mekongi* infection. This has not been greatly studied, but the pathology appears to be similar to that of *S. japonicum* (G.Gerie et al 1978).

Schistosome species where man is NOT a permissive host

Cercarial Dermatitis - This is also called '**Swimmers Itch**', and is mainly associated with cercaria of species of schistosome that normally infect birds or small mammals, and which are not capable of fully developing in man (i.e. man is not a permissive host). Cercarial dermatitis occurs shortly after penetration of the hosts skin by these cercaria, and is caused by dead or dying larvae in the skin. It is a hypersensitivity reaction, characterised by a skin rash, the severity of which varies considerably, depending on factors such as the degree of previous exposure to the cercaria (J-Richter et al 1992).

2-1-11 Complications:

1. End-organ disease
2. Pulmonary hypertension
3. Cor pulmonale
4. Portal hypertension
5. Obstructive uropathy
6. Gastrointestinal bleeding (Curry et al 1995).

2-1-12 Prognosis:

1. Almost all patients improve with treatment.
2. Most patients with early disease or without severe end-organ complications recover completely.

3. Surprisingly, patients with hepatic and urinary disease, even with fibrosis, may improve significantly over months or years following treatment.
4. Resolution of pulmonary disease is less well documented.
5. Patients with heavier worm burdens are less likely to improve and are more likely to require re-treatment.
6. Treatment is indicated for patients with end-stage complications of portal hypertension and severe pulmonary hypertension, but these patients are much less likely to benefit.
7. Co-infection (with malaria, HIV, or hepatitis) worsens the prognosis (Sanral et al 2005).

2-1-13 Medical/Legal Pitfalls:

It is important to take a complete travel and residence history and to consider the diagnosis of schistosomiasis in appropriate patients presenting with nonspecific findings, such as fever, bloody diarrhea, hematuria, portal hypertension, pulmonary hypertension, or CNS abnormalities. Antischistosomal treatment can arrest or improve many of these processes and prevent further complications (Sanral et al 2005).

2-1-14 Special Concerns:

Pregnancy: Physicians may prefer to defer treatment until after the first trimester.

1. Pediatric

- Pediatric and adolescent patients who have traveled or lived in endemic areas are at the highest risk for exposure to schistosomes and are at risk for serious long-term complications.
- These patients usually respond well to drug therapy and should receive aggressive treatment and follow-up care (Sanral et al 2005).

2-1-15Treatment

Schistosomiasis is readily treated using a single oral dose of the drug Praziquantel. While Praziquantel is safe and highly effective in curing an infected patient, it does not prevent re-infection by cercariae and is thus not an optimum treatment for people living in endemic areas. As with other major parasitic diseases, there is ongoing and extensive research into developing a vaccine that will prevent the parasite from completing its life cycle in humans.

Antimony has been used in the past to treat the disease. In low doses this toxic metalloid bonds to sulfur atoms in enzymes used by the parasite and kills it without harming the host. This treatment is not referred to in present-day peer-review scholarship; Praziquantel is universally used. Outside of the US, there is a second drug available for treating *Schistosoma mansoni* (exclusively) called Oxamniquine (M.Ali 1990).

2-1-16 Frequency:

In the US: Acute and chronic schistosomiasis infections are not common in the United States. Although it is estimated that 400,000 infected persons have immigrated to this country, neither susceptible snail species nor chronically infected human reservoirs sufficient to infest freshwater exist. However, pathogenic schistosomes can survive and replicate in human hosts for years and even decades. Therefore, persons who have traveled or immigrated may present to EDs with active cases of acute or chronic schistosomiasis and/or the associated end-organ complications described (Coral-Krebs 1993).

Internationally: Globally, schistosomiasis is a major source of morbidity and mortality. The unique schistosomal life cycle limits endemic areas to tropical and subtropical zones, but these areas exist around the world. Geographic spread continues because of water resource engineering in developing countries and the migration of infected populations. At least 200 million people in at least 74 countries have active schistosomal infection. Of these, approximately 120 million people have symptoms, and 20 million are severely ill. Disease prevalence is heterogeneous in vulnerable locales and tends to be worse in areas with poor sanitation, increased freshwater irrigation usage, and heavy schistosomal infestation of human and/or snail populations (Palmer 1995).

Schistosomal species vary with geography: *S mansoni* and *S haematobium* infections predominate in sub-Saharan Africa. *S mansoni* is endemic in parts of South America and the Caribbean. *S japonicum* is common in China, Indonesia, and the Philippines (Palmer 1995).

2-1-17Mortality/Morbidity

Acute schistosomiasis is associated with a mortality rate of up to 25% in some series. Although most individuals with chronic schistosomiasis have few or no symptoms, significant morbidity can develop (Curry et al 1995).

Complaints are difficult to quantitate because of the geographical distribution of this infection in underdeveloped nations and the frequency of comorbid conditions such as hepatitis. Hepatosplenic disease with portal hypertension is the most common long-term serious outcome, followed by cardiopulmonary involvement, obstructive nephropathy, bacteremia, and malignancy (Curry et al 1995).

End-stage hepatosplenic disease with variceal bleeding, pulmonary hypertension with cor pulmonale, and central nervous system disease are associated with high mortality rates. Although effective treatments have been developed, they may not reverse fibrosis and may not be readily available in endemic areas (Curry et al 1995).

Race:

The frequency of infection among individuals of specific races is based on the geographic distribution of endemic schistosomiasis in large tropical and subtropical regions of Africa, Asia, the Middle East, and the Caribbean. However, all humans appear equally susceptible if exposed to infested freshwater.

The frequency of some complications appears to vary geographically during infection with the same worm species (eg, ascites is more common in the Middle East than in Brazil) (Devin Dean 2005).

Sex: In some endemic areas, rates of symptomatic infection are lower in females than in males. This may reflect lifestyle differences between men and women regarding the likelihood of bathing or drinking from contaminated streams or irrigation ditches. *S haematobium* causes genital lesions in 30% of women who are infected. Vulval lesions may increase the risk of HIV transmission (Devin Dean 2005).

Age:

1. The prevalence and severity of schistosomal infections vary with age.
2. Children and adolescents are infected most often and are infested most heavily.
3. Infections peak in individuals aged 10-19 years. In some areas, the prevalence in this group may approach 100%.
4. In persons older than 19 years, the prevalence of active infection and egg counts slowly declines in populations living in endemic areas. (End-stage complications may persist or worsen.) This decline in active infection may reflect that individuals have an increasing host immune response or a decreasing exposure to contaminated water as they age (Devin Dean 2005).

2-1-18Lab Studies:

- Blood tests are occasionally useful in supporting the diagnosis or assessing the severity of schistosomal infection.
- A complete blood count (CBC) may reveal peripheral eosinophilia, particularly in acute infection, anemia, or both (Moore et al 2007).
- Chemistries
 - 1- An increased alkaline phosphatase and gamma-glutamyltransferase (GGT) are observed with hepatic granulomatosis.
 - 2- Transaminases generally are not affected, and elevations are usually caused by coexisting hepatitis
 - 3- Renal function may be decreased if obstructive nephropathy is severe fever and for those who may have developed recurrent salmonella infection with severe enteric schistosomiasis.
 - 4- Performing a urinalysis is key when diagnosing vesicular infection from *S haematobium*. Gross and microscopic hematuria is common (Moore et al 2007).

Examining stool specimens is key when diagnosing schistosomiasis with primary bowel infection. Stool (Moore et al 2007).

2-1-19Imaging Studies:

1- Ultrasonography

- Ultrasonography (US) is a sensitive means of assessing hepatosplenic disease with periportal fibrosis or urinary obstruction (Jain et al 1989).
- It can demonstrate periportal fibrosis, splenomegaly, portal collaterals, periportal adenopathy, ureteral obstruction, and obstructive nephropathy (Jain et al 1989).

2- Echocardiography can demonstrate pulmonary hypertension and cor pulmonale, if present (M.abdalwahab 1992).

3-chest x-rays may indicate pulmonary hypertension and cor pulmonale, if present (M.abdalwahab 1992).

4-CT scanning may be useful in the evaluation of CNS disease or in the detection of periportal fibrosis (Moore et al 2007).

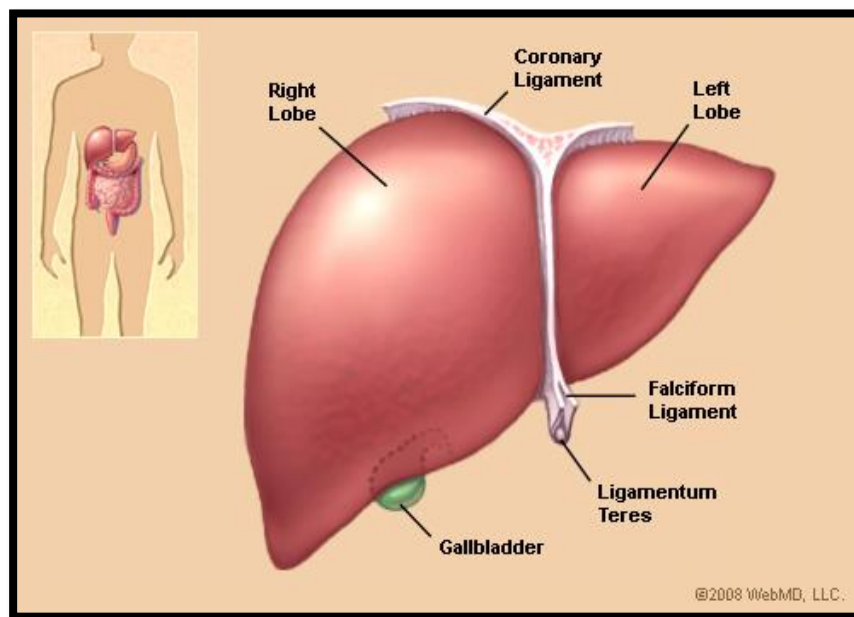
5-Magnetic resonance imaging (MRI) may be useful in the evaluation of CNS disease or in the detection of periportal fibrosis (Moore et al 2007).

Literature Review for anatomy and physiology of interest organs.

Anatomy and physiology

2-2Anatomy of the liver

The liver is the largest internal organ and gland in the body, weighs approximately 1500g. The wedge shape organ occupies most of right hypochondrium and epigastrium region. It has two surface, diaphragmatic and visceral. The diaphragmatic surface is convex and descriptively subdivided into anterior, superior, posterior, and right surface. (fig 3-1) (Jane Bates 2004).



Figure(2-2):show anterior view of the liver (Rose De Bruin 2005).

Surface marking

The upper margin of the liver is approximately level with the xiphisternal joint. On the left it reaches the fifth inter costal space 7-8cm from the midline, and on the right to the fifth rib. which extends from ribs 7to11 in mid axillary line. the inferior border is along a line joining the right lower and upper left extremities (Knodell RG et al 1981).

The lobes of the liver

The liver is divided into a large right lobe and a small left lobe by the falciform ligament(fig 2-2), the proportion between them being as six to one. Posterior surfaces being marked by three fossa: the porta hepatis, the fossa for the gall-bladder and inferior vena cava (Rumack et al 2011).

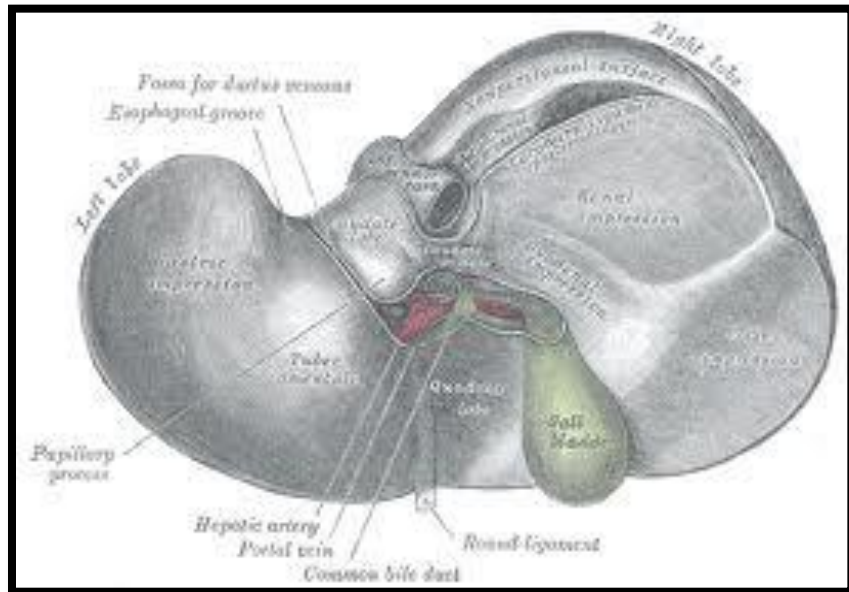
The quadrate lobe is an area of the liver situated on the under surface of the right lobe bound in front by the anterior margin of the liver; behind by the porta hepatis.on the right, by the fossa for the umbilical vein (Lamb CR et al 1991).

The caudate lobe is situated upon the posterior-superior surface of the liver on the right lobe of the liver; It is bounded on the left side by the ligamentum venosum; inferiorly by the portahepatis; on the right by the fossa for the ductus venosum.⁽²⁸⁾ since it receives portal venous and hepatic arterial blood from both the right and left systems. The caudate lobe veins drain directly into the IVC via several small veins (Ishak k et al 1995).

The caudate process is a small elevation of the hepatic substance. It is situated behind the portahepatis, and separates the fossa for the gall-bladder from the fossa for the inferior vena cava (Rumack et al 2011).

The left lobe is flattened. which situated in the epigastric and left hypochondriac regions. Its upper surface is slightly convex and it's under surface present the gastric impression and omental tuberosity (Rumack et al 2011).

The porta hepatis, is found on the posterior-inferior surface and lies between the caudate and quadrate lobes. In it lie the right and left hepatic ducts, the portal vein, the sympathetic and parasympathetic nerve fiber (Rumack et al 2011).



Figure(2-3):shows posterior-inferior surface of the liver (Ryder S et al 2001)

2-2-1Anatomical relationship

The liver is an intra peritoneal structure situated in the right upper quadrant of the abdomen and bounded superiorly by the diaphragm. The size and

shape of the liver are highly variable (<https://www.stefjir.com.>).

The posterior surface of the right lobe of the liver is indented by the right kidney, inferior vena cava and hepatic flexure of the colon but does not indent it. The inferior margin of the left lobe lies close to antrum of the stomach, adjacent to the body of the pancreas, splenic vein, and splenic artery (<https://www.stefjir.com.>).

Segmental anatomy of the liver

In traditional segmental anatomy the liver has three lobes:

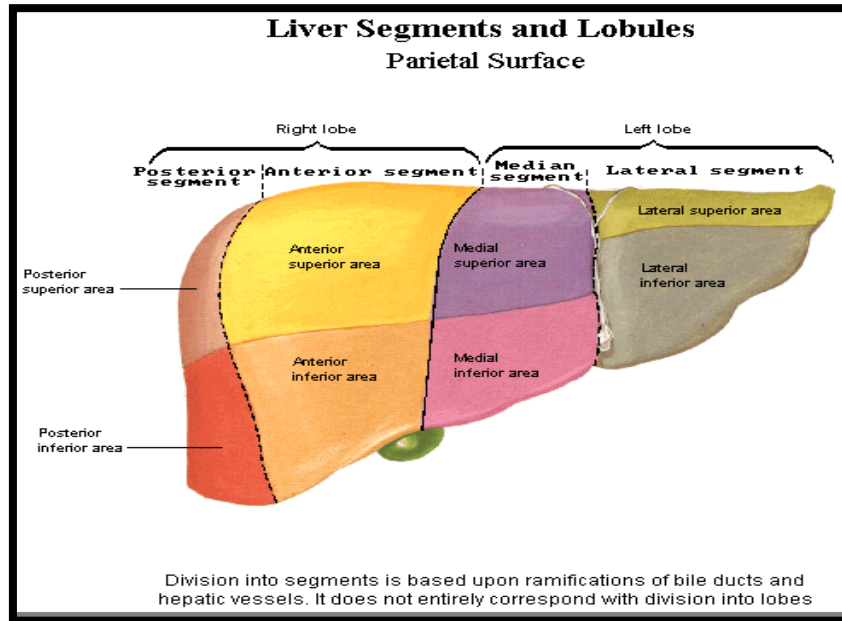
- 1- The right lobe which has anterior and posterior segments.
- 2-The left lobe which has medial and lateral segments.
- 3-The caudate lobe which is considered a separate lobe (Ishak k et al 1995).

The major divisions of the left and right portal veins course centrally within the segments (intra segmental). The major hepatic veins course between the lobes and segments(inter lobar and intersegment) (Ishak k et al 1995).

The main lobar fissure: divides the liver into its true anatomic right and left lobes. This fissure is found in a line joining the gall bladder fossa with the inferior vena cava (Ishak k et al 1995).

The right inter segmental fissure: divides the anterior and posterior segments of the right lobe. The anterior and posterior divisions of the right PV course centrally within these segments (Ishak k et al 1995).

The left inter segmental fissure: divides the left lobe into medial and lateral segments. The left hepatic vein courses within it and dividing the cephalic portions of the medial and lateral segments of the left hepatic lobe (Ishak k et al 1995).



Figure(2-4):shows eight segment of the liver(<https://www.stefjir.com.>).

2-2-2 Blood supply of the liver

2-2-2-1 Arterial supply

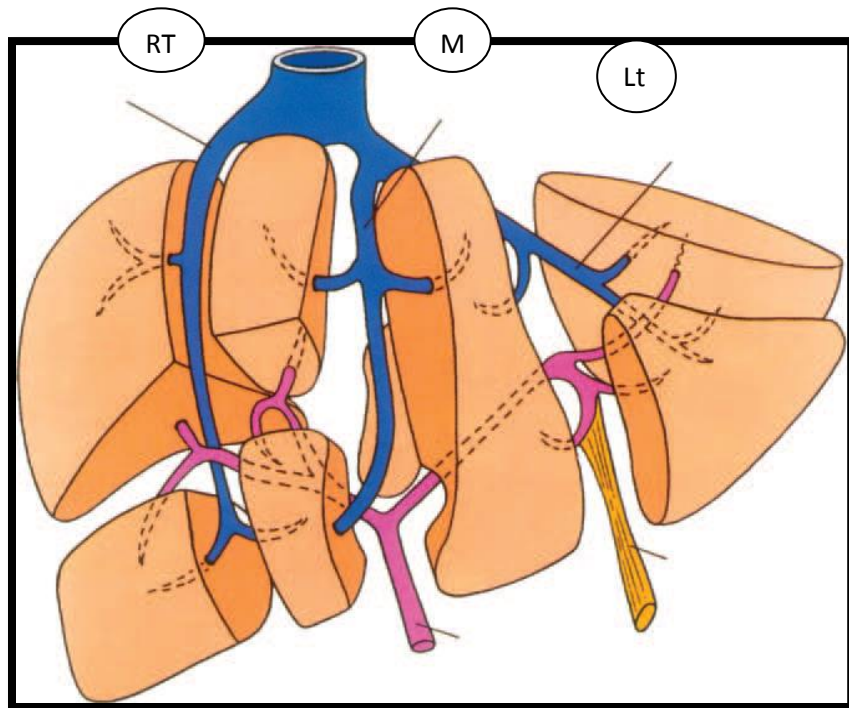
The liver receives a blood supply from hepatic artery which delivers oxygenated blood from the general circulation and hepatic portal vein delivering deoxygenated blood from the small intestine containing nutrients (M.Edosh 2006).

Common Hepatic Artery: this arises from the celiac trunk and passes anteriorly and inferior to reach the superior part of the duodenum. After giving off the gastro duodenal artery, it passes between the layers of the lesser omentum as the proper hepatic artery. Near the portal hepatis, proper hepatic artery divides into the left and right hepatic arteries (M.Edosh 2006).

The Portal Vein: this is formed posterior to the neck of the pancreas by the union of the superior mesenteric vein and the splenic vein. At the right end of the porta hepatis, the portal vein divides into left and right branches each supplying the liver ([URL:http://www.webmd.com](http://www.webmd.com)) .

2-2-2-2 Venous drainage of the liver

The hepatic veins draining the blood from the liver are right is (largest), middle and left is (smallest)veins. The hepatic veins empty into the IVC just superior-posterior liver (M.Edosh 2006).



Figure(2-5):shows three hepatic veins ([URL:http://www.webmd.com](http://www.webmd.com)).

2-2-2-1 Blood circulation through the liver

The liver has a double blood supply from the hepatic artery (20%) and the portal vein (80%). The arterial blood is conducted to the central vein of each liver lobule (M.Eldosh 2006).

2-2-3 Lymphatic drainage of the liver

The principal drainage is via:

- 1-The celiac nodes into the cistern chili.
- 2-The thorax to mediastinal trunks(M.Eldosh 2006).

2-2-4Nerve supply of the liver

The nerves of the liver derive from the hepatic nerve plexus. It's accompanies the branches of the hepatic artery and portal vein to the liver. It consists of sympathetic fibers and parasympathetic fibers (Jane Bates 2004).

2-3Physiology of the liver

The liver performs numerous functions are:

2-3-1 Production of bile

Bile makes the duodenal contents alkaline so that the pancreatic enzymes will be efficient; it also mixes with the feces and ultimately is eliminated from the body (Lamb CR et al 1991).

2-3-2Metabolic function

1- Albumin synthesis:

Albumin plays a rule in maintaining the body's fluid balance, means the total amount of body fluid is compartment in the correct amount (Ishak K et al 1995).

2- Amino acids synthesis:

The liver move amino groups around from protein to protein as different amino acids are made (<https://www.ncbi.nlm.nih.gov>).

3- Fibrinogen, prothrombin and heparin synthesis:

4- The liver manufactures the clot proteins fibrinogen and pro thrombin and also the anticoagulant heparin (heparin is also found in several other organ of the body) (<https://www.ncbi.nlm.nih.gov>).

5- Proteins metabolism:

The liver break down protein to formed ammonia, it removed from the blood and then becomes a principal part of the urea. The kidneys remove urea from the blood and excrete it as part of the urine (<https://www.ncbi.nlm.nih.gov>).

6- Fat metabolism:

The liver removes fatty acids from the blood and change them into lipoproteins which are use by the body (<https://www.ncbi.nlm.nih.gov>).

7- Carbohydrate metabolism:

Liver regulation work of pancreatic hormones (insulin and glucagon's) (<https://www.ncbi.nlm.nih.gov>).

2-3-3Storage

The liver stores glycogen, fats, amino acids, iron and several vitamins (A, D, B complex and k) (<https://www.ncbi.nlm.nih.gov>).

2-3-4Detoxification of blood

The liver detoxifies alcohol, drugs and steroid hormones, therefore prolonged abuse of alcohol and certain drugs can eventually destroy the hepatic cells.

The sex hormones are inactivated and metabolized by the liver. Once the liver is impaired, as with alcoholic cirrhosis, these hormones build up in the blood (Sex hormones will continue to be manufactured by the adrenal cortex) (M.Edosh 2006).

2-3-5 Reticulo endothelial function

The liver contains phagocytes (called Kupffer cells), it removes foreign materials and removes worn out red blood cells (L. Robbins et al 1981).

2-4 Liver Pathology

General pathology of the liver diseases

1-Viral Hepatitis.

2-Amebic Liver Abscesses.

3-Alcoholic Liver Disease.

4-Metabolic Liver Disease.

5-Hemodynamic Liver Disease.

6-Benign Liver Tumors.

7-Malignant Liver Tumors (<https://www.ncbi.nlm.nih.gov>).

Common specific pathology of diffuse liver diseases

2-4-1 Cirrhosis

Etiology includes Alcoholism, chronic Viral hepatitis and Biliary tract disease (M. Edosh 2006).

Is end-stage liver disease associated with regenerating nodules and damage of the liver parenchyma. The main effects of cirrhosis are diminished hepatic function and portal hypertension with splenomegaly, varices and ascites (L. Robbins et al 1981).

Less common causes include hemochromatosis, primary biliary cirrhosis, sclerosing cholangitis, drug-induced liver disease and chronic biliary obstruction. Other causes include α -antitrypsin deficiency, severe steatohepatitis in the morbidly obese and Wilson's disease (Ishak K et al 1995).

Cirrhosis may lead to various complications:

- 1- Esophageal varices (enlarged veins in the wall of the esophagus that can cause life-threatening bleeding).
- 2- Hepatic encephalopathy (confusion and coma).
- 3- Hepato renal syndrome (kidney dysfunction).
- 4- Acne.
- 5- Lung scarring
- 6- Abnormal menstruation ,inflammation of the thyroid gland and kidneys may be present in women with hepatitis (Ryder S et al 2001).

2-4-2Fatty infiltration (Steatosis)

Etiology: obesity ,chronic alcoholism, and less common causes diabetes, pregnancy, cystic fibrosis and glycogen storage disease (M.Edosh 2006).

Non alcoholic hepatosteato necrosis(fatty liver)is a common disorder and the diagnosis can be established by ultrasound examination of the liver or by liver biopsy showing macro vesicular fat. The treatment is that of the underlying condition, including weight loss and therapy of diabetes and hyper lipidemia. Most cases of fatty liver are not associated with inflammation and hepato cellular necrosis (Ryder S et al 2001).

10-20%has non alcoholic steatohepatitis and has the potential to progress on the fibrosis and cirrhosis. Non alcoholic fatty liver disease(NAFLD) is increasingly recognized as a public health problem in the medical community (<https://www.ncbi.nlm.nih.gov>).

The number of patients at risk of advanced liver disease through nonalcoholic steatohepatitis(NASH)and cryptogenic cirrhosis is increasing because of the epidemics of obesity and diabetes related to western life style, associated with fatty liver (<https://www.ncbi.nlm.nih.gov>).

The pathogenesis of (NAFLD) is probably multi factorial, but insulin resistance, either genetically determined or obesity related, is a corner stone. A lot of experimental and clinical data point to NAFLD as the hepatic expression of the metabolic syndrome(MS) (<https://www.ncbi.nlm.nih.gov>).

General risk factors of diffuse fatty liver disease are genetics and environment, but the disease greatly increase with weight gain and obesity.

Fatty liver disease normally affects people over the age of 40, but childhood obesity can lead to development in young adults. Additionally, the disease is more prevalent in women than in men (Ishak K et al 1995).

The accumulation of fat within the hepatic cells may alters liver metabolism. As the level of fat deposition increases, the level of echogenicity may highly reflective portal tract walls (Ryder S et al 2001).

* The stages of fatty infiltration liver are described below:

-Stage 1: Mild

Minimal diffuse increase in hepatic echogenicity with normal visualization of diaphragm and intra-hepatic vessel borders (<https://www.ncbi.nlm.nih.gov>).

-Stage 2: Moderate

Moderate diffuse increase in hepatic echogenicity with slightly impaired visualization of intra-hepatic vessels and diaphragm (<https://www.ncbi.nlm.nih.gov>)

-Stage 3: Sever

Marked increase in echogenicity with poor penetration of posterior segment of right lobe of liver and poor or no visualization of hepatic vessels and diaphragm (<https://www.ncbi.nlm.nih.gov>).

2-4-3 Lymphoma of the liver

Is less common diffuse involvement of the liver is an overall decrease in echogenicity may be seen (M.Edosh 2006).

Abdominal ultrasound is a routine part of staging a new lymphoma patient. The liver is often involved, as well as intra-abdominal lymph nodes There are usually multiple abnormal abdominal lymph nodes. Commonly seen lymph nodes like the cranial mesenteric and the medial iliac lymph nodes are easy to identify. Other chains of lymph nodes that are usually too small to see with ultrasound may become involved as well. It's helpful to know the locations of some of these other groups like the per aortic and the splenic lymph nodes to be able to identify them. The lymph node enlargement can be very variable, with extremely enlarged nodes in one location, and mildly enlarged nodes in another. They tend to be hypo echoic and rounded (Ryder S et al 2001).

Lymphoma can cause a renal mass, or the GI tract might be involved. It's important to do a thorough examination to inform the clinician of any lesions that are out of the ordinary. Fine needle aspirate is an easy technique to confirm the diagnosis of lymphoma in these organs (Ryder S et al 2001).

2-4-4 Viral hepatitis

Hepatitis is inflammation of the liver caused by any of several viruses. The most common of these hepatitis viruses have been designated A, B, and C, although there are others. Severity of disease ranges from very mild (even asymptomatic) to fatal, and liver inflammation is common to all of them, the three hepatitis viruses have different modes of transmission and different consequences for affected people(<https://www.stefjir.com>).

Hepatitis A is an intestinal virus that is spread by the fecal–oral route. Food contaminated by the hands of people with mild cases is the usual vehicle of transmission, although shellfish harvested from water contaminated with human sewage are another possible source of this virus.

Hepatitis A is most often mild, recovery provides lifelong immunity, and the carrier state is not known to occur. A vaccine is available, but people who have been exposed to hepatitis A may receive gamma globulin by injection to prevent the disease (<https://www.stefjir.com>).

Hepatitis B is contracted by exposure to the body fluids of an infected person; these fluids include blood and semen. Hepatitis B may be severe or even fatal, and approximately 10% of those who recover become carriers of the virus. Possible consequences of the carrier state are chronic hepatitis progressing to cirrhosis or primary liver cancer. Of equal importance, carriers are sources of the virus for others, especially their sexual partners.

A vaccine is available for hepatitis B, and health care workers who have contact with blood, even just occasional contact, should receive it. Other potential recipients of the vaccine are the sexual partners of carriers.

Pediatricians now consider this vaccine one of the standard ones for infants (<https://www.stefjir.com>).

Hepatitis C virus is also present in body fluids and is spread by blood or mucous membrane contact. Most people develop chronic disease, but many may remain asymptomatic for years after being infected. With active disease the virus may cause liver failure. The only therapy then is a liver transplant. It is important for healthcare personnel, and their patients, to know that these types of hepatitis are not spread by blood transfusions (<https://www.stefjir.com>).

2-4-4-1 Acute viral hepatitis

Etiology: acute hepatitis Is caused by viral infection. Hepatitis A, hepatitis B, hepatitis C are the commonest cause of viral hepatitis (M.Edosh 2006).

2-4-4-2 Chronic hepatitis

The term Chronic hepatitis means active, ongoing inflammation of the liver persisting for more than six months that is detectable by biochemical and histologic means. It does not imply an etiology.⁽³³⁾ When the inflammation is severe and /or prolonged, hepatic dysfunction. Typically, biochemical tests are used to identify and follow patients with chronic hepatitis, while liver biopsies serve to more precisely define the nature of the chronic hepatitis and provide useful information regarding the extent of damage and prognosis. Histologically, chronic hepatitis is characterized by infiltration of portal tracts by inflammatory cells (M.Edosh 2006). These cells are predominantly mononuclear cells including lymphocytes, monocytes and plasma cells. Chronic hepatitis is designated as mild when

the infiltrate is confined to the portal triad. It is designated as moderately severe chronic hepatitis when the infiltrate extends into the parenchyma and when it extends to adjacent portal triads. The inflammatory process can also extend from the portal tract to the central vein. Severe chronic hepatitis is associated with multilobular or confluent necrosis and is much more likely to progress to cirrhosis (M.Edosh 2006).

Table(2-1): Modified hepatic activity index
 ([URL:http://www.webmd.com](http://www.webmd.com)).

Per portal hepatitis(A)	Score	Confluent necrosis(B)	Score
Absent	0	Absent	0
Mild	1	Necrosis in some areas	1
Moderate (<50%)	3	necrosis in most areas	3
Severe (>50%)	4	necrosis + portal central bridging	4
-----	-----	necrosis + multiple bridging	5
Multacinar necrosis	6	-----	-----
Focal necrosis, and inflammation(C)	Score	Portal inflammation(D)	Score

Absent	0	None	0
One focus	1	Mild, some or all portal areas	1
Two to four foci	2	Moderate, some or all portal areas	2
Five to ten foci	3	Moderate/marked, all portal areas	3
More than ten foci	4	Marked, all portal areas	4
Total Modified HAI = __/18			

2-5 Clinical features of:

2-5-1-Cirrhosis

Clinical presentation depends upon the a etiology, and may involve either chronic symptoms or an acute episode.

1-Pruritus.

2- fatigue.

3- jaundice, with steatorrhoea (M.Edosh 2006).

2-5-2 Fatty infiltration

Most patients with fatty liver are asymptomatic. However, more than 50% of patients with fatty liver reported.

1- fatigue.

2- Malaise or upper abdominal discomfort ([URL:http://www.webmd.com](http://www.webmd.com)).

2-5 3 Lymphoma

Symptoms caused by lymphoma may also occur also with other conditions include:

- 1-Fatigue.
- 2-Fever and chills that come and go.
- 3-Itching all over the body that cannot be explained .
- 4-Loss of appetite.
- 5-Soaking night sweats.
- 6-Weight loss that cannot be explained (Ryder S et al 2001).

2-5-4 Viral hepatitis

2-5-4-1Acute hepatitis

Initial features are of nonspecific symptoms, and its less than six months. common to almost may include:

- 1-malaise.
- 2-muscle and joint aches.
- 3-fever.
- 4-nausea or vomiting.
- 5-diarrhea.
- 6-headache (M.Edosh 2006) .

2-5-4-2Chronic hepatitis

Chronic hepatitis often leads to nonspecific symptoms such as:

- 1-Malaise.
- 2-Tiredness.
- 3-Weakness.

It is commonly identified on blood tests performed either for screening or to evaluate nonspecific symptoms (M.Edosh 2006) .

2-6 Laboratory diagnosis

2-6-1 Cirrhosis

-Raised:

- 1- Alkaline Phosphatase.
- 2- Serum Bilirubin.
- 3-Alanine Aminotransferase[ALT].
- 4- Aspartate Amino transferase[AST].
- 5-Increase Pro thrombin Time.
- 6-Decrease Serum Albumin Level (M.Edosh 2006) .

2-6-2 Fatty infiltration

Liver Function Test Are Usually Normal (M.Edosh 2006) .

2-6-3 Lymphoma

Raised:

- 1-Serum levels of Alkaline Phosphatase.
- 3- Lactate De hydrogenase.

2-6-4 Viral hepatitis

2-6-4-1 Acute hepatitis

Marked Increase:

- 1-Alanine Aminotransferase[ALT].
- 2- Aspartate Aminotransferase[AST].

-Indicated Hepatic Necrosis Of Acute Nature (M.Edosh 2006) .

2-6-4-2 Chronic hepatitis

Moderate to high level of:

- 1-Alanine Aminotransferase[ALT].

2- Aspartate Aminotransferase[AST] (M.Edosh 2006).

2-7Anatomy of the Gallbladder

The gallbladder is a globular or pear– shaped viscous, about 8– 12cm in length with a capacity of about 30– 50ml and consists of three parts; fundus, body and neck. It lies in the gallbladder fossa on the visceral surface of the right lobe of the liver, adjacent to the quadrate lobe (Fig: 2-3) (Rose De Bruin 2005).

The fundus (*below blind end*) usually projects a little beyond the sharp lower border at the liver and touches the parietal peritoneum of the anterior abdominal wall at the tip of the ninth costal cartilage, where the Tran pyloric plane and cross the right costal margin at the lateral border of the right rectus sheath, this is the surface marking of the fundus and the area of abdominal tenderness in the gallbladder disease. The fundus of the normal gallbladder is not palpable but may become so if distended by biliray tract obstruction (Devin Dean 2005) .The fundus lies on the commencement of the transverse colon, just to the left of the republic flexure (Knodell RG et al 1981).

The body passes backward and upward towards the right end of the porta hepatis and is in contact with the first part of the duodenum. The upper end of the body narrows into the neck(M.Edosh 2006).

The neck when the liver is in its normal position (not retracted upwards), lies at higher level than the fundus, the neck continues into the cystic duct. The wall of the neck where it joins the cystic duct may show a small diverticulum (*Hartmann's pouch*); this is not feature of normal (M.Edosh 2006).

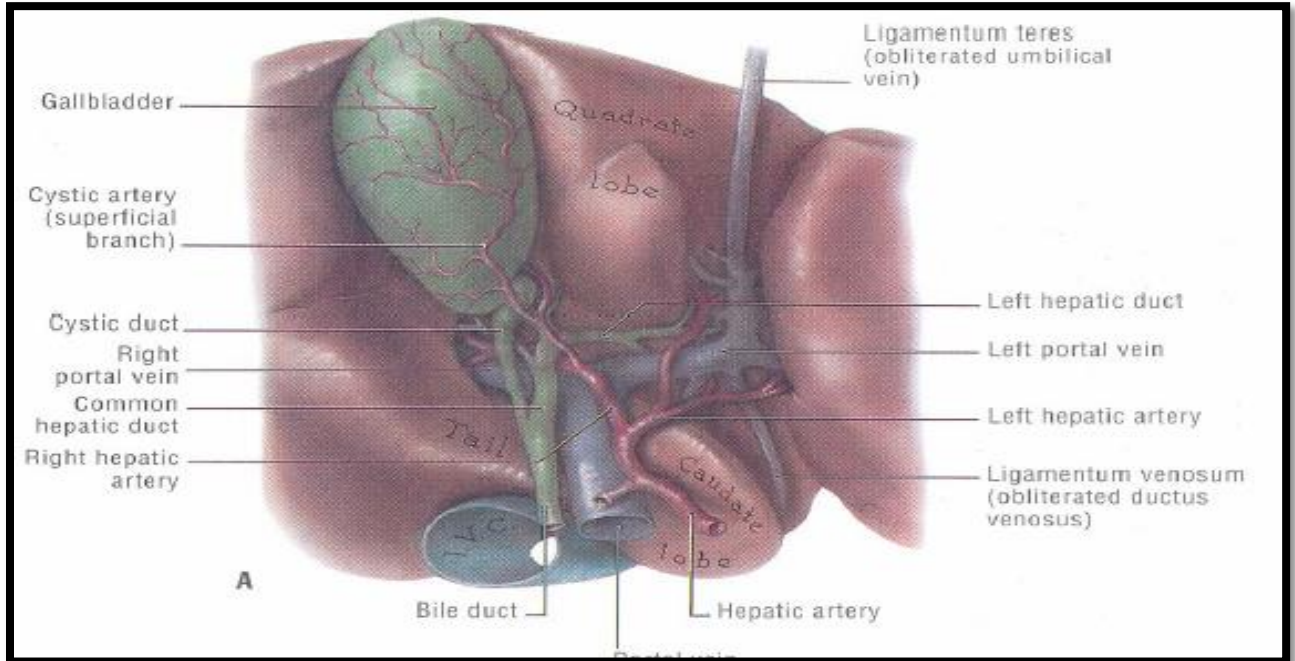


Fig: (2-6). The gallbladder (Rose De Bruin 2005).

2-7-1 Blood supply

The gallbladder is supplied by the cystic artery; the cystic artery is usually a branch of the right hepatic. It runs across a triangle formed by the liver, common hepatic duct, cystic duct (*Calot's triangle*) to reach the gallbladder (Ishak K et al 1995).

2-7-2 Venous drainage

The cystic veins join the right branch of the portal vein. The veins of the fundus and body of the gallbladder pass directly into the liver (Lamb CR et al 1991).

2-7-3 Lymph drainage

Lymphatic channels from the gallbladder drain to node in the porta hepatis to the cystic node (*in Calot's triangle at the junction of the common cystic duct*), and to node situated at the anterior boundary of the epiploic foramen, from there lymph pass to the celiac group of pancreatic nodes (Rose De Bruin 2005).

2-7-4 Development

The gallbladder develops from the hepatic bud as a solid outgrowth of cells. The end of the outgrowth expands to form the gallbladder, while the narrow stem remains as the cystic duct. Later, the gallbladder and cystic duct become canalized. The cystic duct now opens into common hepatic duct to form the bile duct (Rumack et al 2011).

2-8 Physiology of the gallbladder

The relatively watery bile from the liver is stored in the gallbladder, concentrated by the absorption of water and electrolytes, rendered more alkaline by the secretion of bicarbonate (Rose De Bruin 2005).

The discharge of gallbladder bile with stimulated by the entry of food into the duodenum, particularly fatty foods. This involves concentration of the gallbladder accompanied by relaxation of the sphincter of Oddi, a response mediated by cholecystokinin. Initially the gallbladder discharges only a proportion of its contents, and thereafter small quantities are passed at intervals – the presence of clay colored, bulky, offensive smelling stools (Jane Bates 2004).

2-9Pathology

2-9-1 Benign Polypoid lesions

They are present in 4– 6% of the population. An estimated 90% are benign cholesterol polyps, less than 10mm in size and are incidental findings. The remaining 10% are adenomatous polyps that have malignant potential. Most polyps are spherical (attached by a pedicle to tile gallbladder wall). Less common are the broad based (sessile) polyps. Sonographically a polyp appears as a hyper echoic nodule (more echogenic than the surrounding bile) attached to the gallbladder wall the polyp is nonmobile and remains in a fixed position regardless of changes in patient position. The polyp is no shadowing (M.Edosh 2006).

Benign tumors of the gallbladder are uncommon. Adenomas are asymptomatic, being detected on ultrasound or found incidentally at surgery.

Small masses in the wall of the gallbladder, however, are relatively common findings on ultrasound; when multiple they usually represent cholesterol polyps or adherent gallstones. Polypoidal masses warrant a repeat ultrasound in six months. If these are larger than 1cm, surgery is necessary (Rumack et al 2011).

2-3 Previous studies :-

1- Chou et al describes the ultrasound appearances of the liver with hepatic schistosomiasis japonica, and studies the portal hemodynamics in 47 patients with hepatic schistosomiasis japonica using duplex Doppler ultrasound in 2003. All patients but two were Chinese war veterans seen in Taiwan about 35–55 years after their presumed infection in Mainland China. The ultrasound presentations were reviewed. The data from Doppler portal flow studies were available for 39 patients with hepatic schistosomiasis japonica, and compared to data from Doppler portal flow studies in 40 normal healthy volunteers and to this data in 40 patients with postnecrotic cirrhosis. A typical “coarse reticular pattern” due to fibrosis in the whole liver was noted in 40 patients (85%). Other findings included periportal fibrosis (15%), septum-like fibrous bands extending to the liver capsule (32%), and an apparent nodular liver surface (19%). Splenomegaly was noted in seven patients. While coexisting hepatocellular carcinomas were evident in three patients, and esophageal varices were found in three others, yet both conditions were found only in patients with positive hepatitis-B-surface antigen. Doppler flowmetry of the portal veins in hepatic schistosomiasis japonica patients showed a mean flow rate of 15.34 ± 6.82 cm/sec, and a mean flow volume of 993.21 ± 290.63 ml/min, both showed no significant difference from those in normal adults ($p > 0.5$). hepatic schistosomiasis japonica can be confidently diagnosed in patients with hepatic fibrosis when the hepatic pathology is presented as a coarse reticular pattern. The portal hemodynamics in hepatic schistosomiasis japonica patients who have been isolated from the infection site (for more than 35 years) are significantly

different from portal hemodynamics in cirrhotic patients and are similar to those in healthy volunteers (Goal et al 2002).

2- Luciana et al in 1984 used magnetic resonance analysis of liver fibrosis according to WHO patterns for ultrasound assessment of schistosomiasis-related morbidity ultrasound was performed using a real-time device (ALOKA SSD 1700, ALOKA CO, Japan) with an electronic convex 3.5 MHz transducer, the study was done in 60 patients results are ultrasound and magnetic resonance imaging identified periportal thickening in 54 (90%) and 47 (78.3%) cases, respectively by ultrasound . magnetic resonance imaging fibrosis was characterised by hypointense periportal bands on T1-weighted images, which were hyperintense on T2-weighted images in addition to portal hypertension and liver and spleen enlargement . results indicate that new patterns should be constructed to better reflect magnetic resonance imaging findings (<http://www.findarticular.com>).

3- Richter et al about Report of the Second Satellite Symposium on Ultrasound in Schistosomiasis in 2001 to discussed the experiences and results obtained with the Niamey-Belo Horizonte Protocol on Ultrasonography Schistosomiasis using ultrasound as the first tool of choice for assessing liver and spleen changes induced by *Schistosoma* the results are periportal thickening, liver and spleen enlargement , portal hypertension and gall bladder wall thickening. Conclusion preliminary data obtained with the Niamey-Belo Horizonte protocol since 1997 do not yet permit to formulate definite recommendations. The protocol needs to be tested further in different endemic areas and by different research groups (<http://www.pubmedcentral.nih.gov>).

4- Parasitárias et al in 2006 used hepatosplenic schistosomiasis after mass chemotherapy with oxamniquine. To report the effect of treatment in patients with advanced schistosomiasis mansoni living in area of Brazil highly endemic for this disease. A total of 739 inhabitants of a village were subjected to clinical and abdominal ultrasound examinations and were treated with oxamniquine. We have identified 84 individuals with hepatosplenic schistosomiasis. Alcohol abuse was associated with periportal thickening. Four years after treatment, 42 of the 84 individuals were re-examined and regression of splenomegaly was observed in 59% and of periportal thickening in 32%. Our data indicate that mass chemotherapy can lead to reduction of schistosomiasis morbidity but a significant group of patients (68%) will not improve. The association with alcohol abuse should be further evaluated. Thickening of the gallbladder wall can be a useful predictor of no involution of liver fibrosis after treatment (<http://www.nhm.ac.uk/hostel-sites/schisto/heidel>.)

5- Gasim et al in 2015 used Schistosomiasis, hepatitis B and hepatitis C co-infection to evaluation previous researches using A systematic search performed on published data from 1980–2014. Published papers in the databases Google, Medline, PubMed, and MiPc library were searched using the keywords epidemiology, pathogenesis and outcomes of hepatitis B, hepatitis C and schistosomiasis and data were extracted from the relevant studies the results was The prevalence of hepatitis B /schistosomiasis co-infection in countries where schistosomiasis is endemic was high, ranging between 9.6 to approximately 64% in Egypt, and a maximum of 15.8% among hospitalized patients in Brazil. Concurrent infection between hepatitis B and schistosomiasis is often associated with countries where schistosomiasis is endemic and may lead to chronic liver inflammation.

Similarly, hepatitis C infection rates in schistosomiasis populations range from 1% in Ethiopia reaching up to 50% in Egypt. conclusion there is controversy regarding the effects of hepatitis B and hepatitis C on schistosomiasis and vice versa. Vaccination might be a solution to the era of schistosomiasis and co-infection with hepatitis B and hepatitis C (<http://www.pubmedcentral.nih.gov>) .

6- R. Kardorff et al One thousand six hundred and ninety-five inhabitants of 3 rural villages on Ukerewe Island, Lake Victoria, Tanzania, were examined by clinical, parasitological, ultrasonographic and—in part—serological means to evaluate *Schistosoma (S.) mansoni*-related morbidity on a community level. Villagers frequently complained of typical colitis symptoms (abdominal pain 80.1%, bloody stools 43.1%, diarrhoea 35.1%); haematemesis, on the other hand, was rare (and reports doubtful in most cases). 16.9% of the population had been given praziquantel previously. Overall *S. mansoni* prevalence was 86.3%, with a median egg output of 176 eggs per gram and a maximum output of 17 984 eggs per gram Children and adolescents were infected more severely than adults, men more severely than women. Pretreated individuals excreted significantly fewer ova (median 124 vs 192 eggs per gram, $P < 0.001$). Hepatomegaly (determined by ultrasonography) was present in 35%, splenomegaly in 80%. Organomegaly was significantly related to egg output. Pretreated persons had lower rates of splenomegaly and left lobe hepatomegaly. Low-degree periportal fibrosis was common, while severe grades of fibrosis (MANAGIL score II and III) were present in about 6%. About 10% had other abnormalities on liver sonography (irregular parenchymal texture and/or shape); these persons passed significantly more *S. mansoni* ova than others. Clear sonographic signs of portal hypertension were seen in 2.1%. Serum procollagen-IV-

peptide and α -glutamyl-transferase levels were increased in persons with severe periportal fibrosis, irregular liver texture or portofugal collateral vessels. Thus, *S. mansoni* infection in the western part of Ukerewe Island is frequent and often severe, leading to a high prevalence of gastrointestinal symptoms (<http://www.findarticular.com>).

7- Vennervald et al in 2004 study Hepatosplenic schistosomiasis involving organomegaly, portal fibrosis and portal hypertension has been observed in autopsy studies. Here, we have tested the hypothesis that hepatosplenic disease including organomegaly and markers of increased portal pressure can occur in school aged children in the absence of fibrosis. A case-only study of 96 children aged 7–20 years defined by ultrasound detectable hepatomegaly was undertaken in Makueni district, Kenya. A novel method of clinical examination that involved a consensus scoring by three or four examiners was used to classify children as presenting with severe or moderate hepatosplenic disease after palpation of livers and spleens. Ultrasound examination of livers and spleens was based on the Niamey protocol. Clinical measurements included spleen enlargement along the mid-clavicular and mid-axillary lines, liver enlargement along the mid-sternal (MSL) and mid-clavicular lines, as well as organ consistency. The clinical examination indicated that 9% and 60% of the children had severe or moderate hepatosplenomegaly, respectively. Amongst eggpositive children, all clinical measurements, except MSL liver enlargement, correlated with egg count, as did portal vein diameter, spleen length and liver length measured by ultrasound. Peri-portal fibrosis was not observed in any child, whereas 28% of the children were classified as having increased portal pressure according to World Health Organization criteria. There was no

effect of malaria parasitaemia or hepatitis seropositivity on any of the observed parameters. These results indicate that hepatosplenic disease in school-aged children attributable to *S. mansoni* infection, involving hepatosplenomegaly and increased portal vein diameter, can occur in the absence of peri-portal fibrosis (<http://www.nhm.ac.uk/hostel-sites/schisto/heidel>).

8- M. Badawi et al in 2000 study sonographic tissue signature of bright liver to establish a specific quantitative criteria for computerized discrimination of different diffuse liver diseases detected as bright liver by ultrasound. Using 10 tissue characterization parameters namely; mean gray level, 9th percentile, contrast, entropy, attenuation, correlation, angular second moment, average specular intensity, average diffuse intensity and speckle separation distance was able to differentiate between different hepatic pathologies among 45 patients with sonographically detected bright liver and 12 control subjects. A neural network model is proposed to classify different diseases from detecting these quantitative parameters from the ultrasound images. a results of classification of bright livers over 90% sensitivity, specificity, and overall efficiency. concluded that, Computer-assisted sonographic tissue characterization using the neural network classifier is a sensitive and specific technique for separating diffuse liver disease with ultrasonically detected bright liver from control cases (<http://www.findarticular.com>).

9-J. Richter et al study ultrasound in schistosomiasis to review the status of knowledge about morbidity resulting from schistosomal infection in different endemic areas, especially the pathological changes observed using ultrasound, and the way these change over time and in response to chemotherapy using Linear, convex or sector transducers may be used to

assess pathology of the liver, spleen and abdominal vessels. In about 45 cases the result were Liver fibrosis as revealed by ultrasonography generally regresses, though in certain subjects the pathological changes seem to be insensitive to treatment. The time required for regression depends on the severity of the initial involvement, the intensity of reinfection, the age of the subject and possibly on genetic factors. Improvement in pathology is always slow, and can only be seen after several months or even years. Regression is more marked in children, and in patients who initially showed only a slight fibrosis . Ultrasound examination has been successfully used to show that in *S. haematobium* infection, pathological changes resolve rapidly after chemotherapy and do not reappear for a period of at least one year. In *S. mansoni* infection, the regression of periportal fibrosis was found to be slow, but it did occur, especially in young subjects and those with only a moderate level of initial infection (<http://www.pubmedcentral.nih.gov>).

10- Homeda et al in 1988 study periportal fibrosis to assessment periportal fibrosis the cases 44 patients were 11 males and 34 females, their ages ranged from 27 to 65 years.the result all patient have periportal fibrosis and conclusion is ultrasound is more reliable tools to diagnosis periportal fibrosis (Homeida et al 2002).

Chapter Three

Methodology

3-1 Study Population sampling and study area

The study population of 53 patients exposed to bilharzias disease for evaluation with ultrasound was randomly selected from a group of patients, at Elmanagel hospital.

3-2 Study design and duration

This is nonintervention descriptive study, was carried out over a period of February 2014 to February 2017.

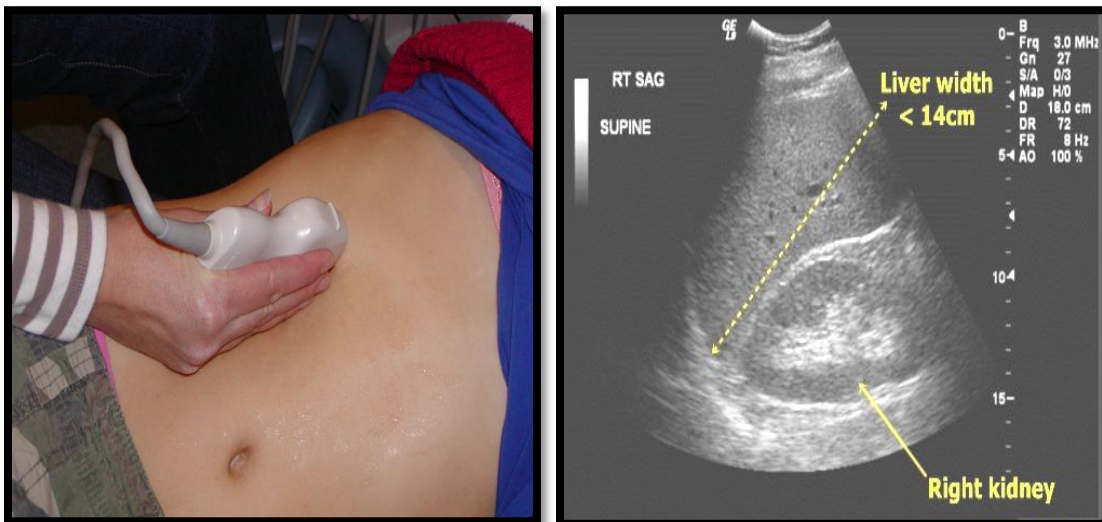
3-3 Technique

In this study the patients after taking an informed consent, patient with bilharzias disease were approached to participate in the study; initially scanned by routine sonographic evaluation, following the scanning protocol established by Jurie-Philadelphia-USA and Burwin Institute of ultrasound (Lunenburg, Canada) and the findings of scan was recorded.

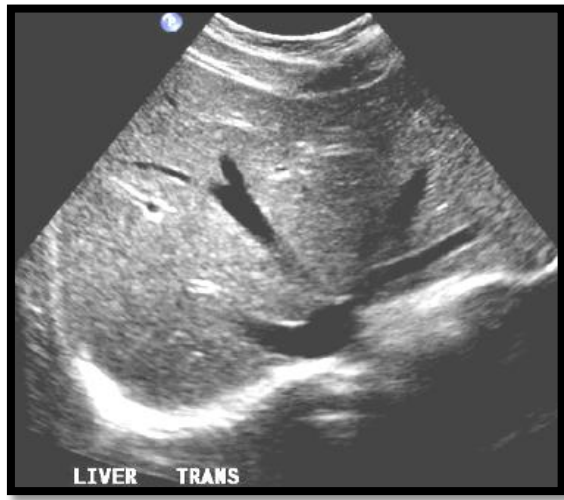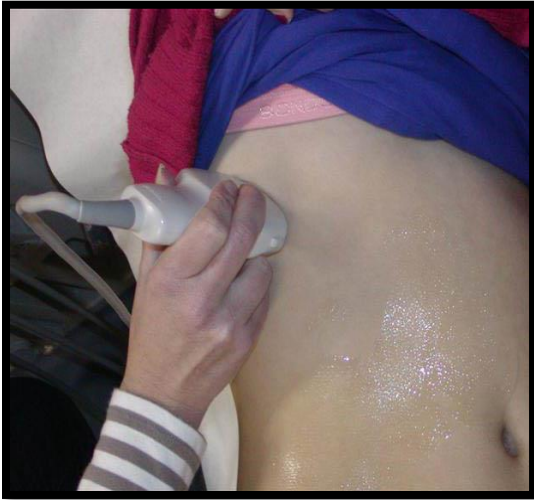Scanning was done in room with dim light, to minimize the reflected artifact of the screen, the cases were examined in supine position then applying a sonic coupling agent to the abdomen, and begin the evaluation with a simple sweep of the transducer up and down to the abdomen and side-to-side across the abdomen to get a rough sense of the abdominal organs before focusing on specific areas of interest (Gilani 2002).

After getting the rough sense that the observations were made and the findings:

1. Size of the liver.
2. Echogenicity and echo-texture.
3. Liver outline were smooth or not.
4. Portal vein diameter.
5. After evaluation the liver, the positive findings were listed.

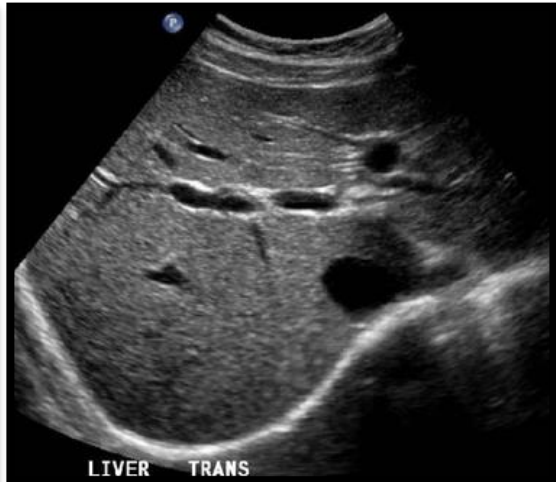
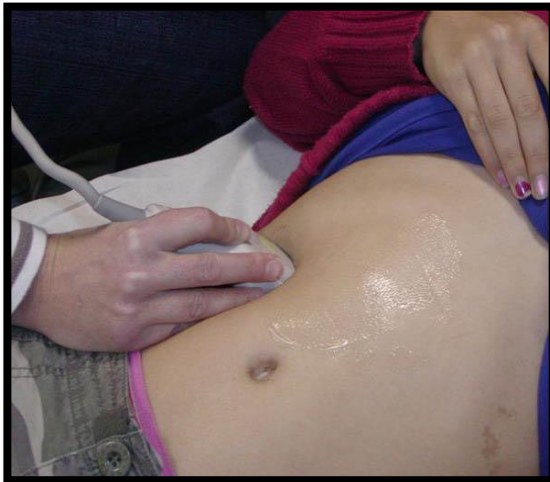
Figure(3-1): Rt medioclavicular line liver width is measured (<https://www.stefjir.com>).



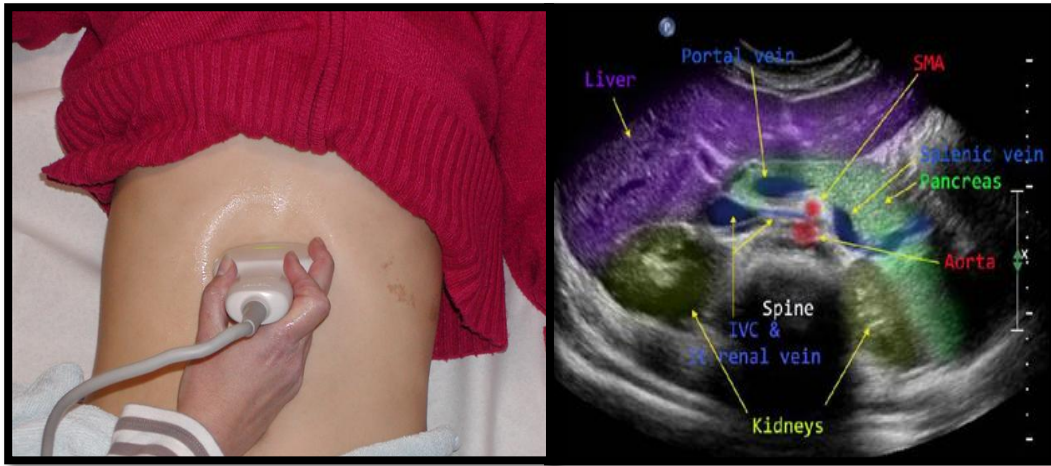
Figure(3-2): Intercostal scan plane
(<https://www.stefjir.com>).

M and RT hepatic vein



Figure(3-3):Sub-costal scan
(<https://www.stefjir.com>)

portal vein coursing transversely



Figure(3-4): The probe angled to the Lt transverse Lt lobe
<https://www.stefjir.com>

3-4 Inclusion criteria of the study cases

- a. Pre portal fibrosis .
- b. Hepatomegaly .
- c. Portal hypertension .
- d. Cirrhosis.
- e. Splenomegaly.

3-5 Exclusion criteria

- a. Hydatid liver disease.
- b. Benign hepatic cysts.
- C. Hepatic adenomas.
- d. Hepatocellular carcinoma.

3-6 Data collection instrument

Different real time system with an ultrasound machine of the following facilities: -

1- Aloka SSd-500.(3.5 MHz-5MHz convextransducer,TA scan).

2-My lab 70 (3.5MHz -5 MHz convextransducer,TA scan).

3-7 Data processing and analysis

Information derived from data were collected from a comprehensive data base of sonographic examination designed for the purpose of the study including gender, age, marital status, echo texture addition to routine sonographic evaluation, and findings were recorded.

For texture analysis after that ultrasound image were stored in computer disk were uploaded into the computer based software; Interactive Data Language (IDL) where the DICOM image were read by IDL where the author clicks on several images that represents liver cirrhosis as grade 0, grade 1, grade 2 and grade 3. In these areas a window of 3×3 pixel were set and the first order statistics were calculated, which include mean, variance, skewness, kurtosis, energy and entropy. The data concerning the liver cirrhosis as grade 0, grade 1, grade 2 and grade 3 were processed by SPSS software with its classes to generate a classification score using stepwise linear discriminant analysis; to select the most discriminant features that can be used in the classification (grading) of liver cirrhosis in one of its four grades. Where scatter plot using discriminant function were generated as well as classification accuracy and linear discriminant function equations to grade unseen images for its grade objectively.

3-8Limitation of this study

Limitation in this study that not all factors can influence on the bilharzias disease were evaluated.

1. Environmental influences .
2. Physiologic factors.
3. Anemia.
4. Social cause.

3-9Ethics issue

The study received ethical clearance from the research board at the Faculty of medicine.

The ultrasound scanning of the study cases forms part of their routine medical management. No part of this study relies on data which normally be collected from routine scanning. All study cases are informed, both by the candidate and by their referring physician, then result of examination will form part of research project. No identification or individual detail will be published, all specific information relating to the client identities will be protected in the same way, to the same level as other medical data collected as a routine part of study case management specifically, clients were informed about the procedure and aim of studies along with the role of this study promoting international best medical practice for Sudan.

Chapter Four

Results

Table(4-1) :Frequency distribution of patients according to gender

Gender	Frequency
Male	31
Female	22
Total	53

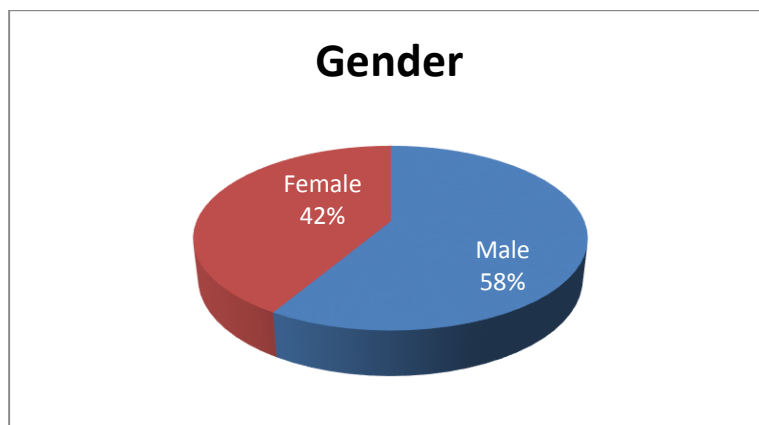


Fig.(4-1): Pie graph of percentage distribution of patients according to gender

Table(4-2) :Frequency distribution of patients according to marital status

marital status	Frequency
Married	45
Single	8
Total	53

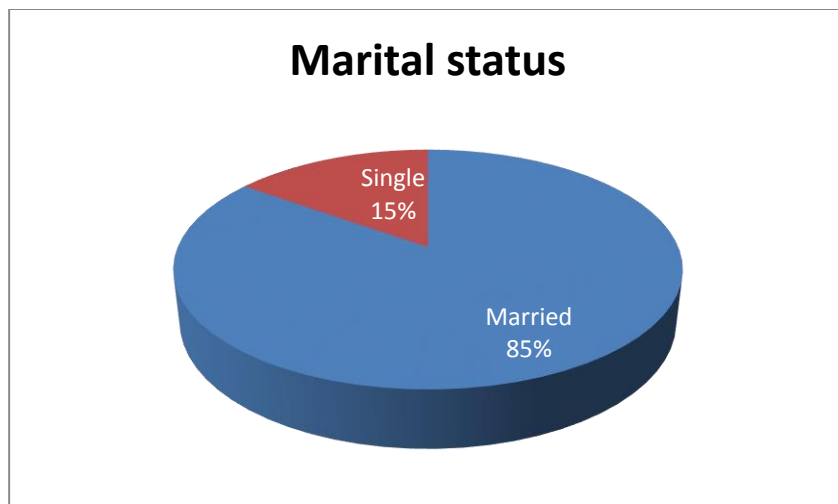


Fig.(4-2): Pie graph of percentage frequency distribution of patients according to marital status

Table(4-3) :Frequency distribution of patients according to occupation

Occupation	Frequency
Farmer	21
House wife	21
Labor	11
Total	53

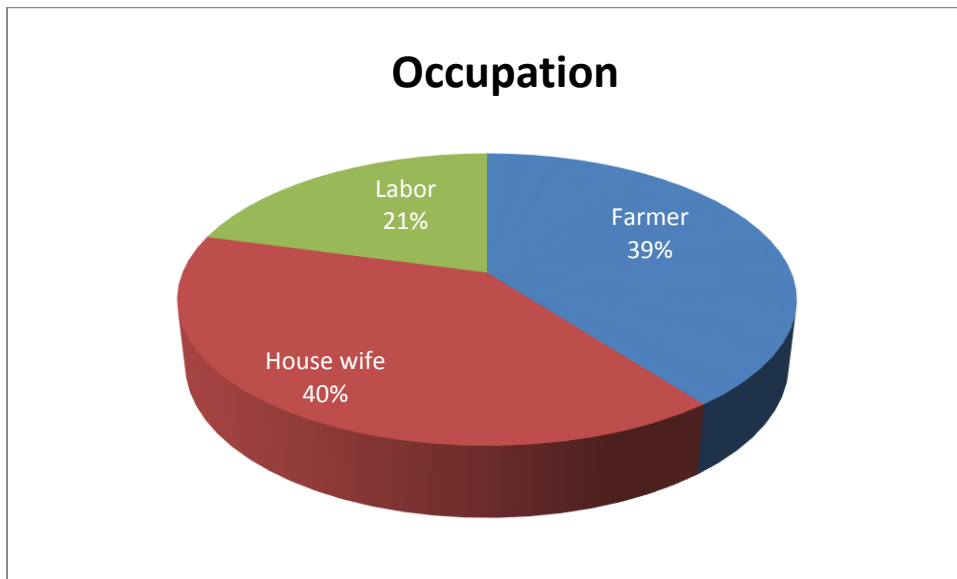


Fig.(4-3): Pie graph of frequency distribution of patients according to occupation

Table(4-4) :Frequency distribution of patients according to liver texture

Texture	Frequency
Homogenous	26
Heterogeneous	27
Total	53

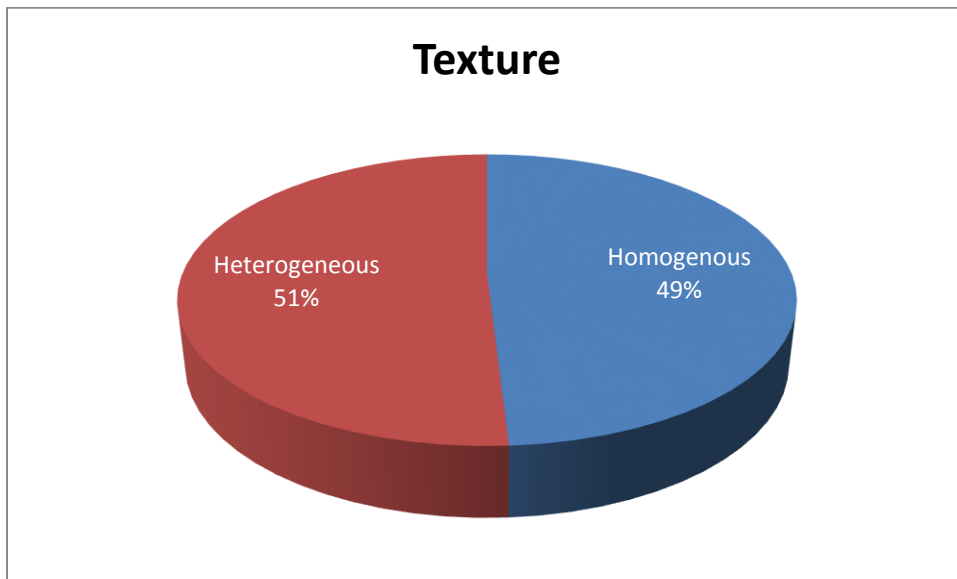


Fig.(4-4): Pie graph of frequency distribution of patients according to liver texture

Table(4-5) :Frequency distribution of patients according to liver echogenicity

Echogenicity	Frequency
Normal	21
Hypoechoic	18
Hyperechoic	13
Nodular	1
Total	53

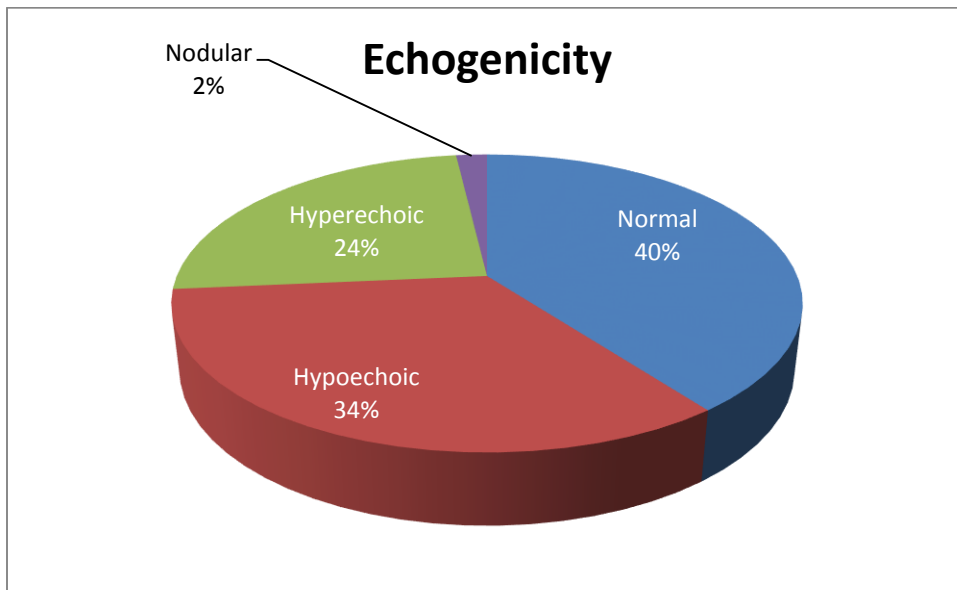


Fig.(4-5): pie graph of frequency distribution for patients according to liver echogenicity

Table(4-6) :Frequency distribution of patients according to cirrhosis grade of liver

cirrhosis grade	Frequency
0	35
1	11
2	7
Total	53

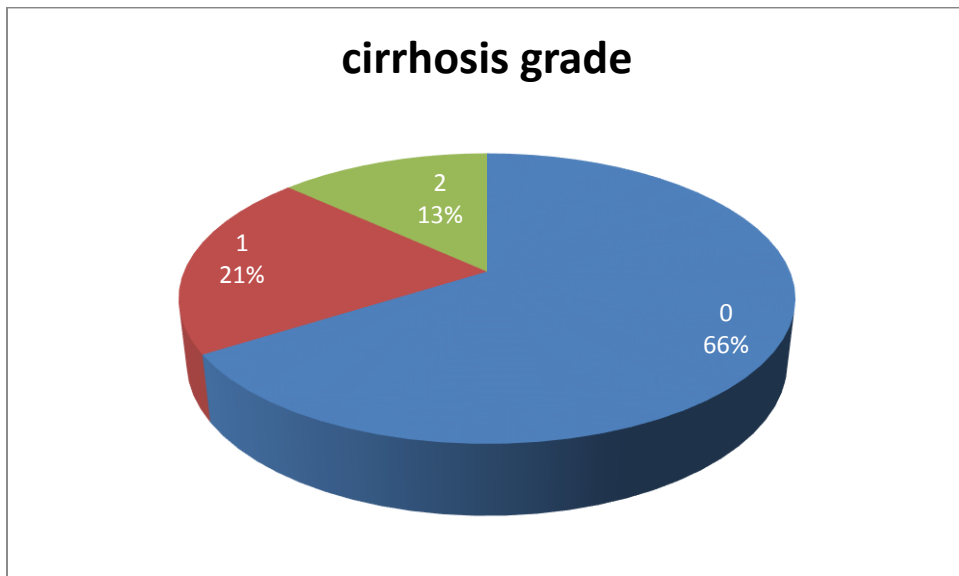


Fig.(4-6): Pie graph of frequency distribution for patients according to cirrhosis grade of liver

Table(4-7) :Frequency distribution of patients according to spleen size

spleen	Frequency
Normal	18
Enlarge	34
Surgical removed	1
Total	53

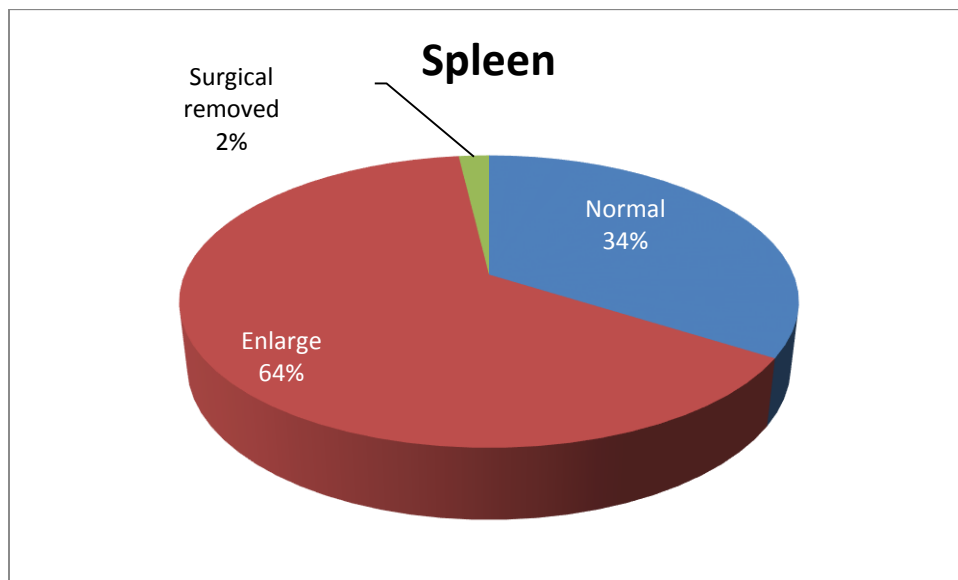


Fig.(4-7): Pie graph of percentage distribution of patients according to spleen size

Table(4-8) :Frequency distribution of patients according to present of ascites

Ascites	Frequency
Yes	18
No	35
Total	53

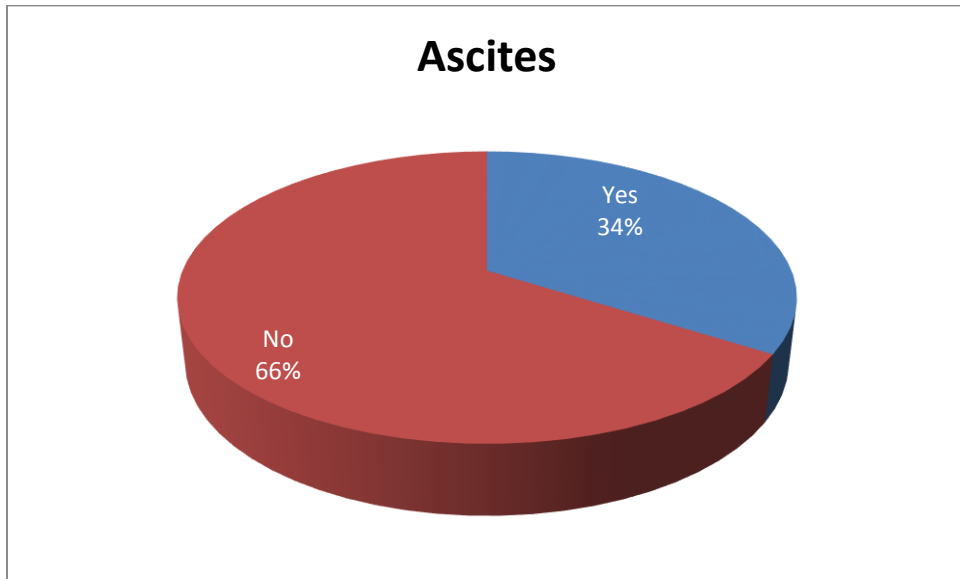


Fig.(4-8): pie graph of percentage distribution of patients according to present of ascites

Table(4-9) :Frequency distribution of patients according to portal vein changes

Portal vein	Frequency
Normal	20
Dilated	31
Periportal fibrosis	2
Total	53

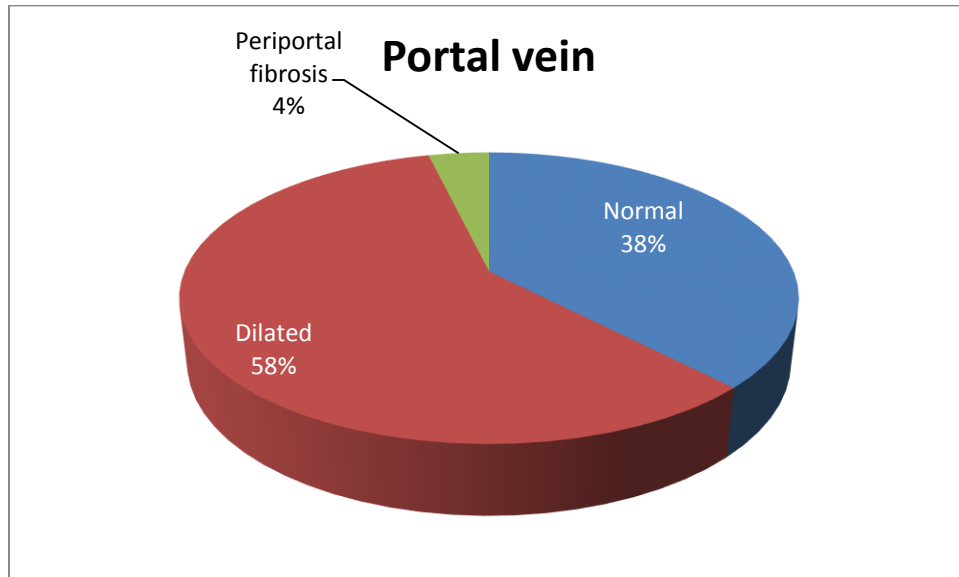


Fig.(4-9): Distribution of patients according to portal vein changes

Table(4-10) :Frequency distribution of patients according to present of collateral

collateral	Frequency
Yes	19
No	34
Total	53

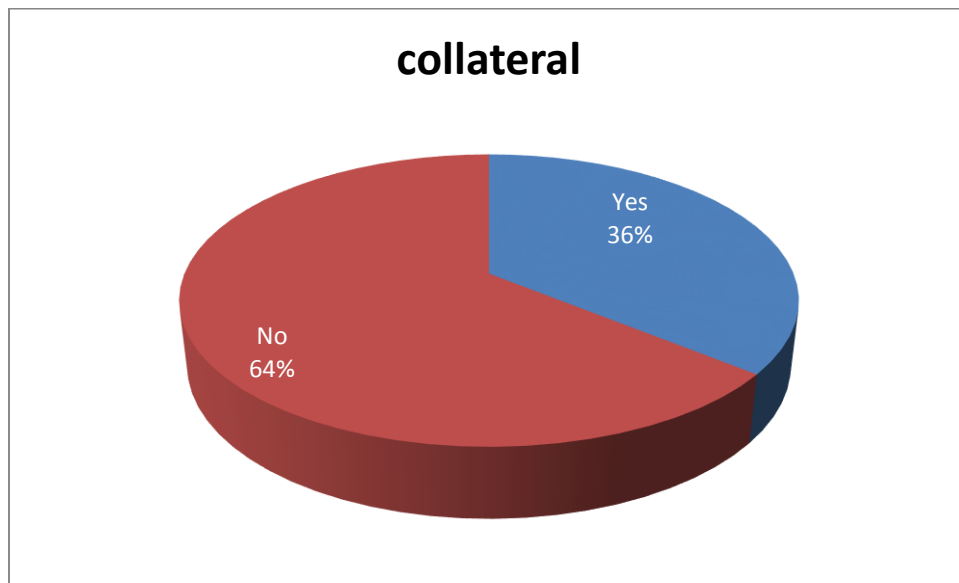


Fig.(4-10): pie graph of frequency distribution of patients according to present of collateral

Table(4-11) :Frequency distribution of patients according to liver size

Liver size	Frequency
Normal	29
Decrease	12
Increase	12
Total	53

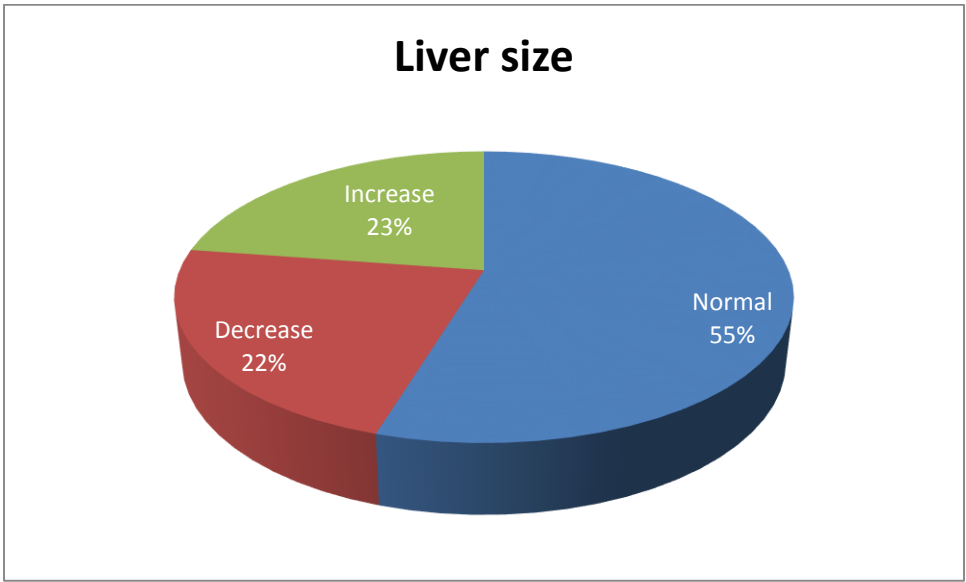


Fig.(4-11): pie graph of percentage distribution of patients according to liver size

Table(4-12): cross-tabulation table show the relation between marital status and cirrhosis grade in percentage

MS	cirrhosis grade			Total
	0	1	2	
Married	56.6%	17%	11.3%	84.9%
Single	9.4%	3.8%	1.8%	15.1%
Total	66%	20.8%	13.2%	100%

Table (4-13):cross-tabulation tables show the relation between texture and cirrhosis grade as percentage

Texture	cirrhosis grade			Total
	0	1	2	
Homogenous	45.4%	1.8%	1.8%	49.1%
Heterogeneous	20.8%	18.9%	11.3%	50.9%
Total	66.2%	20.7%	13.1%	100%

Table (4-14):cross-tabulation tables show the relation between echogenicity and cirrhosis grade as percentage

Echogenicity	cirrhosis grade			Total
	0	1	2	
Normal	37.7%	0%	1.9%	39.6%
Hypoechoic	22.6%	5.7%	5.7%	34%
Hyperechoic	5.7%	13.2%	5.7%	24.6%
Nodular	0%	1.8%	0%	1.8%
Total	66%	20.7%	13.3%	100%

Table (4-15): cross-tabulation tables show the relation between spleen size and cirrhosis grade.

spleen	cirrhosis grade			Total
	0	1	2	
Normal	34%	0%	0%	34%
Enlarge	30.2%	20.7%	13.2%	64.1
Surgical removed	1.8%	0%	0%	1.9%
Total	66%	20.8%	13.2%	100%

Table (4-16) :cross-tabulation table show the relation between ascites and cirrhosis grade as percentage

Ascites	cirrhosis grade			Total
	0	1	2	
Yes	7.5%	13.2%	13.2%	33.9%
No	58.6%	7.5%	0%	66.1
Total	66.1%	20.7%	13.2%	100%

Table (4-17) :cross-tabulation table show the relation between portal vein and cirrhosis grade as percentage

portal vein	cirrhosis grade			Total
	0	1	2	
Normal	37.7%	0%	0%	37.7%
Dilated	24.5%	20.8%	13.2%	58.5%
Periportal fibrosis	3.8%	0%	0%	3.8%
Total	66%	20.8%	13.2%	100%

Table (4-18) :cross-tabulation tables show the relation between collateral and cirrhosis grade as percentage as percentage.

collateral	cirrhosis grade			Total
	0	1	2	
Yes	7.5%	17%	11.3%	35.8%
No	58.5%	3.8%	1.9%	64.2%
Total	66%	20.8%	13.2%	100%

Table (4-19) :cross-tabulation tables show the relation between liver size and cirrhosis grade as percentage

Liversize	cirrhosis grade			Total
	0	1	2	
Normal	45.3%	7.5%	1.9%	54.7%
Decrease	0%	11.3%	11.3%	22.6%
Increase	20.7%	1.9%	0%	22.6%
Total	66%	20.8%	13.2%	100%

Table (4-20) :the mean and standard deviation patient age and liver volume for different liver cirrhosis grade.

Cirrhosis grade	0	1	2
Age	44.4±14.4	54.8±18.7	51.3±14.1
volume	1474.8±1581.5	719.1±334.2	470.4±281.6

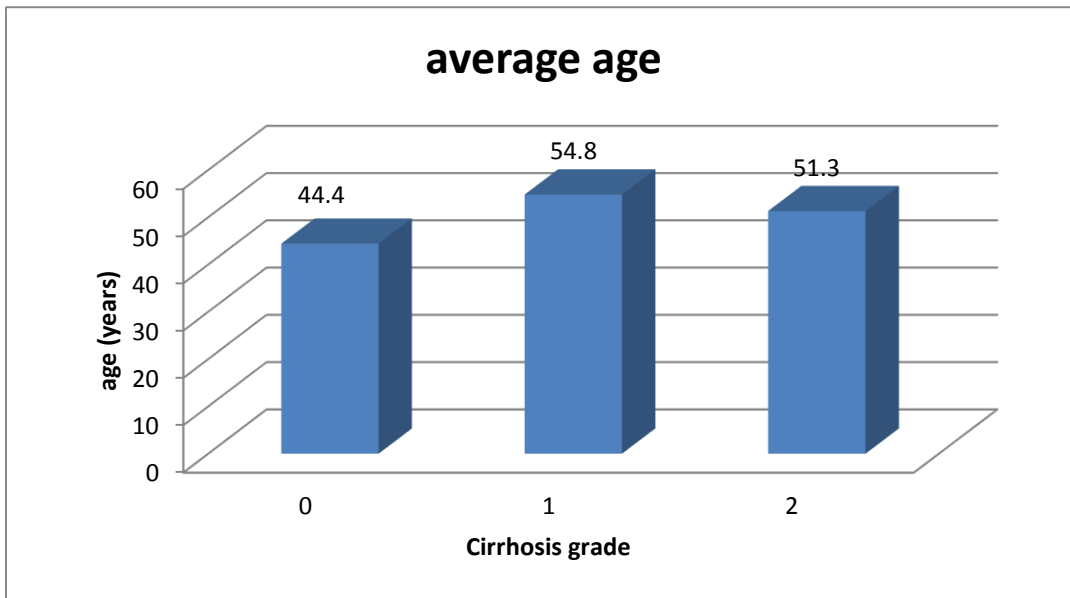


Fig.(4-12):bar graphs show the distribution of average age in respect to cirrhosis grade

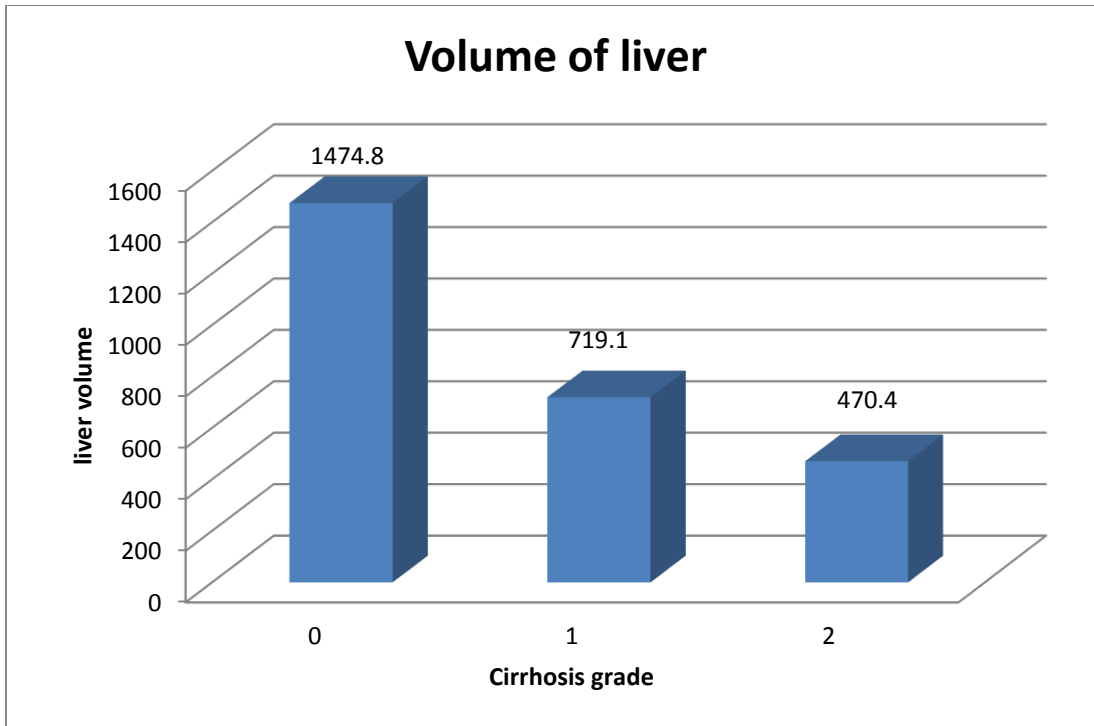


Fig.(4-13):bar graph show the distribution of liver volume in respect to liver cirrhosis grade

Table (4-21): Analysis of Variance table for significance test between age and volume with the liver grade, which shows inconclusive results

ANOVA					
		Sum of Squares	Mean Square	F	Sig.
Age	Between Groups	1025.7	512.9	2.175	.124
	Within Groups	11791.5	235.8		
	Total	12817.2			
Volume	Between Groups	8900927.9	4450463.9	2.569	.087
	Within Groups	86634020.8	1732680.4		
	Total	95534948.8			

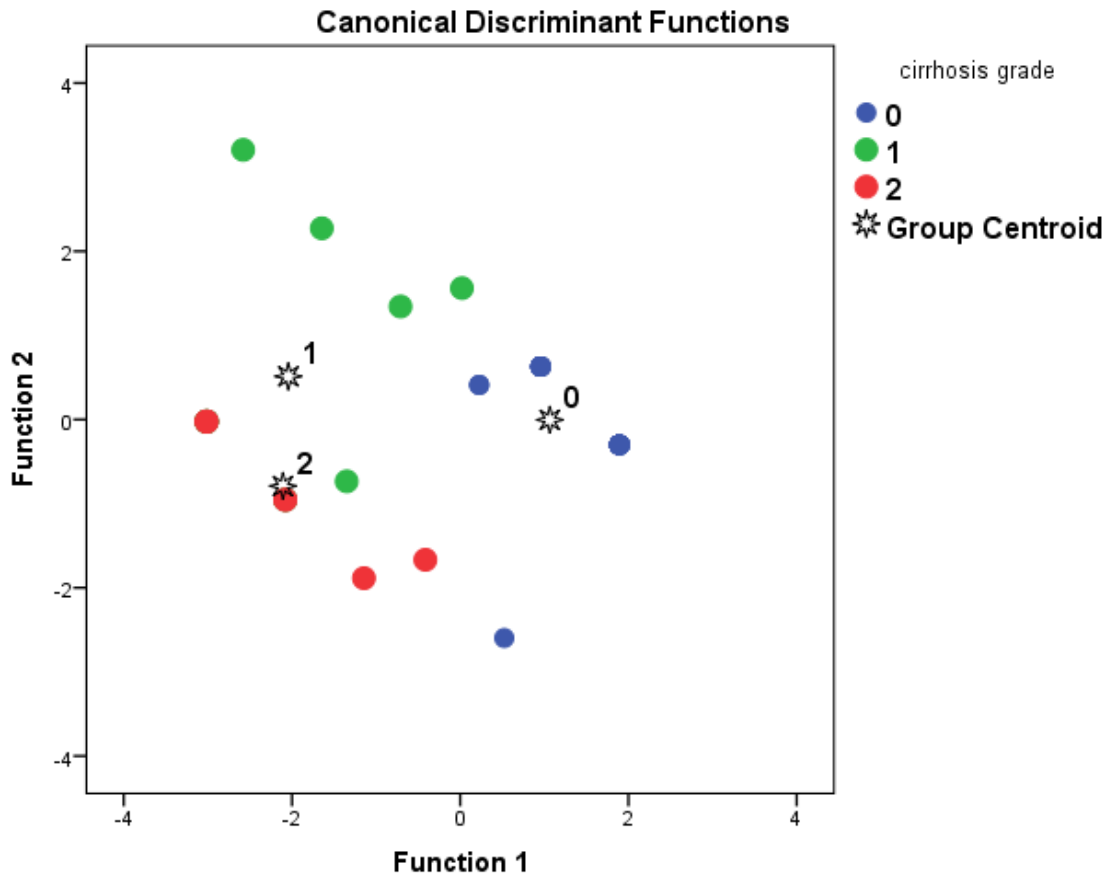


Fig. (4-14): scatter plot show the classification of liver cirrhosis grade as classification center using linear discriminant function

Table (4-22): confusion matrix show the classification accuracy using linear discriminant analysis and ultrasound findings as input function

cirrhosis grade	Predicted Group Membership			Total
	0	1	2	
0	91.4%	0%	8.6%	100%
1	9.1%	63.6%	27.3%	100%
2	0%	42.9%	57.1%	100%
81.1% of original grouped cases correctly classified.				

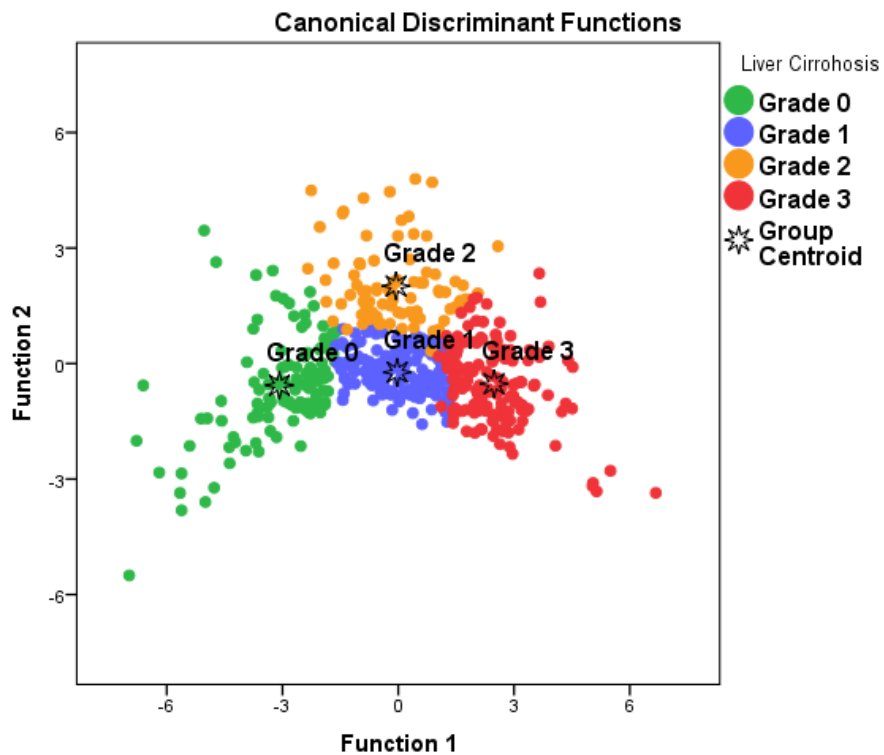
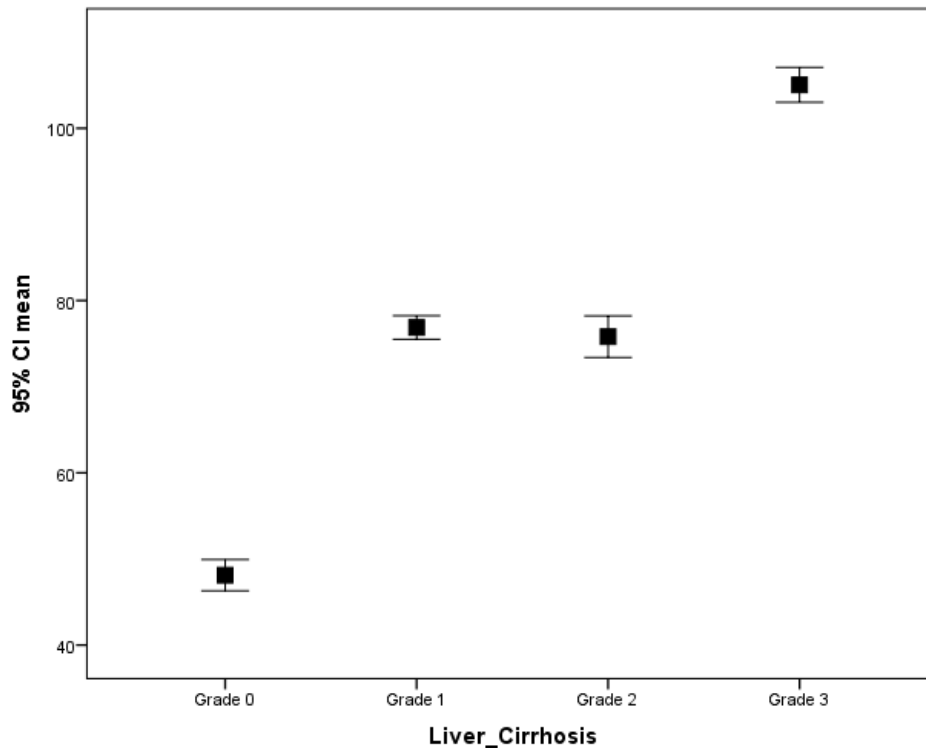


Fig. (4-15) scatter plot show the centroid for the class and the distribution of classes around the classification center according to classification function.

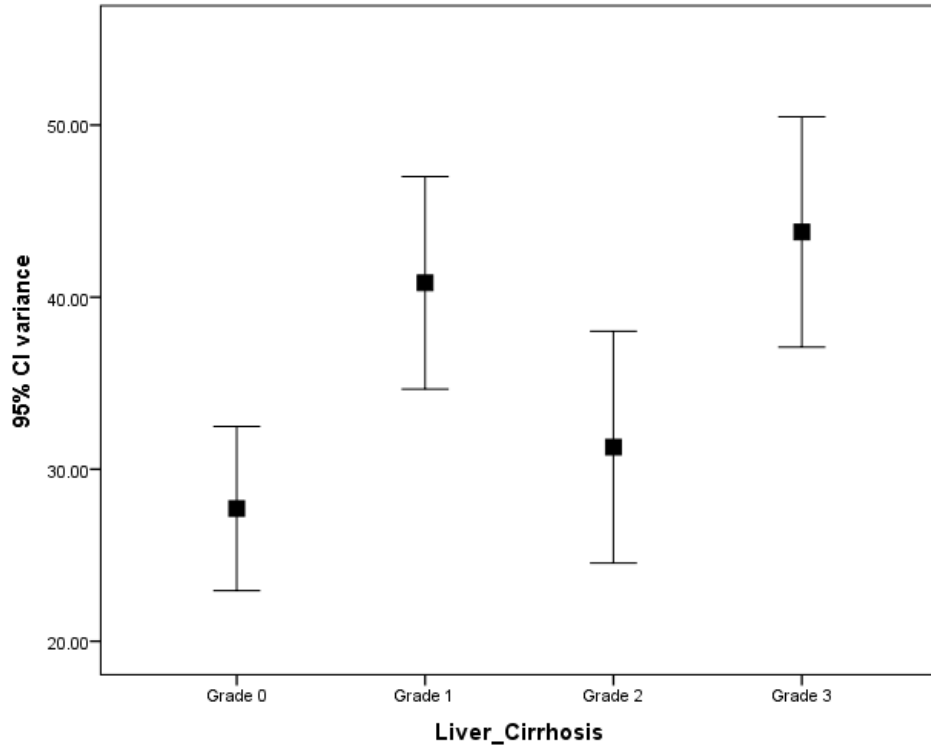
Table (4-23) confusion matrix showed a correct percentage of cross match results in the diagonal line with the off diagonal matrix gives the miss classification percentage

Liver Cirrhosis		Predicted Group Membership				Total
		Grade 0	Grade 1	Grade 2	Grade 3	
%	Grade 0	<u>90.6%</u>	7.7%	1.7%	0.0%	100.0%
	Grade 1	0.0%	<u>100.0%</u>	0.0%	0.0%	100.0%
	Grade 2	0.0%	2.2%	<u>97.8%</u>	0.0%	100.0%
	Grade 3	0.0%	6.7%	2.7%	<u>90.6%</u>	100.0%

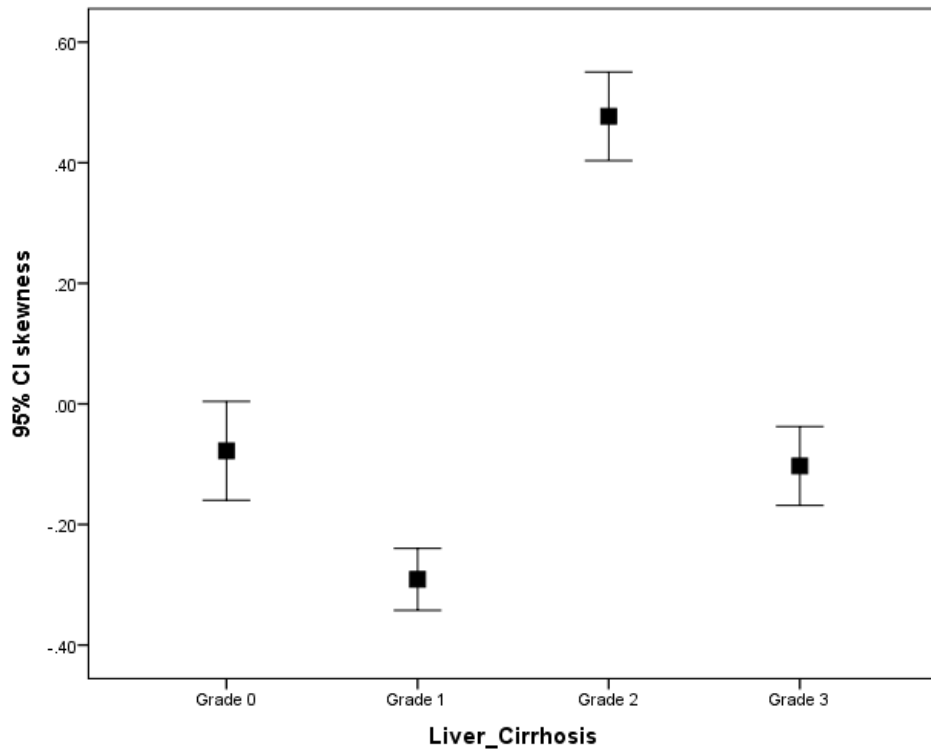
94.7% of original grouped cases correctly classified.



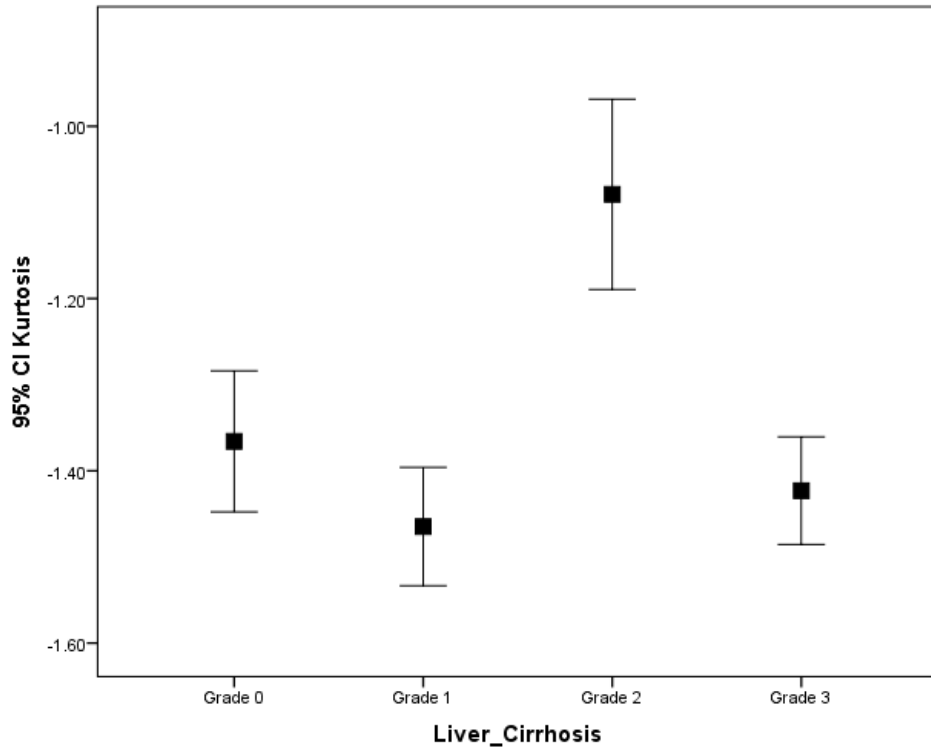
(A)



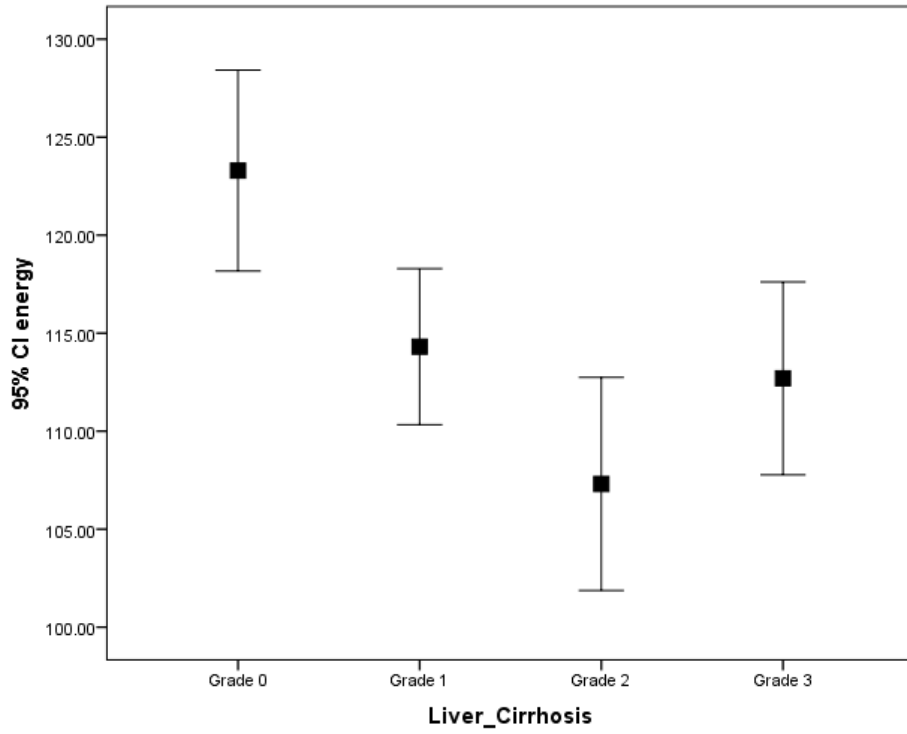
(B)



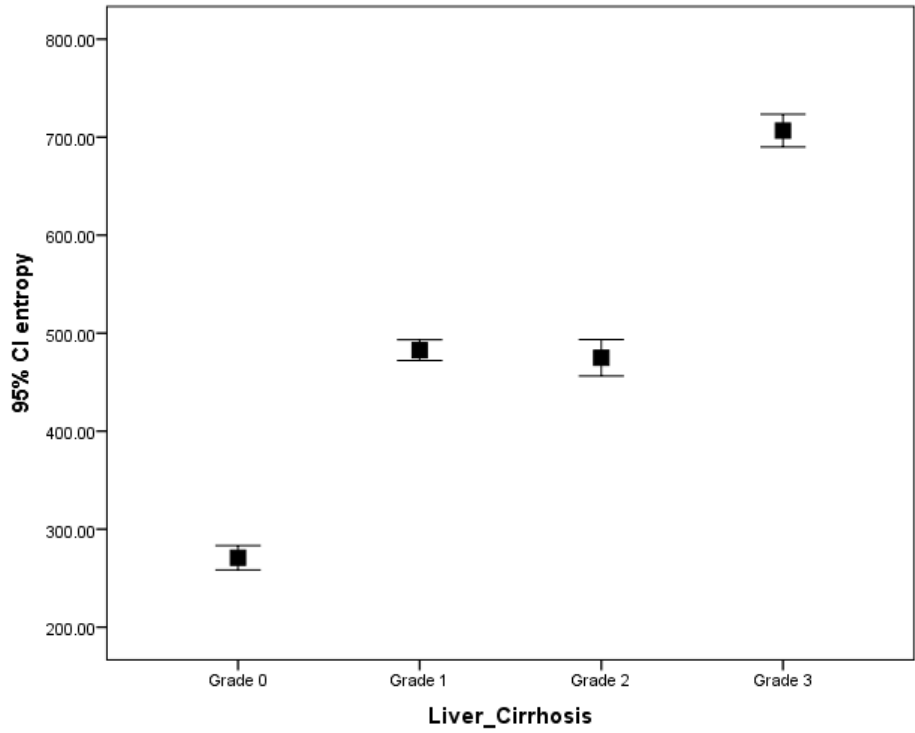
(C)



(D)



(E)



(F)

Fig. (4-16) error bar plot for the textural features (A) mean, (B) variance, (C) skewness, (D) Kurtosis, (E) energy and (F) entropy for liver cirrhosis grade 0, 1, 2 and 3.

Chapter Five

Discussion, conclusion and Recommendation

5-1 Discussion

The data of this study consisted of 53 cases, 31 patients were male forming the incidence of (58%) and this record agrees with R. kardorff et al who was studies clinical, parasitological and in part of serological to evaluate schistosomamansoni –related morbidity on a community level and found more incidence and severity in males. Also this study showed that incidence mostly associated with married patients about (85%).

This analyzed in to three groups farmer, house wife and labor was found incidence about 39%, 40% and 11% and found more incidence in farmer and house wife more in farmer because are interact with environment of schistosoma .

In respect to liver texture the data arranged into two groups homogenous and hetrogenous and it was found that more patients have heterogeneous liver about (51%) and agree with all previous studies in this research because the schistosoma usually cause periportal fibrosis and coarse liver textures. Similarly echogenicity distributed into four groups normal, hypoechoic, hyperechoic and nodular showed the following distribution 40%, 34%, 24% and 2% respectively. echogenicity of liver depended on the severity and time of disease. This agree with M. Badawi et al study sonographic tissue signature of bright liver to establish a specific quantitative criteria for

computerized discrimination of different diffuse liver diseases and found a results of classification of bright livers over 90% sensitivity, specificity, and overall efficiency.

According to the classification of liver into grades where the liver had been classified into three groups grade 0, 1 and 2; this study found that incidence was 66%, 21% and 13% for each grade respectively. This agree with R. Kardorff et al who was studies clinical, parasitological and in part of serological to evaluteschistosomamansonii-related morbidity on a community level and found severe grades of fibrosis (MANAGIL score II and III) were present in about 6%. About 10% had other abnormalities on liver sonography (irregular parenchymal texture and/or shape).

The cardinal signs of liver cirrhosis grade include spleen enlargement and presence of ascites. The result of this study showed that there was three groups in respect to spleen size; normal, enlarge, surgical removed which showed the following percentage 34%, 64%, 2% respectively. Most of the patients had splenomegaly and agree with most of previous studies such as Chou et al, Luciana et al and Vennervald all of them was found spleen enlargement. In case of ascites this study showed that the presence of ascites represents 34% which is mostly attributed to portal hypertention and liver cirrhosis. According to portal vein changes the result of this study showed four groups normal, dilated and periportal fibrosis with the following percentages: 38%, 58% and 4%; respectively. Most of patients had dilated portal vein about (58%) and this agree with all previous studies in my research which were recorded result of portal hypertention and

periportal fibrosis. Liver volume also attributed to cirrhosis grading, in this study liver volume was grouped into three groups normal, decrease and increase as 55%, 22% and 23% respectively. This agrees with almost of the previous studies such as Chou et al, Luciana and Richter which were reported hepatomegaly and liver cirrhosis. Similarly the distribution of patients according to presence of collateral this study reveals two groups present and not present which was 36% and 64% respectively; this was agree with Chou et al studies the portal hemodynamic in patients with hepatic schistosomiasis and found portal hypertension and collateral.

The relationship between liver cirrhosis grade and other variables showed that there is no strong relationship between the marital status and cirrhosis grade. Also texture is unreliable finding in cirrhosis grade because texture affected by other factor such as gain. But there is strong relationship between echogenicity and cirrhosis grade. Echogenicity is play key role in grade of cirrhosis because almost of normal are found in grade 0 about 37.7% of patients and 1.9% of patients in grade 2. In case of spleen size there is no strong relationship between spleen size and cirrhosis grade even all studies found there is large spleen as a result of schistosoma. As mentioned earlier ascites play an important role in liver cirrhosis grading almost all ascites patients are found in grade 1 and 2 patients as the same percent 13.2% but about 7.5% found in grade 0. Also collateral play key role in grade of cirrhosis most of collateral are found in grade 1 and 2 by 17% and 11.3% patients but has 7.5% of them in grade 0 make it somehow unreliable. On the other hand there is no strong relationship between the portal vein and cirrhosis grade as well as liver size volume and age.

In this study linear discriminant analysis was applied on variables extracted from ultrasound finding in order to find the liver grade objectively; all variables discussed above had been entered as input variables to stepwise linear discriminant analysis; the function selected only three variables as the most significant one for classifications, they include: echogenicity, ascites and collateral. The results of classification showed an overall accuracy of 81.1% of original grouped cases correctly classified using linear discriminant function.

In this study texture analysis were applied to ultrasound images for the different grades where the first order textural features (mean, variance, skewness, kurtosis, energy and entropy) were extracted from region of interest that represents grade 0, 1, 2 and 3. Then classifications were carried out using stepwise linear discriminant as above to select the most significant features with the classification process. The results of the classification showed that 94.7% of the original classes were correctly predicted by the classification function. Where the sensitivity was equal to 96.1% and specificity of 90.6%

Stepwise linear discriminant analysis chooses all the entered features as the most discriminant one i.e. none of the features were rejected for redundancy or for correlation problem between them as independent features. The feature mean (mean intensity or signal) gives a good separation between the normal liver tissues Grade 0 and the rest of the grade, but grade 1 and 2 were inseparable. Variance separate all grade from each other's with some degree of overlaps at the max or min values. Skewness and kurtosis clearly separate grade 1 from others grades. While energy separate grade 0 from the rest of

the grades and entropy which showed a minimum deviation (spread) clearly separate grade 0 and 3 from each other and from grade 1 and 2 as well as partial grade 1 from 2.

5-2 Conclusion

In conclusion liver cirrhosis can be grade using ultrasound visual characteristics objectively with an accuracy of 81.1% using linear discriminant equation, where the vote for the grade in the equation will be to the highest value as follows:

$$\text{Grade 0} = (2.445 \times \text{echogenicity}) + (11.7 \times \text{Ascites}) + (11.64 \times \text{collateral}) - 24.96$$

$$\text{Grade 1} = (5.83 \times \text{echogenicity}) + (8.63 \times \text{Ascites}) + (6.09 \times \text{collateral}) - 18.81$$

$$\text{Grade 2} = (4.68 \times \text{echogenicity}) + (5.55 \times \text{Ascites}) + (6.92 \times \text{collateral}) - 13.18$$

Echogenicity: Normal = 1, Hypoechoic = 2, Hyperechoic = 3 and Nodular = 4 Ascites: Yes = 1, No = 2, Collateral: Yes = 1, No = 2

Texture analysis can be used objectively to grade liver cirrhosis using multiple linear discriminant analysis function with a higher classification accuracy than the use of ultrasound features with classification accuracy of 94.4% in contrast to ultrasound features above using the following equations.

$$\text{Grade 0} = (\text{mean} \times 23.5) + (\text{skewness} \times 3.99) + (\text{kurtosis} \times -7.29) + (\text{energy} \times 0.07) + (\text{entropy} \times -2.97) - 175.1$$

$$\text{Grade 1} = (\text{mean} \times 26.4) + (\text{skewness} \times 3.8) + (\text{kurtosis} \times -8.8) + (\text{energy} \times 0.065) + (\text{entropy} \times -3.3) - 228.6$$

$$\text{Grade 2} = (\text{mean} \times 26.76) + (\text{skewness} \times 10.25) + (\text{kurtosis} \times -5.26) + (\text{energy} \times 0.049) + (\text{entropy} \times -3.35) - 228.35$$

$$\text{Grade 3} = (\text{mean} \times 25.44) + (\text{skewness} \times 5.68) + (\text{kurtosis} \times -9.3) + (\text{energy} \times 0.076) + (\text{entropy} \times -3.14) - 237.07$$

5.3 Recommendation

- High incidence in farmers need more health care.
- Ultrasound scanning should be used in every patient with suspicion or diagnosis of schistosoma to clarify the complications of the disease.
- Conventional & doppler ultrasounds are highly recommended for revealing portal hypertension.
- There is a great need to train medical staff doctors and sonologists properly do ultrasound scans to serve schistosoma projects target patients and help in their medical management and help in longitudinal and cross-section schistosoma researches .
- Present these results in different ways to assist in the fight against schistosoma infection, in health education and in the training programs suggested in this study and use my research findings in diagnosis and grading of liver cirrhosis
- Further studies is recommended for evaluation of ultrasound finding for GI tract for schistosomiasis in endemic areas.

References

- 1- Ljosa V, Carpenter AE (2010) Introduction to the quantitative analysis of two-dimensional fluorescence microscopy images for cell-based screening. PLoS Comput Biol 5: e1000603. doi: [10.1371/journal.pcbi.1000603](https://doi.org/10.1371/journal.pcbi.1000603) .
- 2- Coelho LP, Glory-Afshar E, Kangas J, Quinn S, Shariff A, et al. (2010) Principles of bioimage informatics: focus on machine learning of cell patterns. Lect Notes Comput Sci 6004: 8–18.
- 3- Gooding AR, Christlieb M, Brady M (2008) Advanced phase-based segmentation of multiple cells from brightfield microscopy images. Proc IEEE 5th Int Symp Biomed Imaging 181–184.
- 4- Herald T. Lutz & Hassen A. Gharbi. Manual of diagnostic ultrasound in infectious tropical diseases. springer-verlag; Berlin Heidelberg: Germany: 2006.
- 5- G.Gerie,et al:The use of ultrasonography of schistosomal syndrome,Third International work shop,Cairo Egypt,1978.
- 6- J-Richter.et al:apractical guide to the standardized use of ultrasonography of schistosomiasis and related to morbidity, International work shop,Niamy Niger,October,22----26;1992.
- 7-M.abdalwahab;Grading of hepatic schistosomiasis by the use of ultrasound,Amj.Trop Med Hyg,PP403,1992.
- 8-Kloetzek;Splénomegally in schistosoma mansoni Amj.Trop Med Hyg,PP403,1992.

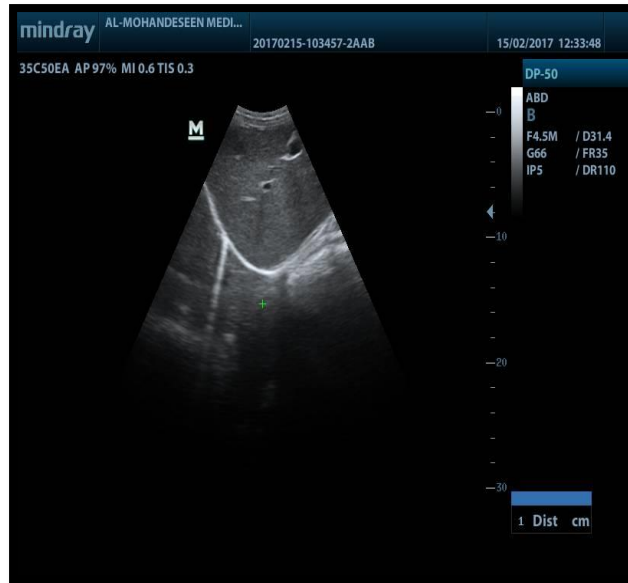- 9- Shawgi H.Elmasri;portal hypertention,pathologies and manegment with special refrence to bilharsial preportal fibroid,Academy of medical Science 2003.
- 10- Hanan.E.Mohamed,ascites in patient with schistosomal preportal fibroid,M.D thesis 1990.
- 11- Mamoun Homeida et al:Diagnosis of pathological confirmed synems preportal fibroid by ultrasonography (Aprospective blind study) 2002.
- 12- Petral L.Willimas, et al: Gray's Antomy's, EL/BS, Therty-seven ed, 1992.
- 13- John V. Basma Jian, et al: Primary Antomy, Williams and Wilkins, Blatimor London, Biliar system 1994..
- 14- Guton, text book of Medical Physiology, W, P. Saunlers Company, 1986.
- 15- Donld Emslie-Smith et al: text book of physiology, eleventh ed, EL/BS, 1998.
- 16- N M Mack. Sween, Murr's, text book of pathology. Arnolal thirteenth ed, 1992.
- 17- REVA A. Curry, et al: Ultrasonography and Introduction to normal structures and functional Anatomy, W. B Sanders. Company, 1st ed, 1995.
- 18- Sanral.et al:text book of diagnostic ultrasonography,Volume one.five ed,2005.
- 19- Qurashi.M.Ali,Ultrasonic evaluation of GB function in patients with schistosoma mansoni infection 1990.

- 20- Coral-Krebs, Ultrasound Atlas of disease process, Appleton and Luge, 1993.
- 21- P.E.S Palmer, Manual of diagnostic ultrasound. WHO, Geneva 1995.
- 22- Devin Dean. Ultrasound of the abdomen and small parts. Part one. The Brwin Institute of diagnostic medical ultrasound; Lunenburg, Canada: 2005. P. 23, 26, 29-33.
- 23- Moore et al. Essential clinical anatomy. 3rd edition. Williams & Wilkins; Lippincott: 2007. p. 164-165, 167, 169.
- 24- John V. Basma Jian et al. Primary anatomy of liver and biliary system. First edition. Blatimor London, Lang medical books; USA: 1989. P. 57
- 25- Jane Bates. Abdominal ultrasound How, why, and when. 2nd edition. Elsevier limited; china: 2004. P. 24, 95.
- 26- Rose De Bruin. Pediatric ultrasound How, why, and when. First edition. Elsevier limited; china: 2005. p. 148.
- 27- Knodell RG et al. Formulation and application of a numerical scoring system for assessing histological activity in asymptomatic chronic active hepatitis. [online]. [1981;1\(5\):431-5.](#) Available from: [URL: http://www.hepatitis-central.com.](http://www.hepatitis-central.com)
- 28- Carol M Rumack et al. Diagnostic ultrasound. 4th edition. Mosby; USA: 2011. p. 96.
- 29- Lamb CR et al. Ultrasonographic findings in hepatic and splenic lymphoma in dogs and cats. Veterinary radiology; 1991. p. 17, 20.
- 30- Ishak K et al. Histological grading and staging of chronic hepatitis. J Hepato: 1995. P. 696-699.

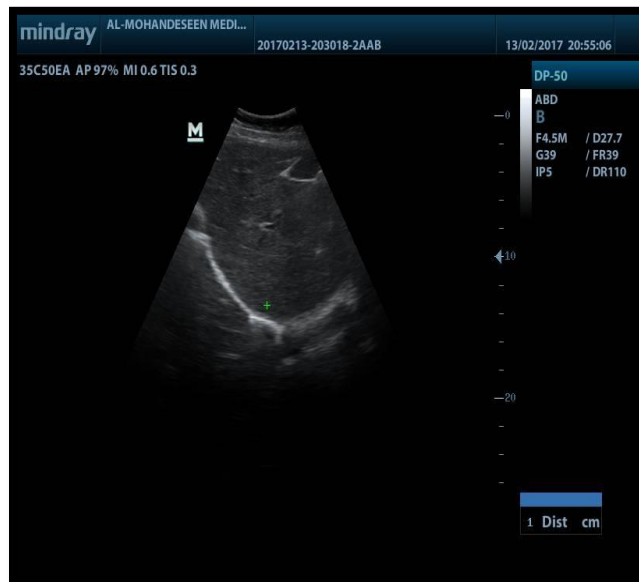
- 31- Ryder S et al. Acute hepatitis. [Online].2001;322(7279):151-153.
Available from: URL: <http://www.pubmedcentral.nih.gov>.
- 32- Liver-Sonography. available from: URL: <https://www.stefjir.com>.
- 33- Elfatih . M. Edosh. Sonographic evaluation of diffuse hepatic disease in Sudan.[Online].2006 jan-2008 jan. Available from: URL: <http://www.afroasianinstitute.com>
- 34- Digestive disorder health center. Available from: [URL:http://www.webmd.com](http://www.webmd.com).
- 35- Department of Radiology. What is the upper limit of normal for the common bile duct on ultrasound.[online]. 2000 Apr ;95(4):897-900.
available from: URL: <https://www.ncbi.nlm.nih.gov>.
- 36- Stanley L.RoBBINS,et al:Basic pathology W.B Saunders company.third ed 1981.
- 37- Gaol Encycology Medecine; schistosomiasis PP1---4 2002.
- 38- <http://www.findarticular.com>.
- 39- <http://www.nhm.ac.uk/hostel-sites/schisto/heidel>.
- 40- <http://www.pubmedcentral.nih.gov>
- 41- Syed Amir Gilani. Guidelines and protocols for medical diagnostic ultrasound. First edition. The brwin institute of ultrasound Asian and middle east branch; Lahore, Pakistan: 2002. P.39-40.

Appendix

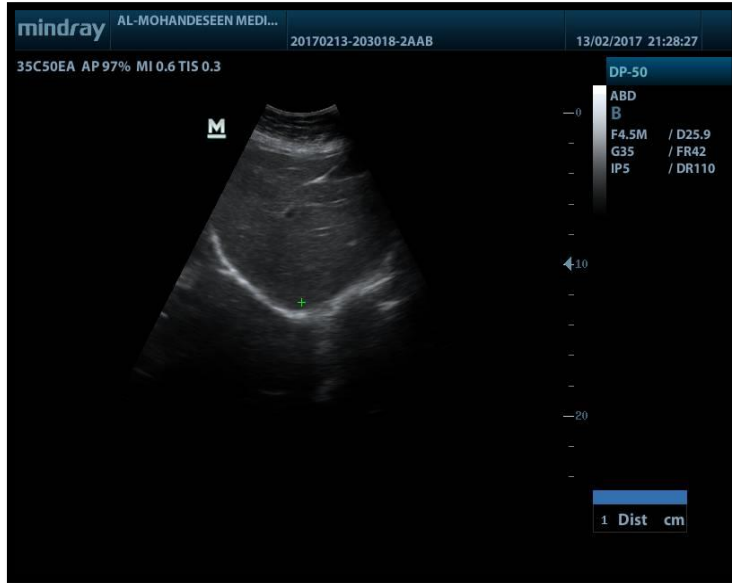
(a)Images:



Fig(a-1): sonogram of normal liver of male 25 years old



Fig(a-2): sonogram of normal liver of female 30 years old



Fig(a-3): sonogram of normal liver of female 20 years old

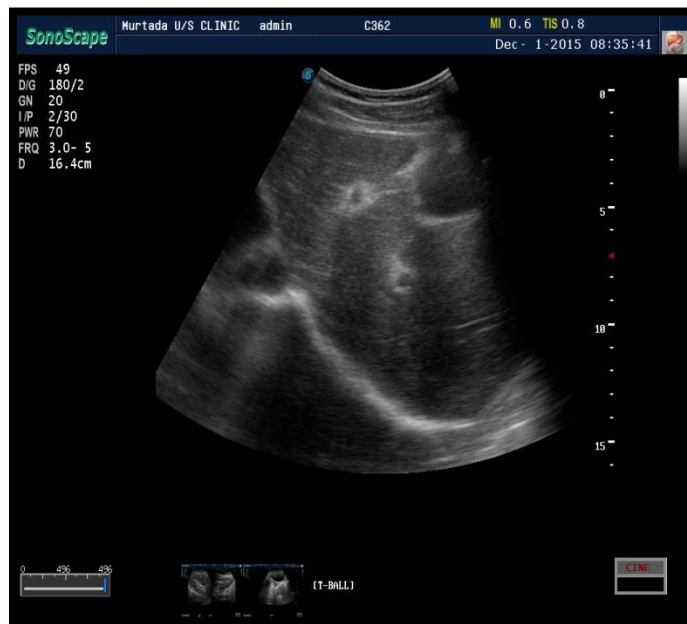


Fig (a-4): sonogram of liver male 32 years old with PPF due to schistosoma

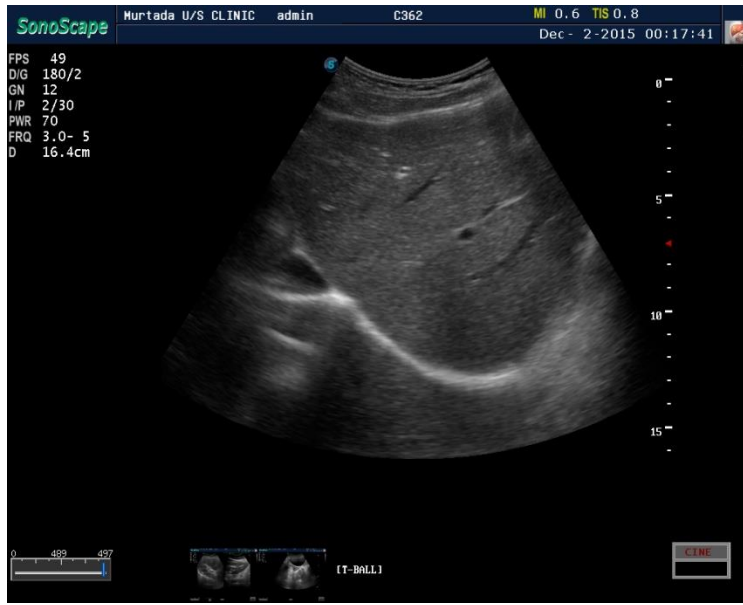

Fig (a-5): sonogram of normal liver female 40 years old exposed to schistosoma

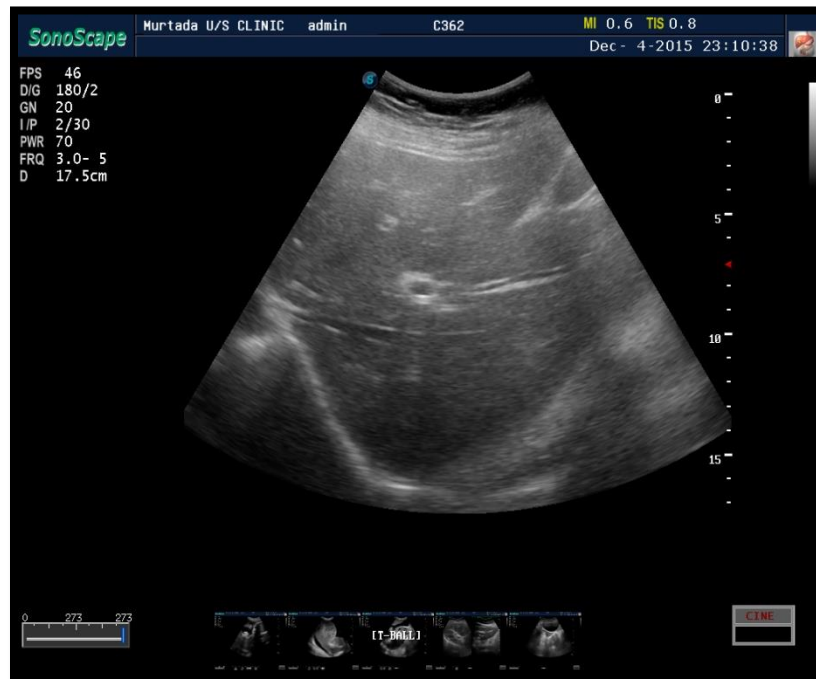


Fig (a-6): sonogram of liver male 56 years old with PPF due to schistosoma

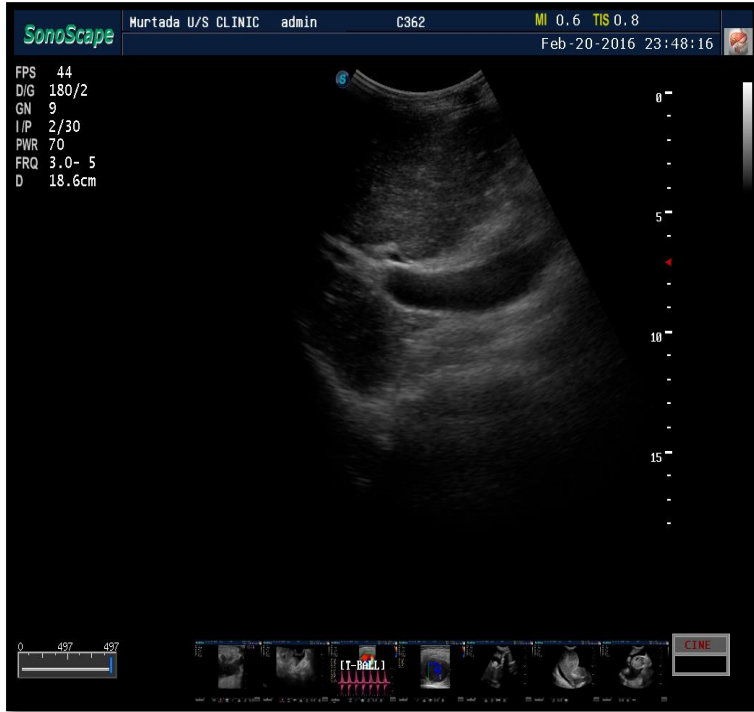


Fig (a-7): sonogram of liver male 60years old with dilated portal vein due to schistosoma

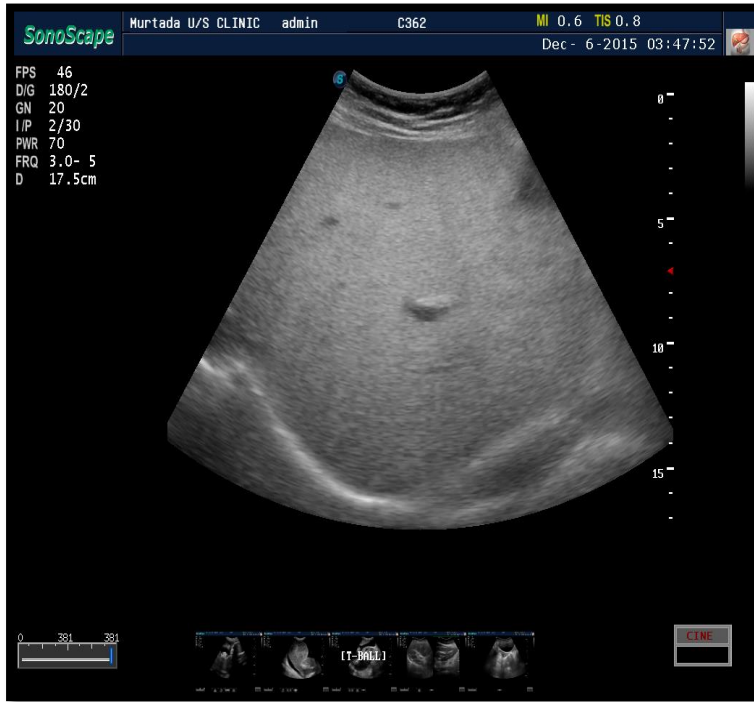

Fig (a-8): sonogram of hyperechoic liver male 45years old with early cirrhotic changes due to schistosoma

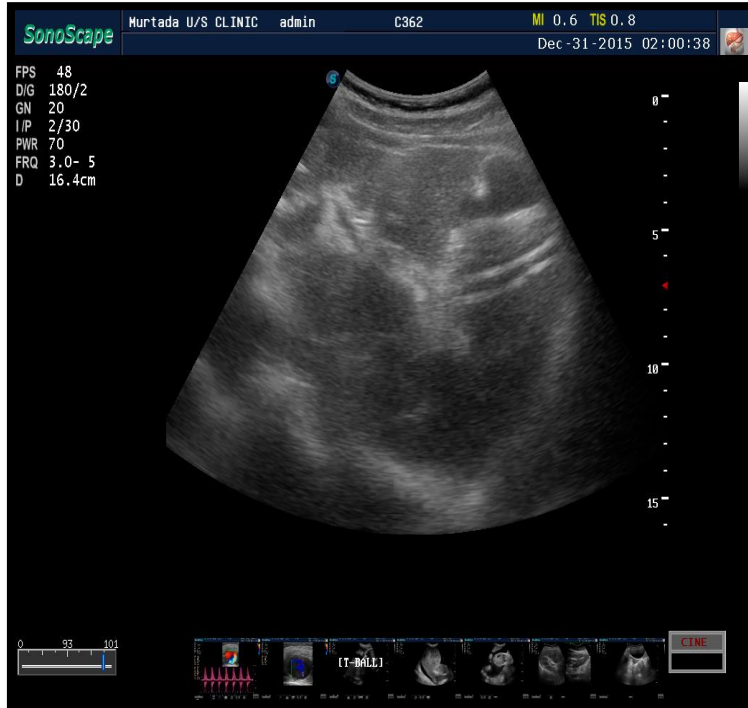


Fig (a-9): sonogram of liver male 52 years old with sever PPF and decrease size due to schistosoma

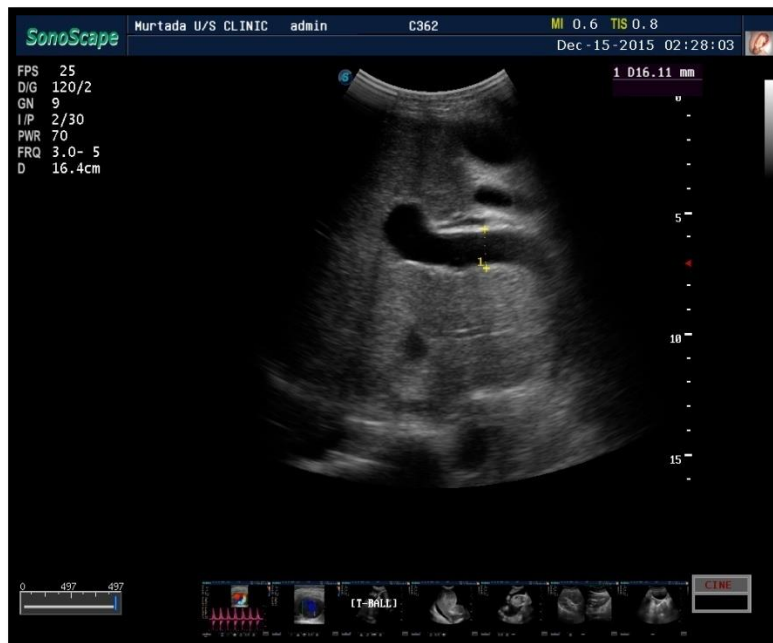

Fig (a-10): sonogram of liver female 52years old with dilated portal vein due to schistosoma

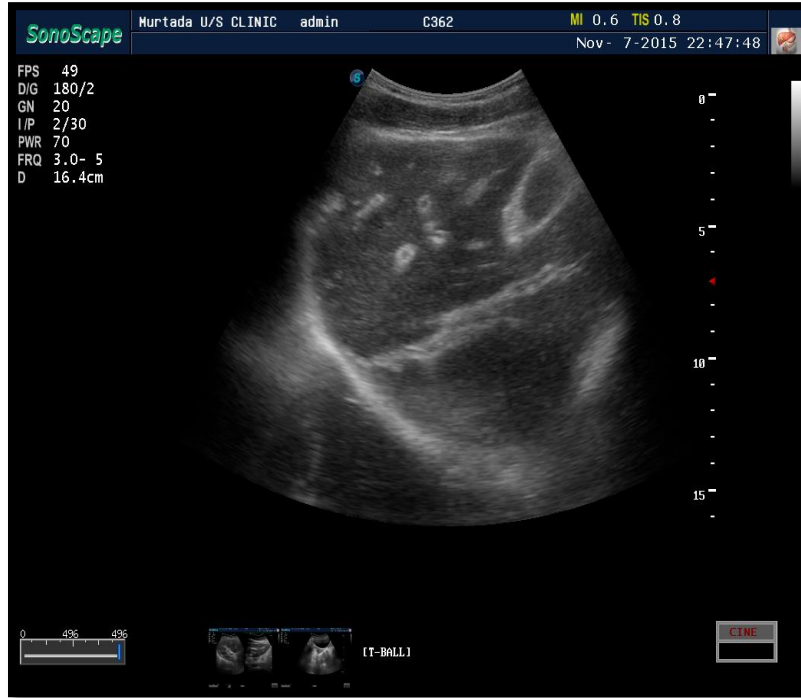


Fig (a-11): sonogram of liver male 30 years old with sever PPF due to schistosoma

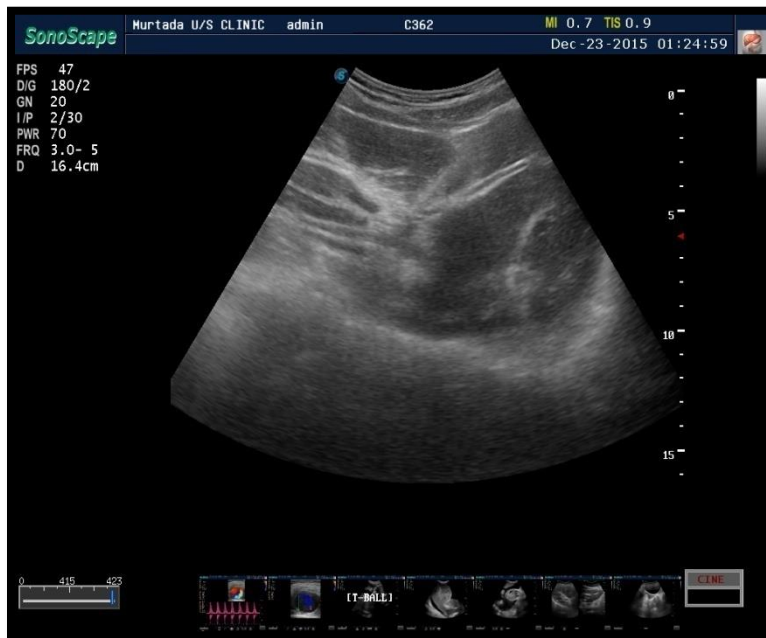

Fig (a-12): sonogram of liver male 47 years old with sever PPF and decrease size due to schistosoma

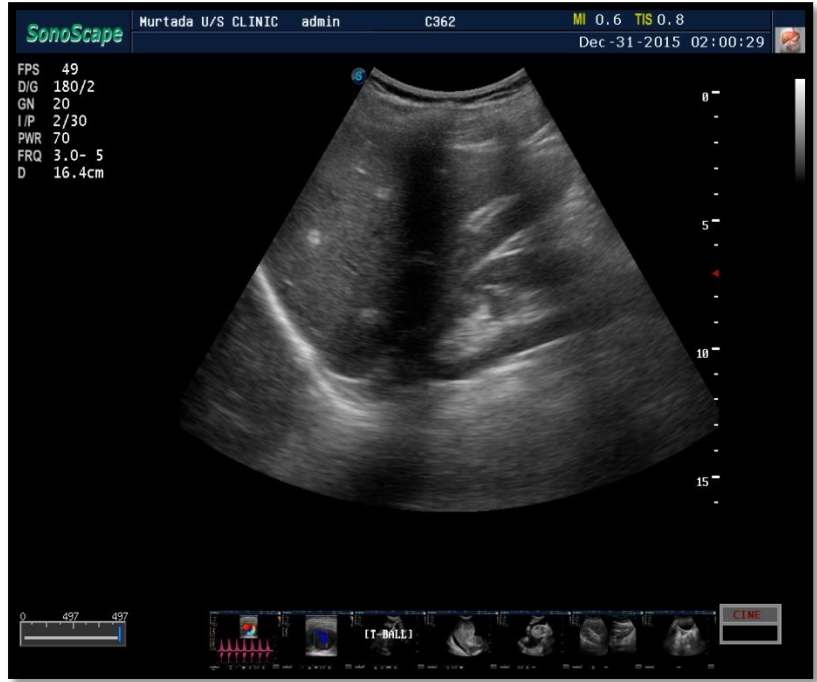


Fig (a-13): sonogram of liver female 55 years old with mild PPF due to schistosoma

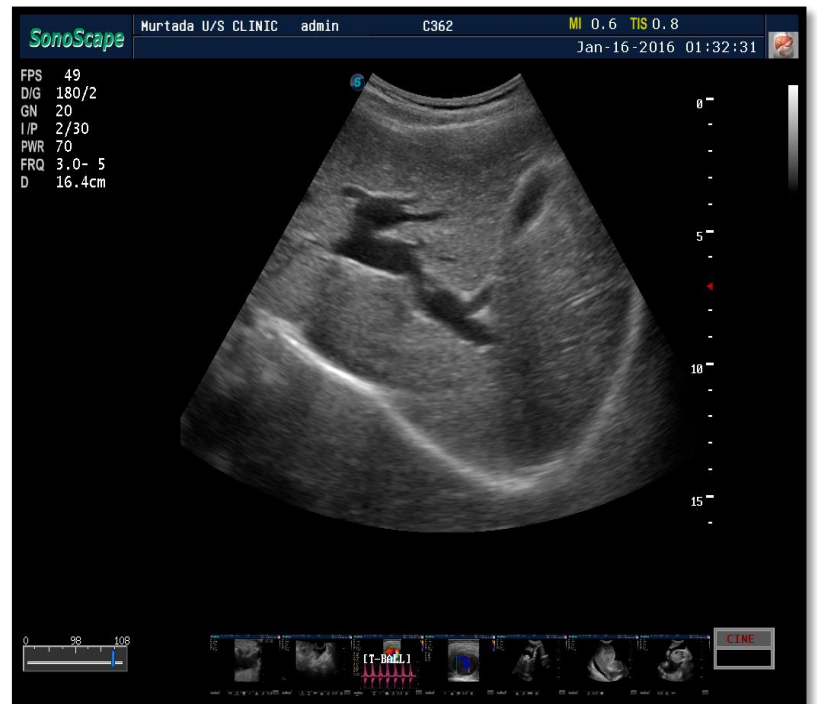

Fig (a-14): sonogram of liver male 65years old with dilated portal vein due to schistosoma

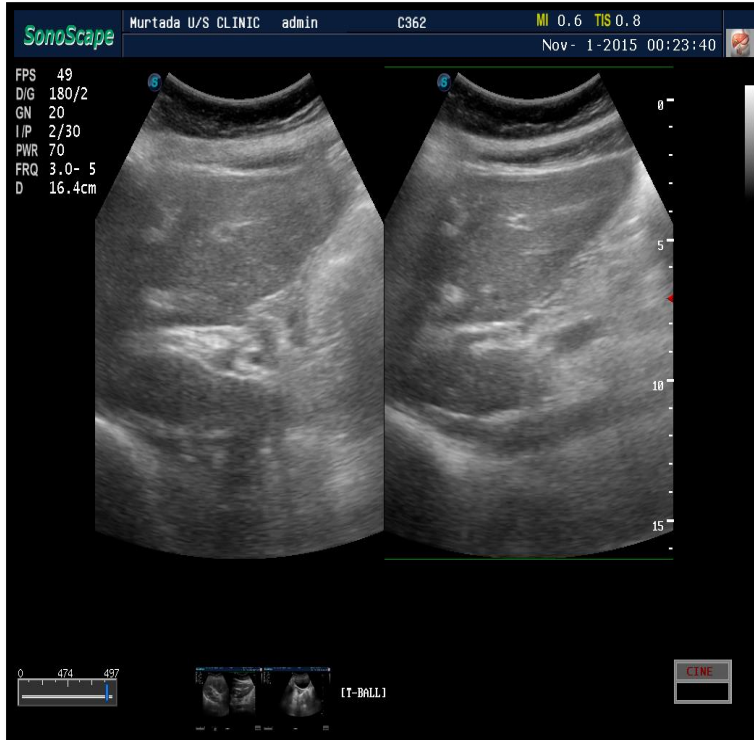


Fig (a-15): sonogram of LT lobe of liver male 26years old with PPF due to schistosoma

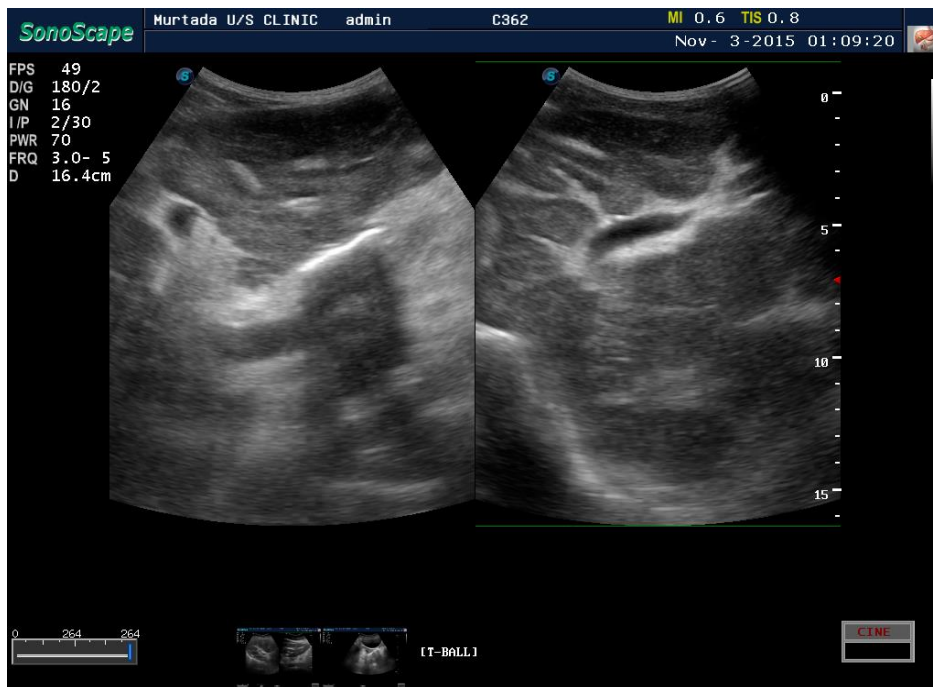


Fig (a-16): sonogram of liver female 56 years old with sever PPF and decrease size due to schistosoma

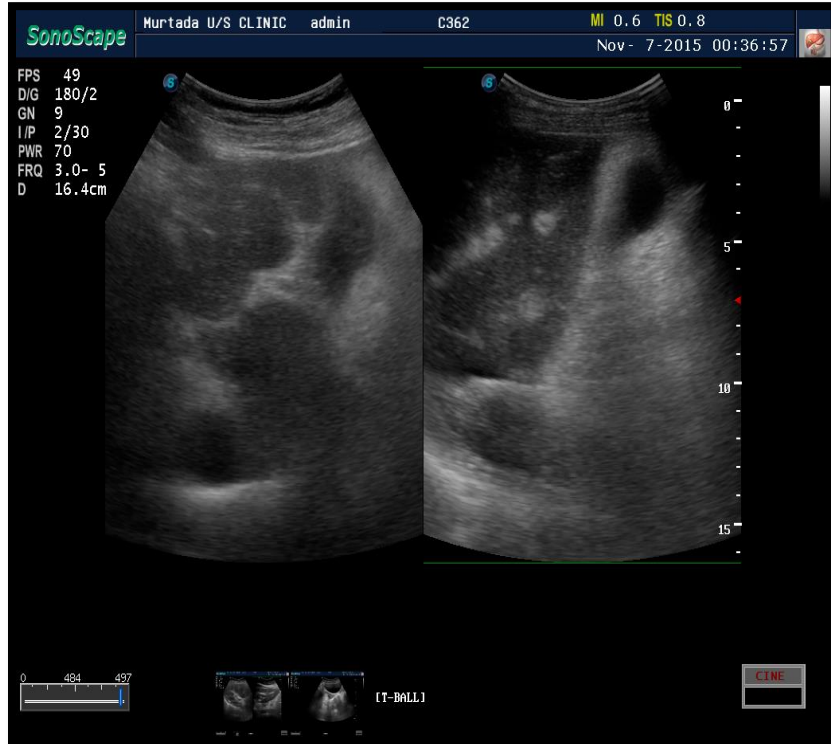


Fig (a-17): sonogram of liver male 58 years old with PPF and thick GB due to schistosoma

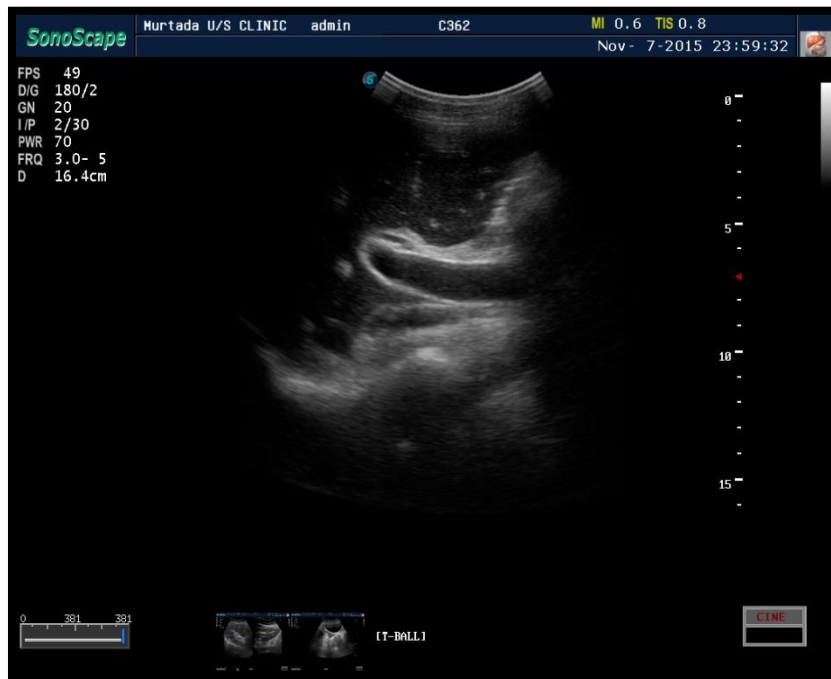

Fig (a-18): sonogram of liver male 28 years old with dilated portal vein due to schistosoma

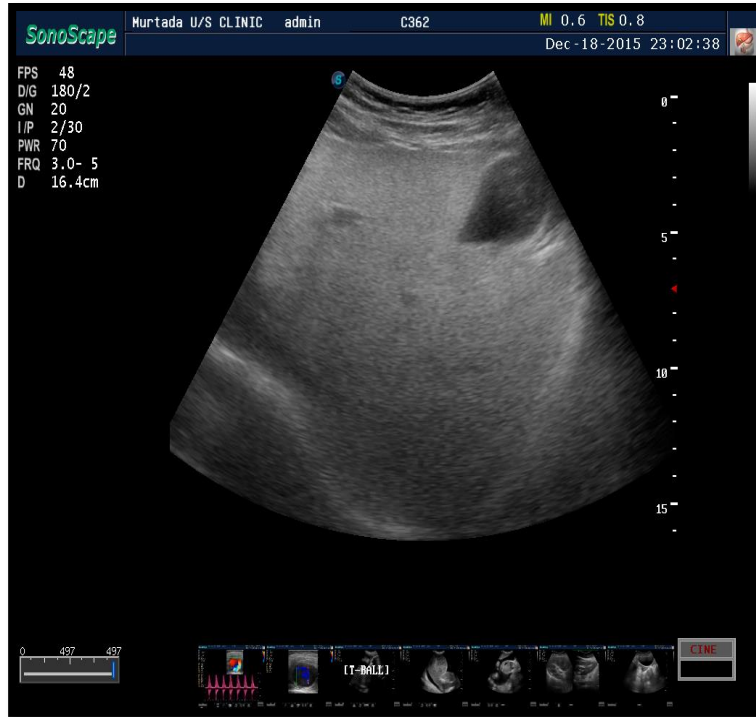


Fig (a-19): sonogram of hyperechoic liver female 38years old exposed to schistosoma

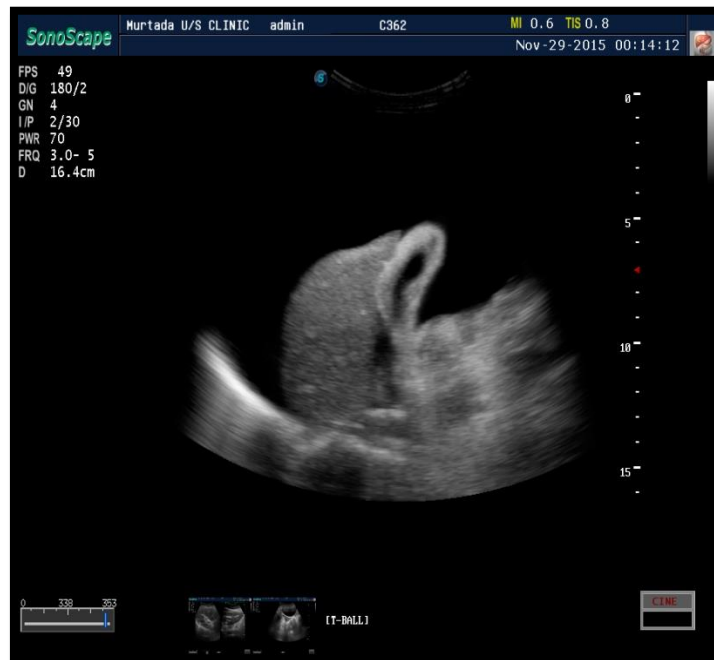

Fig (a-20): sonogram liver cirrhosis and sever ascites female 57years old due to schistosoma

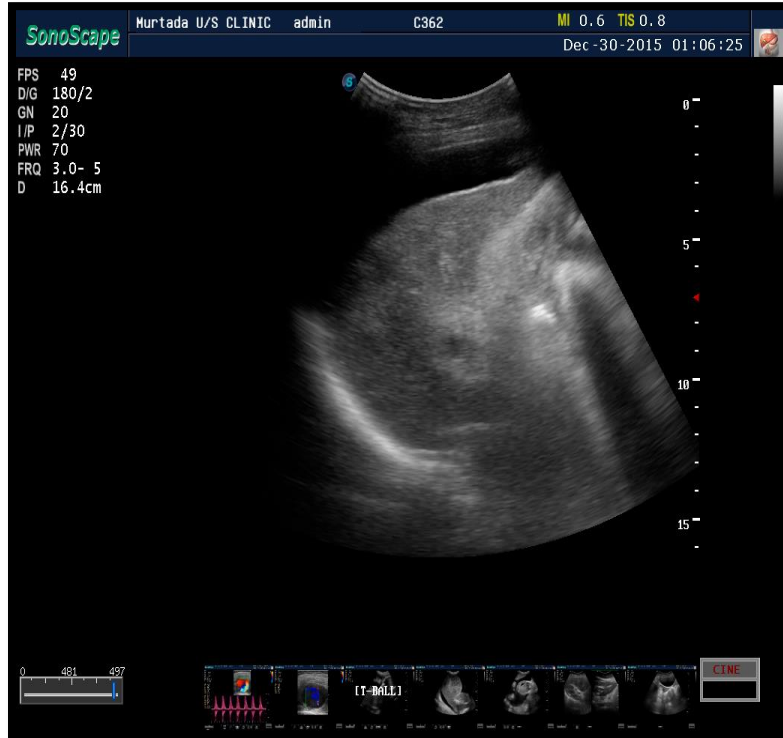


Fig (a-21): sonogram liver cirrhosis and mild ascites male 36years old due to schistosoma

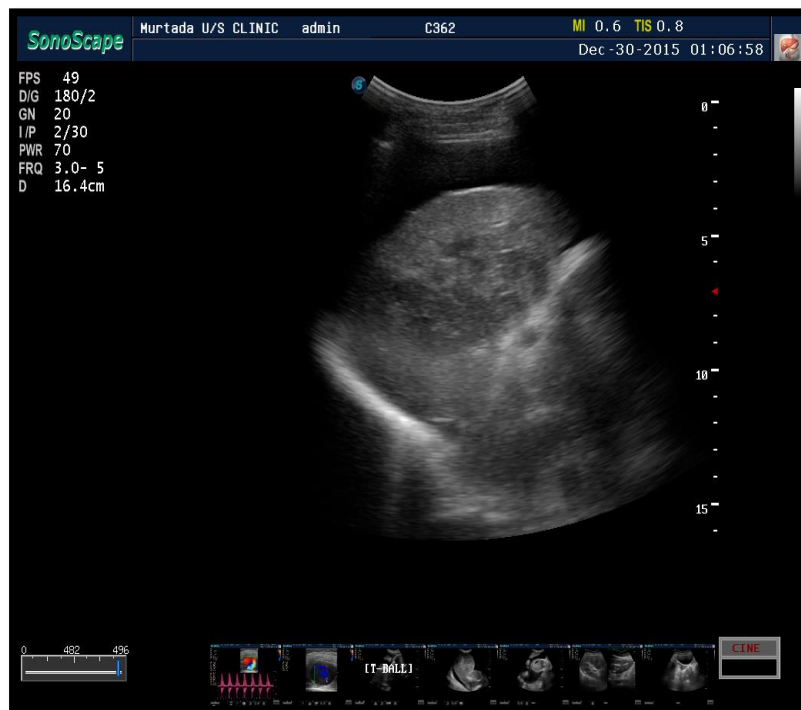


Fig (a-22): sonogram liver cirrhosis and ascites male 48years old due to schistosoma

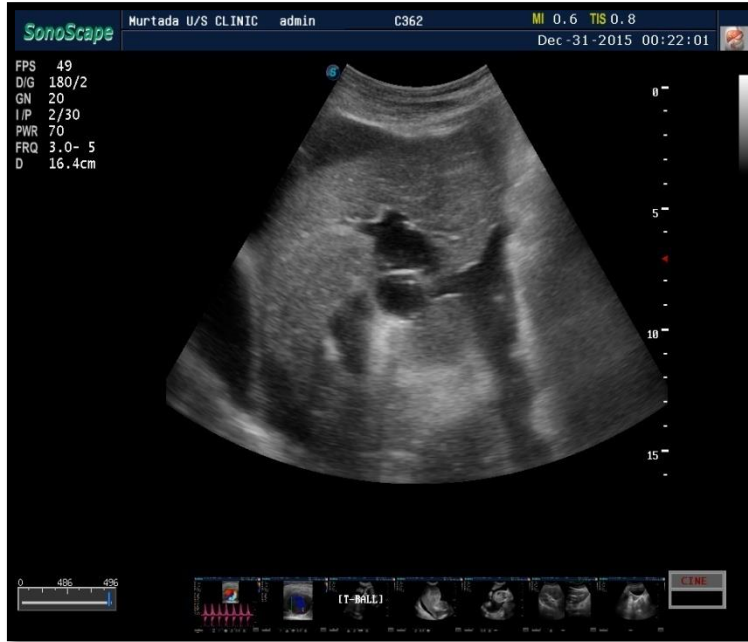

Fig (a-23): sonogram of liver with portal hypertension female 48 years old due exposed to schistosoma

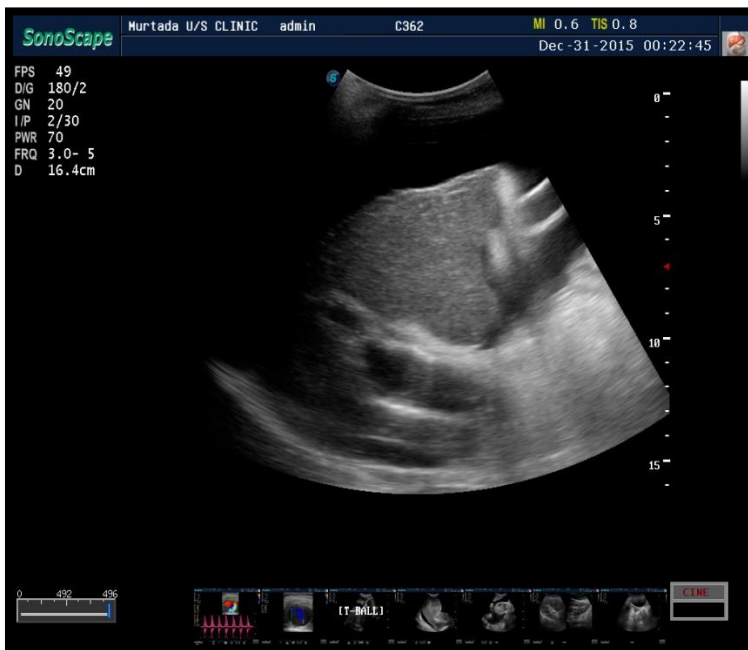

Fig (a-24): sonogram liver cirrhosis and mild ascites male 66years old due to schistosoma

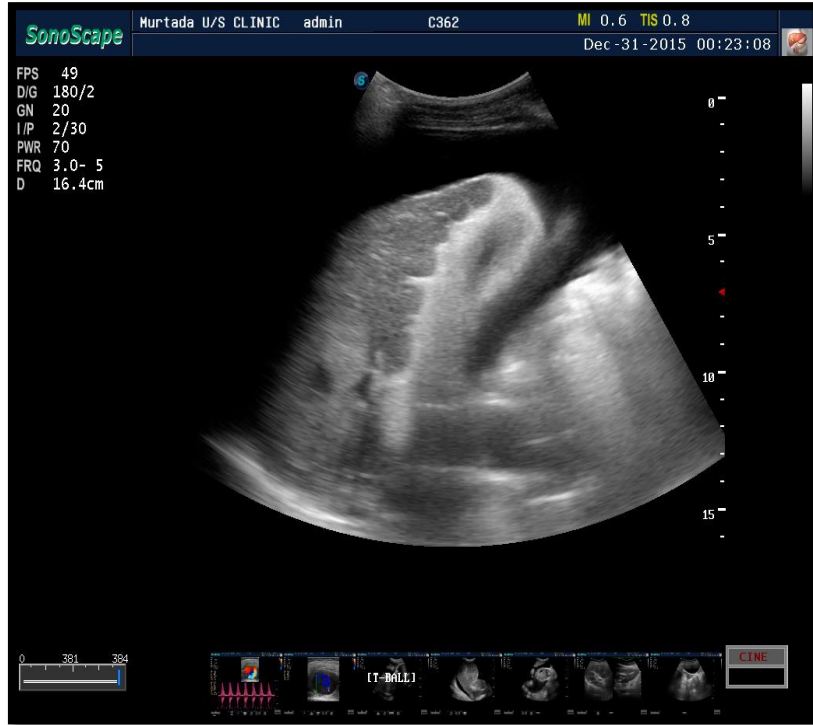

Fig (a-25): sonogram liver cirrhosis with ascites male 56 years old due to schistosoma

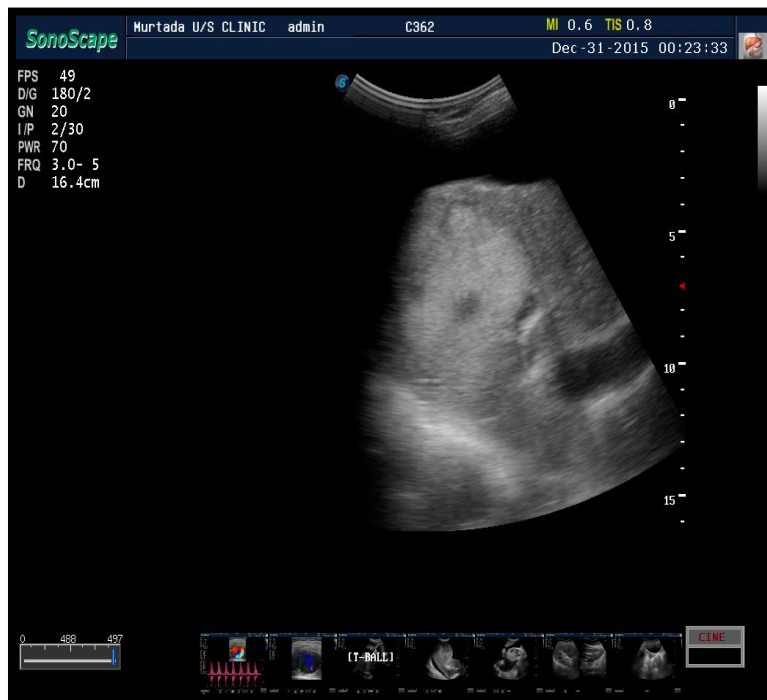

Fig (a-26): sonogram liver cirrhosis with ascites and portal hypertension male 50 years old due to schistosoma

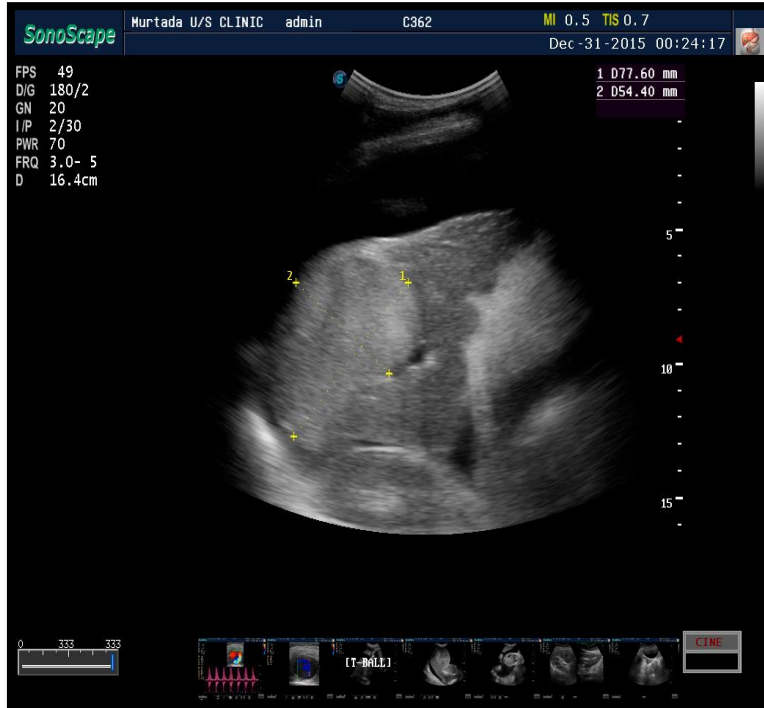


Fig (a-27): sonogram liver cirrhosis with ascites and focal nodule male 56 years old due to schistosoma

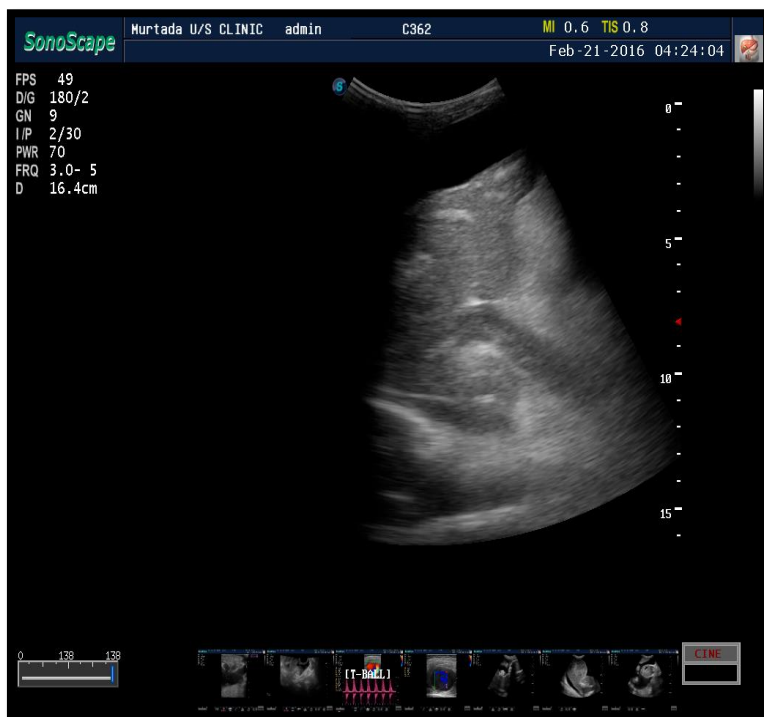


Fig (a-28): sonogram liver cirrhosis and mild ascites male 54years old due to schistosoma

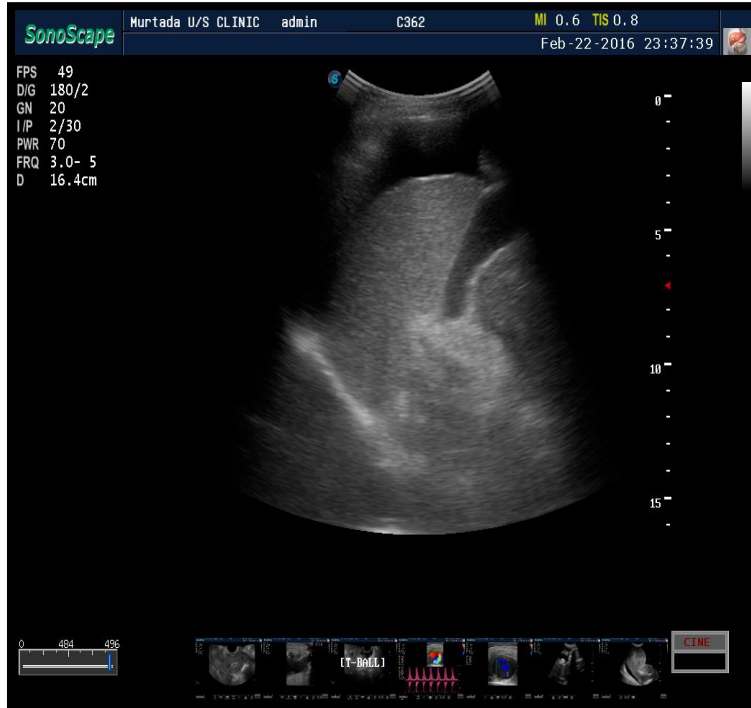


Fig (a-29): sonogram liver cirrhosis and mild ascites male 68 years old due to schistosoma

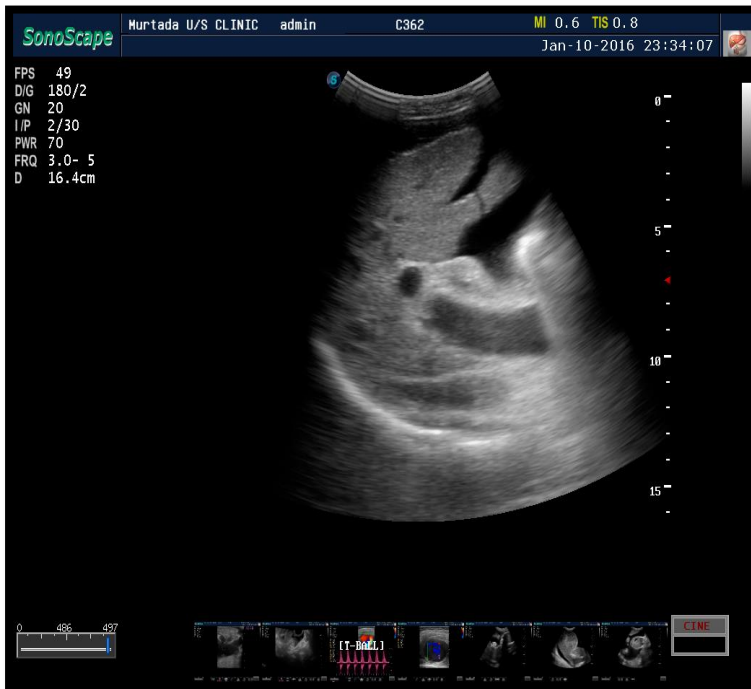

Fig (a-30): sonogram liver cirrhosis, ascites and portal hypertension male 58 years old due to schistosoma

(b) data sheet :

Sudan University
Ph.D Diagnostic Ultrasound
QUESTIONNAIRE

Data collection sheet:

ACKGROUND INFORMATION

1\ Gender ?

(A) Male .

(B) Female .

2\ Age ?

3\ Residence

4\ Married status ?

5\ Occupation ?

Technical adjustment of the ultrasound image :

Gain

Sonographic image of the liver :-

1\ (A) Liver size **(B) volume**

2\ Echo texture (A) Homogenous (B) Hetrogenous

3\ Echogenicity

(A) Normal . (B) Hypoechoic (C) Hyperechoic

(e) nodular (f) cirrhotic change

4\ Grading of liver cirrhosis ?

5\ Other associated findings

1-

2-

3-

4-

THANK YOU