

Appendices

Appendix (I): Data collection sheet

Study of Sickle Cell Disease Impact in Kidneys Morphology and Physiology using Ultrasonography

A	B	C	D	E	F	G	H	I	J	K	L	M	N	O	P	Q	R	S	T	U	V	
No.	Gender	Age	Hieght	Weight	BMI	Tripe	FH	Rt K legth	Rt K width	Rt K Thick	Rt K vol	RRA-RI	RRA-PI	Echo	Lt K legth	Lt K width	Lt K Thick	Lt K vol	LRA-RI	LRA-PI	Echo	

- BMI: Body mass index
- FH: Family history
- Rt K legth: Right kidney length
- Rt K width: Right kidney width
- Rt K Thick: Right kidney thickness
- Rt K vol: Right kidney volume
- RRA-RI: Right renal artery resistive index
- RRA-PI: Right renal artery pusatilty index
- Lt K legth: Left kidney length
- Lt K width: Left kidney width
- Lt K Thick: Left kidney thickness
- Lt K vol: Left kidney volume
- LRA-RI: Left renal artery resistive index
- LRA-PI: Left renal artery pusatilty index
- Echo: Echogenicity

Impact of Sickle Cell Disease in Renal Arteries Blood Flow Indices Using Ultrasonography

Mohamed Abdalla Eltahir^{1,4}, Mohamed Elfadil Mohamed Gar-elnabi¹,
Mohammed Ahmed Ali Omer^{1,3}, Osman Abdelgadir^{1,2}, Elsafi Ahmed Abdallah¹

¹College of Medical Radiologic Science, Sudan University of Science & Technology, Khartoum, Sudan

²Sudan Sickle Cell Anemia Center, Obaied, Sudan

³Department of Radiologic Technology, College of Applied Medical Science, Qassim University, Bursaidah, KSA

⁴Al-Ghad International Colleges for Applied Medical Sciences, Qassim, KSA

Email address:

mohamedsonar@gmail.com (M. A. Eltahir), mohamedelfadilmohamed@gmail.com (M. E. M. Gar-elnabi),

alsafi1000@hotmail.com (M. A. A. Omer), ma.omer@qu.edu.sa (O. Abdelgadir), abdelgadirosman@gmail.com (E. A. Abdallah)

To cite this article:

Mohamed Abdalla Eltahir, Mohamed Elfadil Mohamed Gar-elnabi, Mohammed Ahmed Ali Omer, Osman Abdelgadir, Elsafi Ahmed Abdallah. Impact of Sickle Cell Disease in Renal Arteries Blood Flow Indices Using Ultrasonography. *International Journal of Medical Imaging*. Vol. 5, No. 2, 2017, pp. 9-13. doi: 10.11648/j.ijmi.20170502.11

Received: February 21, 2017; Accepted: March 3, 2017; Published: March 15, 2017

Abstract: The aim of this study was to evaluate the impact of sickle cell diseases (SCD) on renal arteries blood flow indices by using of color Doppler ultrasonography (CDU) in addition to relationships with age and body mass index (BMI). The method adapted was an experimental study among a sample consists of 115 SCD patients and 100 as control group. CDU of the main renal and segmental arteries performed among all patients and controls. All the patients were scanned in stable state condition. The results analysis carried out by EXCELL software for the collected variables which revealed that: the patients showed higher resistivity index RI and pulsatility index PI than control subjects (for patients 0.8 & 1.5 and 0.7 & 1.4 for control group. The significant positive correlation between RI and age ($r = 0.194$, and $r = 0.061$) for patients and control group respectively in the right renal artery and as well the RI correlated proportionally with BMI ($r=0.53$) for patients and ($r=0.05$) for control group.

Keywords: Doppler, Sonography, Pulsatility, Resistivity, Sickle-Cell, Disease

The Sonographic Assessment of Kidneys in Patients with Sickle Cell Disease



Mohamed A Eltahir^{1,2}, Moawia Gameraddin^{1*}, Elsafi A Abdallah², Mahmoud S Babiker¹, Mohamed Elhaj³, Suliman Salih^{1,4} and Mohamed E M Gar-elnabi¹

¹Department of Diagnostic Radiological Technology, Taibah University, Saudi Arabia

²Faculty of Radiological Sciences, Sudan University, Sudan

³Faculty of Alghad, Almadinah, Kingdom of Saudi Arabia

⁴National Cancer Institute, University of Gezira, Sudan

Submission: January 09, 2017; Published: February 03, 2017

*Corresponding author: Moawia Bushra Gameraddin, Department of Diagnostic Radiological technology, faculty of Applied Medical Sciences, Taibah University, Almadinah, Kingdom of Saudi Arabia, Tel: 00966534821130; Email: m.bushra@yahoo.com

Abstract

Sickle cell disease is a hereditary disorder of hemoglobin affecting several abdominal organs and still remaining a health problem. The objective of this study is to assess the renal echogenicity and volume and ascertain the correlation with the duration of disease. Materials and methods: in a cross sectional study, 77 patients with sickle cell disease in West of Sudan were studied by ultrasound from the period of February to November 2016. The patients were scanned with 3.5 MHz probe; renal length, volume and echogenicity were assessed.

Results: The Sickle cell disease was common in female higher than male (42 vs. 35). The renal size and echogenicity were raised in association with sickle cell disease. The duration of the disease had significant impact on renal size, length and echogenicity, p-value = 0.00.

Conclusion: Renal size and echogenicity were raised in proportion to duration of sickle cell disease. The left kidney was more enlarged and hyperechoic than the right kidney. Early sonographic assessment of renal volume and echogenicity is useful for predicting renal diseases in patients with sickle cell diseases.

Keywords: Sonographic; Assessment; Kidneys; Sickle; cell; Disease

Abbreviations: SCD: Sickle Cell Disease; Rt: Right; Lt: Left; HS: Hemoglobin S

Introduction

Sickle cell disease (SCD) is a hereditary disorder caused by SCD and infarction, especially in renal medullae which causes

Appendix III: Ultrasound Images

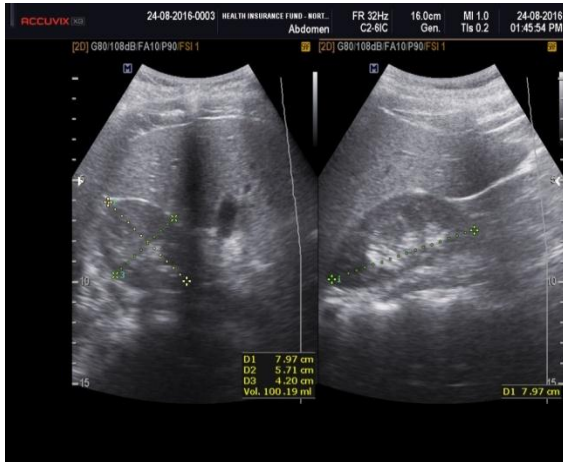


Image 1. Normal size and echogenicity of right kidney in 11 years old male patient with sickle cell disease

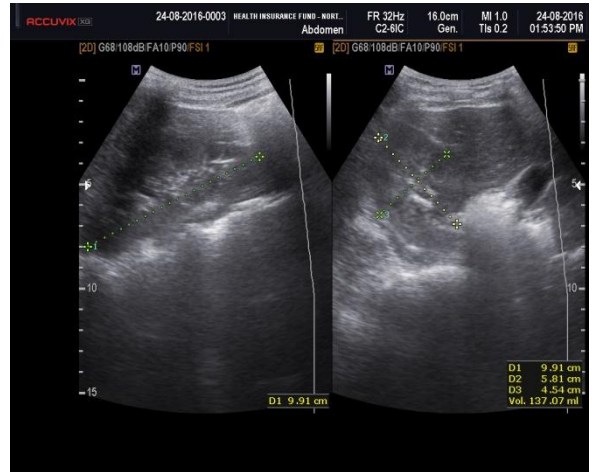


Image 2. 7 year old male patient with sickle cell disease shows increased size & echogenicity of the left kidney.

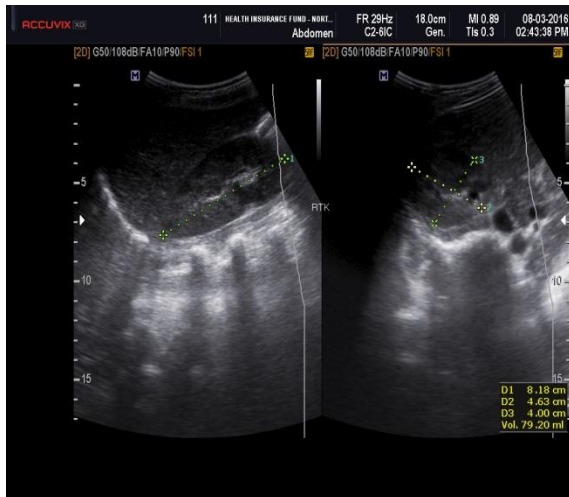


Image 3. 13 years old male patient with sickle cell disease shows normal size and echogenicity of the right kidney.

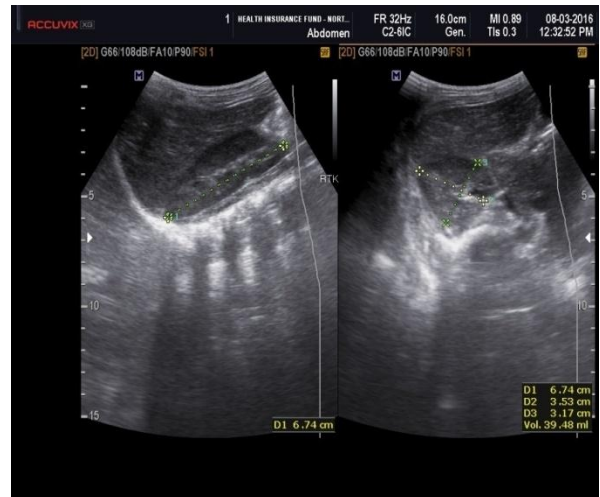


Image 4. 4 years old female with normal size and echogenicity of right kidney.

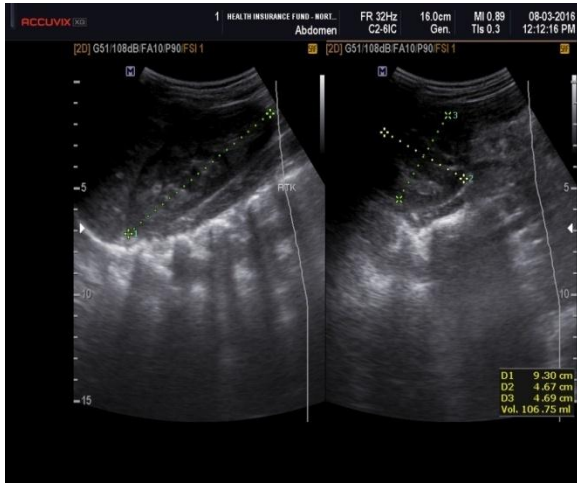


Image 5. 16 years old male patient with SCD shows slightly changes in the right kidney texture.

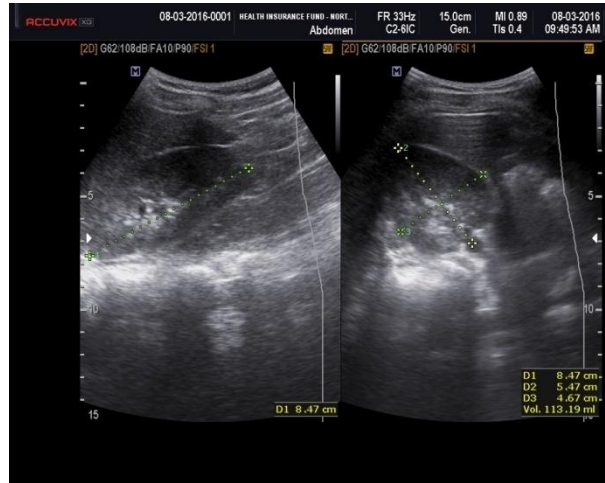


Image 6. 9 years old male patient with normal size & shape of the left kidney.

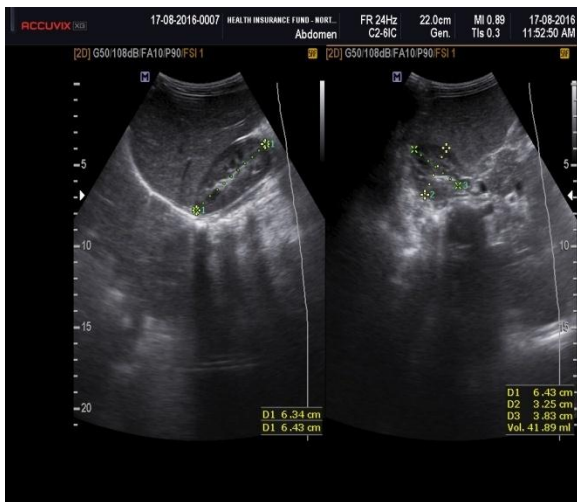


Image 7. 3 years old male patient with SCD shows slightly changes in the right kidney texture.

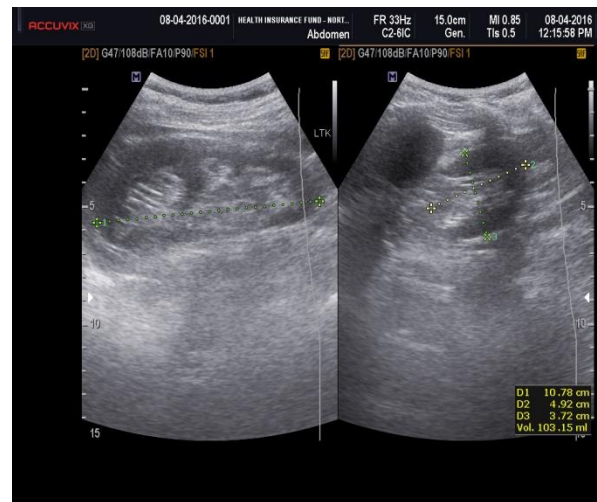


Image 8. 8 years old male patient with SCD shows enlarged left kidney with increased echogenicity.

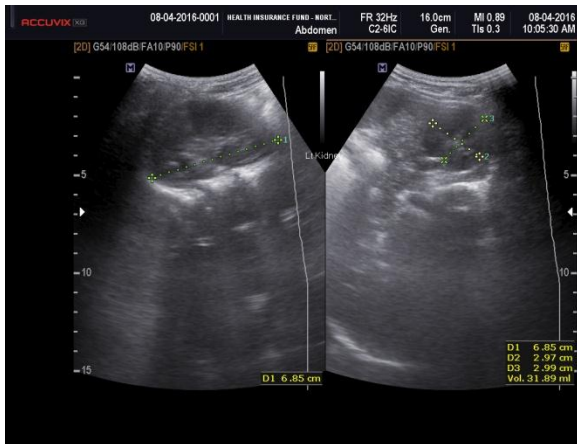

Image 9. 3 years old female patient with normal size & shape of the left kidney.

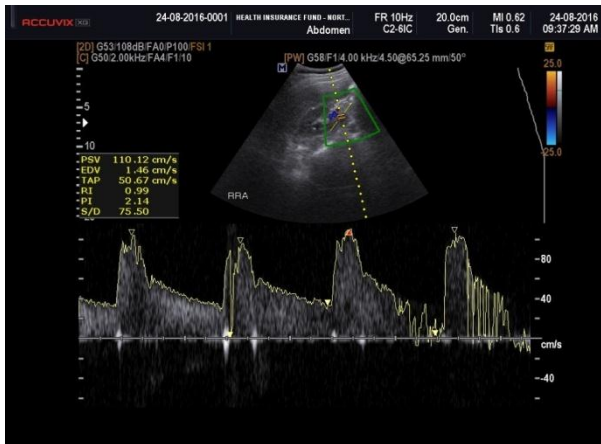

Image 10. 5 years old male patient with SCD shows high RI & PI of right renal artery.

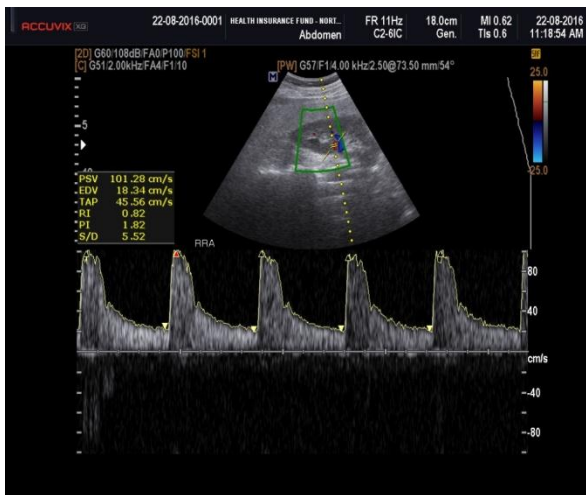


Image 11. 13 years old male patient with SCD shows normal RI & PI of right renal artery.

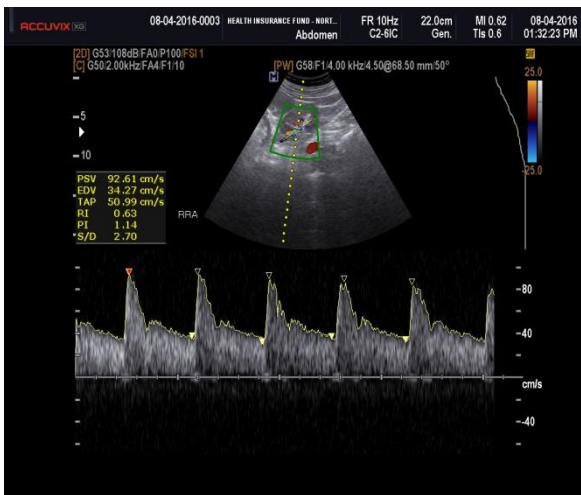


Image 12. 21 years old female patient shows normal RI & PI of right renal artery.

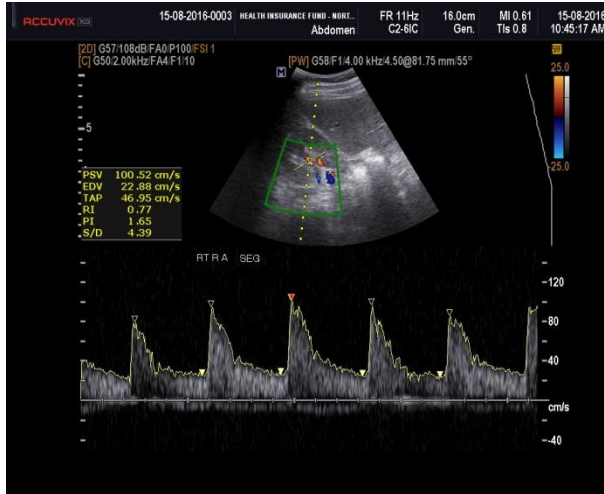


Image 13. 19 years old male patient with SCD shows normal RI & PI of right segmental artery.

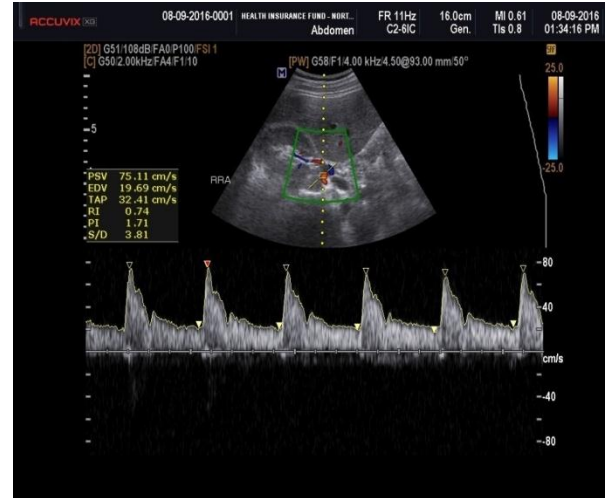


Image 14. 7 years old male patient with normal RI & PI of right renal artery.

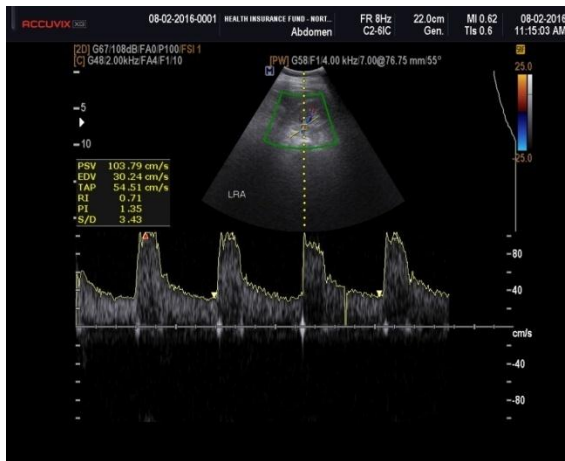


Image 15. 6 years old male patient shows normal RI & PI of left renal artery.

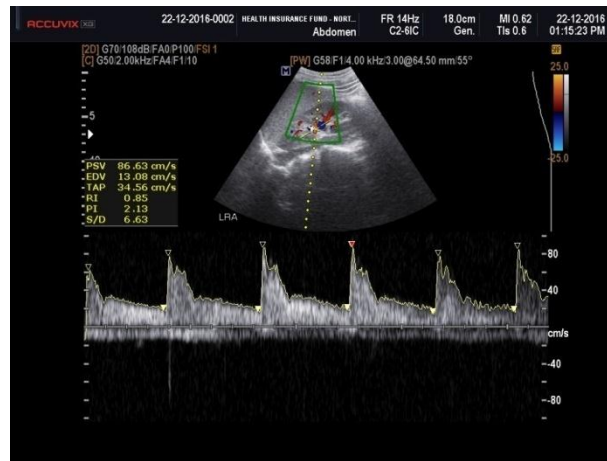

Image 16. 17 years old female patient with SCD shows high RI & PI of left renal artery.

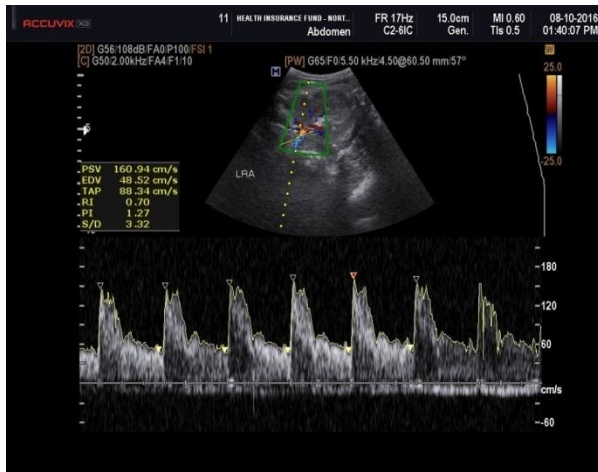


Image 17. 20 years old female patient shows normal RI & PI of left renal artery.

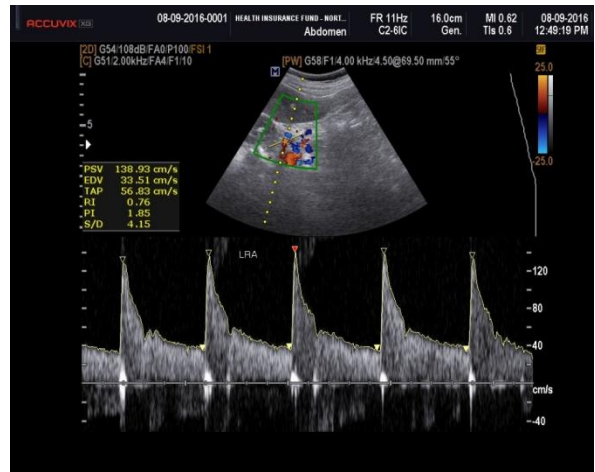


Image 18. 10 years old male patient shows normal RI & PI of left renal artery.

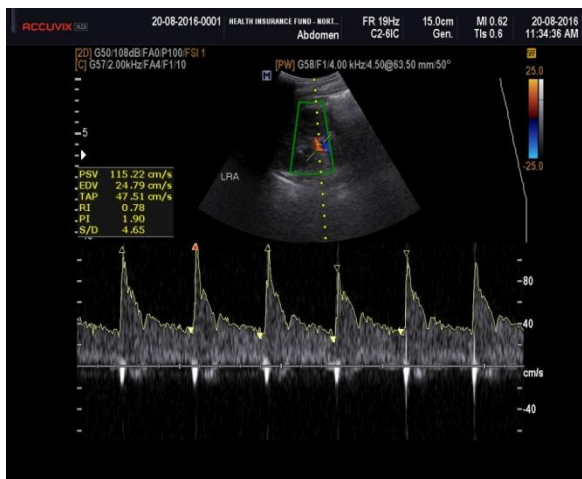


Image 19. 7 years old female patient with SCD shows normal RI & PI of left renal artery.

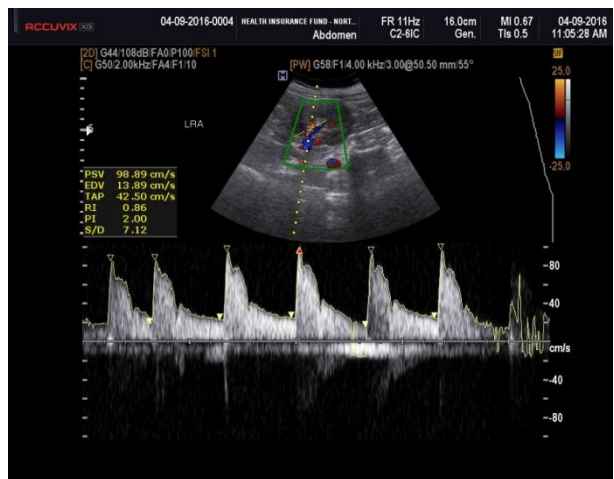


Image 20. 14 years old female patient with SCD shows high RI & PI of left renal artery.