



Sudan University of Sciences and Technology
College of Graduate Studies

**Measurement of Thyroid Volume for Normal Adult Sudanese
using Ultrasonography**

**قياس حجم الغدة الدرقية لدى السودانيين الراشدين باستخدام
الموجات فوق الصوتية**

*A thesis submitted for the Partial Fulfillment of Requirement of
M.Sc. Degree in Medical Diagnostic Ultrasound*

By

Bakhita Abbas Widalha Ahamed

Supervisor

Dr. Ikhlas Abdelaziz Hassan Mohamed

2017

الآية

قال تعالى:

(وَعَلَّمَكَ مَا لَمْ تَكُنْ تَعْلَمُ ۚ وَكَانَ فَضْلُ اللَّهِ عَلَيْكَ

عَظِيمًا)

صدق الله العظيم

سوره النساء آلايه 113

Dedication

This thesis is dedicated to my father, who taught me that the best kind of knowledge to have is that which is learned for its own sake. It is also dedicated to my mother, who taught me that even the largest task can be accomplished if it is done one step at a time. To my husband (MOHAMED) the source of my power and support. To my daughter (RAGHAD) the light of my way. I am also very grateful to my brother and my sister.

Acknowledgement

There are a number of people without whom this thesis might not have been written, and to whom I am greatly indebted

I wish to express my special thanks to **Dr. Ekhlas Abdul-Aziz** for his kind assistance, patient helpful, useful advices and continuous encourage, as well as to my closest friends who gave me the best of the knowledge they possess Also I would like to thank all teachers and all my colleagues .

Abstract

This study to measure the thyroid volume in normal adult Sudanese male and female in Khartoum in altamuze hospital .All the subjects were scanned for thyroid by measured thyroid volume on the affected subjects were evaluated by using (Alpinion-Ecube 7) ultrasound machine by 7.5 MHZ linear transducer from July to September 2016 . The study involved 53 subjects 31 of which female whereas 22were male aged (20-30) years .the data analysed using excel Microsoft office programme and SPSS .the volume of each lobe was calculated automatically in the machine by using ellipsoid formula (the volume=length ×width ×width× depth × 0.52) and the total thyroid volume obtained by adding the volume of the both lobes .The study was result the mean ages and ranges was 25.64±3.61 years old the overall mean volume ±SD ml of thyroid gland was 5.48±1.35ml the mean volume of RT lobe 2.89 ±0.75ml the mean volume of the LT lobe was 2.58 ±0.76ml the RT lobe is greater than the left lobe . the mean thyroid volume for males was 5.6±1.29 ml ,while for females was 5.4±1.40 ml the mean thyroid volume in male is greater than female .The ultrasound has proven as useful method for the assessment of the thyroid volume and it is safety and less expensive.

المستخلص

اجريت هذه الدراسة لقياس حجم الغدة الدرقية بواسطة الموجات فوق الصوتية في مستشفى التميز بالخرطوم باستخدام جهاز Al pinion - ecube7wit transducer. 7.5mhzlinear وقد شملت الدراسة (53) رجل وأمرأة , (31) منهم من النساء بنسبة (58%) و (22) من الذكور بنسبة (42%) وقد تراوحت أعمارهم بين (20 - 30 سنة) و ذلك في الفترة من يوليو 2016 حتي سبتمبر 2016. تم تحليل الحزم الإحصائية للعلوم الاجتماعية. البيانات باستخدام برنامج (spss)

تم قياس حجم الفص الأيمن والفص الأيسر للغدة الدرقية كل علي حدا عن طريق المعادلة (الطول × العرض × العمق × 0.52) داخل الجهاز و الحجم الكلي للغدة نتج باضافة حجم الفصين الأيمن و الأيسر.

و كانت نتيجة الدراسة أن متوسط الأعمار 61.3 ± 25.64 سنة و متوسط حجم الغدة الدرقية كاملة 5.48 ± 1.35 مل و متوسط حجم الفص الأيمن 2.89 ± 0.75 مل و متوسط حجم الفص الأيسر 2.58 ± 0.0 مل الفص الأيمن اكبر من الفص الأيسر . و متوسط حجم الغدة الدرقية الذكور 5.6 ± 1.29 مل و عند النساء 5.4 ± 1.40 مل متوسط حجم الغدة الدرقية عند الذكور اكبر من النساء .

يمكن اعتماد الموجات الصوتية كوسيلة تشخيصيه جيدة لقياس حجم الغدة الدرقية كما أنها امنه و رخيصه .

Table of Contents

الآية	I
Dedication	II
Acknowledgement	III
Abstract	IV
المستخلص	V
LIST OF TABLES	VIII
List of figures	IX
List of abbreviations	XI

Chapter one: Introduction

1.1:Introduction.....	1
1.2 Problem of the study:.....	1
1.3 Objective of the study:	2
1.3.1 General objective:	2
1.3.2 Specific objective:	2
1.4 Overview of the study:.....	2

Chapter two: Theoretical background and Literature review

2-1 Anatomy:	3
2-1-1 Embryological development:	6
2-1-2-1Feature description.....	8
2-1-1-2Thyroid epithelial cell	9
2-2 Physiology:	9
2-2-1T3 and T4 production and action:	10
2-2-2T3 and T4 regulation	12
2-3 Disorders.....	13
2-3-1Hyperthyroidism.....	14
2-3-3Initial hyperthyroidism followed by hypothyroidism:	16
2-3-4Congenital anomalies :.....	17
2-3-4Other disorders :.....	18

2-3-5cancers	18
2-5 previous studies:	21

Chapter Three: Materials and Methods

3.1 Materials	24
3.1.1 Patient population	24
3.1.2 Machine.....	24
3.2 Methods.....	24
3.2.1 Technique used:.....	24

Chapter Four: Result

Result	26
--------------	----

Chapter Five: Discussion' Conclusion and Recommendation

5.1 Discussion	37
5.2 Conclusions:.....	40
5.3 Recommendations :.....	41
References.....	42
Appendix.....	45

LIST OF TABLES

Table	Topic	Page
4-1	Minimum ,maximum ,mean and stander deviation of thyroid volume	26

List of figures

Fig	Figure	Page
2.1	normal thyroid gland	3
2.2	thyroid gland histology	8
2.3	thyroid gland as a part of endocrine system	9
3.1	Measurement of the volume of right lobe of thyroid gland	25
3.2	Measurement of volume of the left lobe of the thyroid gland	25
4.1	Frequency distribution of gender.	27
4.2	shows frequency of mean thyroid volume according to age group.	28
4.3	Frequency distribution of age.	29
4.4	Mean thyroid volume according to gender.	30
4.5	Mean volume of Rt lobe according to gender.	31
4.5	Mean volume of Lt lobe according to gender.	32
4.6	Mean volume of Lt lobe according to gender	32
4.7	scatter plot shows relationship between AP of the Rt lobe and Rt lobe volume.	33
4.8	scatter plot shows relationship between Rt lobe width and Rt lobe volume.	33
4.9	scatter plot shows relationship between Rt lobe length	34

	and Rt lobe volume.	
4.10	scatter plot shows relationship between AP of the Lt lobe and Lt lobe volume.	34
4.11	scatter plot shows relationship between Lt lobe width and Lt lobe volume.	35
4.12	scatter plot shows relationship between Lt lobe length and Lt lobe volume.	35
4.13	scatter plot shows relationship between Rt lobe volume and thyroid volume.	36
4.14	scatter plot shows relationship between Lt lobe volume and thyroid volume.	36

List of abbreviations34

BMI	Body Mass Index
BMR	Basal Metabolic Rate
CT	Computed Tomography
LFT	Left lobe
MRI	Magnetic Resonance Image
RT	lobe Right Lobe
T3	Triiodothyronine
T4	Thyroxin
TBG	Thyroid Binding Globulin
TRH	Thyrotropin Releasing Hormone
TSH	Throid Stimulating Hormone

Chapter one

1.1:Introduction

The thyroid glands a vital endocrine gland in our body which produce a hormone of the greatest importance for the proper growth and function of most of the tissues in the body it's the most common gland imaging by ultrasound especially in topical Africa where other modern imaging modalities as computerized tomography (CT) and magnetic resonance imaging (MRI) are may not be available or more expensive. While the leading anatomy texts describes the adult thyroid as 5 cm long 3 cm wide and 2 cm depth further review of literature shows thyroid volume varies in size with gender age and general nutrition, Estimate of the thyroid gland volume is generally concedes to be important in several pathologic situation such as iodine deficiency Goiter thyroids multi nodular goiter and others. So this study was done to establish the thyroid volume in normal adult Sudanese from 20_30 years old.(G.J .Romanes ,1993)

1.2 Problem of the study:

Thyroid volume can be affected by many variable including gender, age , ethnic group and other factor while there is no reference measure for such variations.

1.3 Objective of the study:

1.3.1 General objective:

The main objective of this study was to measure thyroid volume in Sudanese using ultrasonography.

1.3.2 Specific objective:

- To identify the thyroid volume in normal Sudanese by applying ellipsoid formula to bring the volume of each lobe and adding the results.
- To determine the total volume of thyroid gland.
- To assess the normal echogenecity of thyroid gland

1.4 Overview of the study:

This study will falls in to chapters5: chapter one deal with introduction, it represent the most common image modalities for thyroid, study problem, objectives of study, where chapter two contain the background material of the thesis especially it discusses the anatomy and the physiology of the thyroid, chapter three describe materials and methods used, where chapter four present the results and five deal with discussion , conclusion and recommendation.

Chapter two

Theoretical background and Literature review

2-1 Anatomy:

The thyroid gland or simply, the thyroid, in vertebrate anatomy, is one of the largest endocrine glands. The thyroid gland is found in the neck, below the thyroid cartilage (which forms the laryngeal prominence, or "Adam's apple"). The thyroid gland controls how quickly the body uses energy, makes proteins, and controls how sensitive the body is to other hormones.

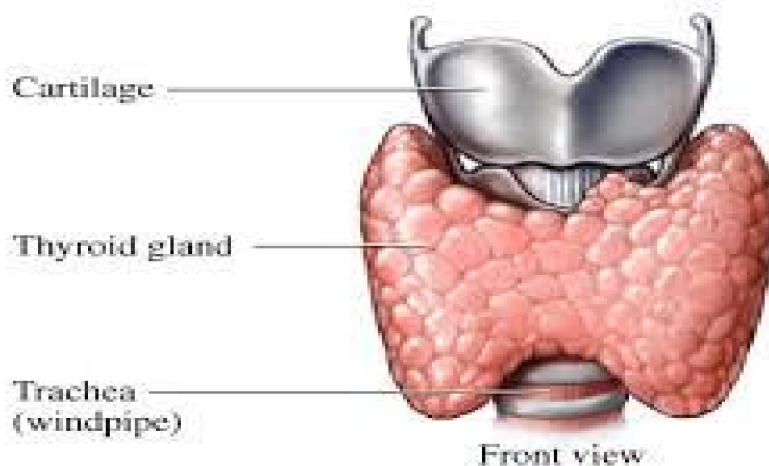


Figure2-1 normal thyroid gland

It participates in these processes by producing thyroid hormones, the principal ones being triiodothyronine (T3) and thyroxine which can sometimes be referred to as tetraiodothyronine (T4). These hormones regulate the growth and rate of function of many other systems in the body. T3 and T4 are synthesized from iodine and tyrosine. The thyroid also produces calcitonin, which plays a role in calcium homeostasis.

Hormonal output from the thyroid is regulated by thyroid-stimulating hormone (TSH) produced by the anterior pituitary, which itself is regulated by thyrotropin-releasing hormone (TRH) produced by the hypothalamus.(Boron, WF.; Boulapep and EL2012). The thyroid gets its name from the Greek adjective for "shield-shaped", due to the shape of the related thyroid cartilage. The thyroid gland is a butterfly-shaped organ and is composed of two cone-like lobes or wings, lobus Dexter (right lobe) and lobus sinister (left lobe), connected via the isthmus. The organ is situated on the anterior side of the neck, lying against and around the larynx and trachea, reaching posteriorly the esophagus and carotid sheath. It starts cranially at the oblique line on the thyroid cartilage (just below the laryngeal prominence, or 'Adam's Apple'), and extends inferiorly to approximately the fifth or sixth tracheal ring. It is difficult to demarcate the gland's upper and lower border with vertebral levels because it moves position in relation to these during swallowing.(Yalçin and Ozan. February 2006).

The thyroid gland is covered by a thin fibrous sheath, the capsula glandulae thyroidea, composed of an internal and external layer. The external layer is anteriorly continuous with the pretracheal fascia and posteriolaterally continuous with the carotid sheath. The gland is covered anteriorly with infrahyoid muscles and laterally with the sternocleidomastoid muscle also known as sternomastoid muscle. On the posterior side, the gland is fixed to

the cricoid and tracheal cartilage and cricopharyngeus muscle by a thickening of the fascia to form the posterior suspensory ligament of Berry. The thyroid gland's firm attachment to the underlying trachea is the reason behind its movement with swallowing. In variable extent, Lalouette's Pyramid, a pyramidal extension of the thyroid lobe, is present at the most anterior side of the lobe. In this region, the recurrent laryngeal nerve and the inferior thyroid artery pass next to or in the ligament and tubercle.(Dorland's 2012).

Between the two layers of the capsule and on the posterior side of the lobes, there are on each side two parathyroid glands. The thyroid isthmus is variable in presence and size, can change shape and size, and can encompass a cranially extending pyramid lobe (lobus pyramidalis or processus pyramidalis), remnant of the thyroglossal duct. The thyroid is one of the larger endocrine glands, weighing 2-3 grams in neonates and 18-60 grams in adults, and is increased in pregnancy.

In a healthy patient the gland is not visible yet can be palpated as a soft mass.

Examination of the thyroid gland is carried out by locating the thyroid cartilage and passing the fingers up and down, examining for abnormal masses and overall thyroid size. (Fehrenbach and Herring 2012).

Then, place one hand on each of the trachea and gently displace the thyroid tissue to the contralateral side of the neck for both sides while the other

hand manually palpates the displaced gland tissue; having the patient flex the neck slightly to the side when being palpated may help in this examination. Next, the two lobes of the gland should be compared for size and texture using visual inspection, as well as manual or bimanual palpation. Finally, ask the patient to swallow to check for mobility of the gland; many clinicians find that having the patient swallow water helps this part of the examination. In a healthy state, the gland is mobile when swallowing occurs due its facial encasement. Thus when the patient swallows, the gland moves superiorly, as does the whole larynx.

The thyroid is supplied with arterial blood from the superior thyroid artery, a branch of the external carotid artery, and the inferior thyroid artery, a branch of the thyrocervical trunk, and sometimes by the thyroid ima artery, branching directly from the subclavian artery. The venous blood is drained via superior thyroid veins, draining in the internal jugular vein, and via inferior thyroid veins, draining via the plexus thyroideus impar in the left brachiocephalic vein.

Lymphatic drainage passes frequently the lateral deep cervical lymph nodes and the pre- and paratracheal lymph nodes. The gland is supplied by parasympathetic nerve input from the superior laryngeal nerve and the recurrent laryngeal nerve.(Fehrenbach and Herring 2012).

2-1-1 Embryological development:

Floor of pharynx of embryo between 18 and 21 days In the fetus at 3–4

weeks of gestation, the thyroid gland appears as an epithelial proliferation in the floor of the pharynx at the base of the tongue between the tuberculum impar and the copula linguae at a point later indicated by the foramen cecum. The thyroid then descends in front of the pharyngeal gut as a bilobed diverticulum through the thyroglossal duct. Over the next few weeks, it migrates to the base of the neck, passing anterior to the hyoid bone. During migration, the thyroid remains connected to the tongue by a narrow canal, the hypoglossal duct. Thyrotropin-releasing hormone (TRH) and thyroid-stimulating hormone (TSH) start being secreted from the fetal hypothalamus and pituitary at 18-20 weeks of gestation, and fetal triiodothyronine (T3) remains low (less than 15 ng/dL) until 30 weeks of gestation, and increases to 50 ng/dL at term. Fetal self-sufficiency of thyroid hormones protects the fetus against e.g. brain development abnormalities caused by maternal hypothyroidism.(Zoeller April 2003).

However, preterm births can suffer neurodevelopmental disorders due to lack of maternal thyroid hormones due their own thyroid being insufficiently developed to meet their postnatal need. The portion of the thyroid containing the Para follicular C cells, those responsible for the production of calcitonin, are derived from the neural crest. This is first seen as the ultimobranchial body, which joins the primordial thyroid gland during its descent to its final location in the anterior neck. Aberrations in embryological development can cause various forms of thyroid dysgenesis.

2-1-2 Histology

At the microscopic level, there are three primary features of the thyroid :(first discovered by Websterson in (1664)Histological section through the thyroid of a horse. 1 follicles, 2 follicular epithelial cells, 3 endothelial cells.

2-1-2-1 Feature description

FolliclesThe thyroid is composed of spherical follicles that selectively absorb iodine (as iodide ions, I-) from the blood for production of thyroid hormones, and also for storage of iodine in thyroglobulin. Twenty-five percent of the body's iodide ions are in the thyroid gland. Inside the follicles, in a region called the follicular lumen, colloid serves as a reservoir of materials for thyroid hormone production and, to a lesser extent, acts as a reservoir for the hormones themselves. Colloid is rich in a protein called thyroglobulin.

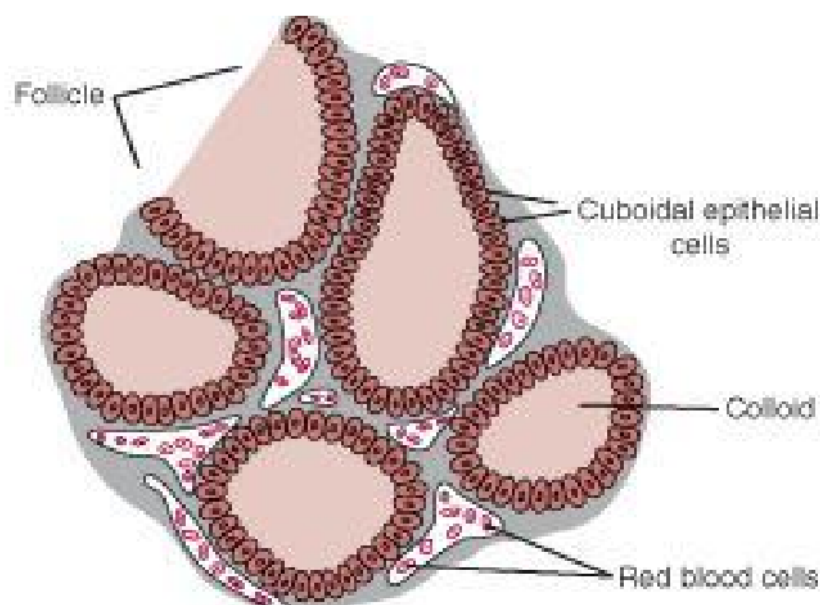


Figure 2-2 thyroid gland histology

2-1-1-2Thyroid epithelial cell

The follicles are surrounded by a single layer of thyroid epithelial cells, which secrete T3 and T4. When the gland is not secreting T3 and T4 (inactive), the epithelial cells range from low columnar to cuboidal cells. When active, the epithelial cells become tall columnar cells. Scattered among follicular cells and in spaces between the spherical follicles are another type of thyroid cell, Para follicular cells, which secrete calcitonin.

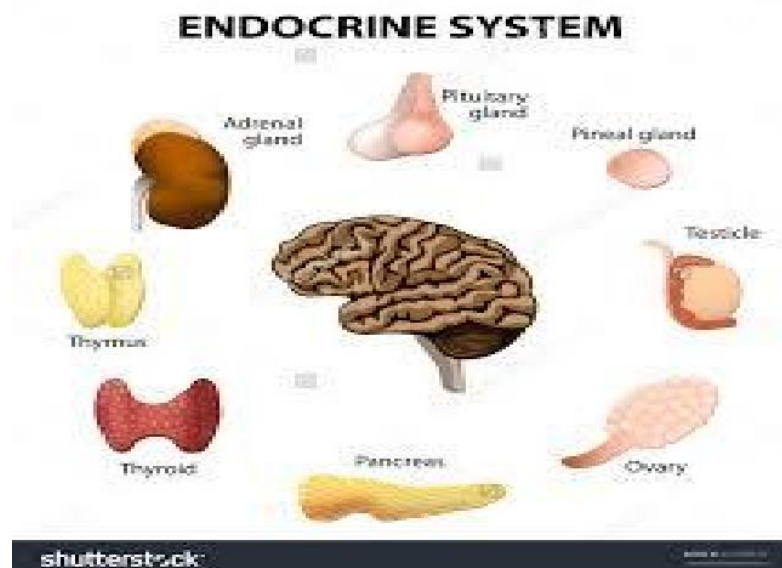


Figure 2-3 thyroid gland as a part of endocrine system

2-2 Physiology:

The primary function of the thyroid is production of the hormones T3, T4 and calcitonin. Up to 80% of the T4 is converted to T3 by organs such as the liver, kidney and spleen. T3 is several times more powerful than T4, which is largely a pro hormone, perhaps four or even ten times more active.(Nussey and Whitehead 2001).

2-2-1T3 and T4 production and action:

Synthesis of the thyroid hormones, as seen on an individual thyroid follicular cell:-

Thyroglobulin is synthesized in the rough endoplasmic reticulum and follows the secretory pathway to enter the colloid in the lumen of the thyroid follicle by exocytosis.- Meanwhile, a sodium-iodide (Na/I) symporter pumps iodide (I-) actively into the cell, which previously has crossed the endothelium by largely unknown mechanisms.- This iodide enters the follicular lumen from the cytoplasm by the transporter pendrin, in a purportedly passive manner.

- In the colloid, iodide (I-) is oxidized to iodine (I₀) by an enzyme called thyroid peroxidase.- Iodine (I₀) is very reactive and iodinates the thyroglobulin at tyrosylresidues in its protein chain (in total containing approximately 120 tyrosyl residues).

- In conjugation, adjacent tyrosyl residues are paired together.- The entire complex re-enters the follicular cell by endocytosis.- Proteolysis by various proteases liberates thyroxin and triiodothyronine molecules, which enters the blood by largely unknown mechanisms.

Thyroxin (T₄) is synthesized by the follicular cells from free tyrosine and on the tyrosine residues of the protein called thyroglobulin (TG). Iodine is captured with the "iodine trap" by the hydrogen peroxide generated by the

enzyme thyroid peroxidase (TPO) and linked to the 3' and 5' sites of the benzene ring of the tyrosine residues on Tg, and on free tyrosine. Upon stimulation by the thyroid-stimulating hormone (TSH), the follicular cells reabsorb Tg and cleave the iodinated tyrosine from Tg in lysosomes, forming T4 and T3 (in T3, one iodine atom is absent compared to T4), and releasing them into the blood. Deiodinase enzymes convert T4 to T3. Thyroid hormone secreted from the gland is about 80-90% T4 and about 10-20% T3. Cells of the developing brain are a major target for the thyroid hormones T3 and T4. Thyroid hormones play a particularly crucial role in brain maturation during fetal development. A transport protein that seems to be important for T4 transport across the blood–brain barrier (OATP1C1) has been identified. A second transport protein (MCT8) is important for T3 transport across brain cell membranes.

Non-genomic actions of T4 are those that are not initiated by liganding of the hormone to intranuclear thyroid receptor. These may begin at the plasma membrane or within cytoplasm. Plasma membrane-initiated actions begin at a receptor on the integrin α V β 3 that activates ERK1/2. This binding culminates in local membrane actions on ion transport systems such as the Na(+)/H(+) exchanger or complex cellular events including cell proliferation. These integrins are concentrated on cells of the vasculature and on some types of tumor cells, which in part explains the proangiogenic effects of iodothyronines and proliferative

actions of thyroid hormone on some cancers including gliomas. T4 also acts on the mitochondrial genome via imported isoforms of nuclear thyroid receptors to affect several mitochondrial transcription factors. Regulation of actin polymerization by T4 is critical to cell migration in neurons and glial cells and is important to brain development T3 can activate phosphatidylinositol 3-kinase by a mechanism that may be cytoplasmic in origin or may begin at integrin alpha V beta3.

In the blood, T4 and T3 are partially bound to thyroxin-binding globulin (TBG), transthyretin, and albumin. Only a very small fraction of the circulating hormone is free (unbound) - T4 0.03% and T3 0.3%. Only the free fraction has hormonal activity.

As with the steroid hormones and retinoic acid, thyroid hormones cross the cell membrane and bind to intracellular receptors ($\alpha 1$, $\alpha 2$, $\beta 1$ and $\beta 2$), which act alone, in pairs or together with the retinoid X-receptor as transcription factors to modulate DNA transcription.(Nussey and Whitehead 2001).

2-2-2T3 and T4 regulation

The production of thyroxin and triiodothyronine is regulated by thyroid-stimulating hormone (TSH), released by the anterior pituitary. The thyroid and thyrotropes form a negative feedback loop: TSH production is suppressed when the T4 levels are high.[19]

The TSH production itself is modulated by thyrotropin-releasing hormone

(TRH), which is produced by the hypothalamus and secreted at an increased rate in situations such as cold exposure (to stimulate thermogenesis). TSH production is blunted by somatostatin (SRIH), rising levels of glucocorticoids and sex hormones (estrogen and testosterone), and excessively high blood iodide concentration.

An additional hormone produced by the thyroid contributes to the regulation of blood calcium levels. Para follicular cells produce calcitonin in response to hyperkalemia.

Calcitonin stimulates movement of calcium into bone, in opposition to the effects of parathyroid hormone (PTH). However, calcitonin seems far less essential than PTH, as calcium metabolism remains clinically normal after removal of the thyroid (thyroidectomy), but not the parathyroid.(Nussey and Whitehead 2001).

2-3 Disorders

Thyroid disorders include

- hyperthyroidism (abnormally increased activity),
- hypothyroidism (abnormally decreased activity) and
- Thyroid nodules, which are generally benign thyroid neoplasms, but may be thyroid cancers.

All these disorders may give rise to goiter, that is, an enlarged thyroid.

2-3-1Hyperthyroidism

Hyperthyroidism, or overactive thyroid, is the overproduction of the thyroid hormones T3 and T4, and is most commonly caused by the development of Graves' disease, human autoimmune disease in which antibodies are produced which stimulate the thyroid to secrete excessive quantities of thyroid hormones. The disease can result in the formation of a toxic goiter as a result of thyroid growth in response to a lack of negative feedback mechanisms. It presents with symptoms such as a thyroid goiter, protruding eyes (exophthalmos), palpitations, excess sweating, diarrhea, weight loss, muscle weakness and unusual sensitivity to heat. The appetite is often increased.

Beta blockers are used to decrease symptoms of hyperthyroidism such as increased heart rate, tremors, anxiety and heart palpitations, and anti-thyroid drugs are used to decrease the production of thyroid hormones, in particular, in the case of Graves' disease. These medications take several months to take full effect and have sideeffects such as skin rash or a drop in white blood cell count, which decreases the ability of the body to fight off infections. These drugs involve frequent dosing (often one pill every 8 hours) and often require frequent doctor visits and blood tests to monitor the treatment, and may sometimes lose effectiveness over time. Due to the side-effects and inconvenience of such drug regimens, some patients choose to undergo radioactive iodine-131 treatment. Radioactive iodine is

administered in order to destroy a portion of or the entire thyroid gland, since the radioactive iodine is selectively taken up by the gland and gradually destroys the cells of the gland. Alternatively, the gland may be partially or entirely removed surgically, though iodine treatment is usually preferred since the surgery is invasive and carries a risk of damage to the parathyroid glands or the nerves controlling the vocal cords. If the entire thyroid gland is removed, hypothyroidism results.(Siegenthaler, W 2007)

2-3-2Hypothyroidism

Hypothyroidism is the underproduction of the thyroid hormones T3 and T4.

Hypothyroid disorders may occur as a result of

- Congenital thyroid abnormalities (Thyroid deficiency at birth. See congenital hypothyroidism),
- autoimmune disorders such as Hashimoto's thyroiditis,
- iodine deficiency (more likely in poorer countries) or
- The removal of the thyroid following surgery to treat severe hyperthyroidism and/or thyroid cancer.

Typical symptoms are abnormal weight gain, tiredness, baldness, cold intolerance, and bradycardia. Hypothyroidism is treated with hormone replacement therapy, such as levothyroxine, which is typically required for the rest of the patient's life. Thyroid hormone treatment is given under the care of a physician and may take a few weeks to become effective.

Negative feedback mechanisms result in growth of the thyroid gland when

thyroid hormones are being produced in sufficiently low quantities, as a means of increasing the thyroid output; however, where hypothyroidism is caused by iodine insufficiency, the thyroid is unable to produce T3 and T4 and as a result, the thyroid may continue to grow to form a non-toxic goiter. It is termed non-toxic as it does not produce toxic quantities of thyroid hormones, despite its size. Thyroid Disorders Information (MedicineNet. Retrieved on 2010-02-07)

2-3-3 Initial hyperthyroidism followed by hypothyroidism:

This is the overproduction of T3 and T4 followed by the underproduction of T3 and T4. There are two types: Hashimoto's thyroiditis and postpartum thyroiditis. Hashimoto's thyroiditis or Hashimoto's Disease is an autoimmune disorder whereby the body's own immune system reacts with the thyroid tissues in an attempt to destroy it. At the beginning, the gland may be overactive, and then becomes underactive as the gland is damaged resulting in too little thyroid hormone production or hypothyroidism. Some patients may experience "swings" in hormone levels that can progress rapidly from hyper-to-hypothyroid (sometimes mistaken as severe mood swings, or even being bipolar, before the proper clinical diagnosis is made). Some patients may experience these "swings" over a longer period of time, over days or weeks or even months. Hashimoto's is more common in females than males, usually appearing after the age of 30, and tends to run in families meaning it can be seen as a genetic disease. Also more common

in individuals with Hashimoto's Thyroiditis are type 1 diabetes and celiac disease. Most thyroid nodules do not cause any symptoms, and most are discovered on an incidental examination. Doctors usually perform a needle aspiration biopsy of the thyroid to determine the status of the nodules. If the nodule is found to be noncancerous, no other treatment is required. If the nodule is suspicious then surgery is recommended.(Treatment for Thyroid disease Retrieved on 2010-02-07).

2-3-4Congenital anomalies :

A persistent thyroglossal duct or cyst is the most common clinically significant congenital anomaly of the thyroid gland. A persistent sinus tract may remain as a vestigial remnant of the tubular development of the thyroid gland. Parts of this tube may be obliterated, leaving small segments to form cysts. These occur at any age and might not become evident until adult life. Mucinous, clear secretions may collect within these cysts to form either spherical masses or fusiform swellings, rarely larger than 2 to 3 cm in diameter. These are present in the midline of the neck anterior to the trachea. Segments of the duct and cysts that occur high in the neck are lined by stratified squamous epithelium, which is essentially identical to that covering the posterior portion of the tongue in the region of the foremen cecum. The anomalies that occur in the lower neck more proximal to the thyroid gland are lined by epithelium resembling the thyroidal acinar epithelium. Characteristically, next to the lining epithelium, there is an

intense lymphocytic infiltrate. Superimposed infection may convert these lesions into abscess cavities, and rarely, give rise to cancers.

2-3-4Other disorders :

Limited research shows that seasonal allergies may trigger episodes of hypo- or hyperthyroidism.

An ectopic thyroid is an entire or parts of the thyroid located in another part of the body than what is the usual case. Yamamoto et al (February 1988).

Some rapid-cycling versions of bipolar disorder seem to have a complex relationship with thyroid dysfunction; however the specifics of the relationship are poorly understood. (Melton, Sarah 2013)

2-3-5cancers

In most cases, thyroid cancer presents as a painless mass in the neck. It is very unusual for thyroid cancers to present with symptoms, unless they have been neglected. One may be able to feel a hard nodule in the neck. Diagnosis is made using a needle biopsy and various radiological studies. (Sharpe & Dohme 2010)

2-3-6Non-cancerous nodules

Many individuals may find the presence of thyroid nodules in the neck. The majority of these thyroid nodules are benign (non-cancerous). The presence of a thyroid nodule does not mean that one has thyroid disease. Most are discovered on an incidental examination. Doctors usually perform a needle aspiration biopsy of the thyroid to determine the status of

the nodules. If the nodule is found to be non-cancerous, no other treatment is required. If the nodule is suspicious then surgery is recommended.

2-4 Significance of iodine:

In areas of the world where iodine is lacking in the diet, the thyroid gland can become considerably enlarged, a condition called endemic goiter. Pregnant women on a diet that is severely deficient of iodine can give birth to infants with thyroid hormone deficiency (congenital hypothyroidism), manifesting in problems of physical growth and development as well as brain development (a condition referred to as endemic cretinism). In many developed countries, newborns are routinely tested for congenital hypothyroidism as part of newborn screening. Children with congenital hypothyroidism are treated supplementally with levothyroxine, which facilitates normal growth and development. Thyroxin is critical to the regulation of metabolism and growth throughout the animal kingdom. Among amphibians, for example, administering a thyroid-blocking agent such as propylthiouracil (PTU) can prevent tadpoles from metamorphosing into frogs; in contrast, administering thyroxin will trigger metamorphosis. In amphibian metamorphosis, thyroxin and iodine also exert a well-studied experimental model of apoptosis on the cells of gills, tail, and fins of tadpoles. Iodine, via iodolipids, has favored the evolution of terrestrial animal species and has likely played a crucial role in the evolution of the human brain. Iodine (and T4) trigger the amphibian metamorphosis that

transforms the vegetarian aquatic tadpole into a carnivorous terrestrial adult frog, with better neurological, visuospatial, olfactory and cognitive abilities for hunting, as seen in other predatory animals. A similar phenomenon happens in the neotenic amphibian salamanders, which, without introducing iodine, don't transform into terrestrial adults, and live and reproduce in the larval form of aquatic axolotl. Because the thyroid concentrates iodine, it also concentrates the various radioactive isotopes of iodine produced by nuclear fission. In the event of large accidental releases of such material into the environment, the uptake of radioactive iodine isotopes by the thyroid can, in theory, be blocked by saturating the uptake mechanism with a large surplus of non-radioactive iodine, taken in the form of potassium iodide tablets. One consequence of the Chernobyl disaster was an increase in thyroid cancers in children in the years following the accident. The use of iodized salt is an efficient way to add iodine to the diet. It has eliminated endemic cretinism in most developed countries, and some governments have made the iodination of flour, cooking oil, and salt mandatory. Potassium iodide and sodium iodide are typically used forms of supplemental iodine. As with most substances, either too much or too little can cause problems. Recent studies on some populations are showing that excess iodine intake could cause an increased prevalence of autoimmune thyroid disease, resulting in permanent hypothyroidism.(Patrick June 2008)

2-5 previous studies:

Wang Hei (1476) anatomically described the thyroid gland and recommended that the treatment of goiter should be dried thyroid. Paracelsus, some fifty years later, attributed goiter to mineral impurities in the water.

Thomas Wharton (1656) named the gland the thyroid, meaning shield, as its shape resembled the shields commonly used in Ancient Greece. Theodor Kocher (1909) from Switzerland won the Nobel Prize in Medicine "for his work on the physiology, pathology and surgery of the thyroid gland". Yousef et al (2010) established a local reference of thyroid volume in Sudanese normal subjects using ultrasound. A total of 103 healthy subjects were studied, 28 (27.18%) females and 75 (72.82%) males. Thyroid volume was estimated using ellipsoid formula. The mean age and range of the subjects was 21.8 (19–29) years; the mean body mass index (BMI) was 22.3 (16.46–26.07) kg/m². The overall mean volume \pm SD volume of the thyroid gland for both lobes in all the patients studied was 6.44 ± 2.44 mL. The mean volume for both lobes in females and males were 5.78 ± 1.96 mL and 6.69 ± 2.56 mL, respectively. The males' thyroid volume was greater than the females'. The mean volume of the right and left lobes of the thyroid gland in males and females were 3.38 ± 1.37 mL and 3.09 ± 1.24 mL, respectively. The right thyroid lobe volume was greater than the left Ahidjo, et al. (2005) determined the normal thyroid

volume using ultrasound in Maiduguri, North-Eastern Nigeria. One hundred and forty three subjects were studied consisting of 72 (50.30%) females and 71 (49.70%) males. The mean age of the subjects was 38.60 ± 13.10 years. The overall mean volume of the thyroid gland for both lobes in all the patients studied was $8.55\text{cm}^3 \pm 1.82$. The mean volume for both lobes in females and males were 7.58cm^3 and 9.72cm^3 respectively. The males thyroid volume was higher than the females ($p = 0.000$). (The mean volume of the right and left lobes of the thyroid gland in males and females were 4.48cm^3 and 4.07cm^3 respectively. The right thyroid lobe volume was higher than the left ($p = 0.000$).

Schlögl S., Werner E., Lassmann M., (2005) performed a study with a commercially available three-dimensional (3-D) system Freescan added to a conventional ultrasound scanner compares the accuracy of conventional thyroid volumetry to several methods of 3-D volume determination. In vitro measurements were performed on thyroid phantoms with known volumes. The standard deviation of the normalized differences was 8.0% (3-D segmentation) and 10.5% (conventional). For the accuracy of volume determination in human thyroids we performed a postmortem study. The thyroid volume was calculated conventionally by the ellipsoid model and by two 3-D methods (segmentation and the newly developed multiplanar volume approximation). The reference volume was determined after resection by submersion. The standard

deviation of the normalized differences was 26.9% for the conventional method, 9.7% for 3-D segmentation and 11.5% for the multiplanar volume approximation.

Marchie et al (2012) stated that: The US thyroid gland volume in school-aged children in Benin City from this study ranges between 1.17 cm³ and 7.19 cm³ , mean volume range of 1.76-4.95 cm³ , median volume range of 1.73-4.73 cm³ , and range of standard deviation from 0.39 cm³ to 1.49 cm³ . The average mean thyroid volume is 2.32 cm³ with the following average dimensions; anteroposterior right lobe =1.06 cm, mediolateral right lobe = 1.01 cm and craniocaudal right lobe = 2.34 cm, and anteroposterior left lobe = 1.01 cm, mediolateral left lobe = 1.04 cm and craniocaudal left lobe = 2.41 cm for both boys and girls respectively,...

Chapter Three

Materials and Methods

This study was done in Altamuze hospital in Khartoum Sudan over three month

3.1 Materials

3.1.1 Patient population

53 healthy adults Sudanese"exclude subjects with anterior neck swelling or clinical evidence of thyroid disease also exclude age above 40years

3.1.2 Machine

Alpinion-Ecube7 with 7.5MHZ linear transducer

3.2 Methods

3.2.1 Technique used:

All individuals were examined in the supine position with the neck hyper extended. Using linear 7.5MHZ probe in Alpinion- Ecube7 machine, transverse and longitudinal section of both lobes of the thyroid gland were scanned. Measurement of the maximum length of the lobe from the sagittal images were recorded. The maximum transverse diameter (breadth) and the maximum depth of each lobe were recorded from the transverse images. To ensure that the probe was in the same position each time, anatomical landmarks were used. For measurement of thyroid length, the probe was

placed longitudinal in the midline of the neck to obtain sagittal views of the larynx; the probe was then moved obliquely to find the maximum length of the thyroid gland, just medial to the carotid vessels. The transverse views were obtained by using the trachea and carotid vessels as landmarks (figure (3.1)(3.2))

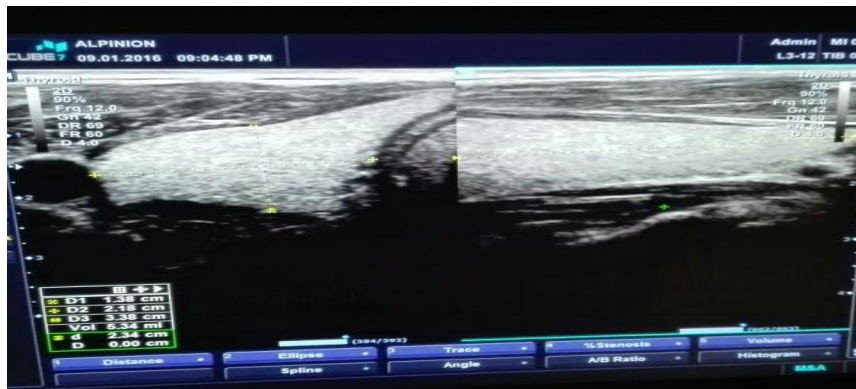

Figure (3-1) Measurement of the volume of right lobe of thyroid gland

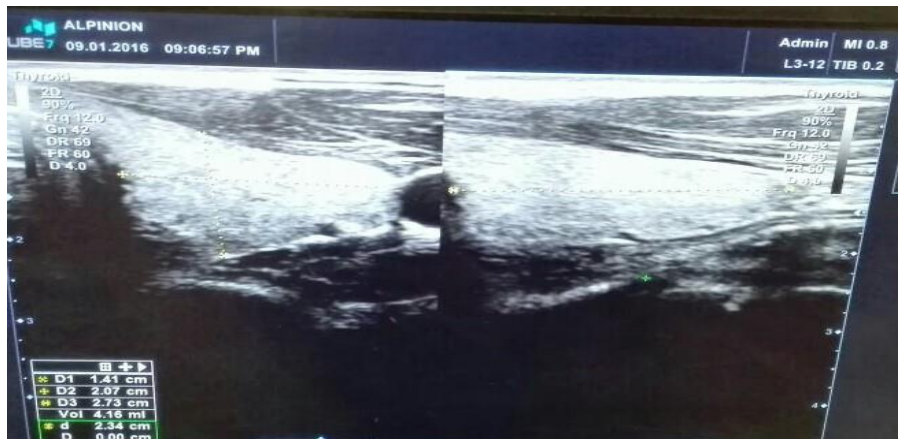

Figure 3-2 Measurement of volume of the left lobe of the thyroid gland

The volume of each lobe was calculated automatically by the machine using the formula for ellipsoid, where thyroid volume = length × breadth × depth × α . total thyroid volume was obtained by adding the volume of both the lobes. Volume of isthmus was not included in the total

Chapter Four

Result

Table (4-1) The mean ,minimum, maximum, and standard deviation of the variables.

	N	Minimum	Maximum	Mean	Std. Deviation
Age	53	20	30	25.64	3.617
AP of Rt Lobe	53	.83	1.80	1.2015	.19188
Width of Rt Lobe	53	1.08	2.20	1.4243	.25839
length of Rt Lobe	53	2.50	3.90	3.2553	.30003
Volume of Rt Lobe	53	1.5	4.6	2.894	.7523
AP of Lt Lobe	53	.80	1.60	1.0753	.20174
Width of Lt Lobe	53	1.00	2.10	1.4668	.24125
Lengt of Lt Lobe	53	1.30	3.74	3.0636	.38949
Volume of Lt Lobe	53	1.4	4.9	2.587	.7659
Thyroid Volume	53	3.1	9.0	5.483	1.3563
Valid N (listwise)	53				

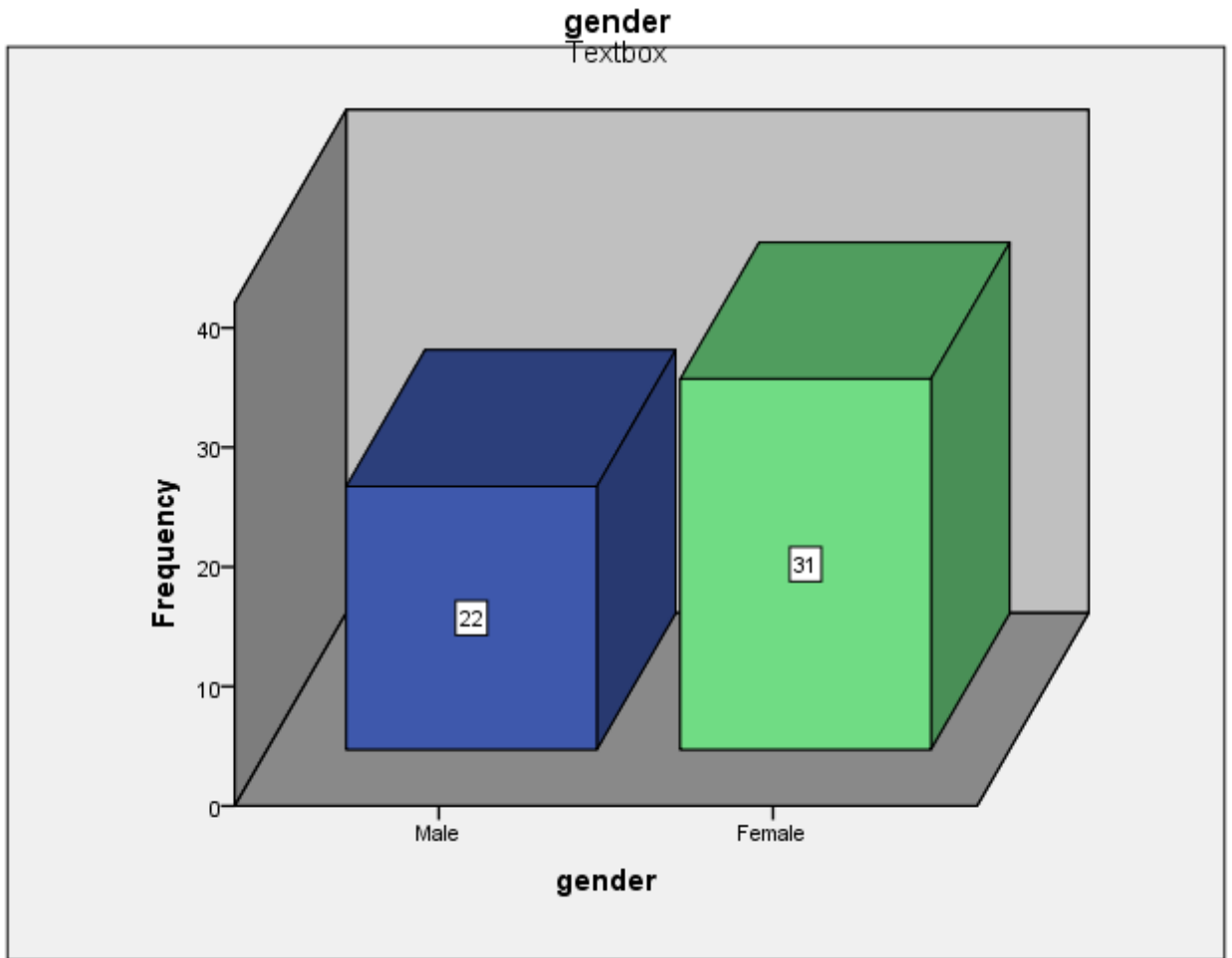


Figure (4.1) Frequency distribution of gender.

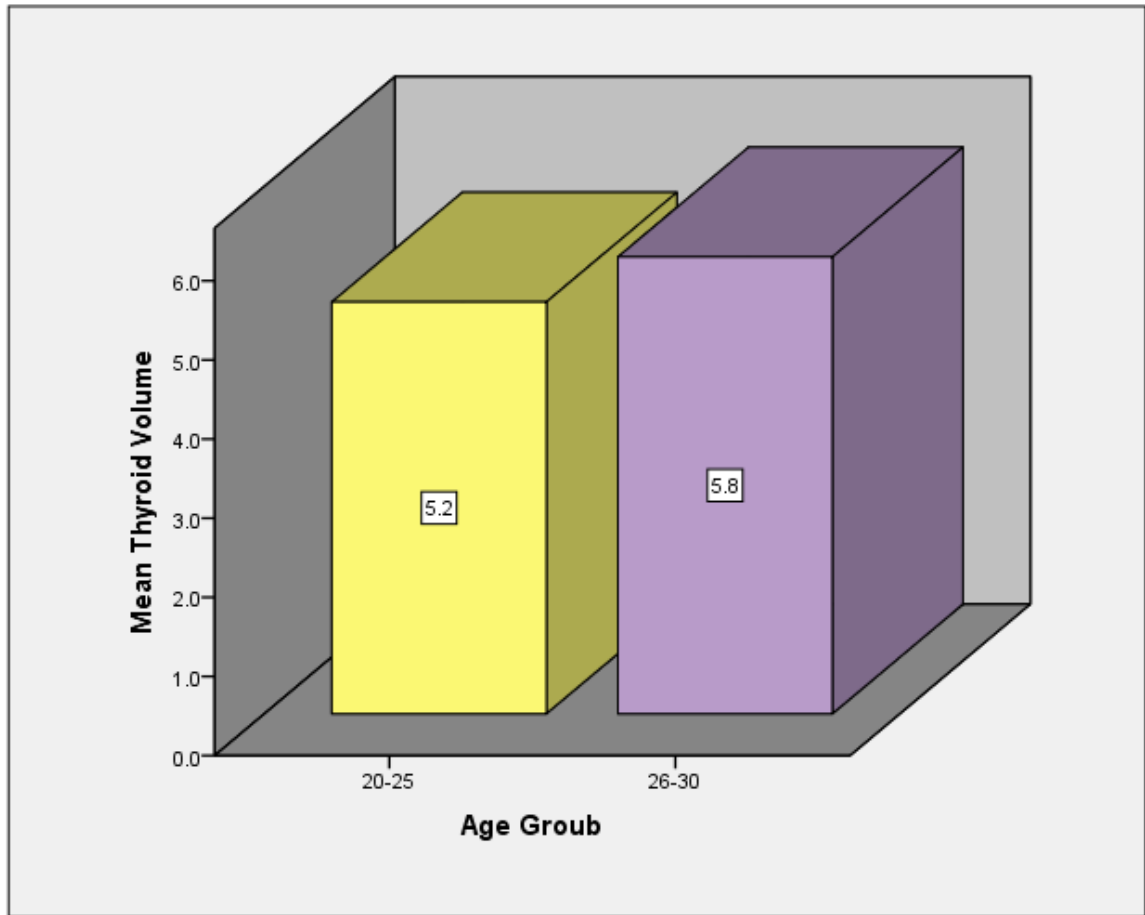


Figure (4.2) shows frequency of mean thyroid volume according to age group.

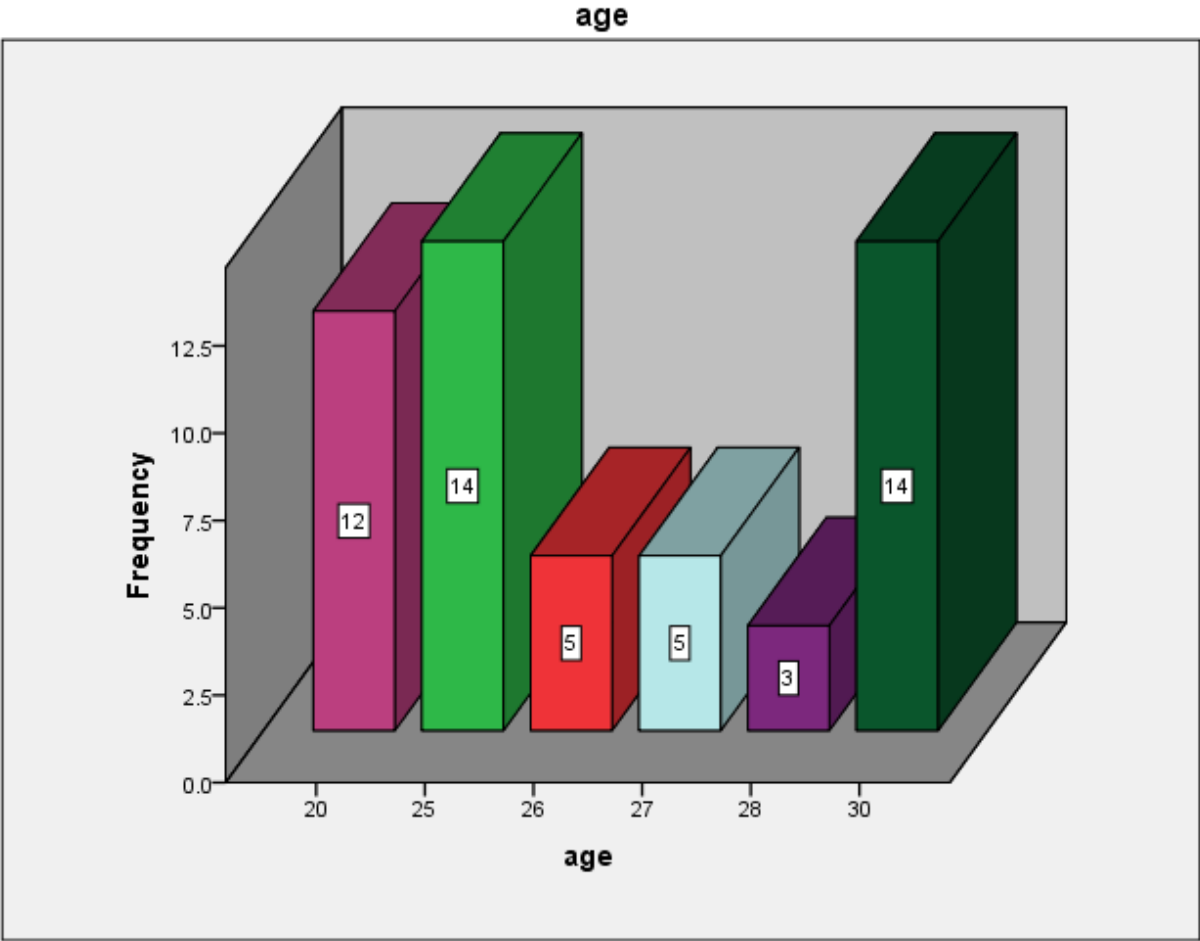
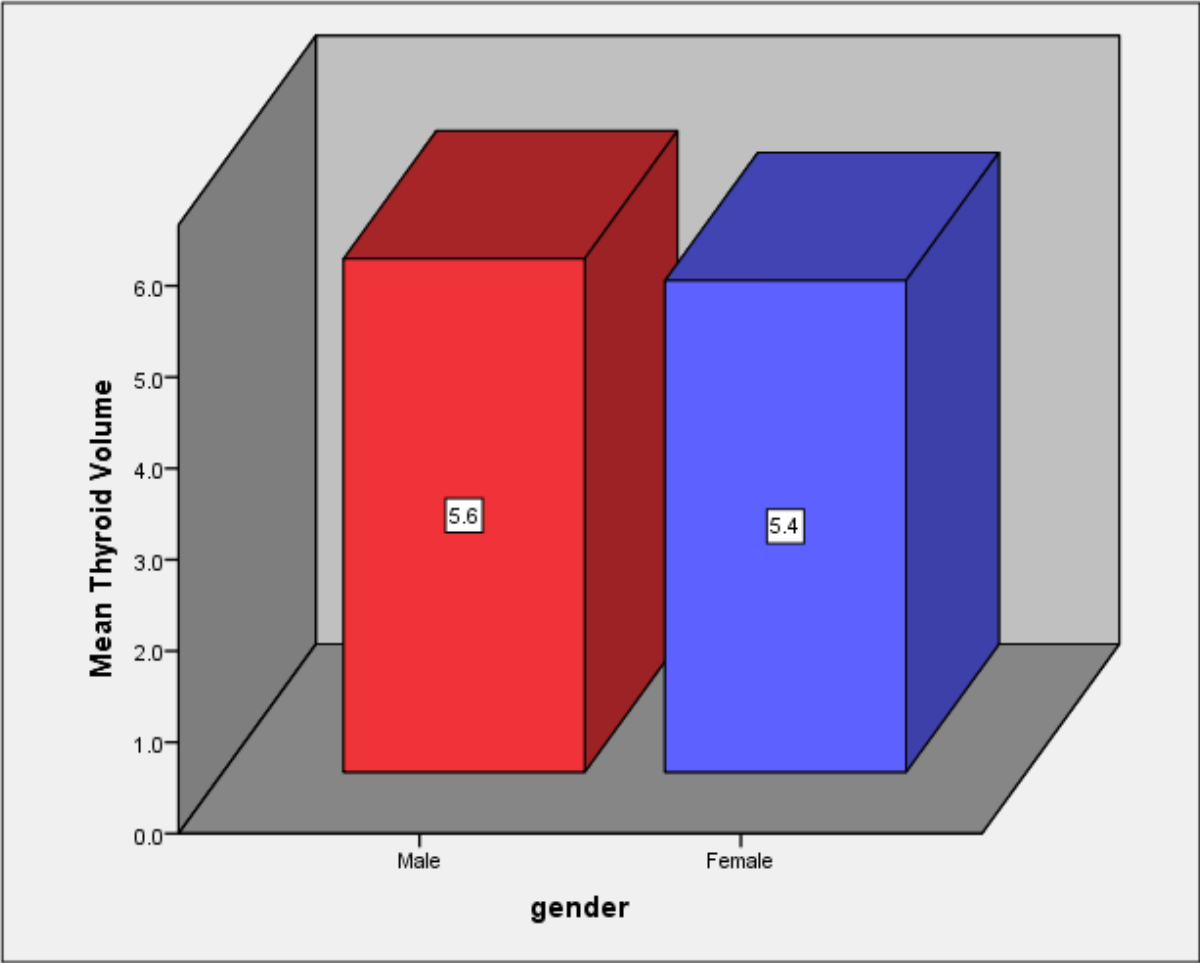
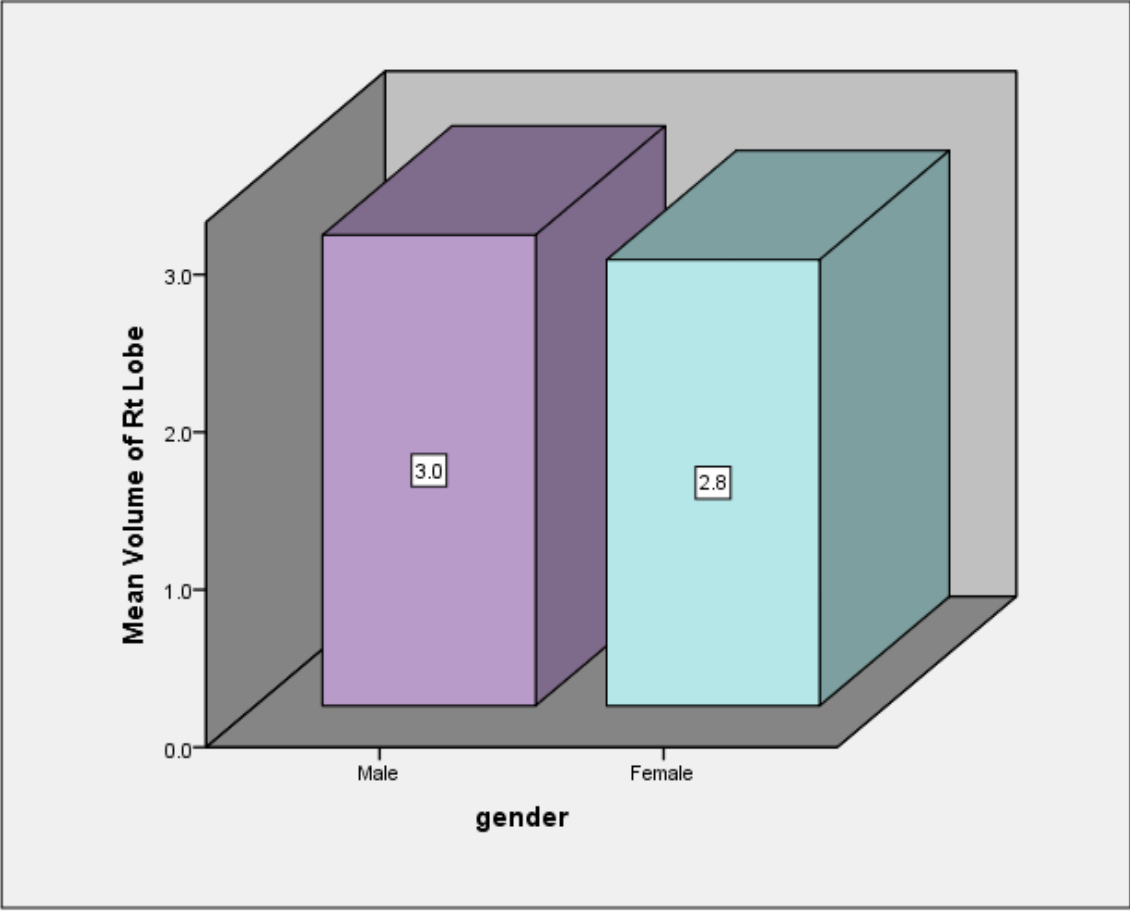


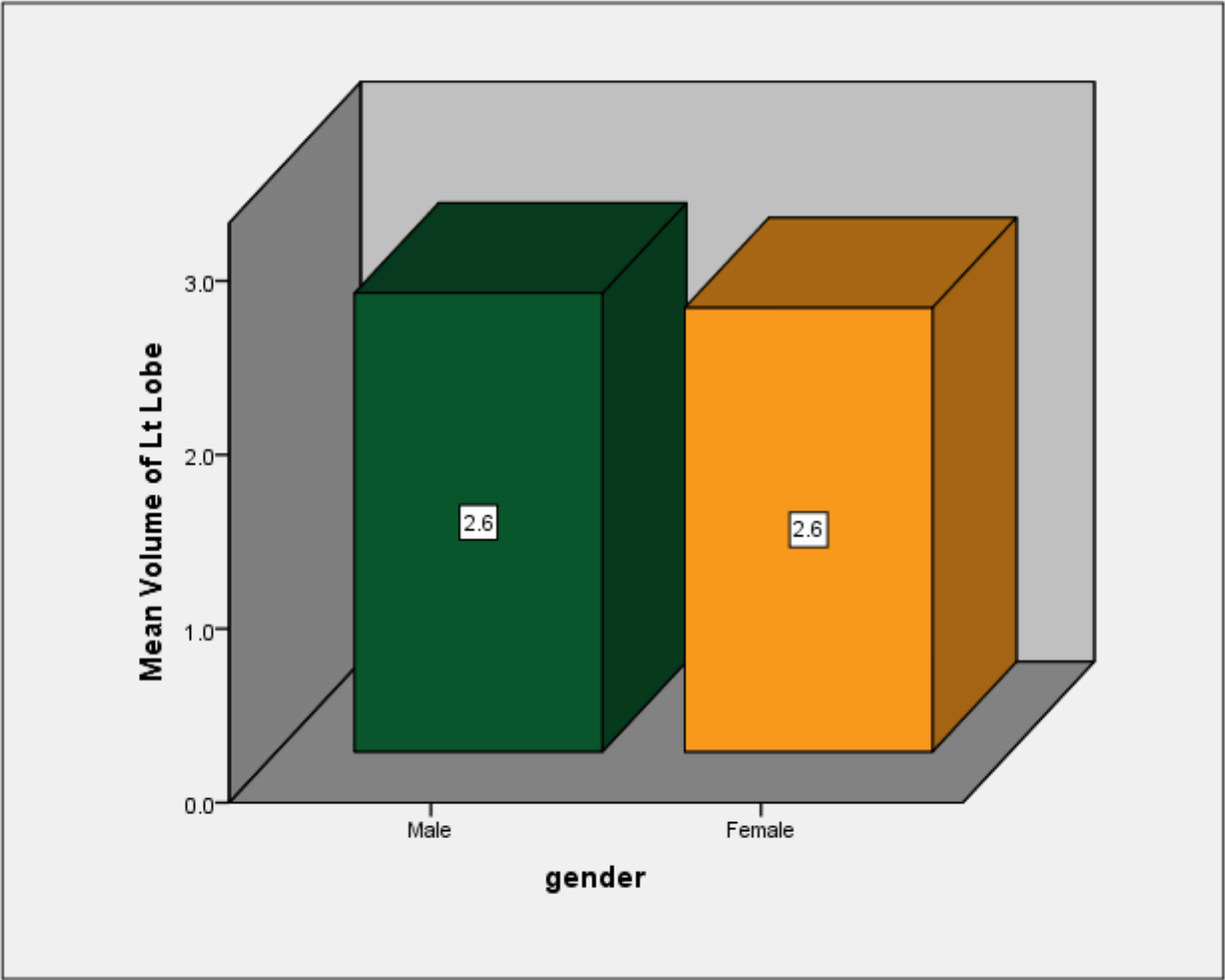
Figure (4.3) Frequency distribution of age.



Figure(4.4) Mean thyroid volume according to gender.



Figure(4.5) Mean volume of Rt lobe according to gender.



Figure(4.6) Mean volume of Lt lobe according to gender.

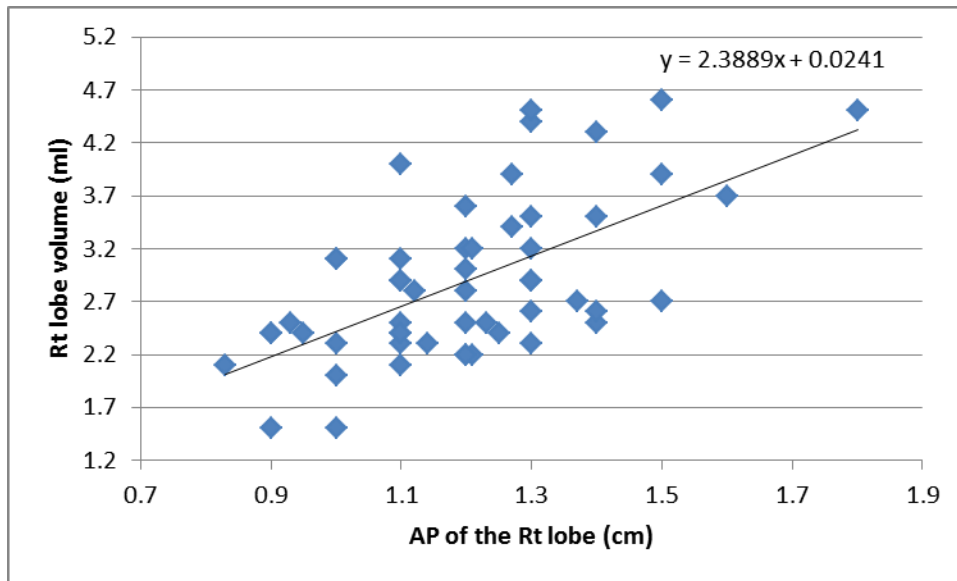


Figure (4.7) scatter plot shows relationship between AP of the Rt lobe and Rt lobe volume.

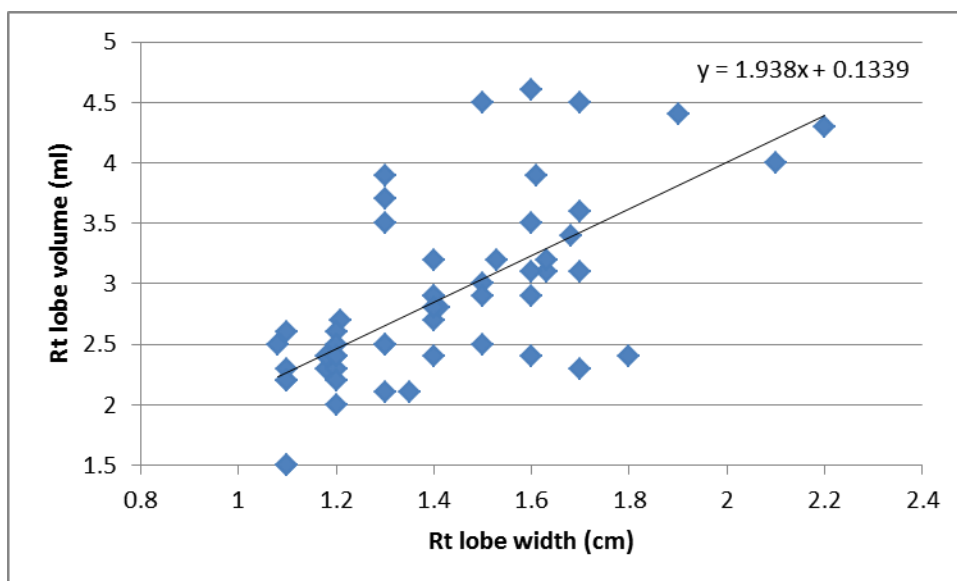


Figure (4.8) scatter plot shows relationship between Rt lobe width and Rt lobe volume.

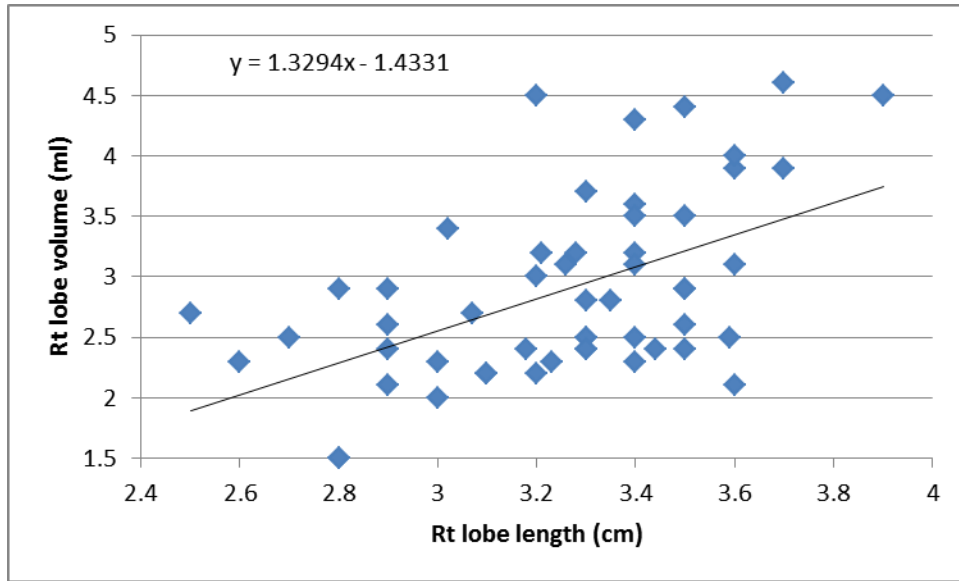


Figure (4.9) scatter plot shows relationship between Rt lobe length and Rt lobe volume.

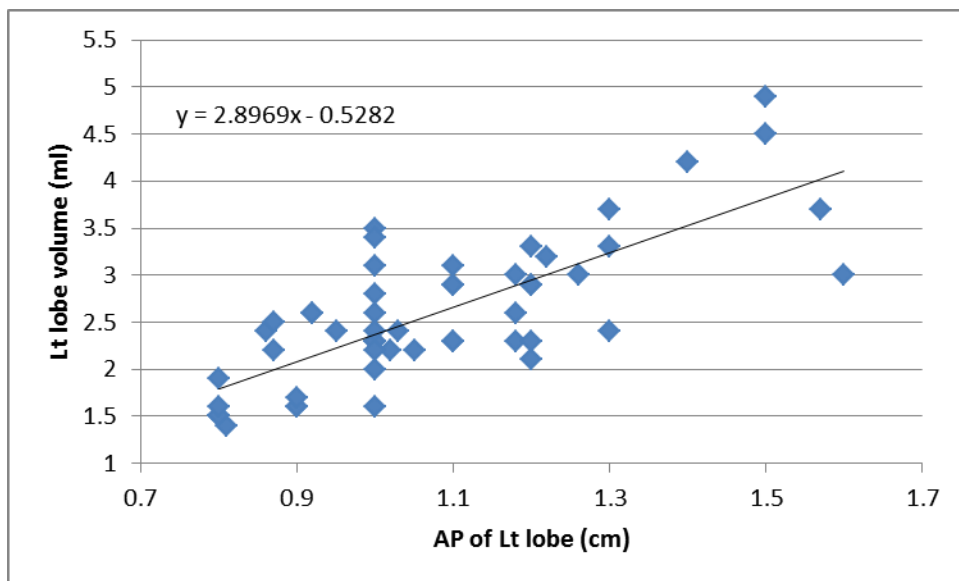


Figure (4.10) scatter plot shows relationship between AP of the Lt lobe and Lt lobe volume.

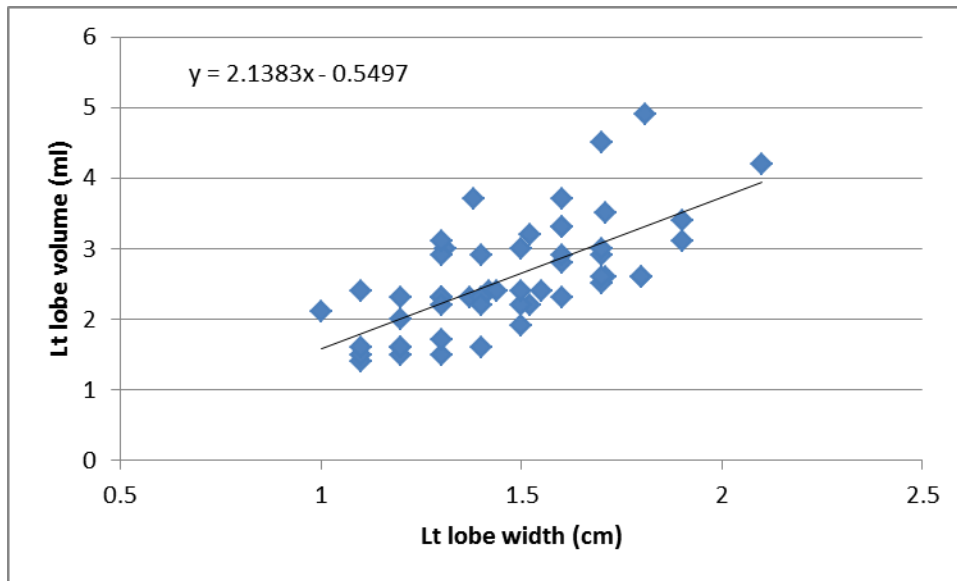


Figure (4.11) scatter plot shows relationship between Lt lobe width and Lt lobe volume.

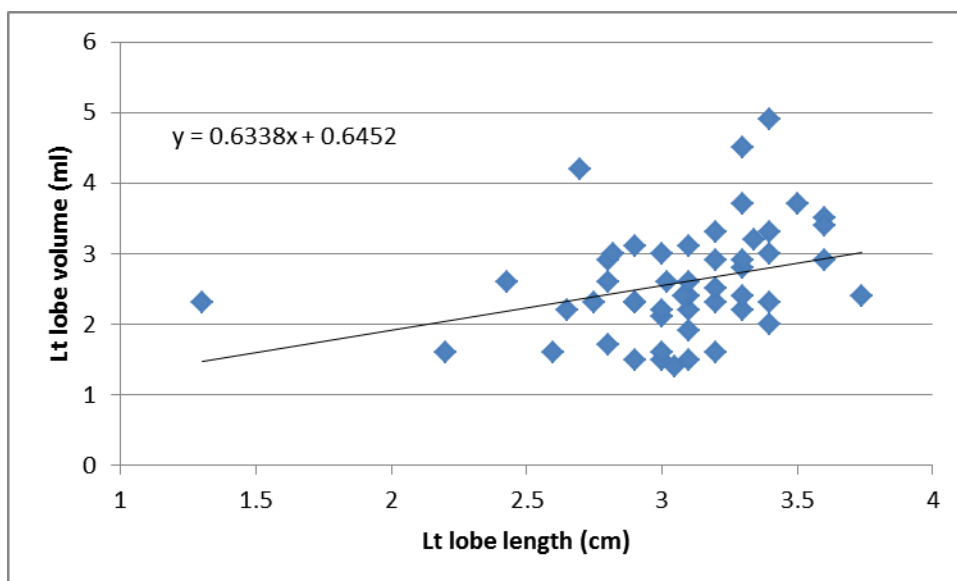


Figure (4.12) scatter plot shows relationship between Lt lobe length and Lt lobe volume.

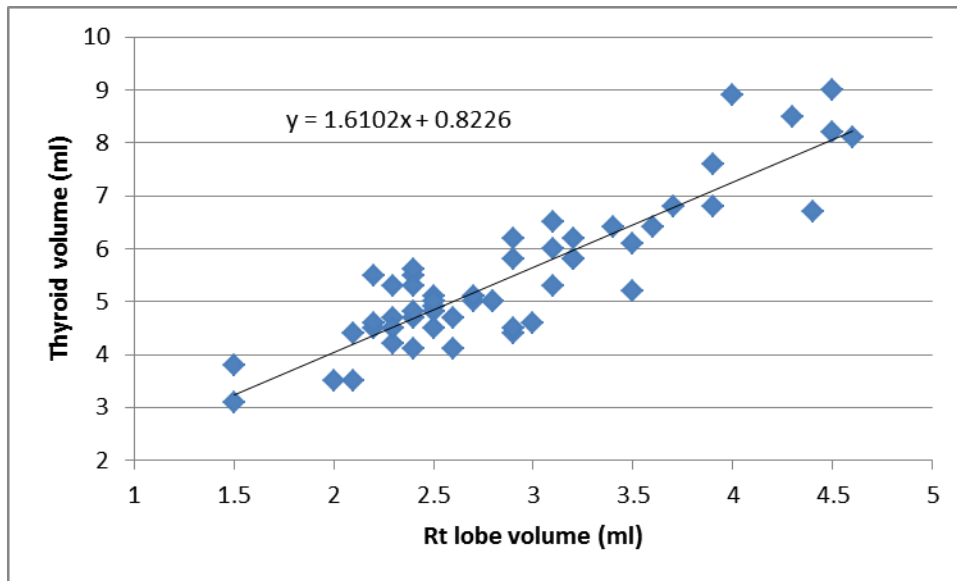


Figure (4.13) scatter plot shows relationship between Rt lobe volume and thyroid volume.

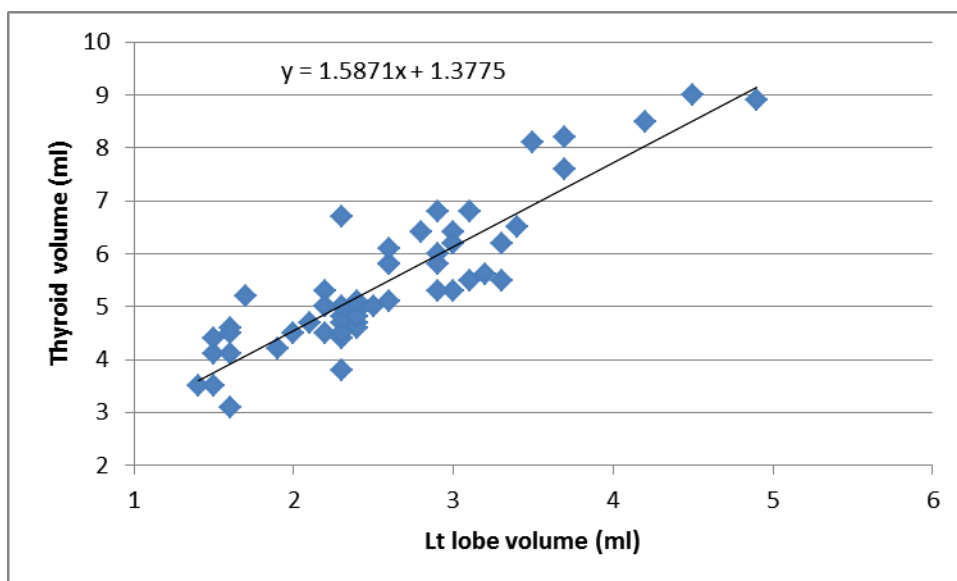


Figure (4.14) scatter plot shows relationship between Lt lobe volume and thyroid volume.

Chapter Five

Discussion' Conclusion and Recommendation

5.1 Discussion

The study include 11 variables (age , gender; AP ,width , length and volume of RT thyroid lobe age, gender; AP width ,and volume of LT thyroid lobe) collected from 53 patients aged from 20-30 years .

The study included the mean, minimum, maximum and standard deviation of each variable as show in table (4-1).

There were 22 male, and 31 female with male to female ratio 42:58 as describe in figure (4-!).

The study divided the samples into two age groups, 20-25 and 25-30 years the study showed frequency of mean thyroid volume according to these age groups it was found that the mean thyroid volume for the age for groups between 26-30 years was 5-2ml and for the age between 26-30 was 5-8ml as shown in figure (4-2).

The frequency of age is also included in this study, it was found that the both ages 25 and 30 years has the maximum frequency 14 patients while the minimum frequency was for 28 years old as describe in figure (4-3).

The mean thyroid volume was described according to gender, it found that the mean thyroid volume for males was 5.6 ml, while for females was 5.4

ml as described in figure (4-4) .

Figure (4-6) described the mean volume of left lobe according to gender; it was found that the mean volume of both males and females was 2.6 ml.

The study showed that there is relationship between the right lobe volume and the AP of the right lobe; it was found that that right lobe volume was increased by 2.38 ml\each cm of AP of the right lobe as described in figure (4-7) .

The study also correlate between the right lobe volume and right lobe width ; it was found that the right lobe volume was increased by 1.93 ml\each cm of right lobe width as described in figure (4-8) .

Figure (4-9) showed that there is correlate between right lobe volume and the length of right lobe; it was found that the right lobe volume was increased by 1.32 ml\each cm of right lobe length. Similarly the left lobe volume has a linear relationship with the AP of the left lobe; it was found that the left lobe volume increased by 2.89 ml \ each cm of AP of the left lobe, as shown in figure (4-10) .

The study also showed that there is a linear relationship between left lobe volume and left lobe width; it was found that the left lobe volume was increased by 2.1 ml \ each cm of left lobe width as described in figure (4-1) .

The study also correlate between the left lobe length and left lobe volume , it was found that the left lobe volume was increased by 0.63 ml \ each cm of length of the left lobe as shown in figure (4-12) .

The study also showed that there is relationship between the thyroid volume and right volume; it was found that the thyroid volume increased by 1.61 ml \ each ml of right lobe volume (figure (4-13)) .

Similarly there is relationship between the thyroid volume and the left lobe volume; it was found that the thyroid volume increased by 1.5 ml \ each ml of the left lobe volume (figure (4-14)).

The study showed that the total thyroid volume was 5.6 ml in male and 5.4 ml in female this value is different from that obtained by Mohamed yousef in 2010 the mean thyroid volume 2.44 ± 6.44 ml and by samah maglad in 2013 mean thyroid volume 0.39 ± 6.40 .

My study it similar to all the previous studies that the right lobe had significantly higher volume than the left lobe (right lobe 2.9)and(left lobe 2.6)

5.2 Conclusions:

This study concluded that The mean volume of thyroid gland was 5.48 ± 1.35 ml .

The RT lobe is greater than the LT lobe (the mean volume of RT lobe $2.89 \text{ml} \pm 0.75$ and the mean volume of the LF lobe was 2.58 ± 0.76)

The mean thyroid volume in male is greater than female (the mean thyroid volume in male was $5.6 \text{ ml} \pm 1.29$ and in female was 5.36 ± 1.40 and also concluded that the thyroid volume is increase with increase of age.

5.3 Recommendations :

The study recommended that :

1. Further study should be done to evaluate thyroid gland volume with large sample volume . .
2. Further study should be done to correlate to ethnic factor (race, height, weight, residence) .
3. lastly recommendation is about establishing records for thyroid volume in other age group like pediatrics and elderly people .

References

- _ Abdulla E. A., Suliman A.A., and Omer M. M. (2011) (Local Reference Ranges of Thyroid Volume in Sudanese Normal Subjects Using Ultrasound),in Journal of Thyroid Research Volume 2011, Article ID 935141, 4 pages .
- _ Anele T (2001) “Ultrasound volumetric measurement of normal thyroid in Nigerians,” The West African Journal of Ultrasound, vol. 2, no. 1, pp. 10–12,.
- _ Archie A. and Alexander M. (1996).The thyroid, the parathyroid, the salivary glands and the cervical lymphnodes, B. Goldberg and H. Petterson, The NICER Institute, Oslo, Norway, 399-429.
- _ Schlögl S., Werner E., Lassmann M (2001)(“The use of three-dimensional ultrasound for thyroid volumetry,” Thyroid, vol. 11, no. 6, pp. 569–574.
- _ Marchie T T, Oyobere O, Eze K C. (2012) Comparative ultrasound measurement of normal thyroid gland dimensions in school aged children in our local environment. Niger J Clin Pract;15:285-92.
- _ WHO, (1994)“Indicators for assessing iodine deficiency disorders and their control through salt iodization,” World Health Organization, Geneva, Switzerland, , (Document no. WHO/NUT94.6)
- _ Boron, WF.; Boulapep, EL. (2012). Medical Physiology (2nd ed.).

Philadelphia: Saunders. p. 1052.

- _ Longo, D; Fauci, A; Kasper, D; Hauser, S; Jameson, J; Loscalzo, J (2012).
- _ Harrison's Principles of Internal Medicine (18th ed.). New York: McGrawHill. pp. 2913, 2918.
- _ Dorland's (2012). Illustrated medical dictionary. Elsevier Saunders. p. 1072
- _ Yalçin B., Ozan H. (February 2006). "Detailed investigation of the relationship between the inferior laryngeal nerve including laryngeal branches and ligament of Berry". Journal of the American College of Surgeons 202 (2): 291–6.
- _ Fehrenbach; Herring (2012). Illustrated Anatomy of the Head and Neck. Elsevier Zoeller RT (April 2003). "Transplacental thyroxine and fetal brain development". J. Clin. Invest. 111 (7): 954–7. The thyroid gland in Endocrinology: Stephen Nussey and Saffron Whitehead (2001) integrated approach Published by BIOS Scientific Publishers Ltd. Thyroid Disorders Information MedicineNet. Retrieved on 2010 02-07
- _ Treatment for Thyroid disease Retrieved on 2010-02-07
- _ Yamamoto M, Shibuya N, Chen LC, Ogata E (February 1988). "Seasonal recurrence of transient hypothyroidism in a patient with

autoimmune thyroiditis". *Endocrinol. Jpn.* 35 (1): 135–42.

- _ Melton, Sarah. (February 2013.) "How Is Thyroid Dysfunction Associated With Bipolar Disorder?". medscape.com. Patrick L (June 2008). "Iodine: deficiency and therapeutic considerations" (PDF). *Altern Med Rev* 13 (2): 116–27.

Appendix

Patient information:

Patient name:

Patient age:

Sonographic characteristic:

Right lobe AP:

RT lobe width:

RT lobe length:

RT lobe volume:

LT lobe AP :

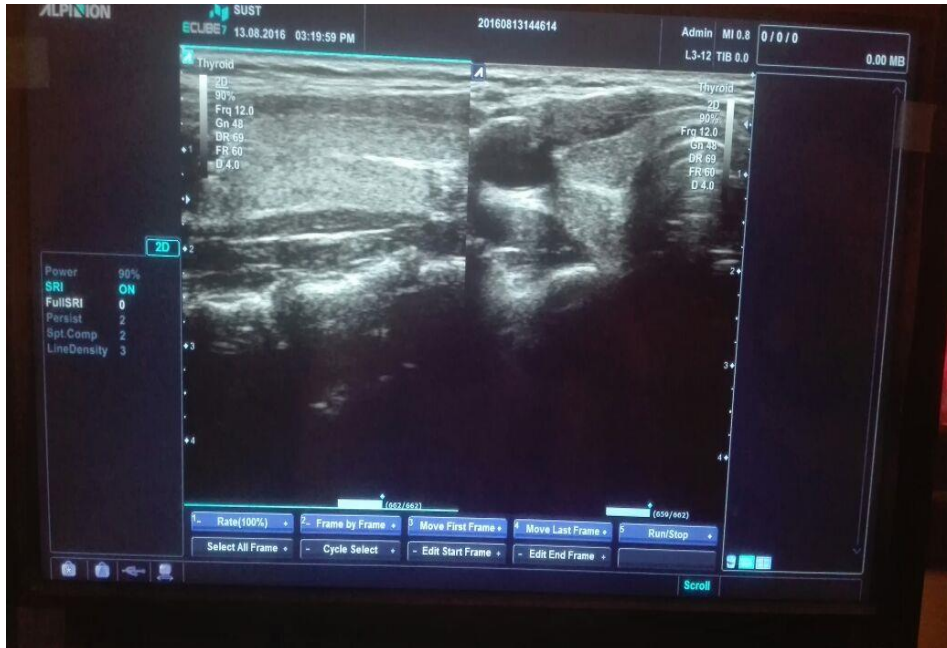LT lobe width:

LT lobe length:

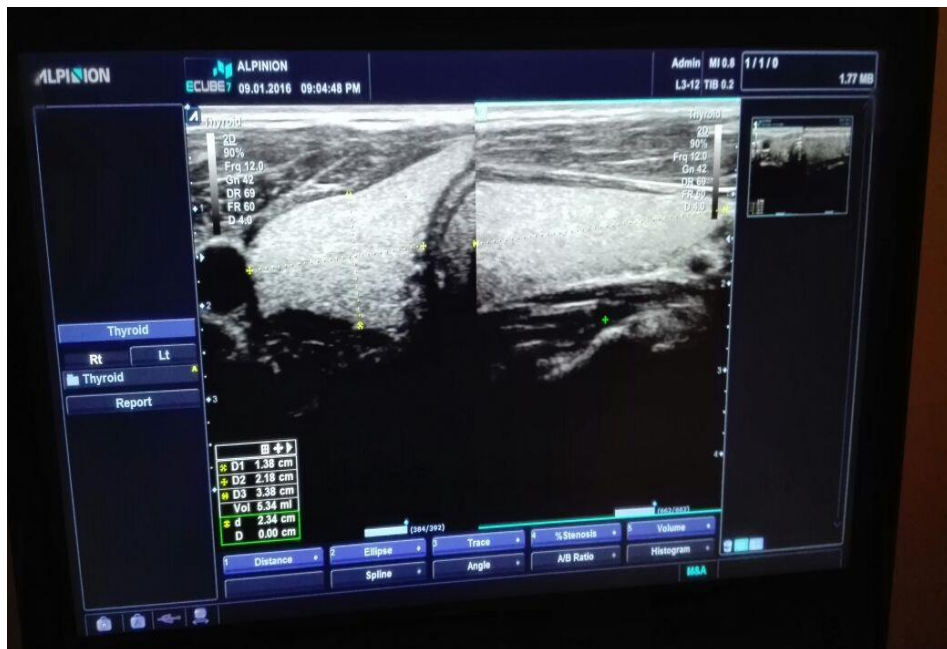LT lobe volume:

Thyroid volume:

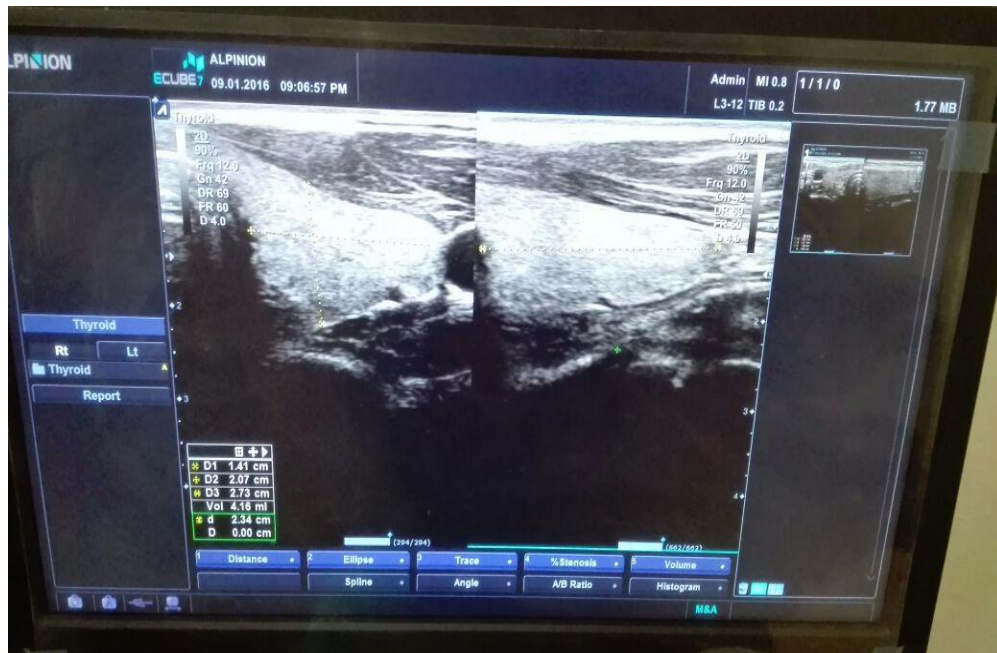Appendices



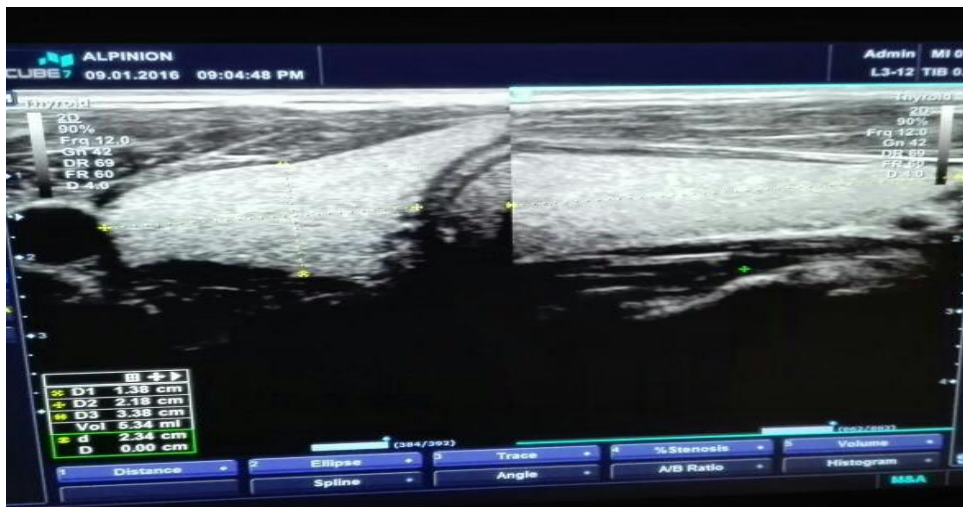Rt thyroid lobe longitudinal and transverse



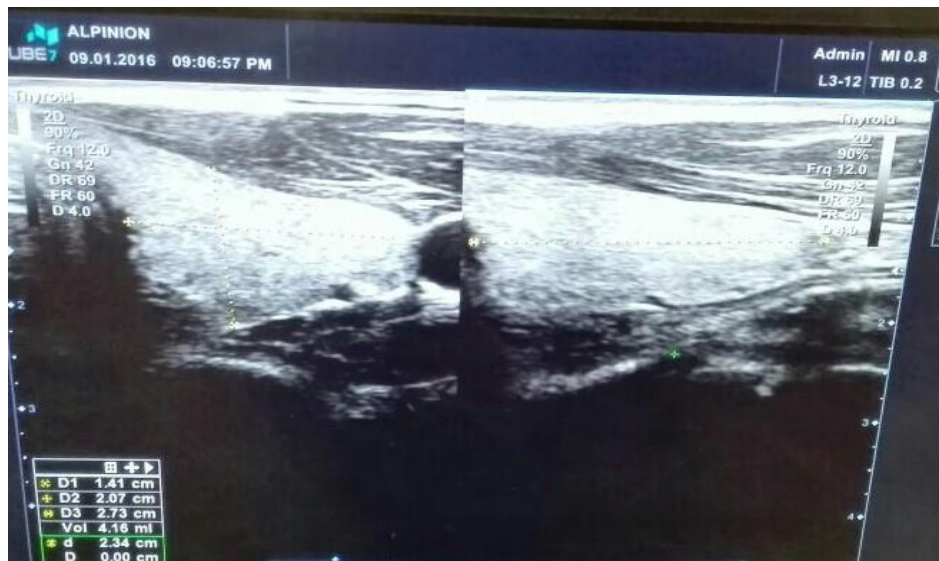Rt thyroid lobe transverse and sagittal



Lt thyroid lobe transverse and sagittal



Measurement of the volume of right lobe of thyroid gland



Measurement of volume of the left lobe of the thyroid gland