



**Sudan University of Sciences and  
Technology college of Graduate Studies**

**Classification of X-ray for Upper Limbs Trauma**

*A Thesis submitted for partial fulfillment of the M.Sc. Degree  
in diagnostic Radiologic Technology*

***By***

***Bodor Abbas Alameen***

***Supervisor***

***Dr. Mohammed Elfadil***

February 2017

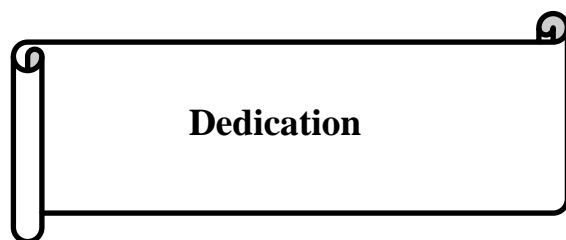بِسْمِ اللَّهِ الرَّحْمَنِ الرَّحِيمِ

قال تعالى :

(اقْرَأْ بِاسْمِ رَبِّكَ الَّذِي خَلَقَ (1) خَلَقَ الْإِنْسَانَ مِنْ عَلَقٍ (2) اقْرَأْ وَرَبُّكَ الْأَكْرَمُ  
(3) الَّذِي عَلَّمَ بِالْقَلَمِ (4) عَلَّمَ الْإِنْسَانَ مَا لَمْ يَعْلَمْ (5))

صدق الله العظيم

سورة العلق



**Dedication**

To my parents

Sisters and brothers

My husband

My son

## **Acknowledgment**

I thank God for enabling me to complete this thesis.

I sincerely thank Dr. Mohammed Elfadil; the Supervisor of my thesis for his continues help supervision and guidance.

I greatly thank all those who Supported and helped me to complete this thesis.

Especially thanks for my family and my husband.

## List of content

Content	Page no
Quran	i
Dedication	ii
Acknowledgment	iii
List of content	iv
List of tables	vii
List of figures	viii
Abstract	xi
Abstract (Arabic)	xii
Chapter One Introduction	
1-1-1 Upper limb	1
1-1-2 Human anatomy	2
Chapter Tow Background and literature review	
2-1 Anatomy	6
2-1-1 the scapula	5
2-1-2 the clavicle	6
2-1-3 shoulder girdle	7
2-1-4 Humreus	11
2-1-5 The elbow joints	12
2-1-6 Forearm	16
2-1-7 The wrist joint	19
2-1- 8 Hand	21

2-2 .Neurovascular system	23
2-2-1 Axillary artery	23
2-2-2 BRACHIAL ARTERY	25
2-2-3 Radial artery in the forearm	25
2-2-4 Median nerve in the arm	27
2-2-5 Brachial plexus	29
2-3 physiology	30
2-3-1 Ossification	30
2-3-2 Bone healing	33
2-4 Pathology	37
2-4-1 Bone fracture	37
2-4-2 Classification	38
2-4-3 Bone fracture	42
Chapter Three Materials and Methods	
3-1 Material	54
3-2 Design of the study	54
3-3 Population of the study	54
3-4 samples and type of the study	54
3-5 Study area and duration	54
3-6 Method of Data collection	55
3-6-1 Imaging techniques	55
3-6-2 Patient preparation	55
3-7 Analysis of data	55

Chapter Four Results	
4-1 Results	56
Chapter five Discussion, conclusion and Recommendations	
5-1 Discussion	65
5-2 Conclusion	67
5-3 Recommendations	68
References	69

## List of tables

<b>Content</b>	<b>Page no.</b>
Table 1-1 Risk factors for upper limb disorders	3
Table 2-1 Timetable for human ossification	31
Table 4-1 frequency distribution table of gender	56
Table 4-2 the mean and standard deviation of body height, weight BMI and age	56
Table 4-3 frequency distribution of type of fracture	57
Table 4-4 frequency distribution of fracture site	58
Table 4-5 frequency distribution of cause of fracture	59
Table 4-6 frequency distribution of fracture healing	60
Table 4-7 frequency distribution of duration before x-ray in days	61



## List of figures

Figures	Page no.
Fig 1-1 Anatomy of upper limbs	1
Fig 1-2 Muscles of upper limbs	2
Fig2-1The left scapula and clavicle	7
Fig 2-2The left shoulder joint	8
Fig 2-3 The (a) anterior and (b) posterior view of the humerus. (c) The humerus with its three major related nerves—axillary, radial and ulnar—all of which are in danger of injury in humeral fractures.	12
Fig 2-4 the elbow joint	14
Fig 2-5 The joint capsule of the right elbow—lateral aspect	15
Fig 2-6 The right radius and ulna	17
Fig 2-7 The wrist joint	20
Fig 2-8 The right carpus, metacarpus and phalanges	21
Fig 2-9 The axillary artery	23
Fig 2-10 Brachial artery	24
Fig 2-11 Radial artery	25
Fig 2-12 Median nerve in the arm	27
Fig 2-13 Brachial plexus	28

Fig 2-14 Types of fracture	37
Fig 2-15 Clavicle fracture	41
Fig 2-16 Fracture of the greater tuberosity of the humerus	42
Fig 2-17 Fracture humerus at surgical neck	42
Fig 2-18 Olecranon fracture	44
Fig2-19An elbow X-ray showing a displaced supracondylar fracture in a young child	46
Fig 2-20Radial head fracture	47
Fig 2-21 Greenstick fracture	49
Fig 2-22 X-ray of Monteggia fracture of right forearm	50
Fig 2-23 The galeaze fracture	51
Fig 2-24Colles fracture on X-ray	52
Fig4-1 a pie graphs shows the % distribution of gender	56
Fig4-2a bar graph of percentage frequency distribution of type of fracture	57
Fig 4-3a bar graph of percentage frequency distribution of fracture site	58
Fig4-4a pie graph of percentage frequency distribution of causes of fracture	59
Fig4-5a pie graph of percentage frequency distribution of fracture healing	60

Fig4-6a pie graph of percentage frequency distribution of duration before x-ray	61
Fig4-7a bar graphs show the type of fracture according to gender (crosstabulation)	62
Fig4-8 a bar graphs show the type of fracture according to site of fracture (crosstabulation)	62
Fig4-9a bar graphs show the site of fracture according to cause of fracture (crosstabulation)	63
Fig4-10 scatter plot show a linear relationship between healing process and the duration before x-ray in days	64

## **Abstract**

The main objective of this study was to classify trauma which occur in upper limbs by using x-ray objectively. The data of this study collected from 53 patients examined by upper limbs X-ray in East Nile Hospital (Modern Hospital in Khartoum – Sudan) in the period from September 2014 to May 2015 using Digital Philips machine. The data were collected use measuring fracture healing and three variables patient height, weight, and body mass index.. The results of the study showed that male represent 58% of the patients whom suffer from upper limb fracture with male to female ratio of 1.4:1. Most of the fracture occurs due to road traffic accident (RTA) 34% then fall down 26%, fights 23% followed by sport 17%. RTA and fall down represented more than 60% of fracture causes. The healing process takes place earlier 87% which ranged from 0.02-1.4 which means the delay of examination make the reduction worse. In conclusion this result gives linear relationship between duration before x-ray and healing.

## المستخلص

الهدف الرئيسي من هذا البحث هو تصنيف الصدمه التي تحدث في الاطراف العليا باستخدام الاشعه السينيه . هذه البيانات جمعت من 53 مريض تم عمل صوره الاشعه لهم في مستشفى شرق النيل (الخرطوم -السودان) في الفتره من سبتمبر 2014 الي مايو 2015 باستخدام جهاز فيليبس الرقمي. استخدم في جمع البيانات ثلاث متغيرات هي ارتفاع المريض,الوزن وكتله الجسم.

أظهرت نتائج الدراسة ان نسبة المرضى الذين يعانون من كسور في اطرافهم العليا 58% مع نسبة الرجال للنساء 1.4 الي 1. معظم الكسور حدث بسبب حوادث الطريق بنسبة تصل الي 34%, السقوط 26%، الشجار 23% و الرياضة 17%. حوادث المرور والسقوط تمثل أكثر من 60% من اسباب الكسور . عملية ارجاع الكسر تحدث مبكرا بنسبة 87% وتتراوح بين 0.02-1.4 مما يعني ان تأخر إجراء الفحص يؤدي الي خطأ في ارجاع الكسر.

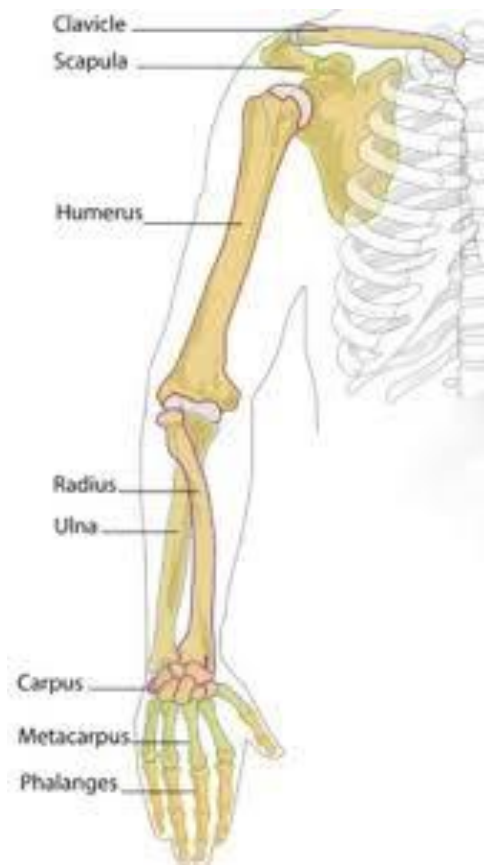وكتنتيجة لهذه الدراسة نتجت علاقة خطيه بين الفتره ما قبل عمل الصورة وشفاء الكسر.

# Chapter One

## Introduction

### 1-1-1 Upper limb:

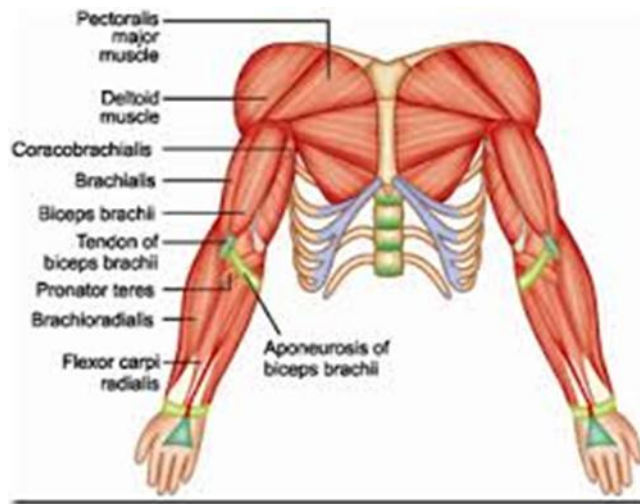
The upper limb consists of four major parts: a girdle formed by the clavicles and scapulae, the arm, the forearm, and the hand. Although very mobile, the limb is supported and stabilized by muscles connected to the ribs and vertebrae.



**Fig 1-1 anatomy of upper limbs**

### 1-1-2 Human anatomy:

The muscles of the upper limb can be classified by origin, topography, function, or innervations. While a grouping by innervation reveals embryological and phylogenetic origins, the functional-topographical classification below reflects the similarity in action between muscles (with the exception of the shoulder girdle, where muscles with similar action can vary considerably in their location and orientation).



**Fig 1- 2 muscles of upper limbs**

Upper limb disorders may present either acutely (with an obvious history of trauma) or chronically. Chronic conditions will often have a history of preceding, exacerbating or causative factors resulting in chronic microtrauma to local structures. In both cases a careful history is essential. Without addressing the underlying factors leading to the presentation, any management of an upper limb disorder is doomed to failure.

These factors are often termed intrinsic (factors relating to oneself) or extrinsic (factors relating to the environment). A classic example of an extrinsic factor is faulty ergonomics in work-related upper limb disorders. Table 1 summarises the important intrinsic and extrinsic factors that should be considered in patients with upper limb disorders.

**Table 1-1 Risk factors for upper limb disorders.**

<b>Intrinsic</b>	<b>Extrinsic</b>
<ul style="list-style-type: none"> <li>• Malalignment</li> <li>• Muscle imbalance</li> <li>• Muscle weakness</li> <li>• Hypo/hypermobility</li> <li>• Systemic illness (e.g. inflammatory arthritis, diabetes, osteoporosis)</li> <li>• Previous injury</li> <li>• Sex, size, body composition</li> <li>• Medications</li> </ul>	<ul style="list-style-type: none"> <li>• Faulty ergonomics</li> <li>• Inappropriate equipment</li> <li>• Excessive intensity</li> <li>• Repetitive activity</li> </ul>

A good history should suggest the diagnosis which may then be confirmed by clinical examination and/or appropriate investigations. It should be remembered that many upper limb disorders are clinical diagnoses which do not require specific investigations.



Important points in the history include:

- Diurnal variation. Inflammatory conditions such as rheumatoid arthritis are worse in the morning and often improve with activity, whereas degenerative or overuse conditions such as osteoarthritis or epicondylitis are worse at the end of the day and are exacerbated by activity.
- Heat or redness strongly suggest inflammation or infection
- Swelling may be objective (visible swelling with tight finger-rings) or subjective – neuropathic disorders may make the limb ‘feel’ swollen (akin to the feeling of swelling in the mouth after dental local anaesthetic).
- Pain site, type, radiation, onset and resolution in relation to exercise or activity.
- Sleep disturbance (neuropathic arm pain is often associated with nocturnal pain and disturbed sleep)
- Precipitant and relieving factors
- Demands of specific sport, exercise, hobbies or job. It is appreciated that not all physicians can have expert knowledge of specific sports or specific work ergonomics. It is quite reasonable to ask the patient what their job or sport entails and even to demonstrate it during the consultation. It should also be remembered that although everyday activities may exacerbate an upper limb disorder they may not be the original causative agent. To determine whether a condition is work-

related it is often helpful to ask whether the pain is worse during the week- (or working) day compared to the weekend and holidays.

### **1-2 Problem statement:**

Usually the patient use traditional method to fix the bone fracture , this is because there is lack of knowledge as well as the member of concern and the facilities ,this situation lead to complication concerning the healing of the fracture therefore solution of these complication well help in the management and prevention of the frequencies of occurrence.

### **1-3 Objective:**

The general objective of this study is to evaluate classification of upper limbs trauma by X ray.

### **1-4 Specific objective:**

- To find age, weight, height, BMI and gender.
- To find causes of trauma.

## Chapter Two

### Background and literature review

#### **2-1 Anatomy:**

##### **2-1-1 the scapula:**

This triangular bone bears three prominent features: the *glenoid fossa* laterally (which is the scapula's contribution to the shoulder joint), the *spine* on its posterior aspect, projecting laterally as the *acromion process*, and the *coracoid process* on its anterior aspect.

Its strong muscular coverings protect the scapula and it is rarely fractured, only by direct and severe violence.

##### **2-1-2 The clavicle:**

This long bone has a number of unusual features:

- It has no medullary cavity.
- It is the first to ossify in the fetus (5th–6th week).
- Although a long bone, it develops in membrane and not in cartilage.
- It is the most commonly fractured long bone in the body.

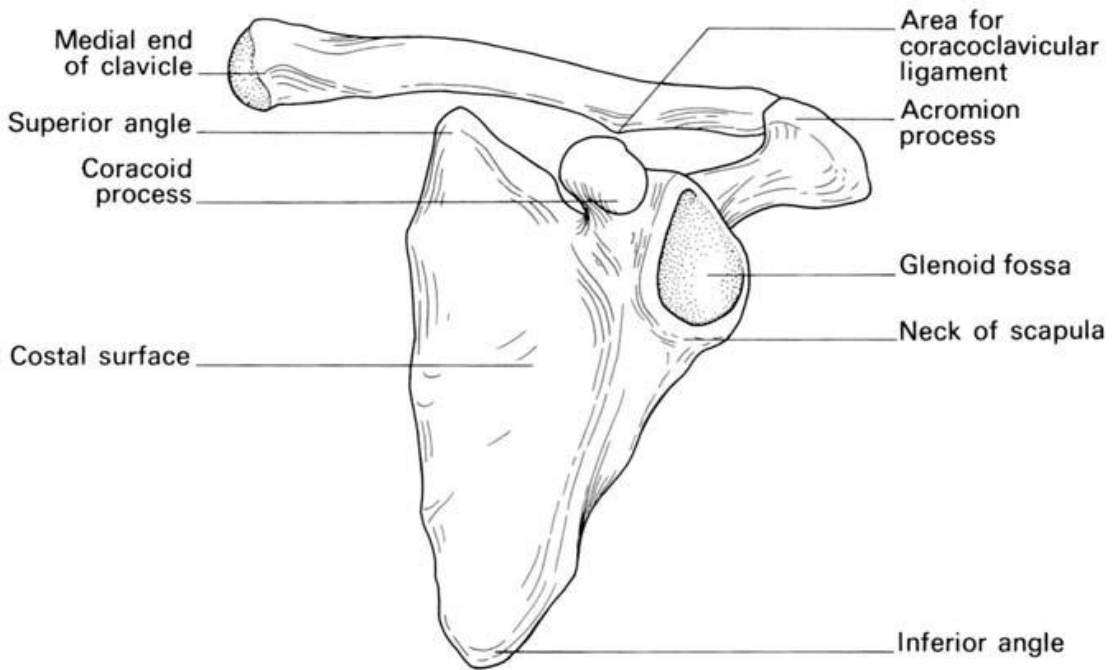
The clavicle is made up of a medial two-thirds which is circular in section and convex anteriorly, and a lateral one-third which is flattened in section and convex posteriorly.

Medially it articulates with the manubrium at the sternoclavicular joint (this joint containing an articular disc), and is also attached to the first costal cartilage by the costoclavicular ligament.

Laterally it articulates with the acromion at the acromioclavicular joint (the joint containing an incomplete articular disc) and, in addition, is attached to the coracoid process by the tough coracoclavicular ligament.

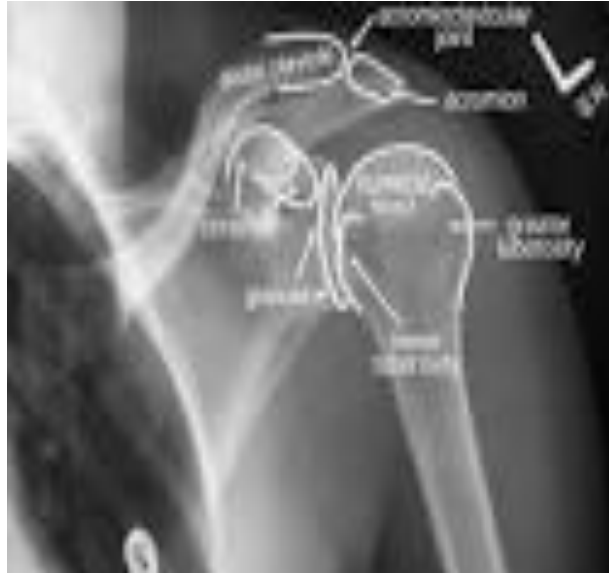The third parts of the subclavian vessels and the trunks of the brachialplexus pass behind the medial third of the shaft of the clavicle, separated only by the thin subclavius muscle. Rarely, these vessels (protected by the subclavius) are torn by the fragments of a fractured clavicle; this was the cause of death of Sir Robert Peel following a fall from his horse.

The sternal end of the clavicle has important posterior relations; behind the sternoclavicular joints lie the common carotid artery on the left and the bifurcation of the brachiocephalic artery on the right. The internal jugular vein lies a little more laterally on either side. These vessels are separated from bone by the strap muscles—the sternohyoid and sternothyroid.



**Fig2-1 the left scapula and clavicle.**

### 2-1-3 shoulder girdle:



**Fig 2-2 the left shoulder joint**

The shoulder girdle or pectoral girdle, composed of the clavicle and the scapula, connects the upper limb to the axial skeleton through the sternoclavicular joint (the only joint in the upper limb that directly articulates with the trunk), a ball and socket joint supported by the subclavius muscle which acts as a dynamic ligament, while this muscle prevents dislocation in the joint, strong forces tend to break the clavicle instead.

The acromioclavicular joint, the joint between the acromion process on the scapula and the clavicle, is similarly strengthened by strong ligaments, especially the coracoclavicular ligament which prevents excessive lateral and medial movements.

Between them these two joints allow a wide range of movements for the shoulder girdle, much because of the lack of a bone-to-bone contact between the scapula and the axial skeleton.

The pelvic girdle is, in contrast, firmly fixed to the axial skeleton, which increases stability and load-bearing capabilities.

The mobility of the shoulder girdle is supported by a large number of muscles, the most important of these are muscular sheets rather than fusiform or strap-shaped muscles and they thus never act in isolation but with some fibres acting in coordination with fibres in other muscles. Muscles:

Of shoulder girdle excluding the glenohumeral joint, Migrated from head Trapezius, sternocleidomastoideus, omohyoideus.

Posterior:

Rhomboideus major, rhomboideus minor, levator scapulae.

Anterior:

Subclavius, pectoralis minor, serratus anterior

The glenohumeral joint (colloquially called the shoulder joint) is the highly mobile ball and socket joint between the glenoid cavity of the scapula and the head of the humerus.

Lacking the passive stabilisation offered by ligaments in other joints, the glenohumeral joint is actively stabilised by the rotator cuff, a group of short muscles stretching from the scapula to the humerus.

Little inferior support is available to the joint and dislocation of the shoulder almost exclusively occurs in this direction.

The large muscles acting at this joint perform multiple actions and seemingly simple movements are often the result of composite antagonist and protagonist actions from several muscles. For example, pectoralis major is the most important arm flexor and latissimus dorsi the most important extensor at the glenohumeral joint, but, acting together, these two muscles cancel each other's action leaving only their combined medial rotation component.

On the other hand, to achieve pure flexion at the joint the deltoid and supraspinatus must cancel the adduction component and the teres minor and infraspinatus the medial rotation component of pectoralis major.

Similarly, abduction (moving the arm away from the body) is performed by different muscles at different stages. The first 10° is performed entirely by the supraspinatus, but beyond that fibres of the much stronger deltoid are in position to take over the work until 90°.

To achieve the full 180° range of abduction the arm must be rotated medially and the scapula must be rotated about itself to direct the glenoid cavity upward.

Muscles:

Of shoulder joint proper

Posterior:

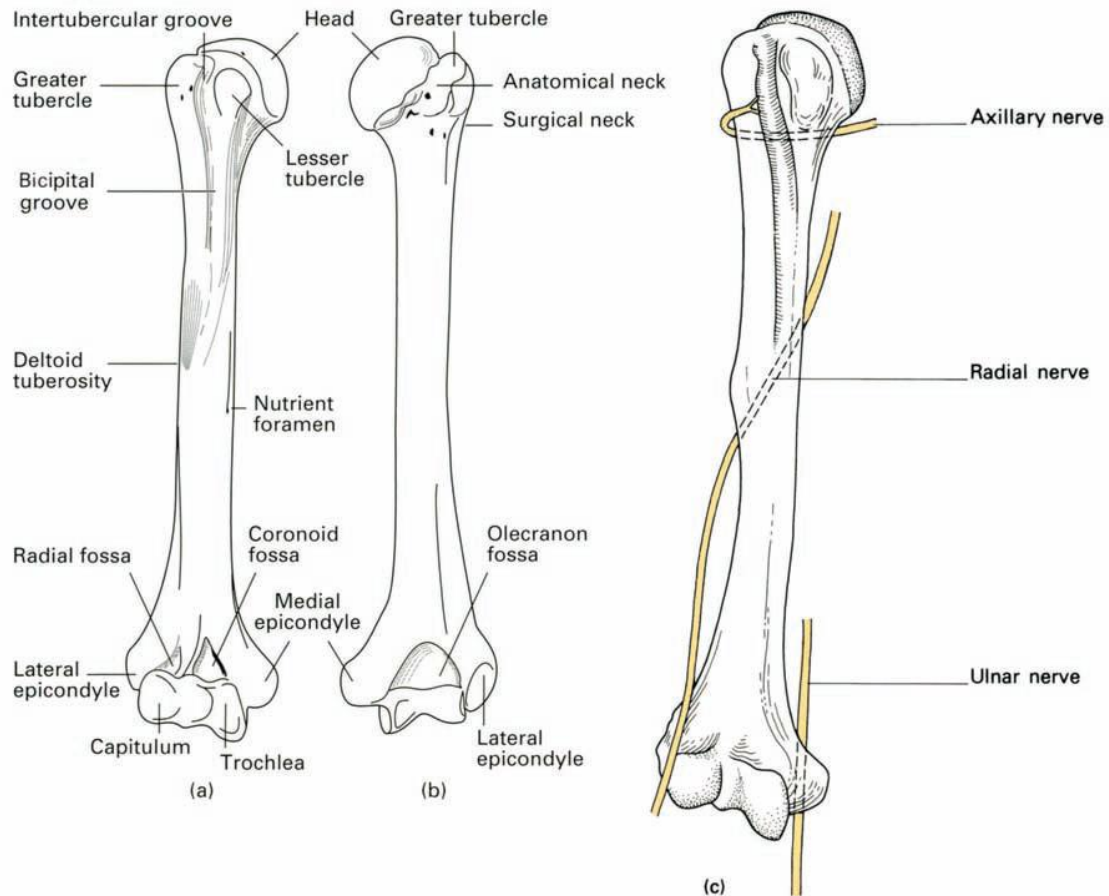
Supraspinatus, infraspinatus, teres minor, subscapularis, deltoideus,  
latissimus dorsi, teres major

Anterior:

Pectoralis major, coracobrachialis.



## 2-1-4Humerus:



**Fig 2-3 The (a) anterior and (b) posterior view of the humerus. (c) The humerus with its three major related nerves—axillary, radial and ulnar—all of which are indanger of injury in humeral fractures.**

The humerus proper (*brachium*), sometimes called the upper arm, the region between the shoulder and the elbow, is composed of the humerus with the elbow joint at its distal end.

### **2-1-5 The elbow joints:**

The elbow joint, although a single synovial cavity, is made up of three distinct articulations, which are:

- The *humero-ulnar*, between the trochlea of the humerus and the trochlear notch of the ulna (a hinge-joint).

- The *humeroradial*, between the capitulum and the upper concave surface of the radial head (a ball and socket joint).

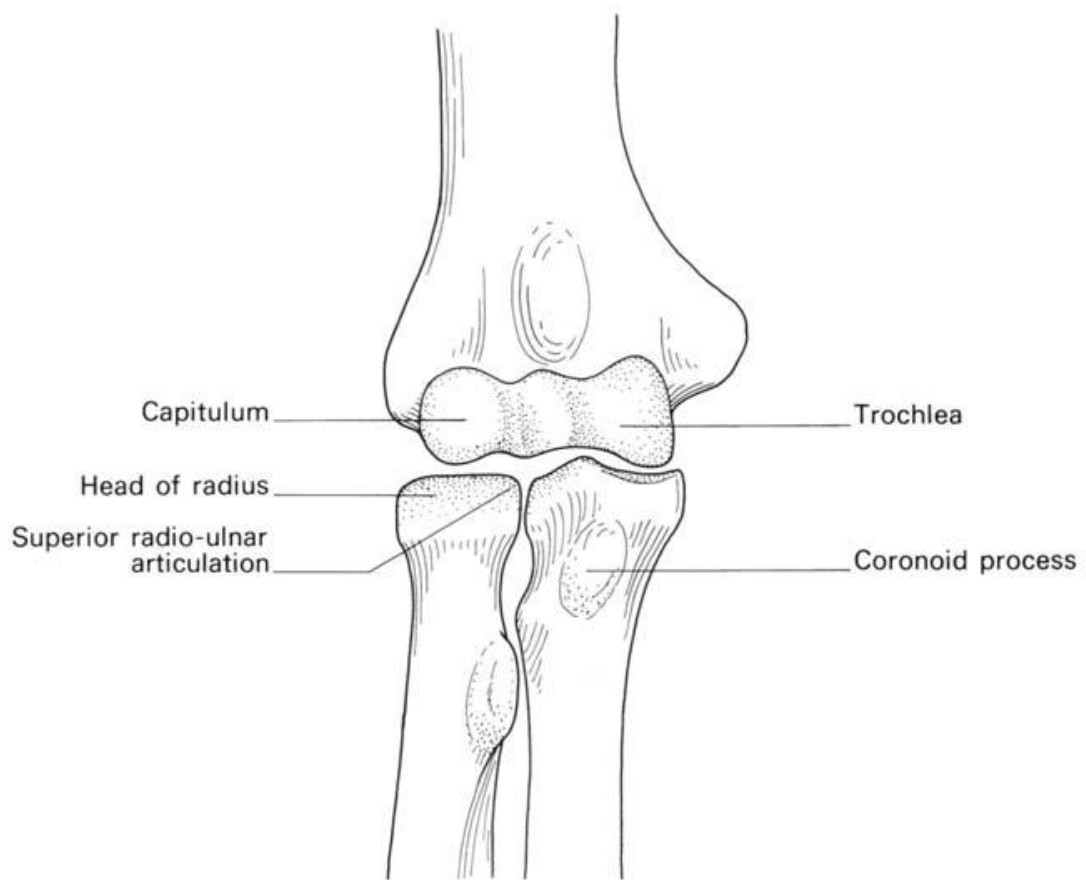
- The *superior radio-ulnar*, between the head of the radius and the radial notch of the ulna, the head being held in place by the tough annular ligament (a pivot joint).

The *capsule* of the elbow joint is closely applied around this complex articular arrangement; the non-articular medial and lateral epicondyles are extracapsular. The capsule is thin and loose anteriorly and posteriorly to allow flexion and extension, whereas it is strongly thickened on either side to form the *medial* and *lateral collateral* ligaments. The lateral ligament is attached distally to the *annular ligament* around the radial head. In order to allow rotation of the radius, the lower margin of the annular ligament is free and, beneath it, the synovium of the elbow bulges downwards on to the neck of the radius.

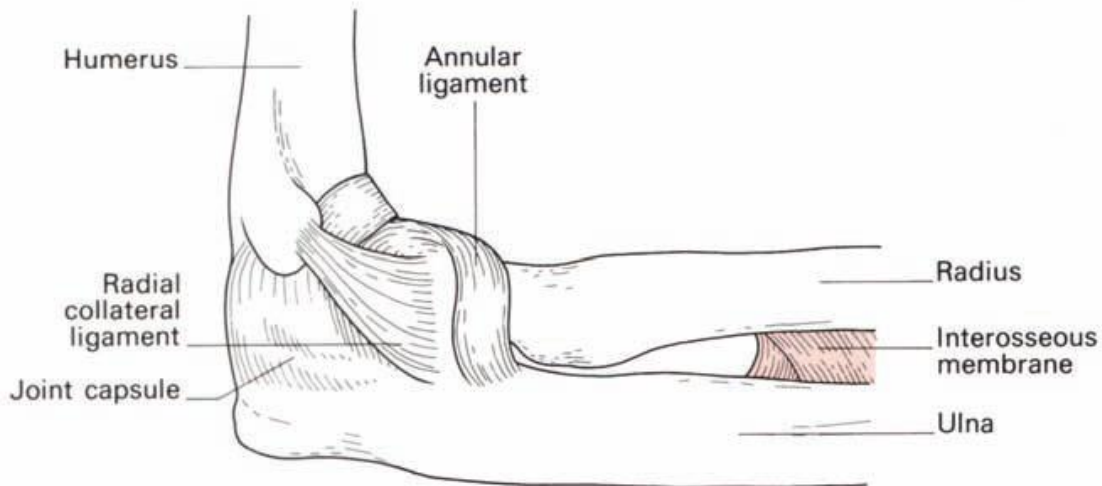
Two sets of movements take place at the elbow:

- Flexion and extension at the humero-ulnar and humeroradial joints;

- Pronation and supination at the proximal radio-ulnar (in conjunction with associated movements of the distal radio-ulnar joint).



**Fig. 2-4 the elbow joint.**



**Fig. 2-5 The joint capsule of the right elbow—lateral aspect.**

Muscles acting on the elbow:

Flexors Extensors:

Bicepstriceps

Brachialis anconeus

Brachioradialis

**The forearm flexor muscles:**

Pronators Supinators:

Pronator teresbiceps

Pronator quadratus supinator

Flexor carpi radialis

Extensor pollicis longus

Extensor pollicis brevis

Abductor pollicis longus

The supinator action of the biceps is due to its insertion on to the *posterior* aspect of the tuberosity of the radius. When the biceps contracts, notonly is the forearm flexed, but the radius ‘unwinds’ as its tuberosity isrotated

anteriorly, i.e. the forearm supinates. Biceps is a powerful muscle, hence supination is more powerful than pronation—try it on yourself.

Screwdrivers and cork screws are made for right-handed people to screw in using this supination action.

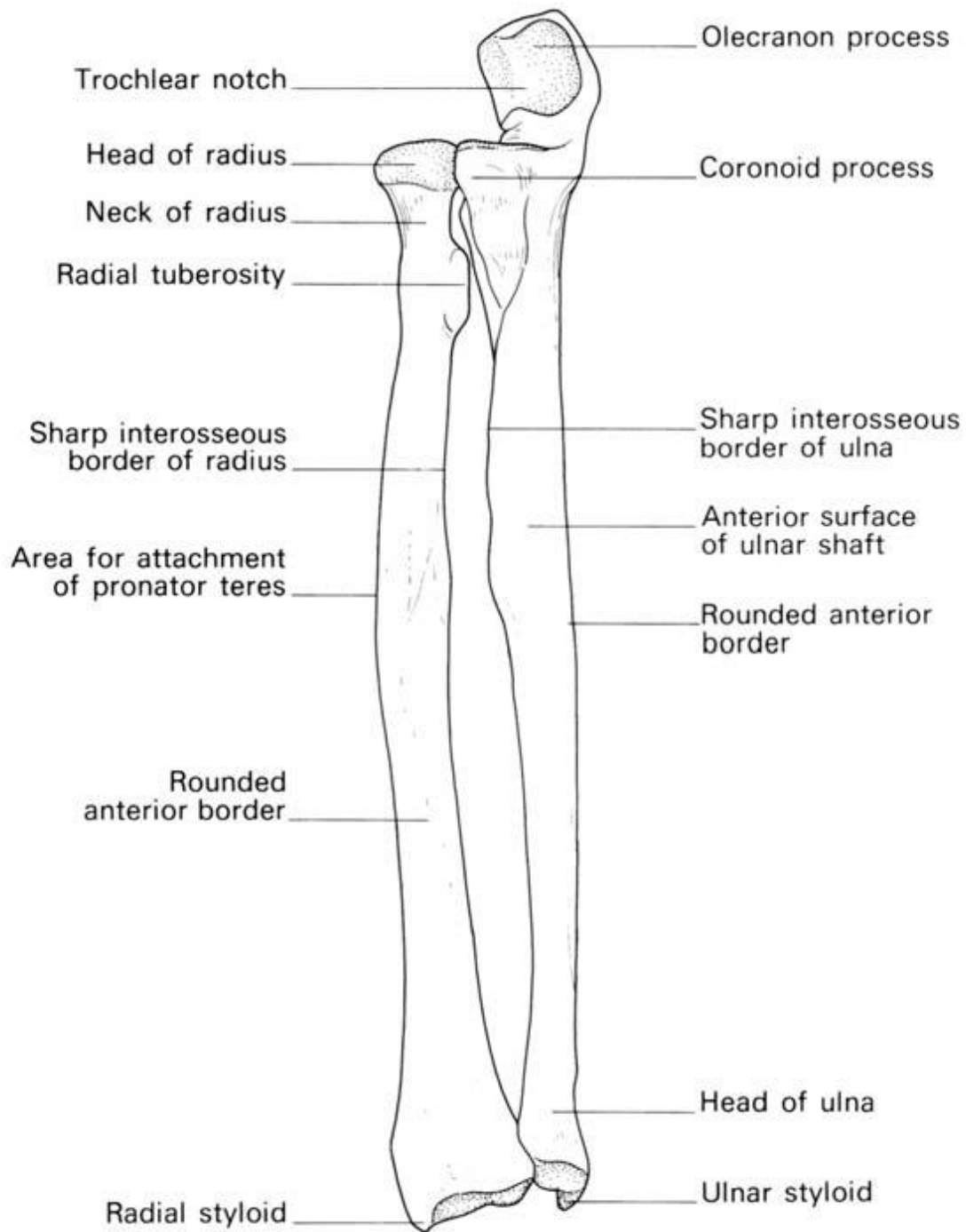
### **2-1-6 Forearm:**

The forearm (*antebrachium*), composed of the radius and ulna; the latter is the main distal part of the elbow joint, while the former composes the main proximal part of the wrist joint.

#### **2-1-6-1 The radius and ulna :**

The radius consists of the *head, neck, shaft* (with its *radial tuberosity*) and expanded distal end. The ulna comprises *olecranon, trochlear fossa, coronoid process* (with its *radial notch* for articulation with the radial head), *shaft* and small distal *head*, which articulates with the medial side of the distal end of the radius at the inferior radio-ulnar joint.

In pronation and supination, the head of the radius rotates against the radial notch of the ulna, the shaft of the radius swings round the relatively fixed ulnar shaft (the two bones being connected by a fibrous interosseous ligament) and the distal end of the radius rotates against the head of the ulna. This axis of rotation passes from the radial head proximally to the ulnar head distally.



**Fig 2-6 The right radius and ulna**

Most of the large number of muscles in the forearm are divided into the wrist, hand, and finger extensors on the dorsal side (back of hand) and the ditto flexors in the superficial layers on the ventral side (side of palm). These

muscles are attached to either the lateral or medial epicondyle of the humerus.

They thus act on the elbow, but, because their origins are located close to the centre of rotation of the elbow, they mainly act distally at the wrist and hand. Exceptions to this simple division are brachioradialis — a strong elbow flexor — and palmaris longus — a weak wrist flexor which mainly acts to tense the palmar aponeurosis.

The deeper flexor muscles are extrinsic hand muscles; strong flexors at the finger joints used to produce the important power grip of the hand, whilst forced extension is less useful and the corresponding extensors thus are much weaker.

Biceps is the major supinator (drive a screw in with the right arm) and pronator teres and pronator quadratus the major pronators (unscrewing) — the latter two rotate the radius around the ulna (hence the name of the first bone) and the former reverses this action assisted by supinator.

Because biceps is much stronger than its opponents, supination is a stronger action than pronation (hence the direction of screws).

Muscles:

Posterior:

(Superficial) extensor digitorum, extensor digiti minimi, extensor carpi ulnaris, (deep) supinator, abductor pollicis longus, extensor pollicis brevis, extensor pollicis longus, extensor indicis.

Anterior:

(Superficial) pronator teres, flexor digitorum superficialis, flexor carpi radialis, flexor carpi ulnaris, palmaris longus, (deep) flexor digitorum profundus, flexor pollicis longus, pronator quadratus Radial Brachioradialis, extensor carpi radialis longus, extensor carpi radialis brevis.

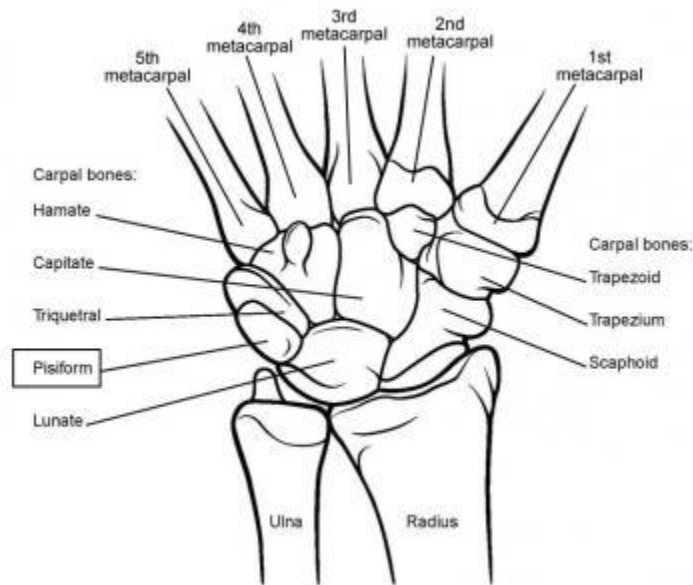
### **2-1-7The wrist joint :**

The articular disc of the inferior radio-ulnar joint covers the head of the ulna and is attached to the base of the ulnar styloid process. This disc, together with the distal end of the radius, form the proximal face of the wrist joint, the distal surface being the proximal articular surfaces of the scaphoid, lunate and triquetrum.

The wrist is a condyloid joint—that is to say, allows flexion, extension, abduction, adduction and circumduction, the last being a combination of the previous four. Flexion and extension are increased by associated sliding movements of the intercarpal joints; although the range of flexion at the wrist is actually less than that of extension, these associated movements make it apparently greater.

Because of the greater distal projection of the radial styloid, the range of abduction at the wrist is considerably less than that of adduction.





**Fig 2-7 The wrist joint**

Muscles acting on the wrist:

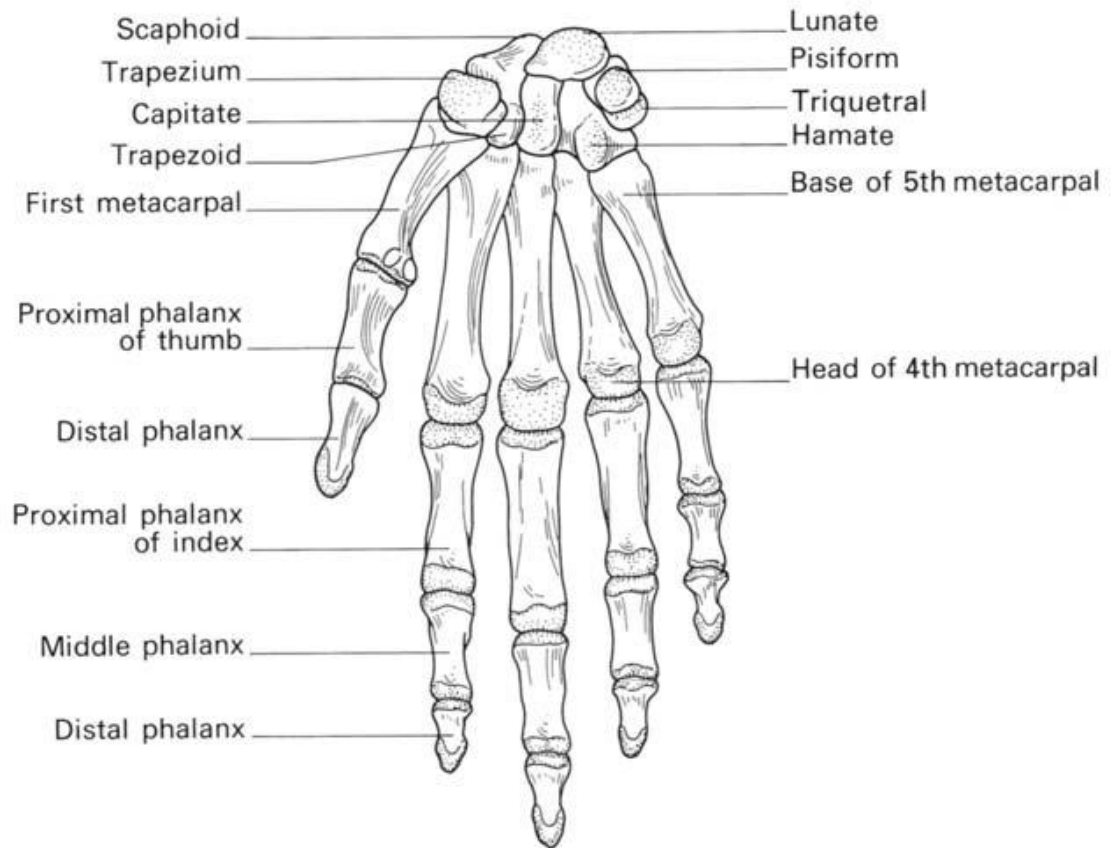
*Flexors*—all the long muscles crossing the anterior aspect of the wrist joint.

*Extensors*—all the long muscles crossing the posterior aspect of the joint.

*Adductors* — flexor carpi ulnaris acting in concord with extensor carpi ulnaris.

*Abductors* — flexor carpi radialis and extensores carpi radialis longus and brevis together with the long abductor and short extensor of the thumb.

## 2-1- 8 Hand:



**Fig. 2-8**The right carpus, metacarpus and phalanges

The hand (*manus*), the metacarpals (in the hand proper) and the phalanges of the fingers, form the metacarpophalangeal joints and interphalangeal joints.

Of the joints between the carpus and metacarpus, the carpometacarpal joints, only the saddle-shaped joint of the thumb offers a high degree of mobility while the opposite is true for the metacarpophalangeal joints. The joints of the fingers are simple hinge joints.

The primary role of the hand itself is grasping and manipulation; tasks for which the hand has been adapted to two main grips — power grip and

precision grip. In a power grip an object is held against the palm and in a precision grip an object is held with the fingers, both grips are performed by intrinsic and extrinsic hand muscles together.

Most importantly, the relatively strong muscles of the thumb and the thumb's flexible first joint allow the special opposition movement that brings the distal thumb pad in direct contact with the distal pads of the other four digits.

Opposition is a complex combination of thumb flexion and abduction that also requires the thumb to be rotated  $90^\circ$  about its own axis.

Without this complex movement, humans would not be able to perform a precision grip.

In addition, the central group of intrinsic hand muscles give important contributions to human dexterity.

On the other hand, finger movements without the corresponding wrist movements require the wrist muscles to cancel out the contribution from the extrinsic hand muscles at the wrist.

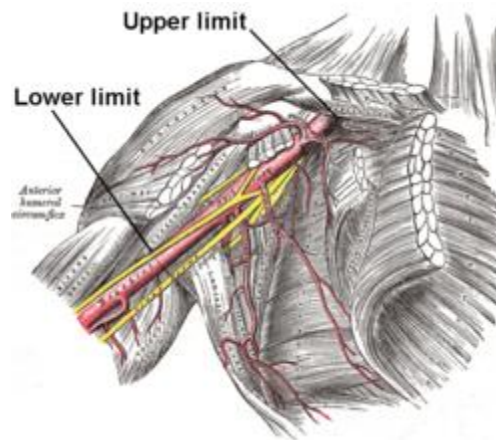
Muscles:

Metacarpal:

Lumbricals, dorsal interossei, palmar interossei  
Thenar  
Abductor pollicis brevis, adductor pollicis, flexor pollicis brevis, opponens pollicis  
Hypothenar  
Abductor digiti minimi, flexor digiti minimi, opponens digiti minimi, palmaris brevis

## 2-2. Neurovascular system:

### 2-2-1 Axillary artery:



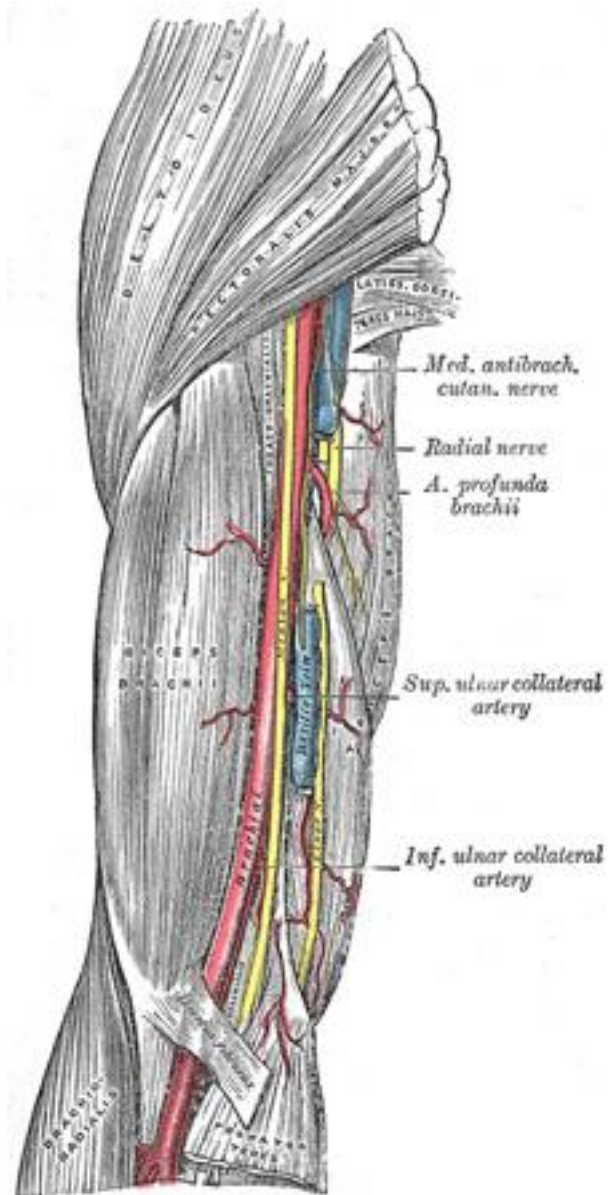
**Fig2-9 Right axillary artery**

**The artery is marked by joining the following two points:**

**1st point:** Begins at the midclavicular point.

**2nd point:** Ends at the medial side of the arm (lateral wall of axilla) close to the posterior axillary fold where its pulsation can be feel.

## 2-2-2 Brachial Artery:



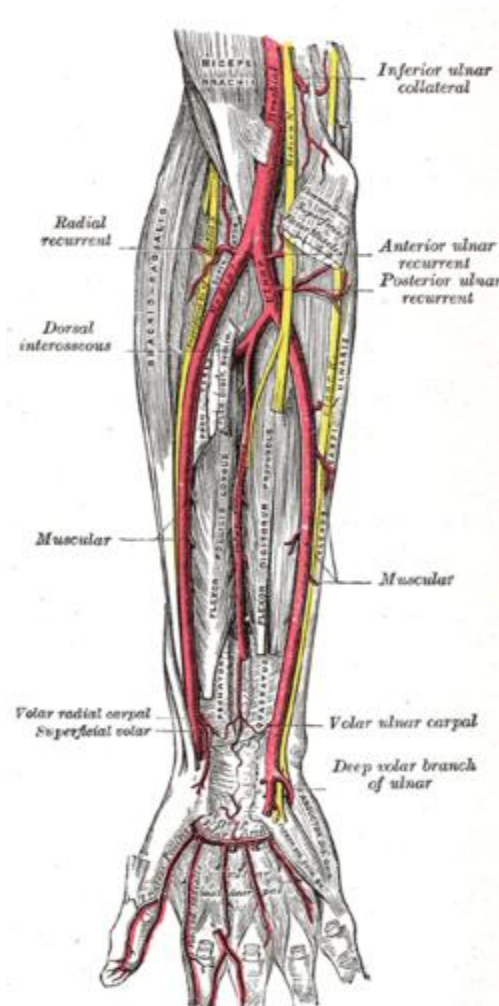
**Fig2-10 Brachial artery**

The artery is marked by joining the following two points:

1st point: Begins at the end of axillary artery (at the medial side of the arm (lateral wall of axilla) close to the posterior axillary fold).

2nd point: Ends at the midpoint of cubital fossa, at the level of the neck of radius medial to tendon of biceps brachii muscle.

### 2-2-3 Radial artery in the forearm :



**Fig2-11 Radial artery**

The artery is marked by joining the following two points:

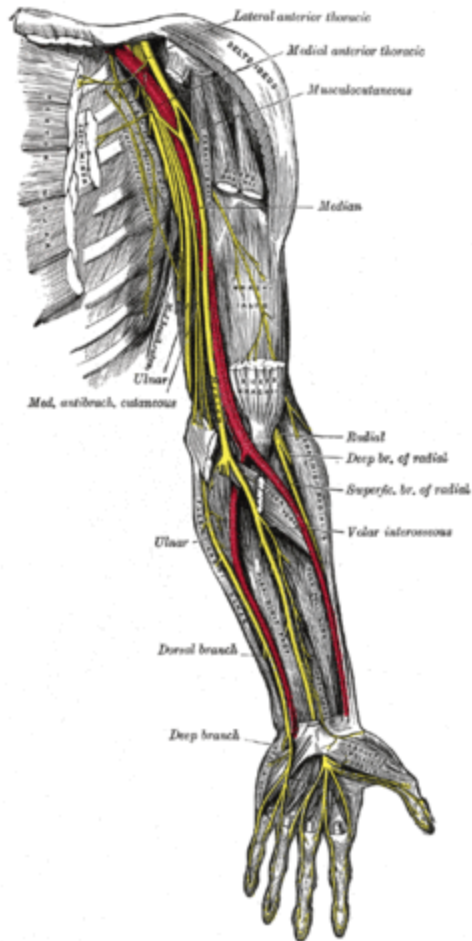
1st point: Begins at the end of brachial artery (at the midpoint of cubital fossa, at the level of the neck of radius medial to tendon of biceps brachii muscle).

2nd point: Ends at a point:

Anterior to the distal end of radius.

Between tendons of flexor carpi radialis (**medially**) and brachioradialis (**laterally**).

#### 2-2-4 Median nerve in the arm :

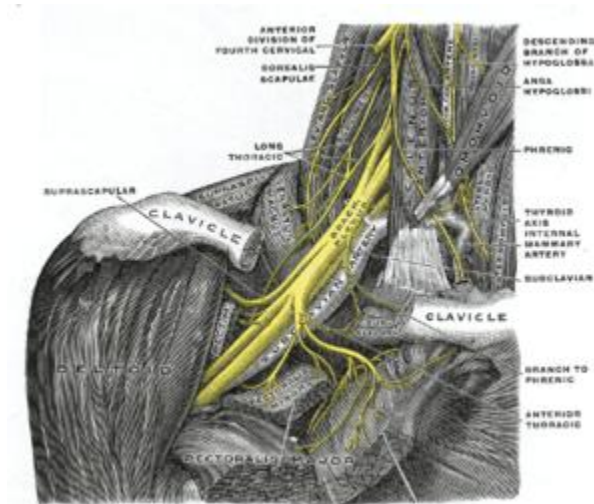


**Fig2-12 Median nerve in the arm**

- The nerve is drawn lateral to the brachial artery in the upper 1/2 and medial to the artery in the lower 1/2 of the arm.
- It crosses the brachial artery anteriorly in the middle of the arm.



## 2-2-5 Brachial plexus:



**Fig2-13 Brachial plexus**

The motor and sensory supply of the upper limb is provided by the brachial plexus which is formed by the ventral rami of spinal nerves C5-T1.

In the posterior triangle of the neck these rami form three trunks from which fibers enter the axilla region (armpit) to innervate the muscles of the anterior and posterior compartments of the limb.

In the axilla, cords are formed to split into branches, including the five terminal branches listed below.

The muscles of the upper limb are innervated segmentally proximal to distal so that the proximal muscles are innervated by higher segments (C5–C6) and the distal muscles are innervated by lower segments (C8–T1).

Motor innervation of upper limb by the five terminal nerves of the brachial plexus:

- The musculocutaneous nerve innervates all the muscles of the anterior compartment of the arm.
- The median nerve innervates all the muscles of the anterior compartment of the forearm except flexor carpi ulnaris and the ulnar part of the flexor digitorum profundus. It also innervates the three thenar muscles and the first and second lumbricals.
- The ulnar nerve innervates the muscles of the forearm and hand not innervated by the median nerve.
- The axillary nerve innervates the deltoid and teres minor.
- The radial nerve innervates the posterior muscles of the arm and forearm

Collateral branches of the brachial plexus:

- The dorsal scapular nerve innervates rhomboid major and minor.
- The long thoracic nerve innervates serratus anterior.
- The suprascapular nerve innervates supraspinatus and infraspinatus
- The lateral pectoral nerve innervates pectoralis major
- The medial pectoral nerve innervates pectoralis major and minor
- The upper subscapular nerve innervates subscapularis
- The thoracodorsal nerve innervates latissimus dorsi
- The lower subscapular nerve innervates subscapularis and teres major
- The medial brachial cutaneous nerve innervates the skin of medial arm.

- The medial antebrachial cutaneous nerve innervates the skin of medial forearm.

## **2-3Physiology:**

Bone is broken down by osteoclasts, and rebuilt by osteoblasts, both of which communicate through cytokine signalling.

### **2-3-1 Ossification:**

**Ossification** (or **osteogenesis**) in bone remodeling is the process of laying down new bone material by cells called osteoblasts. It is synonymous with bone tissue formation. There are two processes resulting in the formation of normal, healthy bone tissue: Intramembranous ossification is the direct laying down of bone into the primitive connective tissue (mesenchyme), while endochondral ossification involves cartilage as a precursor. In fracture healing, endochondral osteogenesis is the most commonly occurring process, for example in fractures of long bones treated by plaster of Paris, whereas fractures treated by open reduction and internal fixation with metal plates, screws, pins, rods and nails may heal by intramembranous osteogenesis.

Heterotopic ossification is a process resulting in the formation of bone tissue that is often atypical, at an extraskeletal location. Calcification is often confused with ossification. Calcification is synonymous with the formation of calcium-based salts and crystals within cells and tissue. It is a process that occurs during ossification, but not *vice versa*.

The exact mechanisms by which bone development is triggered remains unclear, but it involves growth factors and cytokines in some way.

**Table: 2-1 Timetable for human ossification:**

<b>Time period</b>	<b>Bones affected</b>
Third month of fetal development	Ossification in long bones beginning
Fourth month	Most primary ossification centers have appeared in the diaphyses of bone.
Birth to 5 years	Secondary ossification centers appear in the epiphyses
5 years to 12 years in females, 5 to 14 years in males	Ossification is spreading rapidly from the ossification centers and various bones are becoming ossified
17 to 20 years	Bone of upper limbs and scapulae becoming completely ossified
18 to 23 years	Bone of the lower limbs and os coxae become completely ossified
23 to 25 years	Bone of the sternum, clavicles, and vertebrae become completely ossified
By 25 years	Nearly all bones are completely ossified

### **2-3-2 Bone healing:**

**fracture healing**, is a proliferative physiological process in which the body facilitates the repair of a bone fracture.

Generally bone fracture treatment consists of a doctor reducing (pushing) displaced bones back into place via relocation with or without anaesthetic, stabilizing their position, and then waiting for the bone's natural healing process to occur.

Adequate nutrient intake has been found to significantly affect the integrity of the fracture repair. Recently, speed and quality of fracture healing process and osteogenesis has been shown to greatly improve when fracture area is suitably exposed to external static magnetic field, which seems to stimulate physiological processes behind most stages of osteogenesis

The process of the entire regeneration of the bone can depend on the angle of dislocation or fracture. While the bone formation usually spans the entire duration of the healing process, in some instances, bone marrow within the fracture has healed two or fewer weeks before the final remodeling phase.

While immobilization and surgery may facilitate healing, a fracture ultimately heals through physiological processes. The healing process is mainly determined by the periosteum (the connective tissue membrane covering the bone). The periosteum is one source of precursor cells which develop into chondroblasts and osteoblasts that are essential to the healing of bone. The bone marrow (when present), endosteum, small blood vessels, and fibroblasts are other sources of precursor cells.

Phases of fracture healing:

There are three major phases of fracture healing , two of which can be further sub-divided to make a total of five phases.

Reactive Phase:

- i. Fracture and inflammatory phase
- ii. Granulation tissue formation

iii. Cartilage Callus formation

iv. Lamellar bone deposition

Remodeling Phase:

Remodeling to original bone contour

Reactive:

After fracture, the first change seen by light and electron microscope is the presence of blood cells within the tissues adjacent to the injury site. Soon after fracture, the blood vessels constrict, stopping any further bleeding. Within a few hours after fracture, the extravascular blood cells form a blood clot, known as a *hematoma*. All of the cells within the blood clot degenerate and die. Some of the cells outside of the blood clot, but adjacent to the injury site, also degenerate and die. Within this same area, the fibroblasts survive and replicate. They form a loose aggregate of cells, interspersed with small blood vessels, known as *granulation tissue*.

Reparative:

Days after fracture, the cells of the periosteum replicate and transform. The periosteal cells proximal (closest) to the fracture gap develop into chondroblasts which form hyaline cartilage. The periosteal cells distal to (further from) the fracture gap develop into osteoblasts which form woven bone. The fibroblasts within the granulation tissue develop into chondroblasts which also form hyaline cartilage. These two new tissues grow in size until they unite with their counterparts from other parts of the fracture. These processes culminate in a new mass of heterogeneous tissue

which is known as the *fracture callus*. Eventually, the fracture gap is bridged by the hyaline cartilage and woven bone, restoring some of its original strength.

The next phase is the replacement of the hyaline cartilage and woven bone with lamellar bone. The replacement process is known as *endochondral ossification* with respect to the hyaline cartilage and *bony substitution* with respect to the woven bone. Substitution of the woven bone with lamellar bone precedes the substitution of the hyaline cartilage with lamellar bone. The lamellar bone begins forming soon after the collagen matrix of either tissue becomes mineralized. At this point, the mineralized matrix is penetrated by channels, each containing a microvessel and numerous osteoblasts. The osteoblasts form new lamellar bone upon the recently exposed surface of the mineralized matrix. This new lamellar bone is in the form of trabecular bone. Eventually, all of the woven bone and cartilage of the original fracture callus is replaced by trabecular bone, restoring most of the bone's original strength.

Remodeling:

The remodeling process substitutes the trabecular bone with compact bone. The trabecular bone is first resorbed by osteoclasts, creating a shallow resorption pit known as a "Howship's lacuna". Then osteoblasts deposit compact bone within the resorption pit. Eventually, the fracture callus is remodelled into a new shape which closely duplicates the bone's original shape and strength. The remodeling phase takes 3 to 5 years depending on factors such as age or general condition. This process can be enhanced by

certain synthetic injectable biomaterials, such as cerament, which are osteoconductive and actively promote bone healing.<sup>[11]</sup>

### Complications of Fracture Healing:

The main complications include thesephses

-Delayed Union: Poor blood supply or infection.

-Non-Union: Bone loss or wound contamination.

-Fibrous Union: Improper immobilization.

### Fracture Healing:

Factors affecting fracture healing include:

- patient age
- character of fracture
- systemic disorders
- bone disease
- osteoporosis
- osteopenia



## **2-4Pathology:**

### **2-4-1Bone fracture:**

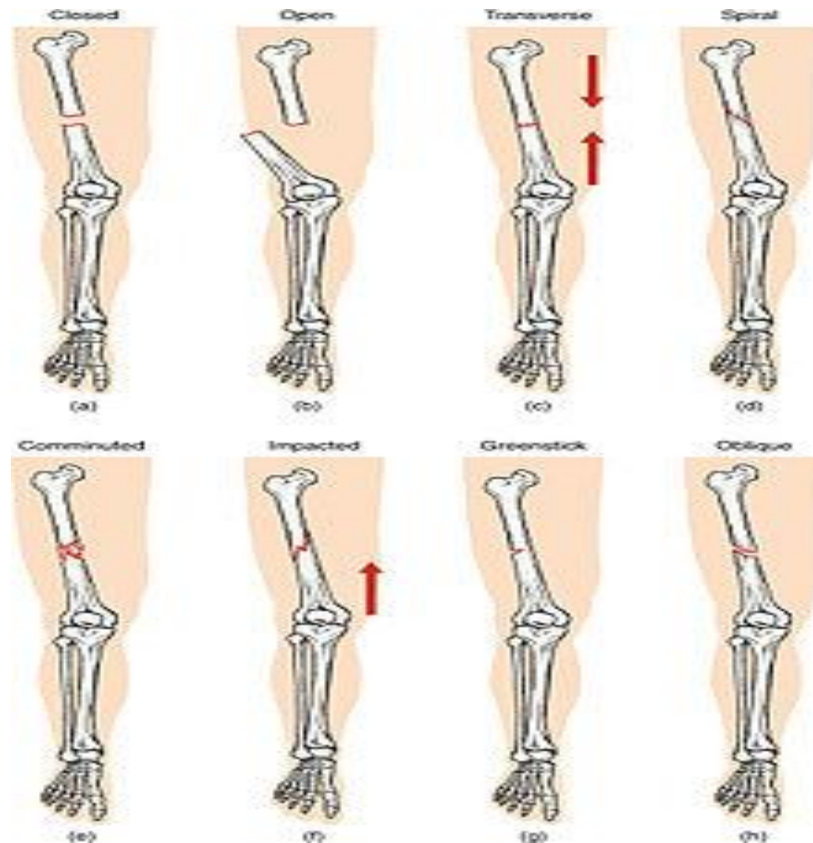
A bone fracture: is a medical condition in which there is a break in the continuity of the bone. A bone fracture can be the result of high force impact or stress, or a minimal trauma injury as a result of certain medical conditions that weaken the bones, such as osteoporosis, bone cancer, or osteogenesis imperfecta, where the fracture is then properly termed a pathologic fracture.

Although broken bone and bone break are common colloquialisms for a bone fracture, *break* is not a formal orthopedic term.

Effects of smoking:

Smokers generally have lower bone density than non-smokers, so have a much higher risk of fractures. There is also evidence that smoking delays bone healing. Some research indicates, for example, that it delays tibial shaft fracture healing from a median healing time of 136 to a median healing time of 269 days. This means that the fracture healing time was approximately doubled in smokers. Although some other studies show less extreme effects, it is still shown that smoking delays fracture healing.

## 2-4-2 Classification:



**Fig 2-14 Types of fracture**

Compare healthy bone with different types of fractures:

- (a) closed fracture
- (b) open fracture
- (c) transverse fracture
- (d) spiral fracture
- (e) comminuted fracture
- (f) impacted fracture
- (g) greenstick fracture
- (h) oblique fracture

In orthopedic medicine, fractures are classified in various ways. Historically they are named after the doctor who first described the fracture conditions. However, there are more systematic classifications in place currently.

Mechanism:

- Traumatic fracture - This is a fracture due to sustained trauma. e.g.- Fractures caused by a fall, road traffic accident, fight etc.
- Pathologic fracture - A fracture through a bone which has been made weak by some underlying disease is called pathological fracture. e.g.- a fracture through a bone weakened by metastasis. Osteoporosis is the most common cause of pathological fracture.
- Periprosthetic fracture - A fracture at the point of mechanical weakness at the end of an implant

Soft-tissue involvement:

- Closed fracture: are those in which the overlying skin is intact
- Open fracture/Compound fracture: involve wounds that communicate with the fracture, or where fracture hematoma is exposed, and may thus expose bone to contamination. Open injuries carry a higher risk of infection.
  - Clean fracture
  - Contaminated fracture

Displacement:

- Non-displaced

- Displaced
  - Translated
  - Angulated
  - Rotated
  - Shortened

Fracture pattern:

- Linear fracture: A fracture that is parallel to the bone's long axis.
- Transverse fracture: A fracture that is at a right angle to the bone's long axis.
- Oblique fracture: A fracture that is diagonal to a bone's long axis.
- Spiral fracture: A fracture where at least one part of the bone has been twisted.
- Compression fracture/Wedge fracture: usually occurs in the vertebrae, for example when the front portion of a vertebra in the spine collapses due to osteoporosis (a medical condition which causes bones to become brittle and susceptible to fracture, with or without trauma).
- Impacted fracture: A fracture caused when bone fragments are driven into each other.
- Avulsion fracture: A fracture where a fragment of bone is separated from the main mass.

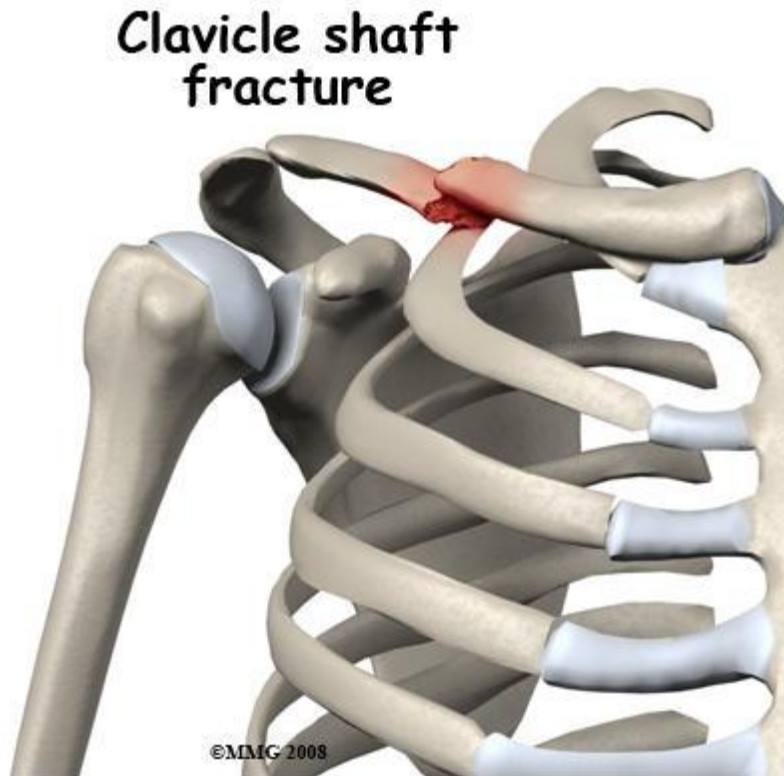
### Fragments:

- Incomplete fracture: A fracture in which the bone fragments are still partially joined. In such cases, there is a crack in the osseous tissue that does not completely traverse the width of the bone
- Complete fracture: A fracture in which bone fragments separate completely.
- Comminuted fracture: A fracture in which the bone has broken into several pieces.

### Anatomical location:

An anatomical classification may begin with specifying the involved body part, such as the head or arm, followed with more specific localization. Fractures that have additional definition criteria than merely localization can often be classified as subtypes of fractures that merely are, such as a Holstein-Lewis fracture being a subtype of a humerus fracture. However, most typical examples in an orthopedic classification given in previous section cannot appropriately be classified into any specific part of an anatomical classification, as they may apply to multiple anatomical fracture sites.

### 2-4-2-1 Fracture clavicle:



**Fig2-15 Clavicle fracture**

The weight of the upper limb is transmitted : - From scapula to clavicle through the coraco-clavicular ligament.

-From clavicle to 1st rib by the costo- clavicular ligament.

- Thus, clavicle fractures under violence between these two ligaments.

The cause is usually a fall on the outstretched hand.

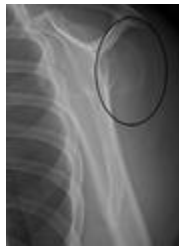The common site for fracture is the point of junction between the lateral **1/3** and medial **2/3** of clavicle.

The Collar bone is so close to the surface of the skin, the fracture is usually visible due to the protruding bone and visible deformity. As with any

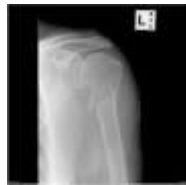fracture there is considerable pain, and bruising may be visible. The patient will often hold their arm in an attempt to relieve the pain.

If the fracture is medial to coraco-clavicular ligament, the lateral part will fall down by the weight of the arm.

#### **2-4-2-2Humerus fracture:**



**Fig2-16 fracture of the greater tuberosity of the humerus**



**Fig2-17Fracture humerus at neck surgical**

A humerus fracture may be classified by the location of the humerus involved: the upper or proximal end, the shaft, or the lower distal. Certain lesions are commonly associated with fractures to occur at the surgical neck of the humerus and anatomical neck of humerus greater and lesser tubercles. This forms the basis for the Neer classification of fractures. Depending on the extent of the injury these fractures may be managed conservatively with a sling or require an open operation to internally fix the fragments. The axillary nerve can be damaged in fractures of this type leading to a

neuropraxia however this may self-resolve. Avascular necrosis may also represent a complication of the fracture or open surgery associated with both deltopectoral (40%) or transdeltoid (10%) approaches during surgery.

Mid-shaft fractures may damage the radial nerve, which traverses the lateral aspect of the humerus closely associated with the radial groove. The median nerve is vulnerable to damage in the supracondylar area, and the ulnar nerve is vulnerable near the medial epicondyle, around which it curves to enter the forearm.

Radiographs are usually considered as a first-line imaging modality to evaluate clinically suspected humerus fracture. US, MRI, and CT are adequate alternatives if radiographs fail to demonstrate the cause of symptoms or do not sufficiently delineate the fracture for management purposes. CT is currently considered the gold standard to diagnose, but has limitations to detect adjacent soft tissue disorders. Depiction of greater tuberosity fractures at US is not uncommon in trauma setting because the fracture may be missed or overlooked at baseline radiographs and the patient will then present for US to scan rotator cuff for abnormalities.

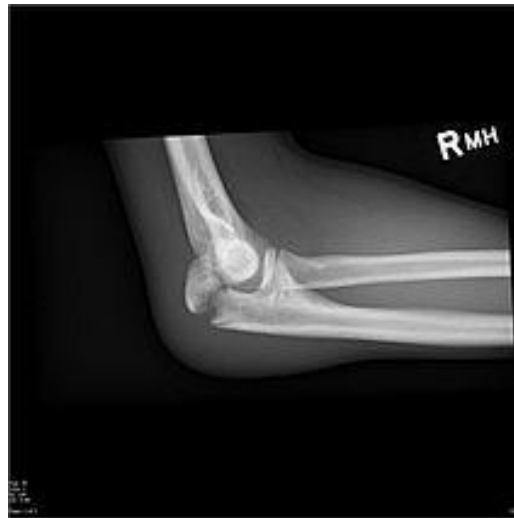### **2-4-2-3 : Elbow fractures:**

They include among others:

- Olecranon fractures.
- Supracondylar humerus fractures.
- Radial head fractures.

#### **2-4-2-3-1:Olecranon fracture:**





**Fig2-18 Olecranon fracture**

Olecranon is the bony point of the elbow. It is the proximal extremity of the ulna which is articulated with the humerus and constituting a part of the elbow articulation. Its subcutaneous situation makes it vulnerable to direct trauma. Powerful pull of the triceps can also cause avulsion fractures. The treatment is often surgery.

Cause:

Olecranon fractures are common. Causes are diverse; it can be a motor vehicle accident, bad fall in sport or a domestic one. They are usually isolated. Or they can be part of a more complex elbow injury.

**Direct trauma:** This can happen in a fall with landing on the elbow. Or by being hit by a solid object. Usually results in comminuted fractures.

**Indirect trauma:** by falling and landing with an outstretched arm.

Classifications:

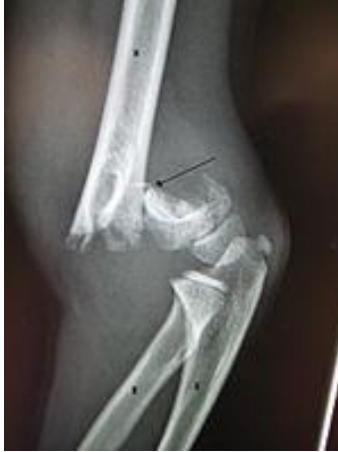Mayo Classification:

Based on the stability, the displacement and the comminution of the fracture.

It is composed of 3 types. And each type is divided in 2 subtypes: subtype A (Non-comminuted) and subtype B (Comminuted).

- Type I: Non-displaced fractures – It can be either non comminuted ones (Type IA) or comminuted (Type IB).
- Type II: Displaced, stable fractures – In this pattern, the proximal fracture fragment is displaced more than 3 mm, but the collateral ligaments are intact. That is why there is no elbow instability. It can be either non-comminuted ones or comminuted .
- Type III: Displaced instable fracture – In this case, the fracture fragments are displaced and the forearm is instable in relation to the humerus. It is a fracture -dislocation. It also may be either non-comminuted or comminuted .

**2-4-2-3-2 Supracondylar humerus fracture:**



**Fig2-19 An elbow X-ray showing a displaced supracondylar fracture in a young child**

A supracondylar fracture is a fracture, usually of the distal humerus just above the epicondyles, although it may occur elsewhere. While relatively rare in adults it is one of the more common fractures to occur in children and is often associated with the development of serious complications.

Classification:

It may be of a flexion type or an extension type, depending upon the displacement of the distal fragment of bone.

*Extension type:* The most common type, accounting for 95% of all supracondylar fractures. The distal fragment is displaced posteriorly.

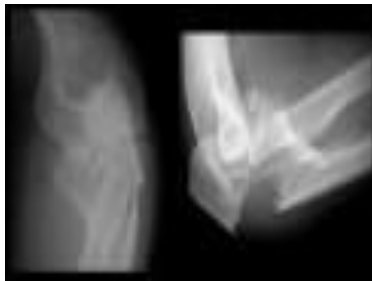
*Flexion type:* The least common variety (5%), where the distal fragment is displaced anteriorly relative to the proximal segment.

*Displacements:* The displacements may present in one of a number of ways: posterior shift, posterior tilt, lateral or medial shift, proximal shift or internal rotation.

Supracondylar fractures can also be categorized by the Gartland classification system, based upon the degree of displacement of the distal fragment.

According to a website for orthopedic surgeons, “This is the most common elbow fracture in children, about 60% of fractures in children. It is most common in children <10, peak incidence is between the ages of 5-8 years of age. Primarily in children who are around age 7 years, which is often a period of maximum ligamentous laxity; therefore, the elbow hyperextends when the child tries to catch himself or herself during a fall. During the hyperextension process, the olecranon (elbow bone) process is forced against the weaker, immature metaphyseal bone of the distal humerus, producing the typical extension-type supracondylar fracture”.

#### **2-4-2-3-3 Radial head fracture:**



**Fig 2-20 Radial head fracture**

Radial head fractures are a type of elbow fracture.

It is not clear if removing fluid from the joint by joint aspiration affects outcomes.

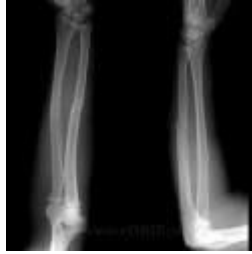#### **2-4-2-4 Forearm fractures:**

Forearm fractures account for most limb fractures. Wrist fractures are the most common forearm fracture. Fracture risk factors include osteoporosis (more common in women than in men) and malignancy (pathological fractures). Fractures of the radius and ulna may occur in isolation - usually due to a direct blow - but these are usually associated with fracture or displacement of the other bone in that forearm. An epidemiological study in Denmark found that 4 out of 5 forearm fractures were treated conservatively.

#### **Classification:**

- Forearm fractures can be classified as either proximal, middle or distal.
- They can affect one or both forearm bones.
- They are either open or closed.
- Proximal forearm fractures may involve the elbow joint (see separate article Elbow Injuries and Fractures; see section below for Monteggia fractures).
- Distal forearm fractures may involve the wrist (see separate article Wrist Fractures)

#### **2-4-2-4-1 Pediatric bone forearm fracture:**



**Fig 2-21 Greenstick fracture**

Fractures may be of greenstick type (incomplete) or complete. A greenstick fracture can occur in one bone with a complete fracture in the other. Complete fractures may be undisplaced, minimally displaced or overriding. Fractures of the proximal third are relatively rare. Middle third fractures account for about 18% of both-bone fractures and distal third fractures for about 75%.

#### **2-4-2-4-2 Ulnar shaft fractures**

- **Definition:** isolated mid-shaft ulnar fractures have the synonym 'nightstick fracture'.

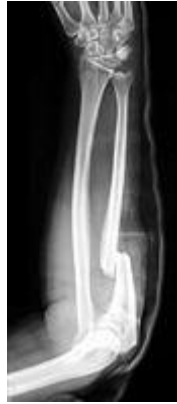Specific fracture types of the ulna include:

- Monteggia fracture - a fracture of the proximal third of the ulna with the dislocation of the head of the radius
- Hume fracture - a fracture of the olecranon with an associated anteriordislocation of the radial head

Classification:

There are four types (depending upon displacement of the radial head):

- I - Extension type (60%) - ulna shaft angulates anteriorly (extends) and radial head dislocates anteriorly.
- II - Flexion type (15%) - ulna shaft angulates posteriorly (flexes) and radial head dislocates posteriorly.
- III - Lateral type (20%) - ulna shaft angulates laterally (bent to outside) and radial head dislocates to the side.
- IV - Combined type (5%) - ulna shaft and radial shaft are both fractured and radial head is dislocated, typically anteriorly



**Fig2-22X-ray of Monteggia fracture of right forearm**

#### **2-4-2-4-3 Radial shaft fractures (Galeazzi fractures):**

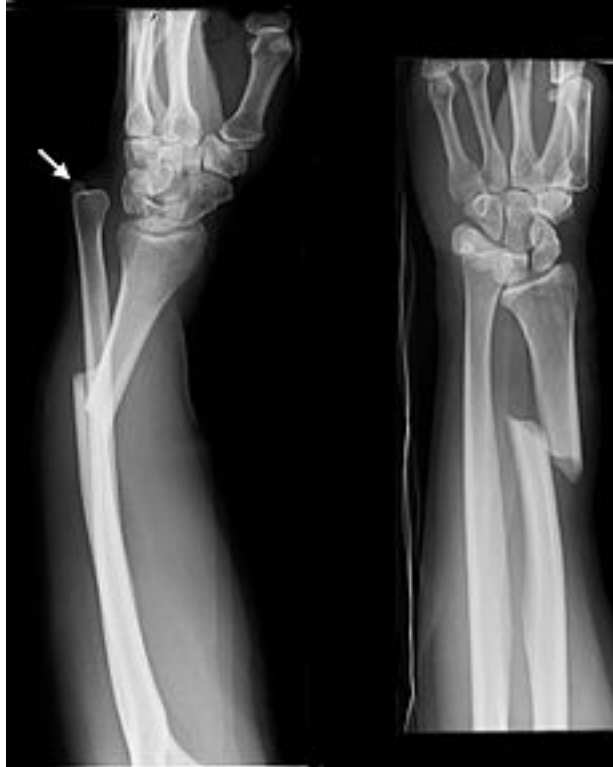

Fig2-23 Galeazzi fractures

Definition: solitary fractures of the distal one third of the radius with accompanying subluxation or dislocation of the distal radioulnar joint (DRUJ). The synonym is reverse Monteggia's fracture.

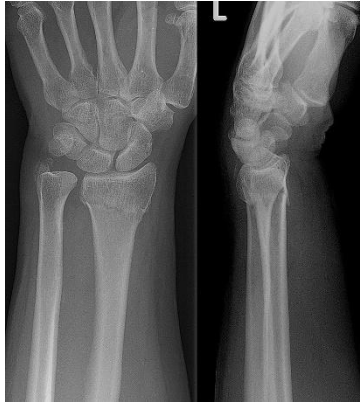**2-4-2-4-4 Distal radius fracture:**

A distal radius fracture is a common bone fracture of the radius in the forearm. Because of its proximity to the wrist joint, this injury is often called a wrist fracture. Treatment is usually with immobilization, although surgery is sometimes needed for complex fractures.

Specific types of distal radius fractures are Colles' fracture; Smith's fracture; Barton's fracture; Chauffeur's fracture (so called because the crank used to start old cars often kicked back and broke the chauffeurs' wrists with a



particular pattern). Most of these names are applied to specific patterns of distal radius fracture but confusion exists because "Colles' fracture" is used as a generic term for distal radius fracture.



**Fig 2-24 Colles fracture**

Classification of wrist fractures:

As with fractures elsewhere in the body, wrist fractures can be:

- Simple
- Compound
- Comminuted
- Greenstick

For a fracture to be compound, the bone does not have to be protruding through the skin. If the bone is fractured and the overlying skin is broken this is a compound fracture and must be treated as such.

**Previous study:**

This study was performed on 1287 patients with upper limb fracture. The male and female patients respectively comprised of 998 (77.5%) and 289 (22.5%) subjects. About 113 patients suffered injuries at shoulderjoint or its surrounding bones. The most common traumatic mechanisms in this group included falls from thestanding position (49.2%), direct hit (19.5%), and then falling down (12.58%). Humerus fractures were observed in 68 patients. There was a significant correlation between humerus fractures and the mechanisms (P=0.000). Thepatients with traumas around the elbow comprised of 182 individuals. Sex distribution of fractures around theelbow shows a significant correlation between sex and elbow fractures. Forearm fractures were observed in 233patients, and there was a significant correlation between age groups and forearm fractures. Fractures around thewrist were observed in 333 patients. There was a significant correlation between patients with fractures around thewrist ( $36.88 \pm 23.81$  years) and patients without fractures ( $30.84 \pm 18.99$  years) around the wrist in terms of the meanage. Hand fractures were observed in 358 patients. There was a significant correlation between hand fractures andsex.

## **Chapter Three**

### **Materials and Methods**

#### **3-1 Material:**

The materials used in this study was balance weight used to measure the patient height, weight as measurement used to measure BMI. The study was carried out in Philips machine in East Nile Hospital, Modern hospital, Digital machine.

### **3-2 Design of the study:**

This study, of a descriptive type where data were collected to classify the bone healing and measuring factors.

### **3-3 Population of the study:**

Adult and children (5-70 years) upnormal who send to x-ray department for upper limbs x-ray examination. If trauma or injury or pathological condition in routine postero-anterior, antero-posterior projections and lateral projection.

### **3-4 Samples and type of the study:**

The data of this study collected 53 patients whom visited East Nile Hospital where the sample were chosen conveniently.

### **3-5 Study area and duration:**

This study conducted in East Nile hospitals, Sudan –Khartoum during the period from September 2014 to May 2015.

### **3-6 Method of Data collection:**

The data were collected using a sheet for all patients in order to maintain consistency of information.

### **3-6-1 Imaging techniques:**

In routine can do postero – anterior (PA), antero-posterior(AP) projections and lateral to this study for the part detected in the upper limbs (clavicle,scapula,shoulder,humerous,elbow,forearm,wrist,hand)x ray.

### **3-6-2 Patient preparation:**

Replace all the material and setting on the chair or stand and explain the procedure to the patient before exam. Distant must be 100 cm. and use the cassette.

The data of this study collected using the following variables: Age, Gender, Weight, height, BMI and healing measurement.

### **3-7 Analysis of data:**

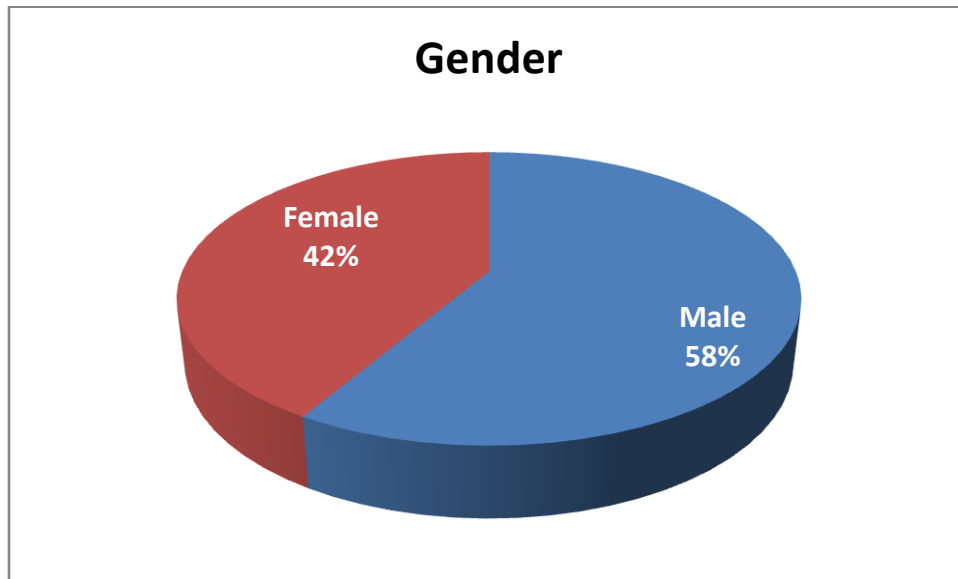
The data was analyzed using computerized statistics for social software (spss),using excel software under windows ,using correlation to estimate the association between the measurement factors(height ,weight,BMI) and the variables collected from the patients bone healing.

## Chapter four Results

### 4-1 Results:

**Table 4-1 frequency distribution table of gender**

<b>Gender</b>	Frequency
Male	31
Female	22
Total	53



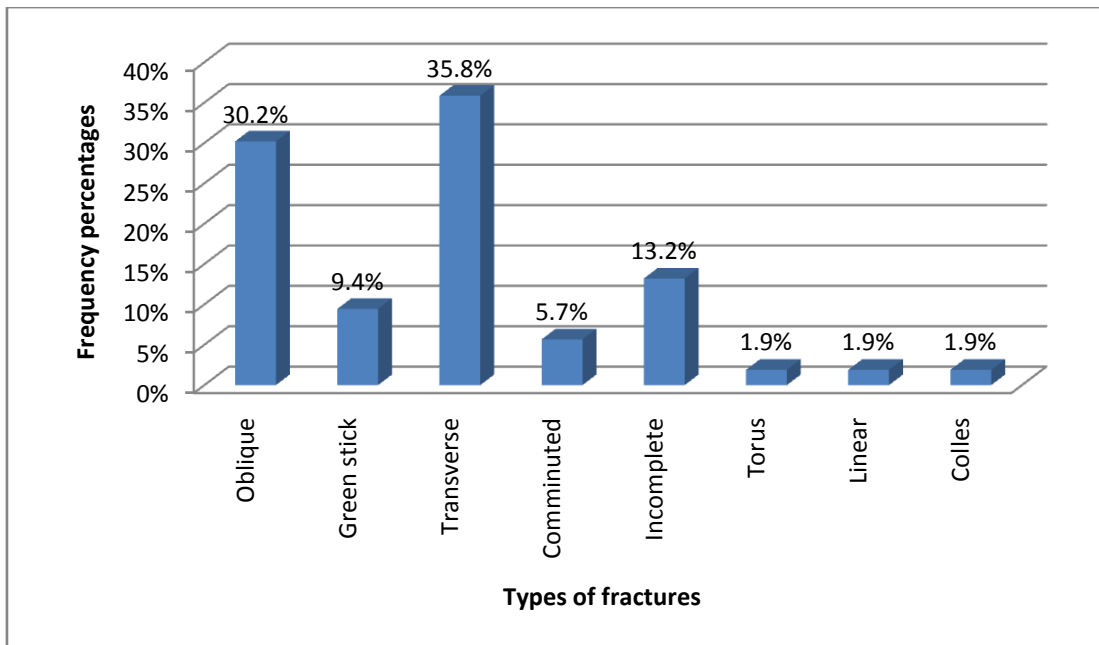
**Figure 4-1 a pie graphs shows the % distribution of gender**

**Table 4-2 the mean and standard deviation of body height, weight BMI and age**

Body characteristics	Mean $\pm$ SD
Length	160.5 $\pm$ 21.1
Weight	66.9 $\pm$ 14.1
BMI	25.8 $\pm$ 3.5
	29.6 $\pm$ 14.6

**Table 4-3 frequency distribution of type of fracture**

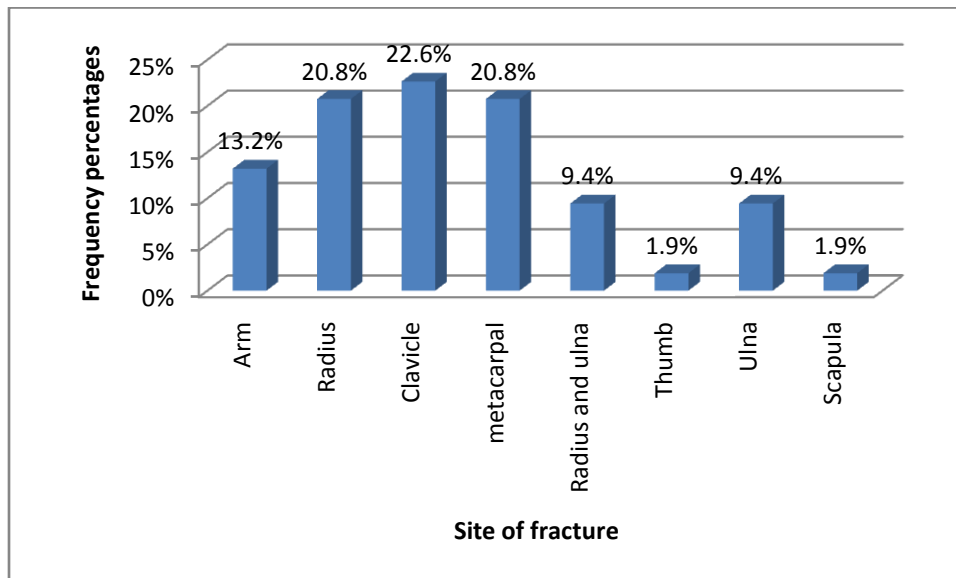
Type of fracture	Frequency
Oblique	16
Green stick	5
Transverse	19
Comminuted	3
Incomplete	7
Torus	1
Linear	1
Colles	1
Total	53



**Figure 4-2 a bar graph of percentage frequency distribution of type of fracture**

**Table 4-4 frequency distribution of fracture site**

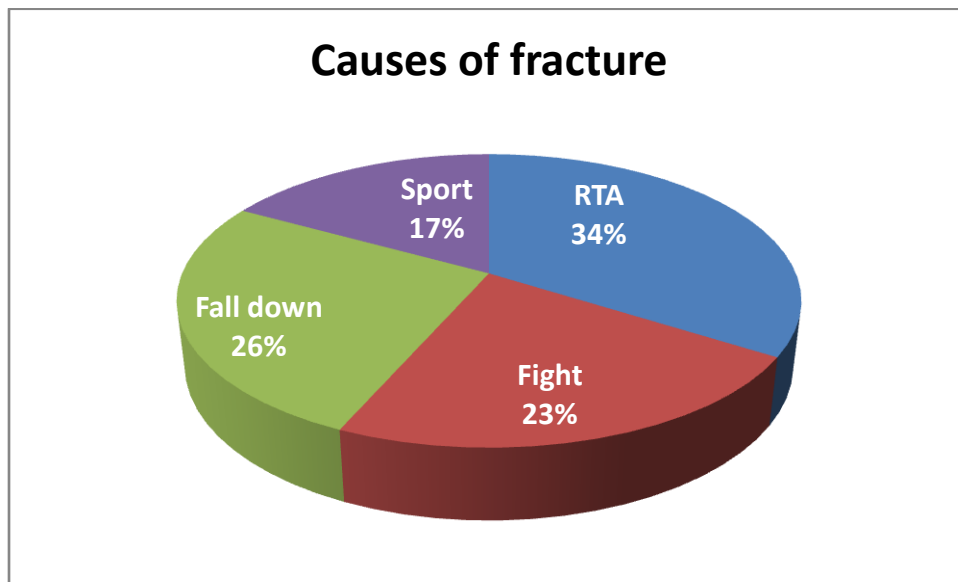
Site of fracture	Frequency
Arm	7
Radius	11
Clavicle	12
Metacarpal	11
Radius and ulna	5
Thumb	1
Ulna	5
Scapula	1
Total	53



**Figure 4-3 a bar graph of percentage frequency distribution of fracture site**

**Table 4-5 frequency distribution of cause of fracture**

<b>Causes of fracture</b>	<b>Frequency</b>
RTA	18
Fight	12
Fall down	14
Sport	9
Total	53

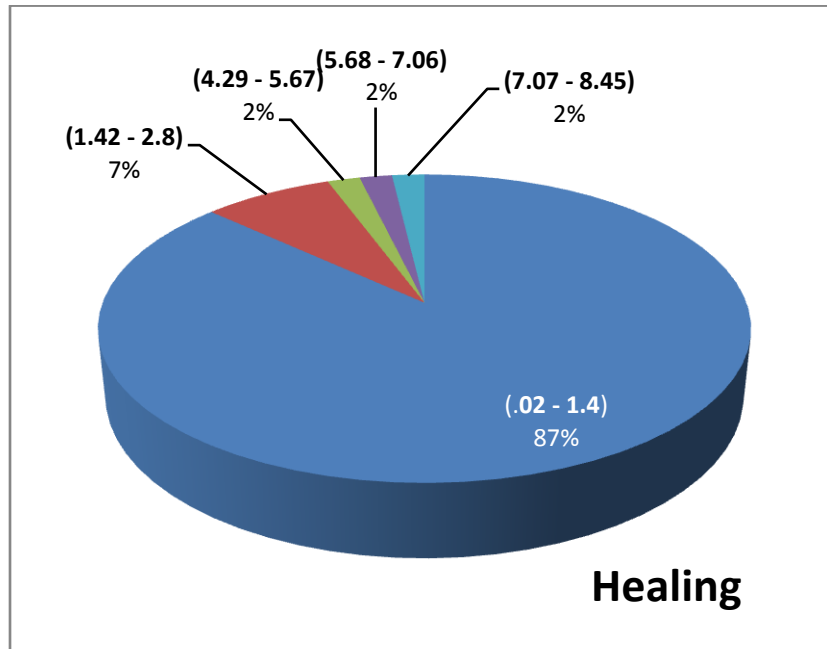


**Figure 4-4 a pie graph of percentage frequency distribution of causes of fracture**



**Table 4-6 frequency distribution of fracture healing**

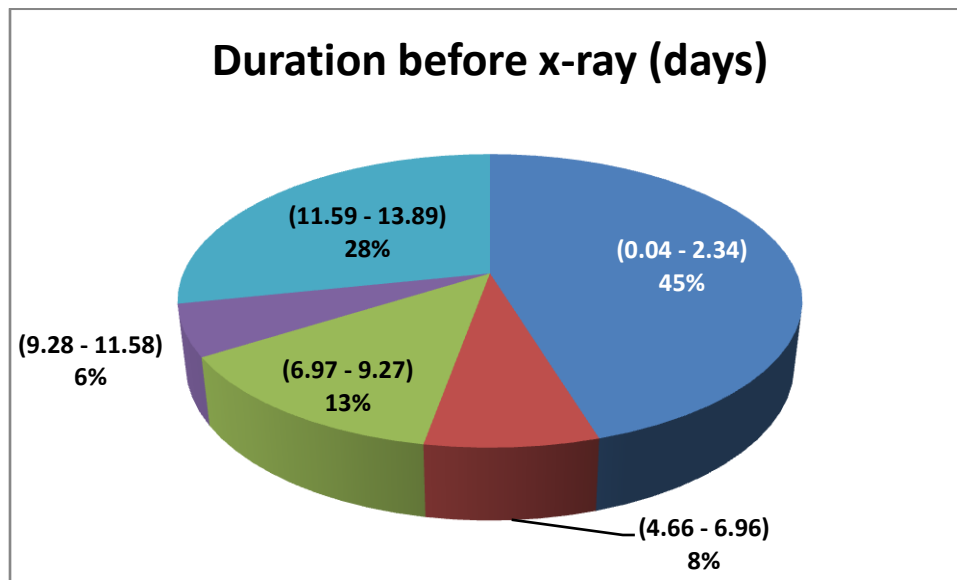
Healing	Frequency
0.02 - 1.4	46
1.42 - 2.8	4
4.29 - 5.67	1
5.68 - 7.06	1
7.07 - 8.45	1



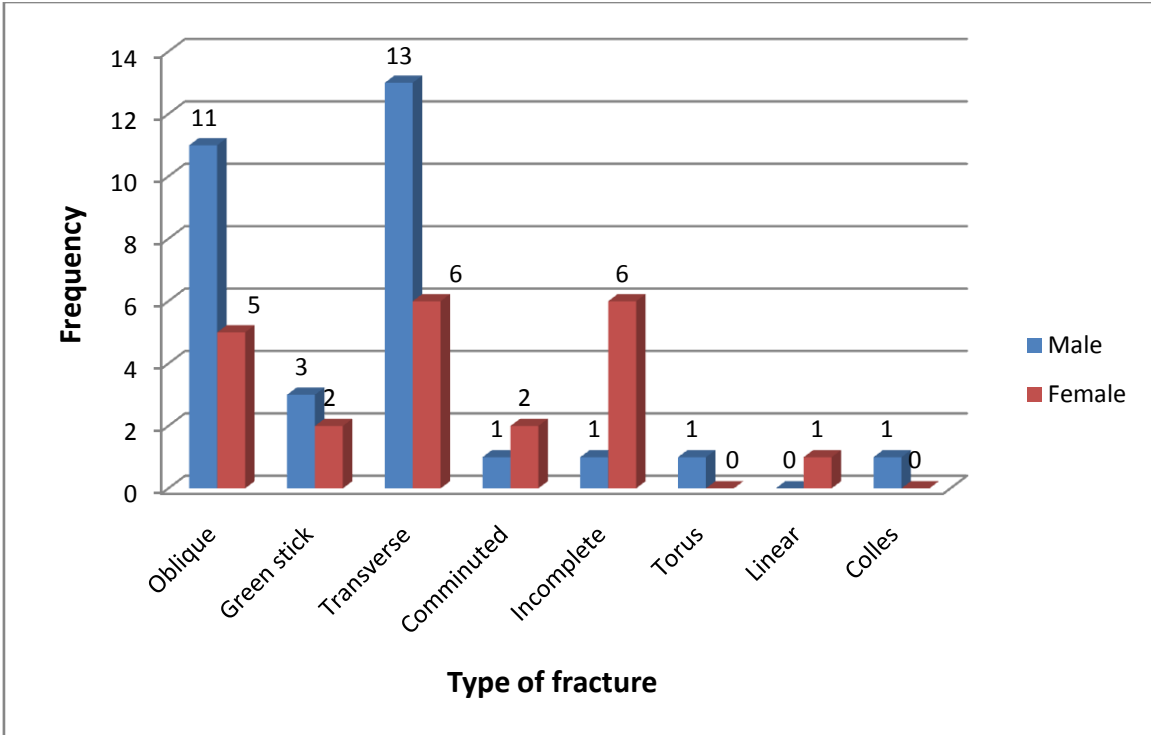
**Figure 4-5 a pie graph of percentage frequency distribution of fracture healing**

**Table 4-7 frequency distribution of duration before x-ray in days**

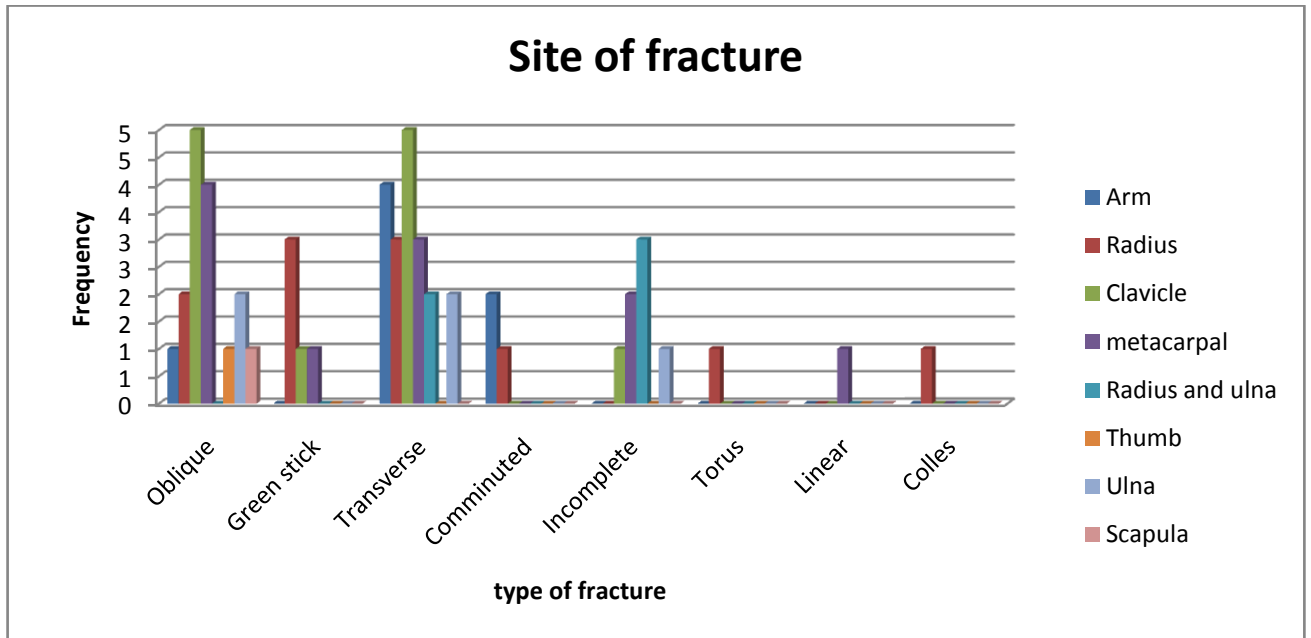
<b>Durationbeforex-ray</b>	<b>Frequency</b>
0.04 - 2.34	24
4.66 - 6.96	4
6.97 - 9.27	7
9.28 - 11.58	3
11.59 - 13.89	15



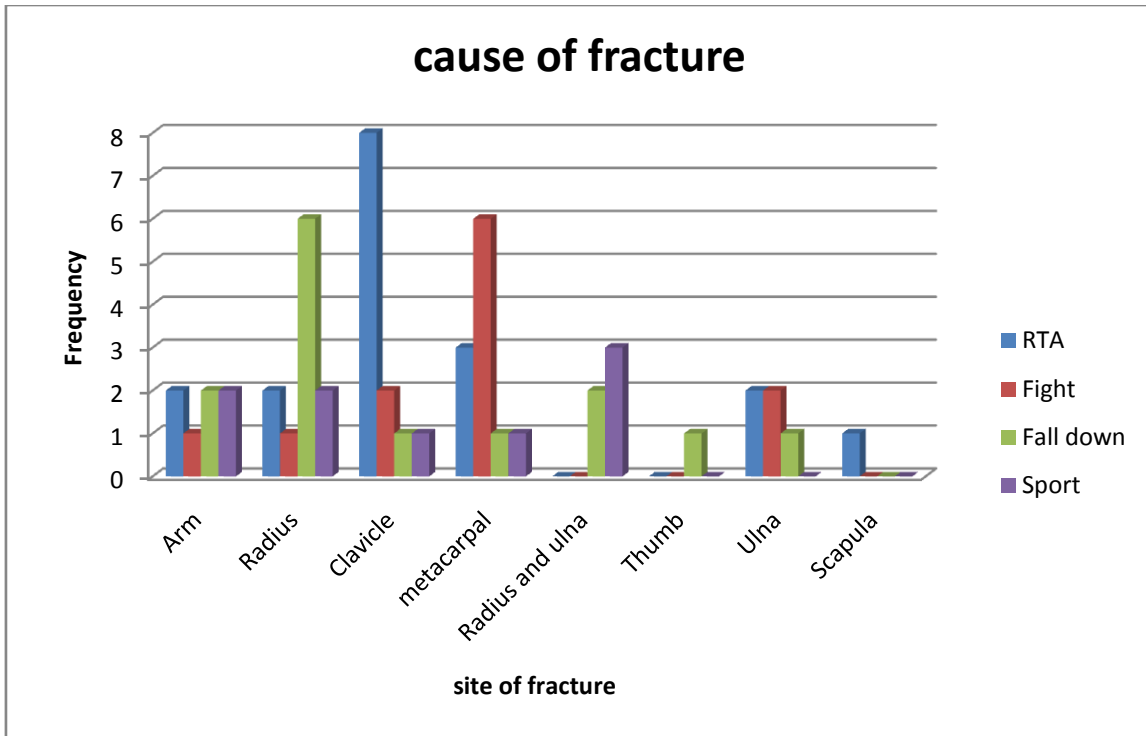
**Figure 4-6 a pie graph of percentage frequency distribution of duration before x-ray**



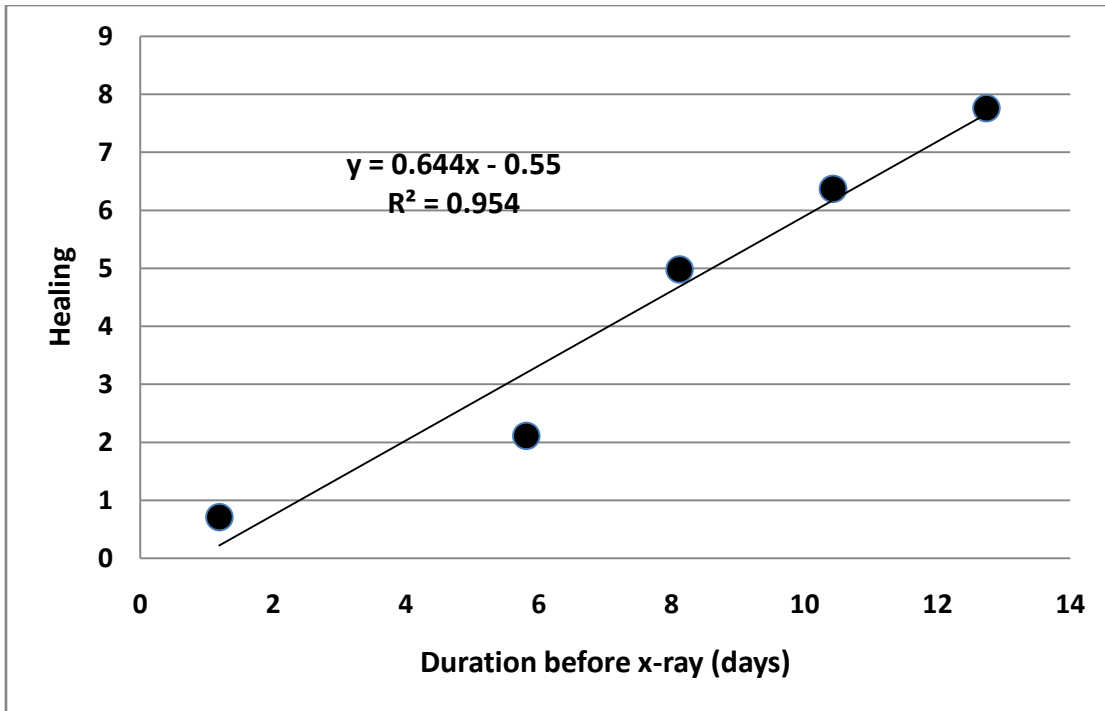
**Figure 4-7 a bar graphs show the type of fracture according to gender (crosstabulation)**



**Figure 4-8 a bar graphs show the type of fracture according to site of fracture (crosstabulation)**



**Figure 4-9** a bar graphs show the site of fracture according to cause of fracture (crosstabulation)



**Figure 4-10 scatter plot show a linear relationship between healing process and the duration before x-ray in days**

# Chapter five

## Discussion, conclusion and Recommendation

### 5-1 Discussion:

The data of this study were collected from 53 patients suffering from upper limb bone fracture for classify purposes. The results of the study showed that male represent 58% of the patients whom suffer from upper limb fracture with male to female ratio of 1.4:1 (Table and Figure 4-1). The mean age of the patient was  $29.6 \pm 14.6$  years with body mass index of  $25.8 \pm 3.5$  kg/m<sup>2</sup>.

Most of the fractures was transverse type which represented 35% of the cases followed by oblique fracture 30.2 the least fractures were Torus, Linear and Colles where each represent 1.9% (Table 4-3 and Figure 4-2).

Fractures mostly occur in the clavicles 22.6% followed by radius and metacarpal 20.8% for each and the least were the thumb and Scapula 1.9% (Table 4-4 and Figure 4-3). Most of the fracture occurs due to road traffic accident (RTA) 34% then fall down 26%, fights 23% followed by sport 17% (Table 4-5 and Figure 4-4). RTA and fall down represented more than 60% of fracture causes.

The frequency distribution of duration before x-ray examination was 45% for the duration ranged from 0.04 to 2.34 days followed by 28% for the duration from 11.6 to 13.9 days (Table 4-7 and Figure 4-6). While the healing process takes place earlier 87% which ranged from 0.02-1.4 (Table

4-6 and Figure 4-5); which means the delay of examination make the reduction worse.

In respect to gender the most common type of fracture in male was oblique and transverse they represent 45.3% (24), while for female the common fractures types was oblique, transverse and incomplete they represents 32.1% (17) the incomplete in male were minimum (Figure 4-7). The oblique and transverse fracture mostly occurs in the clavicles followed by metacarpal and arm then the incomplete fracture in radius and ulna (Figure (4.8). RTA causes 15.1% of the fractures in clavicle and fall down causes 11.3% of the fractures in radius and similarly in metacarpal bones (Figure4-9).

The results of this study showed that there is a direct linear relationship between duration before x-ray and healing, where the healing rate was 0.65/day before the x-ray examination (Figure 4-10)

## **5-2 Conclusion:**

This study aimed to classify trauma for upper limbs x-ray using the body characteristics of patients as an effector and bone healing as response.

The main fractures was transverse followed by oblique fracture and the least were Torus, Linear and Colles .common type of fracture in male was oblique and transverse , while for female the common fractures types was oblique, transverse and incomplete . The oblique and transverse fracture occurs in the clavicles followed by metacarpal and arm then the incomplete fracture in radius and ulna.

The data of this study collected from 53 patient examined by AP,PA and lateral upper limbs x-ray in the period from September 2014 to May 2015 in East Nile Hospital and Modern Hospital in Khartoum using Digital Philips machine.

The measuring factor can be selected objectively using body characteristic length, weight, body Mass index and bone healing.

The results of the study showed that male represent 58% of the patients whom suffer from upper limb fracture with male to female ratio of 1.4:1.

The results of this study showed that there is a direct linear relationship between duration before x-ray and healing,

While the healing process takes place earlier 87% which means the delay of examination make the reduction worse.



### **5-3 Recommendation :**

This study can be extend to include classification lower limbs trauma using x-ray to find differences between them.

- Patient must be careful to do x-ray before complication.
- X ray technician explain to the patient how doing image carefully.
- The doctor only sure that fracture in complete reduction.
- The X-ray machine should be calibrated routinely in order to make sure the exposure factor present real values.
- Careful analysis of reject Film will point out the problem objectively.

## References:

- Brighton, Carl T. and Robert M. Hunt (1986), "Histochemical localization of calcium in the fracture callus with potassium pyroantimonate: possible role of chondrocyte mitochondrial calcium in callus calcification", *Journal of Bone and Joint Surgery*, **68-A (5)**: 703-715
- Brighton, Carl T. and Robert M. Hunt (1991), "Early histologic and ultrastructural changes in medullary fracture callus", *Journal of Bone and Joint Surgery*, **73-A (6)**: 832-847
- Brighton, Carl T. and Robert M. Hunt (1997), "Early histologic and ultrastructural changes in microvessels of periosteal callus", *Journal of Orthopaedic Trauma*, **11 (4)**: 244-253
- Bone formation". *Acta reumatológica portuguesa* **32 (2)**: 103–10. PMID [17572649](#).
- Clinical anatomy eleven edition P 168 -186
- Donoghue PC, Sansom IJ (2002). "Origin and early evolution of vertebrate skeletonization". *Microsc. Res. Tech.* **59 (5)**: 352–72. doi:[10.1002/jemt.10217](#). PMID [12430166](#).
- Good, CR; MacGillivray, JD (February 2005). "Traumatic shoulder dislocation in the adolescent athlete: Advances in surgical treatment". *Curr. Opin. Pediatr.* **17 (1)**: 25–9. doi:[10.1097/01.mop.0000147905.92602.bb](#). PMID [15659959](#).

- Gallucci GL, PiuZZi NS, Slullitel PA, Boretto JG, Alfie VA, Donndorff A, et al. Non-surgical functional treatment for displaced olecranon fractures in the elderly. *Bone Joint J.* Apr 2014;530-4.
- <sup>abcd</sup>HUME AC (August 1957). "Anterior dislocation of the head of the radius associated with undisplaced fracture of the olecranon in children". *J Bone Joint Surg Br* **39-B** (3): 508–12. PMID 13463039. Retrieved 2009-11-09.
- Ham, Arthur W. and William R. Harris (1972), "Repair and transplantation of bone", *The biochemistry and physiology of bone*, New York: Academic Press, p. 337-399
- Murrell GA. Using nitric oxide to treat tendinopathy. *Br J Sports Med* 2007;41(4):227-31.
- McRae, Ronald; Esser, Max (2008). *Practical Fracture Treatment* (5th ed.). Elsevier Health Sciences. p. 187. ISBN 978-0-443-06876-8.
- Predicting Height from the Length of Limb Bones Part of: Examining Effects of Space Flight on the Skeletal System. Emily Morey-Holton. NASA Ames Research Center. Moffett Field, California
- Rodriguez-Merchan EC; Pediatric fractures of the forearm. *Clin Orthop Relat Res.* 2005 Mar;(432):65-72.
- Royal College of General Practitioners. Third National Morbidity Survey in General Practice 1980–1. Series MB5 No 1. London: HMSO; 1986.
- Ross, Lawrence M; Lamperti, Edward D, eds. (2006). *Thieme Atlas of Anatomy: General Anatomy and Musculoskeletal System*. Thieme. ISBN 1-58890-419-9.

- Sellers, Bill (2002). "Functional Anatomy of the Upper Limb". Retrieved June 2011.
- [http://www.wheelessonline.com/ortho/pediatric\\_supracondylar\\_fractures\\_of\\_the\\_humerus](http://www.wheelessonline.com/ortho/pediatric_supracondylar_fractures_of_the_humerus)
- <http://www.eorif.com/Pediatrics/supracondhumerus.html^>
- [http://www.ncbi.nlm.nih.gov/entrez/query.fcgi?cmd=Retrieve&db=mesh&list\\_uids=68003100&dopt=Full](http://www.ncbi.nlm.nih.gov/entrez/query.fcgi?cmd=Retrieve&db=mesh&list_uids=68003100&dopt=Full)