

Sudan University of Science and Technology

College of Graduate Studies

**Immunohistochemical Detection of Cyclin D1 in Ovarian Cancers
Among Sudanese Women**

**الكشف النسيجي الكيميائي المناعي عن السايكلين د1 في اورام المبيض لدى النساء
السودانيات**

**A dissertation submitted in partial fulfillment for the requirements of M.Sc.
Degree in Medical Laboratory Science (Histopathology and Cytology)**

By:

Mohanad Mohammed Mosbah Alhamss

B.Sc. in Medical Laboratory Science (Histopathology and Cytology)

(University of Khartoum 2013)

Supervisor:

Dr. Abu Elgasim Abass AwadElkareem

2017

بِسْمِ اللّٰهِ الرَّحْمٰنِ الرَّحِیْمِ

قال تعالى :

وَيَسْأَلُونَكَ عَنِ الرُّوحِ قُلِ الرُّوحُ مِنْ أَمْرِ رَبِّي وَمَا أُوتِيتُمْ مِنَ الْعِلْمِ إِلَّا قَلِيلًا ﴿٨٥﴾

صدق الله العظيم

سورة الإسراء الآية (85)

I

Dedication

To my father

To my mother

To my sisters

To my sons

To my family

To all my teachers

To all my colleagues and friends

With love and respect.

II

Acknowledgment

I'mgratefull to Allah for the care, insight, peaceful and pity in my life. I would like to express my profound thanks to my supervisor, Dr. Abu ElgasimAbass, for his patience, guidance, unlimited assistance, encouragement and sustained interest throughout the course of this work.

I wish to extend my warmest thanks to the staff of the histopathology and cytology department, college of medical laboratory science, Sudan university of science and technology for their continuous support and encouragement.

Finally, I would like to thanks everybody who imported to the successful realization of this research, as well as expressing my apology to these who I could not mention personally one by one.

Abstract

This an analytical retrospective case control hospital based study was conducted in Radiation and Isotope Center Khartoum (RICK), and national public health laboratory during the period from August 2016 to April 2017. The study aimed to detect cyclin D1 expression in ovarian tumors using immunohistochemistry.

Forty paraffin embedded blocks previously diagnosed as ovarian tumors were collected. Samples include 30(75%) malignant tumors (including serous carcinoma in 14 (35%) samples, mucinous carcinoma in 3 (7.5%) samples, endometrioid carcinoma in 5 (12.5%) samples, clear cell carcinoma in 2 (5%) samples, adenocarcinoma in 4 (10%) samples, germ cell carcinoma in 2 (5%) samples) and 10 (25%) benign samples.

The patient's age ranged between 23 and 70 years with mean age of 46 years, most patients were more than 40 years representing 23 (57.5%) and the remaining 17 (42.5%) patients were less than 40 years.

One section of 3 micrometer thickness was cut from each paraffin block by rotary microtome and stained by immunohistochemical method (indirect streptavidin-biotin immunoperoxidase technique) for detection of cyclin D1. Data collected from patients files and results obtained were analyzed using SPSS computer program.

Immunohistochemical expression of cyclin D1 was revealed positive expression in 18/30 samples and negative result in 12/30 samples in malignant tumors, while all benign tumors gave negative result for cyclin D1 (0/10), with significant statistical association between cyclin D1 expression and histopathological diagnosis of ovarian tumor (P. value = 0.001).

This study concludes that cyclin D1 expression is associated with malignant forms of ovarian tumors.

المستخلص

أجريت هذه الدراسة التحليلية التراجعية المستشفوية الحالة و الحالة الضابطة في المركز القومي للعلاج بالأشعة والطب النووي في ولاية الخرطوم و المعمل القومي للصحة العامة خلال الفترة من أغسطس 2016 إلى أبريل 2017 هدفت الدراسة للكشف عن سايكلين د1 في اورام المبيض باستخدام كيمياء الأنسجة المناعية.

جمعت أربعون عينة مطمورة بشمع البارفين, من عينات مرضى تم تشخيصهم مسبقا بأورام المبيض . تتكون العينات من 30 (75%) عينة لأورام خبيثة , تضمنت سرطان المصل في 14 (35%) من العينات، وسرطان المخاطية في 3 (7.5%) عينة، سرطانبطانة الرحم في 5 (12.5%) عينة، سرطان الخلايا صافية في 2 (5%) عينة، سرطان الخلايا الغديه في 4 (10%) عينة، سرطان الخلايا الجرثومية في 2 (5%) عينة و 10 (25%) عينات لأورام حميدة.

تراوحت اعمار المرضى بين 23- 70 سنة ومتوسط العمر 46 سنة , أغلب المرضى 23 (57.5%) كانت أعمارهم اكثر من 40 سنة وبقية المرضى 17 (42.5%) كانت اعمارهم اقل من 40 سنة.

تم قطع مقطع واحد من كل عينة بسمك $3\mu\text{m}$ بواسطة جهاز المشراح الدوار. تم صبغ العينات بواسطة كيمياء الانسجة المناعية (طريقة تقنية البيوتين المناعي غير المباشرة) للكشف عن سايكلين د1. تم جمع البيانات من ملفات المرضى. تم استخدام برنامج الحزمة الاحصائية للعلوم الاجتماعية SPSS لتحليل البيانات.

أظهرت الدراسة عن التعبير المناعي للواسمة سايكلين د1 انها موجبة الظهور في 30/18 عينة وسالبة الظهور في 30/12 عينة من عينات الاورام الخبيثة بينما كل عينات الأورام الحميدة اظهرت نتائج سالبة للسايكلين د1 مع وجود علاقة احصائية بين السايكلين د1 ونوع الورم (القيمة الاحتمالية=0.001).

خلصت الدراسة الى ان هنالك علاقة بين افراز السايكلين د1 والاورام الخبيثة للمبيض.

List of contents

Content	Page
الآية	I
Dedication	II
Acknowledgement	III
Abstract (English)	IV
Abstract (Arabic)	V
List of contents	VI
List of tables	VIII
List of photographs	IX
Chapter one: Introduction	
1.1 Introduction	1
1.2 Objectives	2
Chapter two: Literature review	
2.1 Scientific background	3
2.2 Structure of the ovary	3
2.2.1 Location and description of ovary	3
2.2.2 Histology and embryology of ovary	3
2.3.1 Disorders of the ovary (benign)	4
2.3.2 Disorder of the ovary (malignant)	5
2.4 Epidemiology of ovarian cancer	7
2.5 Risk factors of ovarian cancer	7
2.6 Diagnosis of ovarian cancer	8
2.7 Treatment of ovarian cancer	9
2.8 Cyclin D1 and its relation with ovarian cancer	10
Chapter three: Materials and methods	
3.1 Materials	11
3.2 Methods	11
3.2.1 Study design	11
3.2.2 Study samples	11
3.2.3 Study area	11
3.2.4 Sample processing	11
3.2.5 Immunohistochemical staining	11

3.2.6 Data analysis	12
3.2.7 Result interpretation	12

VI

Chapter four: Results	
Results	13
Chapter five : Discussion	
Discussion	19
Chapter six : Conclusion and recommendation	
6.1 Conclusion	20
6.2 Recommendations	20
References	21
Appendices 1	27
Appendices 2	28

VII

List of tables

Table	Page
Table (4.1), Distribution of age group among the study population	14
Table (4.2) , Distribution of histopathological diagnosis among the study population	15
Table (4.3), Relation between histopathological diagnosis and cyclin D1 expression	16

VIII

List of photographs

Photograph	Page
Photograph (4.1) Serous carcinoma of ovary shows positive expression of cyclin D1 (40×).	17
Photograph (4.2) Benign ovarian tumor shows negative expression of cyclin D1 (40×).	18

CHAPTER ONE

INTRODUCTION

Chapter one

Introduction

1.1 Introduction:

Ovarian cancer is one of the highly lethal malignancy of the female genital tract due to growth may occur for a long period of time without clinical symptoms and the absence of reliable screening tests in the early stages (Goff, *et al.* 2000).

Worldwide ovarian cancer is the fifth-leading cause of cancer-related deaths in women. It is estimated that in 2016, there will be more than 22,200 new cases of ovarian cancer and more than 14,200 deaths from ovarian cancer in the United States (Doubeni,*et al.*2016).

In Sudan, the incidence rate of the ovarian cancers in Khartoum Sudan during 2009 - 2010 (the specific rate = 8 per 100,000) (Saeed, *et al.*2014).

Risk factors which increase a woman's ovarian cancer include family history, age, childbirth menopause, genetics, previous gynecological problems and lifestyle (Permuth, *et al.*2009).

Methods of ovarian cancer diagnosis include a blood test, magnetic resonance imaging (MRI) or computerized tomography (CT) scan and ultrasound (Gubbels, *et al.* 2010).

The treatment for ovarian cancer depends on the grade and stage of the tumor at presentation. Treatment modalities include either cystectomy, or oophorectomy, salpingo-ophectomy, hysterectomy, chemotherapy and radiotherapy (Nucci and Oliva, 2009).

Cyclin D1 is one of the cell cycle proteins, affects the proliferation of a cell. The expression of cyclin D1 might be responsible for progression and ultimately tumorigenesis of human ovarian cancer epithelial tissues (Wu, *et al.*2009).

Overexpression of cyclin D1 was also observed by Dhare *et al.* in 89% of 81 epithelial ovarian tumor sections in both borderline and invasive tumors. There was no association between protein overexpression and tumor stage or grade of differentiation. Furthermore, no correlation between cyclin D1 expression and clinical outcome was observed (Dhar, *et al.*1999).

The normal ovarian surface epithelium failed to stain with anticyclin D1. Positive immunostaining of cyclin D1 protein was observed in 10 (56%) of 18 ovarian tumors (Shigemasa, *et al.*1999).

1.2 Objectives:

General objective:

To detect cyclin D1 expression in ovarian tumor tissue immunohistochemically and its correlation with histopathological diagnosis.

CHAPTER TWO

LITREATURE REVIEW

Chapter two

Literature review

2.1 Scientific background:

Ovarian cancer is the second most common gynecologic malignancy and the most common cause of gynecologic cancer death in the United States. The majority of ovarian malignancies (95 %) are derived from epithelial cells; the remainder arise from other ovarian cell types (germ cell tumors, sex cord-stromal tumors) (Markman, *et al.* 2001). Ovarian cancer is difficult to detect, especially, in the early stages. This is partly due to the fact that these two small, almond shaped organs are deep within the abdominal cavity, one on each side of the uterus (Wang, *et al.* 2005).

2.2 Structure of the ovary:

2.2.1 Location and description:

Each ovary is an almond-shaped organ, measuring 4×2 cm, and is attached to the back of the broad ligament by the mesovarium. The ovary usually lies in the ovarian fossa, which is bounded by the external iliac vessels above and by the internal iliac vessels and ureter behind. The ovary is surrounded by a thin fibrous capsule, the tunica albuginea, which is covered by a layer of cuboidal cell called germinal epithelium. Before puberty, the ovary is smooth, but after puberty it becomes scarred due to successive corpora lutea degeneration. After the menopause the ovary becomes shrunken (Snell,1995).

2.2.2 Histology and embryology:

The ovary consists of a cortical region and a medullary area. The cortical region consists of follicles (oocytes) that are embedded in the stroma. The medullary region contains a rich vascular bed within a loose connective tissue (Junqnerira and Carneiro, 2005).

2.3 Disorder of the ovary:

2.3.1 Benign disorder:

2.3.1.1 Cystadenofibroma:

Cystadenofibroma is a subset of epithelial ovarian neoplasms that are usually benign. A lesion with a solid portion that exhibits intense contrast enhancement is the prominent feature of cystadenofibroma that mimics malignancy. The presence of rims, plaques, or nodules that have low signal intensity on T2-weighted images and that range from 2 mm to 4 cm in a multiloculated cystic ovarian mass can suggest the diagnosis. The low-signal-intensity foci correspond to intratumoral regions of dense fibrous tissue (Outwater, *et al.*1997).

2.3.1.2 Serous cystadenoma:

These arise from the cuboidal epithelium covering the ovary. This type of benign ovarian tumour is the most common diagnosed in women aged over 40 years, and its presence gives the scarred ovarian surface a smooth appearance (Karlán, *et al.*2012).

2.3.1.3 Mature cystic teratoma:

Mature cystic teratomas are benign germ cell tumors. They usually have the highest sensitivity and specificity for a specific diagnosis with ultrasound as they generally have rather typical features. They are cystic and unilocular in the majority of cases, with mixed echogenicity representing the different components of fat, bone and fluid (Ameye, *et al.*2012).

2.3.1.4 Mucinous cystadenoma:

Mucinous cysts are classically thin walled, large and unilateral. They consist of internal thin-walled locules containing mucin which appears as fluid with low level echogenicity. In general neither serous nor mucinous cystadenomas are associated with significant vascularity (Karlan, *et al.*2012).

2.3.2 Malignant disorder:

2.3.2.1 Serous carcinomas:

Serous carcinomas represent the vast majority of primary malignant ovarian tumors (75%-80%) and are composed of columnar cells with cilia. These tumors are subdivided into high-grade and low-grade serous carcinomas (Malpica, *et al.* 2004).

2.3.2.1.1 High-grade serous carcinoma (HGSC):

These are the most common ovarian carcinomas and most patients present with advanced stage disease (~80%); tumors confined to the ovary at diagnosis are distinctly uncommon (<10%). Microscopically, HGSC show papillary and solid growth with slit-like glandular lumens. The tumor cells are typically of intermediate size, with scattered bizarre mononuclear giant cells exhibiting prominent nucleoli in contrast to LGSCs, these tumors show more than threefold variation in nuclear size. Also, mitotic activity greater than 12/10 high-power microscopic fields (HPFs) favors a diagnosis of HGSC (Prat,2012).

2.3.2.1.2 Low-grade serous carcinoma (LGSC):

LGSC is less common, representing 10%-15% of serous carcinomas and <5% of all ovarian carcinomas. This carcinoma is associated with a serous borderline tumor or represents the recurrent lesion observed after a diagnosis of borderline serous tumor. This tumor is composed of non-hierarchical papillae or micropapillae without nuclear atypia and with less than 12 mitoses per 10 high-

power fields. Patients with these slow growing tumors exhibit a 10-year survival rate of 50% (median overall survival, 82 months) and a relative insensitivity to chemotherapy (Jones, *et al.* 2012).

2.3.2.2 Endometrioid carcinomas:

Endometrioid carcinomas account for 10% of all ovarian carcinomas and are generally unilateral solid masses with a smooth outer surface. These tumors are composed of glands resembling endometrial epithelium and may be associated (23%-42%) with ovarian or pelvic endometriosis. These tumors exhibit CK7-, PAX8-, and hormone (estrogen and progesterone) receptor-positive as well as WT1- and CK20-negative staining; these classifications aid in the distinction from serous and colonic carcinomas, respectively. These tumors are graded into three grades according to the International Federation of Gynecology and Obstetrics (FIGO) system, which is based on the presence of solid areas and the degree of nuclear atypia. Grade 3 tumors tend to harbor *TP53* mutations and may be difficult to distinguish from HGSCs (Geyer, *et al.* 2009).

2.3.2.3 Clear-cell cancers:

Clear-cell cancers account for ~5% of ovarian cancers, although the incidence varies worldwide. The prognosis for stage 1 clear-cell cancers is relatively good. However, advanced stage clear-cell cancers have a worse prognosis than serous ovarian cancers as the tumours tend to be resistant to the standard chemotherapeutic agents used in ovarian cancer. Clear-cell cancers are also strongly associated with endometriosis and a significant proportion carries *ARID1A* mutations (Wiegand, *et al.* 2010).

2.3.2.4 Mucinous carcinomas:

Primary mucinous carcinomas are classified as intestinal tumors (containing goblet cells) and comprise only 2%-3% of ovarian carcinomas. These tumors are unilateral, stage I (75%-80%), large (18-22 cm), and multicystic tumors filled with

mucus. They often contain solid areas. Histologically, they are composed of cysts and glands of variable size, with a confluent pattern and back-to-back glands. Complex papillary architecture is also observed. The cells are tall, columnar, and stratified with basophilic cytoplasm containing mucin. Invasive mucinous carcinomas are sub classified as expansile and infiltrative pattern types (Prat,2012).

2.4 Epidemiology:

The incidence of ovarian cancer varies widely among different populations worldwide with the highest rates reported in Scandinavia, Eastern Europe, Canada, and Africa. The lowest rates have been reported from Asia, with the exception of Japan. The rate of ovarian cancer in Iran has been reported as 3.9 per 100,000 (Haem, *et al.*2015). In Sudan, according to reports derived (2009-2010) from the National Cancer Registry for Khartoum State alone, ovarian cancer was the fourthmost common cancer in women, with an estimated incidence rate of 188 per 100,000 population, a gender specific rate of 8.0 per 100,000 population, and an age standardized rate (ASR) of 7.0 per 100,000 population (Abuidris, *et al.*2016).

2.5 Risk factors:

The risk factors of ovarian cancer include:

2.5.1 Age:

The risk of ovarian cancer increases with age. Women over 50 year have the highest risk of developing ovarian cancer (Roett and Evans, 2009).

2.5.2 Family history:

If a woman's mother or sister has had ovarian, breast, or uterine cancer she is at greater risk of developing ovarian cancer (Permuth, *et al.*2009).

2.5.3 Infertility:

Infertile women and those with a condition called endometriosis and those who use postmenopausal estrogen replacement therapy are at increased risk for ovarian cancer (Pearce, *et al.*2012).

2.5.4 Genetics:

Certain genetic traits can also increase the risk of developing ovarian cancer. Such as women with mutations in the BRCA1 or BRCA2 genes (1 in every 500 women) have a 23-54% risk of developing ovarian cancer (Roett and Evans,2009).

2.5.5 Diabetes:

Developing ovarian cancers has a risk of 20 – 55% higher in diabetic women comparing to non-diabetic ones and slight higher in insulin dependent patient than non-dependent ones (Starup, *et al.*2013).

2.5.6 Obesity/overweight:

Being obese or overweight increases the risk of developing ovarian cancers, and increases the rate of death from these cancers (Cibula, *et al.*2011).

2.5.7 HRT (Hormone replacement therapy):

Slightly increases a women's risk of developing ovarian cancer. Experts say that the risk increases the longer the HRT continues, and returns to normal as soon as treatment stops, being obese or overweight increases the risk of developing many cancers(Permuth, *et al.*2009).

2.5.8 Smoking:

Current smoking has also been associated with decreased risk of clear cell ovarian tumors, however no association was observed with serous and endometrioid tumors; and doubled the risk of mucinous ovarian cancers (Jordan, *et al.*2006).

2.6 Diagnosis of ovarian cancer:

Diagnosis starts with taking history and making physical examination including pelvis, this may be guided by plenty of imaging methods; for instance, CT-scan,

transvaginal ultrasound and MRI. Moreover, biochemical markers should be included, for they help greatly in differential diagnosis and follow up of the disease such as Ca125 which on the other hand showed low value at diagnosis of early stage ovarian cancer. Other markers may include B-HCG, alpha-fetoprotein, and lactate dehydrogenase. Apart from physical examination methods, biological specimens should be adopted for laboratory investigations, this necessitates collecting aspirated fluid from abdominal cavity to check for malignant cells. Then for a definitive diagnosis, the surgical procedure is important to inspect the abdomen. This can be by an open procedure (laparotomy incision) or key surgery

(Laparoscopy) to enable suspicious areas to be biopsied and then sent for microscopically examination (Chobanian and Dietrich, 2008).

2.7 Treatment of ovarian cancer:

2.7.1 Surgery:

Surgery is used to remove as much of the tumour as possible. This is known as debulking surgery or cytoreduction. Patients most commonly have both ovaries removed (bilateral oophorectomy) and a hysterectomy (removal of the uterus). In young women who wish to remain fertile, only the affected ovary is removed and the uterus is left in place (Gubbels, *et al.* 2010).

2.7.2 Chemotherapy:

Chemotherapy after surgery is referred to as 'front-line' or 'first-line' treatment and involves a combination of a platinum and taxane-based chemotherapy (usually carboplatin and paclitaxel). Patients with advanced ovarian cancer who aren't initially able to undergo surgery due to large ascites or invasive tumours can be treated with chemotherapy before being considered for surgery (neoadjuvant treatment) (Hennessy, *et al.* 2009).

2.7.3 Radiation:

Radiation is most often used for palliative purposes and for localized persistent disease after chemotherapy (Roett and Evans,2009).

2.8 Cyclin D1 and it is relation with ovarian cancer:

Cyclin D1 overexpression may play an important role in the tumorigenesis of epithelial ovarian tumors (Shigemasa, *et al.*1999).

Dharet *al.* who used a mouse monoclonal antibody, described overexpression of the cyclin D1 protein in up to 89% of the cancers examined. In their study, the protein expression was spotted in the cytoplasm of the tumor cells in 59% of cases; thus, only 30% of the tumors examined displayed nuclear expression of cyclin D1. Cyclin D1 was overexpressed in both borderline and invasive tumours. There was no association between protein overexpression and tumour stage and differentiation. Furthermore, no correlation between cyclin D1 expression and clinical outcome was observed. However, in tumours overexpressing cyclin D1, the proportion displaying exclusively cytoplasmic localization of protein was higher in those with serous compared with non-serous histology (Dhar, *et al.*1999). According to some authors detected a significant correlation between cyclin D1 expression and malignant potential of the serous ovarian tumors. Moreover, cyclin D1 expression was positively correlated with the advanced stage and tumor grade. The exact impact on tumor biology and the use of cyclin D1 expression in clinical practice remain to be elucidated (Turan, *et al.*2014).

Lin and Yu reported that cyclin D1 expression in malignant tumors and borderline

tumors was significantly higher than that in benign tumors ($P < 0.005$) and normal ovarian tissues ($P < 0.005$). However, there were no significant differences between borderline tumors and malignant tumors ($P > 0.05$), and benign tumors and normal tissue ($P = 0.237$). Overall, cyclin D1 expression was increased from benign to borderline to malignant tumors (Lin and Yu, 2011).

CHAPTER THREE

MATERIALS AND METHODS

Chapter three

Materials and methods

3.1 Materials:

Archived tissue blocks of ovarian tumors were selected for this study.

3.2 Methods:

3.2.1 Study design:

This is hospital based analytical retrospective case control study aimed to detect cyclin D1 expression in ovarian tumors.

3.2.2 Study samples:

Tissue blocks obtained from thirty samples previously diagnosed as malignant ovarian tissue and ten samples which previously diagnosed as benign tumor were collected. Patient's data (age, histopathological diagnosis) were obtained from patients files.

3.2.3 Study area:

This study was held in Radiation and Isotope Center Khartoum (RICK) and national public health laboratory during period from August 2016 to April 2017.

3.2.4 Sample processing:

Sections of 3 μ m thickness was cut by rotary microtome, mounted in positively charged glass slides and put at 60°C oven for 30 minutes.

3.2.5 Immunohistochemical staining:

Immunohistochemical staining was carried out using indirect streptavidin- biotin immune peroxidase technique. Tissue sections (3µm) were deparaffinized in xylene and rehydrated in graded alcohol (100%, 90%, 70%, 50%) and water two minutes for each, then slides were incubated for 10 minutes in 0.3 % hydrogenperoxide to block endogenous peroxidase activity. Antigen retrieval was performed by using PT link water path with citrate buffer (pH 6.8).

The slides then were treated with anti cyclin D1 primary antibody for 30 minutes, then section were incubated in biotinylated secondary antibody for 15 minutes then washed in phosphate buffer saline (pH7.4), incubated in streptavidin-HRP (horseradish peroxidase) for 15 minutes, washed in phosphate buffer saline (pH7.4), incubated in diaminobenzidine tetra hydrochloride (DAB) substrate solution, washed in running tap water. Then counterstained in Mayer'shematoxylin stain for 1 minute. Dehydrated, cleared and mounted in DPX mounting media (Bancroft, *et al.* 2013).

3.2.6 Data analysis:

Data analysis was done using SPSS 20 computer program. Frequencies mean and Chi –square test values were calculated.

3.2.7 Result interpretation:

All quality control measures were adopted; positive and negative control slides were used during immunohistochemical staining. Detection of more than 5 cells with cytoplasm per one field considered as positive result.

3.2.8 Ethical consideration:

Samples were collected after taking ethical acceptance from hospital administration.

CHAPTER FOUR

RESULTS

Chapter Four

4. Results

The age of study population range between 23 and 70 years with mean age of 46 years, and standard deviation 13.8.

Most patient's were more than 40 years representing 23 (57.5%) and the remaining 17 (42.5%) were less than 40 years as indicated in table (4.1).

The study includes forty samples, 30 (75%) samples were malignant and 10 (25%) samples were benign. The diagnosis of malignant samples include serous carcinoma in 14 (35%) samples, mucinous carcinoma in 3 (7.5%) samples, endometrioid carcinoma in 5 (12.5%) samples, clear cell carcinoma in 2 (5%) samples, adenocarcinoma in 4 (10%) samples, and germ cell carcinoma in 2 (5%) samples as indicated in table (4.2).

Cyclin D1 positive expression was found (18/30) in malignant samples, while (12/30) samples showed negative expression, while all benign samples (0/10) showed negative expression for cyclin D1. This result showed significant association (P. value = 0.001) as indicated in table (4.3).

Table (4.1): Distribution of age group among the study population:

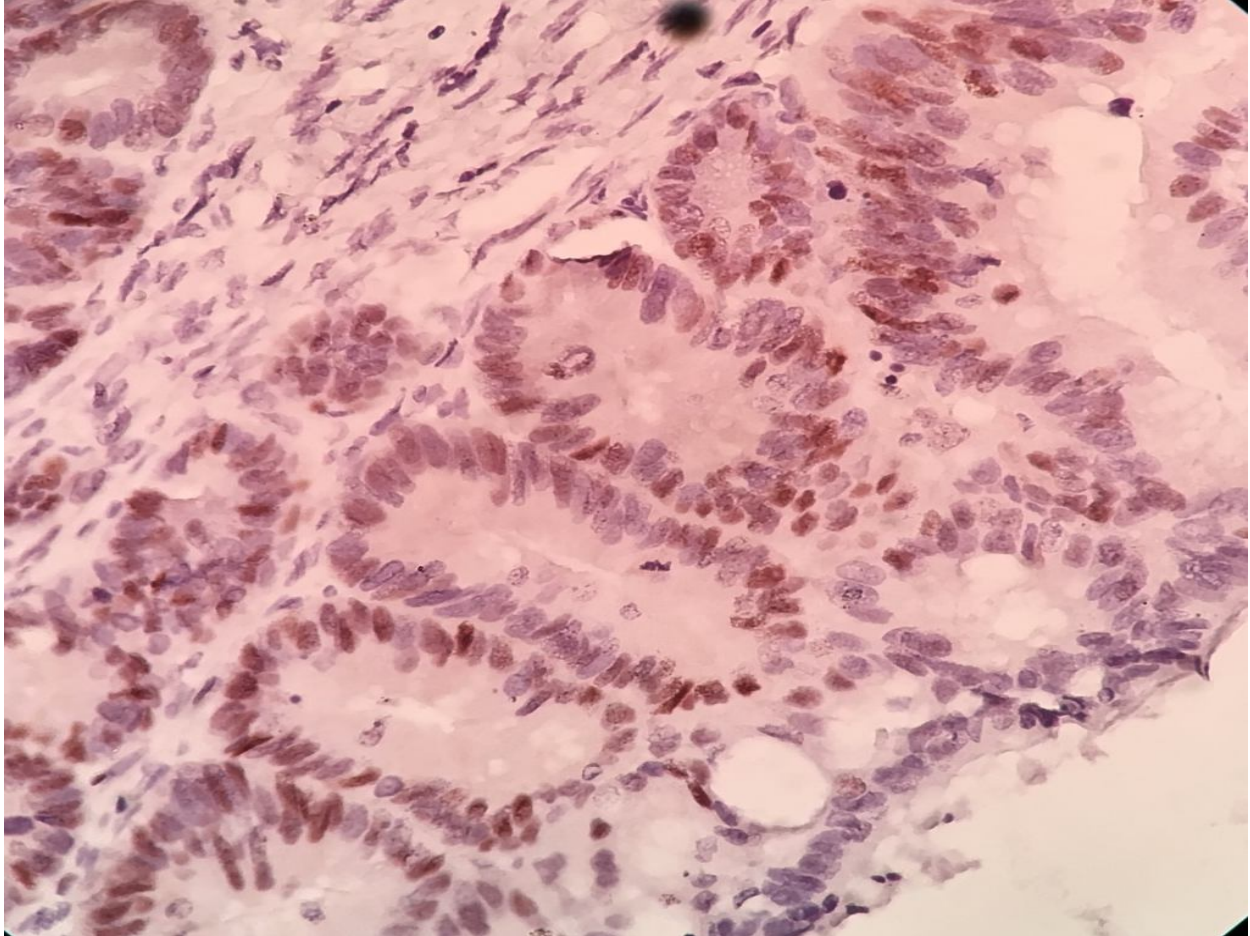
Age group	Frequency	Percentage
Less than 40 years	17	42.5%
More than 40 years	23	57.5%
Total	40	100%

Table (4.2): Distribution of histopathological diagnosis among the study population:

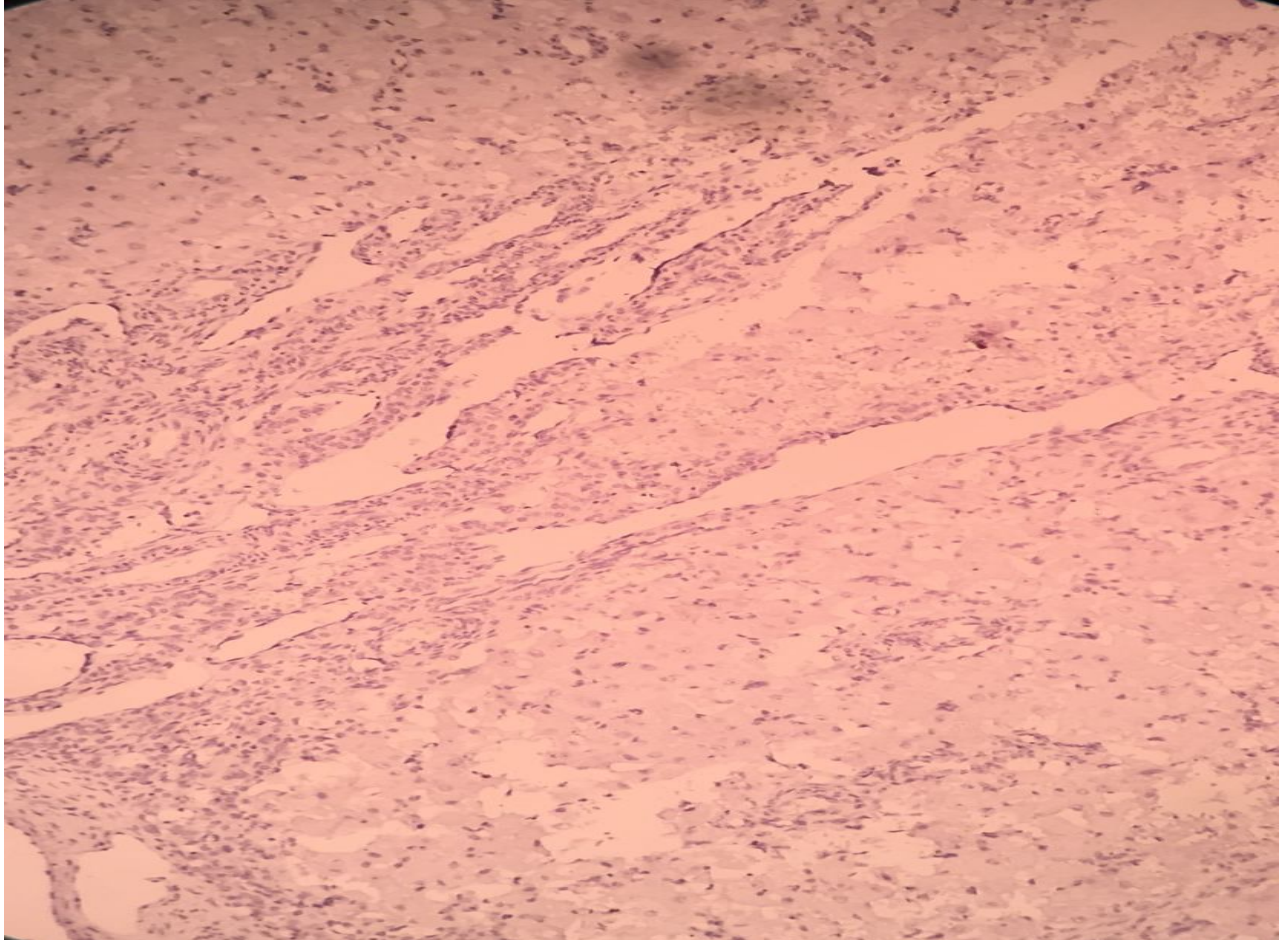
Histopathological diagnosis	Type	Frequency	Percentage
Benign		10	25%
Malignant	Serous carcinoma	14	35%
	Mucinous carcinoma	3	7.5%
	Endometrioid carcinoma	5	12.5%
	Clear cell carcinoma	2	5%
	Adenocarcinoma	4	10%
	Germ cell carcinoma	2	5%
Total		40	100%

Table (4.3): Relation between histopathological diagnosis of ovarian tumor and cyclin D1 expression:

Histopathological diagnosis	Cyclin D1 expression		P. value
	Positive	Negative	
Benign	0 (0.0%)	10 (100%)	0.001
Malignant	18 (45%)	12 (30%)	
Total	18 (45%)	22 (55%)	



Photograph (4.1) Serous carcinoma of ovary show positive expression of cyclin D1 (40×).



Photograph (4.2) Benign ovarian tumor show negative expression of cyclin D1 (40×).

CHAPTER FIVE

DISCUSSION

Chapter Five

5. Discussion

The present study involves 40 cases of ovarian tumors, immunohistochemically stained for cyclin D1. Regarding the age group of patient's, the study revealed that most patients were more than 40 years, indicating that older women are more susceptible to ovarian cancer. This result is compatible with Booth *et al.* (1989), they proved that there was a direct correlation between the age and ovarian cancer, and reported that late menopause and infertility increase the risk of ovarian cancer. Also agree with Abuidris *et al.* (2016), they reported that the incidence rate of ovarian cancer increased greatly in women aged 55 years or older.

The histopathological diagnosis of patients revealed that more frequent type of ovarian cancer was serous carcinoma, this result is compatible with Sarkar *et al.* (2015), they reported that (14 / 20) cases of malignant tumors of ovary were diagnosed as serous carcinoma. Also compatible with Ferrandina *et al.* (2005), they reported that (73 / 110) cases of malignant lesions of ovary were diagnosed as serous carcinoma. Also agree with Lin and Yu (2011), they reported that (21/30) of cases of ovary malignant lesions were diagnosed as serous carcinoma.

Regarding cyclin D1 expression the study found that (18/30) of malignant lesions showed positive expression and (12/30) showed negative expression, while all benign cases of ovarian lesion showed negative expression for cyclin D1. This relation showed significant association (P.valu=0.001). This result is compatible with Lin and Yu(2011), they reported that 90 %(27/30) of malignant lesions showed positive expression, and (2/10) of benign lesions of ovarian showed positive cyclin D1 expression. Also agree with Turan *et al.* (2014), they reported that 95.6 % (22/23) malignant lesions showed positive expression, and positive rate of cyclin D1 in benign ovarian lesions was 48 %(12/25).

CHAPTER SIX

CONCLUSION AND RECOMMENDATIONS

Chapter Six

Conclusion and Recommendations

6.1 Conclusion:

From this study we conclude that:

- The most common age of the ovarian cancer patients is more than 40 years.
- Most histological type of ovarian cancer is serous carcinoma.
- Cyclin D1 expression is associated with malignant forms of ovarian tumors.

6.2 Recommendations:

From this study we recommended that:

Further research should be done on expression of cyclin D1 in ovarian tumors tissue with large sample size.

References

Abuidris, DO., Weng, H-Y., Elhaj, AM., Eltayeb, EA., Elsanousi, M., Iboof RS., *et al.*(2016). Incidence and survival rates of ovarian cancer in low-income women in Sudan, *Molecular and clinical oncology*, **5**(6):823-828.

Ameys, L., Timmerman, D., Valentin, L., Paladini, D., Zhang, J., VanHolsbeke, C., *et al.*(2012). Clinically oriented three-step strategy for assessment of adnexal pathology, *Ultrasound in obstetrics and gynecology*, **40**(5):582–591.

Bancroft, JD., Layton, C., and Kim, S. (2013). *Theory and Practice of Histological Techniques*, 7th Edition, London, Churchill Livingstone, 418.

Booth, M., Beral, V., and Smith, P. (1989). Risk factors for ovarian cancer: a case-control study, *British journal of cancer*, **60**(4):592–598.

Chobanian, N., and Dietrich, CS.,(2008) Ovarian cancer, *The Surgical clinics of North America*, **88**(2): 285 -299.

Cibula, D., Zink, M., Dusek, L., and Majek, O. (2011). Oral contraceptives and risk of ovarian and breast cancers in BRCA mutation carriers: a meta-analysis, *Expert Review of Anticancer Therapy*, **11**(8):1197-1207.

Dhar, KK., Branigan, K., Parkes, J., Howells, RE., Hand, P., Musgrove, C., *et al.*(1999). Expression and subcellular localization of cyclin D1 protein in epithelial ovarian tumour cells, *British journal of cancer*, **81**(7):1174–1181.

Doubeni, CA., Doubeni, AR., and Myers, AE.(2016).Diagnosis and Management of Ovarian Cancer, *American family physician*, **93**(11):937-944.

Ferrandina, G., Legge, F., Martinelli, E., Ranelletti, FO., Zannoni, GF., Lauriola, L., *et al.*(2005). Expression of survivin in ovarian cancer, *British Journal of Cancer*, **92**(2):271 – 277.

Geyer, ET., Lopez-garcia, MA., Sanchez-Estevez, C., Sarrio, D., Moreno-Bueno, G., Franceschetti, I.,*et al.*(2009) Pathogenetic pathways in ovarian endometrioid adenocarcinoma: a molecular study of 29 Cases, *The American journal of surgical pathology*, **33**(8):1157-1163.

Goff, BA., Mandel, L., Muntz, HG., and Melancon, CH. (2000). Ovarian carcinoma diagnosis, *Cancer*, **89**(10):2068–2075

Gubbels, JAA, Claussen, N., Kapur, AK., Connor, JP., and Patankar, MS. (2010).The detection, treatment, and biology of epithelial ovarian cancer, *Journal of Ovarian Research*, **3**(1):8.

Haem, E., Heydari, ST., Zare, N., Lankarani, KB., Barooti, E., *et al.*(2015). Ovarian Cancer Risk Factors in a Defined Population Using Rare Event Logistic Regression, *Middle East Journal of Cancer*, **6**(1):1-9.

Hennessy, BT., Coleman, RL., and Markman, M. (2009). Ovarian cancer, *Lancet*, **374**(9698):1371–1382.

Jones, S., Wang, TL., Kurman, RJ., Nakayama, K., Velculescu, VE., Vogelstein, B., *et al.* (2012). Low-grade serous carcinomas of the ovary contain very few point mutations, *The Journal of pathology*, **226**(3):413-420.

Jordan, SJ., Whiteman, DC., Purdie, DM., Green, AC., and Webb, PM. (2006) Does smoking increase risk of ovarian cancer? A systematic review, *Gynecologic oncology*, **103**(3):1122–1129.

Junqnerira, CL., and Carneiro, J. (2005) The female reproductive system, ovary. Basis Histology text and atlas, 11th Edition, United State of America: McGraw. Hill Companies;. P. 435 – 441.

Karlan, BY., Bristow, RE., and Li, AJ. (2012). Gynecologic Oncology: Clinical Practice & Surgical Atlas. 1st Edition, McGraw-Hill Medical; New York, NY.

Le, D-C., Kubo, T., Fujino, Y., Sokal, DC., Vach, TH., Pham, T-M., *et al.* (2012). Reproductive factors in relation to ovarian cancer: a case–control study in Northern Vietnam, *Contraception*, **86**(5):494-499.

Lin, S., and Yu, HS. (2011). Clinical Significance of Nucleostemin Expression and Its Correlation With Cyclin D1 Expression in Malignant Ovarian Tumors, *International Journal of Gynecological Cancer*, **21**(7):1166-1171.

Malpica, A., Deavers, MT., Lu, K., Bodurka, DC., Atkinson, EN., Gershenson, DM., *et al.* (2004). Grading ovarian serous carcinoma using a two-tier system, *The American journal of surgical pathology*, **28**(4):496–504.

Markman, M., Bundy, BN., Alberts, DS., Fowler, JM., Clark-Pearson, DL., Carson, LF., *et al.*(2001). Phase III trial of standard-dose intravenous cisplatin plus paclitaxel versus moderately high-dose carboplatin followed by intravenous paclitaxel and intraperitonealcisplatin in small-volume stage III ovarian carcinoma: an intergroup study of the Gynecologic Oncology Group, Southwestern Oncology Group, and Eastern Cooperative Oncology Group, *Journal of clinical oncology*,**19**(4):1001–1007.

Nucci, RM., and Oliva, E., (2009). Surface epithelial stromal tumour of the ovary. *Gynecologicopathology*, 1st Edition. China: Elsevier Churchill Livingstone;393-607.

Outwater, EK., Siegelman, ES., Talerman A., and Dunton, C. (1997). Ovarian fibromas and cystadenofibromas: MRI features of the fibrous component, *Journal of Magnetic Resonance Imaging*,**7**(3):465 –471.

Pearce, CL., Templeman, C., Rossing, MA., Lee, A., Near, AM., Webb PM., *et al.*(2012). Association between endometriosis and risk of histological subtypes of ovarian cancer: a pooled analysis of case-control studies, *The lancet oncology*, **13**(4):385-394.

Permuth-Wey and Sellers, (2009). Epidemiology of Ovarian Cancer, *Methods of Molecular Biology*, Cancer Epidemiology, **472**:413-437.

Prat, J. (2012), Ovarian carcinomas: five distinct diseases with different origins, genetic alterations, and clinicopathological features, *VirchowsArchiv : an international journal of pathology*, **460**(3): 237-249

Roett, MA., and Evans, P. (2009).Ovarian cancer: an overview, *American Academy of Family Physicians*, **80**(6):609-616.

Saeed, IE., Weng, H-Y., Mohamed, KH. and Mohammed, SI. (2014). Cancer incidence in Khartoum, Sudan: First results from the cancer registry, 2009-2010, *Cancer Medicine*, **3**(4):1075–1084.

Sarkar, M., Jha, T., Das, TK., Sau, V., Mitra, S., and Roy, K. (2015). Spectrum of epithelial ovarian tumors with HER2/neu expression by the carcinomas among patients admitted in a tertiary care hospital in Eastern India, *International Journal of Medical Science and Public Health*, **4**:1388-1392.

Shigemasa, K., Tanimoto, H., Parham, GP., Parmley, TH., Ohama K., and O'Brien, TJ. (1999). Cyclin D1 Overexpression and p53 Mutation Status in Epithelial Ovarian Cancer, *Journal of the Society for Gynecologic Investigation*,**6**(2):102-108.

Snell SR. (1995). The pelvic cavity of female genital tract, ovary. *Clinical Anatomy for medical students*, 5TH Edition United State of America: Brown and Company, 320–321.

Starup-Linde, J., Karlstad, O., Eriksen, SA., Vestergaard, P., Bronsveld, HK., de Vries F., *et al.*(2013) CARING (CAncer Risk and INsulinanaloGues): the association of diabetes mellitus and cancer risk with focus on possible determinants - a systematic review and a meta-analysis.,*Current Drug Safety*, **8**(5):296-332.

Turan, G., Usta, CS., Usta, A., Kanter, M., Tavli, L., Karacan, M., *et al.* (2014). The expression of HER-2/neu (c-erbB2), survivin and cyclin D1 in serous ovarian neoplasms: their correlation with clinicopathological variables, *Journal of molecular histology*, **45**(6):679–687.

Wang, V., Li, C., Lin, M., Welch, W., Bell, D., Wong, Y-F., *et al.* (2005). Ovarian cancer is a heterogeneous disease, *Cancer genetics and cytogenetics*, **161**(2):170–173.

Wiegand, KC., Shah, SP., Al-Agha, OM., Zhao, Y., Tse, K., *et al.* (2010). ARID1A mutations in endometriosis associated ovarian carcinomas, *The New England journal of medicine*, **363**(16):1532–1543.

Wu, GQ., Xie, D., Yang, GF., Liao, YJ., Mai, SJ., Deng, HX., *et al.* (2009). Cell cycle-related kinase supports ovarian carcinoma cell proliferation via regulation of cyclin D1 and is a predictor of outcome in patients with ovarian carcinoma, *International journal of cancer*, **125**(11):2631-2642.

Appendix 1:

Materials and instruments used for processing and staining of the specimens include:

Disposable gloves.

Rotary microtome.

Microtome knives.

Positively charged slides (Thermo).

Cover glasses.

Dry oven.

Water path (Dako water path).

Coplin jars.

Humidity chamber.

Ethanol (100%, 90 %, 70 %, 50 %).

Xylene.

Mayer`s haematoxylin.

Citrate buffer (pH6.8).

Phosphate buffer (PH7.4).

0.3 Hydrogen peroxidase.

Primary antibody (Cyclin D1).

Secondary antibody (biotinylated secondary antibody).

Streptavidin-HRP

Substrate chromogen (DAB).

DPX

Appendix 2:



**FLEX
Monoclonal Rabbit
Anti-Human
Cyclin D1
Clone EP12
Ready-to-Use
(Dako Autostainer/Autostainer Plus)**

English

Code IS083

Intended use

For *in vitro* diagnostic use.

FLEX Monoclonal Rabbit Anti-Human Cyclin D1, Clone EP12, Ready-to-Use, (Dako Autostainer/Autostainer Plus) is intended for use in immunohistochemistry together with Dako Autostainer/Autostainer Plus instruments. Antibodies to cyclin D1 are useful for the identification of mantle cell lymphomas (1-3). The clinical interpretation of any staining or its absence should be complemented by morphological studies using proper controls and should be evaluated within the context of the patient's clinical history and other diagnostic tests by a qualified pathologist.

Synonyms for antigen

PRAD-1, CCND1, Bcl-1 (1).

Summary and explanation

Cyclin D1 is a 36 kDa protein encoded by the CCND1 (bcl-1) gene located on chromosome 11q13. Cyclin D1 associates with and activates cyclin-dependent kinases (CDKs) CDK4 and CDK6 (1,4,5). The protein functions as a CDK-dependent regulator of the cell cycle by phosphorylating and inactivating the retinoblastoma protein, thereby allowing for progression through the G1-S phase of the cell cycle (1,4,5). Cyclin D1 is also involved in cell cycle and CDK-independent functions including associating with and regulation of a variety of transcription factors and transcriptional co-regulators. Cyclin D1 has also been shown to be involved in the regulation of cellular metabolism, fat cell differentiation and cell migration (1,4,5). Cyclin D1 overexpression is associated with tumorigenesis, and cyclin D1 amplification and/or overexpression have been demonstrated in a variety of human tumors, including mantle cell lymphomas, breast carcinomas, head and neck squamous cell carcinomas and esophageal cancers (1,6). Among lymphoid neoplasms, a subset of chronic lymphocytic leukemia, small lymphocytic lymphoma and multiple myeloma have been reported to express Cyclin D1. The following neoplasms were reported to be negative for Cyclin D1: diffuse large B-cell lymphoma, extranodal marginal zone lymphoma of MALT, follicular lymphoma, marginal zone lymphoma, lymphoplasmacytic lymphoma (II and IB lineage), extranodal NK/T-cell lymphoma, peripheral T-cell lymphoma, NOS, anaplastic large cell lymphoma, Hodgkin lymphoma (7, 8).

Refer to Dako's General Instructions for Immunohistochemical Staining or the detection system instructions of IHC procedures for: 1) Principle of Procedure, 2) Materials Required, Not Supplied, 3) Storage, 4) Specimen Preparation, 5) Staining Procedure, 6) Quality Control, 7) Troubleshooting, 8) Interpretation of Staining, 9) General Limitations.

Reagent provided

Ready-to-use monoclonal rabbit antibody provided in liquid form in a buffer containing stabilizing protein and 0.015 mol/L sodium azide.
Clone: EP12.

Immunogen

Synthetic peptide corresponding to residues near the C-terminus of human cyclin D1.

Specificity

In Western blotting of MCF7 cells lysates the antibody labels a major band of approximately 36 kDa, corresponding to the expected molecular weight of cyclin D1.

Precautions

- For professional users.
- This product contains sodium azide (NaN₃), a chemical highly toxic in pure form. At product concentrations, though not classified as hazardous, sodium azide may react with lead and copper plumbing to form highly explosive build-ups of metal azides. Upon disposal, flush with large volumes of water to prevent metal azide build-up in plumbing.
- As with any product derived from biological sources, proper handling procedures should be used.
- Wear appropriate Personal Protective Equipment to avoid contact with eyes and skin.
- Unused solution should be disposed of according to local, State and Federal regulations.

Storage

Store at 2-8 °C. Do not use after expiration date stamped on vial. If reagents are stored under any conditions other than those specified, the conditions must be verified by the user. There are no obvious signs to indicate instability of this product. Therefore, positive and negative controls should be run simultaneously with patient specimens. If unexpected staining is observed which cannot be explained by variations in laboratory procedures and a problem with the antibody is suspected, contact Dako Technical Support.

Specimen preparation including materials required but not supplied

The antibody can be used for labeling immunohistochemical tissue sections. Tissue specimens should be cut into sections of approximately 4 µm.

Pre-treatment with heat-induced epitope retrieval (HER) is required using Dako PT Link (Code PT100/PT101). For details, please refer to the PT Link User Guide. Optimal results are obtained by pre-treating tissues using EnVision™ FLEX Target Retrieval Solution, High pH (50x) (Code K8010/K8004) for 20 minutes at 97°C followed by 5 minutes in EnVision™ FLEX Wash Buffer (Code K8007).

Paraffin-embedded sections. Pre-treatment of formalin-fixed, paraffin-embedded tissue sections is recommended using the 3-in-1 specimen preparation procedure for Dako PT Link. Follow the pre-treatment procedure outlined in the package insert for EnVision™ FLEX Target Retrieval Solution, High pH (50x) (Code K8010/K8004).

Note: After staining the sections must be dehydrated, cleared and mounted using permanent mounting medium.

The tissue sections should not dry out during the treatment or during the following immunohistochemical staining procedure. For greater adherence of tissue sections to glass slides, the use of Dako Sitanized Slides (Code S3003) is recommended.

Staining procedure including materials required but not supplied

The recommended visualization system is EnVision™ FLEX, High pH, (Dako Autostainer/Autostainer Plus) (Code K8010) used according to the protocol given below. Reagents must be appropriately diluted before use. All steps should be performed at room temperature (20-25 °C).

- Incubate tissue section with 200 µL EnVision™ FLEX Peroxidase-Blocking Reagent (DM821) for 5 (±1) minutes
- Rinse in EnVision™ FLEX Wash Buffer (Code K8007) for 1-5 minutes
- Incubate tissue section with 200 µL primary antibody (Code IS083) for 20 (±1) minutes
- Rinse in EnVision™ FLEX Wash Buffer (Code K8007) for 1-5 minutes
- Incubate tissue section with 200 µL EnVision™ FLEX-HRP (Code DM822) for 20 (±1) minutes
- Rinse in EnVision™ FLEX Wash Buffer (Code K8007) for 1-5 minutes
- Incubate tissue section with 200 µL EnVision™ FLEX Wash Buffer (Code K8007) for 5 (±1) minutes
- Rinse in EnVision™ FLEX Wash Buffer (Code K8007) for 1-5 minutes
- Incubate tissue section with 200 µL EnVision™ FLEX Substrate Working Solution (Codes DM823 and DM827) for 5 (±1) minutes
- Incubate tissue section with 200 µL EnVision™ FLEX Substrate Working Solution (Codes DM823 and DM827) for 5 (±1) minutes
- Rinse in EnVision™ FLEX Wash Buffer (Code K8007) for 1-5 minutes
- Counterstain slide with EnVision™ FLEX Hematoxylin (Code K8018) for 5 (±1) minutes
- Rinse in deionized water for 1-5 minutes
- Incubate tissue section with 200 µL EnVision™ FLEX Wash Buffer (Code K8007) for 5 (±1) minutes
- Rinse in deionized water for 1-5 minutes
- Mount slides with permanent mounting medium.

Programmin out for reagents