



**Sudan University of Sciences and technology**

**College of Graduate studies**



**Evaluation of the Role of Ultrasound in Post-menopausal Vaginal  
Bleeding Using Ultrasonography**

تقييم دور الموجات فوق الصوتية في النزيف المهبلي بعد انقطاع الطمث

A Thesis Submitted for Partial Fulfillment of the Requirements of M.Sc.  
Degree in Medical Diagnostic Ultrasound

By

Nehad Ali Mohamed Idris

Supervisor:

Dr. Mohamed Elfadil Mohamed Garelnabi

Associated professor

2017

## آية

قال الله تعالى:

(وَعَلَّمَ آدَمَ الْأَسْمَاءَ كُلَّهَا ثُمَّ عَرَضَهُمْ عَلَى الْمَلَائِكَةِ فَقَالَ أَنْبِئُونِي بِأَسْمَاءِ هَؤُلَاءِ إِنْ كُنْتُمْ صَادِقِينَ (31) قَالُوا سُبْحَانَكَ لَا عِلْمَ لَنَا إِلَّا مَا عَلَّمْتَنَا إِنَّكَ أَنْتَ الْعَلِيمُ الْحَكِيمُ (32) قَالَ يَا آدَمُ أَنْبِئْهُمْ بِأَسْمَائِهِمْ فَلَمَّا أَنْبَأَهُمْ بِأَسْمَائِهِمْ قَالَ أَلَمْ أَقُلْ لَكُمْ إِنِّي أَعْلَمُ الْغَيْبَ السَّمَاوَاتِ وَالْأَرْضِ وَأَعْلَمُ مَا تُبْدُونَ وَمَا كُنْتُمْ تَكْتُمُونَ) (33)

صدق الله العظيم

الآيات 31- 33 سورة البقرة

## *Dedication*

I dedicate my dissertation work to my family and many friends. A special feeling of gratitude to my loving parents, Ali and Fatima whose words of encouragement and push for tenacity ring in my ears. My sisters Alia, Wafaa and Raghad, my brothers (Mussab and Ziad whom never left my side and are very special.

I also dedicate this dissertation to my many friends whom supported me throughout the process. I will always appreciate all they have done,

I dedicate this work and give special thanks to my best friend Elbushra and my wonderful sister Rahba for being there for me throughout the entire program. Both of you have been my best cheerleaders.

# *Acknowledgement*

First of all I thank Allah the almighty for helping me to complete this thesis.

I thank Prof. Mohammed Elfadil my supervisor for his help and guidance.

I am also indebted to my brother Dr. Abdelrahman Hassan who has been a constant source of encouragement and enthusiasm, not only during this thesis project but also during years of my Master program.

My Thank extend to anyone who help me to complete this study, with his full patience cooperation.

I owe to the working team in Dar Elelaj Hospital & East Nile Hospital for their helping during the process of data collection.

Finally I would like to thank my friends, teachers and colleagues.

## **Abstract**

This study aimed to evaluate the role of ultrasound in postmenopausal women with vaginal bleeding in order to find out the most common causes of post-menopausal vaginal bleeding on 100 post-menopausal patients with age range (43-80yrs) with vaginal bleeding occurring at least one year after the last menstruation. This was a cross sectional retrospective study was carried out in Khartoum state, Sudan, in ultrasound departments of Dar Alelag Hospital and East Nile Hospital during period from November 2016 to February 2017. The study found that a total of 100 women with post-menopausal vaginal bleeding were evaluated, (33%) of cases had endometrial thickening more than 6mm. Uterine fibroid (26% of cases). Adnexal masses (16% of cases) (12% of cases) were vaginal bleeding due to infection. Endometrial polyp (7% of cases). Cervical mass (6% of cases). Higher frequency of post menopausal women with vaginal bleeding was occurred between ages (60-69 year). (33%) of cases was endometrial thickening more than 6 mm. also there is a decreased in incidence of post-menopausal vaginal bleeding with increasing parity.

Study concluded that ultrasound was excellent method for evaluation women with post-menopausal vaginal bleeding.

## ملخص الدراسة

هدفت الدراسة لمعرفة دور الموجات فوق الصوتية في تقييم النزيف المهبلي للنساء بعد انقطاع الطمث وأيضا معرفة أكثر الأسباب المؤدية للنزيف المهبلي في مائة امرأة تتراوح اعمارهم من (43-80 سنة) بحالة نزيف مهبلي بعد انقطاع الطمث سنة واحدة علي الأقل. هذه دراسة مقطعة وصفية أجريت في ولاية الخرطوم- السودان في أقسام الموجات فوق الصوتية بمستشفى دار العلاج التخصصي ومستشفى شرق النيل في الفترة من شهر نوفمبر 2016 الي فبراير 2017. تم جمع البيانات وتصنيفها وتحليلها بواسطة برنامج الحزم الاحصائية للعلوم الاجتماعية. وجدت الدراسة بعد تحليل مائة حالة نزيف مهبلي لنساء بعد انقطاع الطمث لهن أن 33% من الحالات كانت لديهم تضخم سمك بطانة الرحم أكثر من 6 ملمترات و 26 من الحالات كانت أورام ليفية في الرحم و 16% كانت لديهم أورام في المبايض و 7% كانت لديهم لحميات في بطانة الرحم و 12% من الحالات كانت نتيجة لالتهابات الحوض و 6% من الحالات كانت نتيجة أورام عنق الرحم ووجدت الدراسة أن هناك نقص في حالات النزيف عند النساء الأكثر انجابا. خلصت الدراسة الا أن الموجات فوق الصوتية كانت طريقة ممتازة لتشخيص أسباب النزيف للنساء ما بعد انقطاع الطمث.

## List of contents

No	Contents	Page no
-	الإية	I
-	Dedication	II
-	Acknowledgement	III
-	Abstract	IV
-	Abstract Arabic	V
-	List of contents	VI
-	List of tables	VII
-	List of figures	VIII
-	List of abbreviations	IX
<b>Chapter one: Introduction</b>		
1.1	Introduction	1
1.2	Problem of the study	3
1.3	Objectives of the study	3
1.4	Significance of the study	3
1.5	Overview of study	3
<b>Chapter Two: Background and Literature Review</b>		
2.1	Anatomy	5
2.2	Physiology	10
2.3	Pathology affect post menopause women	12
2.4	Sonography of post menopause uterus and ovaries.	17
2.5	Previous studies	19
<b>Chapter Three: Materials &amp;Methods</b>		
3.1	Material	23
3.2	Methods	24
<b>Chapter Four: Results</b>		
4.1	Results	26
<b>Chapter Five: Discussion, Conclusion &amp; Recommendations</b>		
5.1	Discussion	32
5.2	Conclusion	35
5.3	Recommendations	36
5.4	Limitation	37
5.5	References	38
-	<b>Appendices</b>	-

## List of tables

<b>Tables No</b>	<b>Subject</b>	<b>Page No</b>
4.1	Frequency distribution of age group	26
4.2	Frequency distribution of PMB causes	27
4.3	Cross tabulation between Causes of PMB & Age in group	28
4.4	Cross tabulation between causes of PMB & LMP	29
4.5	Cross tabulation between Causes of PMB & Parity	30
4.6	statistical analysis of age, LMP & endometrial	31



## List of figures

Figure No	Subject	Page No
2.1	Anatomy of uterus.	9
2.2	Anatomy of ovary.	9
2.3	Changes during menstrual cycle.	12
2.4	FSH, LH and Progesterone levels during the menstrual cycle.	12
2.5	US of endometritis.	13
2.6	US of endometrial atrophy.	14
2.7	US of endometrial polyp.	15
2.8	US of endometrial carcinoma.	16
2.9	US of leiomyoma.	17
2.10	US of normal post menopausal uterus & ovary.	18
3.1	Philips HD7 ultrasound machine.	23
4. 1	Frequency distribution of age group	26
4. 2	Frequency distribution of PMB causes	27
4. 3	Cross tabulation between Causes of PMB & Age	28
4. 4	Cross tabulation between causes of PMB & LMP	29
4.5	Cross tabulation between Causes of PMB & Parity	30

## Abbreviations

ACS	American Cancer Society
CL	Corpus Luteum
EEC	Endometrial Echo Complex
EVS	Endovaginal Scan
ET	Endometrial Thickening
HRT	Hormone Replacement Therapy
LMP	Last Menstrual Period.
PMB	Post Menopausal Bleeding
TVS	Transvaginal Scan
TAS	Transabdominal Scan.

# **Chapter One**

## **1.1 Introduction :**

Ultrasonography is one of the well accepted and high sensitive imaging modality for the diagnosis and follow-up of postmenopausal uterus & ovaries. Advantages of using ultrasonic imaging include its mobility and low cost as well as the ability to measure the dimensions of the uterus and adnexa, check for the presence of masses or cysts and evaluate the structure and echogenicity of the parenchyma. Uterine ultrasound examination provides an objective and precise method for detection of a change in the size and shape and endometrial thickness as well. Postmenopausal vaginal bleeding refers to any vaginal bleeding other than expected cyclic bleeding that occurs with sequential hormone replacement therapy. Menopause women meaning who are without a period for more than one year, you shouldn't have any menstrual bleeding, even a little spotting is not normal after menopause. Although there is no general consensus about the time between menopause and the bleeding episode and its origin. One year is considered to be a sufficient period of time for the stabilization of the endocrine changes and for the definition of bleeding as postmenopausal. (Ruth et al. (2001)).

The most common causes of postmenopausal vaginal bleeding are endometrial atrophy (thinning of the endometrium). The endometrium become very thin after menopause because of lower estrogen levels, this may cause unexpected vaginal bleeding. Other cause includes: polyps, these are growths, usually noncancerous, that can develop in the uterus, on the cervix, or inside the cervical canal. (Rumack et al. (2011)).

Endometrial hyperplasia: In this condition, the lining of the uterus becomes thick, and bleeding may occur as a result, obesity may be the cause of the problem; some women with endometrial hyperplasia may have abnormal cells that can lead to endometrial cancer. Hormone therapy, infection of the

uterus or cervix, leiomyoma of uterus and cervix, use of certain medications such as blood thinners and other types of cancer can cause postmenopausal bleeding. (Rumack et al. (2011)).

Many women who experience postmenopausal bleeding may not have other symptoms than bleeding, but symptoms may be present this can depend on the cause of bleeding. Many symptoms that occur during menopause like hot flashes, often begin to decrease during the postmenopausal time period, there are, however, other symptoms that postmenopausal women may experience include vaginal dryness, stress incontinence, increased urinary tract infections and weight gain. (Moradan et al. (2013)).

Diagnosis of postmenopausal vaginal bleeding by using trans-abdominal sonography for diagnosis clear cause such as fibroid, adnexal masses or transvaginal with or without saline infusion to exclude endometrial cancer. The sonographic scan should be performed transvaginal with a 5- to 10-MHz transducer and an empty bladder, for resolution of the endometrial echotexture, margins, and double-layer thickness measurement. TVS provide us with excellent diagnostic information for assessing the endometrium. Transverse/coronal and longitudinal/sagittal (long-axis) images of the uterus should be obtained in each examination and should also include images of the cervix and fundal and cornual portions of the endometrium. The uterus and adnexa should be imaged in each examination, although it is understood that the ovaries may not be seen on trans abdominal sonography alone is not sufficient in a woman with menopausal vaginal bleeding because of suboptimal resolution of the endometrium and its borders. Endometrial thickness should be measured on a sagittal (long-axis) image of the uterus, and the measurement should be performed on the thickest portion of the endometrium, excluding the junction of the endometrium and myometrium, which may not be visible in all postmenopausal women. In hysteroscopy we show endometrial tissue by inserting a fiber optic scope into the vagina and cervix, and then pump carbon dioxide gas through the scope,

this helps to expand the uterus and makes the uterus easier to seen' (Moradan et al.( 2013)).

## **1.2 Problem of the study:**

The incidence and rate of post-menopausal vaginal bleeding is increased now day and there is a lack in the local studies. In which may cause by many condition related to the pelvic genital organ so the useful ultrasound scan can help in assessing such the morbidity that lead to bleeding.

## **1.3 Objectives of the study:**

### **1.3.1 General objective**

The main aim of this thesis was to evaluate the role of ultrasound in diagnosis of post-menopausal vaginal bleeding causes.

### **1.3.2 Specific objectives**

- To detect the most common causes of post-menopausal vaginal bleeding.
- To correlate causes with age, parity and last menstrual period.

## **1.4 Significance of the study:**

Postmenopausal bleeding is the most common presenting symptom of gynecological pathology and should always be regarded with suspicion and investigated promptly. Ultrasound has revolutionized the evaluation of PMB by providing a minimally invasive means to determine the etiology for the bleeding. It assessment of the endometrial cavity allows treatment to be tailored to the specific cause of vaginal bleeding, thus saving women time, money and exposure to unnecessary interventions.

## **1.5 Overview of the study:**

This study was consist of five chapters, chapter one was an introduction introduce briefly this thesis and contained (problem of study also contain general, specific objectives, significant of the study and overview of the study). Chapter two was anatomy, physiology, pathology literature review (anatomy, physiology, pathology, sonography of postmenopausal uterus and

ovaries. Chapter three was describe the methodology (material, method) used in this study. Chapter four was included result of presentation of final finding of study; chapter five included discussion, conclusion and recommendation for future scope in addition to references and appendices.

# **Chapter Two**

## **Background and Literature Review**



## **Literature Review:**

### **2.1 Anatomy:**

The uterus is a hollow, thick-walled muscular organ. Its internal structure consists of a muscular layer, or myometrium, which forms most of the substance of the uterus, and a mucous layer, the endometrium, which is firmly adherent to the myometrium. The uterus is located between the two layers of the broad ligament laterally, the bladder anteriorly, and the recto sigmoid colon posteriorly. The uterus is divided into two major portions, the body and the cervix, by a slight narrowing at the level of the internal OS. The fundus is the superior area of the body above the entrance of the fallopian tubes. The area of the body where the tubes enter the uterus is called the cornua. The anterior surface of the uterine fundus and body is covered by peritoneum. The peritoneal space anterior to the uterus is the vesico-uterine pouch, or anterior cul-de-sac. This space is usually empty, but it may contain small bowel loops. Posteriorly, the peritoneal reflection extends to the posterior fornix of the vagina, forming the recto-uterine recess, or posterior cul-de-sac. Laterally, the peritoneal reflection forms the broad ligaments, which extend from the lateral aspect of the uterus to the lateral pelvic side walls. (Williams et al. (1989)).

The round ligaments arise from the uterine cornua anterior to the fallopian tubes in the broad ligaments; extend anterolateral and course through the inguinal canals to insert into the fascia of the labia majora. The cervix is located posterior to the angle of the bladder and is anchored to the bladder angle by the parametrium. The cervix opens into the upper vagina through the external OS.

At menopause, the uterus begins to atrophy gradually due hypoestrogenism. Most of the uterine atrophy occurs in the body, resulting in a lower body to cervix ratio. In the seventh and eighth decade, the cervix typically appears larger than the body. Like the uterus, the size of the normal ovary is most

dependent on the age group of the patient (the ovary exhibits only minor changes in volume with the menstrual cycle). The ovary gradually increases in size during infancy and attains its largest volume during the reproductive years; after menopause, the ovary gradually atrophies. (Williams et al. (1989)).

The ovaries are more difficult to find and visualize following menopause for the following reasons: they atrophy and are smaller in volume, reduced blood flow developing and maturing follicles are absent. Ovarian volume decreases gradually with increasing years. The postmenopausal uterus gradually atrophies and in older women may quite small and difficult to visualize. In women who are more than 5 years PM, the uterus measures 3.5 to 7.5 cm in length, 2 to 4 cm in width, and 1.7 to 3.3 cm in anteroposterior dimension, the reduction in uterine size is directly related to years since menopause, and the atrophy is most rapid in the first decade after the onset of menopause. Uterine atrophy is most predominant in the body (the cervix also shrinks but much less than the body). Thus, in post menopause women, the body appears to be small compared to the cervix (mean body-to-cervix ratio of 1.4:1 in postmenopausal women compared to 2:1 in premenopausal women). Cervix called the vaginal fornix. Although the space is continuous, it is divided into anterior, posterior, and two lateral fornices. (Snell, et al. (2005)).

The two fallopian tubes run laterally from the uterus in the upper free margin of the broad ligament. Each tube varies from 7 to 12 cm in length and is divided into intramural, isthmic, ampullary and infundibular portions. The intramural, or interstitial, portion is approximately 1 cm long, is contained within the muscular wall of the uterus, and is the narrowest part of the tube. The isthmus, constituting the medial third, is slightly wider, round, cordlike, and continuous with the ampulla, which is tortuous and forms approximately one-half the length of tube. The ampulla terminates in the most distal

portion, the infundibulum, or fimbriated end, which is funnel shaped and opens into the peritoneal cavity. The ovaries are elliptical in shape, with the long axis usually oriented vertically. The surface of the ovary is not covered by peritoneum but by a single layer of cuboidal or columnar cells called the germinal epithelium that becomes continuous with the peritoneum at the hilum of the ovary. The internal structure of the ovary is divided into an outer cortex and inner medulla.

In the nulliparous female, the ovary is located in a depression on the lateral pelvic wall called the ovarian fossa, which is bounded anteriorly by the obliterated umbilical artery, posteriorly by the ureter and the internal iliac artery, and superiorly by the external iliac vein' (Snell, et al. (2005)).

The fimbriae of the fallopian tube lie superior and lateral to the ovary. The anterior surface of the ovary is attached to the posterior surface of the broad ligament by a short mesovarium. The lower pole of the ovary is attached to the uterus by the ovarian ligament, whereas the upper pole is attached to the lateral wall of the pelvis by the lateral extension of the broad ligament known as the suspensory ligament of the ovary. The suspensory ligament contains the ovarian vessels and nerves. These ligaments are not rigid, and therefore the ovary can be quite mobile, especially in women who have had pregnancies. The arterial blood supply to the uterus comes primarily from the uterine artery, a major branch of the anterior trunk of the internal iliac artery. The uterine artery ascends along the lateral margin of the uterus in the broad ligament and at the level of the uterine cornua, runs laterally to anastomose with the ovarian artery. The uterine arteries anastomose extensively across the midline through the anterior and posterior arcuate arteries, which run within the broad ligament and then enter the myometrium. The uterine plexus of veins accompanies the arteries. The ovarian arteries arise from the aorta laterally, slightly inferior to the renal arteries. They cross the external iliac vessels at the pelvic brim and run

medially within the suspensory ligament of the ovary. After giving off branches to the ovary, the ovarian arteries continue medially in the broad ligament to anastomose with the branches of the uterine artery. The ovarian veins leave the ovarian hilum and form a plexus of veins in the broad ligament that communicate with the uterine plexus of veins. The right ovarian vein drains into the inferior vena cava inferior to the right renal vein, whereas the left ovarian vein drains directly into the left renal vein' (Snell, et al. (2005)).

The lymphatic drainage of the pelvic organs is variable, but tends to follow recognizable patterns. The lymph vessels of the ovary accompany the ovarian artery to the lateral aortic and periaortic lymph nodes. The lymphatics of the fundus and upper uterine body and fallopian tube accompany those of the ovary. The lymphatics of the lower uterine body course laterally to the external iliac lymph nodes, whereas those of the cervix course in three directions: laterally, to the external iliac lymph nodes; posterolaterally, to the internal iliac lymph nodes; and posteriorly, to the lateral sacral lymph nodes. The lymphatics of the upper vagina course laterally with the branches of the uterine artery to the external and internal iliac lymph nodes, whereas those of the middle vagina follow the vaginal artery branches to the internal iliac lymph nodes. The lymphatic vessels of the lower vagina near the orifice join those of the vulva and drain to the superficial inguinal lymph nodes' (Snell, et al. (2005)).

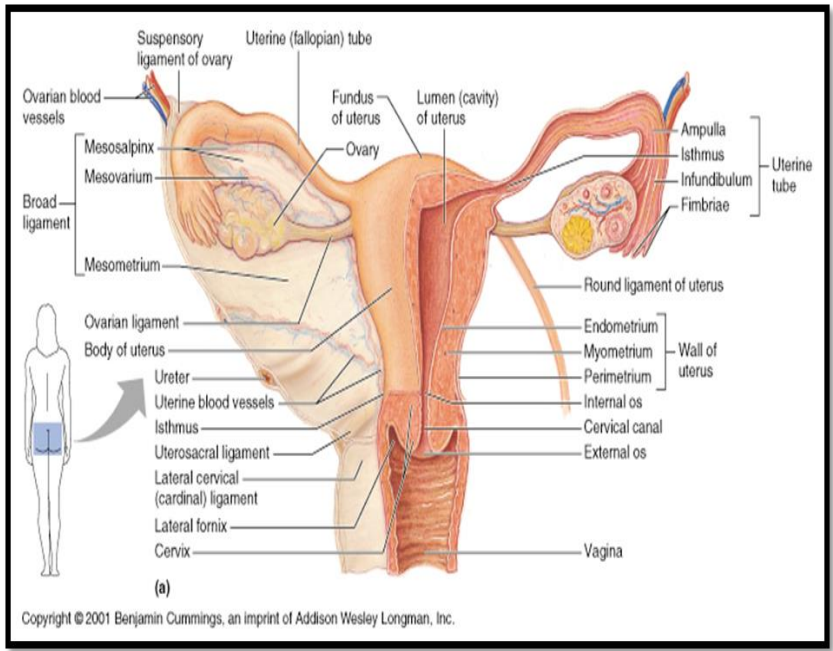


Figure (2.1): Anatomy of uterus. [BodyWellnessProgram.com](http://BodyWellnessProgram.com)

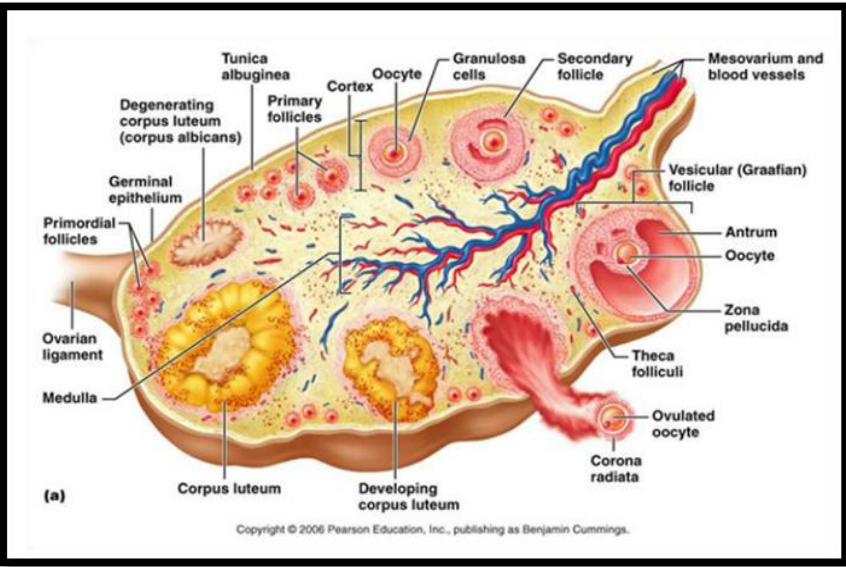


Figure (2.2): Anatomy of ovary. [BodyWellnessProgram.com](http://BodyWellnessProgram.com)

## **2.2 Physiology:**

In the normal female between the age of 9 and 16, cyclic changes occur in the ovaries and uterus in response to endocrinologic activities. These cyclic changes are known as the menstrual cycle and represent the reproductive phase of a female's life cycle. The changes associated with the ovary are known as the ovarian cycle whereas those associated with the endometrium are known as the endometrial cycle. (<https://en.m.wikibooks.org/human-physiology>).

The purpose of the ovarian cycle is to provide a suitable ovum for fertilization, whereas that of the endometrial cycle is to provide a suitable site in which the blastocyst can implant and develop properly. Since the endometrial changes are regulated by the ovarian hormones, the two cycles are intimately related. The typical menstrual cycle is 28 days however variations are very common and normal. For the purpose of description, the 28 day "idealized" cycle is used. The cycle is divided into four or five phases. It is customary to assign the first day of menstruation as the first day of the cycle. Throughout the reproductive years, at the onset of each menstrual cycle, a number of small, immature follicles known as primary or primordial follicles undergo growth and development. The hormonal stimulus that activates the follicular process is mediated by follicle-stimulating hormone which is secreted by the anterior pituitary gland. With each menstrual cycle, there is usually only one mature follicle, known as the dominant or graafian follicle, which makes its way to the surface of the ovary where it appears as a transparent cyst. The mature preovulatory follicle contains the ovum at one end and a cystic cavity or antrum at the other. (<https://en.m.wikibooks.org/human-physiology>).

The ovum is released from the mature follicle during ovulation. Ovulation normally occurs on day 14 which is the mid-point of the idealized cycle. Following ovulation, the ruptured dominant follicle becomes the corpus

hemorrhagicum which is then followed by the corpus luteum. The corpus luteum secretes progesterone (as well as estrogen) which is absolutely necessary to maintain the endometrium for successful implantation. If fertilization does not occur, the CL undergoes regressive changes, progesterone output is diminished, and by the end of the cycle complete regression occurs. The failing CL triggers endometrial sloughing and menstrual bleeding ensues. The end point of the regressing CL is the corpus albicans, which is a small fibrous area in the cortex of the ovary. During menstruation, the functional layer of the endometrium is sloughed off and along with blood, passes into the vagina. Following menstruation, a new functional layer begins to form from the basal layer. Primed by estrogen secreted by the ovary, the endometrium progressively thickens throughout the proliferative and secretory phases. Following ovulation and the formation of the CL, the endometrial glands exhibit secretory activity. If fertilization does not occur, the corpus luteum undergoes regressive changes, and the endometrium, supported by the hormonal output of the ovary, begins to "shrink". The shrinking is due to the loss of tissue fluids and secretions which occurs secondary to the drop in estrogen. Estrogen has a "water-retaining" effect on tissues whereas progesterone is a factor in the secretory activity of the gland. As the endometrium shrinks, the spiral arteries kink resulting in vascular stasis followed by ischemia, necrosis, sloughing and bleeding. (<https://en.m.wikibooks.org/human-physiology>).

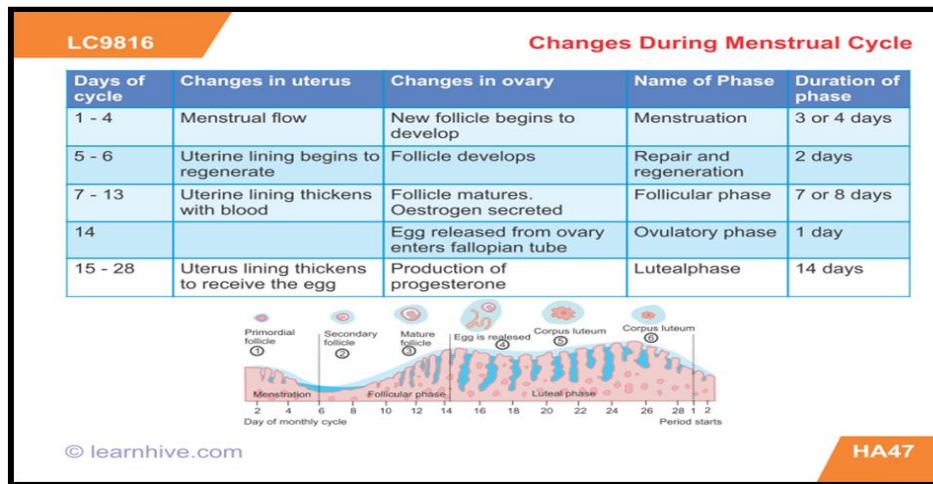


Figure (2.3): Changes during menstrual cycle. Women's Health Network

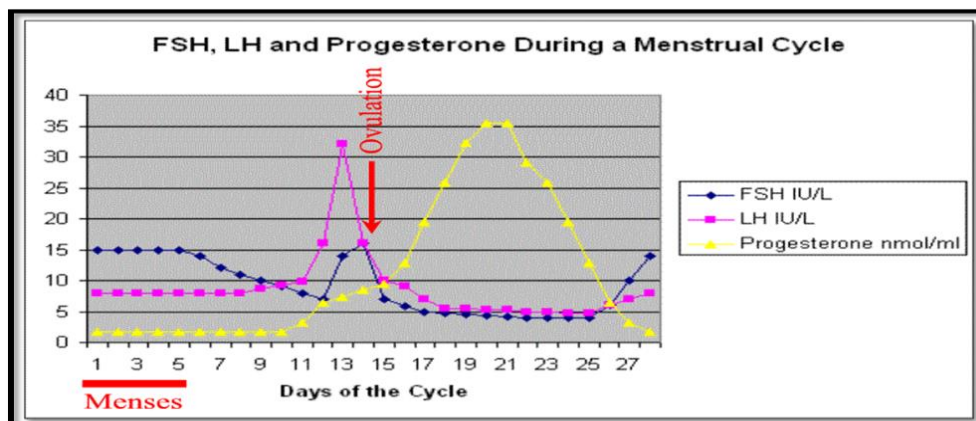


Figure (2.4): FSH, LH and Progesterone levels during the menstrual cycle.

The Brookside Associates

### 2.3 Pathology affects post menopause women:

**Endometritis:** is inflammation of the endometrium and may occur with different situations including following delivery. It is more frequent following cesarean section than vaginal delivery. The most common source of organisms is the normal vaginal flora. Patients with endometritis initially present with fever, chills, uterine bleeding, foul lochia, and abdominal and pelvic pain. Infection may progress into myometrium (myometritis), around the uterus (per metritis), or spread throughout the body, causing septicemia.



The sonographic findings of endometritis include nonspecific endometrial thickening, endometrial fluid, and air. In symptomatic patients, the presence of endometrial fluid with air is strong evidence of infection. (Wachsberg et al. ((1992)).

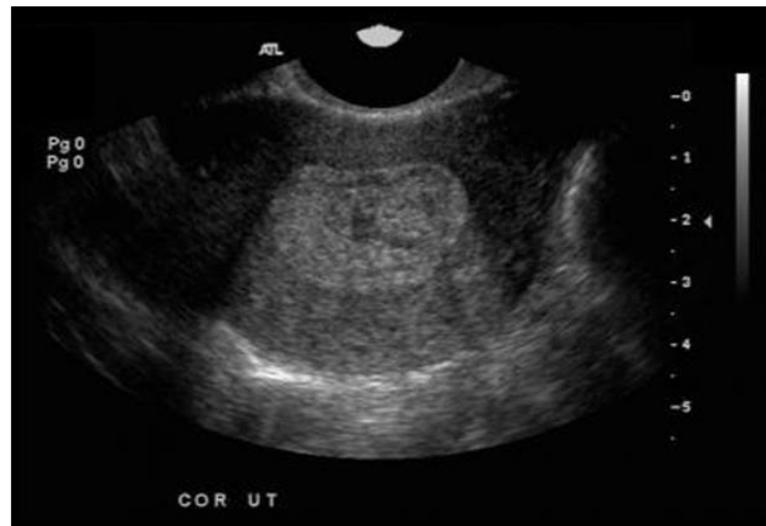


Figure (2. 5): sonogram shows a markedly heterogeneous and thickened endometrium, a finding that is compatible with endometritis.

<https://sites.google.com/site/sonographyfolder>

***Endometrial Atrophy:*** The majority of women with postmenopausal uterine bleeding have endometrial atrophy. On transvaginal sonography, an atrophic endometrium is usually thin, measuring less than 5 mm, and in these patients, no further investigation or therapy is necessary. Histologically, the endometrial glands may be dilated, but the cells are cuboidal or flat, and the stroma is fibrotic. A thin endometrium with cystic changes on transvaginal sonography is consistent with a diagnosis of cystic atrophy, but when the endometrium is thick, the appearance is indistinguishable from that of cystic hyperplasia. (Choo et al. (1985)).

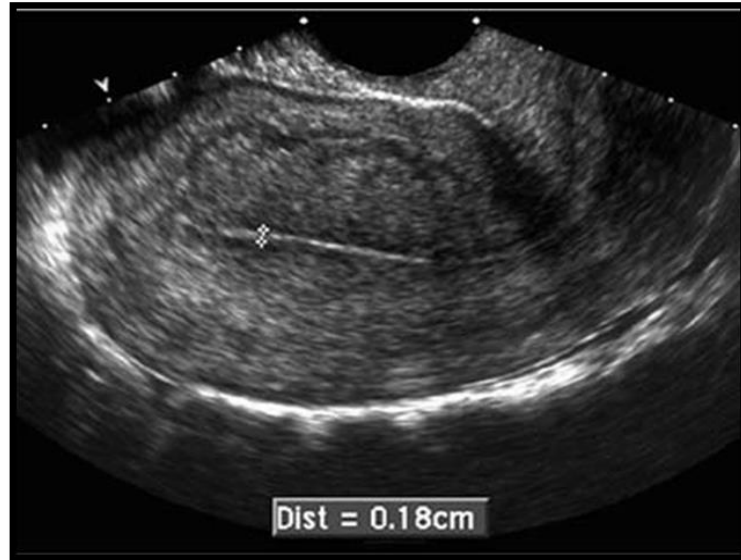


Figure (2. 6) : Sagittal transvaginal US shows a thin postmenopausal endometrium (white arrow) endometrial atrophy. Radiology Key

***Endometrial Polyps:*** are common benign lesions more frequently seen in premenopausal and postmenopausal women. Polyps may cause uterine bleeding, although most are asymptomatic. In the menstruating woman, endometrial polyps may be associated with intermenstrual bleeding or menometrorrhagia and may be a cause of infertility. Histologically, polyps are localized overgrowths of endometrial tissue covered by epithelium and projecting above the adjacent surface epithelium. They may be pedunculated or broad based, or may have a thin stalk. Approximately 20% of endometrial polyps are multiple. Malignant degeneration is uncommon. Occasionally, a polyp will have a long stalk, allowing it to protrude into the cervix or even into the vagina.

On sonography, polyps may appear as nonspecific echogenic endometrial thickening, which may be diffuse or focal. However, they may also appear as a focal, round, echogenic mass within the endometrial cavity. This appearance is much more easily identified when there is fluid within the endometrial cavity outlining the mass. Because fluid is instilled into the endometrial cavity during SHG, this technique is ideal for demonstrating

polyps. SHG is also a valuable technique when transvaginal sonography is unable to differentiate an endometrial polyp from a submucosal leiomyoma. Endocervical polyps are the most common cervical growths, they appear as single smooth or lobulated masses, usually under 3 cm in greatest dimension. They typically manifest as vaginal bleeding or discharge. (Kurman et al.(2002)).

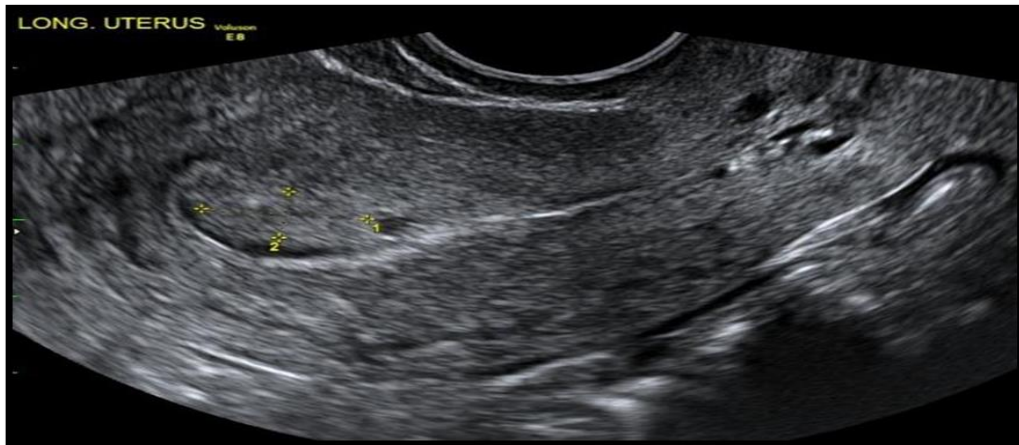


Figure (2.7): Transvaginal ultrasound demonstrates a polyp within the endometrial cavity. Radiopaedia

***Endometrial Carcinoma:*** is the most common gynecologic malignancy in North America. The American Cancer Society estimated 40,100 new cases of endometrial carcinoma. Most of endometrial carcinomas (75%-80%) occur in postmenopausal women. The most common clinical presentation is uterine bleeding, although only about 10% of women with postmenopausal bleeding will have endometrial carcinoma. There is a strong association with estrogen replacement therapy in postmenopausal women and an ovulatory cycles in premenopausal women. Other risk factors include obesity, diabetes, hypertension, and low parity. Approximately 25% of patients with atypical endometrial hyperplasia will progress to well-differentiated endometrial carcinoma (Kurman et al. (2002)).

Sonographically, a thickened endometrium must be considered cancer until proven otherwise. The thickened endometrium may be well defined,

uniformly echogenic, and indistinguishable from hyperplasia and polyps. Cancer is more likely when the endometrium has a heterogeneous echotexture with irregular or poorly defined margins. Cystic changes within the endometrium are more frequently seen in endometrial atrophy, hyperplasia, and polyps but can also be seen with carcinoma. Endometrial carcinoma may also obstruct the endometrial canal, resulting in hydrometra or hematometra' (Kurman et al.( 2002)).

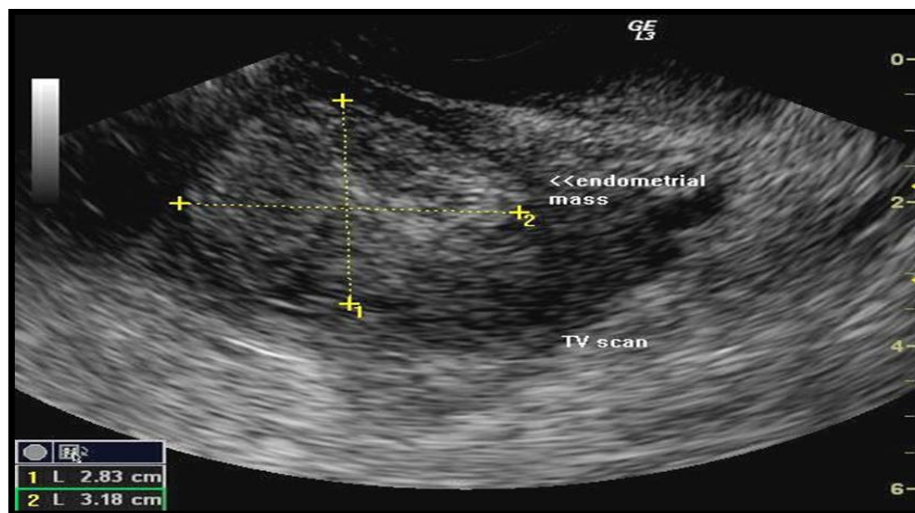


Figure (2.8): Transvaginal sonography of the uterus in postmenopausal patient showed carcinoma of the endometrium (adenocarcinoma).

### Radiopaedia

**Leiomyomas:** (fibroids) are the most common benign neoplasms of the uterus. They occur in 20% to 30% of females over age 30 years and are more common in black women. Fibroids are usually multiple and are the most common cause of enlargement of the nonpregnant uterus. Although frequently asymptomatic, women with leiomyomas can experience pain and uterine bleeding. Leiomyomas may be classified as intramural, confined to the myometrium; submucosal, projecting into the uterine cavity and displacing or distorting the endometrium; or sub serosal, projecting from the peritoneal surface of the uterus. Intramural fibroids are the most common. Submucosal fibroids, although less common, produce symptoms most

frequently and may also be associated with infertility. Sub serosal fibroids may be pedunculated and may present as an adnexal mass. They may also project between the leaves of the broad ligament, where they are referred to as “intraligamentous.” Cervical fibroids account for approximately 8% of all fibroids. Leiomyomas rarely develop in postmenopausal women, and most stabilize or decrease in size after menopause. They may increase in size in postmenopausal patients who are undergoing hormone replacement therapy. A rapid increase in fibroid size, especially in a postmenopausal patient, should raise the possibility of sarcomatous change’ (Smith et al. (1980)).

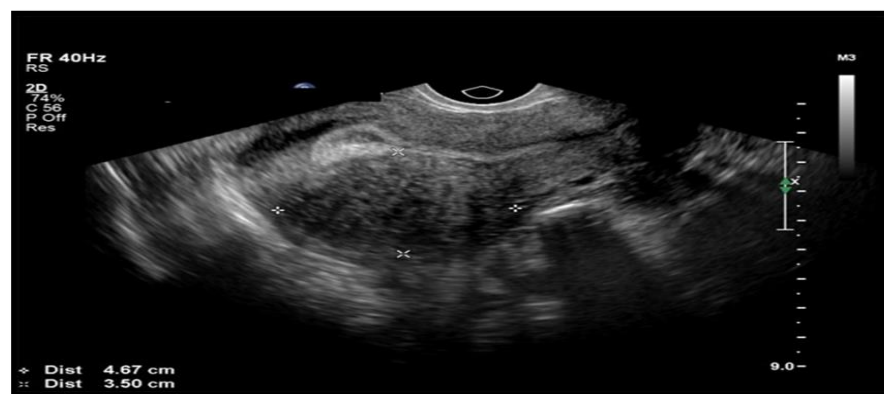

Figure (2.9): Transvaginal sonogram shows leiomyoma (between the markers) that extends from the serosa to the mucosa. [OBGYN.Net](http://OBGYN.Net)

## 2.4 Sonography appearances of postmenopausal uterus and ovaries:

After menopause, the endometrium becomes atrophic because it is no longer under hormonal control, sonographically, the endometrium is seen as a thin echogenic line measuring no more than 8 mm in the normal asymptomatic woman uterus also become small in body and shrunk more than cervix. (Lin et al. (1991)).

Calcified BV in the periphery of the myometrium is common and seen as bright echoes. (Warda (2014))

After menopause, the ovary atrophies and the follicles disappear over the subsequent few years, with the ovary decreasing in size with increasing age” (Merz et al. (1996)).

Because of its smaller size and lack of follicles, the postmenopausal ovary may be difficult to visualize sonographically. Sonographic visualization of normal postmenopausal ovaries varies greatly in the literature, from a low of 20% to a high of 99%, using either the transabdominal or the transvaginal approach. The variation is likely caused by differences in technique and length of time since menopause. Mean ovarian volume ranges are reported from 1.2 to 5.8 cc. (Cohen et al. (1990)).

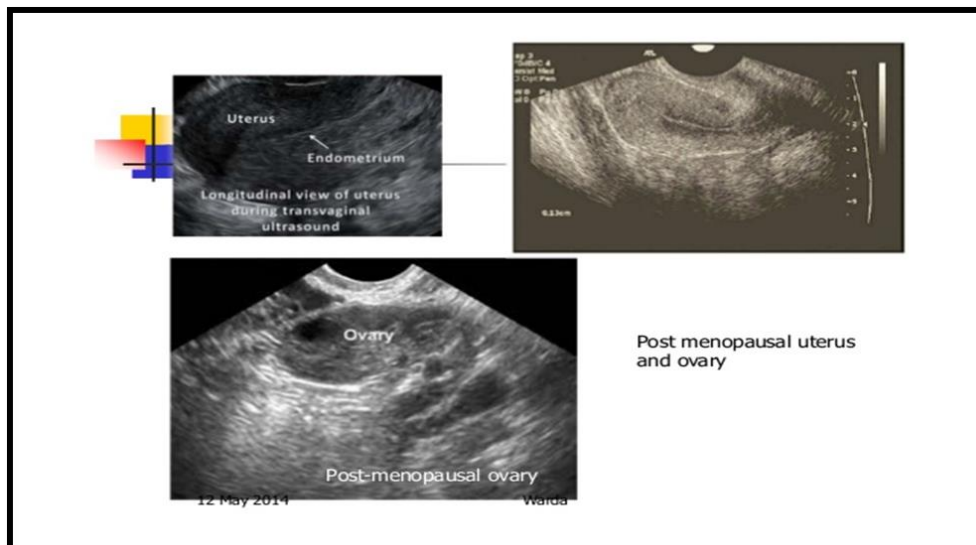


Figure (2.10): Transvaginal sonogram shows normal post menopausal uterus & ovary. [www.slideshare.net/ultrasound-gyne-oncology-warda](http://www.slideshare.net/ultrasound-gyne-oncology-warda)

## **2.5 Previous Studies:**

Burbos et al. (2012) aimed to evaluate the incidence of endometrial cancer in postmenopausal women presenting with vaginal bleeding. Cross-sectional study of postmenopausal women presenting with vaginal bleeding in a gynecological oncology center in the United Kingdom. All women underwent transvaginal ultrasound scanning (TVS) as the initial investigation tool to evaluate the endometrium. Endometrial biopsy was performed only in cases where endometrial thickness measured equal to or greater than 5 mm. The patients were divided into two groups based on their age: less than 50 years (Group A) and 50 years or older (Group B). Over a 57-month period, 4454 women were investigated for postmenopausal vaginal bleeding. Of these, 259 (5.8%) women were diagnosed with endometrial carcinoma. 260 (5.8%) women were younger than 50 years. Endometrial biopsy was not performed in 130 women in Group A that had an endometrial thickness measurement of less than 5 mm on ultrasonography. With a median follow-up period of 3 (1–5) years, they found no cases of endometrial cancer in women under the age of 50 that did not undergo endometrial biopsy at the time of initial evaluation. Overall, no cases of endometrial cancer were diagnosed in postmenopausal women under the age of 50 years. They found no cases of endometrial cancer amongst 260 women presenting with postmenopausal vaginal bleeding under the age of 50 years.

Moradan determine cause of PMB, was carried out on 60 post-menopausal patients with uterine bleeding in Amir University hospital, Sunman, Iran, between Oct 2008 and Dec 2009. The mean ( $\pm$ SD) age of the study group was  $60.3 \pm 4.8$  and the median age of post-menopausal lady in atrophic and endometrial polyp groups were 51 and in hyperplasia group was 53 years old. The mean ( $\pm$ SD) age of menopause in the study group was  $51.7 \pm 1.7$

years. Most endometrial abnormal pathology was present between 50 to 53 years old and the mean duration of vaginal bleeding was  $14.9 \pm 10.5$  days. A total of 60 women with post-menopausal uterine bleeding were evaluated. Twenty-nine cases had endometrial thickness more than 6 mm, it was considered most common cause of PMB, and 25 of these cases had abnormal pathology consisting of endometrial hyperplasia (11 cases), endometrial polyp (13 cases) and endometrial cancer (one case). Four cases had endometrial atrophy with normal pathology. Thirty-one cases had endometrial thickening less than or equal to 6mm and 26 of these cases had normal pathology (endometrial atrophy), five cases had abnormal pathology consisting of an endometrial hyperplasia (2 cases) and endometrial polyp (3 cases). (Moradan et al. (2011)).

Luiz et al. (1995) He was aimed to determine the benign and malignant causes of post menopausal bleeding. The study was conducted on 748 women who reported genital bleeding occurring at least one year after the last menstruation. Benign causes were most frequent than malignant causes. Among the benign causes, the most frequent were cervicitis (19,95%), prolapsed uterus with decubitus ulcer (19,41%), dysfunctional hemorrhage (13,29%) and endometrial polyps (12,77%). In the group of malignant causes, cancer of the cervix was the neoplasm most often detected (59,26%); endometrial cancer was next, affecting 29,63%. The cancer of the cervix/ cancer of the body ratio were 2:1.

Other study done by Janesh et al. to diagnose endometrial pathology in women with postmenopausal bleeding: a meta-analysis. Study determined the diagnostic accuracy of endometrial thickness measurement by pelvic ultrasonography for predicting endometrial carcinoma and disease (hyperplasia and/or carcinoma) during an investigation of postmenopausal bleeding. Study performed a systematic quantitative review of the available published literature, which consisted of online searching the Medline and



EMBASE databases (1966–2000) coupled with scanning of bibliography of known primary and review articles. The selection of studies, assessment of study quality, and extraction of data were performed in duplicate under masked conditions. Included in the analyses were 57 studies with 9031 patients. Accuracy data were summarized using likelihood ratios for various cut-off levels of abnormal endometrial thickness. The commonest cut-offs were 4 mm (9 studies) and 5 mm (21 studies), measuring both endometrial layers. None of the nine studies using the  $\leq 4$  mm cut-off level were of good quality. Only four studies (out of the 21) used the  $\leq 5$  mm cut-off level, which employed the best-quality criteria. Using the pooled estimates from these four studies only, a positive test result raised the probability of carcinoma from 14.0% (95% CI 13.3–14.7) to 31.3% (95% CI 26.1–36.3), while a negative test reduced it to 2.5% (95% CI 0.9–6.4). In conclusion, ultrasound measurement of endometrial thickness alone, using the best-quality studies cannot be used to accurately rule. (Janesh et al. (2002)).

Other study done by Gupta et al. to evaluating the utility of TVUS-obtained EEC thickness for the assessment of women with postmenopausal bleeding, the study include more than 9000 patients, demonstrated that an EEC of 3 mm or less would provide a posttest probability of 0.4% for endometrial cancer; a 4-mm threshold, 1.2%; and a 5-mm threshold, 2.3%. In this study, the best quality evidence was that for the 5-mm threshold. The authors of a second large meta-analysis of nearly 6000 women reported that an EEC of 5 mm or less was associated with a 4% chance of endometrial cancer. (Gupta et al. (2002)).

Another study by Bindman et al. To determine the accuracy of EVS in detecting endometrial disease in postmenopausal women with vaginal bleeding studies were included if they prospectively collected EVS measurements of endometrial thickness prior to obtaining endometrial tissue for histology evaluation in postmenopausal women with vaginal bleeding. Of

85 studies that included data on EVS and endometrial histology, 35 were included in the meta-analysis and included 5892 women. The overall summary estimates of sensitivity and specificity were calculated for thresholds of endometrial thickness from 3 to 10 mm. Using a 5-mm threshold to define abnormal endometrial thickening, 96% (95% confidence interval [CI], 94%-98%) of women with cancer had an abnormal EVS result, whereas 92% (95% CI, 90%-93%) of women with endometrial disease (cancer, polyp, or atypical hyperplasia) had an abnormal result. (Bindman et al. (1998)).

# **Chapter Three**

## **Methodology**

## **Materials and Methods:**

### **3.1 Material:**

We used Mindray real time ultrasound machine with triplex system accompanied with both trans-abdominal and trans-vaginal probes (Mindray china PC6 2009 trans-abdominal curvilinear 3.5-5 MH. and trans-vaginal transducers 7.5 MH) & philips HD7 ultrasound machine.

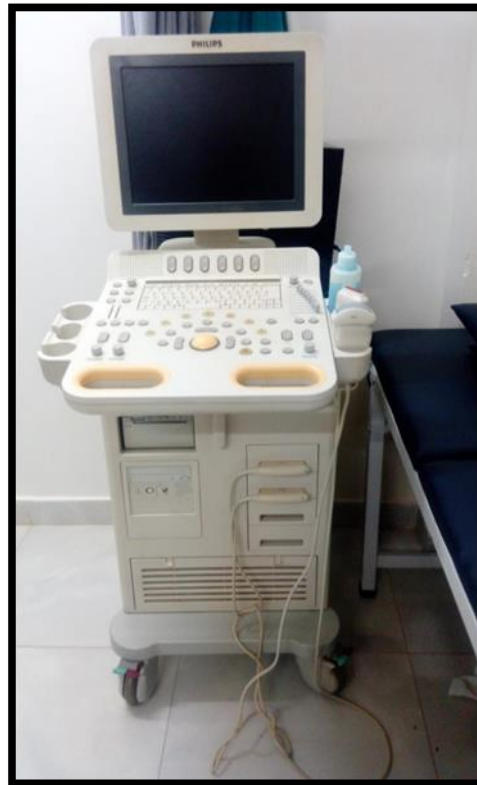

Figure (3.1): Philips HD7 ultrasound machine

#### **3.1.1 Type of the study:**

This was a cross sectional study, deal with the post-menopausal women with vaginal bleeding who came to ultrasound department.

#### **3.1.2 Area of the study:**

This study was done and carried out in Khartoum state in the ultrasound departments of Dar Elelaj and East Nile Hospital.

#### **3.1.3 Study populations:**

Post-menopausal women with vaginal bleeding who came to the area of the study during the specific duration of the study.

### **3.1.4 Sample size and Sampling Procedure:**

The sample size was 100 case of women with postmenopausal vaginal bleeding.

### **3.1.5 Sampling technique:**

Convenient sampling technique was used because it will be difficult to randomize the sample being a clinic based study.

### **3.1.6 Inclusion criteria:**

Post-menopausal vaginal bleeding women with or without palpable mass or pain those referred to the ultrasound department.

### **3.1.7 Exclusion criteria:**

Postmenopausal women who received hormone replacement therapy (HRT).

### **3.1.8 Duration of the study:**

This study was done from November 2016 to February 2017

## **3.2 Methods:**

### **3.2.1 Equipments and Technique:**

All patients with postmenopausal vaginal bleeding with or without pelvic pain or palpable mass were included in the study. Ages of the patients and the clinical features were recorded. Transabdominal sonography 3.5 - 5 MHz and transvaginal scan was done for all the patients with a linear 5- to 7-MHz probe and sonohysterography in some cases. Transabdominal sonography was performing by placing the transducer in contact with the skin just above the symphysis pubis, reasonably full urinary bladder was essential for TAS when it used as the primary technique. Patients were instructed to arrive with a full bladder by drinking 20 to 30 ounces of water or other liquids about one hour before the scheduled examination. Some patients were overfilled and unable to hold on until the examination starts. Full bladder indicates bladder distention just to the point of mild patient discomfort. In endovaginal sonography evaluations, the patient's bladder was emptied since this allowed

close proximity of the vaginal transducer to the body of the anteverted uterus. EVS study was performed with the patient on a gynecological examination table and the patient in a lithotomy position (flat on her back, legs flexed on the thighs, thighs flexed on the abdomen and abducted with stirrups used to support the feet and legs. This setup enables free, unobstructed movement of the probe in both vertical and horizontal directions by the operator

### **3.2.2 Method of data collection**

The data was collected by clinical data sheets, ultrasound imaging and interview with the patients.

### **3.2.3 Method of Data analysis**

The data was analyzing by using SPSS (Statistical Package for Social Science) and the results presented in form of graphs, tables and Chi-Square Tests.

### **3.2.4 Ethical considerations**

No identification or individual details were published. No information or patient details was disclosed or used for other reasons than the study purpose.

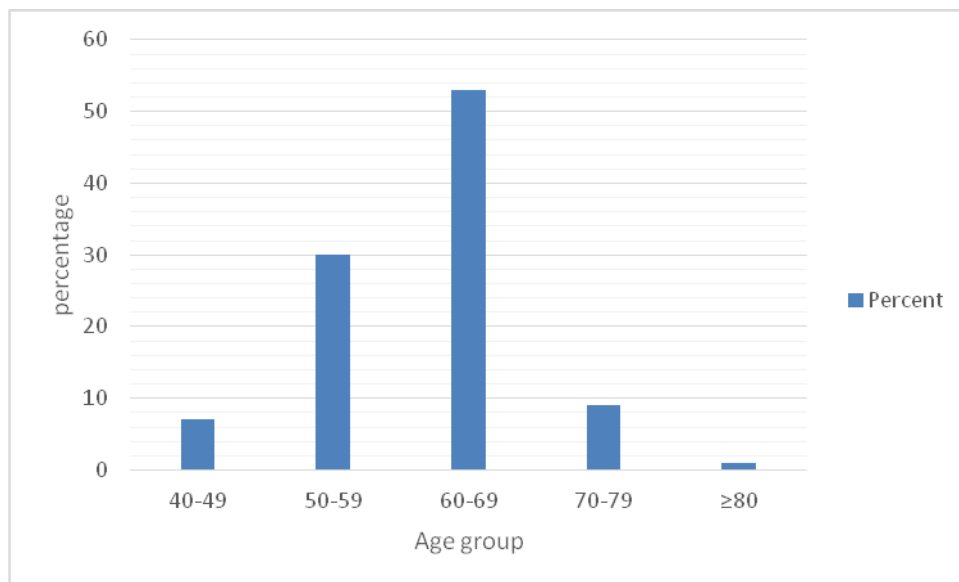
# **Chapter Four**

## **Data Analysis and Results**

#### 4.1 Results:

**Table (4.1)** Shows frequency distribution of age group

Age groups	Frequency	Percent
40-49	7	7.0 %
50-59	30	30.0 %
60-69	53	53.0 %
70-79	9	9.0 %
$\geq 80$	1	1.0 %
Total	100	100.0 %

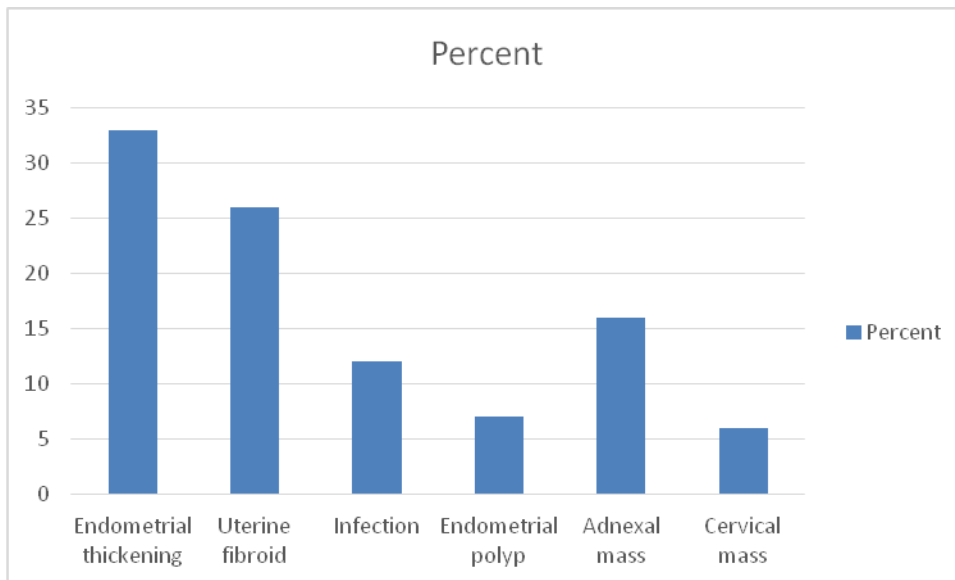


**Figure (4.1)** Shows frequency distribution of age group



**Table (4.2)** Shows frequency distribution of PMB causes:

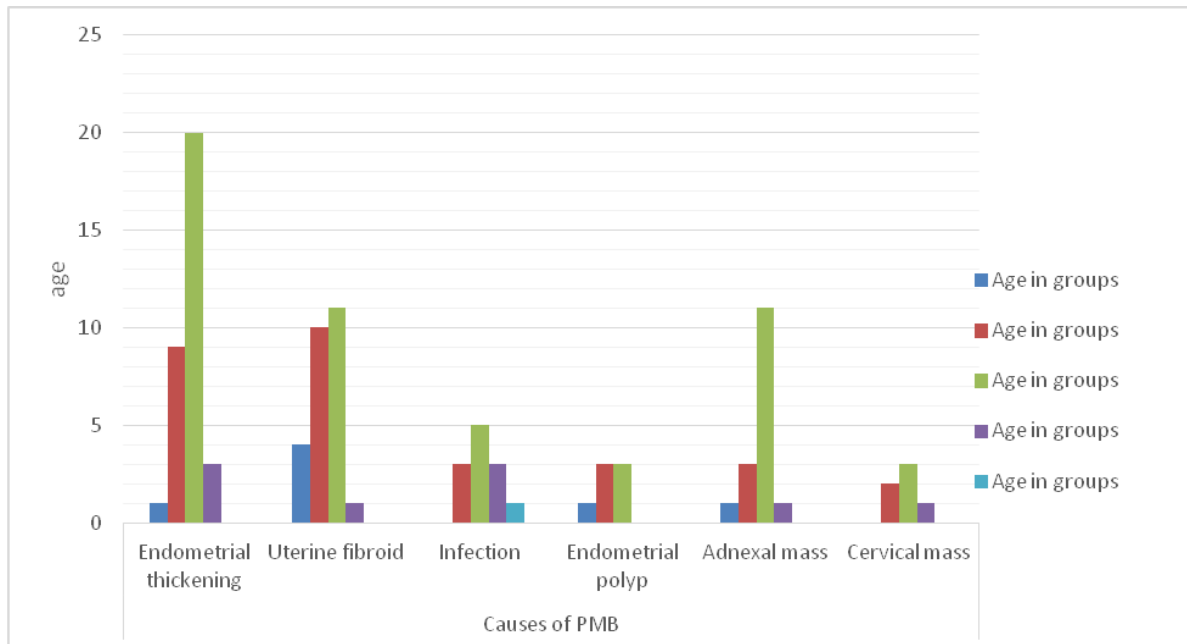
Causes of PMB	Frequency	Percent
Endometrial thickening	33	33.0
Uterine fibroid	26	26.0
Infection	12	12.0
Endometrial polyp	7	7.0
Adnexal mass	16	16.0
Cervical mass	6	6.0
Total	100	100.0



**Figure (4.2)** Shows frequency distribution of PMB causes

**Table (4.3)** Shows cross tabulation between Causes of PMB & Age in group

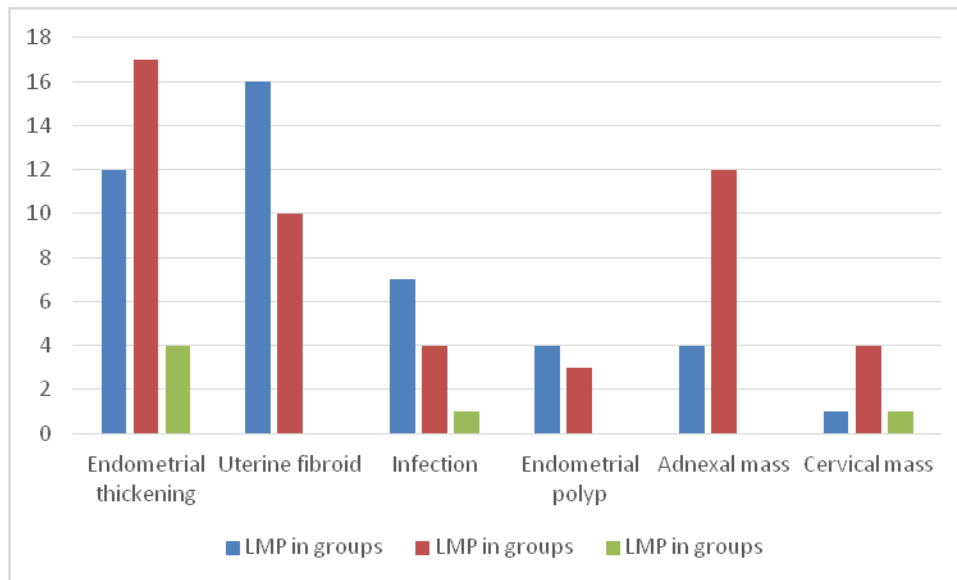
Age Vs causes of PMB		Age in groups					Total
		40-49	50-59	60-69	70-79	≥80	
Causes of PMB	Endometrial thickening	1	9	20	3	0	33
	Uterine fibroid	4	10	11	1	0	26
	Infection	0	3	5	3	1	12
	Endometrial polyp	1	3	3	0	0	7
	Adnexal mass	1	3	11	1	0	16
	Cervical mass	0	2	3	1	0	6
Total		7	30	53	9	1	100



**Figure ( 4.3)** Shows cross tabulation between Causes of PMB & Age in group

**Table (4.4)** Cross tabulation between causes of PMB & LMP

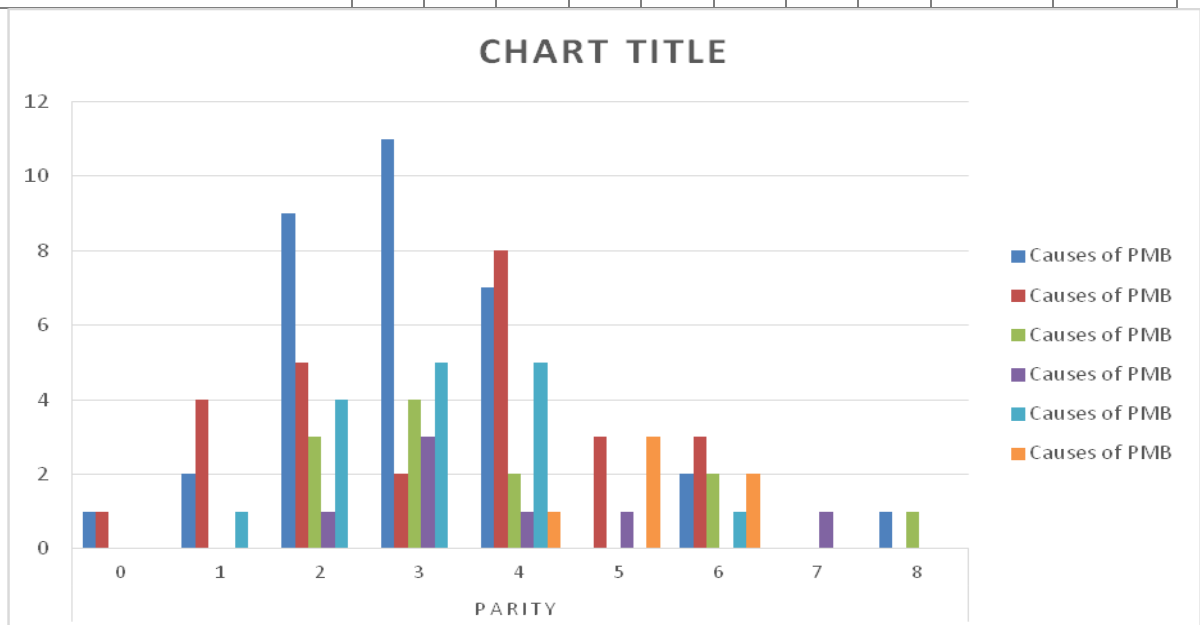
Causes of PMB		LMP in groups			Total
		1-10	11-20	21-30	
	Endometrial thickening	12	17	4	33
	Uterine fibroid	16	10	0	26
	Infection	7	4	1	12
	Endometrial polyp	4	3	0	7
	Adnexal mass	4	12	0	16
	Cervical mass	1	4	1	6
Total		44	50	6	100



**Figure (4.4)** Cross tabulation between causes of PMB & LMP

**Table (4.5 )** Shows cross tabulation between Causes of PMB & Parity

		Parity									Total
		0	1	2	3	4	5	6	7	8	
Cause of PMB	Endometrial thickening	1	2	9	11	7	0	2	0	1	33
	Uterine fibroid	1	4	5	2	8	3	3	0	0	26
	Infection	0	0	3	4	2	0	2	0	1	12
	Endometrial polyp	0	0	1	3	1	1	0	1	0	7
	Adnexal mass	0	1	4	5	5	0	1	0	0	16
	Cervical mass	0	0	0	0	1	3	2	0	0	6
Total		2	7	22	25	24	7	10	1	2	100



**Figure 4.5** Shows cross tabulation between Causes of PMB & Parity

**Table (4.6)** Shows statistical analysis of age, LMP & endometrial thickness

	Min	Max	Mean	Std. Deviation
Age	43	80	60.83	7.047
LMP	1	30	12.99	6.349
Endometrial thickness in mm	3	18	6.39	3.843

**Chapter Five**  
**Discussion, Conclusion and**  
**Recommendations**

## **Discussion, Conclusion and Recommendation:**

### **5.1 Discussion:**

The main objective of this study was to determine the role of ultrasound in evaluation of post menopause women with vaginal bleeding.

The study was carried out on 100 post-menopausal patients with vaginal bleeding occurring at least one year after the last menstruation in Khartoum state in the ultrasound departments of Dar Alelag Hospital and East Nile Hospital between Nov 2016 and 2 Feb 2017. A total of 100 women with post-menopausal vaginal bleeding were evaluated, Thirty-three cases (33%) had endometrial thickening more than 6mm. uterine fibroid (26% of cases). Adnexal masses (16% of cases). (12% of cases) were vaginal bleeding due to infection. Endometrial polyp (7% of cases). Cervical mass (6% of cases). In present study, thickened endometrial was considered endometrium cancer until proved otherwise. So, this requires prospective study to confirm the nature of thickening. Related to uterine fibroid the percent (26% of cases) was considered logical, fibroid not common after menopause. Most of them stabilize and decrease in sizes after menopause. Rapid increase in post-menopausal fibroid sizes should raise possibilities of sarcomatous change (Smith et al. (1980)).

So most of them were referred for histopathology.

Regarding the endometrial polyp's, which was (7% of cases). This was considered logical, because uterine polyps are more likely develop in women who are between 40-50 years and rarely occur after menopause. (Janesh et al. (2002)).

Higher frequency of samples sizes of PMB was occurring between ages (60-69 year). Were (53%) of cases less frequently in age after 80 years. Minimum age of bleeding was 43-year old and maximum was 80-year-old and 60-year-old was means age.

Related to parity study showed that decrease the incidence and cases of post-menopausal vaginal bleeding with increasing parity. Women who had parity 3&4 had more frequent post-menopausal vaginal bleeding. As justification for this, Present study have not had sufficiently large sample sizes to produce stable estimation as compare to parity of menopause women.

Maximum endometrium thickness was 18 mm and minimum thickness seen was 3mm. There was significant relation between adnexal mass and endometrium thickening. Endometrium was thickened in 6 cases of adnexal mass.

Endometrial thickening more common between ages 60-69 year. 20 cases from 33 cases was occur at this age. One case was occurring in age 40-49 year. No case of endometrial thickening after age 80.

Regarding LMP as compare with incidence of vaginal bleeding. (50% cases) were occurring in women who LMP between 11-20-year-old. (44 cases) who had LMP 1-10 year. (6 cases) who had LMP 21-30 year.

Regarding most common causes (endometrial thickening).Study found that (33%) was endometrial thickening more than 6 mm. This finding agrees with study done by the Moradan S, Ghorbani R, Far M. This study was carried out on 60 post-menopausal patients with uterine bleeding in Amir University hospital, Sunman, Iran, between Oct 2008 and Dec 2009. A total of 60 women with post-menopausal uterine bleeding were evaluated. Twenty-nine cases had endometrial thickness more than 6 mm and was considered most common causes of PMB (Moradan et al.( 2011)).

Other study done by S Naik Jyoti, D Rege, Kusum D, Tashnani under the title of (pathology of genital tract in post-menopausal bleeding) concluded over period of 44 months between January 1996 and September 2000 in surgical pathology department found that endometrial thickening contributed to 50% of causes of PMB.



Occurrence of endometrium thickening could be due to fluctuating levels of progesterone from follicular remnant, effect of which persist even up to 15years after cessation of menses.

## **5.2 Conclusion:**

Ultrasonography is one of the well accepted and high sensitive imaging modality for the diagnosis and follow-up of postmenopausal uterus ovaries. The main objective of this study was to determine the role of ultrasound in evaluation of post-menopause women with vaginal bleeding in order to assess the major causes of such conditions. The study was carried out on 100 post-menopausal patients with vaginal bleeding occurring at least one year after the last menstruation in Khartoum state in the ultrasound departments of Dar Alelag Hospital and East Nile Hospital during period from November 2016 to February 2017. A total of 100 women with post-menopausal vaginal bleeding were evaluated, (33%) of cases had endometrial thickening more than 6mm. Uterine fibroid (26% of cases). Adnexal masses (16% of cases) (12% of cases) were vaginal bleeding due to infection. Endometrial polyp (7% of cases). Cervical mass (6% of cases). Study concluded that ultrasound is excellent method for evaluation women with post-menopausal vaginal bleeding. And was considered high sensitive in endometrial thickening regardless of it nature (benignancy or malignancy). It was easy do, token short time, it was none invasive procedure for women. Also study found that ultrasound (TVS &TAS) had excellent reporting in adnexal masses and was considered sensitive 100%.

### **5.3 Recommendations:**

1. More advanced ultrasound equipment's with high frequency TVS probe and
2. Doppler facilities should be used to reduce the false positive and false negative results.
3. Another research studies should be done with expanding period of time and should include more samples for precise and accurate results.
4. Women with postmenopausal uterine bleeding may be assessed initially with either endometrial biopsy or transvaginal ultrasonography; this initial evaluation does not require performance of both tests.
5. Endometrial thickening more than 5 mm should be take further workup for histopathology, ultrasound alone is not enough to exclude malignancy.
6. When bleeding persists despite negative initial evaluations, additional assessment usually is indicated.

## **5.4 The Limitations:**

It is not possible to complete a meaningful transvaginal ultrasound examination with a reliable measurement of endometrial thickness in all patients. An axial uterus, marked obesity, coexisting myomas, or previous uterine surgery all can contribute to difficulty in obtaining reliable transvaginal ultrasound assessment of endometrial thickness and texture. Failure to adequately identify a thin, distinct endometrial thickness in a postmenopausal patient with bleeding should trigger some alternative method of evaluation. In addition, when endometrial fluid is present, it should not be included in measuring endometrial thickness.

## References:

- Carol M. Rumack, Stephanie R. Wilson, J. William Charboneau, Deborah Choo YC, Mak KC, Hsu C, et al. Postmenopausal uterine bleeding of nonorganic cause. *Obstetric Gynecologic* 1985; 66:225-228.
- Clinical Anatomy for Medical Student*, 5<sup>th</sup> edition, Richard S. Snell, M.D. PH.D.
- Cohen HL, Tice HM, Mandel FS. Ovarian volumes measured by ultrasound: bigger than we think. *Radiology* 1990; 177:189- 192.
- Gupta JK, Chien PF, Voit D, Clark TJ, Khan KSA *Obstet Gynecol Scand*. 2002 Sep; 81(9):799-816.
- <https://en.m.wikibooks.org/human-physiology> accessed on 5/10/2016 at 4:30 pm.
- Janesh K. Patrick F. W. Chien, et.al. ultra-sonographic endometrial thickness for diagnosing endometrial pathology in women with postmenopausal bleeding. *Acta Obstet. Gynecology. Scan*, Volume 81, Issue 9, Sept 2002: Pages 799–816
- Kurman RJ, editor. *Blaustein's pathology of the female genital tract*, 5th ed. New York: Springer-Verlag; 2002.
- Levine. *Diagnostic Ultrasound*. 4th ed. Mosby Elsevier; Philadelphia: 2011. P 842-847.
- Lin MC, Gosink BB, Wolf SI, et al. Endometrial thickness after menopause: effect of hormone replacement. *Radiology* 1991; 180:427-432.
- Luiz Neto, Marair Gracio, Edmund Chada; et al. post-menopausal genital bleeding, *Sao Paulo Med. J.* vol.113 no.5 Sept./Oct. 1995.
- Mariam A. Rule of ultrasound in diagnosis different pelvic pathologies among post-menopausal women in Khartoum Session. *Alzaem Alazhari University*; Sudan: 2011.

Merz E, Miric-Tesanic D, Bahlmann F, et al. Sonographic size of uterus and ovaries in pre- and postmenopausal women. *Ultrasound Obstetric Gynecologic* 1996; 7:38-42.

Moradan Sa, Ghorbani Rb, Far MFC. ultrasonography finding in post-menopausal vaginal bleeding, *IMJM*, Volume 10, number 2, Dec 2011, 19.

Moradan S, Ghorbani R, Far M. abnormal uterine bleeding in menopausal women. *J Obstetrics and Gynecology Can.* May 2013; 35(5):473-475.

Nikolaos Burbos, Patrick Musonda, Joaquin J. incidence of endometrial cancer in young post menopausal women presenting with vaginal bleeding, *Gynecologic Oncology*, April 2012; Vol. 125(1) :120–123

Ruth B, Robert L, Beryl R, et al. Evaluation of women with post-menopausal bleeding. *Ultrasound Med.* 2001; 10(2):1025-1336

[Smith-Bindman R1](#), [Kerlikowske K](#), [Feldstein VA](#), [Subak L](#), [Scheidler J](#), [Segal M](#), [Brand R](#), [Grady D](#). Endovaginal ultrasound to exclude endometrial cancer and other endometrial abnormalities. 1998 Nov 4; 280(17):1510-7

Smith JP, Weiser EB, Karnei Jr RF, Hoskins WJ. Ultrasonography of rapidly growing uterine leiomyomata associated with anovulatory cycles. *Radiology* 1980; 134:713-716.

Wachsberg RH, Kurtz AB. Gas within the endometrial cavity at postpartum ultrasound: a normal finding after spontaneous vaginal delivery. *Radiology* 1992; 183:431-433.

Williams PL, Warwick R, editors. *Gray's anatomy*, 37th ed. Edinburgh: Churchill Livingstone; 1989

# **Appendices**

## Appendix A

**Sudan University of Science and Technology**

**College of Graduate Studies**

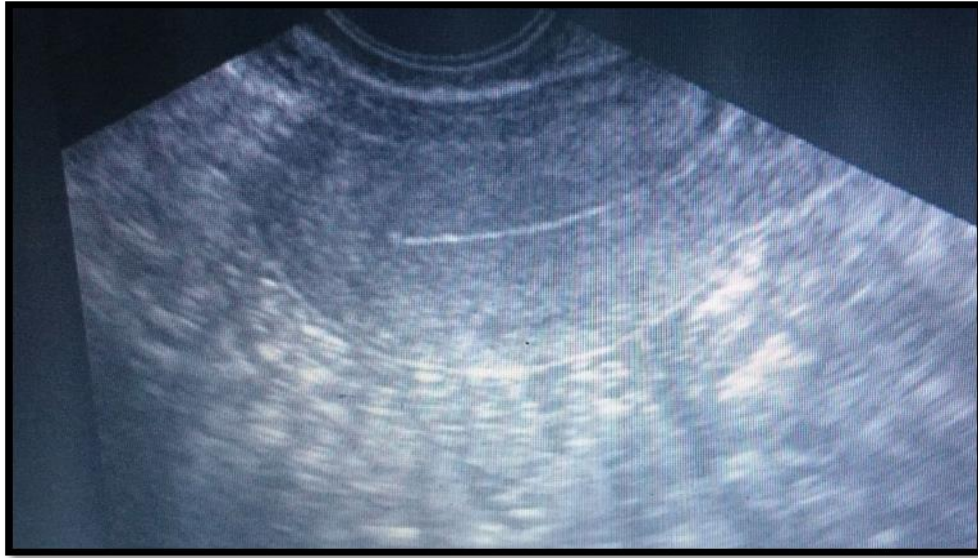
**Assessment of post-menopausal vaginal bleeding in Khartoum state**

**Data collection sheet**

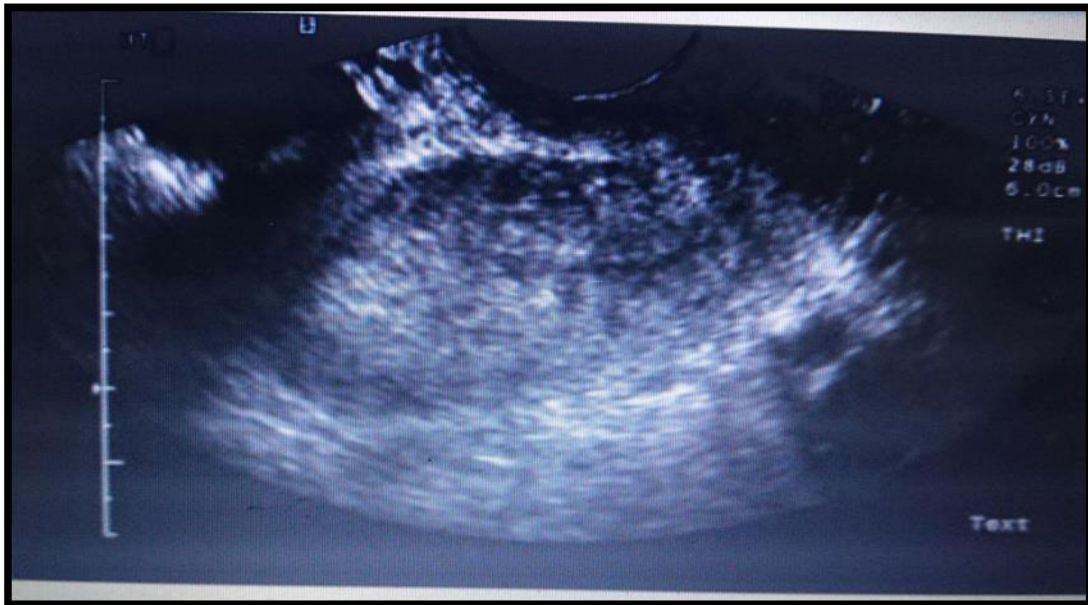- Date .....Age .....
- Parity .....LMP.....
- Uterine size.....
  
- Causes of vaginal bleeding:
  - 1-Endometrial thickness .....
  - 2-Uterine fibroid .....
  - 3-Infection .....
  - 4-Endometrial polyp.....
  - 5-Adnexal mass.....
  - 6- Cervical lesion .....



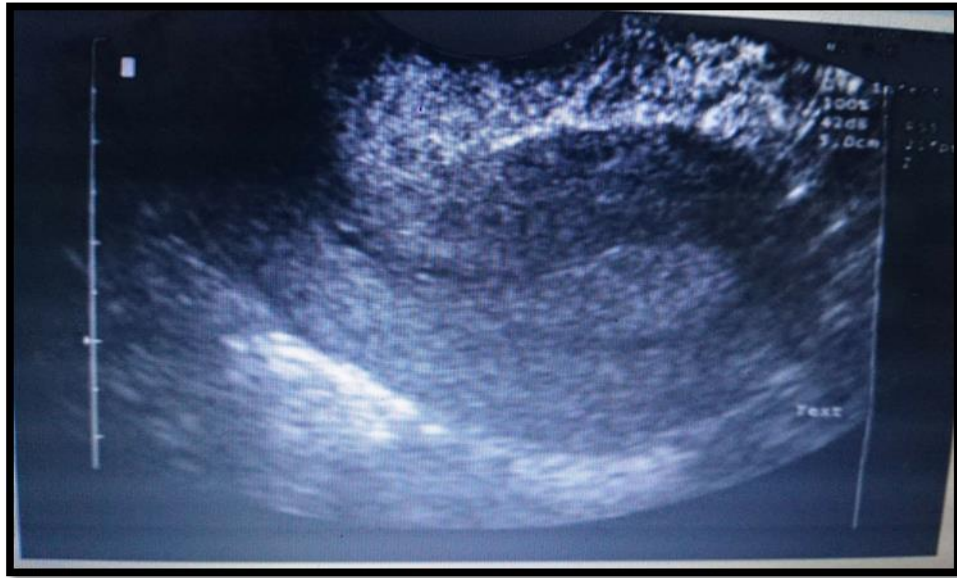## Appendix B



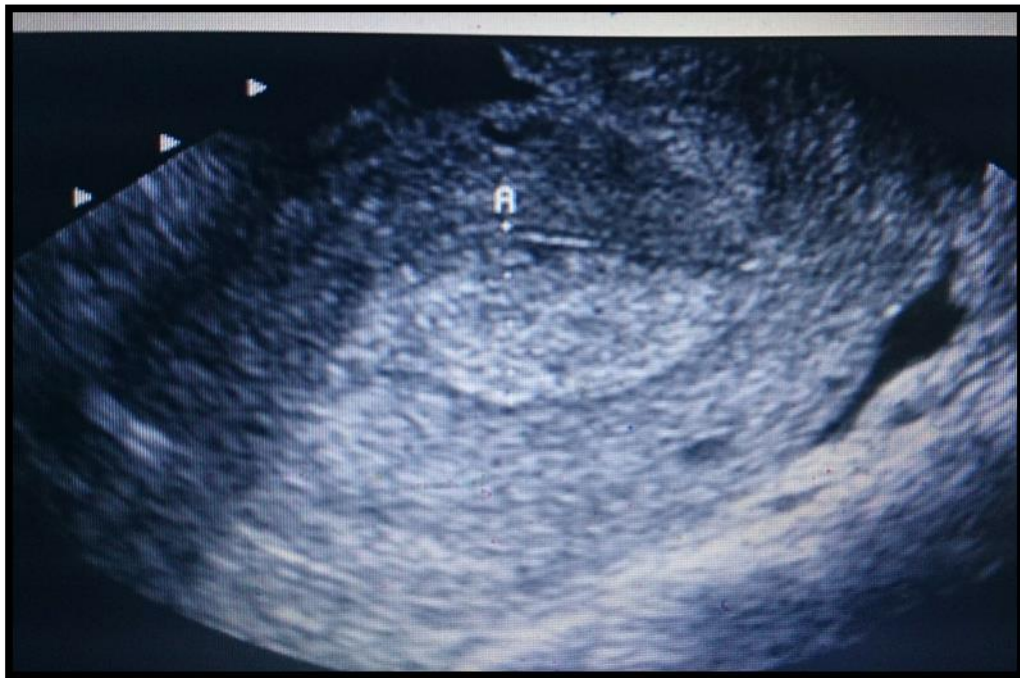
**Appendix 1:** Long axis transvaginal ultrasound image in postmenopausal patient shows endometrial atrophy.



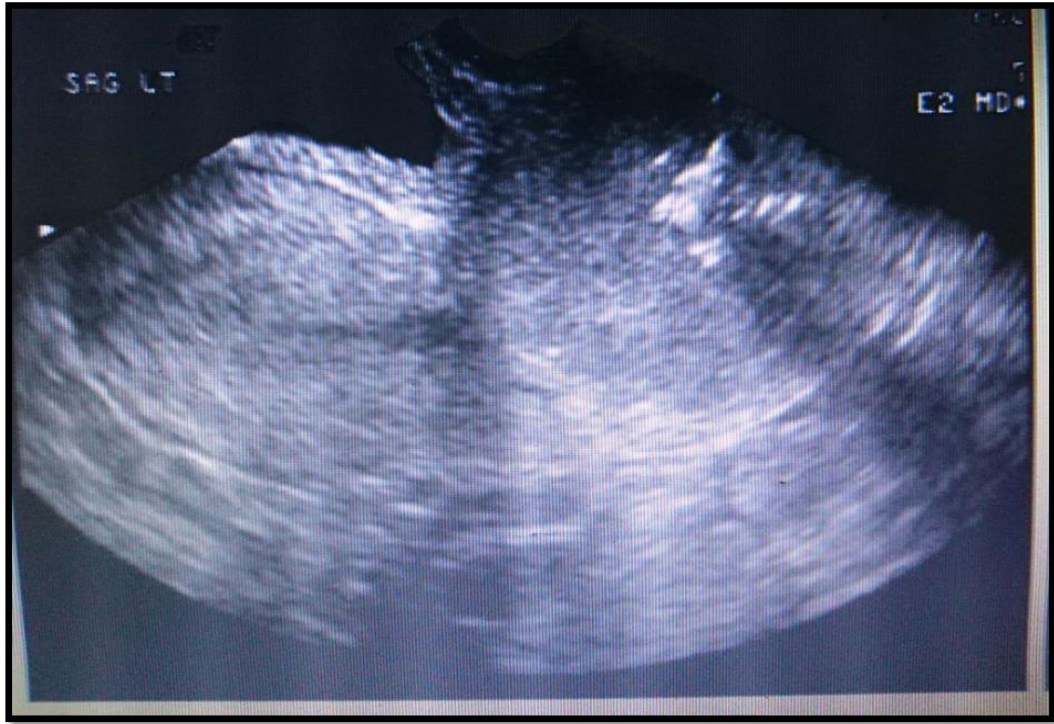**Appendix 2:** Transvaginal ultrasound in postmenopausal patient shows endometrial cancer.



**Appendix 3:** Transvaginal ultrasound in postmenopausal patient shows endometrial polyp.



**Appendix 4:** Transvaginal ultrasound of a postmenopausal woman with vaginal bleeding shows an abnormally thickened endometrium.



**Appendix 5:** Transvaginal ultrasound of a postmenopausal woman with vaginal bleeding shows cervix lesion