

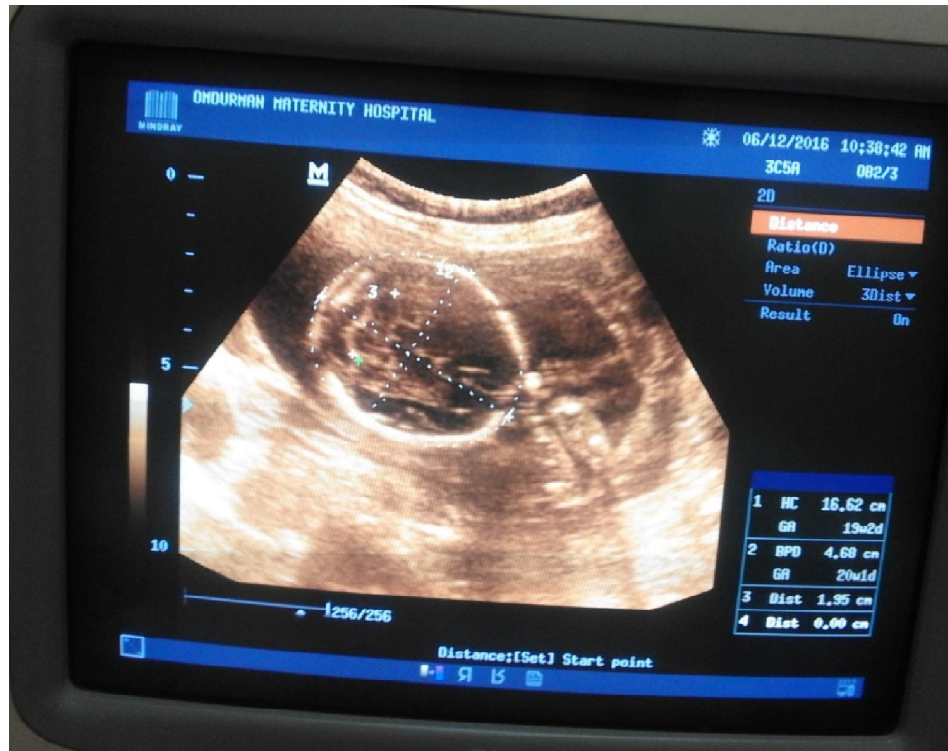

Image 1: shows ultrasound image of TCD of the fetus at 19 week gestational age which TCD measure 19.5 mm .

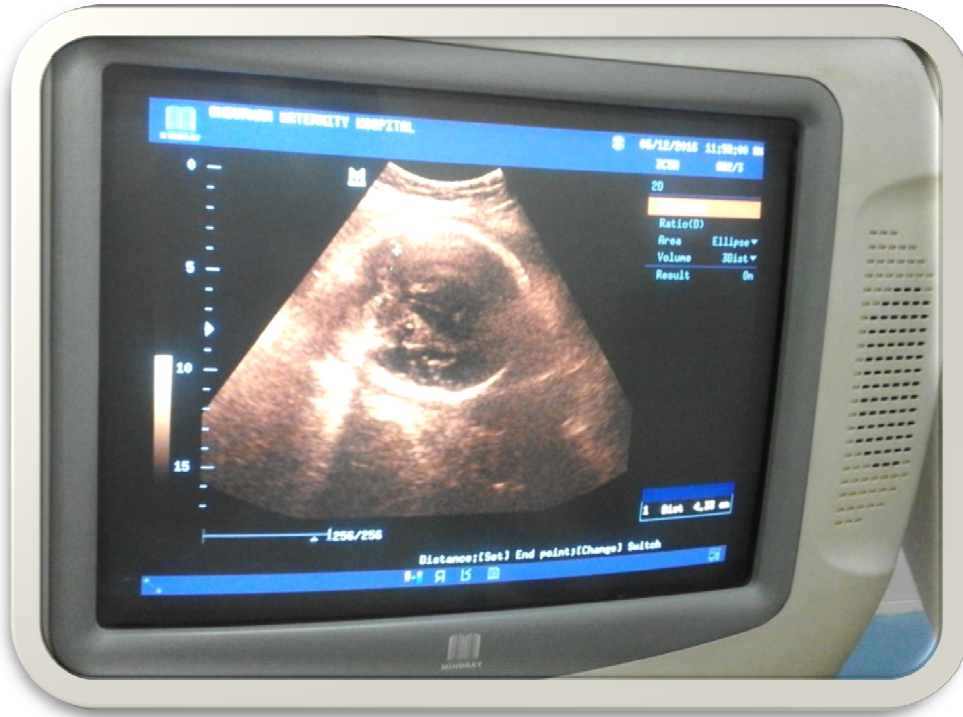


Image 2 shows: ultrasound measurement of TCD at 42week gestational age which measure 42mm.

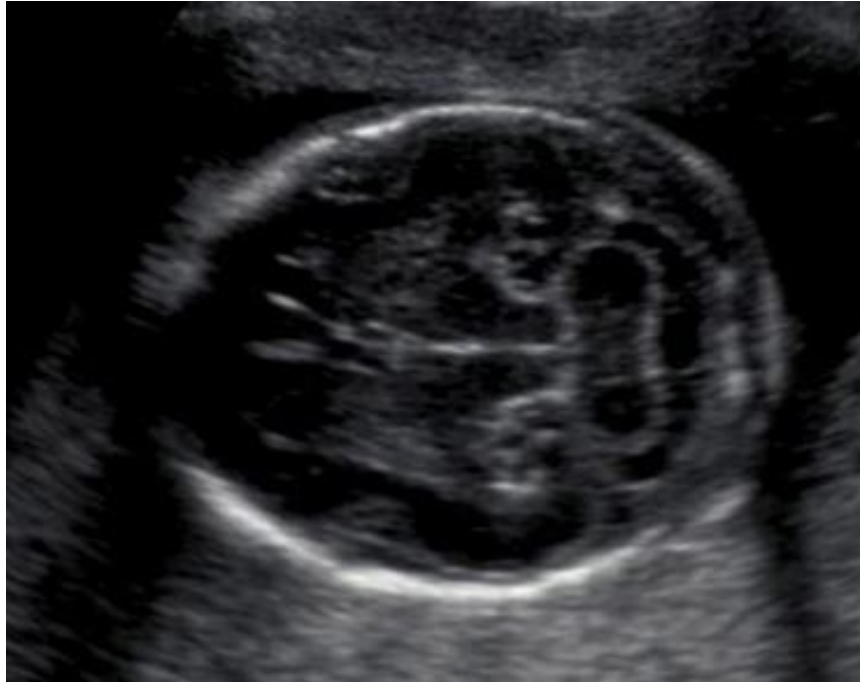

Image 3 shows ultrasound image of fetal cerebellum at second trimester .

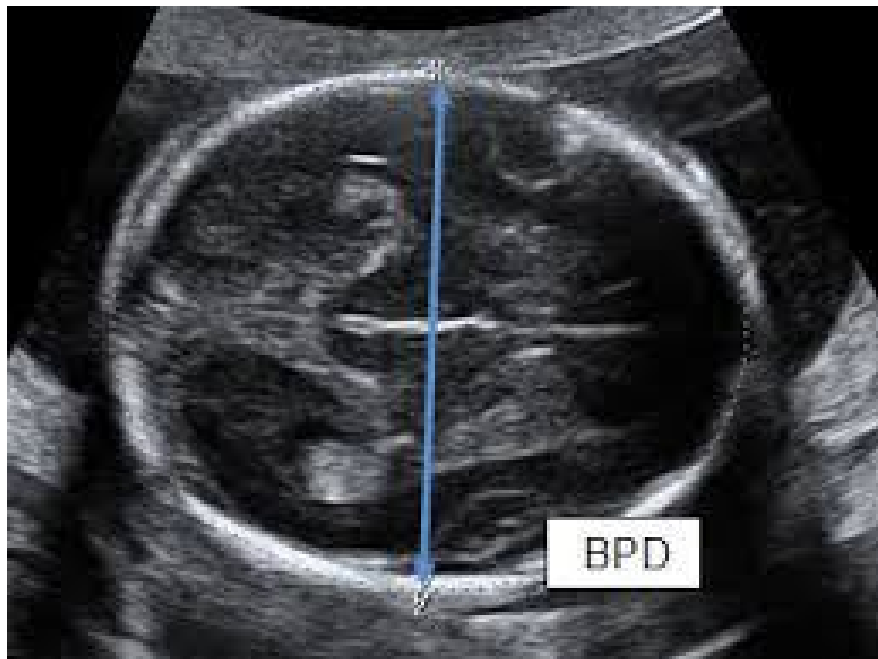


Image4: shows ultrasound image of fetal BPD at second trimester.

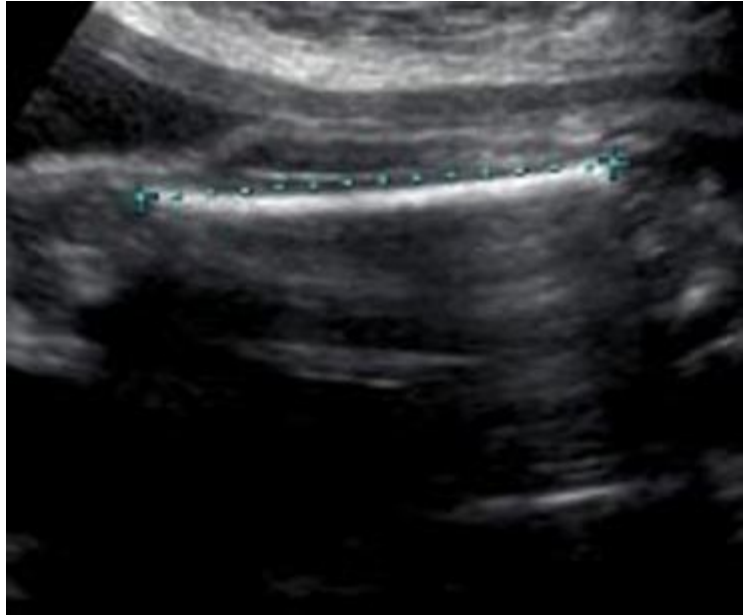


Image 5: shows ultrasound image of fetal FL at second trimester.