

A HERD OUTBREAK OF CAMEL POX IN QASSIM REGION, KINGDOM OF SAUDI ARABIA

By

Amir, M. Saad¹ and Tourki Alrobaish²

1-Qassim Veterinary Diagnostic Laboratory, Buraydah, KSA, 2-Ministry of Agriculture, Eion Aljawa Province, Qassim, KSA.

ABSTRACT

A camel herd is attacked by the camel pox virus in Eion aljawa, Qassim region, KSA, during February-March, 2005. Infected animals showed depression, prostration, emaciation and suffered from pruritus. A morbidity rate of 38% and a mortality rate of 8% are recorded. Camel calves are most affected. Macroscopic and microscopic lesions are described. The changes encountered are typical of pox lesions vis vesicles, pustules and scabs. Erythema and papules are noticed on the right arm of the herdman. The findings are discussed and compared with other relevant studies.

INTRODUCTION

Camel pox is a contagious viral disease caused by an orthopoxvirus. It has a worldwide distribution (Higgins, 1985). The disease is highly prevalent in Qassim Region, Kingdom of Saudi Arabia. Many herd outbreaks frequently occur in the region particularly at the beginning of the rainy season when the camels are under poor nutritional status. The camel calves are most vulnerable and are seriously affected by the virus (Abu Elzein, 2004). The disease is mild in most cases, however, a severe form is occasionally encountered that causes high fatalities.

There is a great dispute concerning the communicability of the disease to man. (Marennikova *et al.*, 1974) reported that the disease could be zoonotic under certain conditions. However, many workers found little evidence to support this belief (Kriz, 1982). In addition, the reports which indicated that people drinking milk from affected camels in field outbreaks in Northern Kenya, developed ulcers on the lips and in the mouth were unverified (Davies *et al.* 1975).

The present paper records the morbidity and mortality rates, abortions % in a camel pox herd outbreak occurred during February-March 2005 in Eion Eljawa Province, Qassim Region about 400Km North East of Elriyadh and describes pathological lesions of the disease. It further reports for the first time the development of skin lesions on the arm of the herdman who was in close contact with the sick animals and was nursing them.

MATERIALS AND METHODS

The Herd: The camel herd was composed of 42 animals of different ages and sexes. The young camels (less than 3 years) were 14. The animals were kept in a fenced-land with an area of about 6 square kms. Animal movement was allowed only within the boundaries of this confined land. Water and feed were provided by the camel owner.

Sampling: Properly separated, non-haemolysed serum samples were sent to Elriyadh Diagnostic Veterinary Laboratory for immuno-serodiagnosis. Small portions taken from pustules and scabs were fixed in 10% neutral formol saline. They were processed, blocked in paraffin wax, sectioned and stained with haematoxylin and eosin for histopathological examination at Qassim Diagnostic Veterinary Laboratory.

RESULTS

Sixteen animals, 10 of them were young, contracted the disease and showed pox lesions. (38% Morbidity). Death occurred in 4 animals, all of them were camel calves, (Mortality of 8.5%). No postmortem examination was conducted because we did not get a dying animal or a recently dead animal during our visit to the farm (about 120 kms from the laboratory). Out of the 4 pregnant she camels which were infected, two had aborted (50% abortion rate). In the two cases, abortion occurred at late stages of pregnancy (Fig. 1).




Fig. (1): Aborted (stillbirth) fetus, note the complete development of the fetus

Clinical Signs: The affected animals were febrile, depressed, prostrated and anorexic. They lost weight and got emaciated because of restricted suckling and grazing due to extensive mouth lesions. The sick animals suffered from pruritus as manifested by loss of hair on affected parts due to rubbing.

Pathological Lesions:

Macroscopically: the lesions were the classic ones of pox with vesicles, pustules and scabs. These were observed on the lips, buccal mucosa, around nostrils and on and around the eyelids (Fig. 2 and 3). They were also found on the internal sides of the thighs which had fine skin and on the external sides of them if alopecia attributed to rubbing has occurred. However, the lesions were palpated and identified when the thighs were covered by hair.

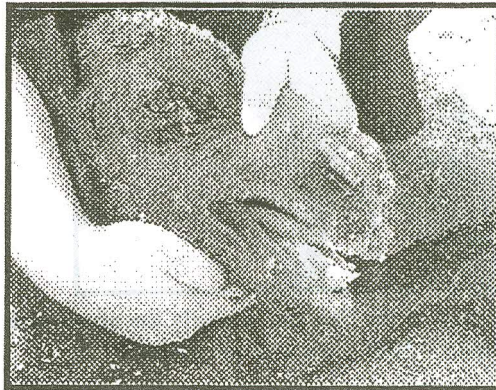

Fig. (2): Pustules on the lips, muzzles, nostrils and on the eyelids and peri-orbital area of a camel calf.



Fig. (1): Scabs on the lips, muzzles, nostrils and the eyelids of a camel calf.

One of the affected camel calves showed very severe mouth lesions that resulted in destruction and distortion of the lips particularly the upper one (rounded mouth) (Fig. 4). This had led to reduced ability of the lips to seize and grasp the feed.



Fig. (4): Destruction and distortion of the lips, particularly the upper one, of a camel calf compared with a normal one (front)

The lesions noticed on the herdman's arm comprised localized erythema and firm raised papules with a zone of hyperaemia around the base (Fig. 5).



Fig. (5): Erythema and hyperaemic papules on the herdman's arm

The histopathological examination was limited to the skin lesions only. The lesions in the epidermis were similar to those of other poxviruses with localized acanthosis associated with hyperkeratosis. In some parts, the thickened epidermis extended into the dermis (Fig. 6). Acanthosis was followed by vesicle formation that soon filled with neutrophils to form a pustule. Rupture of the pustule occurred within a week to 10 days. The newly ruptured pustule appeared as an empty space containing epithelial cells, neutrophils, keratin threads and a pink-staining proteinous precipitate (Fig. 7).



Fig. (6): Acanthosis. Note thickening of the epidermis and extension of some parts of it into the dermis




Fig. (7): A pustule ruptured during processing. Note the pink-staining proteinous precipitate in the empty spaces, keratin threads, epithelial cells and neutrophils

The inclusion bodies were visible in affected epithelial cells. These were demonstrated as vacuolated cells with eosinophilic intracytoplasmic inclusions (Fig. 8).

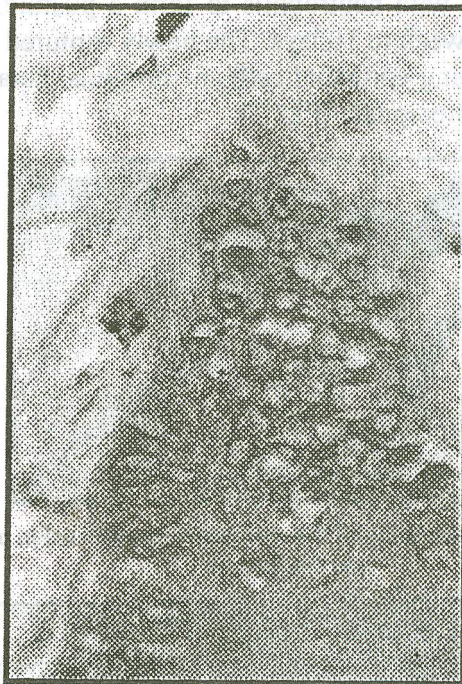

Fig.8. Vacuolated cells with eosinophilic intracytoplasmic inclusion bodies

DISCUSSION

Camel pox is a contagious viral disease of wide distribution among camel communities in different parts of the world (McGrane and Higgins, 1986). It is endemic in the Kingdom of Saudi Arabia (Abu Elzein, 2004) and is blamed for the high losses it causes in terms of fatalities, abortions and reduced meat and milk production (Hafez *et al.*, 1986).

The incubation period ranged between 4-7days. The first lesions that appear are vesicles (can burst if rubbed or scratched) that progress to pustules followed by scab formation. The scabs fall down to leave scar tissue.

It should be stressed that acanthosis, i-e thickening of the epidermis, constitutes a vital step preceding vesicle formation.

The severity of infection varies according to the age of the animal, its immunological and nutritional status (Abu-Elzein, 2004). The disease is usually severe and acute in camel calves which didn't receive maternal antibodies in the colostrums or the maternal immunity acquired has waned. Adult camels that were not subjected to previous natural exposures of the disease are highly susceptible too, and may pick up the acute form of the disease (Hussein *et al.*, 1987). These findings were similar to the results obtained in this study that camel calves constituted 62% of the number of animals affected, and all deaths were from this age group.

The type of infection encountered in this outbreak could be generally graded as medium. Judgment is based on the confinement of the lesions to the face and the thighs, coupled with the low mortality which didn't exceed 10%. Conversely, the lesions in the severe form spread over the whole body with a mortality rate exceeding 20% (Hafez *et al.*, 1986; Hussein *et al.*, 1987) while in the light infection there is no fatalities (Alhendi *et al.*, 1994).

The vacuolar appearance of the eosinophilic inclusions is caused mainly by lipid dissolving out of the inclusions during tissue processing. Although this is a variable feature, yet it is considered as an important diagnostic tool for the disease in animals and birds when tied with the cutaneous lesions and specifically, when serological examination can not be carried out.

The zoonotic nature of the disease is still disputed. In the current report we described lesions on the arm of the herdman similar to those of pox lesions; viz erythema and papules. A similar observation was noticed by (Richard, 1979) in Ethiopia who found a child covered with pustules all over his body in a camp where camel pox outbreak had occurred. In contrast to these observations, Kriz, (1982) found little evidence in Somalia to support the belief that the disease is zoonotic. In our opinion, we think this controversy arose from the fact that all suspected cases were not confirmed by the health authorities.

REFERENCES

- 1- Abu Elzein, E.M.E. (2004). J. Sc. Tech. 29: [28–32].
- 2- Abu Elzein, E.M.E. (1985). Blue tongue in camels: a serological survey of the one-humped camel (*Camelus dromedarius*) in the Sudan. Rev. Elev. Med. Vet. Pays Trop. 38(4): [438–442].
- 3- Alhendi, A. B.; Abu Elzein, E.M.E.; Gameel, A. A., Hassanein, M. M. (1994).
- 4- Davies, F. G.; Mungai, J. M.; Shaw, T. (1975). Characteristics of a Kenyan camel pox virus. J. Hyg., Cambridge, 75: [381 – 385].
- 5- Hussein, M.F.; Hafez, S.M.; Gar Elnabi, M. (1987). Proc. 10th Symp. Saudi Bio. Soc. 20–24 April, Riyadh, King Saud Univ. Press. [8–14].
- 6- Hafez, S. M.; Eisa, Y.M.; Amjad, A.M.; Al-Sharif, A.K.; Alskayran, A.; Dela Cruz, D. (1986). Preliminary studies on camel pox in Saudi Arabia. Proc. 9th Symp. Saudi Bio. Soc. Riyadh, King Saud Univ. Press. 78.
- 7- Higgins, A.J. (1985). Common ectoparasites of the camel and their control. Brit. Vet. J. 141: [197 – 215].
- 8- McGrane, J.J. and Higgins, A.J. (1986). The Camel in Health and Disease. London, UK, Bailliere Tindall. [92–97].
- 9- Kriz, B. (1982). A study of camel pos in Somalia. J. Comp. Path. 92(1): [1–8].
- 10- Marennikova, S.S.; Shenkman, L.S., Shelukhina, E.M. and Maltseva, N.N. (1974). Isolation of camel pos and investigation of its properties. Acta Virologica. 18: [423–428].
- 11- Richard, D. (1980). Dromedary pathology and production. In: IFS Camels. Provisional Report No. 6. Workshop on camels. Khartoum, Sudan. 1979. 12: 18–20. [409–430]. Stockholm, IFS.
- 12- Richard, D. (1979). Study of the pathology of the Dromedary in Borana Awraja (Ethiopia). Ph.D. Thesis. IEMVT, Maiso-Alfort, France. (English version). [312].