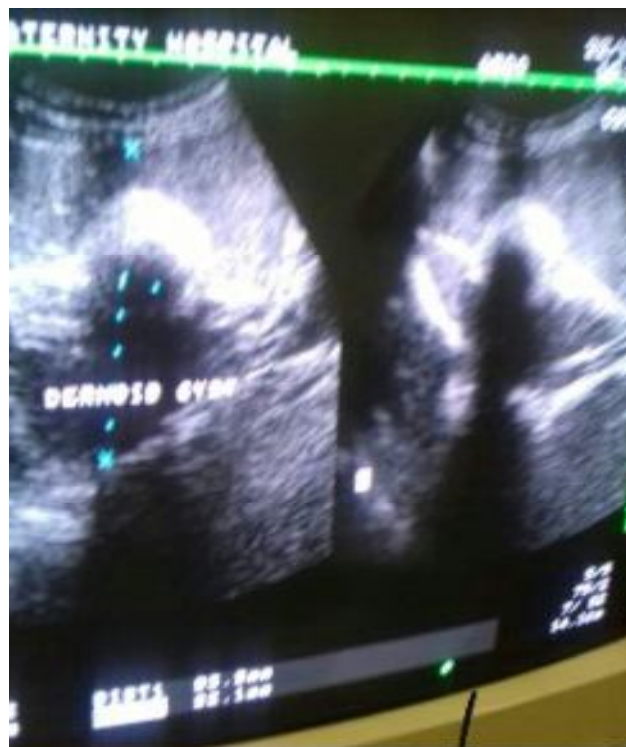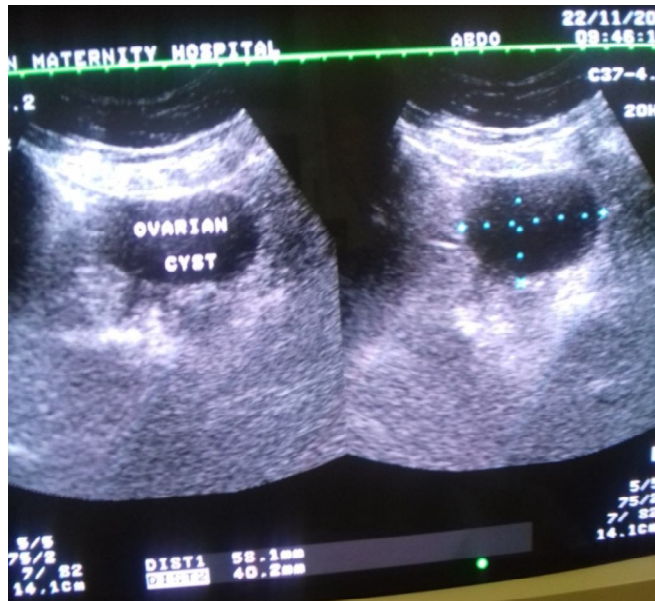

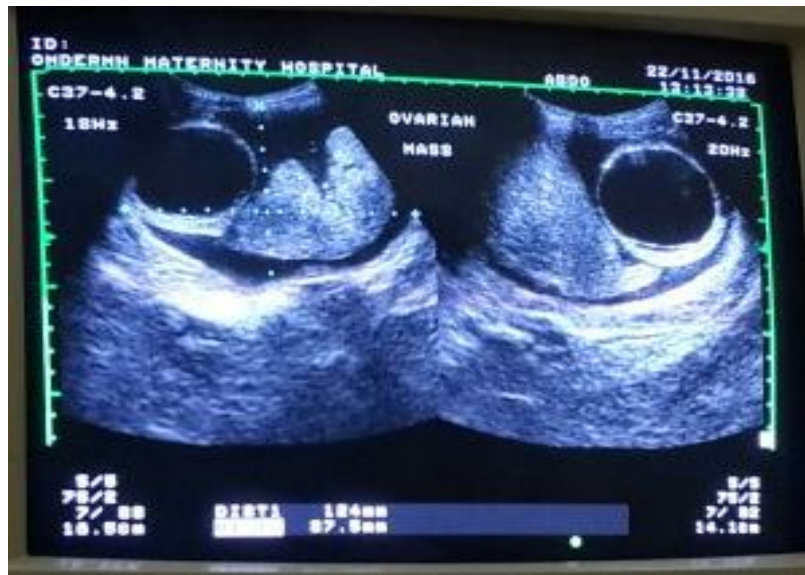


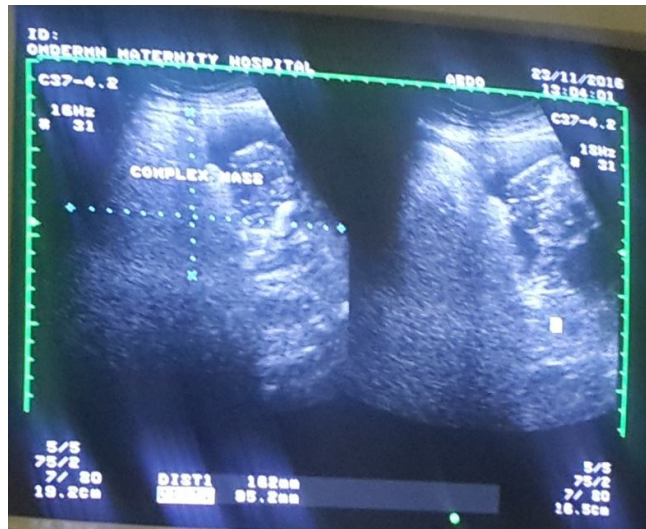
Appendix 1 U/S image of 40 years female shows Rt ovarian dermoid cyst.



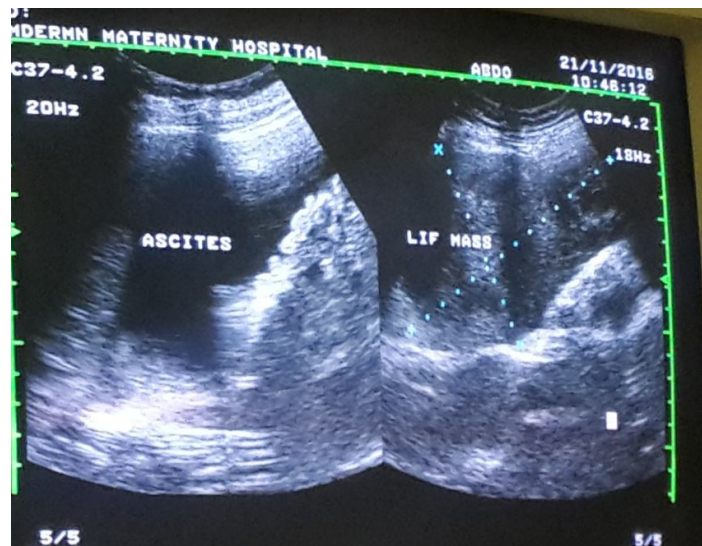
Appendix 2 U/S image of 41 years female shows right ovarian cyst.



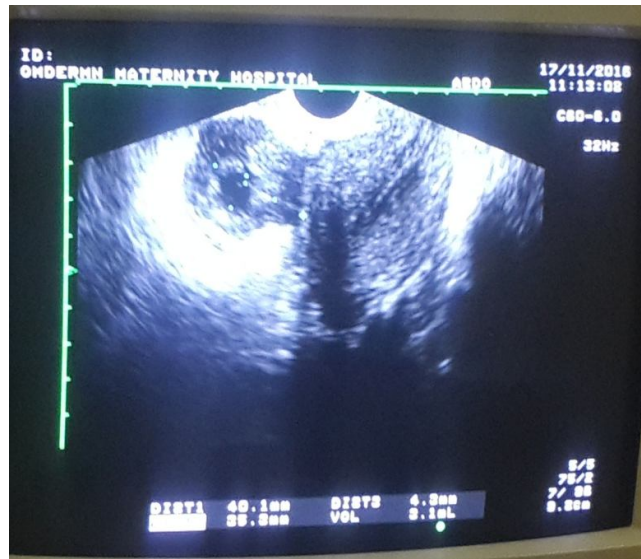
Appendix 3 U/S image of 18 years female shows Rt ovarian mass.



Appendix 4 U/S image of 55 years female shows Lt ovarian mass.



Appendix 5 U/S image of 55 years female shows Lt ovarian mass.



Appendix 6 U/S image of 30 years female shows Rt tubal ectopic pregnancy.