

SUDAN UNIVERSITY OF SCIENCES & TECHNOLOGY

COLLEGE OF GRADUATE STUDIES

Measurement of Normal Optic Nerve for Adult Sudanese Using
Computed Tomography

قياس العصب البصري الطبيعي لدى السودانيين البالغين باستخدام

الاشعة المقطعية المحوسبة

*A thesis Submitted for Partial Fulfillments the Requirements of
M.Sc. Radiological Imaging Diagnosis*

By;

Shihabaldin Ibrahim Mohamed Ahmed

SUPERVISOR:

D. IKHLAS ABDALAZEEZ

2017

قال تعالى

بسم الله الرحمن الرحيم

(هُوَ الَّذِي جَعَلَ الشَّمْسَ ضِيَاءً وَالْقَمَرَ نُورًا وَقَدَرَهُ مَنَازِلَ لِتَعْلَمُوا عَدَدَ السِّنِينَ وَالْحِسَابَ
مَا خَلَقَ اللَّهُ ذَلِكَ إِلَّا بِالْحَقِّ يُفَصِّلُ الْآيَاتِ لِقَوْمٍ يَعْلَمُونَ)

صدق الله العظيم

سورة يونس الاية (5)

Dedication

To my Father

To my mother for her moral support and all the work she did to get me where I am today.

To my wife and my daughter Retaj

To my lovely sisters and brothers for their kind support.

To my friends who stood beside me and supported me.

Thanks for all

ACKNOWLEDGMENTS

I thank almighty God for giving me the strength, courage and determination in conducting this study, despite all difficulties.

I would like to thank gratefully my supervisor

Dr. Ikhlas Abdelaziz

Phrases may not cover what I mean to show, but a word must be penned to those who helped me and guided me through the way and to those who intended to help me accomplish this work, it's because of their patience and splendid character

I reached this far.

Abstract:

This study was conducted to find out the mean optic nerve length and width in Sudanese population using CT.

Number of 100 patients CT orbit and brain was performed for Sudanese patient there ages between 20–80 years old, were 49 males and 51 females.

The result after data analysis was found the overall mean of optic nerve length was $[5.0052 \pm .43099]$ cm, and mean of optic nerve width $[\.3971 \pm .10012]$ cm. with minimum length $[4.00\text{cm}]$, and maximum length $[6.23 \text{ cm}]$.with minimum width $[\.23\text{cm}]$, and maximum width $[\.65 \text{ cm}]$.

There is a correlation between Also there is correlation between the optic nerve length and the patient weight as weight increase the length increase.

The optic nerve (length & width) slightly higher in males.

There is no relation between optic nerve width & length and the tribe.

خلاصة البحث

أجريت هذه الدراسة لقياس متوسط طول و عرض العصب البصري الطبيعي في المواطن السوداني باستخدام الأشعة المقطعية. وقد أجري التصوير لعدد مائة مريض باستخدام الأشعة المقطعية للعين والمخ لمواطنين سودانيين تراوحت اعمارهم ما بين ال 20 الي ال 80 عاما منهم 49 من الرجال و 51 من النساء .

وكانت النتيجة بعد تحليل البيانات كالآتي :- المتوسط الكلي لطول العصب البصري كان (5,0052+ _ 43099,سم) و متوسط العرض كان (3,971+ _ 10012,سم) و اقل طول (4,00,سم) و اعلى طول (6,23,سم) و اقل عرض (23,سم) و اعلى عرض (65,سم)

كانت هنالك علاقة ما بين طول العصب البصري ووزن المريض كلما زاد وزن المريض زاد طول العصب البصري .

طول و عرض العصب البصري اطول نسبيا في الرجال وليس هنالك علاقة بين طول و عرض العصب البصري بالقبيلة

List of Contents

No.	Content	Page no.
	Chapter One	
1.1	Introduction	1
1.2	Research problem	1
1.3	General objective	2
1.4	Specific objective	2
1.5	Research content	2
	Chapter Two	
2.1	Anatomy of the Eye	3
2.2	The optic nerve	3
2.3	The retina	16
2.4	Physiology of the Eye	17
2.5	Pathology of the Eye	17
2.6	Previous studies	27
	Chapter Three	
	Materials and Methods	30
3.1	Materials	30
3.2	Methods	32
	Chapter Four	
	Results	34
	Chapter Five	
5.1	Discussion	39
5.2	Conclusion	40
5.3	Recommendation	41
	References	42
	Appendix	44

List of Figures

Fig no.	Figure title	Page no.
2.1	Shows anatomy of optic nerve	3
2.2	Int aorbital parte of optic nerve	8
2.3	Visual pathway	9
2.4	Blood supply of optic nerve	11
3.1	Shows Toshiba CT machine 16 scanner	31
3.2	Shows neu soft CT machine 128 scanner	31
3.3	Axial CT orbit shows optic nerve	33
3.4	Axial CT orbit shows measurement length of optic nerve	33
4'1	Area distribution	35
4.2	Shows comparsion between males & female s optic nerve length diameter	36
4.3	Correlation between optic nerve length and weight	38
4.4	Correlation between optic nerve width and age	38
5.1	Sagittal CT orbit shows measurement length of optic nerve	45
5.2	Coronal CT orbit shows measurement width of optic nerve	45

List of Tables

Table no.	Title	Page no.
4.1	Gender distribution	34
4.2	Area distribution	34
4.3	Descriptive statistics	35
4.4	Group statistics	36
4.5	correlation statistics	37

Chapter One

1.1 Introduction

The optic nerve it is the sensory nerve of the retina .Its fibers originate in the ganglion layer and converge on the posterior part of the eye ball. The nerve passes backwards through the orbit and optic canal into the middle cranial fossa where it unites with the nerve of Opposite side of the optic chiasma (Longman-2003)

Optic Nerve, or the second cranial nerve has four portions, they are : intra cranial , intracanalicular , intra orbital and intraocular

Although we speak of the optic nerve ,it is very important to realis that it is really no nerve at all ,but essentially a fiber tract joining two portions of is uncontrollable .They are: It is an outgrowth of the brain , Its fibers possess no neurolemmal cells , It is surrounded by the meninges ,unlike any peripheral nerve and both the primary and secondary neurons are in the retina.(Agarwal-2008)

CT and MRI has great value in measurements of the optic nerve

1.2 Research problem

There is no comprehensive anthropometric study on normal measurement of optic nerve and therefore it was thought pertinent to undertake present study to evaluate the optic nerve measurement in different Sudanese tribes.

1.3 General Objective

To measure normal optic nerve in different Sudanese tribes using CT in order to find new index for Sudanese.

1.4 Specific objectives

- To evaluate the optic nerve diameter in axial, sagittal and coronal CT image.
- To correlate the finding with patient age, gender.
- To compare the optic nerve measurement in different Sudanese tribes.

1.5 Research content :

The study contains five chapters, chapter one consisted of introduction that contain an idea about the eye and the optic nerve in Addition to Research problem, Objectives. Chapter two includes the literature review and previous studies . Chapter three describes the material and methods. Chapter four includes the result, chapter five includes the discussion, conclusion , recommendations references and appendix.

Chapter Two

Theoretical Background and Literature Review

2.1 Anatomy of the Eye

When you look at a person eye you see only small part of the whole eye. Three layers of tissue form the eye ball: the sclera, the choroids, and the retina. The white of the eye is part of front surface of the sclera. The other part of the front surface of the sclera is called the cornea and is sometime spoken of as the window of the eye because of its transparency .At casual glance, however, it dose not look transparent colored part of the eye. A mucous membrane known as the conjunctiva is kept moist by tears formed in the lacrimal gland located in the upper lateral portion of the orbit.(Longman et al ,2003)

The middle layer of the eye ball ,the choroid, contains a dark pigment to prevent the scattering of incoming light rays. Two involuntary muscles make up to front part of the choroids .One is the iris, the colored structure seen through the cornea, and the other is the ciliary muscle. the black center of the iris is really a hole in the this doughnut-shape muscle ,it is pupil of the eye. So me of the fibers of the iris are arranged like spokes in the wheel .When they contract, the pupils dilate ,letting in more light rays . Other fibers are circular. When they contract, the pupils constrict, letting fewer light rays. Normally, the pupils constrict in bright light and dilate in dim light. When we look at distant objects, the ciliary muscle is relaxed, and the lens has only a slightly curved shape. To focus on near objects, however, the ciliary muscle contract. As it contracts, it pulls the choroids coat forward toward the lens, thus causing the lens to bulge and curve even more. Most of us become more

farsighted as we grow older and lose the ability to focus on close objects because our lenses lose their elasticity and can no longer bulge enough to bring near objects into focus. Presbyopia or old sightedness is the name for this condition . The retina or innermost layer of the eyeball contains microscopic receptor cells, called rods and cones because of their shapes. Dim light can stimulate the rods, but fairly bright light is necessary to stimulate the cones. In other words, rods are the receptors for night vision and cones for daytime vision. There are three kinds of cones; each is sensitive to a different color: red, green, or blue. Scattered throughout the central portion of the retina, these three types of cones allow us to distinguish between different colors (Longman,2003)

2.2.1 The Optic Nerve

The optic nerve is sensory nerve of the retina. Its fibers originate in the ganglion layer and converge on the posterior part of the eye ball. The nerve passes backwards through the orbit and optic canal into the middle cranial fossa where it unites with the nerve of opposite side of the optic chiasma. (Longman et al 2003).

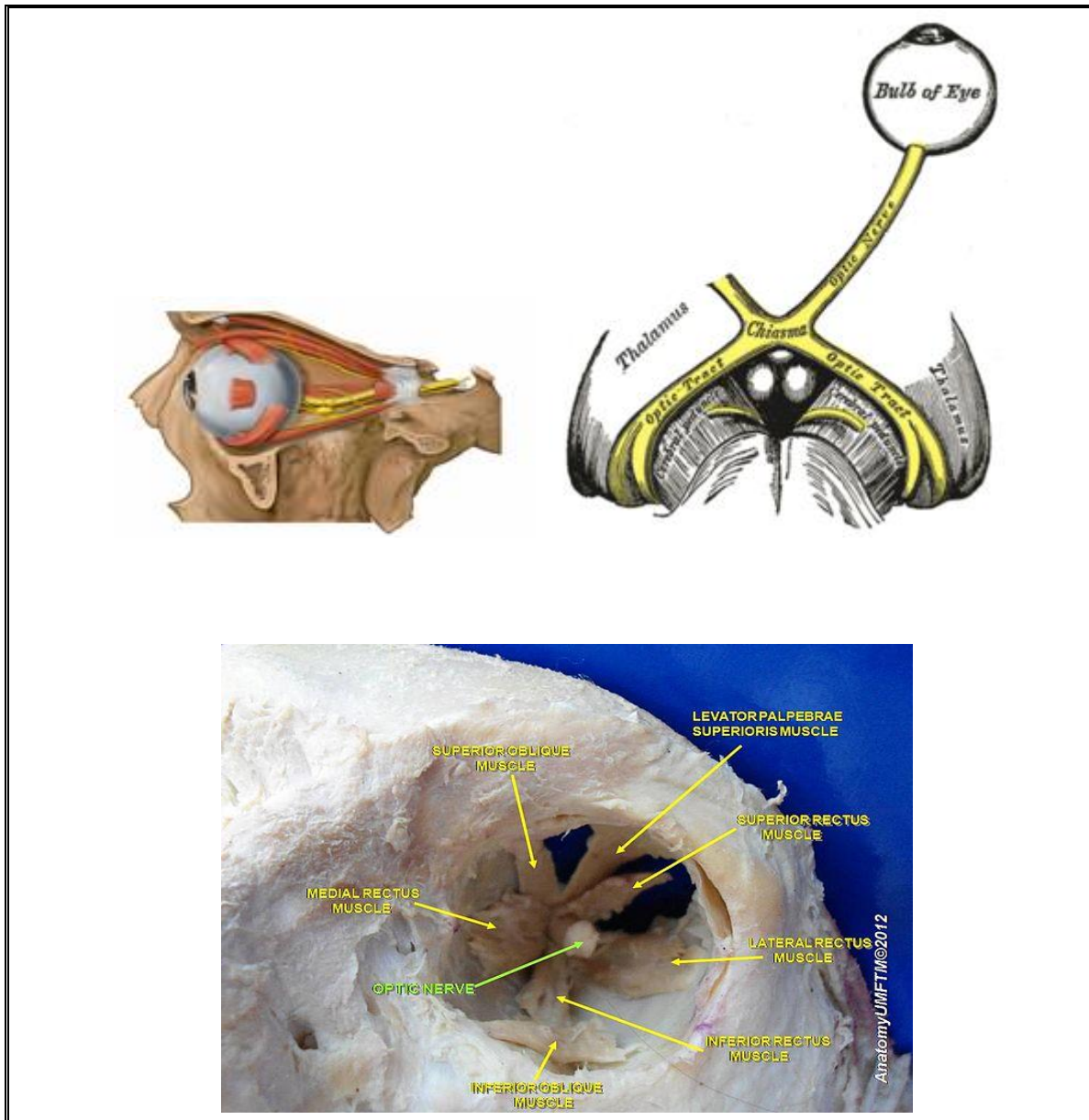


Fig (2.1) : shows anatomy of optic nerve

Optic Nerve, or the second cranial nerve has four portions, they are :

intra cranial , intracanalicular , intra orbital and intraocular

Although we speak of the optic nerve ,it is very important to realist that it is really no nerve at all ,but essentially a fiber tract joining two portions of is uncontrollable .They are: It is an

outgrowth of the brain , Its fibers possess no neurolemmal cells , It is surrounded by the ménages ,unlike any peripheral nerve and both the primary and secondary neurons are in the retina.(Agarwal-2008)

2.2.2 Intracranial Portion

Optic nerve unsheathed in pia runs as a flattened band from the anterior lateral angle of the somewhat quadrilateral optic chiasma . It runs forwards and The laterally and slightly downwards to the optic foramen . (Agarwal-2008)).

2.2.3 Intra canalicular Portion

At its entry into the optic canal, it receives a covering of arachnoid mater and since the dura mater is prolonged through the canal as aperiosteum, the nerve is in fact from here onwards surrounded by all three meninges and also of course, the cerebrospinal fluid. It traverses the optic canal and enters the orbit.(Agarwal-2008) .

2.2.4 Intraorbital Portion

As a rounded cord, it now runs forwards and slightly laterally and downwards in a somewhat sinuous manner to allow for ocular movements and is continued into the back.(Agarwal-2008) .

2.2.5 Intraocular Portion

It then enters the eyeball just above and 3 mm medial to the posterior pole.
(Agarwal-2008).

2.2.6 Relation

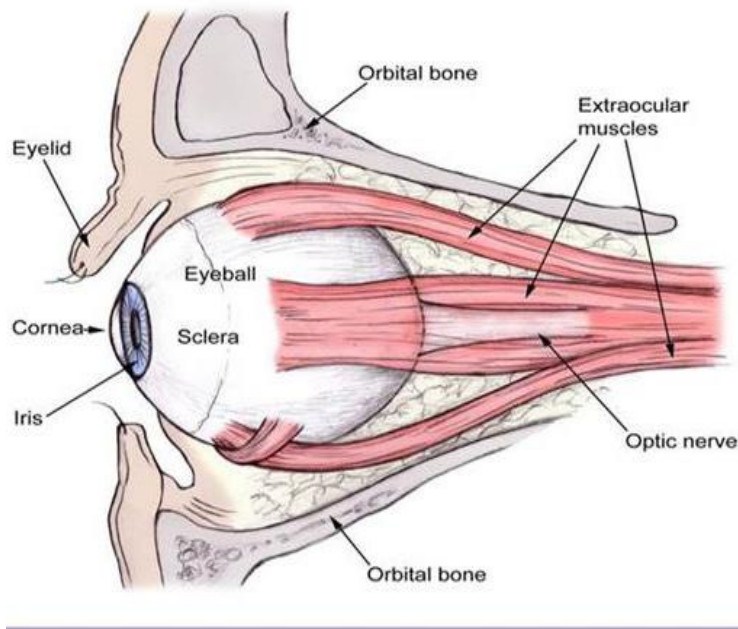
2.2.6.1 Intracranial Portion

The nerve lies at first above the diaphragm sellae, which covers the pituitary body. Between the two nerves in front of the chiasma is a triangular space in which is a variable portion of the pituitary, covered by the diaphragm sellae. Above the nerve is the anterior perforated substance, the medial root of the olfactory tract and the anterior cerebral artery, which crosses superiorly to reach its medial side. The internal carotid artery is at first below and then lateral. (Agarwal-2008).

2.2.6.2 Intra-canalicular Portion

The pia forms a sheath closely adherent to the nerve . The dura constitutes the periosteal lining to the canal and at its orbital end splits to become continuous on the one hand with the periorbita and on the other hand with the dura of the optic nerve. The ophthalmic artery crosses below the nerve in the dural sheath to its lateral side. It leaves the dura at or near the anterior end of the canal. Thus, the internal carotid artery is to some extent tied to the dural sheath by its ophthalmic branch and it is also indirectly attached to the optic nerve by the adherence of the sheaths and by branches to the nerve from the ophthalmic artery. Medial to the optic nerve is the sphenoidal air sinus or a posterior ethmoidal sinus, from which it may be separated by a thin plate of bone only. This provides the explanation of retrobulbar neuritis following a sinus infection. (Agarwal-2008).

2.2.6.3 Intraorbital Portion



Figure(2.2) intraorbital part of optic nerve (Agarwal-2008).

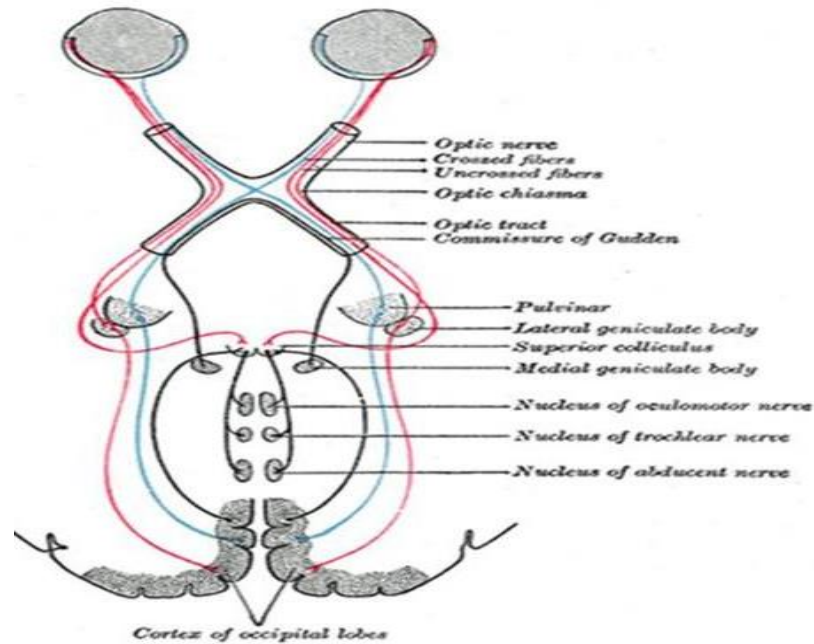
At the optic foramen, the nerve is surrounded by the origin of the ocular muscles. The superior and medial rectus is closely adherent to the dural sheath.

It is this connection which gives rise to the pain in Anatomy of the Optic Nerve extreme movements of the globe, so characteristic of retrobulbar neuritis. Between the optic nerve and the lateral rectus are the divisions of the III cranial nerve, nasociliary nerve, sympathetic nerves and the VI cranial nerve. The nasociliary nerve, ophthalmic artery and superior ophthalmic vein cross the nerve superiorly between the nerve and the superior rectus from its lateral to medial side. The ciliary ganglion is lateral to the nerve between the nerve and the lateral rectus. The central retinal artery near the optic foramen, runs forwards in or outside the dural sheath of the nerve. Then it crosses the subarachnoid space to enter the nerve on its under and medial aspect about 12 mm behind the eye. (Agarwal-2008).

2.2.6.4 Intraocular Portion

The intraocular portion passes through the sclera and choroid and finally appears in the eye as the optic disk . The intraocular portion of the optic nerve head has an average diameter of 1.5 mm. (Agarwal-2008).

2.2.7 Visual pathway



Fig(2.3): visual pathway (Agarwal-2008).

Light is the stimulus that results in vision (that is our ability to see objects as they exist in our environment). Light enters the eye through the pupil and is refracted or bent so that it is focused on the retina. Refraction occurs as light passes through the cornea, the aqueous humor, the lens, and the vitreous humor on its way to the retina. The innermost layer of the retina contains the rods and cones, Which are the photoreceptor cells of the eye.(Longman,et al 2003)

They respond to a light stimulus by producing a nervous impulse. The rod and cone photoreceptor cells synapse with neurons in the bipolar and ganglionic layers of the retina. Nervous signals

eventually leave the retina and exit the eye through the optic nerve on the posterior surface of the eyeball. No rods or cones are present in the area of the retina where the optic nerve fibers exit. The result is a "blind spot" known as the optic disc.(Longman,et al 2003).

After leaving the eye, the optic nerves enter the brain and travel to the visual cortex of the occipital lobe. In this area of the brain, visual interpretation of the nervous impulses that were generated by light stimuli in the rods and cones of the retina result in "seeing".(Longman,et al 2003).

2.2.8 Blind spot

The beginning of the optic nerve in the retina is called the optic nerve head or optic disc. Since there are no photoreceptors (cones and rods) in the optic nerve head, this area of the retina cannot respond to light stimulation. As a result, it is known as the "blind spot," and everybody has one in each eye. The reason we normally do not notice our blind spots is because, when both eyes are open, the blind spot of one eye corresponds to retina that is seeing properly in the other eye .(montgomery-1998)

2.2.9 Blood supply of optic nerve

The visual pathway is mainly supplied by pial net work of the vessels except the orbital part of optic nerve which also supplied by and axial system derived from the central artery of retina .The pial plexus around different parts of the visual pathway gets contribution from different arteries.

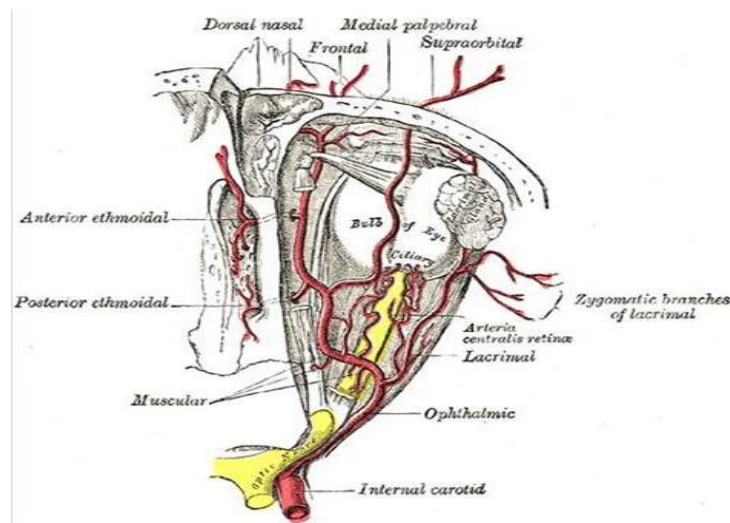
visual pathway is supplied by:Pial plexus , Calcarian A , Posterior cerebral A and Anterior choroidal A

Blood supply of the optic nerve head: The surface layer of the optic disc is supplied by capillaries derived from the retinal arterioles.

The prelaminar region is mainly supplied by centripetal branches of the peripapillary choroid with some contribution from the vessels of lamina cribrosa.

The lamina cribrosa is supplied by branches from the posterior ciliary arteries and arterial circle of Zinn.

The retrolaminar part of the optic nerve is supplied by centrifugal branches from central retinal artery and centripetal branches from pial plexus formed by branches from the choroidal arteries, circle of Zinn, central retinal artery and ophthalmic artery. (Agarwal-2008).



Figure(2.4):blood supply of optic nerve(Agarwal-2008).

2.2.10 Congenital Optic Nerve Anomalies

Congenital optic nerve anomalies are quite a common entity and are often included in the differential diagnosis of various clinical disorders as they are often associated with visual field defects

central nervous system (CNS) malformations and other ocular abnormalities. A thorough knowledge of the embryological development of the optic nerve entails a better understanding of the development of optic nerve anomalies. (Agarwal-2008).

2.2.10.1 Aplasia

Aplasia is a rare anomaly characterized clinically by a total blind eye with an afferent pupillary defect, an absent optic disk and an absent retinal vasculature. (Agarwal-2008).

2.2.10.2 Hypoplasia

The optic disk hypoplasia is a sporadic condition. The affected can be micro-ophthalmic or of normal size and usually exhibit a wide range of visual impairment from normal vision to severe visual loss with strabismus or nystagmus in bilateral cases. Visual acuity is determined primarily by the integrity of the papillomacular bundle. The visual fields show a localized defect. The disk is surrounded by a peripapillary halo, bordered by a dark pigment ring called as the double ring sign. Retinal vascular tortuosity is commonly seen. (Agarwal-2008).

2.2.10.3 Bergmister's Papillae

The glial sheath of Bergmister envelops the posterior third of the hyaloid artery it begins to atrophy about the seventh month of gestation, even before the main vessel atrophies. The extent of the atrophy is below the surface of the disk. If the atrophy at the disk is less complete a tuft of glial tissue may be seen throughout the life over the optic disk called the Bergmister's papillae. (Agarwal-2008).

2.2.10.4 Myelinated Nerve Fibers

Medullation or myelination of the optic nerve begins in the fetal life from the lateral geniculate body towards the globe. Normally the myelination is completed shortly after birth at which time the myelin sheath reaches the posterior aspect of the lamina cribrosa. The medullated fibers may be seen starting from the disk and extending towards the periphery. Fundus examination shows irregular feather-like patches which may or may not obscure the retinal blood vessels. Rarely, isolated peripheral patches of myelination may also occur. Myelination of the nerve fibers results in visual field defects. Myopia, coloboma, polycoria, keratoconus, oxycephaly and neurofibromatosis have been associated with myelinated nerve fibers. (Agarwal-2008).

2.2.10.5 Optic Nerve Head Drusen

Deposition of hyaline like calcified material within the substance of the optic nerve head. Optic nerve head drusen can be inherited or can be associated with hereditary degenerative conditions like retinitis pigmentosa or angioid streaks or can be following long standing papilledema, papillitis, vascular occlusions. Clinically has an irregular, nodular, mulberry like appearance of the surface of the disk. The physiological cup can be absent but venous pulsation is present there can be abnormal tortuous, anomalously branching vessels. Disk can be pallor some times but will have irregular margins. They vary greatly in size, shape and number, smaller ones often coalesce to form larger ones. The differential diagnosis of optic disk drusen includes papilledema with which it is often confused.

Patients with disk drusen usually remain asymptomatic although few cases have been reported to develop peripapillary and macular hemorrhage. Drusen may directly compress the nerve fibers

within the disk and cause various visual field defects like enlargement of the blind spot, arcuate scotoma or peripheral field constriction. Central visual acuity is usually good. (Agarwal-2008).

2.2.10.6 Coloboma of optic disk

A coloboma of the optic disk results from incomplete closure of the embryonic fissure. The fissure initially closes in the middle and then extends anteriorly and posteriorly until a small crescent at the posterior pole remains open. When the lips of the fissure fail to fuse, typical colobomas result. The coloboma of the optic nerve may occur alone or may be associated with coloboma of the iris, retina, choroid or ciliary body. (Agarwal-2008).

2.2.11 Optic Nerve Tumors

Tumors of the optic nerve are relatively rare lesions. However, these lesions have significant risk for visual morbidity as well as other problems related to the central nervous system (CNS). Optic nerve glioma (astrocytoma) is the most common intrinsic tumor of the optic nerve. Juvenile pilocytic astrocytomas are by far the most common optic nerve tumor of children. Malignant gliomas of the optic nerve occur much less frequently and are seen in adults. Meningiomas of the optic nerve sheath are the second largest group of tumors which may affect the optic nerve and occur more commonly in adults. Lastly, secondary tumors of the optic nerve may arise from direct invasion from intraocular malignancies, meninges, adjacent structures, as well as distant metastases. (Agarwal-2008).

2.2.11.1 Optic nerve glioma

Gliomas (juvenile pilocytic astrocytoma) are the most important optic nerve tumor of children, accounting for 65 percent of all intrinsic optic nerve tumors. Gliomas are benign neoplasms arising from the neuroglia (astrocytes and oligodendrocytes). The majority of optic nerve gliomas are of astrocytic origin. However, a few rare optic nerve gliomas arise from oligodendrocytes. The descriptive term juvenile pilocytic astrocytoma is often used to describe this low-grade glioma. Gliomas grow slowly, but can spread under the dura to invade local structures. Patients typically present before the age of 20 with progressive visual loss, proptosis, and disk pallor with or without papilledema. Management includes observation, radiation, and surgery.

Gross Appearance: Optic nerve gliomas are typically contained within the dura . The dura is stretched and thin, but usually intact. Typical gliomas appear tan to dusky red from the vascular congestion within the tumor. Orbital gliomas are characteristically fusiform, with the borders of the tumor difficult to delineate. Thus, it is helpful to obtain cross-sections at the end of each specimen. Gliomas may also invade the arachnoid and pia, and extend through the subdural space. This pattern occurs more often in neurofibromatosis patients. The nerve itself may be of normal thickness, but the overall diameter may be increased because of the perineural component. Cross-sections through the middle portion show the whitish nerve enlarged and surrounded by a cuff of arachnoidal tissue, which is then covered by stretched dura.

(Agarwal-2008).

2.2.11.2 Optic nerve meningiomas

Meningiomas are the second most common optic nerve tumor, after gliomas. Meningiomas are benign neoplasms arising from

meningothelial cells typically in the arachnoid. Patients generally are middle-aged adults and present with decreased vision, visual field loss, proptosis, disk atrophy, disk swelling, and later on opticociliary shunt vessels. Meningiomas grow slowly, but are invasive and infiltrate surrounding structures. Management includes conservative monitoring, radiotherapy, and surgery . (Agarwal-2008).

2.3 The Retina

The retina is the innermost layer of the eye (the tunica intima or internal tunic) and is comparable to the film inside of a camera. It is composed of nerve tissue which senses the light entering the eye .(Montgomery,1998)

This complex system of nerves sends impulses through the optic Nerve back to the brain, which translates these messages into images that we see. That is, we “see” with our brains; our eyes merely collect the information to do so. The retina is composed of 10 layers, from the outside (nearest the blood vessel enriched choroid) to the inside (nearest the gelatinous vitreous humor) Pigmented epithelium, photoreceptors, bacillary layer (outer and inner segments of cone and rod photoreceptors), external (outer) limiting membrane, outer nuclear (cell bodies of cones and rods), outer plexiform (cone and rod axons, horizontal cell dendrites, bipolar dendrites), inner nuclear (nuclei of horizontal cells, bipolar cells, amacrine cells, and Müller cells), inner plexiform (axons of bipolar cells and amacrine cells, dendrites of ganglion cells), ganglion cells (nuclei of ganglion cells and displaced amacrine cells), nerve fiber layer (axons from ganglion cells traversing the retina to leave the eye at the optic disc), and internal limiting membrane (separates the retina from the vitreous).(Montgomery,1998).

Beneath the pigmented epithelium of the retina are these layers, from the outside (furthest from the retina) to the inside (closest to the retina): sclera (white part of the eye) ,large choroidal blood vessels,choriocapilaris Bruch's membrane (separates the pigmented epithelium of the retina from the choroid)(Montgomery,1998).

2-4 Physiology of the Eye

Process of vision: light waves from an object (such as a tree) enter the eye first through the cornea, which is the clear dome at the front of the eye.It is like a window that allows light to enter the eye.The light then progresses through the pupil, the circular opening in the center of the colored iris.(Montgomery,1998).

Fluctuations in the intensity of incoming light change the size of the eye's pupil.As the light entering the eye becomes brighter, the pupil will constrict (get smaller), due to the pupillary light response .As the entering light becomes dimmer, the pupil will dilate (get larger).(Montgomery,1998). Initially, the light waves are bent or converged first by the cornea and then further by the crystalline lens (located immediately behind the iris and the pupil), to a nodal point (N) located immediately behind the back surface of the lens.At that point, the image becomes reversed (turned backwards)and inverted (turned upside-down).(Montgomery,1998).

2.5 Pathology of the Eye

2.5.1 Optic Atrophy:

Optic atrophy of the optic disc (visible to an eye doctor looking inside the eye) is the result of degeneration of the nerve fibers of the optic nerve and optic tract. It can be congenital (usually hereditary) or acquired.(Montgomer,1998)

If acquired, it can be due to vascular disturbances (occlusions of the central retinal vein or artery or arteriosclerotic changes within the optic nerve itself), may be secondary to degenerative retinal disease (e.g., optic neuritis or papilledema), may be a result of pressure against the optic nerve, or may be related to metabolic diseases (e.g., diabetes), trauma, glaucoma, or toxicity (to alcohol, tobacco, or other poisons). (Montgomery, 1998).

2.5.2 Optic neuritis:

Optic neuritis is an inflammation of the optic nerve. It may affect the part of the nerve and disc within the eyeball (papillitis) or the portion behind the eyeball (retrobulbar optic neuritis, causing pain with eye movement). It also includes degeneration or demyelination of the optic nerve. There will be no visible changes in the optic nerve head (disc) unless some optic atrophy has occurred. (Montgomery, 1998).

The condition is unilateral rather than bilateral. If the nerve head is involved, it is slightly elevated, and pupillary response in that eye is sluggish. There usually is a marked but temporary decrease in vision for several days or weeks, and there is pain in the eye when it is moved. Single episodes generally do not result in optic atrophy nor in permanent vision loss; however, multiple episodes can result in both. (Montgomery, 1998)

2.5.3 papilledema:

Papilledema is edema or swelling of the optic disc (papilla), most commonly due to an increase in intracranial pressure (often from a tumor), malignant hypertension, or thrombosis of the central retinal vein. The condition usually is bilateral, the nerve head is very elevated and swollen, and pupil response typically is normal. (Montgomery, 1998).

Vision is not affected initially (although there is an enlargement of the blind spot), and there is no pain upon eye movement. Secondary optic atrophy and permanent vision loss can occur if the primary cause of the papilledema is left untreated.(Montgomery,1998).

2.5.4 Ischemic optic neuropathy:

Ischemic optic neuropathy is a severely blinding disease resulting from loss of the arterial blood supply to the optic nerve (usually in one

eye), as a result of occlusive disorders of the nutrient arteries .Optic

neuropathy is divided into anterior, which causes a pale edema of the optic disc, and posterior, in which the optic disc is not swollen and the abnormality occurs between the eyeball and the optic chiasm. (Montgomery,1998)

Ischemic anterior optic neuropathy usually causes a loss of vision that may be sudden or occur over several days. Ischemic posterior optic neuropathy is uncommon, and the diagnosis depends largely upon exclusion of other causes, chiefly stroke and brain tumor .(Montgomery,1998)

2.5.5 Glaucoma:

Glaucoma is an insidious disease which damages the optic nerve, typically because the “intraocular pressure” (IOP) is higher than the retinal ganglion cells can tolerate. This eventually results in the death of the ganglion cells and their axons, which comprise the optic nerve. Thus, less visual impulses are able to reach the brain. (Montgomery,1998)

In advanced glaucoma, the visual field in the peripheral retina is decreased or lost, leaving vision in the central retina (macular area) intact. This results in “tunnel vision.” Elevated eye pressure occurs when too much aqueous fluid enters the eye and not enough of the aqueous fluid is leaving the eye. Eye pressure can be measured by performing a “tonometry” test. (Montgomery, 1998)

Normally, fluid enters the eye by seeping out of the blood vessels in the ciliary body. This fluid eventually makes its way past the crystalline lens, through the pupil (the central opening in the iris), and into the irido-corneal angle, the anatomical angle formed where the iris and the cornea come together. Then the fluid passes through the trabecular meshwork in the angle and leaves the eye, via the canal of Schlemm. (Montgomery, 1998)

If the rate of aqueous fluid entering the eye is too great, or if the trabecular meshwork “drain” gets clogged (for instance, with debris or cells) so that the fluid is not leaving the eye quickly enough, the pressure builds up in what is known as “open angle glaucoma.” It is more common with increasing age (Montgomery, 1998).

Open angle glaucoma, which tends to be a chronic and painless condition, also can be caused when the posterior portion of the iris, surrounding the pupil, somehow adheres to the anterior surface of the lens (creating a “pupillary block”). This can prevent intraocular fluid from passing through the pupil into the anterior chamber. (Montgomery, 1998).

On the other hand, if the angle between the iris and the cornea is too narrow, or is even closed, then the fluid backs up because it cannot flow out of the eye properly. This causes an increased intraocular pressure in what is known as “closed angle glaucoma.”

Typically, there is an acute (sudden), painful onset. It can be accompanied by the appearance of rainbow-colored rings around white lights. (Montgomery, 1998).

An internal pressure more than that which the eye can tolerate can deform the lamina cribrosa, the small cartilaginous section of the sclera at the back of the eye through which the optic nerve passes.

A deformed lamina cribrosa seems to “pinch” nerve fibers passing through it, eventually causing axon death. Untreated glaucoma eventually leads to optic atrophy and blindness. (Montgomery, 1998)

Eye pressure is measured by using a “tonometer” (with the test being called “tonometry”), and the standard tonometer generally is considered to be the “Goldmann tonometer.” The normal range of intraocular pressure (IOP) is 10mm Hg to 21mm Hg, with an average of about 16mm Hg. Typically, eyes with intraocular pressure

measurements of 21mm Hg or higher, using a Goldmann tonometer, are considered to be “ocular hypertensive” and are suspect for glaucoma. (Montgomery, 1998).

However, although glaucoma typically is associated with elevated IOP, the amount of pressure which will cause glaucoma varies from eye to eye and person to person. Many people with glaucoma actually have IOP’s in the normal range (“low tension” glaucoma), possibly indicating that their lamina cribrosas are too weak to withstand even normal amounts of pressure.

Conversely, many people with IOP’s which would be considered high have no evidence of glaucomatous damage (Montgomery, 1998)

Glaucomatous changes in the optic disk (optic nerve head) usually can be detected over time. If the optic cup within the optic disk

increases in size over a period of months or years, if nothing is observed anywhere around the nerve head rim, and/or if an asymmetry is observed between the optic cups of the two eyes, then that person may be considered to be a “glaucoma suspect” .In glaucoma, optic nerve rim atrophy and/or notching, with a corresponding visual field decrease, usually will occur in this order:

Visual field loss, caused by optic nerve damage, is measured by using a “visual field analyzer” or “perimeter,” especially by measuring and comparing changes over time. The procedure is known as 18 “perimetry.”Most field loss due to glaucoma usually is not even measurable until 25% to 40%of the optic nerve’s axons have been destroyed. (Montgomery,1998).

Studies seem to show that the first fibers to die are the larger fibers, which primarily carry form and motion information, rather than the smaller fibers, which primarily detect light. Therefore, pattern Discrimination perimetry (PDP), which requires detection of both form and motion, may be a better test for early glaucoma than conventional perimetry, which requires detection of spots of light .(Montgomery,1998).

In pattern discrimination perimetry (PDP), various locations of the retina are stimulated with a checkerboard pattern on a background of randomly moving dots. The more random the dot movements, the more difficult it is to continue to perceive the checkerboard pattern.

Even a normal eye eventually will not be able to see the checkerboard when the dot movement is random enough. (Montgomery,1998).

The more advanced the stage of glaucomatous nerve damage, the less “noisy” the dots need to be for the checkerboard pattern to be

indistinguishable from the background of moving dots. In effect, the PDP seems to be more sensitive than a standard perimeter in detecting early glaucomatous visual field losses. (Montgomery, 1998).

Typically, the elevated pressure in open angle glaucoma can be controlled using glaucoma medications, which either decrease the production of aqueous fluid or else increase its outflow from the eye.

However, closed angle glaucoma often requires surgical intervention to be controlled. (Montgomery, 1998).

2.5.6 Cataract:

Normally, all the layers of the crystalline lens are clear, and light passes through it unobstructed. However, with age or due to certain systemic diseases, as well as with a cumulative absorption of ultraviolet radiation over many years, the lens material can become cloudy, yellow, brown, and even opaque. Anything in the lens which obstructs entering light is referred to as a “cataract.” (Montgomery, 1998).

More than 50% of people over the age of 60 have some form of a cataract. It has been said that if one lives long enough, he/she will develop a cataract. Even some infants are born with a “congenital” cataract which, if left untreated, can cause permanent visual impairment or blindness, even if the cataract is removed years later. (Montgomery, 1998).

It is not possible to remove a primary cataract without irreparably damaging the crystalline lens within which the cataract is contained.

A laser cannot be used successfully to remove a cataract, except as described later (in the case of a secondary cataract). Therefore, cataract surgery involves removing most or all of the lens of the

eye and replacing it with an artificial “intraocular lens” or “lens implant,” made of a hard plastic (polymethyl methacrylate or PMMA), silicone, acrylic, or hydro gel material .(Montgomer,1998).

An “extracapsular” cataract extraction (ECCE) is the routine type of cataract removal. In an ECCE procedure, an opening is made in the front of the lens capsule. Through this opening, the lens nucleus is removed, either as a whole or by dissolving it into tiny pieces and vacuuming out the pieces, a procedure called “phacoemulsification.” Next, the lens cortex also is sucked out, leaving the lens capsule in place, and into the lens capsule is inserted the artificial lens implant.(Montgomery,1998)

Prior to the 1980’s, the entire crystalline lens was removed in a cataract surgery, called an “intracapsular” cataract extraction (ICCE). Usually, this was performed using “cryoextraction,” where acryoprobe froze the entire lens, permitting its complete removal. Now, in the unusual case of an intracapsular lens extraction, or ICCE, the implant lens is placed in front of the iris, rather than behind it, because there is no lens capsule to hold the implant in place. Rarely is this procedure done anymore.(Montgomery,1998). Approximately 1-2% of post-cataract extraction patients develop swelling in the area of the retina responsible for central vision (the macula). This swelling occurs in cystoids spaces, and is referred to as cystoids macular edema. After an initial improvement following surgery, these patients subsequently will describe blurred vision. Cystoids macular edema can occur as early as days, or as late as several years, following surgery. Treatment options include observation, topical therapy, periocular injections, and surgery.(Montgomery,1998).

occurring carotenoids in the crystalline lens—lutein and

zeaxanthin (molecular cousins of beta carotene and vitamin A)—have been shown to reduce the risk of cataracts. These pigments act as antioxidants within the lens, inhibiting the formation of free radicals, which can damage lenticular material and contribute to the development of cataracts(Montgomery,1998)

Thus, it may be that the greater the amount of antioxidants such as lutein and zeaxanthin in the system, the less the risk of cataract formation. These two antioxidants are found particularly in yellow fruits and in green leafy vegetables (especially xanthophyll-rich vegetables such as spinach, kale, collard greens, and broccoli), in eggs, and as nutritional supplements (Montgomery,1998

2.5.7 Retinal detachment (RD):

Normally, with age, the vitreous gel collapses and detaches from the retina—an event known as a posterior vitreous detachment. Occasionally, however, the vitreous membrane pulls on and creates a tear in the retina. Vitreous fluid can seep into or beneath the retina, detaching it from the pigmented epithelium underneath. (Montgomery,1998). When a retinal detachment occurs, a shower of floaters may be observed by the person experiencing the detachment. These are thousands of blood cells being liberated from a tiny blood vessel which has been broken due to the retinal tear or detachment. Sometimes the floaters are described as being like a “shower of pepper” before the eyes. (Montgomery,1998). Sudden flashes of light, as well as a “web” or “veil” in front or else in the periphery of the eye, also may appear in conjunction with the onset of floaters. The retinal tear and subsequent detachment must be repaired as soon as possible, usually with one of these procedures: sealing it using an argon laser (“photocoagulation”), freezing it (“cryotherapy” or “cryopexy”), securing it, after cryotherapy, with a tiny belt around the equator of the eye (“scleral

buckle” surgery), injecting a gas bubble into the eye (in conjunction with photocoagulation or cryopexy) so that the bubble rests against

The hole or tear (“pneumatic retinopexy”), requiring the person to keep his/her head in the same position for several days, or removing the vitreous gel and filling the eye with a gas bubble or silicon oil (“vitrectomy”). (Montgomery, 1998).

2.5.8 Retinitis pigmentosa (RP):

One of the most devastating conditions affecting the rods is “retinitis pigmentosa,” an inherited disorder in which the rods gradually degenerate. With time, night vision is severely affected. Eventually, all peripheral vision will continue to be destroyed, to the point where only central or “tunnel” vision remains. (Montgomery, 1998)

There is no known treatment. However, since blue and ultraviolet light may make aggravate the condition, amber-colored glasses with an ultraviolet absorption coating, worn during the day, may slow down the disease process. (Montgomery, 1998).

Studies have shown that retinitis pigmentosa is caused by mutations in the rhodopsin gene, the peripherin gene, and possibly in other genes within the rod. Mutations in the peripherin gene also may be the cause of another devastating retinal disorder: “macular dystrophy.” (Montgomery, 1998)

2.6 Previous studies

Benevento, et al 2011 studied Optic Nerve Measurements in Normal Human Eyes by MRI and they used Coronal MRI imaging of normal human eyes it's showed an average ONSD range of 4.0 – 6.0 with SD 0.5mm, and an average OND range of 2.6 – 4.0 with SD 0.3mm. These ranges are consistent with published data on the ONSD. However, we are not aware of any published data on the OND.

Newcombe, et al 2008 Used T2-weighted magnetic resonance imaging of the optic nerve sheath to detect raised intracranial and they found 35 results that the Measurement of ONSD was possible in 95% of cases. The ONSD was significantly greater in TBI patients with raised ICP (>20 mmHg; $\pm 6.31, 0.50$ mm, 19 measures) than in those with ICP of 20mmHg or less ($\pm 5.29, 0.48$ mm, 26 measures; $P < 0.0001$) or in healthy volunteers ($\pm 5.08, 0.52$ mm; $P < 0.0001$). There was a significant relationship between ONSD and ICP ($r = 0.71, P < 0.0001$). Enlarged ONSD was a robust predictor of raised ICP (area under the receiver operating characteristic curve = 0.94), with a best cut-off of 5.82 mm, corresponding to a negative predictive value of 92%, and to a value of 100% when ONSD was less than 5.30 mm.

Brex, et al 2011 describe an MRI technique for quantifying optic nerve atrophy resulting from a single episode of unilateral optic neuritis. They imaged 71 patients, with a median time since onset of optic neuritis of 17 months (range 3–17 months), using a coronal-oblique fat-saturated -echo fast fluid-attenuated inversion-recovery (sTE fFLAIR) sequence. The mean cross-sectional area of the intraorbital portion of the optic nerves was calculated by a blinded observer from five consecutive 3mm slices from the orbital apex forwards using a semiautomated contouring technique and compared with data from 71 controls. The mean optic nerve area

was 7711mm² in the affected eye of the patients, 7111mm² in the contralateral eye ($P = .1$) compared to the affected eye) and 7111 mm² in controls ($P = .13$ compared to the affected eyes). There was a significant negative correlation between disease duration and the size of the affected optic nerve ($r = -.11$, $P = .171$). The measurement coefficient of variation was 811%. The sTE fFLAIR sequence enables measurement of optic nerve area with sufficient reproducibility to show optic nerve atrophy following a single episode of unilateral optic neuritis. The correlation of increasing optic nerve atrophy with disease duration would be consistent with ongoing axonal loss in a persistently demyelinated lesion, or Wallerian degeneration following axonal damage during the acute inflammatory phase.

Hickman, et al 2009 investigate optic neuritis as a model for atrophy in multiple sclerosis (MS) lesion they performed serial magnetic resonance imaging (MRI) on 7 patients with a history of optic neuritis using a fat saturated short-echo fast fluid-attenuated inversion recovery (sTE fFLAIR) sequence. The first study was performed a median of 711 months after the onset of optic neuritis and the second 7 year later. Using a computer-assisted contouring technique, a blinded observer calculated the mean area of the intra-orbital optic nerves. The mean area of affected optic nerves decreased over 7 year by .11mm² from 7717 to 7.11mm² ($p = .17$). Poor visual acuity and decreased visual-evoked potential (VEP) amplitude were associated with atrophy. These findings suggest that atrophy is a feature of focal demyelinating lesions, it may evolve over several years, and may have functional significance. Optic neuritis provides a model to study the effect of inflammatory demyelination the ability to accurately measure visual function and to visualize and measure the optic nerves using magnetic resonance imaging.

Newman , etal 2009 evaluate the utility of measuring the optic nerve sheath diameter in children with shunted hydrocephalus, suspected of having raised intracranial pressure used 13 children with shunted hydrocephalus were examined, six had well controlled ICP, 71 however manifested symptoms suggestive of intracranial hypertension. A clinical history was taken from all patients and their parents or carers. The shunt valve was examined clinically, and signs of raised intracranial pressure were sought. Ultrasound examination was performed in both eyes to measure the optic nerve sheath diameters 3mm behind the globe. These measurements were compared with control data obtained from 7.137 children who attended the radiology department for unrelated renal ultrasound examination. Control data are the upper limit of normal for optic nerve sheath diameter is 81. mm (measured 3mm behind the globe) in patients over 7 year of age, and 81. mm in children less than 7 year of age. Those patients with functioning ventriculoperitoneal shunts had a mean optic nerve sheath diameter of 111 (SD .1.) mm; those with raised intracranial pressure had a mean optic nerve sheath diameter of .10 (.10) mm ($p < .1 \dots 7$). These results confirm that optic nerve sheath diameters in excess of the control data are strongly suggestive of raised intracranial pressure 138.

Chapter Three

Materials and Methods

The study has been carried out during the period from October to December 2016 ,on hundred (n=100) Sudanese males and females patients who presented to the clinical department of the Computerized Tomography (CT) in two hospital in Khartoum city of Sudan in AL-Ribat Teaching Hospital and Yastabshroon Hospital . The100-study group included 49 men and 51 women with their aged being between 20-80 years . Evaluation of CT images of the brain and orbital area of the patients with no previous trauma in this area , no chronic diseases of the optic nerve or surgeries interfering with orbital.

Data was collected through Questionnaire and patients interviewing system ,prior to imaging; where personal demographic notes ; age , sex , weight and tribal .and collected randomly according to our inclusion criteria, and statistical analysis was performed using Statistical Package for Social Sciences (SPSS).

3.1 Materials :

3.1.1 Study population

The total sample of patients were (100) there ages between 20–80 years old all were under CT orbit and brain.

Patient with optic nerve disorder or orbit disorder or diabetic patient

3.1.2 Machine

TOSHIBA Emotion 16 CT scanner in Yastabshiroon Hospital and Neou Soft 128 CT scanner in Ribat University Hospital (Omer Sawi Complex) .

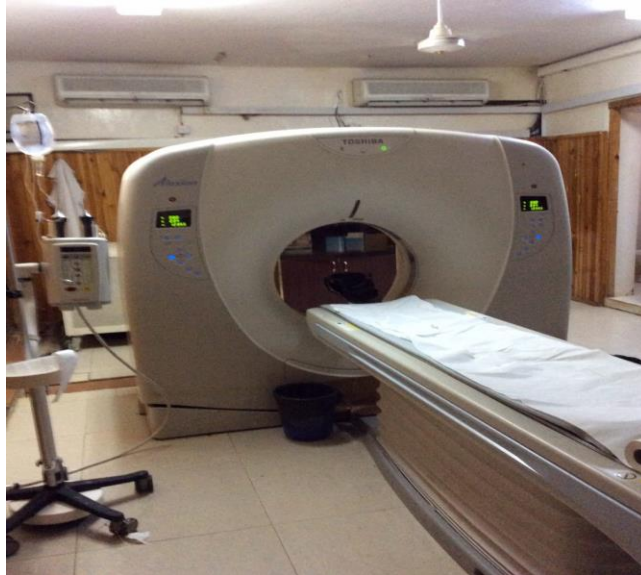

Figure (3:1) shows TOSHIBA 16 CT scanner

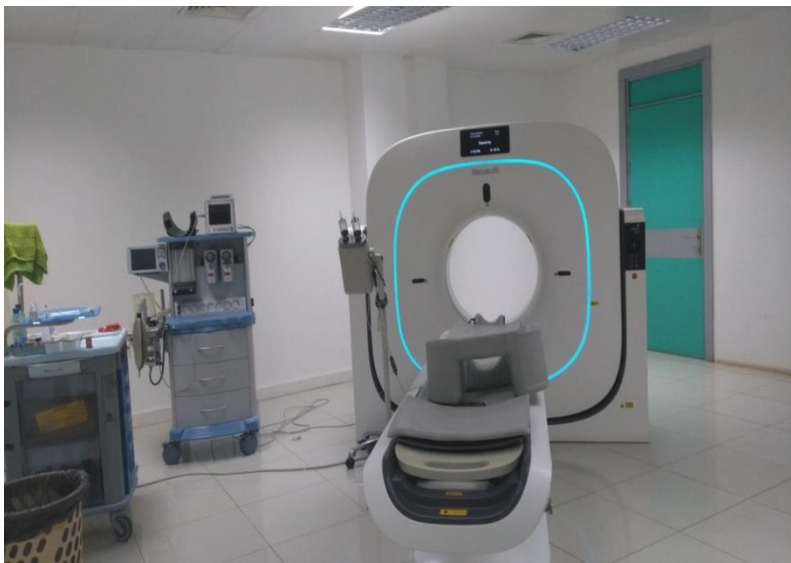

Figure (3:2) shows Neou Soft 128 CT scanner

3.2 Methods:

3.2.1 Protocol Used:

The patients lies supine on the examination couch . Both orbits are examined using head holder . The patients are positioned so that the longitudinal alignment light lies in the midline , and the horizontal alignment light passes through the orbits . Straps and foam pads are used for immobilization .

Anteroposterior and lateral scout view taken to show scanning range and slice thickness.

3.2.2 Measurement method:

optic nerve Length was measured in two steps; firstly identify the lens of eye in the axial cut to identify the site of the optic chiasm , secondly identify the optic nerve and chiasma length that the optic nerve go through it. .

The length of optic nerve was measured in axial cuts and sagittal cut. Taken from the posterior part of the eye ball to the optic chiasma in the base of skull. and the widths of the optic nerve measured from the area between the two border of optic canal in coronal cuts and axial cuts.

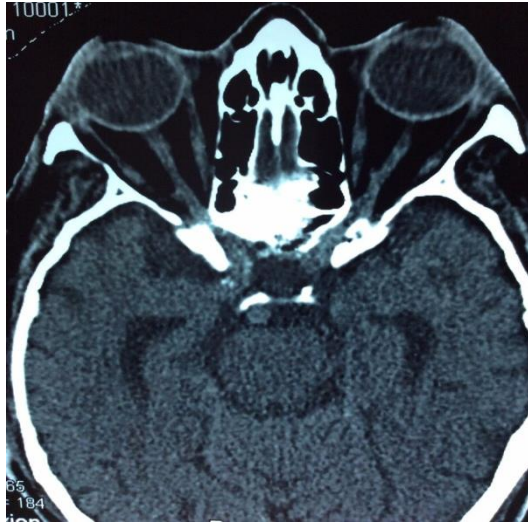


Fig 3:3 axial CT orbit without contrast , shows optic nerve in 40 year old male

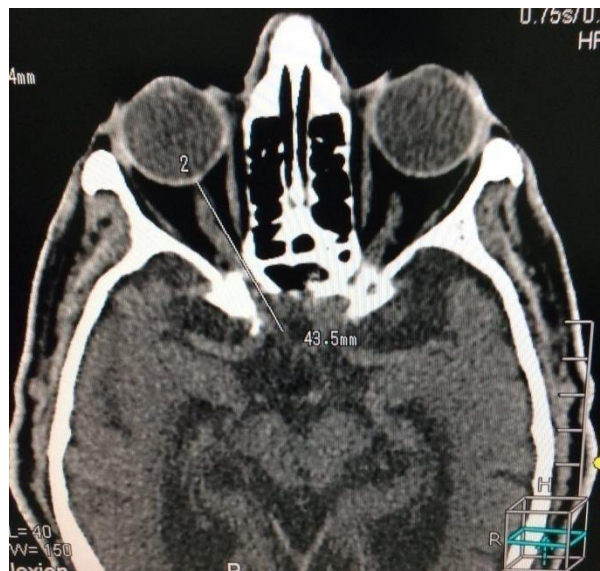


Fig 3:4 axial CT orbit without contrast in 40 year male shows measurement length of left optic nerve .

Chapter Four

Results:-

Table (4.1): gender distribution

Gender

	Frequency	Percent	Valid Percent	Cumulative Percent
Valid Female	51	51.0	51.0	51.0
Male	49	49.0	49.0	100.0
Total	100	100.0	100.0	

Table (4.2): Area distribution:

Area

	Frequency	Percent	Valid Percent	Cumulative Percent
Valid North	24	24.0	24.0	24.0
South	18	18.0	18.0	42.0
East	24	24.0	24.0	66.0
West	12	12.0	12.0	78.0
Middle	22	22.0	22.0	100.0

Gender

	Frequency	Percent	Valid Percent	Cumulative Percent
Valid Female	51	51.0	51.0	51.0
Male	49	49.0	49.0	100.0
Total	100	100.0	100.0	

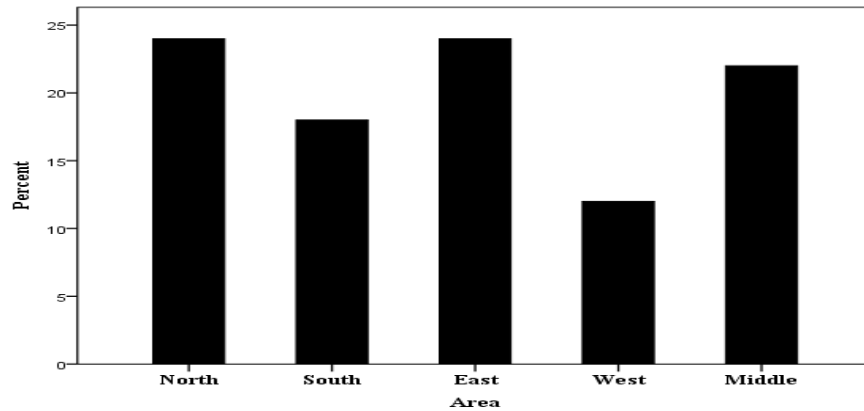


Figure (4.1):Area distribution

Table (4.3):Descriptive statistics

	N	Minimum	Maximum	Mean	Std. Deviation
Age	100	20	94	44.83	19.697
Weight	100	52	112	79.46	14.181
Length	100	4.00	6.23	5.0052	.43099
Width	100	.23	.65	.3971	.10012

Table(4.4):Group statistics

	Gender	N	Mean	Std. Deviation	Std. Error Mean
Length	Female	51	4.907	.42483	.05949
	Male	49	5.106	.41760	.05966
Width	Female	51	.3890	.11078	.01551
	Male	49	.4055	.08804	.01258

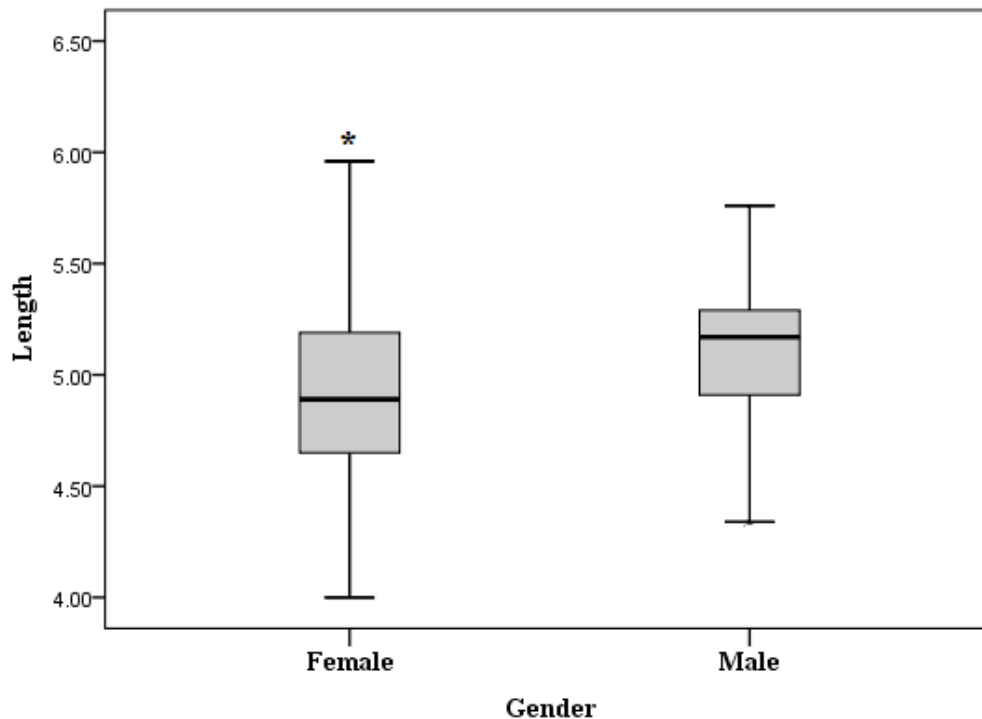


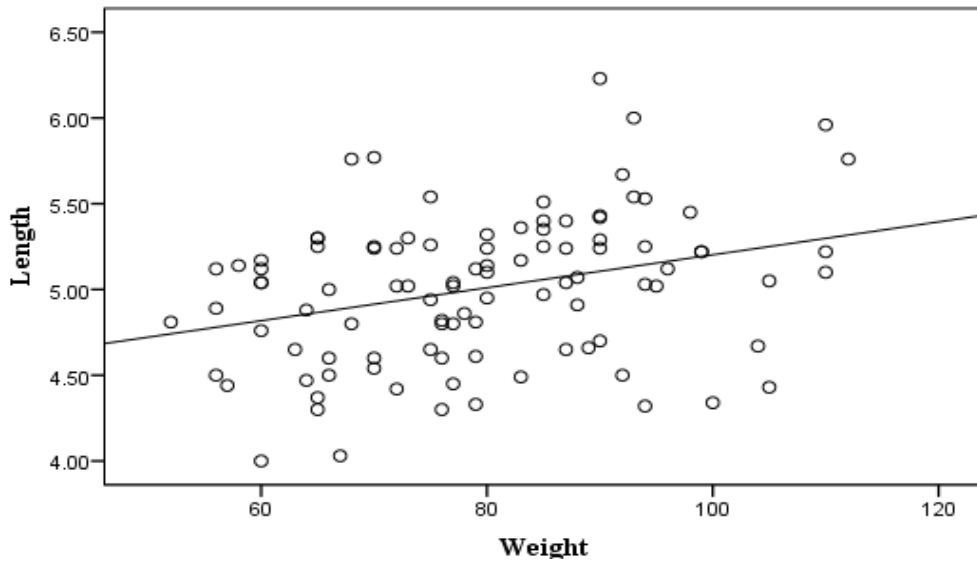
Figure (4.2): Show comparison between males & females optic nerve length diameter using independent sample T test (* strike indicates the significant difference at $p < 0.05$)

Table(4.5):Correlations statistics

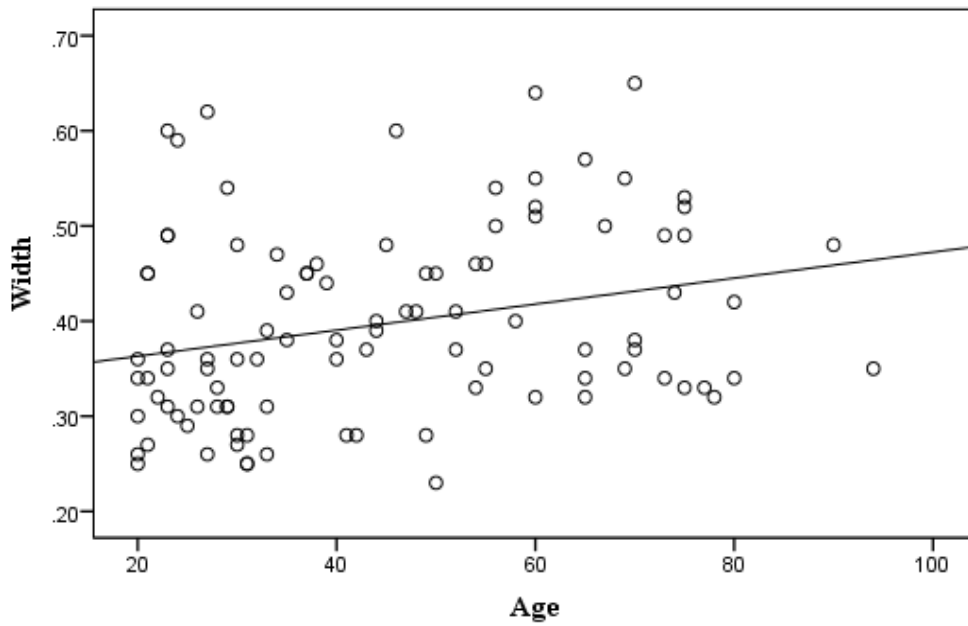
Correlations

		Weight	Age	Length	Width
Weight	Pearson	1	.649**	.316**	.257**
	Correlation				
	Sig. (2-tailed)		.000	.001	.010
	N	100	100	100	100
Age	Pearson	.649**	1	.273**	.269**
	Correlation				
	Sig. (2-tailed)	.000		.006	.007
	N	100	100	100	100
Length	Pearson	.316**	.273**	1	.491**
	Correlation				
	Sig. (2-tailed)	.001	.006		.000
	N	100	100	100	100
Width	Pearson	.257**	.269**	.491**	1
	Correlation				
	Sig. (2-tailed)	.010	.007	.000	
	N	100	100	100	100

** . Correlation is significant at the 0.01 level (2-tailed).



Figure(4.3):correlation between optic nerve length and weight



Figure(4.4):correlation between optic nerve width and age

Chapter Five

Discussion, Conclusion and Recommendations

5.1 Discussion

Number of 100 patients CT orbit and brain was performed for Sudanese patient there ages between 20–80 years old, were 49 males and 51 females.

The result after data analysis was found the overall mean of optic nerve length was $[5.0052 \pm .43099]$ cm, and mean of optic nerve width $[\.3971 \pm .10012]$ cm. with minimum length $[4.00\text{cm}]$, and maximum length $[6.23 \text{ cm}]$. with minimum width $[\.23\text{cm}]$, and maximum width $[\.65 \text{ cm}]$.

The result of this studies (minimum length $[4.00\text{cm}]$, and maximum length $[6.23 \text{ cm}]$.) similar to result obtained by MRI in (Benvento , etal 2001 studies optic nerve measurements in normal human eyes by MRI (minimum length $\{4.00\text{cm}\}$ and maximum length $\{6.00\text{cm}\}$).

From these results there is correlation between the width of optic nerve and age, as age increase the width increase.

Also there is correlation between the optic nerve length and the patient wieght as weight increase the length increase.

The mean optic nerve length for male $[5.1069 \pm .41760]$ cm, is slightly higher than mean optic nerve length for female $[4.9075 \pm .42483]$ cm .

The mean optic nerve width for male $[\.4055 \pm .08804]$ cm, is slightly higher than mean optic nerve width for female $[\.3890 \pm .11078]$ cm . There is no relation between optic nerve width & length and the tribe.

5.2 Conclusion

- using CT This study was conducted to find out the mean optic nerve length and width in Sudanese population.
- The overall mean of optic nerve length in 100 Sudanese patient was $[5.0052 \pm .43099]$ cm, and mean of optic nerve width $[\.3971 \pm .10012]$ cm.
- There is a correlation between Also there is correlation between the optic nerve length and the patient wieght as weight increase the length increase.
- The optic nerve (length & width) slightly higher in males.
- There is no relation between optic nerve width & length and the tribe.

5.3 Recommendation

- The minimum length of optic nerve must not exceed [4.00cm], and maximum length [6.23 cm].
- The minimum width of optic nerve must not exceed [.23cm], and maximum width [.65 cm].
- Is always important to know the reference value for optic nerve diameters in Sudanese population, to state the pathology and abnormality easily.
- The age ,gender and weight are important parameters that affect the optic nerve length and width.
- I recommend for next studies to correlate the optic nerve diameter with diabetic pateints.
- Also I recommend using a larger sample size, from difference state of the country. Finally I recommend for next studies to use MRI in measuring the optic nerve for Sudanese population.

References:

Amar Agrawal , Athiya Agrawal , 2008 , Manual of Neuro - ophthalmology ,Ajanta ,third ed .

Catherine Westbrook ,2008 ,hand book of MRI technique , Cambridge ,UK ,third ed .

Suzanne Henwood , 1999 ,clinical CT for technique and practice , Cambridge University 1 e

D G MacManus NMR Research Unit , Institute of Neurology , University College London , Queen Square , London , WC 2011N3BG , UK.

FJ Newcombe,¹ Jonathan P Coles,¹Maria Giulia Abate,¹Iain E Perkes,¹Peter JA Hutchinson , ³Jo G Outtrim, ¹Dot A Chatfield,¹ and David K Menon¹ Virginia 2008.

J,D, Benevento ,J.P.S. Garcia ,A.B. Baxter ,P.M.T. Garcia, R.A. Holliday and R.B. Rosen Ophthalmology , Radiology , New York Eye & Ear Infirmary , New York , N Y Ophthalmology , New York Medical College , Valhalla , NY 2011 .

N J Scolding Institute of clinical Neurology , Frenchay Hospital , Bristol BS 20111 16LE , UK .

P A Brex NMR Rsearch Unit , Institute of Neurosciences ,University College London , Queen Square , W C 20111 N3BG , UK .

P Y , UK D H Miller NMR Research Unit , Institute of Neurology , University Collage London , Queen Square , London 2011 .

S .J . Hickman SJ , Kapoor R , Jones SJ, Altmann DR , Plant GT , Miller DR .Corticosteroids do not prevent optic nerve atrophy following optic neuritis , J Neural Neurosurg Psychiatry .2009 .

S . J .Hickman SJ , P . A . Brex , C . M .H . Brierley , N . C . Silver , G .J .Barker , N . J , Scolding , D . A . S , Composton , I .F . Moseley , G . T . Plant , D .H .

Miller NMR Research Unit , Institute of Neurology , University College London , Queen Square , Kondon , W C 2009 .

Shlomo Melmed Kenneth S .Polonsky , P .Reed Larsen , Henery M . Kronenberg , 2011 , Williams Textbook of Endocrinology (12 th edition) .

Ted Montgomery , 1998 , Anatomy , Physiology and Pathology of human eye , California .

Welsey Longman , 2003 ,human anatomy and physiology , 6th ed San , Francisco .

Appendex

SUDAN UNIVERSITY OF SCIENCES & TECHNOLOGY

COLLEGE OF GRADUATE STUDIES

M S c Diagnostic Radiologic Technology

Research About:

Measurement of Normal Optic Nerve for Adult Sudanese Using
Computed Tomography

The data collection questioner

No	Age	Gender	wieght	tribe	Axial mm	sagittal	coronal
1							
2							
3							
4							
5							
6							
7							
8							
9							
10							
11							
12							
13							
14							
15							

Figure 3:5 sagittal CT orbit without contrast shows optic

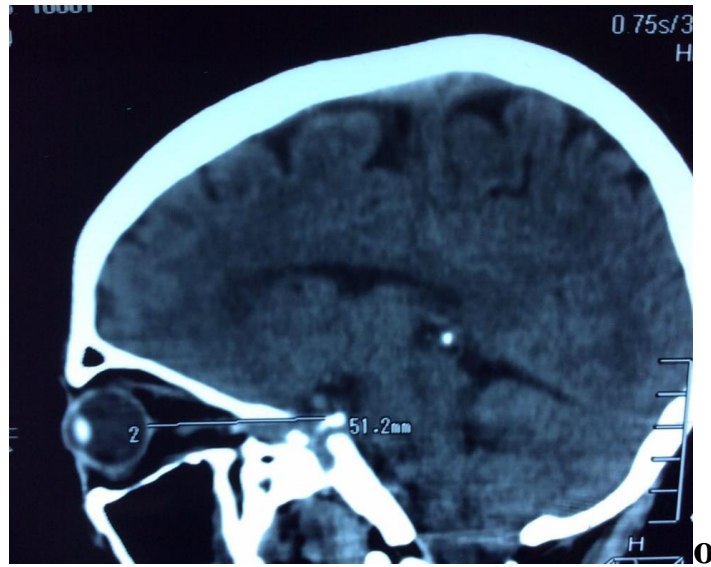


Figure 1 sagittal CT orbit without contrast shows measurement of length optic nerve of left eye

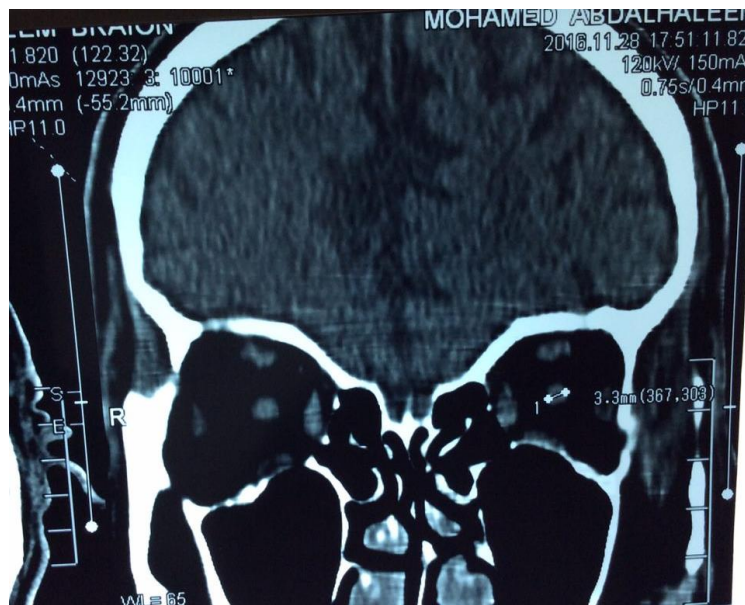


Figure 2 coronal CT orbits without contrast in 40 years male shows measurement of width optic nerve of left eye