

بسم الله الرحمن الرحيم

Sudan University of Science and Technology

Collage of Graduate Studies



Study of uterine fibroid with ultrasonography

دراسة لحمية الرحم بالموجات فوق الصوتية

*A thesis Submitted for Partial Fulfillment for the
Requirements of M.Sc Degree in Medical Diagnostic
Ultrasound*

Prepared by

FATHIA BABIKER ELRAIH ELSHIKH

Supervisor

Dr. Mona Ahmed Mohammed

2016

الآية

بِسْمِ اللَّهِ الرَّحْمَنِ الرَّحِيمِ
أعوذ بالله من الشيطان الرجيم

قال تعالى : (ولا تعملون من عمل الا كنا عليكم شهودا)

صدق الله العظيم

سوره يونس الايه (61)

Dedication

For my father- smile of my life

For my mother – the first teacher for me

For all who give me a hand in this
research

Acknowledgment

I thank .Dr. Mona Ahmed Mohammed for her close contact supervision and guidance throughout this work

Abstract

This is practical study which was done during September -2015 to July 2016 and was carried out in Sudan-Khartoum state scanned in many hospital include, (Aldayat, Alsaudi hospitals).The objective of this study is asses the role of ultrasonography in diagnosis of uterine fibroid .Study depend on practical scanning, of 50 patients of uterine fibroid from different area, their age is variable ,which data was collected on configuration of easy question and ultrasound finding from July 2015 to July 2016.All patients were subjected to be examined by U/S scanning using 'Honda' Aloka and General Electric scanners with 3,5MHz probe We found that the most common related age between(31 -40) years (20) patients 40% .Most common related clinical finding was uterine bleeding and back pain .The majority of the fibroids were intramural (25) patient 50 % with only 10 patient 20% noted as sub-mucosal. multiple type are found in (5)patient (10%). The most popular echo pattern of the various fibroid nodules was mixed echogenicity(28) patient (56%). In the testing group, the majority of the fibroids observed has peripheral blood flow 45 patient (90%) by Doppler scan . finally the researcher recommended that, The women should be educated about fibroid mass ,for early complain to health centers and early diagnoses , because Fibroids create serious complicated problems due to frequent and excessive bleeding, may lead to hysterectomy. Adequate knowledge of the sonographic patterns of fibroids among clinicians/sonographers in order to improve the quality of diagnosis. finally Further studies should be carried out in this field on many aspects such as increasing the number of patients to show the relation between the uterine fibroid and other clinical symptoms and Doppler indices finding

ملخص الدراسة

هذه الدراسة أجريت خلال سبتمبر 2015 م إلى يوليو 2016 م طبقت بجمهورية السودان ولاية الخرطوم (مستشفيات السعودي و الدايات ام درمان). أجرت الدراسة تقييم المسح بالموجات فوق الصوتية في تشخيص لحمية الرحم ،هنالك (50) مريضه تم اختيارهن عشوائيا و جميعهن لديهن لحمية رحم

كل المريضات فحصن بالموجات فوق الصوتية باستخدام ماسحات هوندا, الوكا وجنرال اليكترويك بطاقة مقدارها 3.5 ميغا هرتز.

هذه الدراسة وجدت أن معظم هولاء المرضي تتراوح اعمارهم بين (31 - 40 سنة) 20 مريض (40%) , وانهم يعانون من اعراض متباينة اكثر هانزيف الرحم 37 مريض (47%) و الام الحوض (35) مريض (70%)

كما وجدت الدراسة ان (90%) منهم يعاني من تضخم الرحم , كما وجدت الدراسة ان intramural fibroid عند هولاء المرضي 50% و subserosal 20% و multi location 5 مريض 10% و sub mucosal 10 مريض 20% وان في 90% من اللحميات اظهرت في الدوبلار peripheral blood flow وان اكثرها (56%) لديه . Mixed echo pattern

تمت التوصية بتحسين الخدمات في أقسام أمراض النساء بالمستشفيات و تحديث الأجهزة و تدريب الكوادر للمساعدة في دقة التشخيص لهذا الورم كما أوصت بزيادة عدد أخصائيين أمراض النساء في المستشفيات. كما تمت التوصية بعمل دراسات اخري في هذا المجال وزياده عددالمرضي وعلاقه اللحميه بالعقم والاجهاضات واستخدام الدوبلار

Table of contents

Topics	Page No
Quran	I
Dedication	II
Acknowledgment	iii
Abstract in English	IV
Abstract in Arabic	VI-VII
List of tables	IX
List of figure	IX
CHAPTER ONE	
Introduction	1
the problem of the study	2
Objectives	2
General objective	2
Specific objectives	2
Overview of the study	2
CHAPTER TWO	
Anatomy	3 -6
Physiology	7 -8
Pathology	9 -15
Previous Studies	20 -21
CHAPTER THREE	
Material & methods	22
CHAPTER FOUR	
Results	23
CHAPTER FIVE	
Discussion	33-34
Conclusion	35
Recommendation	36

Reference	37
Appendix	38 -46

NO	table	page
Table: (4-1)	Distribution of patients according to their ages	23
Table: (4-2)	Distribution bleeding among testing group	24
Table: (4-3)	Distribution of pelvic pain among testing group	25
Table: (4-4)	Distribution of Fertility among testing group	26
Table: (4-5)	Distribution of Uterine size among testing group	27
Table: (4-6)	Distribution of Fibroid Type among testing group	28
Table: (4-7)	Sizes of fibroid nodules	29

List of table

LIST OF FIGURE

4-1	FIGURE Distribution of patients according to their ages	23
4-2	FIGURE Distribution bleeding among testing group	24
4-3	FIGURE Distribution of pelvic pain among testing group	25
4-4	FIGURE Distribution of Fertility among testing group	26
4-5	FIGURE Distribution of Uterine size among testing group	27
4-6	FIGURE Distribution of Fibroid Type among testing group	28
4-7	FIGURE Sizes of fibroid nodules	29

CHAPTER ONE

INTRODUCTION

CHAPTER ONE

1-1 Introduction

Uterine fibroids are benign (not cancer) growths that develop from the muscle tissue of the *uterus*. They also are called leiomyomas or myomas. The size, shape, and location of fibroids can vary greatly. They may be present inside the uterus, on its outer surface or within its wall, or attached to it by a stem-like structure. A woman may have only one fibroid or many of varying sizes. A fibroid may remain very small for a long time and suddenly grow rapidly, or grow slowly over a number of years. Fibroids are responsive to hormones (e.g. stimulated by oestrogens). Being rare in prepubertal females, they commonly accelerate in growth during pregnancy and involute with menopause. Fibroids, which are often multiple, are classified according to their site within the uterine wall. Intramural Submucosal: growing into the uterine cavity. They may be pedunculated and may protrude through the cervical os. Subserosal: growing outwards from the uterus (Alfred Abuhamad 2007)

Sonography remains the method of choice for diagnosis characterized size. Location and blood flow using B-mode scan and Doppler color Doppler will identify vessels (Alfred Abohamed 2007).

- **1.-4 Statements of the problem:-**

Uterine fibroids are the most common benign tumors affecting premenopausal women and are often associated with bleeding and hysterectomy

Main objective1-6

Role of ultrasound in diagnosis uterine fibroid

Specific objectives1-7

To evaluate the role of the US in diagnosis of uterine fibroid

To identify most common type of fibroid

ultrasound feature of each type To identify

to determine the incidence of fibroid

1-8 Overview of the study:

This study consist of five chapters, chapter one contains introduction, hypothesis, objectives and overview of the study. chapter two deals with literature review which includes anatomy of the female pelvic organs ,physiology , pathology, imaging technique and previous study .chapter three contains methodology of the study, chapter four contains the results ,chapter five contain discussion , conclusion and recommendations, finally there are list of references and appendices which include ultrasound images .

CHAPTER TWO

Literature Review

CHAPTER TWO

Theoretical background

2-1-1Anatomy

2-1-1-1Labia majora

are two prominent longitudinalcutaneous folds that extend downward and backward from the mons pubis to the perineum. Together with the labia minora they form the labia of the vulva.

(Snell 2014).

2-1-1-2Vaginal vestibule

- Bordered by the labia minora laterally, by the urethra and clitoris anteriorly, by the hymenal ring inferiorly.
- (Snell 2014).

2-1-1-3Vagina

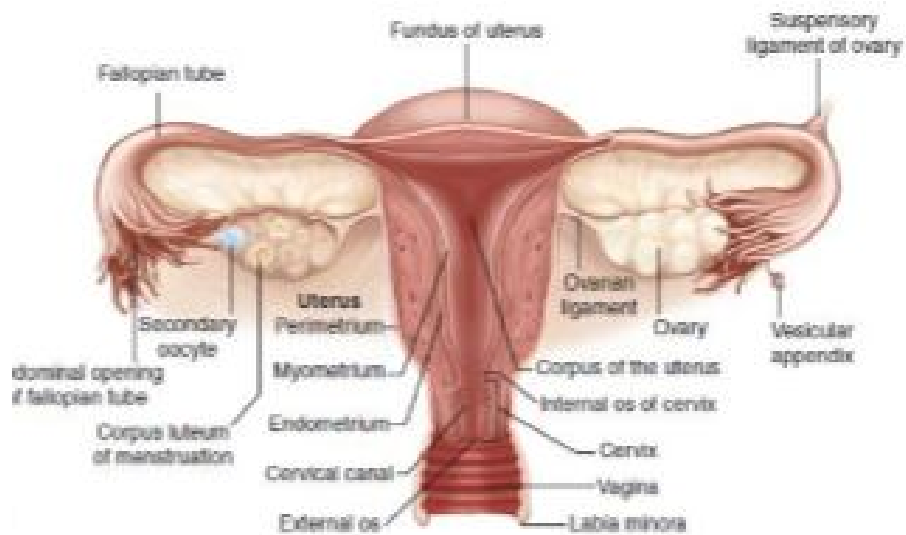
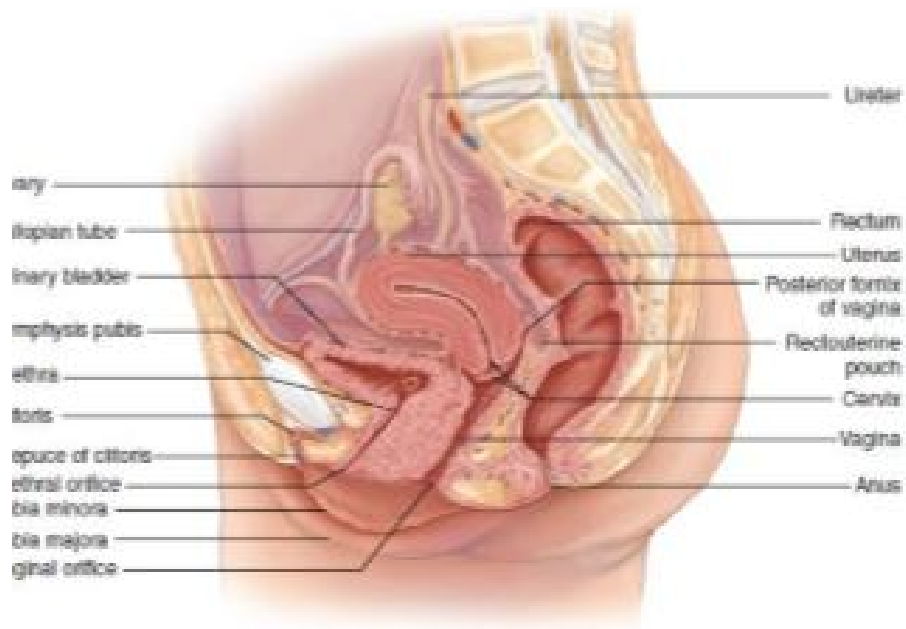
Strong canal of muscle (7.5cm)extend from the uterus to the vestibule of the external genitalia..(Snell 2014).

2-1-1-4.vaginal fornix

the circular cul-de-sac formed around the cervix

4 regions: the anterior fornix, the posterior fornix and 2 lateral fornices.

- (Snell 2014).



Reproductive System
(Snell 2014)

2-1-1-5 Uterus

Pear-shaped, thick-walled, muscular organ

Layers of uterine wall

The serous layer (perimetrium)

The muscular layer

The mucous layer (endometrium)

(Snell 2014).

2-1-1-6 Cervix

- lower 1/3 of uterus. connects uterus to vagina via endocervical canal
- External os: opening of endocervical canal to ectocervix
- Internal os: indistinct upper limit of endocervical canal
- (Snell 2014).

2-1-1-7 Ligaments

- Broad ligament
- Round ligament
- Cardinal ligament
- Utero-sacral ligament
- (Snell 2014).

2-1-1-8 Oviduct

Four portion

Interstitial portion:

Isthmic portion: narrow

Ampulla: wide and tortuous

Fimbria: funnel-shaped mouth

(Snell 2014).

2-1-1-9Ovary

Paired organ, ellipticThe suspensory ligament of the ovary

The ovarian ligament

(Snell 2014).

Structure of ovary

- Covered by cuboid or low columnar epithelium
- Consist of a cortex and a medulla
- Cortex: oocytes in various stages of maturity.
- Medulla: fibers, smooth muscle cells, blood vessel, nerves.
- (Snell 2014).

2-1-1-10Blood vessel

The ovarian artery

- Originated as branches of the abdominal aorta, (vein left: left renal vein).
- Turn over the common iliac artery and ureter,descend into the pelvis. Enter into ovary through the mesovarium
- (Snell 2014).

The uterine artery

- a terminal branch of the hypogastric artery
- Cross the ureter near the cervix (2cm)
- Ascend along the lateral border of the uterus
- uterine body branch and cervix-vagina branch
- (Snell 2014).

2-1-1-11Lymph

- External genitalia
- superficial inguinal gland
- deep inguinal gland

Pelvic lymph

1.iliac lymph

internal iliac and external iliac, common iliac

2.Anterior Sacral lymph

3.Lumbar lymph: abdominal aorta

(Snell 2014).

2-1-1-12Adjacent organs

- Urethra
- Urinary bladder (uterovesical pouch)
- Ureter (Water under the bridge)
- Rectum (rectouterine pouch or pouch of Douglas)
- Vermiform appendix
- (Snell 2014).

2-1-2 Physiology

2-1-2-1 The uterus contains an inner lining called the endometrium (which builds up and sheds monthly in response to hormonal stimulation). The lower portion of the uterus is called the cervix, which contains a small opening called the os. Menstrual blood flows through the os into the vagina during menstruation. Semen travels through the os into the uterus and the fallopian tubes following ejaculation during sexual intercourse. The cervical os dilates (opens) during childbirth. The ovaries, two small almond-shaped structures located on each side of the uterus, are the female gonads (reproductive glands). Female babies are born with over 400,000 ova (the gametes, also referred to as egg cells or oocytes), which are stored in the ovaries. The female body does not produce any additional ova. The ovaries produce estrogen and progesterone. The ovaries are close to, but not actually connected to the fallopian tubes, thin tube-like structures that are the site of fertilization, the fusion of the male and female gametes.

(essential anatomy & physiology 4 edition)

2-1-2-2 The Menstrual/Hormonal Cycle

The hormonal cycle facilitates maturation and rupture of the ovarian follicle resulting in the release of an ovum (the female reproductive or germ cell). Each month a series of changes take place which prepares the uterus for pregnancy. This cycle (menstrual cycle) is described below:

The first day of menstruation (referred to as Day 1) occurs when levels of estrogen and progesterone are low. In response to these low levels, the hypothalamus secretes gonadotrophin releasing hormone (GnRH) which triggers the anterior pituitary gland to release two hormones: follicle stimulating hormone (FSH), and luteinizing hormone (LH). (essential anatomy & physiology 4 edition)

FSH stimulates the development of many follicles within the ovary. One dominant follicle takes over. As it continues to grow, it produces increasing amounts of estrogen, which stimulates the release of LH, and inhibits FSH, which suppresses further follicular development. (essential anatomy & physiology 4 edition)

When LH levels are highest (LH surge), the ovarian follicle "ruptures" and releases one ovum, which is "swept" into the fallopian tube by hair-like projections called cilia that line the fimbriae (the fringe-like end of the fallopian tube that is closest to the ovary). This process is called ovulation. Increasing estrogen levels causes the cervical mucous (vaginal secretions) to become clear and profuse and the os to dilate. These two actions may facilitate the transport of semen (containing sperm) from the vagina, through the uterus, and into the fallopian tube. Following ovulation, the ruptured follicle is transformed into the corpus luteum, a glandular mass that continues to produce estrogen and high levels of progesterone. The progesterone causes the endometrium to thicken, preparing it for implantation of a fertilized egg. If fertilization takes place during ovulation, hormonal levels remain high, essential for the maintenance of the pregnancy.) If fertilization does not occur, the corpus luteum shrinks and levels of both estrogen and progesterone decrease. The withdrawal of estrogen and progesterone cause the blood vessels of the endometrial (uterine) lining to "break" resulting in vaginal bleeding (menstruation). The average menstrual cycle is 28-35 days, and menstrual flow usually continues for three to seven days, although there are variations among women. Following menstruation, estrogen and progesterone levels are low, triggering the hypothalamus to once again

release GnRH, starting the entire cycle again. If fertilization does take place, menstruation will not reoccur for the duration of the pregnancy .
(essential anatomy & physiology 4 edition)

2-1-3 Pathology:-

2-1-3 -1 Congenital Uterine Anomaly

are malformations of the uterus that develop during embryonic life. Occur in less than 5% of all women, but have been noted in up to 25% of women who have had miscarriages and/or deliveries of premature babies. When a woman is in her mother's womb, her uterus develops as two separate halves that fuse together before the woman is born.

- **Unicornuate:** only one half of the uterus has developed
- **Didelphys:** the two halves of the uterus remain separate
- **Bicornuate:** an abnormal, indented external uterine surface and two endometrial cavities
- **Septate:** a normal external uterine surface but two endometrial cavities
- **Arcuate:** a normal external uterine surface with a 1 cm or less indentation into the endometrial cavity

(Alfred Abohamed 2007).

2-1-3 -2 Endometrial polyps

Are benign nodular protrusions of the endometrial surface, and one of the entities included in a differential of endometrial thickening. endometrial polyps can either be sessile or pedunculated. they can often be suggested on ultrasound or MRI studies, but may require sonohysterography or direct visualisation for confirmation.

((Alfred Abohamed 2007)).

2-1-3 -3 Endometrial carcinoma

Is generally considered the most common gynaecological malignancy .it frequently presents with uterine bleeding and both ultrasound and pelvic MRI are useful modalities for evaluation. Endometrial carcinoma is divided to two subtypes:

- Type I (80%): arising in setting of unopposed hyperestrogenism and endometrial hyperplasia
- Type II (20%): arising in the setting of endometrial atrophy, in a female between 65 to 75 years old, and endometrial intraepithelial carcinoma. (Alfred Abohamed 2007).

2-1-3 -4 Endometrial hyperplasia (EH)

Refers to an increased proliferation of the endometrial glands relative to the stroma. One of the main concerns is the potential malignant transformation of the endometrial hyperplasia to the endometrial carcinoma .((Alfred Abohamed 2007)).

2-1-3 -5 Endometritis

Endometritis is inflammation of the endometrial lining of the uterus. In addition to the endometrium, inflammation may involve the

myometrium and, occasionally, the parametrium. Endometritis can be divided into pregnancy-related endometritis and endometritis unrelated to pregnancy. When the condition is unrelated to pregnancy, it is

referred to as pelvic inflammatory disease (PID). Endometritis is often associated with inflammation of the fallopian tubes (salpingitis), ovaries (oophoritis), and pelvic peritoneum (pelvic peritonitis). (Alfred Abohamed 2007)

2-1-3 -6 Endometrioma / Endometriosis

An ovarian endometrioma is a cystic mass arising from ectopic endometrial tissue within the ovary. It contains thick, brown, tar-like fluid, which may be referred to as a "chocolate cyst." Endometriomas are often densely adherent to surrounding structures, such as the peritoneum, fallopian tubes, and bowel. (Alfred Abohamed 2007).

2-1-3 -7 Fibroids

A uterine fibroid (known medically as a *leiomyoma* or *myoma*) is a noncancerous (benign) growth of smooth muscle and connective tissue. Fibroids can range in size from as small as a pinhead to larger than a melon. Fibroids have been reported weighing more than 20 pounds.

Fibroids originate from the thick wall of the uterus and are categorized by where they grow:

- *Intramural fibroids* grow within the middle and thickest layer of the uterus (called the *myometrium*).
- *Subserosal fibroids* grow out from the thin outer fibrous layer of the uterus (called the *serosa*). Subserosal can be either stalk-like (*pedunculated*) or broad-based (*sessile*).

- *Submucosal fibroids* grow from the uterine wall toward and into the inner lining of the uterus (the *endometrium*). Submucosal fibroids can also be stalk-like or broad-based.(Alfred Abohamed 2007).

2-1-3 -8 NabothianCyst

- Multiple cysts within the cervix ((Alfred Abohamed2007)).

2-1-3 -9 Cervical Cancer

- typically Squamuse cell carcinoma SCC
- cervical stenosis with endometrial fluid collection
- parametrial invasion
- irregular, poorly defined margins of lateral cervix

(Alfred Abohamed 2007).

2-1-3-10Adenomyosis

Form of endometriosis where there is aberrant endometrial tissue in the myometrium ,Diffuse or focal , US - Sonographic appearance overlaps w/ fibroids, but presence of small cysts or hypoechoic areas or variation during menstrual cycle is suggestive of adenomyosis, Irregular, myometrial, cystic spaces predominantly involving the posterior uterine wall, an enlarged uterus with a widened posterior wall (see Image 1), an eccentric endometrial cavity, and decreased uterine echogenicity without lobulations, contour abnormality, or mass effects (which is more commonly seen with leiomyomas). Sonograms may also show an

ill-defined margin between the normal myometrium and the abnormal myometrium, as well as an elliptically shaped myometrial abnormality. (Alfred Abohamed 2007).

2-1-3 -11 Benign Ovarian Neoplasm's

- mucinous or serous cystadenomas, Brenner tumors
- granulosa cell tumors, fibromas, thecomas (secrete estrogens → endometrial hyperplasia)
- Sertoli-Leydig cell tumors (secrete androgens → virilization)
- cannot differentiate from malignant neoplasms
- complex lesions with septations and solid tumor nodules (Alfred Abohamed 2007).

2-1-3 -12 Ovarian Teratomas

most common benign ovarian neoplasm , classic mimicker , rarely malignant , at risk for torsion , complex, partially cystic, w/ echogenic areas that may shadow , dermoid plug = Rokitansky nodule , presence of strumaovarii can (rarely) cause thyrotoxicosis.

(Alfred Abohamed 2007).

2-1-3 -13 Cystic Adnexal Mass

- Hydrosalpinx.
- cystic teratoma.
- corpus luteum cyst.

- benign or malignant ovarian tumor.

(Alfred Abohamed 2007).

2-1-3 -14 Polycystic Ovaries

This include enlarged ovaries , echogenic stroma , cysts in periphery (>5 cysts over 5mm in size).

(callen 2016).

2-1-3 -15 Stein – Leventhal

PCO, obesity, infertility / amenorrhea, and hirsutism .

(callen 2016).

2-1-3 -16 Hemorrhagic Cysts

usually result from haemorrhage into a corpus luteum or other functional cyst. Radiographic features are variable depending on the age of the haemorrhage. They typically resolve within eight weeks.,differential diagnoses include endometrioma, hemorrhagic corpus luteum cyst, dermoid, follicular cyst .

(Alfred Abohamed 2007).

2-1-3 -17 Hydrosalpinx

is a descriptive term and refers to a fluid filled dilatation of the fallopian tube. Caused by PID, endometriosis, prior instrumentation, leading to adhesions that obstruct the peritoneal opening of the tube , infected = pyosalpinx .

(Alfred Abohamed 2007).

2-1-3 -18 Tubo-Ovarian Abscess

refers to a collection of pus in the tube Severe form of PID, usually bilateral , complex, multiloculated adnexal mass w/ echoes from debris/pus , may have thick septations. (Alfred Abohamed 2007).

2-1-3 -19 Endometrial Fluid

Fluid in the endometrial cavity can result from a number of causes if excessive and associated with distension.

There are essentially three types of fluid:

- hydrometra: simple fluid
- haematometra: haemorrhagic content / clot
- pyometra: pus

caused by cervical stenosis , cervical carcinoma , hydrometrocolpos and endometritis . (Alfred Abohamed 2007).

2-1-3 -20 Pelvic Free Fluid

free fluid to accumulate The cul-de-sac, also known as **pouch of Douglas** or **rectouterine pouch**, Separate into Gynecologic and non-Gynecologic etiologies. (Alfred Abohamed 2007).

2-1-4 physics

In physics the term “ultrasound” applies to all acoustic energy with a frequency above human hearing (20,000 hertz or 20 kilohertz). Typical diagnostic sonographic scanners operate in the frequency range of 2 to 18 megahertz (Ultrasound Teaching Manual 2nd edition)

2-1-4 -1 From sound to image

In ultrasound, the following events happen:

- The ultrasound machine transmits high-frequency (1 to 5 megahertz) sound pulses into your body using a probe.
- The sound waves travel into your body and hit a boundary between tissues (e.g. between fluid and soft tissue, soft tissue and bone).
- Some of the sound waves get reflected back to the probe, while some travel on further until they reach another boundary and get reflected.
- The reflected waves are picked up by the probe and relayed to the machine.
- The machine calculates the distance from the probe to the tissue or organ (boundaries) using the speed of sound in tissue (5,005 ft/s or 1,540 m/s) and the time of the each echo's return (usually on the order of millionths of a second).

- The machine displays the distances and intensities of the echoes on the screen, forming a two dimensional image .

(Ultrasound Teaching Manual 2nd edition)

2-1-4 -2 Diagnostic applications

Some diagnostic application ,abdominal, cardiac, maternity, gynecological, urological and cerebrovascular examination, breast examination, and small pieces of tissue as well as in pediatric and operational review.

(Ultrasound Teaching Manual 2nd edition)

modes of ultrasound 2-1-4-3

Four different modes of ultrasound are used in medical imaging These are:

- A-mode: A-mode is the simplest type of ultrasound. A single transducer scans a line through the body with the echoes plotted on screen as a function of depth. Therapeutic ultrasound aimed at a specific tumor or calculus is also A-mode, to allow for pinpoint accurate focus of the destructive wave energy.
- B-mode: In B-mode ultrasound, a linear array of transducers simultaneously scans a plane through the body that can be viewed as a two-dimensional image on screen.
- M-mode: M stands for motion. In m-mode a rapid sequence of B-mode scans whose images follow each other in sequence on screen enables doctors to see and measure range of motion, as the

organ boundaries that produce reflections move relative to the probe.

- Doppler mode: This mode makes use of the Doppler effect in measuring and visualizing blood flow. Doppler sonography play important role in medicine

(Ultrasound Teaching Manual 2nd edition)

2-1-5 imaging technique

Pelvic ultrasound can be done three ways: transabdominal, transrectal, and transvaginal.

(Ultrasound Teaching Manual 2nd edition)

2-1-5-1 Transabdominal ultrasound

A small handheld device called a transducer is passed back and forth over the lower belly. A transabdominal ultrasound is commonly done in women to look for large uterine fibroids or other problems.

(Ultrasound Teaching Manual 2nd edition)

2-1-5-2 Transrectal ultrasound.

The transducer is shaped to fit into the rectum. A transrectal ultrasound may be done to check for problems in men or women. It is the most common test to look at the male pelvic organs, such as the prostate and seminal vesicles. Sometimes, a small sample of tissue (biopsy) may be taken with small tools inserted through the rectum during a transrectal ultrasound.

(Ultrasound Teaching Manual 2nd edition)

2-1-5-3 Transvaginal ultrasound.

The transducer is shaped to fit into a woman's vagina . A woman may have both transabdominal and transvaginal ultrasounds to look at the whole pelvic area. A transvaginal ultrasound is done to look for problems with fertility or pregnancy. In rare cases, a hysterosonogram is done to look at the inside of the uterus by filling the uterus with fluid during a transvaginal ultrasound. Sometimes, a small sample of tissue (biopsy) may be taken with small tools inserted through the vagina during a transvaginal ultrasound.

(Ultrasound Teaching Manual 2nd edition)

2-1-2 Previous studies

The study included 103 cases of uterine bleeding done by Transvaginal ultrasound ,conclude AUB, most of the patients were between 40 and 45 years of age (67.97%) , menorrhagia was the dominant clinical presentation and Uterine fibroid was the leading cause of AUB.(Talukdar APRIL 2016)

Study involved (244) women patient with uterine fibroid were evaluated ,by transabdominal ultrasound conclude that The most common sonographic patterns of uterine mixed echo patterns. Benjamin 2016)(

Study involved (1364) Premenopausal women were screened by ultrasonography,**Conclusion:** The results of this study suggest that most of patient develop uterine fibroid tumors before menopause ,and most common related ages between(30 – 45) yearSchectman,2011)(

Study involved 41 proven case , Most uterine fibroid had two or more sonographic abnormalities, most frequently uterine contour irregularity (76 per cent), mixed echo texture (68 per cent) and uterine enlargement (66 per cent) . (Jaffe 2013)

Study which was conducted in 50 patients with uterine bleeding, done by transabdominal ultrasound, conclude that the majority of patients were admitted due to menorrhagia, and most of them were peri-menopausal women. Fibroid uterus is the most common cause in the study population, (**KUMAR 2015**)

Study involved 225 patient swith benign fibroid done by Doppler ultrasound conclude Sensitivity, specificity, and positive predictive value of increased peripheral vascularity in the diagnosis of fibroid were 100%, 86%, and 19%, respectively .(Arduini 2015)

CHAPTER THREE

Material and Method

CHAPTER THREE

Material and methods

3-1 material

3-1-1 Patients and sampling:

The sonographic scanning of the 50 patient in the study with uterine fibroid came to ultrasound department to checkup.

3-1-2 Area of the study:

This study was started in July 2015 and continued up September 2016. The study was carried out in Khartoum state. the hospital which I had done this research include Aldayat hospital and Alsudi hospital.

3-1-3 Equipment used:

An ultrasound machines of U/S scanning using 'Honda' Aloka and General Electric scanners with 3,5MHz probe

3-2 methods

3-2-1 Technique used:

3-2-1-1 Trans abdominal U/S scanning:

3-2-1-2Patient Preparations:

The bladder must be full enough, gives patient 4 to 5 glasses of fluid and examined after one hour. do not allow the patient to micturate, alternatively fill the bladder through a urethral catheter with sterile normal saline, stop when patient feels uncomfortable, avoid catheterization if possible because of the risk of infection. avoid over distention of the urinary bladder was critical because it is worse as an

empty urinary bladder; if the patient cannot retain urine give his lasex (20 mg/ I V or tabs). this procedure is restricted to patient without any cardiac problem .

3-2-1-3Position of the patient:

The patient should lie supine, the patient should be relaxed, lying comfortably and breathing quietly, lubricates the lower abdomen with coupling agent. hair anywhere on the abdomen will trap air bubbles so apply coupling agent generously.

3-2-1-4Scanning technique:

Start with a transverse scans from the symphysis pubis up wards to the umbilicus and we must be angle the probe sharply down word until the uterus appears in the center of the screen and endometrial line appear , adjusted the gain of the image and freeze it, here I measured the width of the uterus. then sagital scane from the symphysis pubis up wards to the umbilicus and we must be angle the probe sharply down word until the uterus appears in the center of the screen and endometrial line appear , adjusted the gain of the image and freeze it, here I measured the length , AP diameter and endometrial thickness .then I scan from one side to another to evaluate the uterine shape, if it is normal or abnormal, also evaluate the uterine texture, and texture and size of mass if present .

3-2-2 Data analysis: The data analyzed using (Statistical Package for the Social Sciences)program.

CHAPTER FOUR

Result

Chapter Four

Result

Table (4-1) - Distribution of patients according to their ages

Age/years	No.	Percentage
20-30	15	30%
31-40	20	40%
Above 40	15	30%
Total	50	100%

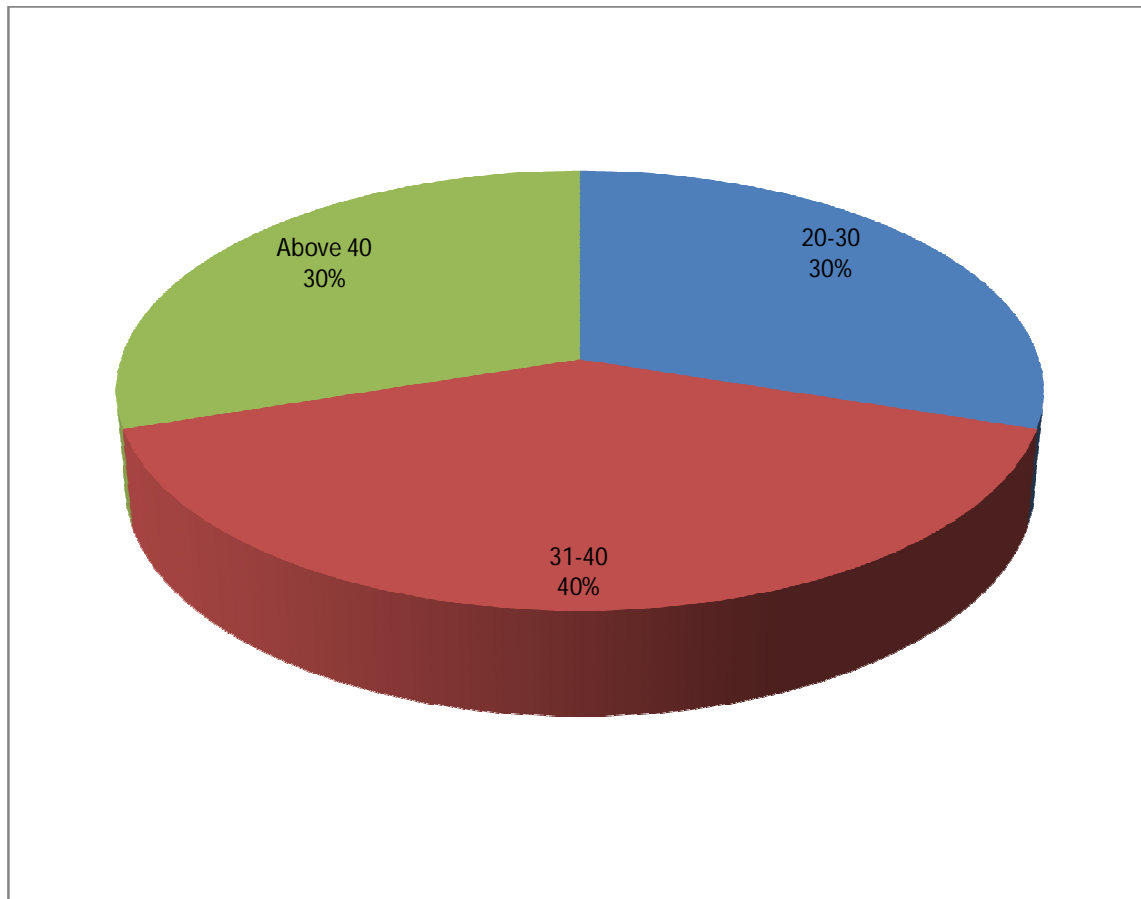


Figure (4-1): Distribution of patients according to their ages

Table (4-2) : Distribution bleeding among testing group

Groups	No.	Percentage
Bleeding	37	74%
None	13	26%
Total	50	100%

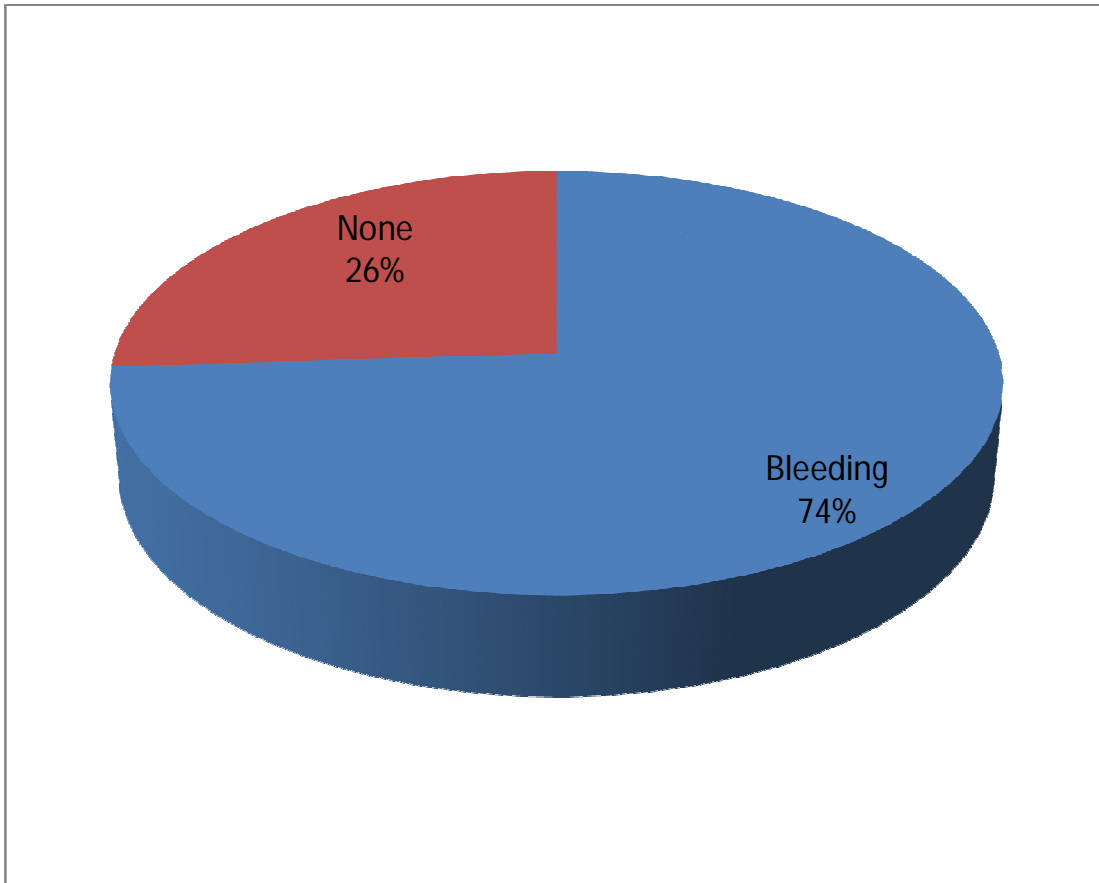


Figure (4-2): Distribution of bleeding among testing group

Table (4-3): Distribution of pelvic pain among testing group

Groups	No.	Percentage
pelvic pain	35	70%
None	15	30%
Total	50	100%

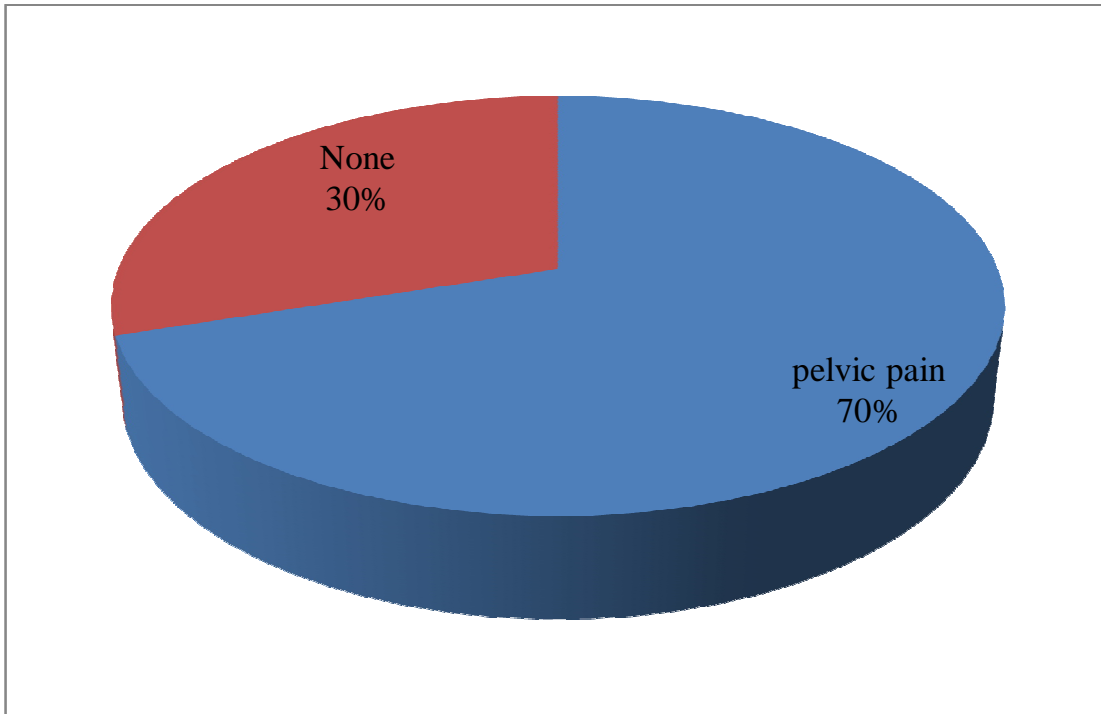


Figure (4-3): Distribution of pelvic pain among testing group

Table (4-4): Distribution of menopause among testing group

Groups	NO.	Percentage
Perimenopausal	45	90%
Postmenopause	5	10%
Total	50	100%

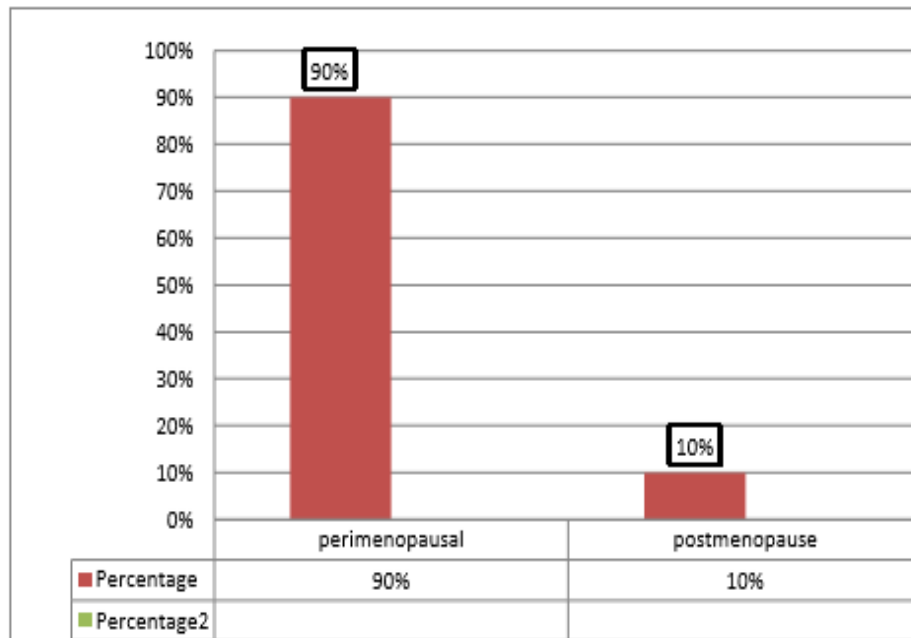


Figure (4-4): Distribution of Fertility among testing group

Ultrasound Findings

Table (4-5) : Distribution of Uterine size among testing group

Groups	No.	Percentage
Small	0	0%
Normal	4	8%
Enlarge	46	92%
Total	50	100%

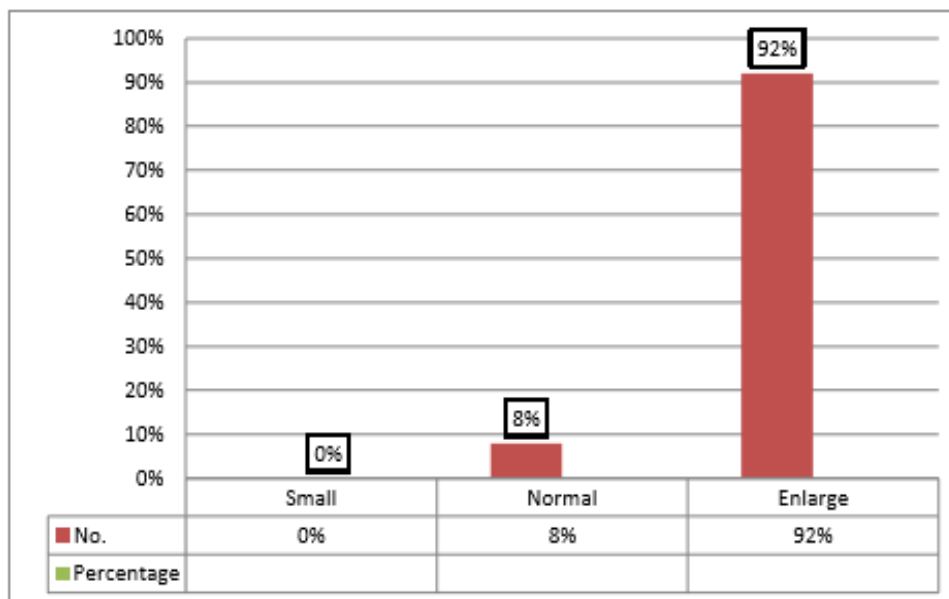


Figure (4-5) : Distribution of Uterine size among testing group

Table (4-6) : Distribution of Fibroid Type among testing group

Groups	No.	Percentage
Intra	25	50%
Subserosal	10	20%
Multi	5	10%
Sub mucosal	10	20%
Total	50	100%

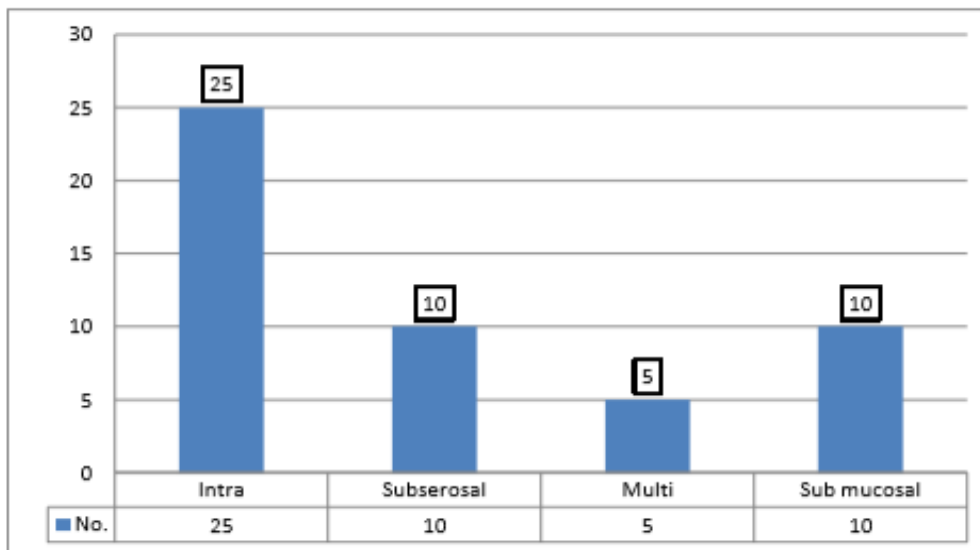


Figure (4-6) : Distribution of Fibroid Type among testing group

Table 4-7: Sizes of fibroid nodules

Diameter of the largest fibroid nodule	Frequency	Percentage
<3 cm	17	34
3–4.9 cm	15	30
5 cm and above	18	36
Total	50	100.0

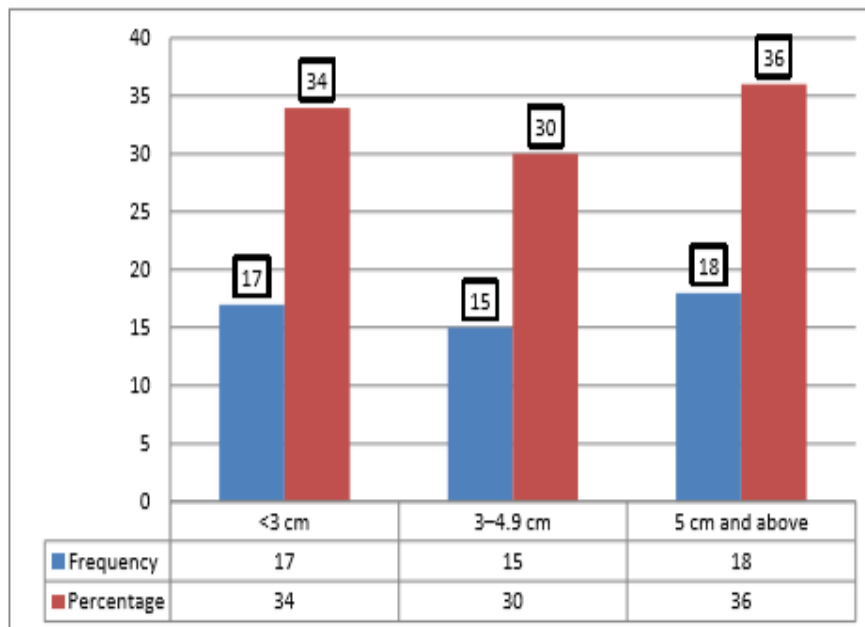


Figure 4-7: Sizes of fibroid nodules

CHAPTER FIVE

Discussion & Conclusion& Recommendation

CHAPTER FIVE

Discussion, conclusion and recommendation

Discussion

This study had been conducted in Khartoum state hospitals, to evaluate the role of ultrasonography in diagnosis of uterine fibroid using trans abdominal ultrasonography, there were 50 cases in this study, all cases were suffering from fibroid and their ages is vary .

The largest group with uterine fibroid came for scanning age between (31– 40) years was 20 patient which was 40%,(20- 30) years was 15 patient which was 30% and above 40 years 15 patient which was 30% Similar results were achieved by (Schectman,2011)**Table (4-1)**

The patients with varying symptoms like vaginal bleeding (37)patient 74% and (35) patient 70% with pelvic pain .this indicate the majority of patients were with vaginal bleeding and pelvic pain Similar results were achieved by(KUMAR 2015)**Table(4-2) and Table(4- 3)**

Pre menopause there were (45) patients 90% out of 50 , while (5) patients (10%) out of 50 cases were postmenopausal women . this indicate the majority of patients wereperi-menopausal Similar results were achieved by(Schectman,2011)**Table(4-4)**

The distribution of uterine size in the diagnosed patients, and it indicates that 4 cases (8%) out of 50 cases have normal size, while 46

cases (92%) out of 50 cases of them their uterine size is enlarged . this indicate the majority of patients with uterine fibroid has abnormal uterine shape and contour Similar results were achieved by(**Jaffe 2013**)**Table (4-5)**

In terms of the location of fibroids in the uterus, The majority of the fibroids observed among testing group were intramural 25 patient (50 %), subserosal 10 patients (20%) , sub mucosal 10 patients (20%) and multi 5 patients (10%) Similar results were achieved by(**KUMAR 2015**)**Table (4-6)**

Fibroid are vary in size <3 cm were 17 patient (34%),(3-4.9) cm were 15 patient (30%) and 5 cm and above were 18 patient (36%) **table (47)**

Echo pattern of fibroids and age of participants show Mixed echo pattern is the commonest sonographic patterns 28 patient (56%) , Similar results were achieved by(**Benjamin 2016**)**Table(4-8)**

That intramural fibroids were predominant (50 %) 25 patient among the sampled population and most common related age between (31-40) , Similar results were achieved **by(Benjamin 2016)Table(4-9)**

Doppler finding among testing group, the majority of the fibroids observed among testing group has peripheral blood flow 45 patient (90%)in the study population, this indicate the majority of patients with uterine fibroid. Similar results were achieved by (Arduini 2015)**Table(4-10)**

CONCLUSION

- Most common age group was (35 – 44)years
- Most common clinical finding was pelvic pain and uterine bleeding.
- The most popular echo pattern of the various fibroid nodules was mixed echogenicity,
- Majority of the fibroids observed among study population were intramural 25 patient.
- The majority of the fibroids observed has peripheral blood flow in Doppler scan.

Recommendation

- The pre menopausal women should be learned about fibroid mass ,for early complain to health centers and early diagnoses , because Fibroids create serious complicated problems due to frequent and excessive bleeding may lead to hysterectomy.
- Adequate training of the sonologist to improve the quality of diagnosis.
- Finally Further studies should be carried out in this field on many aspects such as increasing the number of patients to show the relation between the uterine fibroid and other clinical symptoms and Doppler indices finding .

REFERENCES

Alfred Abohamed,MD 2007. Ultrasound in obstetrics and gynecology .
page no 423, 424,435,436,482,488,489,492,493,498,499.

Archer R,MD 2012 . Us national library of medicine .

Berna Seckine.2015 . Journal of clinical ultrasound.

Burbos N , et al 2010. US national library of medicine .

Chummys Sinnatamby FRCS, lasst anatomy .

Fernández -Parra et al 2010. sogc clinical practice guideline , October .

Gambacciani et al 2010 . sogc clinical practice guideline .

Gregoriou et al 2010. sogc clinical practice guideline .

Jane Bates, FRCS 2010. Practical gynecological ultrasound. Page no
312,313,323,324,335,336,342,343,356,357,367,368.

Martinez-Rubio and Alcazar 2010 . sogc clinical practice guideline .

Mossa et al 2010 . sogc clinical practice guideline .

Peter W.callen MD 2016, callens ultrasonography in obstetric and gynecology . Page no 518,519,532,533,587,588,590,591.

Richard S.snell. 2014 . clinical anatomy 2014. Page No

423, 424, 425, 456, 457, 458, 460, 461, 465, 466, 471, 472

Warwish carter 2012 . Us national library of medicine .

Appendix 1

Data sheet

Title -----

General information

Patient adage -----

Maternal state *married* ----- *single* -----
Fertile ----- *infertile*-----

Clinical information

Pelvic pain

Suprabupic pain --- *RLQ pain* --- *LLQ pain* ----

Vaginal bleeding *yes* ----- *no* -----

Vaginal discharge *yes* ----- *no* -----

Frequency *yes* ----- *no*-

Dysurea *yes*----- *no*---

Haemtourea *yes* ----- *no*---

Vomiting *yes*----- *no*---

Pelvic swelling *yes* ----- *no* ---

Menstrual period *regular* ----- *irregular*-----

Ultrasound finding

Uterine size *normal* ----- *enlarged* ---- *small*-----

Uterine mass *no* ----- *yes* -----

Size -----

Texture and location -----

Doppler finding

peripheral ----- *central* ----- *mixed* -----

Ovaries

Normal -----

Abnormal -----

Pouch of Douglas *free* ----- *collection* -----

Lt &RT adenixal mass *no* ----- *yes* ----

Size ----- *Texture* -----

Other ultrasound finding-----

Appendix 2

Image of the researcher

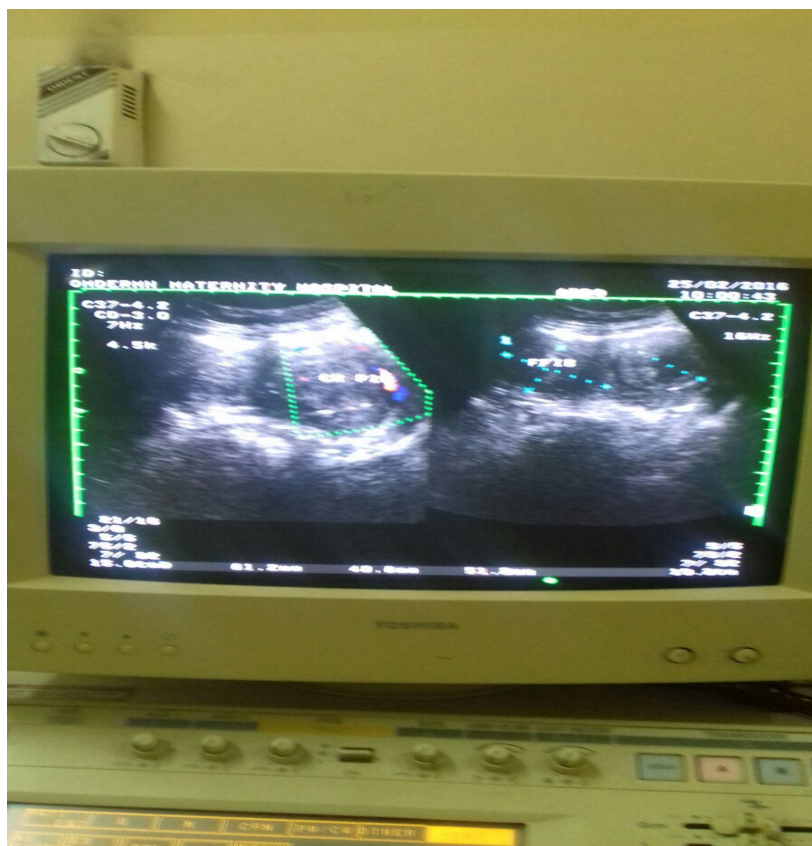

Image (1) transabdominal u/s for 24 y women with uterine fibroid and central vasculertywith color doppler

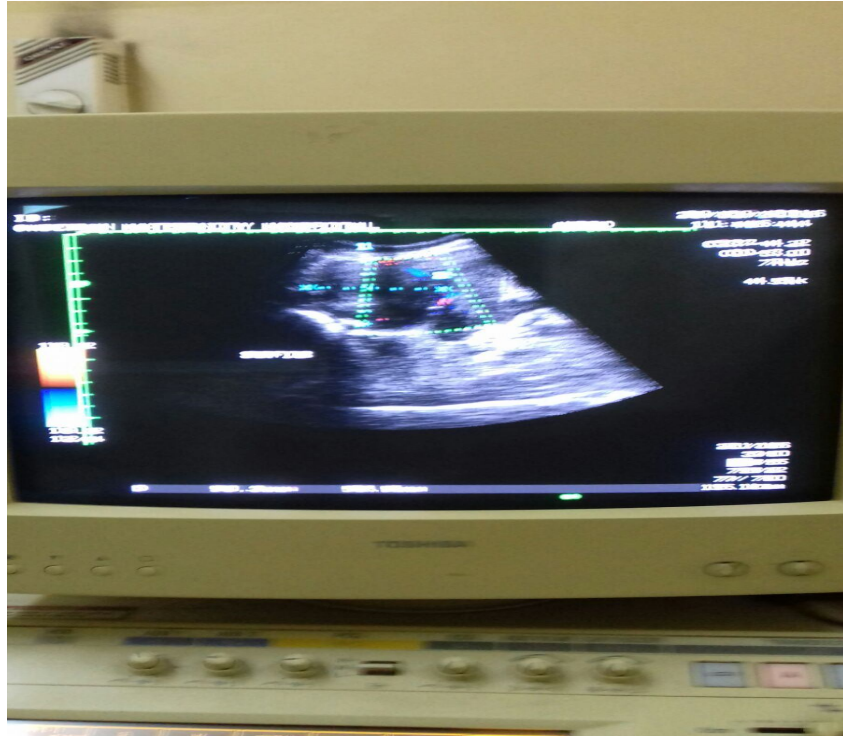


Image (2) transabdominal u/s for 28 y woman with uterine fibroid and peripheral hyper vascularity with color doppler

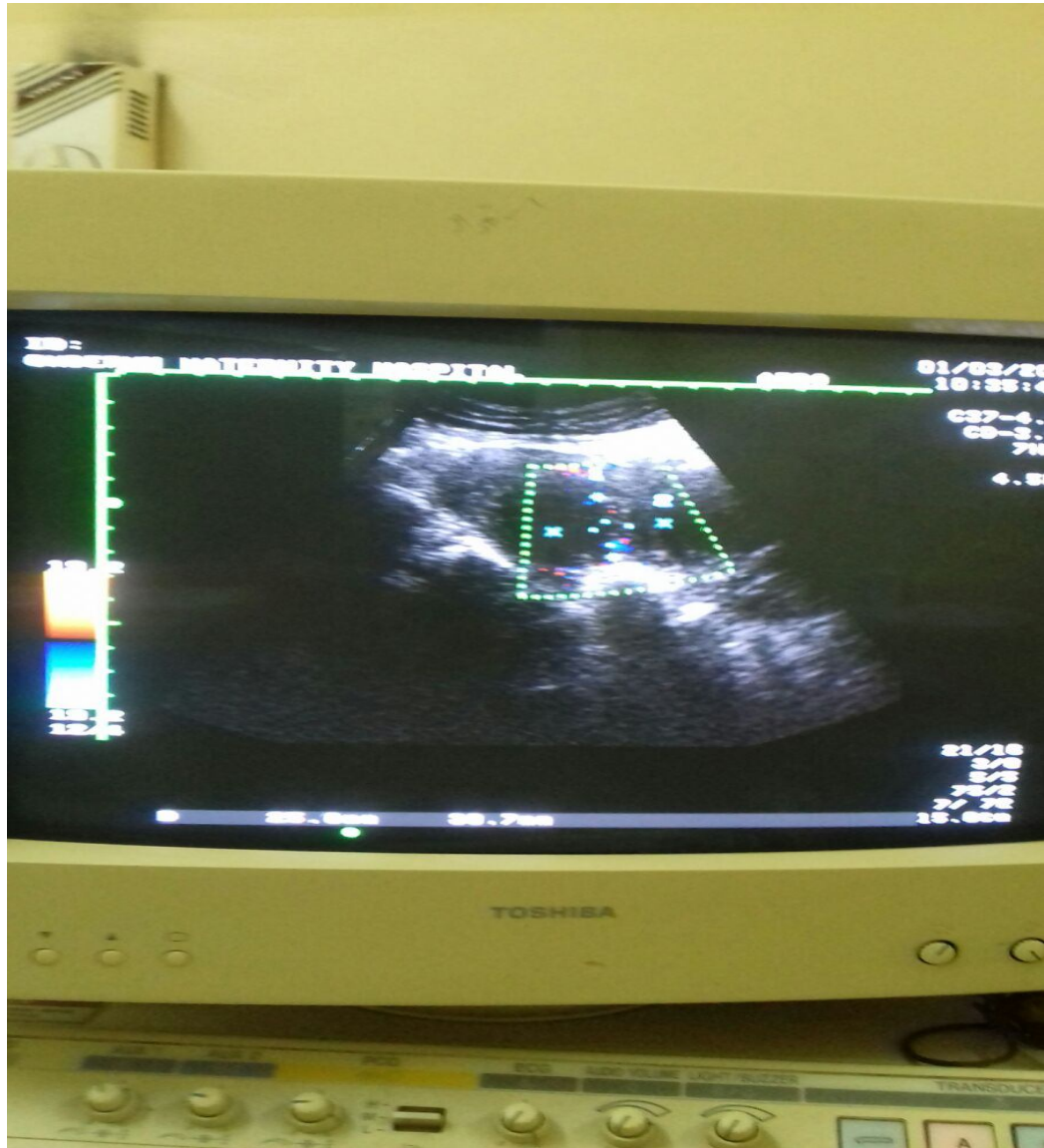

Image (3) transabdominal u/s for 36 y women with uterine fibroid and mixed vascularity with color doppler

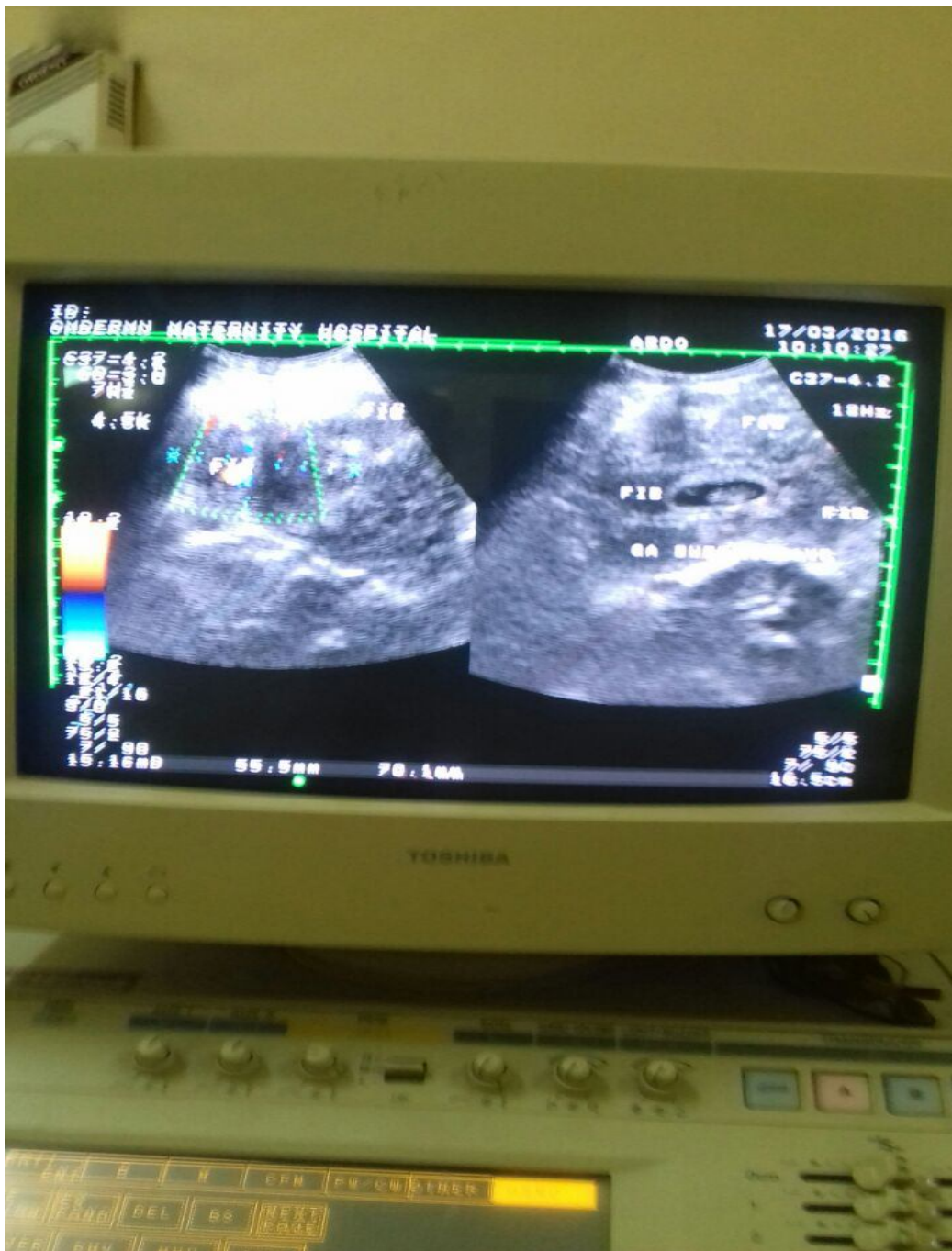


Image (4) transabdominal u/s for 46 y women with uterine fibroid and peripheral hyper vascularity with color doppler

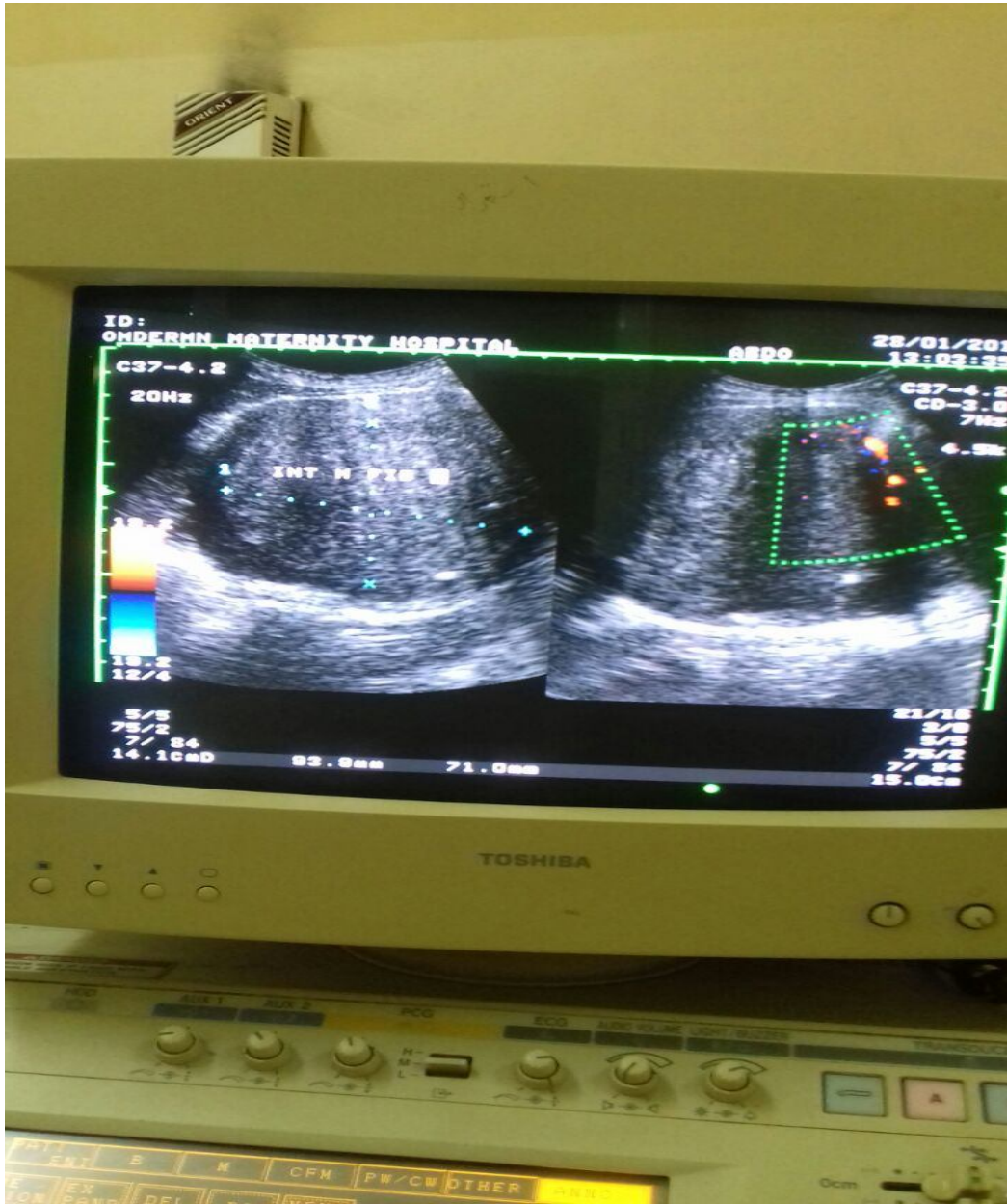


Image (5) transabdominal u/s for 45 y women with uterine fibroid and peripheral hyper vascularity with color doppler

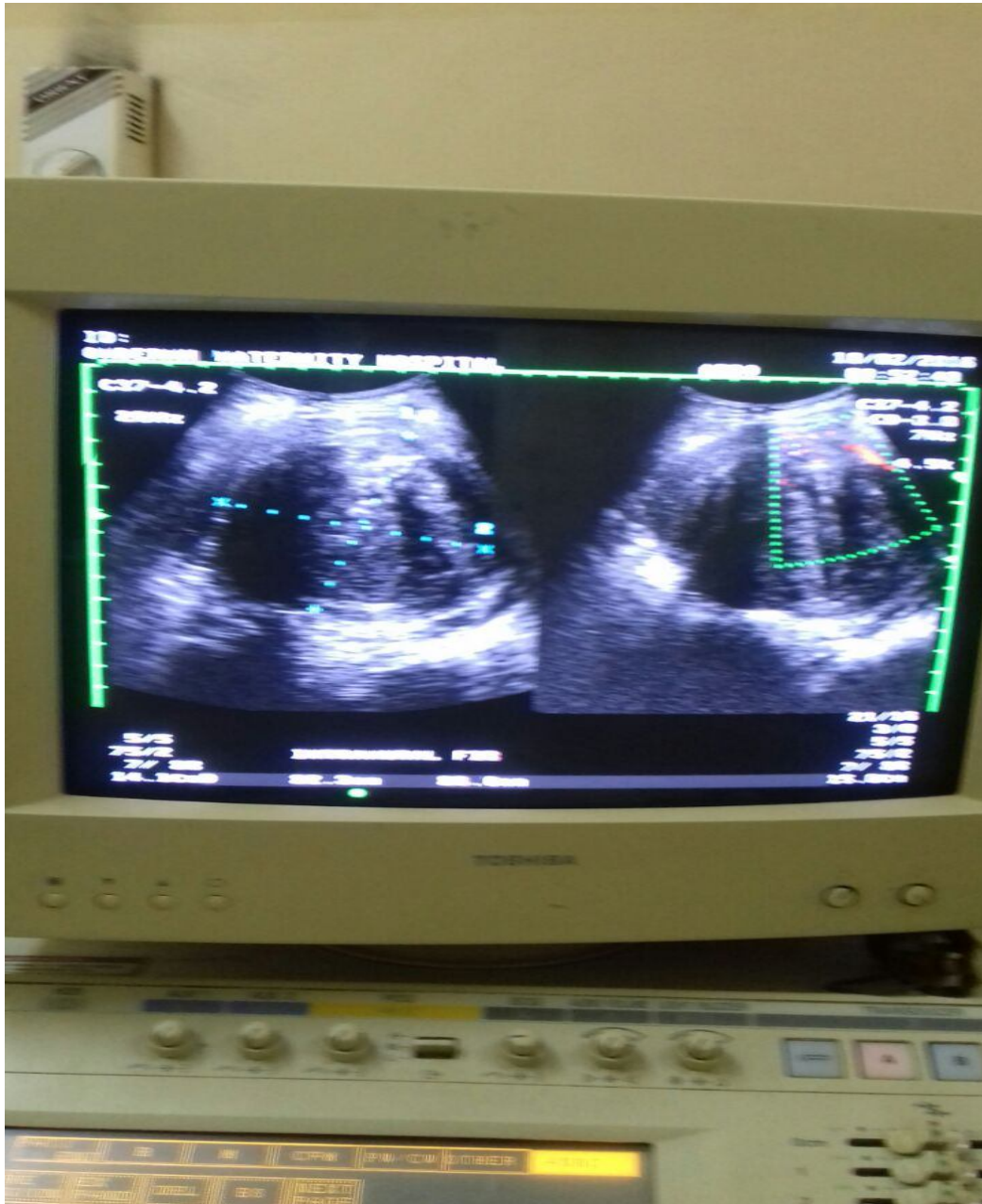

Image (6) transabdominal u/s for 46 y women with uterine fibroid and peripheral hyper vascularity with color doppler

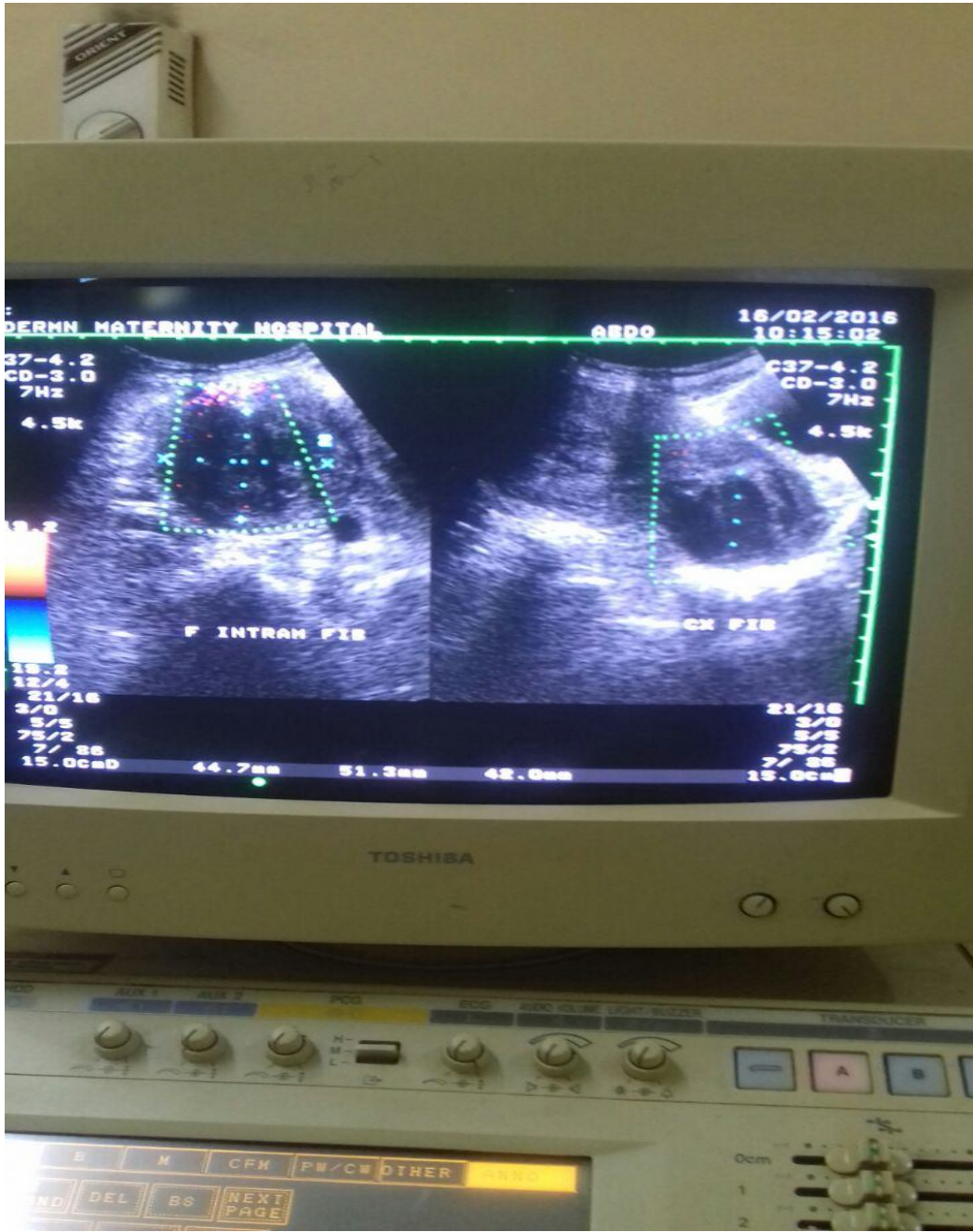


Image (7) transabdominal u/s for 37 y women with uterine fibroid and peripheral hyper vascularity with color doppler

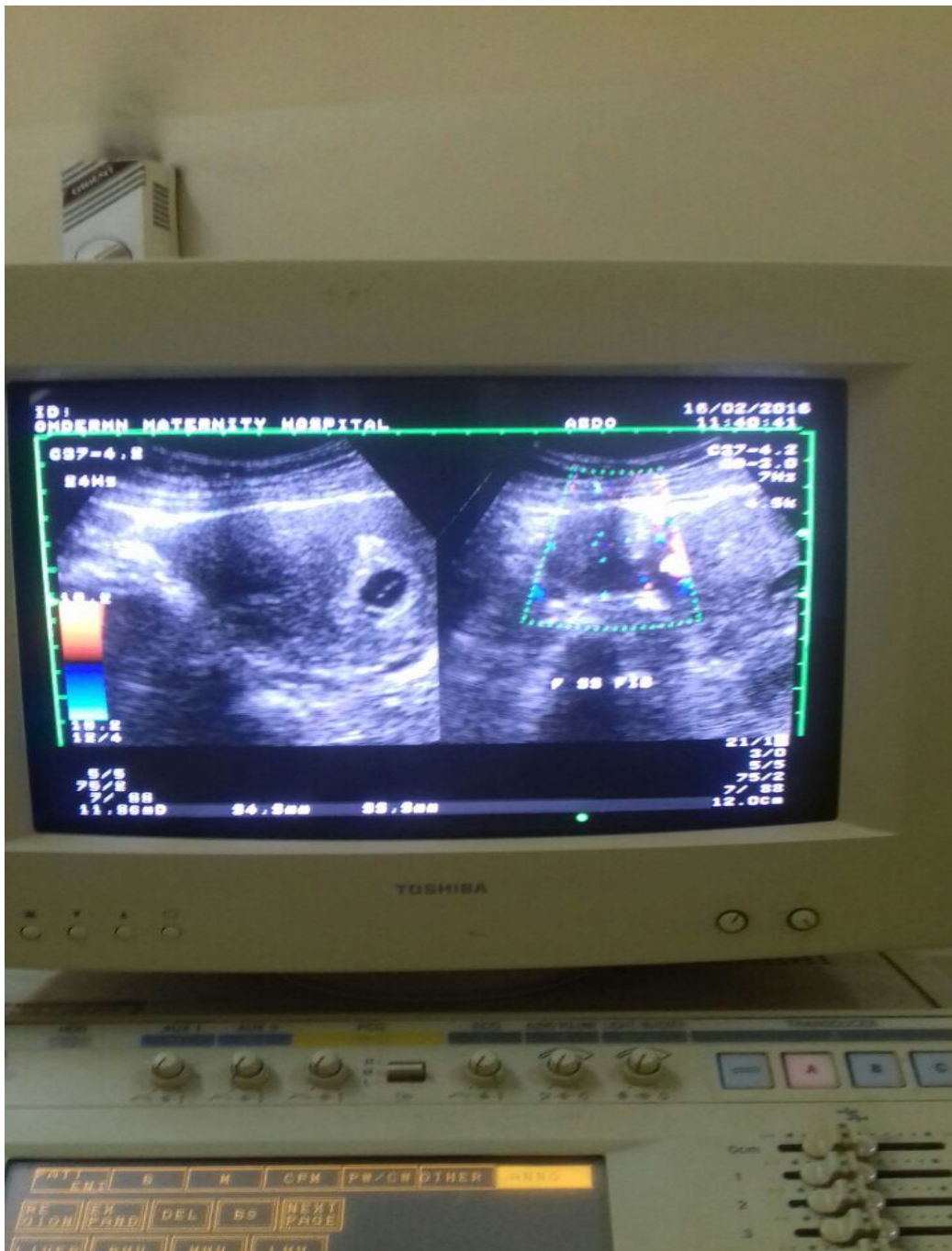


Image (8) transabdominal u/s for 35 y women with uterine fibroid and peripheral hyper vascularity with color doppler

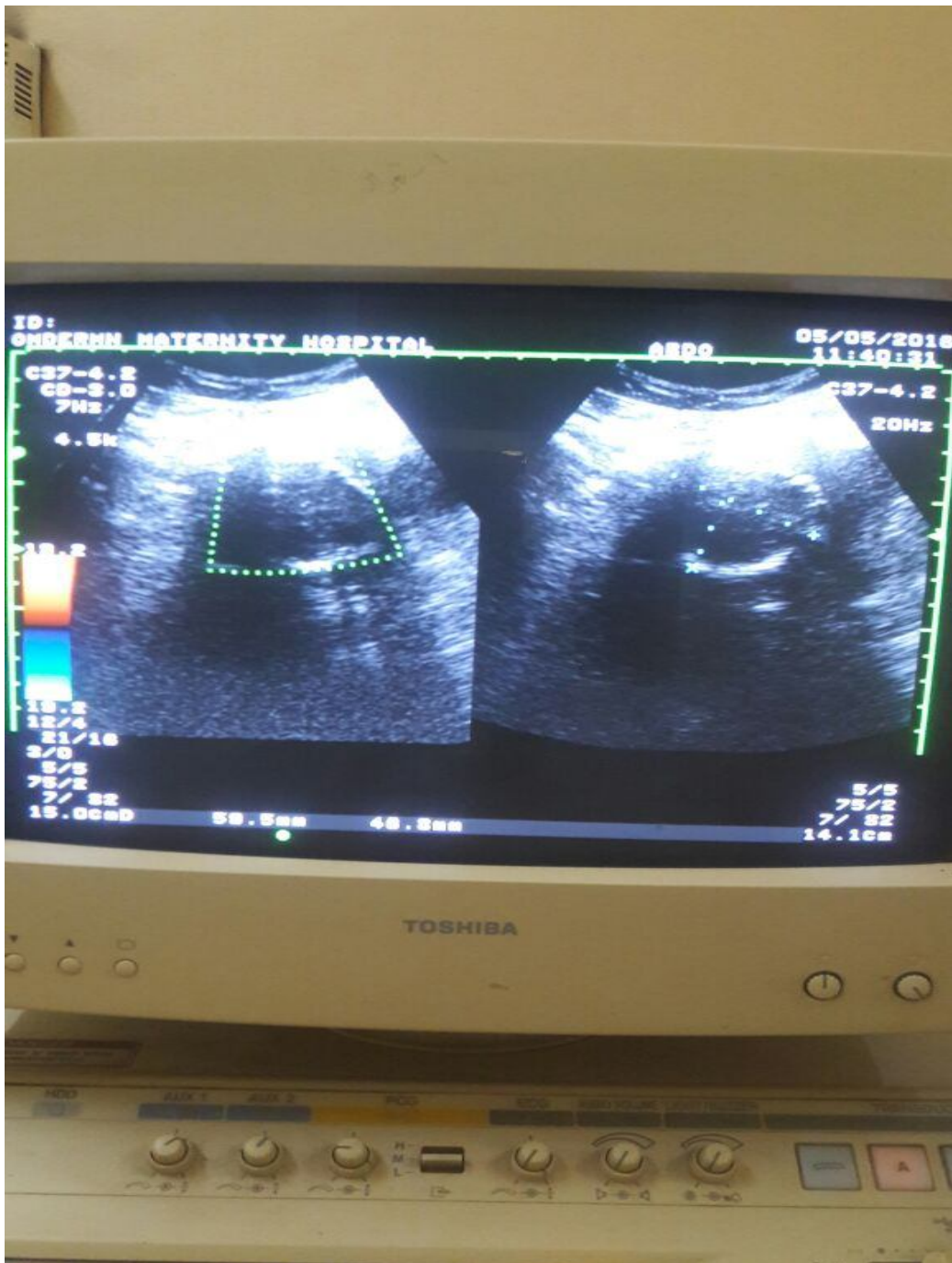


Image (9) transabdominal u/s for 38y women with uterine fibroid and peripheral hyper vascularity with color doppler

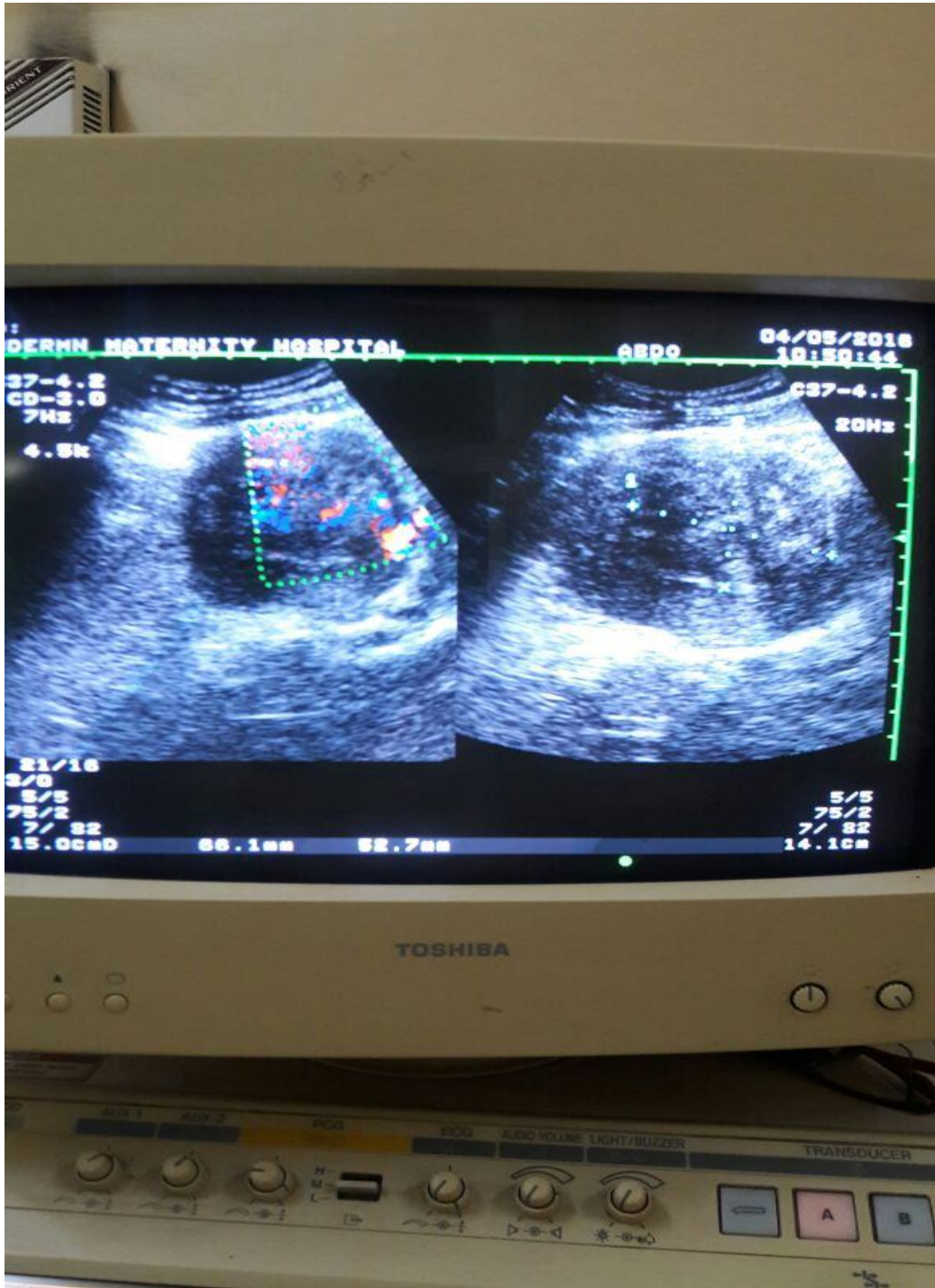


Image (10) trans abdominal u/s for 28 y women with uterine fibroid and mixed vascularity with color doppler

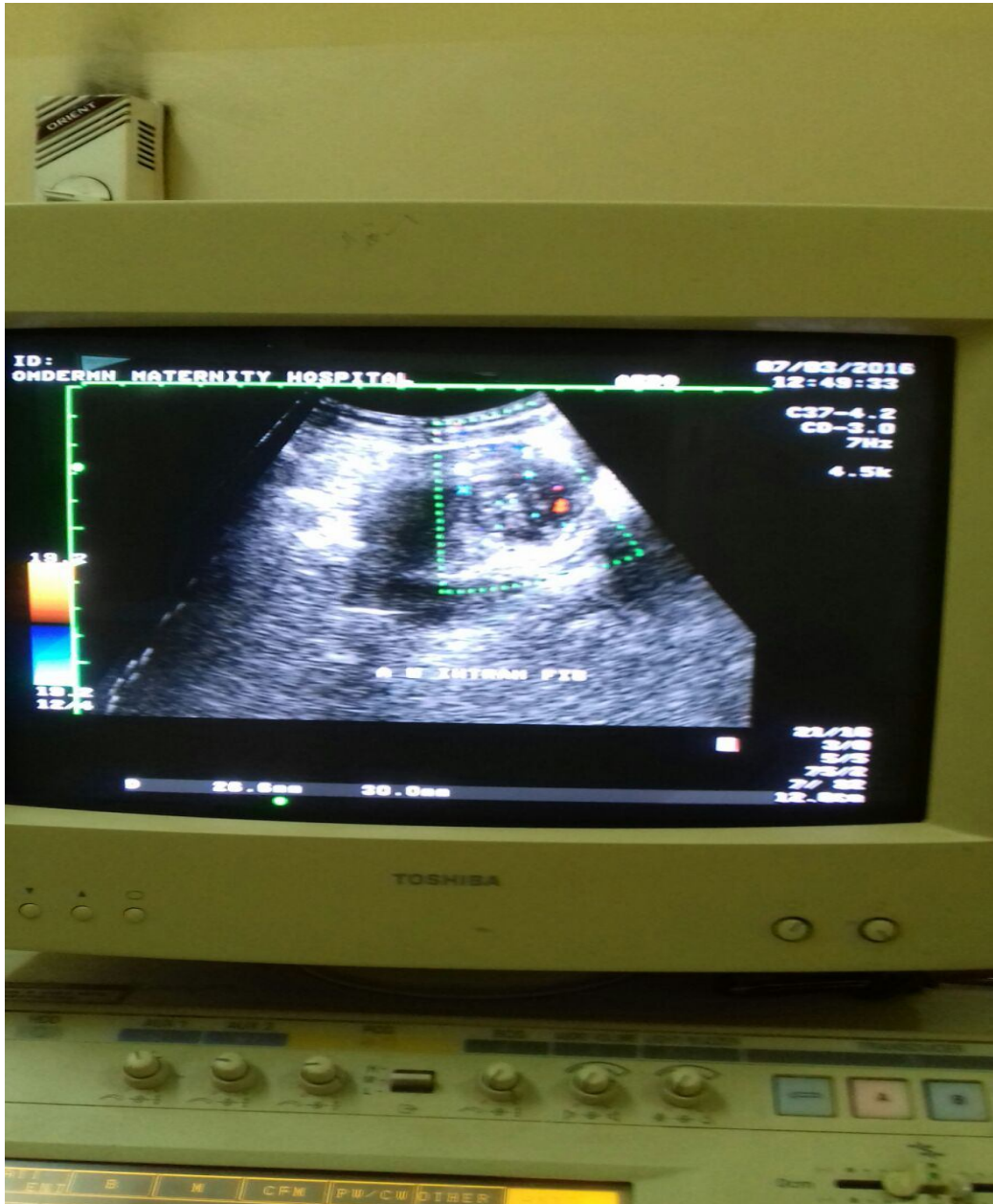

Image (11) transabdominal u/s for 32 y women with uterine fibroid and peripheral hyper vascularity with color doppler

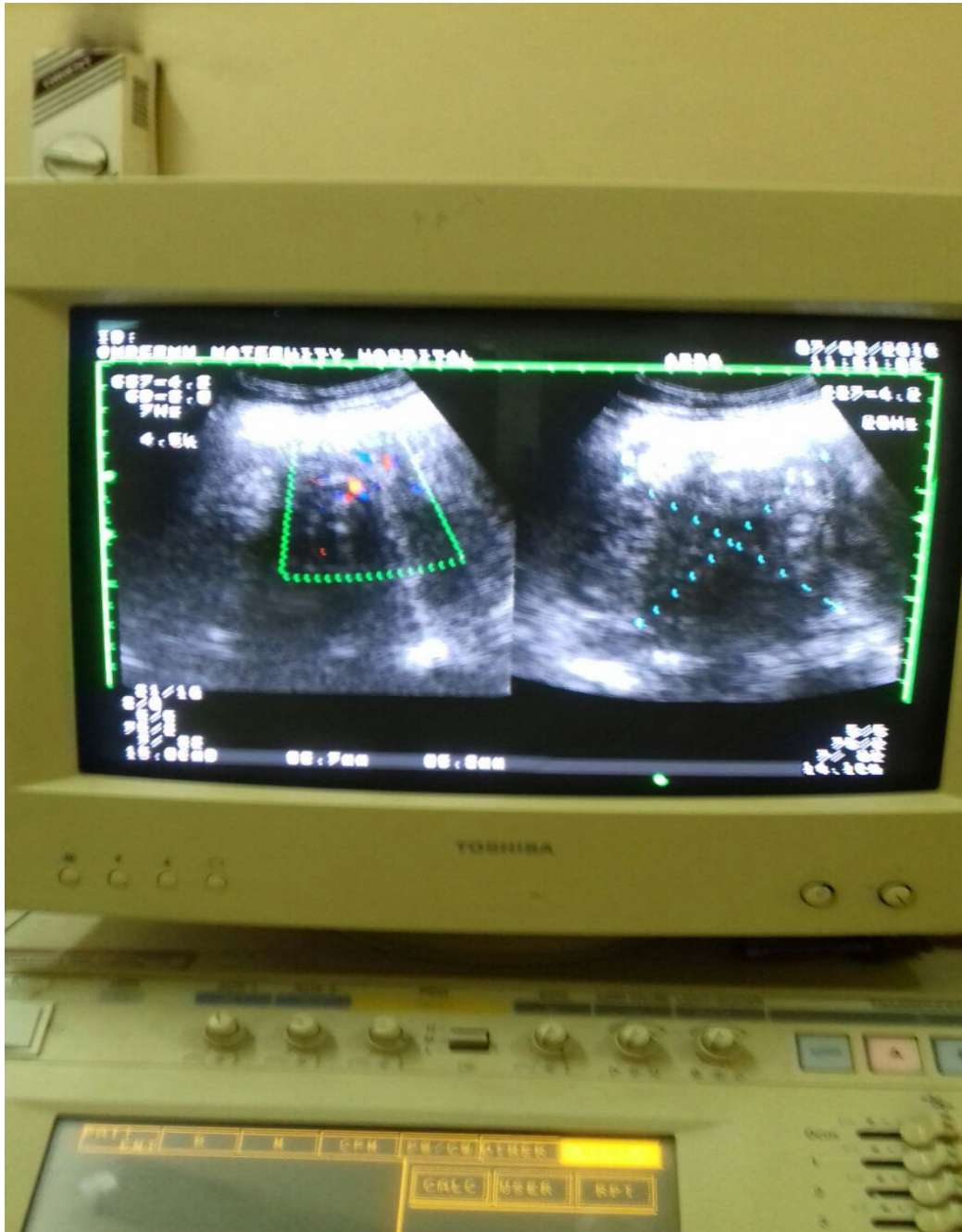


Image (12) transabdominal u/s for 43 y women with uterine fibroid and central vascularity with color doppler

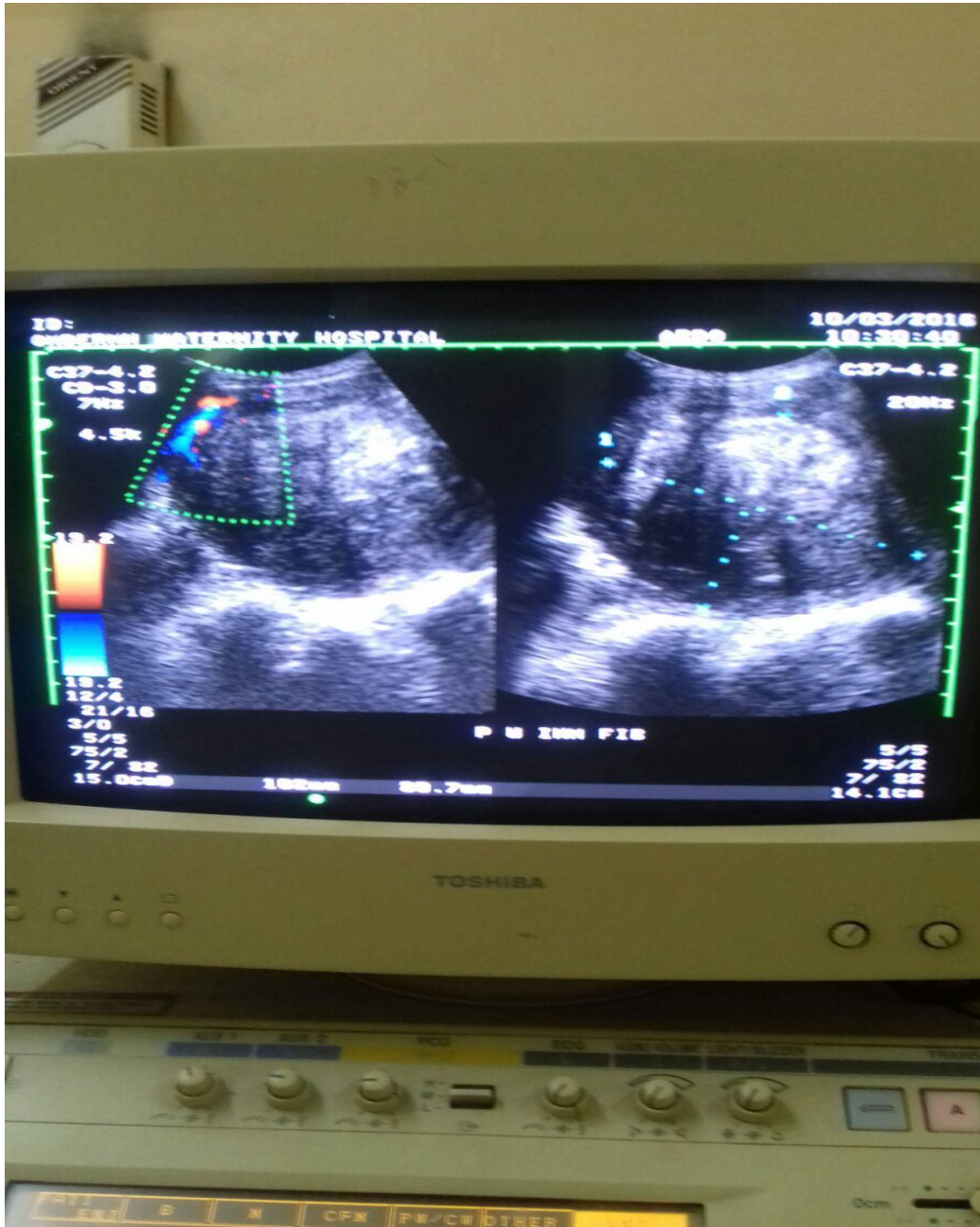


Image (13) transabdominalu/s for 34y women with uterine fibroidand peripheral hyper vasculertywith color doppler

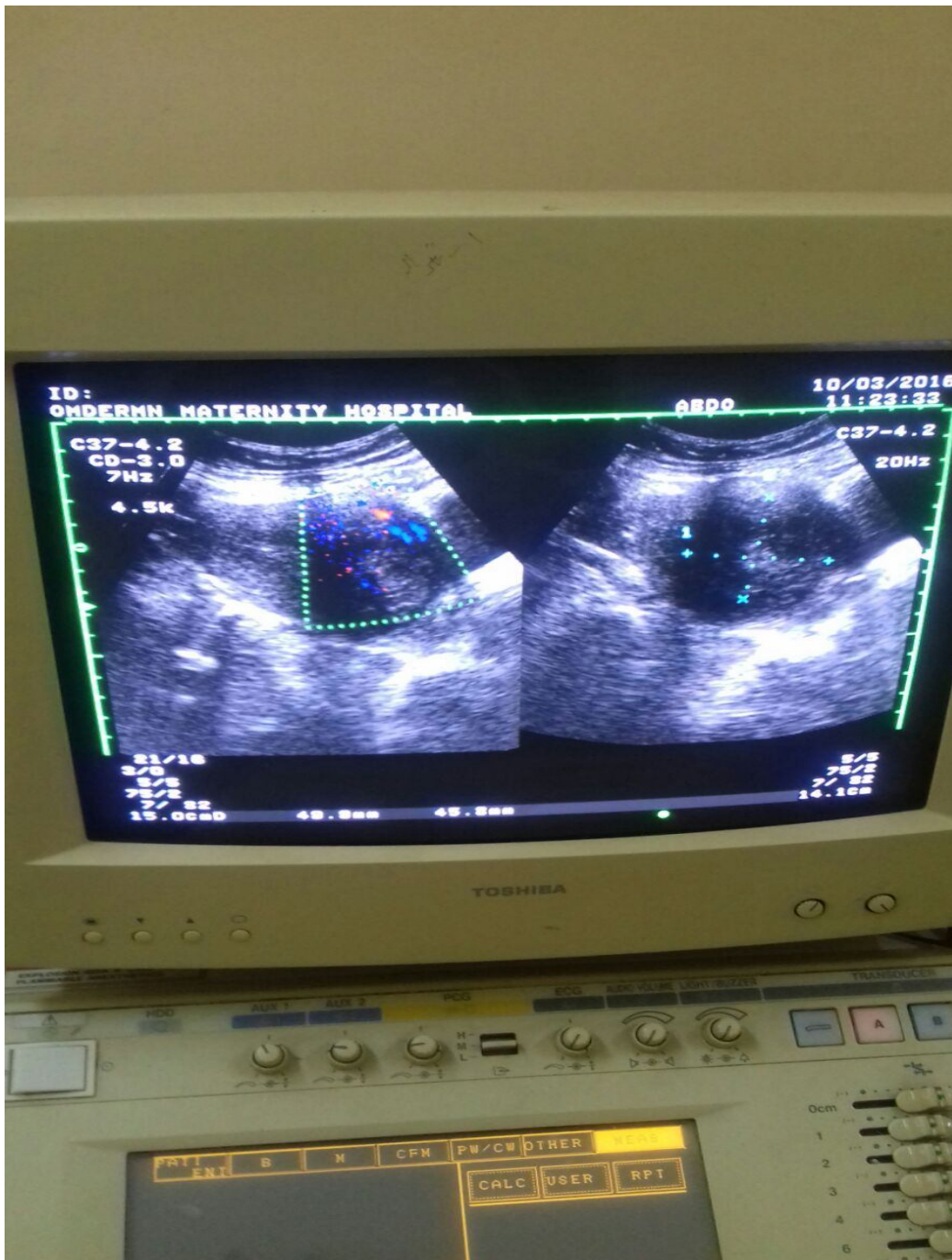


Image (14) transabdominal u/s for 41 y women with uterine fibroid and peripheral hyper vascularity with color doppler

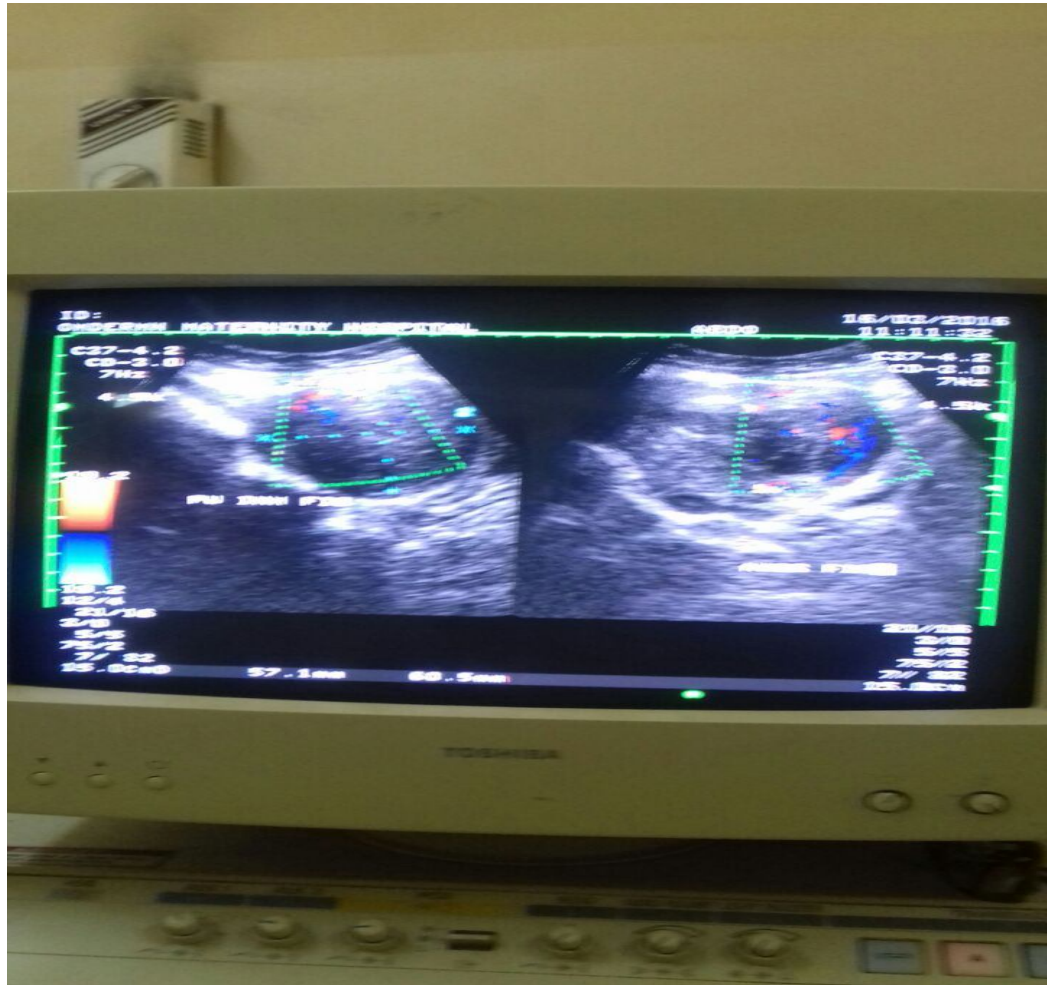

Image (15) transabdominal u/s for 45 y women with uterine fibroid and central vascularity with color doppler