



Sudan Universe of Sciences and technology

College of Graduate studies



**Daignosis of Benign and Malignant Tumors of Prostate Gland
Using Ultrasonography**

**تشخيص الاورام الحميدة والخبيثة الخاصة بغدة البروستاتا باستخدام
الموجات فوق الصوتية**

*A Thesis submitted Partial Fulfillment of Requirements of the Msc
Degree in Medical Diagnostic Ultrasound*

By

Myada Ali Albasher Karam Alla

Supervisor

Dr. Babiker Abd Elwahab Awad Alla

2017

الآية

بسم الله الرحمن الرحيم

قال تعالى:

(اللَّهُ لَا إِلَهَ إِلَّا هُوَ الْحَيُّ الْقَيُّومُ لَا تَأْخُذُهُ سِنَّةٌ وَلَا نَوْمٌ لَهُ مَا فِي السَّمَوَاتِ
وَمَا فِي الْأَرْضِ مَنْ ذَا الَّذِي يَشْفَعُ عِنْدَهُ إِلَّا بِإِذْنِهِ يَعْلَمُ مَا بَيْنَ أَيْدِيهِمْ وَمَا
خَلْفَهُمْ وَلَا يُحِيطُونَ بِشَيْءٍ مِنْ عِلْمِهِ إِلَّا بِمَا شَاءَ وَسِعَ كُرْسِيُّهُ السَّمَاوَاتِ
وَالْأَرْضَ وَلَا يَئُودُهُ حِفْظُهُمَا وَهُوَ الْعَلِيُّ الْعَظِيمُ).

سورة البقرة الآية (255)

Dedication

- *To my dear and my mother.*

- *To my father ,brothers, sisters.*

- *To my friends.*

- *And to my colleagues.*

Acknowledgement

I would like to thank *Dr. Babiker Abdelwahab*, my Supervisor for his kind advice, true guidance, great help and valuable critics: I'm very grateful to *Prof. Mohammed Elfadil*, my co-supervisor for her full advice, encouragement and great help.

I would like also to thank *Dr, Ahmmed Almustafa* Abo Kunna Dean of college of Medical Radiological Sciences (SUST) for his help and good advice.

I'm continuous very full thanks to my *Friend Lubna sirrag eldeen* for his encouragement and support.

Abstract

This study was a descriptive cross sectional study which aimed to evaluate the role of U/S and fPSA in differentiation between benign prostatic hyperplasia and prostatic carcinoma, carried out in Elribat hospital (renal unit) from November 2016 to February 2017.

There were 50 patients were scanned transabdominal using Aloka and Toshiba U/S machines. All patients had benign prostatic hyperplasia or prostatic carcinoma and referred by physician. Any patient had normal prostate or prostatitis was excluded from this study.

Firstly ultrasound scanning was done for patients to evaluate AP diameter, transverse, thickness, volume shape and echo-texture of the prostate. Then tPSA and fPSA were done to all patients, finally histopathology was done for all patients.

Data was collected using data collected sheets and analyzed using SPSS program. Study found that there were 60% of patients had benign prostatic hyperplasia, while other (40%) patients had prostatic cancer. Also study showed there were 32 patients (64%) out of 50 cases had normal shape, 30 patients(60%) of them had benign prostatic hyperplasia, 2 patients (4%) had cancer. 34patients (68%) out of 50 had presence of calcification.

Study concluded that using ultrasound and fPSA was accurate that tPSA in differentiation between benign prostatic hyperplasia and prostatic cancer or any tool alone.

The Study recommended that ultrasound scanning should be done routinely for any patient had age more than forty.

المستخلص

هذه الدراسة دراسته مقطعيه وصفية هدفت الى تقييم دورالموجات الصوتيه والمضاد الجيني المحدد الحر في التفريق بين تضخم البروستاتا الحميد وسرطان البروستاتا التي اجريت في مستشفى الرباط (وحدة المسالك البولية) من نوفمبر 2016 الي فبراير 2017 وتم فحص 50 مريضا من الذكور بالموجات الصوتيه عن طريق البطن باستخدام ماسحات الوكا وتوشيبا وكان لجميع المرضى الذين يعانون من التضخم الحميد والخبيث لغدة البروستاتا حيث تم تحويلهم بواسطة المريض المعالج

تم اجراء المسح بالموجات فوق الصوتيه لتقييم ارتفاع عرض سمك شكل وحجم نسيج البروستاتا

وكذلك تم القيام باخذ فحص المضاد الجيني المحدد الكلي والحر لجميع المرضى وقد تم اخيرا التشريح المرضى لكل المرضى

وقد تم جمع البيانات باستخدام اوراق البيانات التي تم جمعها وتحليلها باستخدام برنامج SPSS

ووجدت الدراسة ان هنالك 60% من المرضى مصابون بالزيادة المفرطه للبرستاتا و في حين ان اخرين 40% من المرضى مصابون بتضخم البرستاتا كما اظهرت الدراسة ان هنالك 33مريضا(64%) من 50 حاله كان الشكل طبيعي،36 مريض (60%) من كان لهم تضخم البرستات الحميد.

كان هنالك 34مريضا (68%) من 50 حاله لديهم تكلس وخلصت الدراسة الى انه باستخدام الموجات فوق الصوتيه والمضاض الجيني المحدد الحر ادق من المضاض الجيني المحدد الكلي الكلي في التفريق بين التضخم الحميد والخبيث لغده البروستاتا.

واوصت الدراسة ان المسح بالموجات فوق الصوتيه ينبغي ان يتم شكل روتيني لدى اي مريض العمر اكثر من اربعين

Table of Contents

الأية	
Dedication	II
Acknowledgement.....	III
Abstract	IV
المستخلص	V
List of Tables.....	IX
List of Figures	XI
List of Abbreviations.....	XIII

Chapter one: Introduction

1-1 Introduction.....	2
1-2 problem of the study:	4
1-3 Objectives of the study:	4
1-3-1 General objectives:	4
1-4 Overview of the study:.....	5

Chapter Two: Literature review

2.1Anatomy:	6
2.1.1 Vascular Supply and Lymphatic Drainage:	9
2.1.2age Changes in the Prostate	10
2.2 Physiology of Prostate:	12
2.3 Pathology.....	13
2.3.1 Prostatitis:.....	13
2.3.2 Acute bacterial prostatitis.....	14
2.3.3 Chronic bacterial prostatitis:	15

2-3-4Chronic prostatitis/chronic pelvic pain:	15
2-3-5Granulomatous prostatitis:	15
2-3-6 Prostate cysts:	15
2-3-7Benign Enlargement of the Prostate:.....	16
2-3-8Prostate adenocarcinoma	18
2-4Prostate-Specific Antigen:	18
2-4-3PSA Velocity:	20
2-4-4Free/Total PSA Ratio:	20
2-4-5Current PSA Standards:.....	21
2-5 Sonographic Appearance Gray-Scale US of prostatic cancer and benign prostatic hyperplasia.....	22
2-6 Other Imaging Techniques	23
2-6-1Magnetic resonance imaging:.....	23
2-6-2Computed tomography:	23
2-6-3Radionuclide bone scans:	24
2-6 Ultrasound appearance of normal prostate:	24
2-7 Previous Study	25

Chapter Three: Materials and Methods

3.1 Materials:.....	27
3.2 Design of the study:	28
3.3 Population of the study:	28
3.4 Sample size and type:.....	28
3. Technique used:	29
3.7 Methods of data collection:.....	32
3.8 Data Analysis:	32

3.19 Ethical approval:33

Chapter four:Results

Results34

Chapter Five: Discussion, Conclusion & Recommendations

5.1 Discussion48

5-2 Conclusion:51

5-3 Recommendations:.....53

References:54

Appendices57

List of Tables

Table no	Subject	Page
3-1	Ultrasound finding score	33
4-1	Shows the age group with respect to histopathology result	36
4-2	Shows occupation distribution	36
4-3	Shows marital status	37
4-4	Shows histopathology result frequency	38
4-5	Crosstabulation table that shows the frequency of histopathology results(BPH and adenocarcinoma) in relation to ultrasound finding in prostate size	39
4-6	Crosstabulation table that shows the frequency of histopathology results(BPH and adenocarcinoma) in relation to ultrasound finding in prostate shape	40
4-7	Crosstabulation table that shows the frequency of histopathology results(BPH and Adenocarcinoma) in relation to presence of calcification	41
4-8	Crosstabulation table that shows the frequency of histopathology results(BPH and Adenocarcinoma) in relation to the presence of mass	42
4-9	Crosstabulation table that shows the frequency of histopathology results(BPH and Adenocarcinoma) in relation to the site of mass	43
4-10	Crosstabulation table that shows the frequency of histopathology result (BPH and Adenocarcinoma) in relation to ultrasound finding in prostate texture	44
4-11	Crosstabulation table that shows the frequency of histopathology result(BPH and Adenocarcinoma) in relation to prostate diameter(trans>anteroposterior and	45

	anteroposterior>transverse	
4-12	Show the total PSA value	46
4-13	Crosstabulation table that shows the frequency of histopathology results (BPH and Adenocarcinoma) in relation to fpsa/ tpsa ratio	46
4-14	Statistical table of u/s ,fpsa ,tpsa ,Age	48
4-15	Statistical table of U/S in result group	49

List of Figures

Figure no	Subject	Page
2.1	Shows zonal anatomy of prostate	8
2.2	Shows the parts of prostate	10
2.3	Shows blood supply of prostate	10
2.4	Shows the function of prostate	14
2.5	U/S image of prostatitis	15
2.6	U/S image of cystic lesion of prostate	16
2.7	U/S image of prostatic calcification	17
2.8	U/S image of benign prostatic hyperplasia	18
2.9	U/S image of benign prostatic hyperplasia	18
2.10	U/S image of prostatic adenocarcinoma	19
2.11	U/S image of normal prostate	25
3.1	Show machine used in measurement of tpsa and fpsa	30
4.1	Show occupation distribution	36
4.2	Show marital status distribution	37
4.3	Show histology result frequency	38
4.4	Frequency of histopathology result in relation to u/s findings in prostate size	39
4.5	Frequency of histopathology result in relation to u/s findings in prostate shape	40
4.6	Frequency of histopathology result in relation to Presence of calcification	41
4.7	Frequency of histopathology result in relation to presence of mass	42
4.8	Frequency of histopathology result in relation to site of mass	43
4.9	Frequency of histopathology result in relation to u/s findings in prostate texture	44
4.10	Frequency of histopathology result in relation to u/s findings in prostate diameter	45
4.11	Figure (4.11). Shows the frequency of histopathology results (BPH and adenocarcinoma) in relation to fPSA/tPSA.	46

4.12	Figure (4.12). shows the correlation between prostatic volume and residual urine.	47
4.13	Figure (4.13). shows the correlation between prostatic volume and fPSA/tPSA in malignant cases.	47
4.14	Figure (4.14). Shows the correlation between prostatic volume and fPSA/tPSA in benign prostatic hyperplasia cases.	48

List of Abbreviations

AP	Antero posterior
BPH	Benign Prostatic Hyperplasia
CT	Computed Tomography
DHT	Dhydrotestosterone
DRE	Digital Rectal Examination
FPSA	Free Prostatic Specific Antigen
HIV	Human Immune Deficiency
LUTS	Lower Urinary Tract Symptoms
MRI	Magnetic Resonance Imaging
PSA	Prostatic Specific Antigen
TPSA	Total Prostatic Specific Antigen
TRUS	Trans Rectal Ultrasound
TZ	Tranzition Zone

Chapter one

Introduction

Chapter one

Introduction

1-1 Introduction

Prior to World War II, sonar, the technique of sending sound waves through water and observing the returning echoes to characterize submerged objects, inspired early ultrasound investigators to explore ways to apply the concept to medical diagnosis. In 1929 and 1935, Sokolov studied the use of ultrasonic waves in detecting metal objects. Firestone (1940) and Simons (1945) developed pulsed ultrasonic testing using a pulse-echo technique.

Shortly after the close of World War II, researchers in Japan began to explore the medical diagnostic capabilities of ultrasound. The first ultrasonic instruments used an A-mode presentation with blips on an oscilloscope screen. That was followed by a B-mode presentation with a two dimensional, gray scale image. Japan's work in ultrasound was relatively unknown in the United States and Europe until the 1950s. Researchers then presented their findings on the use of ultrasound to detect gallstones, breast masses, and tumors to the international medical community. Japan was also the first country to apply Doppler ultrasound (an application of ultrasound that detects internal moving objects such as blood coursing through the heart for cardiovascular investigations) in 1980 (Simons 1945).

The prostate develops tumors more frequently than other organs. Luckily these tend to be much slower growing than other tumors, which means that a

man could live years with prostate cancer and end up dying of another cause. The sluggishness of the tumor growth and the small tumors' low probability of migrating to other parts of the body make prostate cancer controversial to treat, especially since the gold standard for treatment (complete removal of the prostate – can leave a man impotent and/or incontinent).

Many of the symptoms of an enlarged prostate and prostate cancer are similar and the two conditions can be difficult to differentiate (Firestone1940).

The patient needs to be told the difference between the two conditions and how prostate enlargement, also known of as benign prostatic hyperplasia (BPH), is not in any way a precursor to prostate cancer.

Transabdominal ultrasound examination

Ultrasound waves are used to detect the prostate gland's size and to check for tumors. However, this test cannot differentiate between prostate cancer and BPH unless the cancer has spread beyond the prostate.

Protein-specific antigen (PSA) assessment

PSA is a protein that is secreted by the prostate gland. PSA is normally present in the blood but the level increases with age and is significantly raised in both BPH and prostate cancer. However, the rise that is seen in the case of BPH is generally not as steep as that seen in prostate cancer.

PSA circulates in blood in two forms: free or attached to a protein molecule called α - Antichemotrypsin. The free PSA test is more often used for men who have higher PSA values (Bunting2002).

This study was done in Khartoum and AlGazeera states, in which there are fifty patients were scanned by ultrasound and laboratory investigations including (tPSA,fPSA and histopathology) to evaluate the accuracy of each one.

This is first study done in Sudan, in which using U/S scanning, fPSA, tPSA and histopathology, but there were multiple studies done out of Sudan using fPSA, tPSA and trans rectal ultrasonography.

1-2 problem of the study:

Total PSA is not accurate examination in detecting of prostate disorders and reliable in differentiation between benign nodular hyperplasia and prostate carcinoma alone, and U/S could be an imaging modality that could help in reach to a diagnosis.

1-3 Objectives of the study:

1-3-1 General objectives:

To evaluate the role of U/S and fPSA in differentiation between benign nodular hyperplasia and prostatic carcinoma.

1-3-2 Specific objectives:

To demonstrate shape, dimensions, volume, and U/S texture of prostate in patient with benign prostatic hyperplasia and prostate cancer.

To select cases which are highly suspicious to be of prostate enlargement using specially designed criteria.

To correlate that the result of tPSA and fPSA with feature of both of them.

To correlate fPSA over tPSA with the result.

To correlate prostate volume in benign and malignant tumor with age and with residual volume of urine.

1-4 Overview of the study:

This study consist of five chapters, chapter one contains introduction, hypothesis, objectives and overview of the study. Chapter two deals with literature review which includes , tumor markers, information about prostate specific antigen, appearance of normal and abnormal prostate in ultrasound, investigations which usually done for prostate and previous studies. Chapter three contains methodology of the study. Chapter four contains results of the study. Chapter five contains discussion of the results, conclusion and recommendations. Finally there are list of references and appendices which include ultrasound images.

Chapter Two

Literature review

Chapter Two

Literature review

2.1 Anatomy:

The prostate is a pyramidal fibro muscular gland which surrounds the prostatic urethra from the bladder base to the membranous urethra and is itself surrounded by a thin but tough connective tissue capsule. It lies at a low level in the lesser pelvis, behind the inferior border of the symphysis pubis and pubic arch and anterior to the rectal ampulla, through which it may be palpated. Being somewhat pyramidal, it presents a base or vesicle aspect superiorly, an apex inferiorly and posterior, anterior and two inferolateral surfaces. The prostatic base measures about 4 cm transversely. The gland is 2 cm in anteroposterior and 3 cm in its vertical diameters, and weighs c.8 g in youth, but almost invariably enlarges with the development of benign prostatic hyperplasia (BPH), weighing usually 40 g, but sometimes as much as 150 g or even more after the first five decades of life. Superiorly the base is largely contiguous with the neck of the bladder. The urethra enters the prostate near its anterior border. The apex is inferior, surrounding the junction of the prostatic and membranous parts of the posterior urethra. The anterior surface lies in the arch of the pubis, separated from it by a venous plexus (Santorin's plexus) and loose adipose tissue (Richard S. Snell 1995). It is transversely narrow and convex, extending from the apex to the tissue. The inferolateral surfaces are related to the muscles of the pelvic sidewall: the anterior fibers of levator ani embrace the prostate in the pubourethral sling or pubourethralis. These the posterior surface is separated from the rectum by the prostatic capsule and by Denonvilliers' fascia, a dense condensation of pelvic fascia which develops by obliteration of the rectovesical peritoneal pouch. It is obliterated from below upwards as fetal life progresses so that at birth this fascia separates the prostate the seminal vesicles and the ampulla of the vasa deferentia from the rectum. The posterior surface is transversely flat

and vertically convex. Near its superior (juxtavesical) border is a depression where it is penetrated by the two ejaculatory ducts. Below this is a shallow, median sulcus, usually considered to mark a partial separation into right and left lateral lobes. The anterior and lateral aspects of the prostate are covered by a layer of fascia derived from the endopelvic lies between this extension of the endopelvic fascia and the capsule of the prostate (Richard S .Snell). Anteroinferiorly the fascia and the capsule of the prostate merge and blend with the puboprostatic ligaments. The prostate is traversed by the urethra and ejaculatory ducts, and contains the prostatic utricle. The urethra usually passes between its anterior and middle thirds. The ejaculatory ducts pass anteroinferiorly through its posterior region to open into the prostatic urethra.

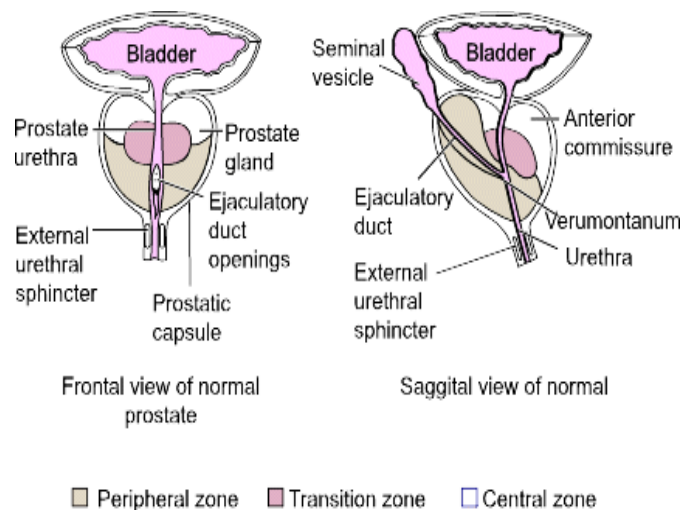


Figure (2-1). Shows zonal anatomy of prostate(susan,2008)

(Richard s .snell1995and Williams1860) The prostate gland was initially thought to be divided into five anatomical lobes, but it is now recognized that five lobes can only be distinguished in the fetal gland prior to 20 weeks' gestation. Between then and the onset of BPH, three lobes are recognizable, two lateral and a median lobe. This simplified view of prostatic location is retained because clinicians refer to left and right 'lobes' when describing rectally palpable and endoscopic ally visible abnormalities in the diseased state when prostatic anatomy is distorted by BPH. From an anatomical and particularly from a morbid anatomical perspective, the glandular tissue may

be subdivided into three distinct zones, peripheral (70% by volume), central (25% by volume), and transition (5% by volume) Non-glandular tissue (fibro muscular stoma) fills up the space between the peripheral zones anterior to the preprostatic urethra(Kaye KW1990)and (M Neal JE1981). The central zone surrounds the ejaculatory ducts posterior to the preprostatic urethra and is more or less conical in shape with its apex at the verumontanum. The transition zone lies around the distal part of the preprostatic urethra just proximal to the apex of the central zone and the ejaculatory ducts. Its ducts enter the prostatic urethra just below the preprostatic sphincter and just above the ducts of the peripheral zone the peripheral zone is cup-shaped and encloses the central transition zone and the preprostatic urethra except anteriorly, where the space is filled by the anterior fibro muscular stoma. Simple mucus-secreting glands lie in the tissue around the preprostatic urethra, above the transition zone and surrounded by the preprostatic sphincter. These simple glands are similar to those in the female urethra and unlike the glands of the prostate. The zonal anatomy of the prostate is clinically important because most carcinomas arise in the peripheral zone, whereas BPH affects the transition zone, which may grow to form the bulk of the prostate. BPH begins as micro nodules in the transition zone; these grow and coalesce to form macro nodules around the inferior margin of the preprostatic urethra, just above the verumontanum. Macro nodules in turn compress the surrounding normal tissue of the peripheral zone posteroinferiorly thereby creating a 'false capsule' around the hyperplastic tissue, which coincidentally provides a plane of cleavage for surgical enucleation of the hyperplastic tissue. As the transition zone grows, it produces the appearance of 'lobes' on either side of the urethra above. These lobes may, in due course, compress or distort the preprostatic and prostatic parts of the urethra to produce symptoms. The central zone surrounding the ejaculatory ducts is rarely involved in any disease. It shows certain

histochemical characteristics which are different from the rest of the prostate and is thought to be derived from the Wolffian duct system (much like the epididymis, vasa deferentia and seminal vesicles), whereas the rest of the prostate is derived from the urogenital sinus.

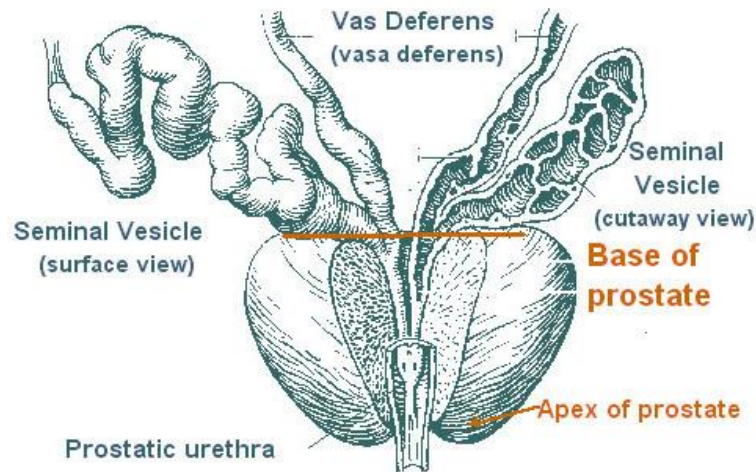


Figure (2-2) show parts of prostate (HenryGray, 1918)

2.1.1 Vascular Supply and Lymphatic Drainage:

Arteries: the prostate is supplied by branches from the inferior vesical, internal pudendal and middle rectal arteries (Richard S Snell1995) and (Leventtis2001). They perforate the gland along a posterolateral line from the junction of the prostate with the bladder down to the apex of the gland.

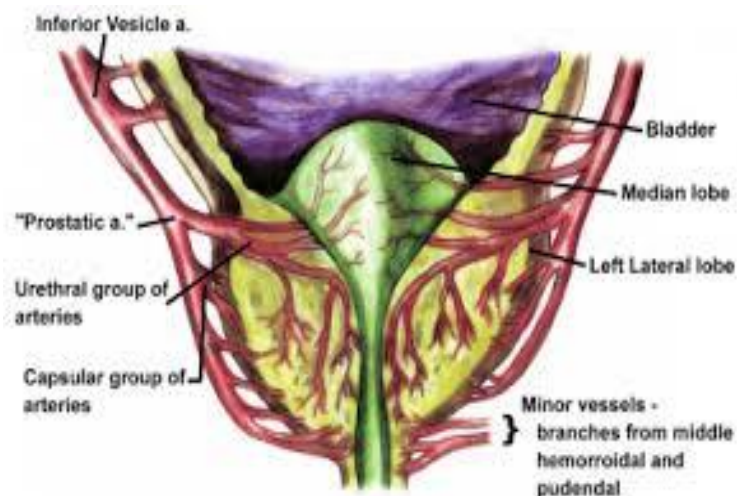


Figure (2-3) show blood supply of prostate (susan2008)

Veins: The veins run into a plexus around the anterolateral aspects of the prostate, posterior to the arcuate pubic ligament and the lower part of symphysis pubis, anterior to the bladder and prostate . The chief tributary is the deep dorsal vein of the penis. The plexus also receives anterior vesical and prostatic rami (which connect with the vesical plexus and internal pudendal vein), and drains into vesical and internal iliac veins (Leventtis2001).

Lymphatic Drainage: Collecting vessels from the vas deferens end in the external iliac nodes, while those from the seminal vesicle drain to the internal and external iliac nodes. Prostatic vessels end mainly in internal iliac, sacral and obturator nodes. A vessel from the posterior surface accompanies the vesical vessels to the external iliac nodes and one from the anterior surface reaches the internal iliac group by joining vessels which drain the membranous urethra.

Innervation: the prostate has an abundant nerve supply from the inferior hypo gastric (pelvic) plexus (Richard S Snell1995) and (Williams1860). The prostatic capsule is covered by numerous nerve fibers and ganglia which form a periprostatic nerve plexus. The greatest density of nerves is found in the preprostatic sphincter, followed by the anterior fibro muscular stroma, and the peripheral zone is the least densely innervated.

2.1.2age Changes in the Prostate

At birth, the prostate has a system of ducts embedded in a stroma which forms a large part of the gland. Follicles are represented by small end-buds on the ducts. Before birth there is hyperplasia and squamous metaplasia of the epithelium of the ducts, colliculus seminalis and prostatic utricle, possibly due to maternal estrogens in the fetal blood. This subsides after birth and is followed by a period of quiescence lasting for 12-14 years. At puberty, between the ages of approximately 14 and 18 years, the prostate gland enters a maturation phase: it more than doubles in size during this time (J.Androl

2010). Growth is almost entirely due to follicular development, partly from end-buds on ducts, and partly from modification of the ductal branches. Morphogenesis and differentiation of the epithelial cords starts in an intermediate part of the epithelial anlage and proceeds to the urethral and sub capsular parts of the gland; the latter is reached by the age of 17-18 years. The glandular epithelium is initially multilayered squamous or cuboidal, and is transformed into a pseudo stratified epithelium consisting of basal, exocrine secretary (including mucous) and neuroendocrine cells. The mucous cells are temporary, and are lost as the gland matures. The remaining exocrine secretary cells produce a number of products including acid phosphatase, prostate-specific antigen and microseminoprotein. This growth of the secretary component is associated with a condensation of the stroma, which diminishes relative to the glandular tissue. These changes are probably a response to the secretion of testosterone by the testis. During the third decade the glandular epithelium grows by irregular multiplication of the epithelial infoldings into the lumen of the follicles. After the third decade the size remains virtually unaltered until 45-50 years, when the epithelial foldings tend to disappear, follicular outlines become more regular, and amyloid bodies increase in number. All these changes are signs of prostatic involution. After 45-50 years the prostate tends to develop BPH. The nature of BPH has been outlined earlier in this chapter. It is an age-related condition: if a man lives long enough then it is inevitable, although it is not always symptomatic. *Benign ductal ectasia* is seen in older men who develop atrophy and dilation of peripheral prostatic ducts. These are visible as single or grouped, radially oriented, 1 to 2-mm-diameter tubular structures in the peripheral zone, starting at the capsule and radiating toward the urethra. When clustered, dilated ducts can form a hypo echoic area that could be mistaken as prostate cancer. Ductal ectasia has no clinical significance.

Prostatic calcifications and corpora amylacea are normal findings and are more common with advancing age. Both form bright, echogenic foci or clumps in the prostate.

Corpora amylacea are simply proteinaceous debris in dilated prostatic ducts, most often seen in periurethral glands and along the surgical capsule, although they can occur anywhere in the prostate. When densely clustered, corpora amylacea can cause significant sound attenuation, which prevents TRUS examination of the anterior parts of the prostate. On Doppler imaging they create a prominent “twinkle” artifact. Subclinical infections, inflammation, and atrophy may contribute to their formation.

2.2 Physiology of Prostate:

The prostate produces a secretion that makes up a large portion of semen volume (M.Y.sukkar2000) and (Retrieved2009). The prostatic secretions are a milky white mixture of simple sugars (such as fructose and glucose), enzymes, and alkaline chemicals. The sugars secreted by the prostate function as nutrition for sperm as they pass into the female body to fertilize ova. Enzymes work to break down proteins in semen after ejaculation to free sperm cells from the viscous semen. The alkaline chemicals in prostatic secretions neutralize acidic vaginal secretions to promote the survival of sperm in the female body.

The prostate contains the ejaculatory duct that releases sperm during ejaculation. The ejaculatory duct opens to allow semen to pass from the ductus deferens into the urethra and eventually out of the body. During orgasm, smooth muscle tissue in the prostate contracts in order to push semen through the urethra.

Urine released from the urinary bladder is carried by the urethra to the body's exterior (Retrieved2009andJohn.Ehall2006). Under normal conditions, urine in the urethra passes through the prostate with no complications whatsoever. The prostate enlarges slowly throughout a man's lifetime, potentially leading

to the restriction or blockage of the urethra by the time a man reaches his fifties or sixties. An enlarged prostate can lead to difficulty urinating or eventually even an inability to urinate. There are many treatments for an enlarged prostate including medications, lifestyle changes, and prostatectomy, the surgical removal of the prostate.

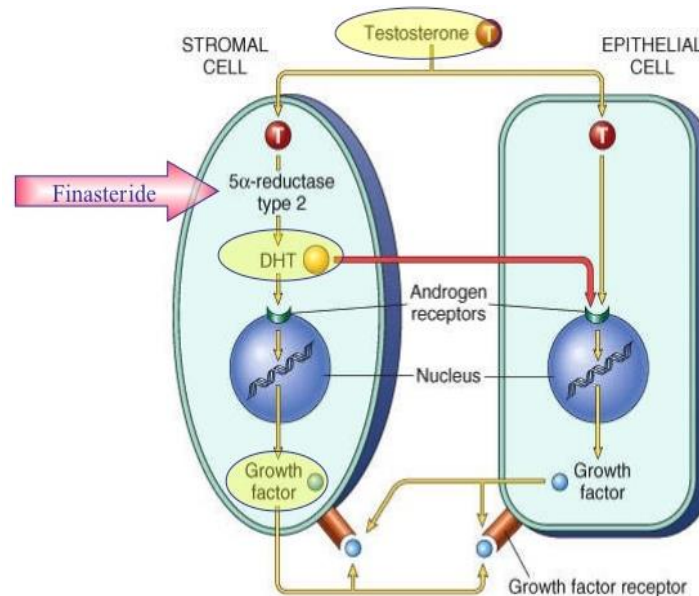


Figure (2-4) Show the function of prostate(McNeal JE1992)

2.3 Pathology

2.3.1 Prostatitis:

Understanding of the condition called “prostatitis” has changed over the years. It is not merely “infection in the prostate.” Rather, prostatitis refers to a chronic pain syndrome in which, surprisingly, infection, inflammation, and even involvement of the prostate are not always present. Prostatitis and pelvic pain complaints quality of life of many men, who have chronic pain, sexual dysfunction, and LUTS. Patient and physician are often frustrated because diagnosis and treatment can be time-consuming and ineffective (Pontari2007). The impact of prostatitis on quality of life has been likened to the morbidity of myocardial infarction, angina, or Crohn’s disease. An estimated 9% to 13% of all men in the 40 to 50-year-old age group are affected. About 25% of visits to urologists relate to prostatitis symptoms. In

men under 50 years, chronic prostatitis/chronic pelvic pain syndrome is the leading cause of visits to a urologist, and in men over 50, it is the third most common cause, after BPH and cancer.

Classification system for prostatitis syndromes that includes the following four categories: I. Acute bacterial prostatitis II. Chronic bacterial prostatitis III. Chronic prostatitis/chronic pelvic pain syndrome A. Inflammatory B. Non inflammatory IV. Asymptomatic inflammatory proctitis (Rothman2007 and Krieger1999).

2.3.2 Acute bacterial prostatitis

Is the least common form of prostatitis, seen in about 2 of 10,000 office visits; 5% to 10% become chronic.

Ultrasound findings are seen only in about half of these men and can include edema, prostate enlargement, increased blood flow, venous engorgement, hypo echoic peripheral halo, and altered patchy echo changes that can be decreased or increased, or both.

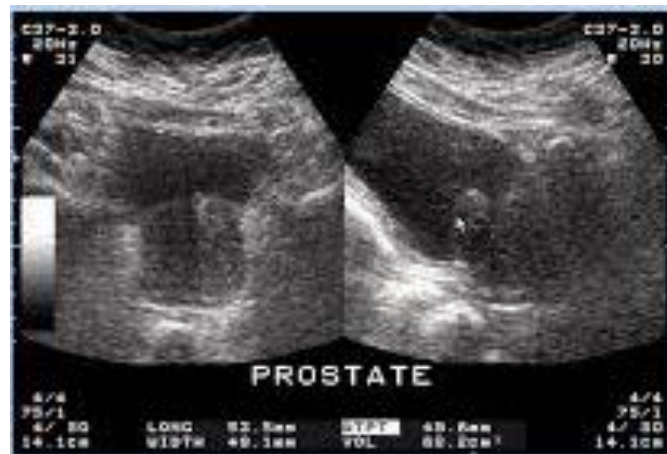

Figure (2-5) Show inflammation of prostate(James F,2008)

Abscesses occur in 0.5% to 2.5% of patients with acute bacterial prostatitis and are more common in those with underlying diabetes mellitus or immune suppression (including HIV) and after catheterization or instrumentation. In such patients, TRUS should be promptly employed for diagnosis. Small abscesses may not need drainage, but larger abscesses can be easily drained

transrectally or transperineally, using TRUS guidance, or can be unroofed at cystoscopy.

2.3.3 Chronic bacterial prostatitis:

Is also uncommon Patients are typically febrile but have recurrent episodes of bacterial urinary infection–like symptoms.

2-3-4Chronic prostatitis/chronic pelvic pain:

Syndrome is the most common form of prostatic inflammation. It accounts for about 90% of cases and affects about 1.9:100 men.

2-3-5Granulomatous prostatitis:

Is usually idiopathic but also can follow prior instrumentation and may be caused by bacteria. The contribution of TRUS is limited in patients with *acute* prostatitis. Physical examination and placing the probe in the rectum are often difficult because of pain. Ultrasound may demonstrate significant mimicking carcinoma. In general, inflamed prostates are hypo echoic and often show several strikingly hypo echoic areas and enhanced vascularity.

2-3-6 Prostate cysts:

Have been grouped into six categories: (1) parenchymal cysts, (2) isolated medial cysts (utricle and müllerian), (3) ejaculatory duct cysts, (4) abscesses, (5) cystic tumors, and (6) cysts related to parasitic disease (schistosomiasis, hydatid disease). The most common cysts are Parenchymal degenerative cysts, Retention cysts, Congenital cysts, Müllerian duct cysts, Cystic neoplasm's and Seminal vesicle cysts.

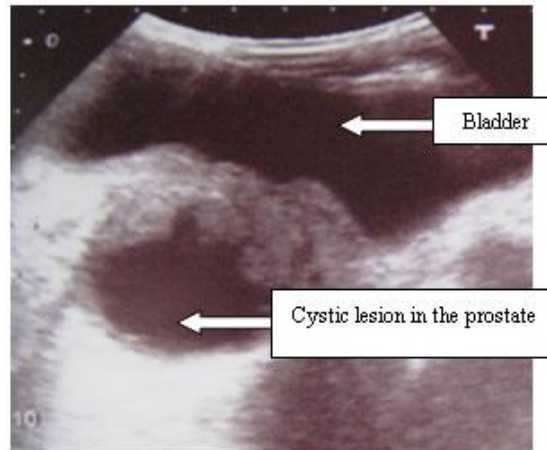


Figure (2-6) show cystic lesion in prostate(James F,2008)

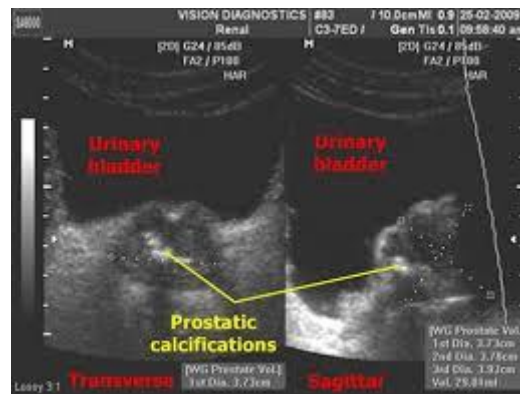
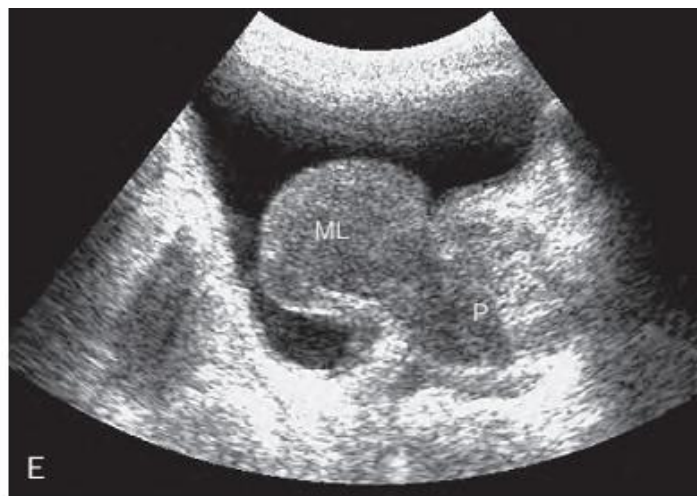

Figure (2-7) Show calcification of prostate(James F,2008)

2-3-7 Benign Enlargement of the Prostate:

Benign enlargement of the prostate is common in men older than 50 years. The cause is possibly an imbalance in the hormonal control of the gland. The median lobe of the gland enlarges upward and encroaches within the sphincter vesicae, located at the neck of the bladder. The leakage of urine into the prostatic urethra causes an intense reflex desire to micturate. The enlargement of the median and lateral lobes of the gland produces elongation and lateral compression and distortion of the urethra so that the patient experiences difficulty in passing urine and the stream is weak. Back-pressure effects on the ureters and both kidneys are a common complication. The

enlargement of the uvula vesicae (owing to the enlarged median lobe) results in the formation of a pouch of stagnant urine behind the urethral orifice within the bladder. The stagnant urine frequently becomes infected, and the inflamed bladder (**cystitis**) adds to the patient's symptoms. In all operations on the prostate, the surgeon regards the prostatic venous plexus with respect. The veins have thin walls, are valve less, and are drained by several large trunks directly into the internal iliac veins. Damage to these veins can result in a severe hemorrhage.



Figure(2-8) show longitudinal plane of benign prostatic hyperplasia(Barry MJ,1992)

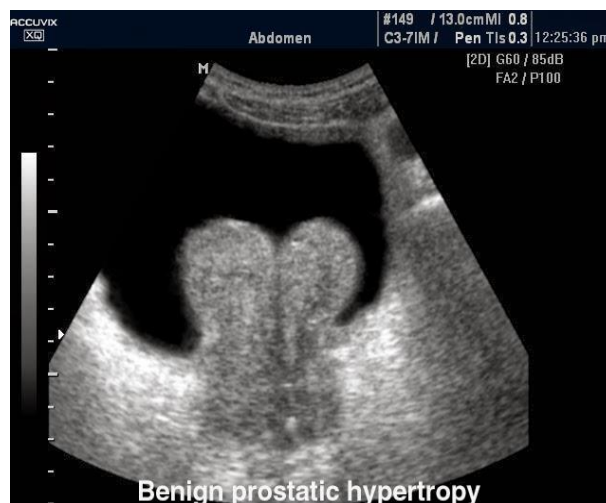


Figure (2-9) show transverse plane of benign prostatic hyperplasia(Barry MJ,1992)

2-3-8 Prostate adenocarcinoma

Has become the most frequently diagnosed cancer in men, two to three times more than lung and colorectal cancer. It is a disease seen primarily in men over age 50. More than 95% of primary malignant tumors of the prostate are adenocarcinomas. Rarely, a variety of other primary neoplasms involve the prostate, including prostate transitional cell carcinoma, sarcomas, and lymphomas (Baratt2002). The prostate can be secondarily affected by tumors of regional structures, including bladder and rectum (Campbell2007 and Chang1998).

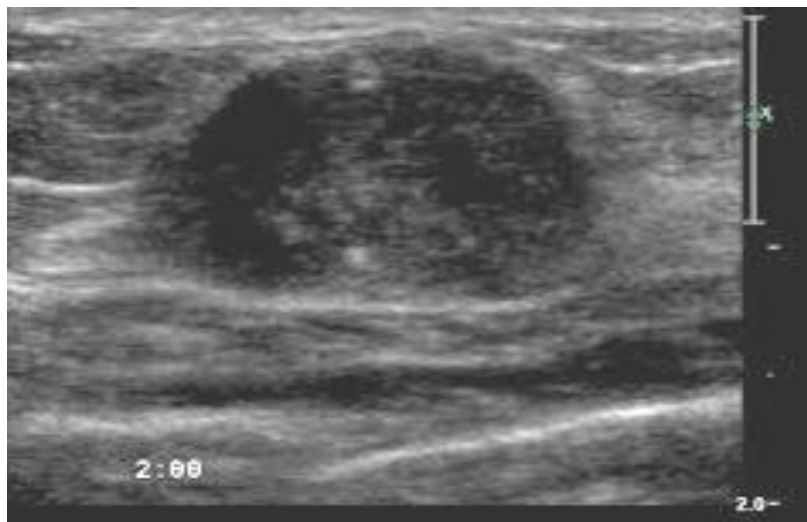

Figure (2-10) show prostatic adenocarcinoma (Shinohara K, 1989)

2-4 Prostate-Specific Antigen:

Prostate-specific antigen has been a tremendous advance in the diagnosis and management of prostate cancer. PSA is a normally occurring enzyme secreted by the epithelial cells of prostate ducts and functions to liquefy the ejaculate (Carroll2009 and Thompson2008). The prostate is the main source of PSA, and only trace amounts are found in other tissues in men and women. Some PSA leaks into the serum, where it can be measured. Abnormal serum PSA levels result from excessive leakage or excessive production (Bunting2002). Cancer is believed to produce on average 10 times as much PSA as a similar

volume of benign tissue. In the serum, PSA is partly unbound (free) and partly bound to proteins such as alpha-1-antitrypsin. The ratio of free to total PSA (percent free PSA) differs in benign and malignant conditions. With cancer and chronic prostatitis, the ratio tends to be low. Prostate-specific antigen is probably best considered as a nonspecific test of prostate abnormality or irritation (Jung, 2008).

Elevated levels occur with cancer but also variably with benign conditions, including BPH, inflammation, after ejaculation, prostate manipulation, biopsy, and cystoscopy. PSA level of 4 mg/mL or less (and more currently, <2.5 ng/mL) was believed to be “negative” and not needing biopsy; values over 10 ng/mL are sufficiently high to recommend biopsy in every case and yield cancer at biopsy exceeding about 50%. The 4 to 10-ng/mL window was problematic because about 35% to 44% of men in this range have cancer (Toi, 2007). The remainder have benign causes for increased PSA (e.g., BPH) and often undergo unnecessary biopsy (low specificity) (Erzioni2002) and (Garnick, 1993). Additional tactics involving PSA density, PSA velocity, and age-specific PSA were developed for the 4 to 10-ng/mL group to avoid biopsy when the elevation was likely caused by benign conditions.

2-4-IPSA Density PSA density (PSAd) is defined as PSA/volume (e.g., PSA 6.0 and gland volume 75 cc; $PSAd = 6.0/75 = 0.08$). Restricting biopsy in the PSA 4 to 10-ng/mL group to those with PSAd in excess of 0.12 to 0.15 will detect about 80% of those with cancer and avoid some biopsies in the above example, the PSAd is 0.08, which is less than 0.12 (Polascik1999). This PSA level is consistent with the prediction from gland volume, and thus biopsy could be avoided at present, with about 80% confidence that cancer is not present. However, 20% of cancers will be missed. PSAd has now also become a marker for prostate cancer aggressiveness to help determine if active surveillance is reasonable for men with low-risk, low volume cancer at biopsy (Littrup2000) and (Loeb2008).

Transition zone (TZ) PSA density is calculated as PSA/TZ volume. It attempts to increase PSA specificity by accounting for the proportion of PSA manufactured by the TZ, which is the site of hyperplasia. Cutoff was estimated at 0.35 ng/mL/cc. This technique has not been reproducible mainly because of difficulties in measuring TZ volume accurately. In our hands, total PSA is more accurate in cancer detection (Polascik1999)

2-4-2Age-Specific PSA Prostate-specific antigen normally increases with age. By using different threshold PSA levels at different ages, it may be possible to make PSA more sensitive in younger men and less sensitive in older men and avoid unneeded referral for biopsy. Although PSA does increase with age, the change related to age alone is very slight. Most of the increase with age is caused by the prostate enlargement with BPH found in older men (Price, 2001). Therefore, age-specific PSA is really a surrogate for prostate volume, which is better evaluated with TRUS

2-4-3PSA Velocity:

Over time, PSA levels in men with cancer usually rise more rapidly than in men with BPH. The rate of PSA rise over time is termed velocity. In the 4 to 10–ng/mL PSA group, if three PSA tests are done over 2 years and velocity exceeds 0.75 ng/mL/yr, this rapid change distinguishes men with cancer from those with BPH with a specificity of 90%. For men up to age 59 and for PSA less than 4 ng/mL, a lower PSA velocity threshold of 0.4 ng/mL/yr could be used. Higher velocities are associated with increased cancer aggressiveness (Loeb2008) and (Gonzalzo2007).

2-4-4Free/Total PSA Ratio:

Prostate-specific antigen in the blood is partly free and partly bound to proteins, especially alpha-1-antitrypsin. The usual PSA measurement is the sum of free plus bound. For unexplained reasons, the free/total ratio tends to be high with benign conditions and low with cancer. In the 4 to 10–ng/mL PSA range, using a free/total ratio of less than 20% detects about 95% of

cancers and decreases the number of biopsies by about 30%. However, 5% of clinically significant cancers will be missed. An exact cutoff ratio has not yet been generally accepted (Littrup2000) and (Loeb2008).

2-4-5 Current PSA Standards:

All the previous techniques using PSA derivatives can decrease the number of biopsies, but at the cost of missing clinically significant cancer. In practice, it is unusual to see PSA greater than 1.5 ng/mL in a healthy man of any age.

Remember also that not all cancers produce PSA, and that 20% to 40% of men with clinically significant cancer will have normal PSA. Biopsy is indicated when there is an obvious suspicious nodule at palpation or ultrasound, even if PSA is normal. Although PSA and its variants remain the best serum test for prostate cancer detection, interventional guidance, and therapeutic monitoring, controversy surrounds “normal” values, test characteristics such as sensitivity and specificity, and PSA’s value in screening for prostate cancer (Carroll2009). Previously, 4.0 and more currently 2.5 ng/mL was taken as the upper limit of normal, especially regarding the need for biopsy. Most “normal” men at any age have PSA less than about 1.5 ng/mL (Loeb2008). Remember that PSA is not a dichotomous “yes/no” or “positive/negative” test, but rather provides a continuous index of risk for prostate cancer (Price, 2001). There is no level below which cancer is not found, not even at levels less than 0.5 ng/ mL. Higher levels imply higher risk of cancer, especially aggressive cancer (Carroll2009). A normal PSA should not prevent proceeding to biopsy if the DRE or ultrasound findings are suspicious for cancer. The screening tools are PSA and digital rectal examination (Meyer1998) and (Neal2000).

Prostate cancer is seen in men over 50 years of age and on average takes about 10 years to cause death. At these ages, there are many competing causes for mortality. Therefore, most recommendations suggest annual screening with DRE and PSA between ages 50 to 75 years, and also suggest

that screening be performed only in reasonably healthy men who have an expected life span of 10 years.

2-5 Sonographic Appearance Gray-Scale US of prostatic cancer and benign prostatic hyperplasia

The classic appearance is that of a hypo echoic nodule in the peripheral zone that cannot be attributed to benign causes typically located in the peripheral zone and abutting the capsule. The sensitivity of this finding is similar to cancer detection by DRE, PSA, and MRI. CT cannot detect cancer until there is gross glandular distortion by extensive tumor growth. The sonographic appearance of prostate cancer has been debated extensively. Early investigators incorrectly thought that most prostate cancers were hyper echoic (Lee1985). Others subsequently confirmed that a significant portion of peripheral zone cancers are hypo echoic to some extent (Engelbrecht2000) and (Dahnert1986). Also, hypo echoic lesions tended to have more aggressive appearances than is echogenic lesions. Further research suggests that echogenicity varies with the presence of tumor glands with enlarged Lumina, as well as residual prostatic glands and stroma. Hyper echoic cancer has been described but occurs infrequently. With large cancers, the appearance may be caused by a desmoplastic response of the surrounding glandular tissue to the presence of the tumor or to infiltration of neoplasm into a BPH background with preexisting degenerative calcifications (Hasegawa1994). Uncommon histological types of cancer, including the cribriform pattern and comedo necrosis with focal calcifications, can be echogenic (Dahnert1986) and (Rifkin1990). A few extensive cancers have a hyper echoic appearance, probably as a result of the infiltration of the neoplasm into background of BPH. Biopsy of hyper echoic lesions with sonographic guidance is the only way to prove that the lesion seen represents a neoplasm. When the tumor replaces the entire peripheral zone, it often is less echogenic than the inner gland, which is a reversal of the normal sonographic relation (Hamper1990).

When the entire gland is replaced with tumor, on a BPH background, the gland may be diffusely inhomogeneous. Only about 50% of hypo echoic areas are cancer. Other benign causes of hypo echoic areas seen in the prostate include normal internal sphincter muscle, hyperplasia, prostatitis, cysts, hematoma, vessels, benign glandular ectasia, and cysts. Fortunately, 70% of prostate cancers arise in the homogeneous peripheral zone, which also has a fairly homogeneous ultrasound texture against which cancer is easier to detect. About 20% are in the transition zone, where prostate cancers are very difficult to find against the heterogeneous and variably vascular background of hyperplasia (Pallwein2008).

The ultrasound findings of benign prostatic hyperplasia: there is an increase prostatic volume with calculated volume exceeding 30ml ($\text{width} \times \text{height} \times \text{length} \times 0.52$), the central gland is enlarge and is hypo echoic or of mixed echogenicity, calcification may be seen both within the enlarge gland as well as in the pseudo capsule (representing compressed peripheral zone) and post-micturition residual volume is typically evaluated.

2-6 Other Imaging Techniques

2-6-1Magnetic resonance imaging:

Is an increasingly useful technique to evaluate the prostate to detect and stage cancer. Its accuracy in tumor detection, sizing, and staging are improving with use of end rectal and pelvic coils, contrast agents, and specialized sequences. The main pitfalls to use of MRI are availability, cost, time, and intolerance of the end rectal coil. Biopsy equipment has been adapted for use with MRI.

2-6-2Computed tomography:

Scan plays no role in primary tumor detection or local staging, but it helps with detection of lymph adenopathy and distant metastases. CT is of great value in radiotherapy planning and confirming seed placement with brachytherapy.

2-6-3 Radionuclide bone scans:

play no role in primary tumor detection or local staging but they are the mainstay for detecting bone metastases in men with skeletal symptoms or PSA greater than 10 ng/mL.¹

2-6 Ultrasound appearance of normal prostate:

By using a trans rectal scanning, the seminal vesicles are paired, relatively hypo echoic multi septated structures cephalad to the base of the prostate. The anterior urethra and it is surrounded smooth muscle and glandular area appears relatively hypo echoic and can be quite prominent measured 2cm in diameter. Because the sphincter is muscular, it frequency is very hypo echoic especially in young man. Often Corpora amylacea seen as an echogenic foci. Typically, the peripheral zone is more uniform in texture and slightly more echogenic than the transitional zone. The peripheral zone echogenicity is the standard for echogenicity in the prostate and is define to be isochenic. Echogenicity in other areas of the gland is compared to that of the peripheral zone.⁽²⁾

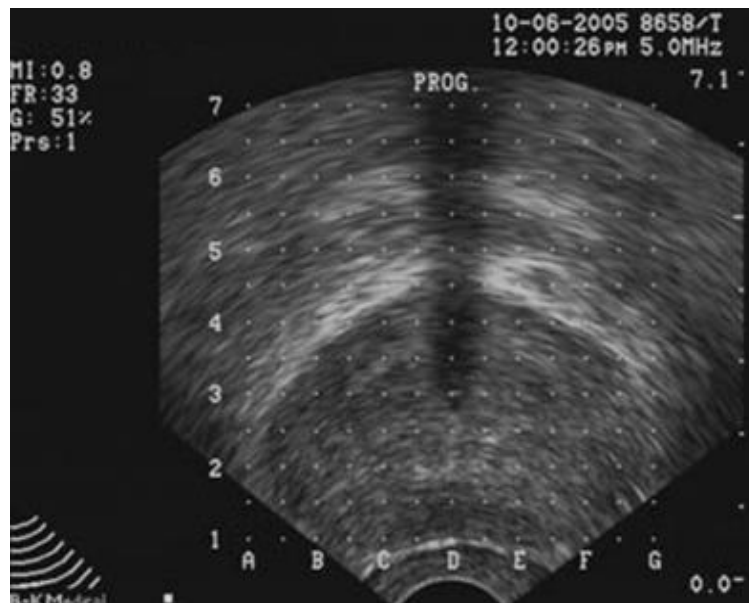


Figure (2.11) Shows a trans rectal ultrasound image of normal prostate(Ayala AG,1989)

2-7 Previous Study

Study done by J. Strax in which he concluded that measurement of a man's prostate-specific antigen, or PSA, level is currently the most commonly used test for early detection of prostate cancer. Yet researchers question the test's adequacy as a cancer-screening tool since studies show that it may detect tumors that would never require treatment while, at the same time, fails to find some aggressive cancers.

A study done by Dr. Ruth Etzioni provides conclusive evidence that a variation of the test that relies on two types of PSA measurements could improve the test's accuracy for men with borderline-normal total PSA levels. Although the benefit of this approach was modest, the researchers concluded that its use could translate into a significant reduction in medical costs and complications for this group of men by eliminating unnecessary biopsies to confirm the PSA test results.

Study appears in the October issue of *Cancer Epidemiology, Biomarkers and Prevention*. Co-authors include Seth Falcon and Dr. Charles Koppaerberg of the Public Health Sciences Division and colleagues at the University of Washington and at the Harvard School of Public Health.

The researchers conducted the study in order to resolve a controversy over whether analyzing a man's free PSA level — the amount of PSA protein that is not bound to other proteins in the blood serum — in conjunction with his total PSA level provides any benefit for accurate early cancer detection. Although this combination test has become popular in recent years.

Study done by Xavier Filella, Juan Alcover, Rafael Molina, Alfredo Rodríguez, Pablo Carretero, Antonio Manuel Ballesta. They conclude that free PSA may be a useful marker for the diagnosis of prostate cancer.

Study appears in 2007 in *AL-ZAEIM AL-AZHARI UNIVERSITY*, which done by Amer Awad Ahmed Elhaj.

Trans abdominal ultrasound scanning done for patients with enlarged prostate for measuring their prostate dimensions and volume.

Study resulted that; Ultrasound is a good diagnostic tool in diagnosis of prostate pathologies and there is a significant proportional relation between patient age and prostate gland size and thus the prostate gland size is apparently increased with increasing age.

Study appears in 2009 in SUDAN UNIVERESITY, which done by Babiker Abdelwahab Awad.

Transabdominal ultrasound scanning done for patients with enlarged prostate for measuring their prostate dimentions and volume.

Study resulted that;Ultrasound and free PSA are more accurate than total PSA in diagnosis of prostatic enlargement .

Study done by Kattak et, al state that evaluation of prostate with the help of ultrasound is safe, reliable, reducible, and easy to perform. It gives good assessment of gross pathology of urinary tract.

Study resulted that:Ultrasound is agood diagnostic tool in diagnosis of prostate pathologies.

Study done by Martha K. Terris in 1999 .They concluded that the Trans rectal appearances of squamous cell carcinoma involved the prostate is an irregular, anterior, relatively hyper echoic appearance.

Study resulted that:Ultrasound is good tool for differentiation between benign prostatic hyperplasia and prostate cancer.

Chapter Three

Materials and Methods

Chapter Three

Materials and Methods

3.1 Materials:

Equipment used:

(A) An ultrasound machines of facilities as shown in the following table:

U/S machine name	Aloka	General Electric
Model	SSD 500	LOGIQ 5
Movement	Portable	Mobile
Type of probe	Curvilinear	- Curvilinear - Linear - Transvaginal
Energy of probe	3.5 MHz	- 3.5 MHz - 10 MHz - 7.5 MHz

- All these machines have Printer with thermal paper.

(B) Sony printer with thermal paper.

(C) Computer for data analysis.

(B) TOSOH AIA 200 PACK UCPA design of following features:

Throughput of 200 tests/hour.

- 576 tips (6 tip racks).
- 2 substrate bottles.
- Walk away time approx. 4 hours.
- 960 tests (48 trays) can be loaded at any time.
- 3 incubators.
- 2 sampling arms.



Figure (3.1). Shows TOSOH machine which used in measurement of tPSA and
fPSA

(C) Computer for data analysis.

3.2 Design of the study:

This study was across sectional descriptive study which aimed to evaluate the role of ultrasound and free PSA in differentiation between BPH and Prostate cancer.

3.3 Population of the study:

The population of this study were patients of age above forty years, with BPH or prostate cancer. Patients of age under forty years, with normal prostate or had other prostatic complications were excluded.

3.4 Sample size and type:

This study consisted of 50 patients 30 patients had BPH while other 20 patients had prostate cancer.

Firstly ultrasound scanning was done for patients to evaluate AP diameter, transverse, thickness, volume shape and echo-texture of the prostate. Then tPSA and fPSA were done to all patients, finally histopathology was done for all patients.

3.5 Place and duration of the study:

This study was carried out in the period from November 2016 to February 2017 in Khartoum state at College of Radiologic Sciences (Sudan University for science and Technology) and ElRibat Teaching hospital.

3. Technique used:

PSA screening test:

Since the amount of PSA in the blood is very low, detection of it requires a very sensitive type of technology (monoclonal antibody technique), which it is a part of Enzyme – Linked immunosorbent technique, which used in this study.

In this study blood samples was taken from the patients and the serum was separated by using centrifuge, then frozen it, and finally measured the total PSA and free PSA by using AIA-PACK UCPA design.

• Enzyme-linked immunosorbent assay (ELISA):

Enzyme immunoassays combine the specificity of antibodies with the sensitivity of simple spectrophotometric enzyme assays by using antibodies or antigens coupled to an easily assayed enzyme that also possesses a high turnover number.

ELISA method require the preparation of a calibration curve during the assay. In the double-antibody method for ELISA. The unknown antigen solution is reacted with specific antibody attached to a solid phase, washed and treated with enzyme-labeled antibody (directed against a different epitope), if monoclonal antibodies are being used). After a further wash the enzyme substrate is added. The amount of enzyme activity measured under standard condition is directly proportional to the amount of antigen present.

An advantage of this method is that only one procedure is required to couple the enzyme to all antibody preparations.

Amplification immunoassays have already been developed for hormones, pathogenic viruses and bacteria, and tumor markers.

Under standard condition the enzyme activity measured is a proportional to the amount of specific antigen in the original solution.

Trans abdominal U/S scanning:

(A) Patient Preparations:

The bladder must be full enough, gives patient 4 to 5 glasses of fluid and examined after one hour. Do not allow the patient to micturate, alternatively fill the bladder through a urethral catheter with sterile normal saline, Stop when patient feels uncomfortable. Avoid catheterization if possible because of the risk of infection. Avoid over distention of the urinary bladder was critical because it is worse as an empty urinary bladder; such the prostate is difficult to localize in this situation. If the patient cannot retain urine give his Lasix (20 mg/ I V or tabs). This procedure is restricted to patient without any cardiac problem

(B) Position of the patient:

The patient should lie supine but may need to be rotated obliquely. The patient should be relaxed, lying comfortably and breathing quietly, lubricates the lower abdomen with coupling agent. Hair anywhere on the abdomen will trap air bubbles so apply coupling agent generously.

(C) Choice of transducer:

Uses a curve linear probe of 3.5 MHZ frequency. ⁽⁴⁹⁾

Scanning technique:

Start with a transverse scans from the symphysis pubis up wards to the umbilicus and we must be angle the probe sharply down word until the prostate appears symmetrical in the center of the screen. Adjusted the gain of the image and freeze it, here I measured the AP diameter and width of the prostate from one side to another. Evaluate the prostate shape, if it is normal or abnormal; also evaluate the prostate texture, which divided into five sections:

(A) Normal texture.

- (B) Below normal with or without calcifications (Hypo echoic).
- (C) Above normal (Hyper echoic).
- (D) Mixed (Heterogeneous).
- (E) Above normal (Dense) with nodule.

Any area appears abnormal must be viewed in several projections then rock slide. Then scans in a longitudinal plane “parallel to mid sagittal plane of the body” and measured the thickness (Cephalocaudal diameter) of prostate, scanning just from above symphysis pubis with gradual caudal angulations of the probe until the prostate appears in the center of the image. Freeze the image on split screen after adjusted the gain and measure the thickness (cephalocaudal diameter) of the prostate from upper edge to lower one. Then I calculate the volume of the prostate by using the prolate ellipsoid formula Known as Ellipsoid method;

$$V = AP \cdot TH \cdot T \cdot c$$

Where **V** represent Volume. **AP** represents the anteroposterior diameter of the prostate and **TH** represents the thickness of prostate. **T** represents the width or transverse diameter of the prostate, and **c** represents a constant approximately **(0,532)**

The same formula is used to measure the bladder volume and bladder post void residual volume.

Then the researcher use ultrasound findings score which graded from one to seven degrees to evaluate the maximum and minimum score for prostatic carcinoma, in this score any ultrasound finding was gave degree as demonstrating in following table:-

Table (3.1).Which demonstrates ultrasound findings score

Variables	Scores			Total
	0	1	2	
Volume	< 30ml	>30 ml		
Shape	Normal	Abnormal		
Transverse diameter	<anteroposterior	>anteroposterior		
Calcification	Not present	Present		
Presence of nodule	Not present	Present		
Texture	Homogeneous	Heterogeneous	Dense and heterogeneous	

Finally complete the abdomen pelvic examination by the scanning remainder abdominal organs mainly urinary bladder and kidneys to detect any associated pathologies.

Ultrasonographic sonograms took place and information of the patient is collected by using special data collecting sheet.

3.7 Methods of data collection:

Using a special data collection sheet (questionnaire), a random sample of 50

patients were studied, the data collecting sheet was designed to cover the assessment of prostate AP diameter, transverse diameter, thickness of prostate , volume, shape and echo-texture of prostate, total PSA , free PSA and Histopathology results.

3.8 Data Analysis:

The data analyzed using SPSS program. The data was coded and analyzed using statistical computed analysis in form of frequencies and corsstabulation tables. The results were obtained after the contents of data-collection sheets, were changed into numerical values for the purpose of the computer use.

These numerical values being symbolized, they again gave us true valuable results.

3.19 Ethical approval:

The ethical approval was granted from the hospital and the radiology department; which include commitment of no disclose of any information concerning the patient identification.

Chapter four

Results

Chapter four

Results

Table (4.1). Shows the age group with respect to histopathology results.

Age group	Total	Benign nodular hyperplasia	Percent age	Adenocarcinoma	Percent age	Total percentage
40 – 50	2	2	100%	0	0	100%
51 – 60	12	7	58.3%	5	41.7%	100%
61 – 70	15	9	60%	6	40%	100%
71 – 80	21	12	57.1%	9	42.9%	100%
Total	50	30	60%	20	40%	100%

Table (4.2) Shows occupation distribution

Occupation	Frequency	Percent
Farmer	36	72.0
Engineer	8	16.0
teacher	6	12.0
Total	50	100.0

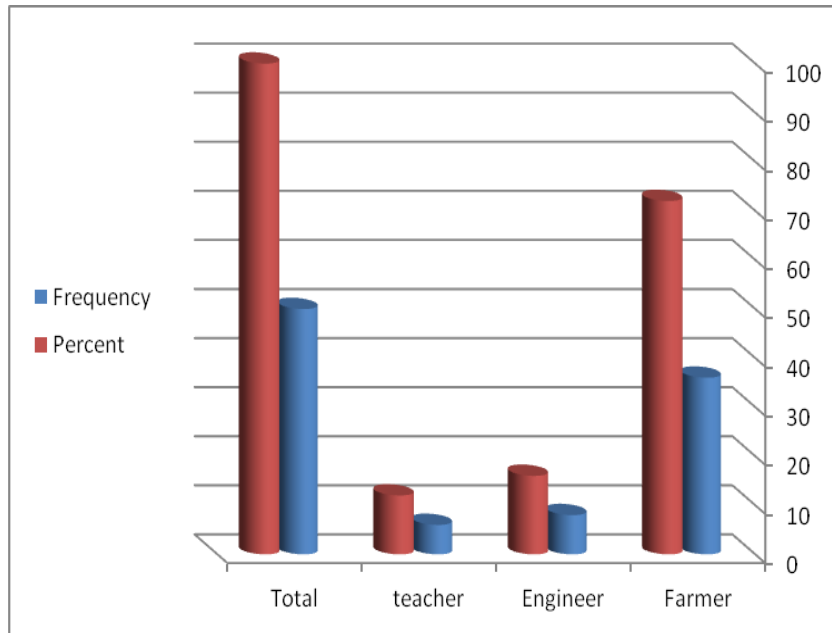
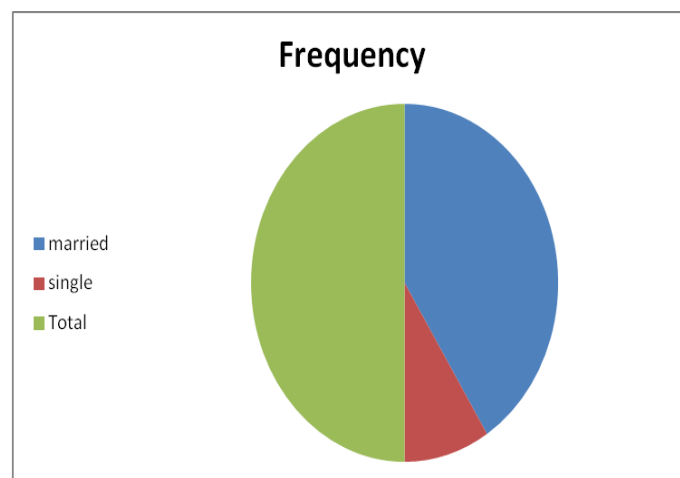


Figure (4.1) Shows occupation distribution

Table(4.3) Shows Marital status distribution

MS	Frequency	Percent
married	41	82.0
single	9	18.0
Total	50	100.0



figure(4.2)Shows Marital Status distribution

Table(4.4) Shows histopathology result frequency

Prostate volume	No of Pts	Total	Percentage
BPH	30	30	60%
Cancer	20	20	40%
Total	50	50	100%

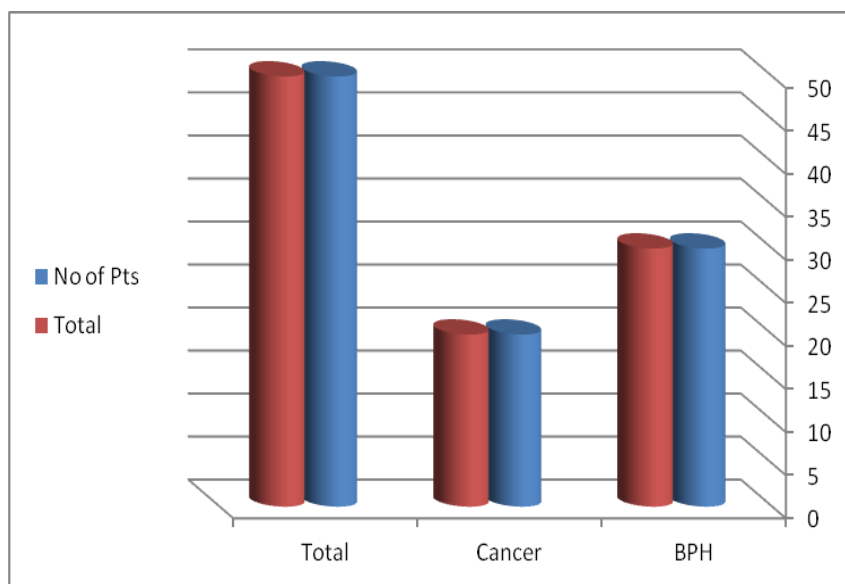


Figure (4.3) Shows histopathology result frequency

Table (4.5) Crosstabulation table that shows the frequency of histopathology results (BPH and adinocarcinoma) in relation to ultrasound findings in prostate size

Prostate volume	Hypotrophy	Hypertrophy	Total	Percentage
BPH	0	30	30	60%
Cancer	1	19	20	40%
Total	1	49	50	100%

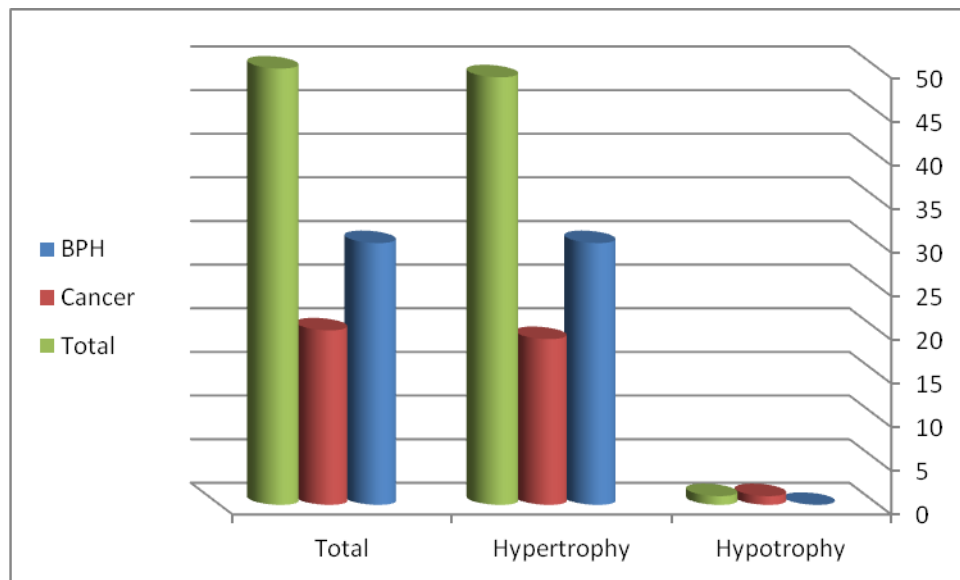


Figure (4.4) shows the frequency of histopathology results (BPH and adinocarcinoma) in relation to ultrasound findings in prostate size

Table (4.6) Crosstabulation table that shows the frequency of histopathology results (BPH and adinocarcinoma) in relation to ultrasound findings in prostate shape (normal and abnormal).

Shape	Normal	Abnormal	Total	Percentage
BPH	30	0	30	60%
Cancer	2	18	20	40%
Total	22	18	50	100%

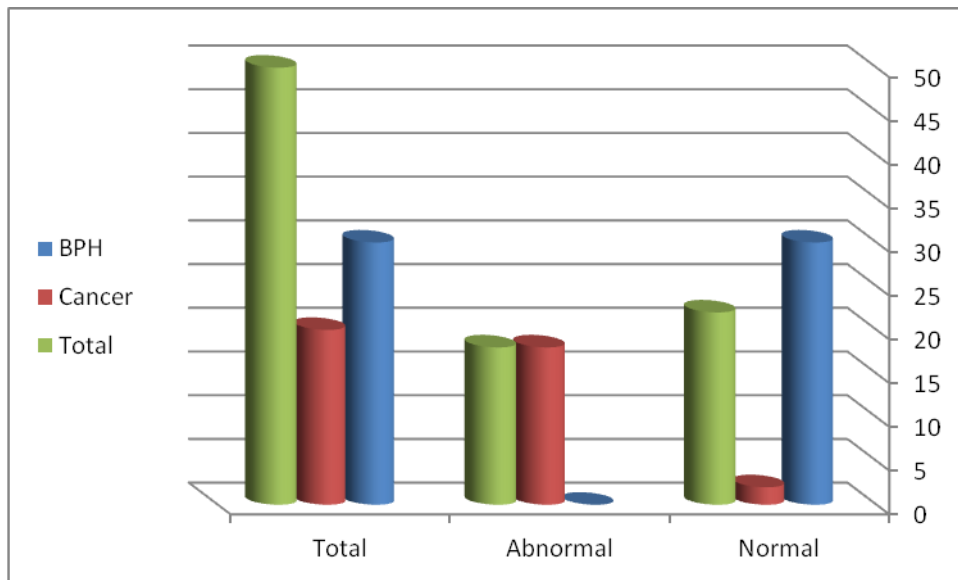


Figure (4.5) shows the frequency of histopathology results(BPH and adinocarcinoma) in relation to ultrasound findings in prostate shape (normal and abnormal).

Table (4.7) Crosstabulation table that shows the frequency of histopathology results (BPH and adenocarcinoma) in relation to presence of calcification

Calcification	Histopathology		Total
	Benign	Malignant	
Found	19	15	34
Not found	11	5	16
Total	30	20	50

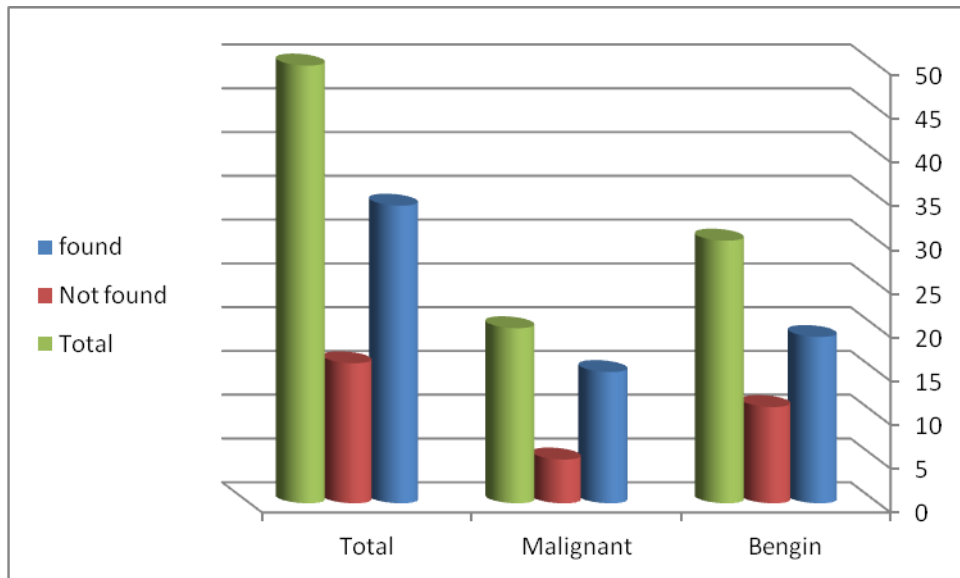


Figure (4.6) shows the frequency of histopathology results(BPH and adenocarcinoma) in relation to presence of calcification

Table (4.8) Crosstabulation table that shows the frequency of histopathology results (BPH and adenocarcinoma) in relation to presence of mass

Mass	Histopathology		Total
	Benign	Malignant	
Found	0	19	19
Not found	30	1	31
Total	30	20	50

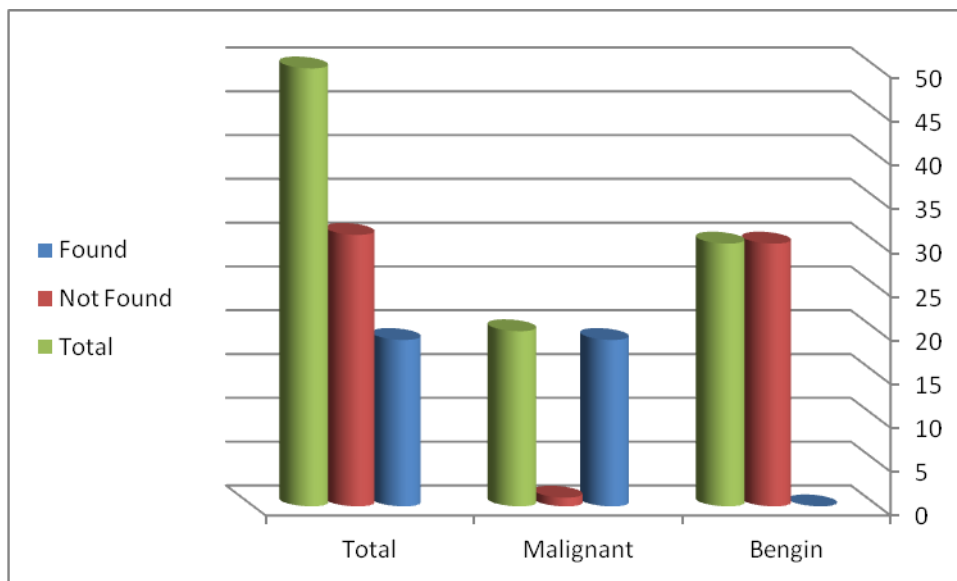


Figure (4.7) shows the frequency of histopathology results (BPH and adenocarcinoma) in relation to presence of mass

Table (4.9) Crosstabulation table that shows the frequency of histopathology results (BPH and adenocarcinoma) in relation to site of mass.

Site of Mass	Histopathology		Total
	Benign	Malignant	
Not Found	30	0	30
Peripheral	0	20	20
Total	30	20	50

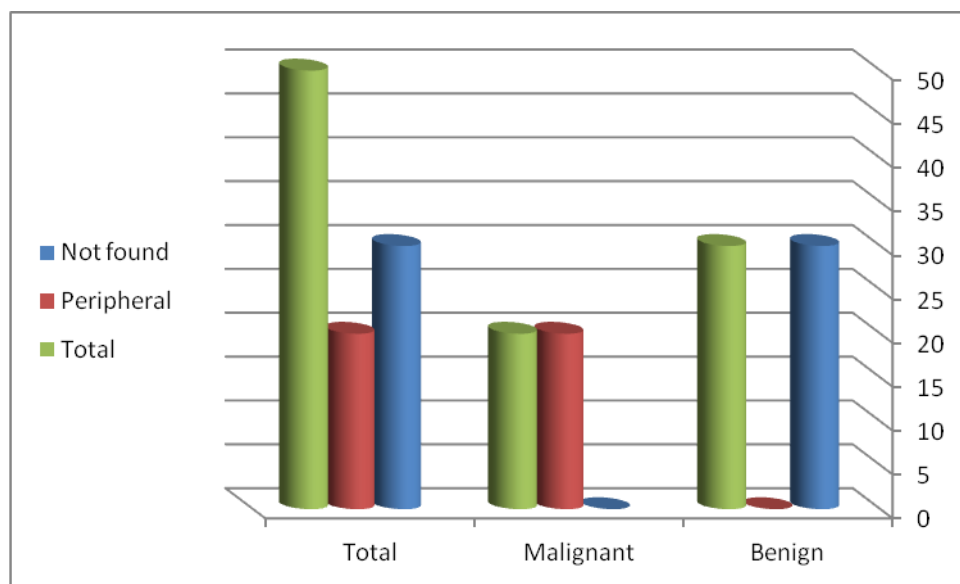


Figure (4.8) shows the frequency of histopathology results (BPH and adenocarcinoma) in relation to site of mass

Table (4.10). Crosstabulation table that shows the frequency of histopathology results (BPH and adinocarcinoma) in relation to ultrasound findings in prostate texture (Homogeneous, Heterogeneous and Dense with heterogeneity).

Texture	Regular	Heterogeneous	Dense and Heterogeneous	Total	Percentage
BPH	30	0	0	30	60%
Cancer	0	19	1	20	40%
Total	30	19	1	50	100%

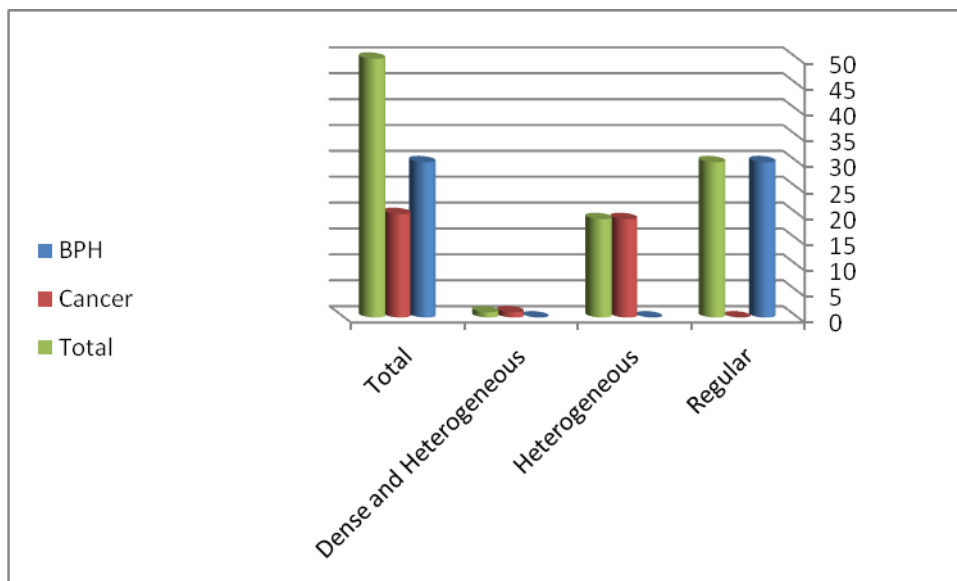


Figure (4.9) shows the frequency of histopathology results (BPH and adinocarcinoma) in relation to ultrasound findings in prostate texture (Homogeneous, Heterogeneous and Dense with heterogeneity).

Table (4.11). Cross tabulation table that shows the frequency of histopathology results (BPH and adenocarcinoma) in relation to prostate diameters (Transverse > Anteroposterior and Anteroposterior > Transverse).

Diameter	Trans <AP	AP>Trans	Total	Percentage
BPH	29	1	30	60%
Cancer	1	19	20	40%
Total	30	20	50	100%

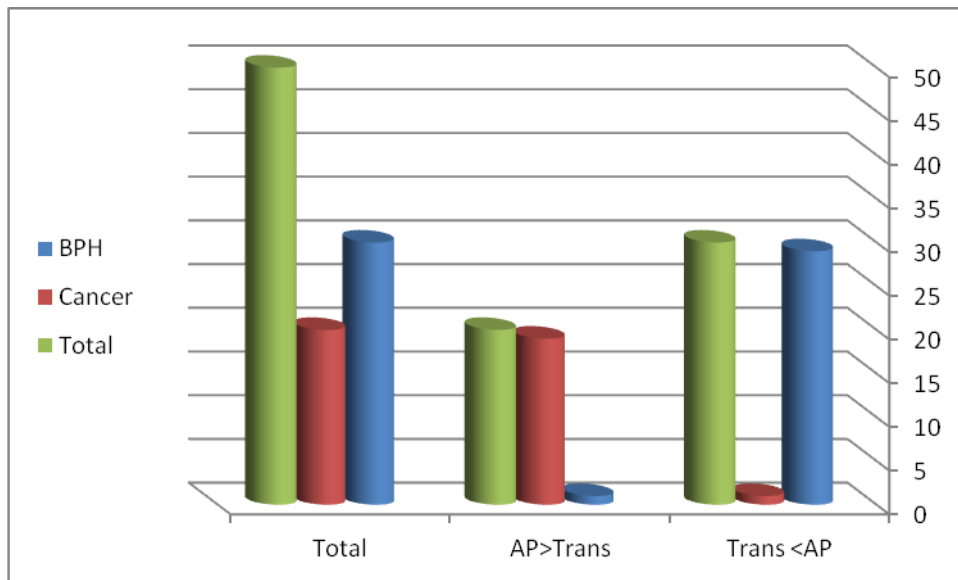


Figure (4.10) shows the frequency of histopathology results (BPH and adenocarcinoma) in relation to prostate diameters (Transverse > Anteroposterior and Anteroposterior > Transverse).

Table (4.12) of the Total PSA value in patients under study

TPSA (ng/ml)	BPH	%	Cancer	%
<2	0	0%	0	0%
2-4	0	0%	0	0%
4-10	18	36%	0	0%
10-25	8	16%	4	8%
25-50	2	4%	0	0%
50-100	2	4%	2	4%
>100	0	0%	14	28%
TOTAL	30	60%	20	40%



Table (4.13). Cross tabulation table that shows the frequency of histopathology results (BPH and adenocarcinoma) in relation to fPSA/tPSA.

fPSA/tPSA	<25%	>25%	Total	Percentage
BPH	0	30	30	60%
Cancer	20	0	20	40%
Total	20	30	50	100%

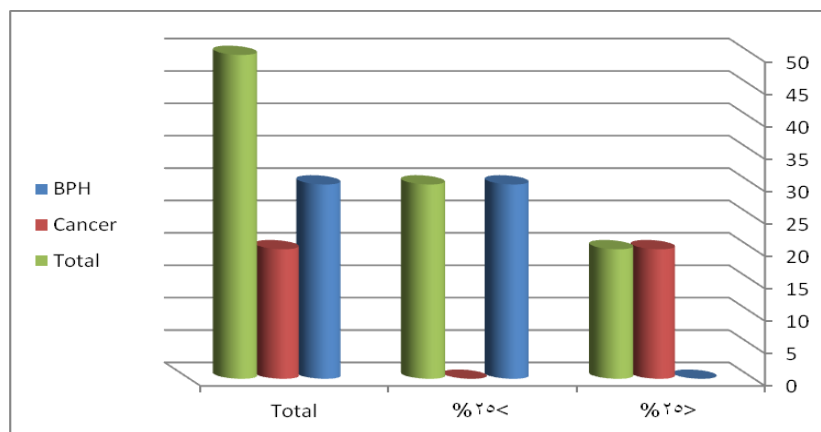


Figure (4.11). Shows the frequency of histopathology results (BPH and adenocarcinoma) in relation to fPSA/tPSA.

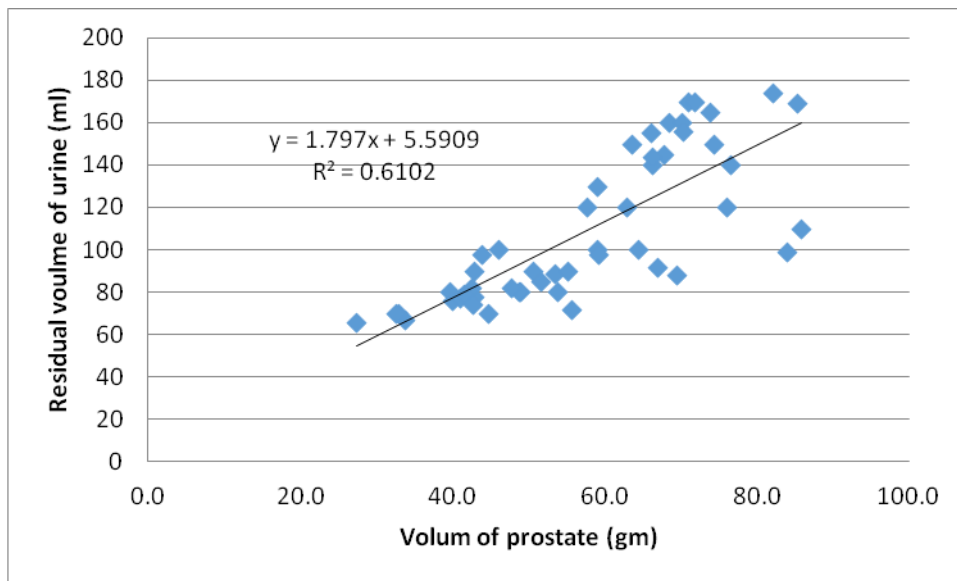


Figure (4.12). shows the correlation between prostatic volume and residual urine.

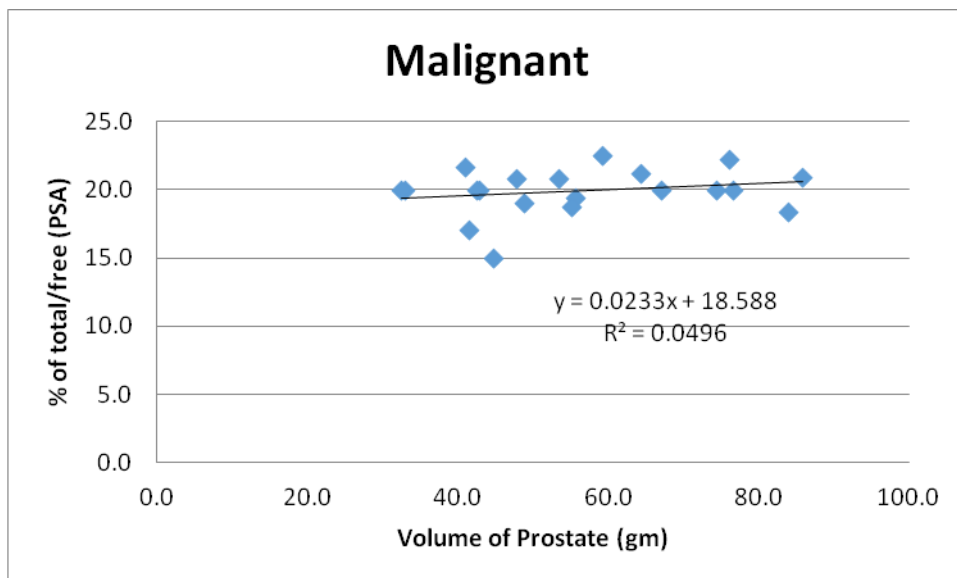


Figure (4.13). shows the correlation between prostatic volume and fPSA/tPSA in malignant cases.

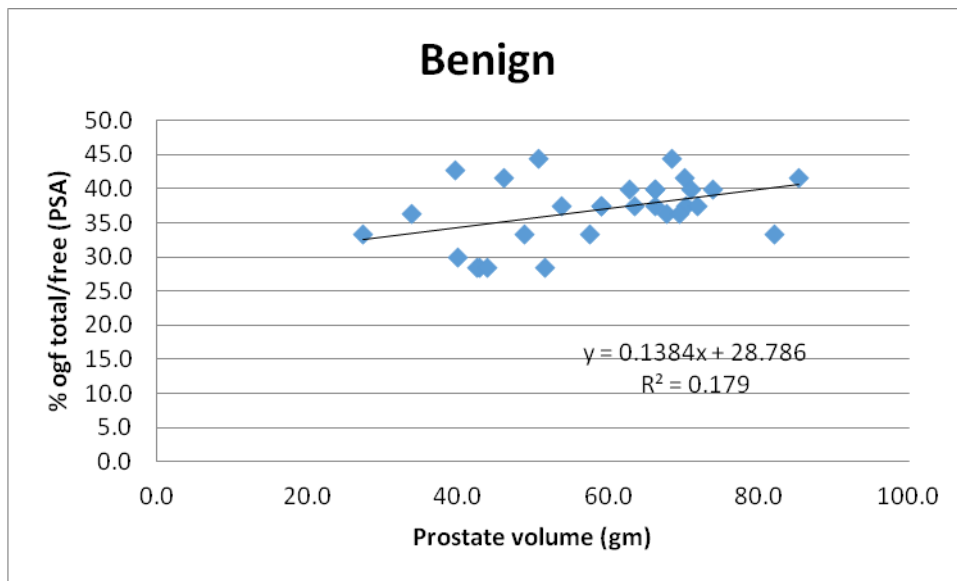


Figure (4.14). Shows the correlation between prostatic volume and fPSA/tPSA in benign prostatic hyperplasia cases.

Table (4-14) Statistical table of u/s ,fpsa ,tpsa ,Age

Descriptive Statistics

	N	Minimu m	Maximu m	Mean	Std. Deviation
Age	50	43	77	57.94	9.561
AP Diameter	50	4.0	6.6	5.154	.6466
Transverse Diameter	50	3.8	6.1	5.060	.5222
Volume	50	27.4	85.8	57.54	15.1460
Residual Volume	50	66	174	109.0	34.841
Total PSA	50	6	80	23.16	20.507
Free PSA	50	2	17	5.58	3.648

Table(4-15) Statitital table of U/S in result group

Group Statistics

	Histopathology	N	Mean	Std. Deviation	Std. Error Mean	p-value
AP Diameter	Benign	30	5.457	.5722	.1045	0.001
	Malignant	20	4.700	.4657	.1041	0.001
Transverse Diameter	Benign	30	4.883	.4579	.0836	0.002
	Malignant	20	5.325	.5098	.1140	0.002
Volume	Benign	30	58.379	14.4145	2.6317	0.63
	Malignant	20	56.298	16.4846	3.6861	0.63

Chapter Five

Discussion, Conclusion & Recommendation

Chapter Five

Discussion, Conclusion & Recommendation

5.1 Discussion

A total of 50 patients were selected randomly, concerning age group table (4.1), the incidence of prostatic disorders distributed in age group 61-71years (as expected), therefore the increasing of age is a risk factor for prostatic disorders, including BPH and Prostatic cancer. Table (4.2) showed that 36 patients (72%) out of 50 cases were farmer; this might indicates that there is a relation between farmer and prostatic disorders. In patients under this study the author observed that most cases of prostatic cancers were found in patients who married, this indicate that, sexual activity might be a factor that influenced prostatic disorders, Show that distribution in table (4.3). Table (4.4) shows distribution of samples results comprises the following, 30patients (60%) of cases were benign prostatic hyperplasia, 20 patients (40%) prostatic cancer. Table (4.5) shows hypertrophy 30patients of BPH, 19patients of prostatic cancer and show hypotrophy in 1patient of prostatic cancer, not found hypotrophy in patients of BPH.

Concerning table (4-14), the mean age of prostatic disorders group is 57.94 years.

The statistical analysis could be used to show the error involved in the procedure used and hence to predict which of them is more reliable. Statistical analysis detect the error of mean of AP diameter, transverse diameter and volume of prostate in case of benign prostatic hyperplasia (0.10, 0.08, 2.6) respectively. In addition the error of mean of tPSA and fPSA is (0.3 and 0.16) respectively, therefore U/S and fPSA have low percentage of error and could be used effectively.

Also statistical analysis showed that the error of mean for AP, transverse, volume of prostate, tPSA and fPSA values in prostate cancer, as follow (0,10,

0.11, 3.6, 3.8, 0.8) respectively. Therefore according to U/S findings and fPSA have low error , and could be used as accurate diagnostic method. In agreement to studies reported by Ruth, Seth, et;al , Amer , G Sperandeo, et; al , and Kattak, et; al. (1992)

Tables (4-6,4-7, and 4-8) showed that there were 32 patients (64%) out of 50 cases have normal shape,30 patients(60%) of them have benign prostatic hyperplasia, 2patients (2%) have cancer. and, 34patients (68%) out of 50were have presence of calcification . No any mass in31 patients (62%) and 19cases (38%) have masses. Table (4-9) shows 20 patients (40%) of prostatic cancers were have peripheral masses, the author observed that all cases of cancers have peripheral site. In Table (4-8, 4-9 and 4-10), which show the relations between the U/S findings in prostate texture and masses. There were 30patients (40%) of BPH have regular and homogenous echo texture, 19 patients out of20patients have prostatic cancers them have irregular and heterogeneous echo texture. This means that incase of enlarge prostate with texture change notice in ultrasound scanning this is increase probability of cancer ,as well as no change of prostate texture is increase the probability of BPH. Similar results were achieved by Kattak et, al , G Spermaneo, et; al , Martha K and James F, et; al (2000)

In Table (4-11) there were29 patients (96.6%) out of 30 cases of BPH their anteroposterior diameter is greater than transverse diameter and 1patient was anteroposterior diameter less than transverse diameter .19patients (95%) outof20patientstheir transverse diameter greater than anteroposterior diameter and 1patient the transverse diameter less than anteroposterior diameter. All these mean that; The ultrasound features of benign nodular hyperplasia are enlarged prostate with normal shape and usually with homogeneous texture, While the ultrasound features of prostate cancer are enlarged prostate, there may be changing in shape, but usually there is changed texture. Similar results were achieved by James F, et;al and Martha K(2000).

Table (4-12) show the evaluate of the total PSA in benign prostatic hyperplasia and prostatic cancer, observed the increasing total PSA in benign and malignant lesions.

The usage ratio of FPSA/TPSA as a tool for prostate cancer screening, in table (4-13) observed the increasing FPSA/TPSA ratio decreasing the probability of cancer, decreasing FPSA/TPSA increasing the probability of cancer.

Although PSA is the most useful tumor marker for the early detection of the prostatic lesions but the calculation of FPSA/TPSA ratio is more accurate than measurement of TPSA alone for prediction of prostate cancer. This result matched with previous studies enrolled in literature review achieved by Babiker, (2009)

5-2 Conclusion:

This study was proved its hypothesis that; the tPSA is not reliable and accurate in diagnosis of prostate disorders and differentiates between Prostatic carcinoma, BPH and Inflammation of prostate.

U/S scanning is a good diagnostic tool for diagnosis of prostatic disorders and more accurate than tPSA in showing enlargement of the prostate and prediction of prostate cancer.

The U/S features of BPH that; the volume of prostate is more than 30 cm³ diffusely hypo echoic, it is AP diameter is greater than transverse diameter, of normal shape and not usually seen nodule, but there may be multiple calcifications

Features of U/S in prostate cancer are usually are abnormal texture (heterogeneous) with presence of nodule, which may be present in central or peripheral of prostate , the transverse diameters is greater than AP diameter (are usually suggestive of growth changes). Other cases may be appears as hypertrophied and have a dense texture with nodule or not also the transverse diameter is greater than AP diameter.

None of these three tools (U/S scanning, tPSA and fPSA) is accurate (100%) alone in differentiated between prostate carcinoma and BPH, but U/S scanning is very preferable in prediction of prostate disorders in general because it can give the volume of prostate and it's dimensions. (Accuracy 79%), simple, cheap, save, and valuable.

Free PSA/tPSA ratio is more accurate than tPSA alone in differentiation between prostate carcinoma and BPH.

When the tPSA is more than 10ng/ml, fPSA is more than 2ng/ml and it is ratio to tPSA is less than 1/4 that increased the probability of cancer. While when the fPSA is less than 2ng/ml, or greater than this value and it is ratio to tPSA is equal 1/4 or more increased the probability of BPH.

The Ca prostate increases the binding PSA with α - anti chemo-trypsin protein, while the BPH increase the fPSA in blood.

The age and sexual activity are a risk factors for prostate disorders.

In this study, it is found that, there were a large number of farmers patients, this might indicate that there was a relation between Farmers and prostate disorders.

5-3 Recommendation:

Elder male i.e. (50 years or greater) and those who have high sexual activity are advised to do U/S scanning routinely to exclude the presence of prostatic disease or not, because U/S is cheap, safety and reliable than tPSA.

The study recommends that the Government should introduce the transrectal ultrasound machines and increase the training institutes of ultrasound for increasing the sonologists skills and experiences

If there is indication of Ca prostate by U/S scanning, the patient must be investigate for fPSA, tPSA and the fPSA/tPSA ratio should be calculated, if it is also give an indication of cancer, then the histopathology will be done for confirmation only, if it is not available, no need of it for giving the patient the treatment, because the prediction of U/S and fPSA/tPSA tools together is very high.

The study recommended that the government should be increase the specialist hospitals for urology diseases because they increased in Sudanese now a days.

The histopathology is not usually available, and it is very expensive. According to its high values in diagnosis of CA prostate and differentiated between it and BPH, study advised the ministry of health and private laboratories to indorsing it, until it is becomes available to any patient.

According to the high cost of scientific research which the researcher was faced, the government should appeal universities in Sudan and companies to support the researchers in order to improve plans of treating and management of such diseases.

Further studies should be carried out in this field on many aspects such as increasing the number of patients, to show the relation between prostate disorders and infertility, comparing between the role of U/S scanning and other diagnostic tools, using a transrectal ultra sonographic approach and color Doppler ultrasonography.

References:

- Agamemnon D. Stefan S. 2003 Color Atlas of Physiology edition. Printed in Germany by: Appl Druck GmbH & Co. KG, Wemding, Germany. Hieme Stuttgart · New York
- Andrea G. Rockall ... [et al.]. 2013 Diagnostic imaging. — Edition published by A. Rockall, A. Hatrick, P. Armstrong, M. Wastie... Library of Congress Cataloging-in-Publication Data.
- Andrew T. G, 2013. Atlas Of Ultrasound – Guided Regional Anesthesia. Edition. Saunders, an imprint of Elsevier Inc. ISBN: 978-
- Armstrong, M. Wastie. 2013. Diagnostic Imaging. Editions
- Arthur C. Guyton. Jackson, M. 2006 Textbook of Medical Physiology. International Edition. Elsevier Inc. Library of Congress Cataloging-in-Publication Data,
- Asim K. Frank A Chervenak. 2006. Donald School Textbook of Ultrasound in Obstetrics and Gynecology. This edition published in the Taylor & Francis e-Library.
- Betty B. T, 2007. Pocket protocol for ultrasound scanning. Edition Saunders, an imprint of Elsevier Inc.
- Carol M. Rumack, [et al.] 2011 Diagnostic Ultrasound, Edition
- Carol M. Rumack, Stephanie R. Wilson, J. William Charboneau, Deborah Levine, 2011, Diagnostic ultrasound 4th, Elsevier Churchill Livingstone.
- D.A. Christensen, Ultrasound Bioinstrumentation, John Wiley and Sons, New York, 1988.
- Edward F. Goljan, 2010. Rapid Review Series Pathology. Edition. Philadelphia, PA: 19103-2899 by Mosby. Inc an affiliate of Elsevier Inc
- Farideh J, and Janice Mc Currie. 2008 Clinical Physiology and Pharmacology the Essentials. John Wiley & Son, Ltd. Printed and bound in Singapore by Markono Pte. Ltd.

Haim A. 2010 Basics of Biomedical Ultrasound for Engineers. John Wiley & Sons, Inc., Hoboken, New Jersey, United States of America Published simultaneously in Canada.

Harald Lutz, Elisabetta Buscarini. Manual of Diagnostic Ultrasound. Vol. Edition World Health Organization 2011 Printed in Malta by Gutenberg Press Ltd.

Harsh M. 2010 Textbook Of Pathology. Edition. Published by Jitendar P Vij Jaypee Brothers Medical Publishers, India.

Jan T, Radu B, Christoph F. 2013 Dietrich Student Edition. EFSUMB – European Course Book. Ultrasound of the liver 04.10.201306:59

Kyung W, Harold M. Chung. 2012 Gross Anatomy, Edition. Lippincott Williams & Wilkins, a Wolters Kluwer business. Philadelphia,

Peter H. Kevin M. Abigail T. 2010. Diagnostic Ultrasound Physics and Equipment. Edition. Cambridge University Press, New York.

Richard s .Snell, 2012, clinical anatomy by region, Wolters Kluwer

Richard Snell. 2012. Clinical Anatomy by Regions. 9th edition. Lippincott Williams & Wilkins, a Wolters Kluwer business.

Sandra L.tlagen-Ansert.Text book of diagnostic ultrasound seven edision

Stephanie R. Michelle M. Stephen E. 2007 Anatomy for Diagnostic Imaging. Edition. British Library Cataloguin g in Publication Data.

Stephen G. 2007. Clinical Physiology Made Ridiculously Simple. Publisher: Medmaster; 2007 edition (January 1, 2007).

Steven M. Penny, 2011, Examination review for ultrasound abdomin and obstetrics and gynecology, 1ed' Wolters Kluwer.

Sumeet B and Satish K B. 2013 Differential Diagnosis in Ultrasound. Edition. Jaypee Brothers Medical Publishers.

Susan Standring. 2008 Gray's Anatomy. Edition. Elsevier Inc. Printed in Spain

Trish Chudleigh, Basky Thilaganathan, 2004, Obstetric Ultrasound How,
Why and When, Elsevier Churchill Livingstone
Ultrasound teaching manual Matthias Hofer,MD with the collaboration of
Tatijana Reihls MD

Appendices

Appendices (A) Ultrasound images of BPH and prostate cancer

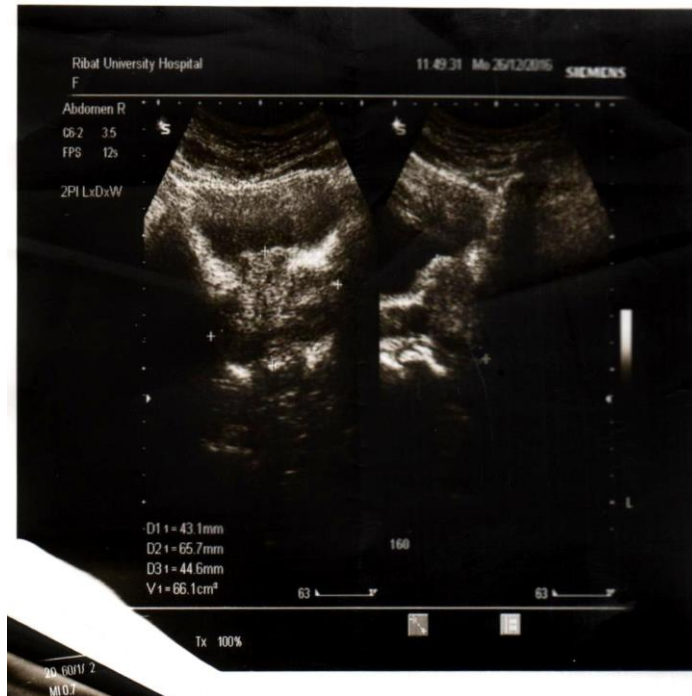

Image no(1)benign prostatic hyperplasia Patient age:70year occupation: farmer

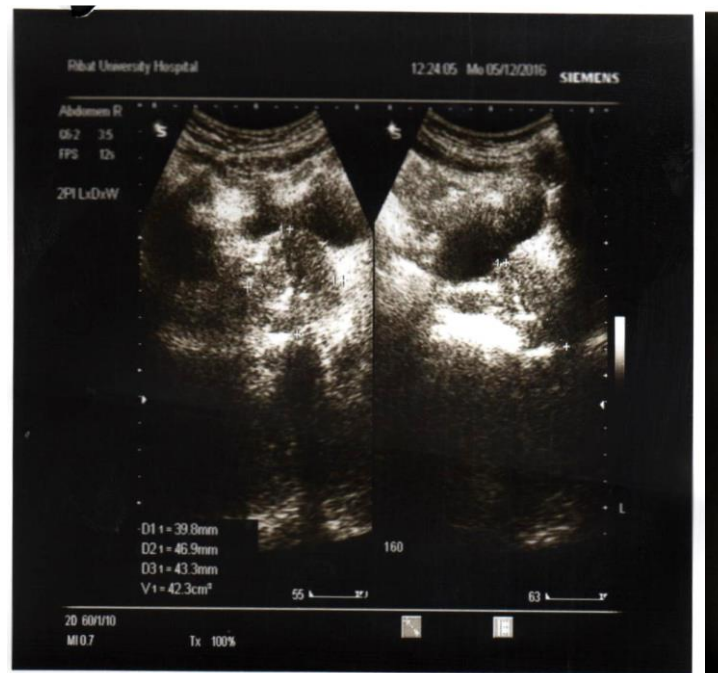

Image no(2) benign prostatic hyperplasia Patient age:65year occupation: farmer

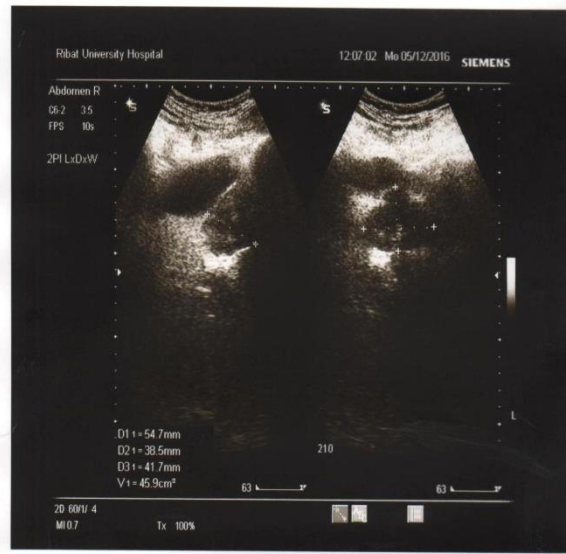

Image no(3) benign prostatic hyperplasia Patient age:58years occupation: teacher

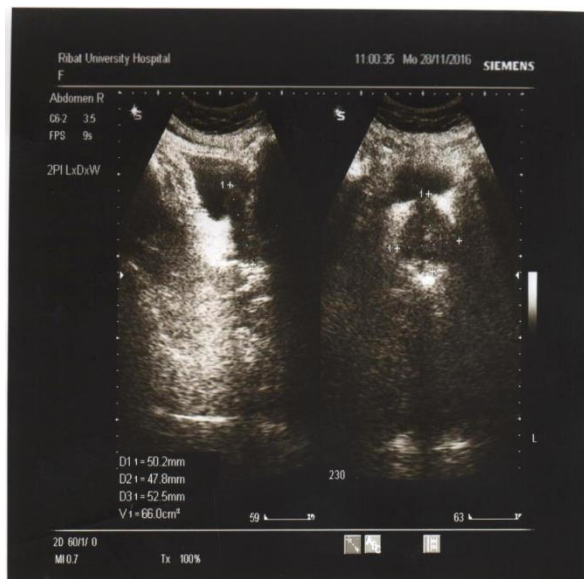

Image no(4) benign prostatic hyperplasia Patient age:62years occupation:farmer

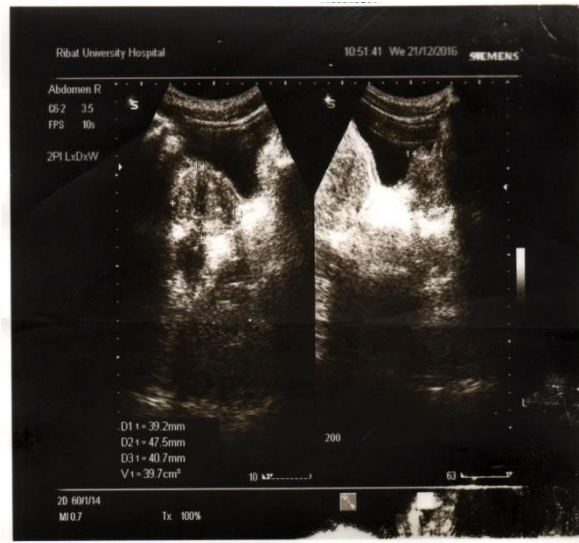
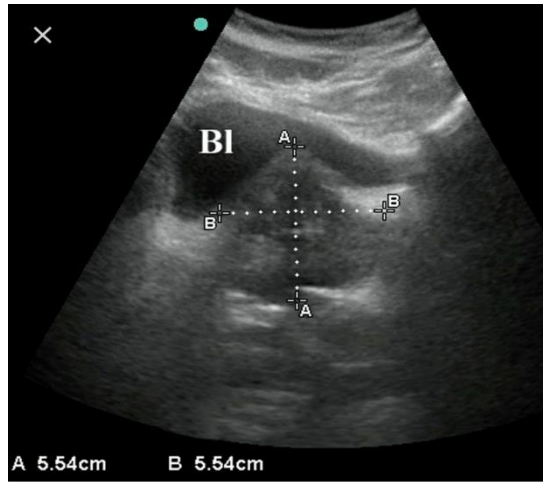


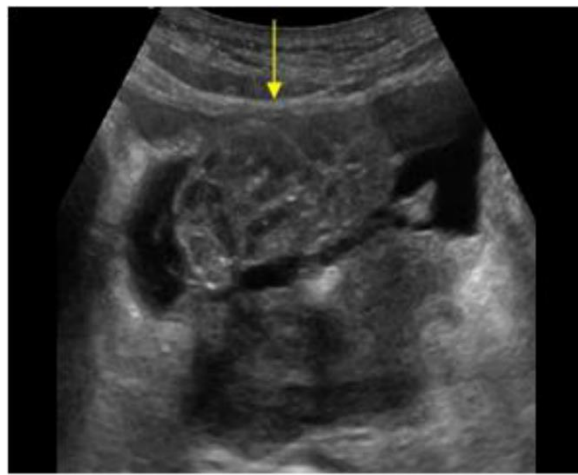
Image no (5) benign prostatic hyperplasia Patient age: 74 years occupation: Engineer

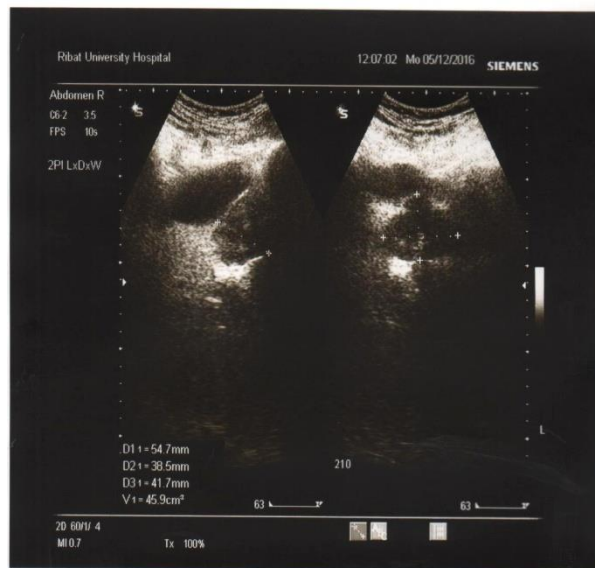

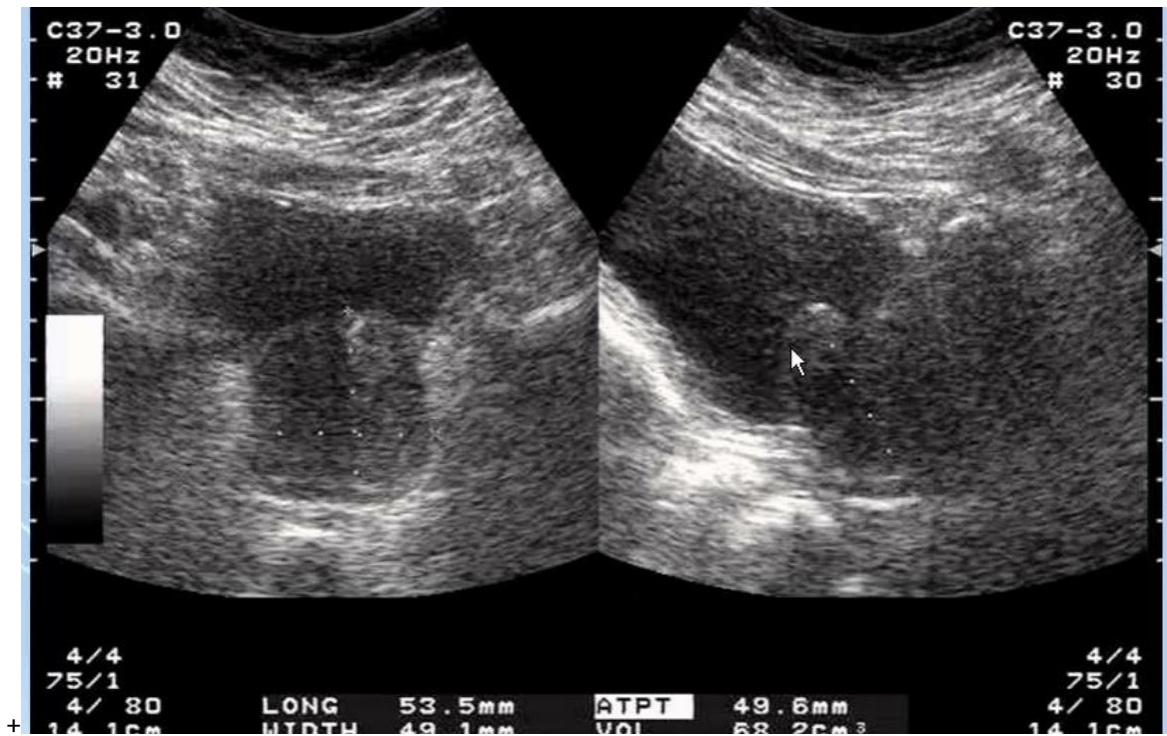
Image no(6) benign prostatic hyperplasia Patient age:71years occupation: farmer



Image(7) Prostate Cancer Patient age:57year occupation:teacher



Image(8) Prostate Cancer Patient age:61year occupation: farmer



Image(9) Prostate Cancer Patient age:51year occupation: farmer

Appendices (B) data sheet

Sudan University of Science and Technology.

College of Post graduate Studies

Ultrasound screening of prostate gland in Sudanese elderly men

Date:.....

Age :.....

Marital Status:

Married ()

Number of years ()

Fertile () Number of children ()

Single ()

- Residence:.....

- Occupation:.....

C/o

1. Dysurea () Frequency of urine at night () Drip ling ()

2. Referred by Doctor: ()

Ultrasound Findings:

(A) General findings;

- Shape changes Yes () No ()

- Echo texture changes Yes () No ()

- AP Diameter () cm

- Transverse diameter () cm

- Thickness of the prostate () cm

(B) Specific Findings:

- Echotexture: eg. Nodules Yes () No ()

- Volume () cm³

(C) Presence of Lymph nodes

Found () not found ()

(D) Others:

- Presence of Prostatic mass Yes () No ()

Solid () Cyst ()

- Presence of Calcification Found () not found ()

- Site:.....

- P. V. R Volume () mls

Data collection sheet (Laboratory Findings)

- Name:
- Date:
- PSA:
- Free PSA:

- **Histopathology:**

Done ()

Not done ()