

**Sudan University of Science and Technology  
College of Graduate Studies**

**Role of Laminin -5 as Marker of Malignant  
Transformation in Colorectal Polyps**

**دور الالامينين موسما للتحويل السرطاني للحميات القولون والمستقيم  
الحميده**

**A dissertation submitted for partial fulfillment of the requirements of  
the degree of M.Sc in medical laboratory sciences (histopathology  
and cytology)**

**By:**

Amna Wad Abosalih Mohammed Hammed

B.Sc (Honor) in medical laboratory sciences (histopathology and  
cytology)

(Shendi University 2010)

**Supervisor:**

Dr. Abu Elgasim Abass Awad Elkareem

2016

بِسْمِ اللَّهِ الرَّحْمَنِ الرَّحِيمِ

قال تعالى :

((وَأَسْأَلُكَ رَبُّكَ فَتَرْضَى ﴿٥﴾ أَلَمْ يَجِدْكَ يَتِيمًا فَآوَى ﴿٦﴾ وَوَجَدَكَ ضَالًّا فَهَدَى ﴿٧﴾))

سورة الضحى الآية 5-7

## **Dedication**

I dedicate my dissertation work to my family

To my love mother

To my father and to my brothers

I dedicate to my sister who have never left my side and are very special

I dedicate this work and give special thanks to my best friends Ohood,  
Hadeel, Mashier, Esraand Eman

## **Acknowledgment**

Firstly I would like to thank Allah for give me the knowledge, strength and support to complete this dissertation.

I would like to thank the supervisor Dr. Abu Elgasim Abass Awad Elkareem for his perfect supervision, advice, encouragement, support and guidance from the early stage of this research as well as giving me opportunities of experiences throughout the project.

I would like to thank Nada Salih the senior of histopathology and cytology department in the radiation and isotopes center Khartoum for her help.

I would like to thanks Amal Hassan my colleague in histopathology department in the national public health laboratory for her great help.

Finally I want to thank all the staff of Sudan University of science and technology, college of medical laboratory sciences and everyone helped me even with words.

## **Abstract**

This is a hospital based descriptive retrospective case study conducted in national public health laboratory during the period from July 2016 to October 2016, the study aimed to detect the role of laminin 5 in invasiveness in colorectal polyps.

A total of 40 formalin fixed paraffin blocks previously diagnosed as colorectal polyps, 14(35.0%) samples were juvenile polyps, 14(35.0%) samples were adenomas polyps and 12(30.0%) samples were hyper plastic polyps were selected for this study. One section of three microns was cut from each block and stained by immunohistochemical method (avidin biotin technique) for laminin 5 detection. The data obtained was analyzed using SPSS computer program version 20.

The patient ages ranged between 3-80 years with mean age 43 years, most of patients 22(55.0%) were above 50 years and the remaining 18(45.0%) were less than 50 years.

Regarding gender patient sex revealed that 11(27.5%) patients were female and 29(72.5%) patients were male.

Positive expression of laminin-5 among study samples were 16/40 samples, distributed as follow in adenomas polyps 7/14 samples, juvenile polyps 7/14 samples and in hyper plastic polyps 2/12 samples, while negative expression of laminin-5 among study samples is 24/40 samples, the most negative expression of laminin-5 was seen in hyper plastic polyps account 10/12, adenomas polyps account 7/14 samples and juvenile polyps 5/14 samples with significant correlation between Laminin-5 and polyps types (P. value 0.047).

The study revealed there is role of laminin -5 as marker for malignant transformation in colorectal polyps and laminin 5 expression is associated with adenomatous polyps and juvenile polyps; they are more common pre-cancerous lesions of colorectal cancer.

## ملخص البحث

اجريت هذه الدراسة التراجعية الوصفية في المعمل القومي للصحة العامة خلال الفترة من يوليو 2016 إلى اكتوبر 2016 لدراسة دور اللامينين في الكشف عن غزو الاورام الحميدة للقولون والمستقيم.

اختيرت اربعون قالب شمعي لهذه الدراسة مغمورة في البرافين تم تشخيصها مسبقا كعينات أورام حميدة للقولون والمستقيم. قطعت القوالب بسمك ثلاثة مايكرون وصبغت بطريقة الكشف النسيجي الكيميائي المناعي باستخدام تقنية البايوتين افيدين. وحلت البيانات التي تم الحصول عليها باستخدام برنامج الحزمة الاحصائية للعلوم الاجتماعية إصدار 20. تراوحت أعمار المرضى بين 3-80 سنة مع متوسط عمر 43 عاما، ومعظم أعمار المرضى تتركز فوق 50 عاما 22 (55.0%) والباقي 18 (45.0%) أعمارهم كانت أقل من 50 عاما. كان جنس المرضى 11 (27.5%) منهم إناث و 29 (72.5%) منهم ذكور.

اشتمل تشخيص المرضى علي الأورام الحميدة للاحداث 14 (35.0%) عينة والأورام اللحمية تمثل 14 (35.0%) عينة وأورام التنسج المفرط تمثل 12 (30.0%) عينة.

ظهر التعبير الإيجابي للامينين وسط مجتمع الدراسة في 16 عينة من مجمل 40 عينة بينما كان التعبير الايجابي اكثر شيوعا في الاورام الحميدة للاحداث 7 عينات من مجمل 14 عينة والاورام الحميدة اللحمية 7 عينات من مجمل 14 عينة و 2 عينة من مجمل 12 عينة في عينات اورام فرط التنسج الحميدة وظهر التعبير السلبي للامينين وسط مجتمع الدراسة في 24 عينة من مجمل 40 عينة, اكثر شيوعا للتعبير السلبي يوجد في 10 عينات من مجمل 12 عينة من اورام فرط التنسج الحميدة وفي 7 عينات من مجمل 14 عينة من الاورام اللحمية الحميدة و 5 عينات من مجمل 14 عينة من الاورام الحميدة للاحداث مع وجود علاقة بين اللامينين و أنواع الاورام الحميدة للقولون والمستقيم (القيمة الاحتمالية تساوي 0.047).

وخلصت الدراسة الى أن اللامينين يمثل دور مهم في عملية التنبؤ بغزو محتمل في البوليبيات الحميدة للقولون والمستقيم بواسطة الخلايا السرطانية والى ايجابيه اللامينين مشتركه بين الاورام الغدية واللحمية للاحداث فهي تمثل الانواع الاكثر شيوعا في الاورام ما قبل السرطانية في سرطان القولون والمستقيم.

### List of Abbreviations

CT	Computed tomography
CRCs	Colorectal cancers
DAB	3,3- diaminobenzidene tetra hydrochloride
DNA	Deoxyribonucleic acid
DPX	Distyrene plasticizer xylene
FAP	Familial adenomatous polyposis
HNPCC	Hereditary non polyposis colon cancer
HPP	Hyperplastic polyposis
MAP	MUTYH-associated polyposis
MRI	Magnetic resonance imaging
MUC	Mucin
PJS	Peutz-Jeghers syndrome
PCR	Polymerase chain reaction
PET	Positron emission tomography
SPSS	Statistical package for social sciences
CK	Cytokeratin
US	Ultrasound
UV	Ultra violet

## List of Contents

Subject	Page
الآية	I
Dedication	II
Acknowledgement	III
Abstract (English)	IV
Abstract (Arabic)	VI
List of abbreviations	VII
List of contents	IX
List of tables	X
List of photographs	XI
<b>Chapter One</b>	
<b>Introduction</b>	
1.1 Introduction	1
1.2 Objectives	3
<b>Chapter Two</b>	
<b>Literature Review</b>	
2.1. Scientific back ground	4
2.2. Anatomy and physiology of colon and rectum	4
2.3. Abnormalities of colon and rectum	5
2.3.1. Inflammation of colon and rectum	5
2.3.2. Precancerous of colon and rectum	5
2.3.3. Malignant lesions of colon and rectum	5
2.3.3.1. Adenocarcinoma	6
2.3.3.2. Carcinoid tumors and neuroendocrine tumors	6
2.3.3.3. Other colorectal cancer	6
2.3.3.3.1 Leiomyosarcoma	6
2.3.3.3.2 Lymphoma	6
2.3.3.3.3 Melanoma	7
2.4. Signs and symptoms of colorectal cancer	7
2.5. Risk factors of colorectal cancer	7
2.6. Diagnosis of colorectal cancer	7
2.6.1 Colonoscopy	8
2.6.2 Barium enema	9
2.6.2. Imaging techniques	9
2.6.3.1 Computed tomography (CT) and ultrasound (US)	9
2.6.3.2 Magnetic resonance imaging (MRI)	9
2.6.3.3 Positron emission tomography (PET) scan	9
2.6.4 Fecal occult blood test	9
2.7.3. Immunohistochemistry	9
2.7.4. Tumor marker	9



2.7.4.1 Laminin-5	9
2.8. Staging of colorectal cancer	10
2.9. Management of colorectal cancer	10
<b>Chapter Three Materials and Methods</b>	
3.1. Materials	12
3.2. Methods	12
3.2.1. Study design	12
3.2.2. Study samples	12
3.2.3. Sample processing	12
3.2.4. Staining method	12
3.2.5. Result interpretation	13
3.2.6. Statistical analysis	13
3.2.7. Ethical considerations	13
<b>Chapter Four Results</b>	
4. Results	14
<b>Chapter Five Discussion</b>	
5. Discussion	22
<b>Chapter Six Conclusion and Recommendation</b>	
6.1 Conclusion	24
6.2 Recommendations	24
References	25
Appendices	32

### List of Abbreviations

CT	Computed tomography
CRCs	Colorectal cancers
DAB	3,3- diaminobenzidine tetra hydrochloride
DNA	Deoxyribonucleic acid
DPX	Distyrene plasticizer xylene
FAP	Familial adenomatous polyposis
HNPCC	Hereditary non polyposis colon cancer
HPP	Hyperplastic polyposis
MAP	MUTYH-associated polyposis
MRI	Magnetic resonance imaging
MUC	Mucin
PJS	Peutz-Jeghers syndrome
PCR	Polymerase chain reaction
PET	Positron emission tomography
SPSS	Statistical package for social sciences
CK	Cytokeratin
US	Ultrasound
UV	Ultra violet

## List of Tables

<b>No</b>	<b>Table</b>	<b>Page</b>
4.1	Distribution of histopathological diagnosis among study population.	15
4.2	Distribution of age groups among study population.	16
4.3	Distribution of sex among study population.	17
4.4	Expression of laminin among study population	18
4.5	Relation between laminin 5 expression and histopathological diagnosis.	19

### List of Photograph

<b>No</b>	<b>Photograph</b>	<b>Page</b>
1.4	Adenomatous of colorectal polyp shows positive cytoplasmic expression of laminin5 (40x).	20
4.2	Hyperplastic of colorectal polyp shows negative cytoplasmic expression of laminin5 (40x).	21

## Chapter One

### Introduction

#### 1.1 Introduction:

Colorectal cancer is cancer of colon and rectum, also known as bowel cancer, colon cancer or rectal cancer (Maka, *et al.* 2013).

The type of colorectal cancer includes adenocarcinoma, carcinoid tumor, gastrointestinal stromal tumor, lymphoma, leiomyosarcoma, melanoma and squamous cell carcinoma (Vinay, *et al.* 2003).

Colorectal cancer is the third most common cancer worldwide and fourth most common cause of death (Labianca, 2010). It is the third most commonly diagnosed cancer in male and the second in female (Maka, *et al.* 2013).

Colorectal cancer in Sudan is less among young patient (<40 years old) % and highest incidence was identified in the age group 41–60 years (Mohamed, *et al.* 2015).

The risk factor of colorectal cancer divided to non-modified risk factor such as age, family history of colorectal cancer and adenomatous polyps and inherited genetic risk, environmental risk factors such as nutritional, physical activity, obesity, smoking and heavy alcohol consumption (Greg, 2000).

Diagnosis of colorectal cancer can be by varies ways include screening tests, colonoscopy, CT colonography, fecal occult blood test, double-contrast barium enema and genetic testing (Labianca, *et al.* 2010).

Treatment depends on many things, including the stage of the cancer; treatments may include surgery to remove the tumor, chemotherapy to kill cancer cells, radiation therapy to destroy cancerous tissue, targeted therapy to keep cancer from growing and spreading (Sebastian, 2014).

Laminins are high-molecular weight proteins of the extracellular matrix. They are a major component of the basal lamina, a protein network

foundation for most cells and organs. Required for morphogenesis, organizing cell adhesions and cell signaling (Domogatskaya, *et al.* 2012). There are actually many different types of laminins-5 at least twelve laminin-5 isoforms have been described, each of which may have a distinct, tissue-specific biological role for example laminins are mostly involved in the interaction between cells and the extracellular matrix. Yet, laminin-1 appears to primarily affect epithelial cells, while laminin-2 can act on muscle and nerve cells, and laminins 5, 8 and 10 are present within blood vessels (Jun, 2009).

Laminin-5 marker used as immunohistochemical markers in prognostic tumor pathology, helpful in determine invasiveness and metastasis of colorectal cancer, were assessed for expression of laminin-5 by immunohistochemistry and they reported that Ten polyps stained positive and the number of polyps expressing the laminin-5 increased significantly as the phenotype of the adenomas became more atypical one of the 15 hyperplastic polyps, two of the 16 tubular adenomas (12.5%), and six of the 24 adenomas with a villous component (25%) were positive. Two of 12 (17%) serrated adenomas, regarded as a distinct form of colorectal neoplasia, showed expression (Lenander, 2003).

## **1.2 Objectives:**

### **1.2.1 General objective:**

To study the role of laminin -5 as marker of potential invasiveness in colorectal polyps.

### **1.2.2 Specific objectives:**

- 1- To detect the expression of laminin-5 in colorectal polyps using immunohistochemical method.
- 2- To correlate the expression of laminin-5 with different types of colorectal polyps.

## **Chapter Two**

### **Literature Review**

#### **2. Literature Review:**

##### **2.1 Scientific background:**

Colorectal cancer is cancer that starts in the colon or rectum. Most colorectal cancers are adenocarcinomas; colorectal cancer often begins as a growth called a polyp, which may form on the inner wall of the colon or rectum (Vinay, *et al.* 2003).

Colorectal carcinoma (CRC) is the third most prevalence cancer in world (Rama, *et al.* 2015). More than million new patients diagnosed annually over half of all patients diagnosed with colorectal cancer above 70 years (Tom, 2012).

##### **2.2 Anatomy and physiology of colon and rectum:**

The large intestine or large bowel is divided into colon and rectum. Its total length varies but is approximately 5 to 6 feet, the large bowel has segments that are both intraperitoneal and extraperitoneal, the cecum, transverse colon and most of the sigmoid colon are intraperitoneal segments, the ascending colon, both the hepatic and splenic flexures, the proximal and distal sigmoid colon have their posterior surface in the retroperitoneum (Miguel, *et al.* 2003).

The colon has the same four layers that are present in most parts of gastrointestinal tract the mucosa, submucosa, muscularis propria, and serosa. The mucosa is the inner lining of the colon and rectum. It is made up of a thin layer of epithelial layer, a layer of connective tissue and a thin layer of muscle the submucosa is a layer of connective tissue that surrounds the mucosa. It contains mucous glands, blood vessels, lymph vessels and nerves, the muscularis propria lies outside the submucosa. It is a thick layer of muscle, it has an inner ring of circular muscle fibers and an outer ring of long muscle fibers that surround the wall of the colon



and rectum and the serosa is the outer layer of the colon. It is not found on most of the rectum (Gray and Lewis, 2000).

### **2.3 Abnormalities of colon and rectum:**

#### **2.3.1 Inflammation of colon and rectum:**

The two most common diseases are ulcerative colitis and Crohn's disease. Crohn's inflammation can occur anywhere in the digestive tract from the mouth to the anus. By contrast, ulcerative colitis only involves inflammation of the large intestine or colon (Vincenza, *et al.* 2013).

#### **2.3.2 Precancerous lesion of colon and rectum:**

Polyps are abnormal growths that stick out from the lining and can turn into cancer. They are classified into hyperplastic polyps and adenomatous polyps (Bond, 2000).

Colorectal adenomas are the almost precancerous lesion of colorectal cancer (Vincenza, *et al.* 2013). The adenomas include tubular, tubulovillous and villous (Bond, 2000).

#### **2.3.3 Malignant lesions of colon and rectum:**

##### **2.3.3.1 Adenocarcinomas**

The majority of colorectal cancers (CRCs) are classified as adenocarcinoma and account for about 90-95 percent of all colorectal cancers. Adenocarcinomas have two subtypes, mucinous and signet ring cell. The mucinous subtype comprises about 10-15 percent of adenocarcinomas while the signet ring cell subtype comprises less than 0.1 percent of adenocarcinomas (Niek, *et al.* 2015).

Younger patients, larger tumors, higher rates of lymph node metastasis, and peritoneal metastasis were correlated with mucinous adenocarcinoma histology when compared to non-mucinous adenocarcinoma histology (Numata, *et al.* 2012).

### **2.3.3.2 Carcinoid tumors and neuroendocrine tumors:**

This slow-growing cancer forms in the neuroendocrine cell in the lining of the gastrointestinal tract. These tumors account for just 1 % of all colorectal cancers, but half of all of the cancers found in the small intestine, the vast majority of lesions are asymptomatic and are found incidentally during endoscopy. The management of these lesions depends upon the size of the lesion, involvement of the muscularis, location, and presence of metastatic disease. Small lesions (1 cm) can often be treated locally, either endoscopically or transanally. However, larger lesions (> 2 cm) require a formal oncologic resection (Philip and Steven, 2006).

### **2.3.3.3 Other colorectal cancer:**

#### **2.3.3.3.1 Leiomyosarcoma:**

Leiomyosarcomas occur in the colon and rectum, true rectal leiomyosarcomas are rare and account for less than 0.1% of all malignant tumors of the rectum, leiomyosarcoma is characterized by malignant spindle cells with cigar shaped nuclei arranged in interweaving fascicles. They often have an increased amount of nuclear and cellular atypia, some degree of necrosis, and a high number of mitoses (Chattopadhyay, *et al.* 2008).

#### **2.3.3.3.2 Lymphoma:**

Primary colorectal lymphoma represents a rare minority among the colonic neoplasms. Early diagnosis is often difficult because of unspecific symptoms, with subsequent delays in diagnosis and management (Domenico, *et al.* 2014).

Lymphoma involving the colon and rectum is rare and can occur either as primary colorectal lymphoma or as a manifestation of systemic disease. Most patients with primary colorectal lymphoma present with abdominal pain, and obstruction is unusual (Quayle and Lowney, 2006).

#### **2.3.3.3.3 Melanoma:**

Primary anorectal melanoma is a rare disorder. About 1% of all carcinomas are melanomas, typically presenting in the fifth or sixth decade of life and predominantly in woman. Patients present themselves with local symptoms like rectal bleeding and a changed defecation pattern (Van, 2008).

#### **2.4 Signs and symptoms of colorectal cancer:**

Signs and symptoms of colon cancer tend not to be specific. In other words, the signs and symptoms can occur due to a number of different conditions (Robert, 2009).

The symptoms of bowel cancer can include change in normal bowel motion, such as diarrhea or constipation, rectal bleeding or blood in stools also include dark-colored stool change in bowel habits and change in stool consistency (Robert, 2009).

#### **2.5 Risk factor of colorectal cancer:**

##### **2.5.1 Family history:**

Colorectal carcinoma usually occurs in one of three patterns sporadic, inherited, or familial, sporadic disease is usually seen in 70% to 75% of cases. Approximately 20% to 25% of cases occur in patients who have other family members who have also colon cancer (Farin, 2005).

##### **2.5.2 Genetic alterations:**

Changes in certain genes increase the risk of colon cancer include hereditary non polyposis colon cancer (HNPCC), familial adenomatous polyposis (FAP), attenuated FAP, and MUTYH-associated polyposis (MAP), hamartomatous polyps are the primary lesions in peutz-Jeghers syndrome (PJS) and juvenile polyposis syndrome (JPS), finally, hyperplastic polyposis (HPP) (Jasperson, *et al.* 2010).

### **2.5.3 Colonic polyps**

Studies have shown that a history of colonic adenomatous polyps places a patient at an increased risk for developing colorectal cancer (Sandro, *et al.* 2016).

### **2.5.4 Dietary**

High meat intake and low consumption of vegetables, fruits and whole grains have been associated with increased risk of colorectal cancer (Sandro, *et al.* 2016).

### **2.5.5 Alcohol:**

High rates of alcohol consumption may also increase risk of CRC it is most strongly associated with risk. Although beer consumption has been associated with rectal cancer, the findings are weak and inconsistent for both colon cancer and precursor adenomas (Greg, 2000).

### **2.5.6 Smoking**

It is extremely harmful to the colon and rectum, evidence shows that 12% of colorectal cancer deaths are attributed to smoking the carcinogens found in tobacco increase cancer growth in the colon and rectum (Cosnes, 2004).

## **2.6 Diagnosis of colorectal cancer:**

### **2.6.1 Colonoscopy:**

It provides strong estimates of the predictive value of the various symptoms and signs of colorectal cancer (Robert, 2009).

A colonoscopy examines the whole length of the large bowel this is generally the most accurate test to examine the large bowel for cancer and polyps. It is still possible, however, that small polyps may be missed, especially if they are behind one of the many folds in the bowel or the bowel is not completely clear (Labianca, *et al.* 2010).

## **2.6.2 Barium enema:**

Barium enema is widely available and may be used to investigate patients with symptoms suggesting of CRC (Halligan, *et al.* 2013).

## **2.6.3 Imaging techniques:**

### **2.6.3.1 Computed tomography (CT) and ultrasound (US):**

Computed tomography (CT) and ultrasound (US) are in the majority of cases able to detect local and metastatic spread of malignancy. Increasingly, the requirement is for tumor staging and detection of tumor recurrence on follow-up (Saunders, 2002).

### **2.6.3.2 Magnetic resonance imaging (MRI):**

MR imaging of primary rectal tumors can be used to assess the tumor in terms of stage and depth of invasion (Harmeet, 2011).

### **2.6.3.3 Positron emission tomography (PET) scan:**

In a positron emission tomography (PET) scan a small amount of radioactive glucose is injected into the body. When scanned, cancer cells will appear brighter (Christina, *et al.* 2015).

## **2.6.4 Fecal occult blood test**

Colorectal cancer may also be detected on routine examination of fecal occult blood (Christina, *et al.* 2015).

## **2.6.5 Immunohistochemistry:**

Immunohistochemical stains were became more important in determining the origin and differentiation of gastrointestinal tract tumors use many marker for this aim such as Keratin 7, CK20, MUC1, MUC2 and MUC5AC (Wong and Chu, 2012).

## **2.6.6 Tumor marker:**

### **2.6.6.1 Laminin:**

Laminin is a heterotrimeric glycoprotein. This major component of the basement membrane of epithelium is composed of three chains  $\alpha$ 3,  $\beta$ 3, and  $\gamma$ 2. The  $\gamma$ 2 chain is specific to isoform laminin-332, also called

laminin-5. This protein interacts with at least two integrin receptors, expressed by epithelial cells  $\alpha3\beta1$  and  $\alpha6\beta4$  (Zuccari, *et al.* 2011). Laminin regulate many biological functions, including cell adhesion, migration, proliferation, differentiation and survival (Jun, *et al.* 2010)

Expression is increased during carcinogenesis and expression is upregulated during the progression of human colon cancer (Lenander, *et al.* 2003).

Previous study Lenander, *et al* were used laminin 5 to study the role of laminin -5 as marker of potential invasiveness in colorectal polyps they studied sixty seven polyps of different types (15 hyperplastic polyps, 12 serrated adenomas, 16 tubular adenomas, and 24 adenomas with a villous component) were assessed for expression of laminin 5 by immunohistochemistry and they reported that Ten polyps stained positive and the number of polyps expressing the laminin 5 increased significantly as the phenotype of the adenomas became more atypical one of the 15 hyperplastic polyps, two of the 16 tubular adenomas (12.5%), and six of the 24 adenomas with a villous component (25%) were positive. Two of 12 (17%) serrated adenomas, regarded as a distinct form of colorectal neoplasia, showed expression (Lenander, *et al.* 2003).

### **2.7. Staging of colorectal cancer:**

Stage is the strongest predictor of survival for patients with colorectal cancer and appropriate patient management (Carolyn and Frederick, 2004). The TNM staging system classifies the extent of cancer based on anatomical information about the size and extent; it is the most widely used staging system worldwide (Steward and Murray, 2013).

### **2.8 Management of colorectal cancer:**

Treatment options are dependent on the stage of the disease, the performance status of the patient and increasingly the molecular makeup of the tumor depending on the stage of CRC, recurrence rates, survival

times and management are different. In early-stage tumors (UICC stage I) radical hemicolectomy with lymph node resection without any additional treatment is appropriate. In low-risk carcinomas (pT1, G1-2, L0, and R0) local procedures such as endoscopic mucosal resection or a laparoscopic segment resection, tumors invading the serosa (T3) or spreading to local lymph nodes (N+) have a higher risk of recurrence, so adjuvant treatment is recommended (Sebastian, 2014).

## **Chapter Three**

### **Materials and Methods**

#### **3. Materials and Methods:**

##### **3.1 Materials:**

Archive tissue blocks previously diagnosed as colorectal polyps with different types were used in this study.

##### **3.2 Methods:**

###### **3.2.1 Study design:**

This is hospital based descriptive retrospective case study aimed to study the role of laminin -5 as marker of potential invasiveness in colorectal polyps.

###### **3.2.2 Study samples:**

Forty tissue formalin fixed paraffin blocks of colorectal polyps were obtained from tissues previously diagnosed as colorectal polyps at national public health laboratory during the period from July 2016 to October 2016. Patient identification data including age and sex was obtained from patient`s file.

###### **3.2.3 Sample processing:**

Section of 3 $\mu$  in thickness was obtained from each formalin fixed paraffin wax embedded tissue using rotary microtome, mounted into positively slides (Thermo) then dewaxed in oven.

###### **3.2.4 Staining Method:**

###### **3.2.4.1 Immunohistochemical staining:**

Paraffin sections were immunostained using avidin biotin technique. Sections were put in oven and cleared in two change of xylene for two minutes, then rehydrated through descending concentration of ethanol (100%, 90%, 70% and 50%) and water two minutes for each, then antigen retrieved by water path for forty minutes, then treated with 3% hydrogen peroxide and methanol solution for fifteen minutes, then



washed in phosphate buffer saline (pH7.4) for five minutes. Then treated with laminin 5 primary antibody for twenty minutes, then rinsed in phosphate buffer saline then binding of antibody detected by incubating for twenty minutes with biotin followed by fifteen minutes with strepto avidin (Thermo kit), then the sections were washed in three changes of phosphate buffer saline, then treated with substrate and 3,3-diaminobenzidene tetra hydrochloride (DAB) chromogen for seven minutes, then washed in phosphate buffer saline, then counterstained in Mayer's haematoxylin for one minute, then washed and blued in running tap water, then dehydrated through ascending concentration of ethanol (50%, 70%, 90%, 100%), then cleared in xylene and mounted in DPX mountant (Bancroft and Marilyn, 2008).

#### **3.2.5. Result interpretation:**

All quality control measures were adopted during sample staining for immunohistochemical results assessment. Positive and negative controls were used to confirm location of positivity of laminin 5 expression that was confirmed by five cells per field.

#### **3.2.6. Statistical analysis:**

Data were analyzed using SPSS version 20 computer program. Frequencies, means and Chi-square test were calculated.

#### **3.2.7. Ethical considerations:**

Hospital administration agreements were taken ethically for archive samples and patient data collection.

## Chapter Four

### Results

#### 4. Results:

Forty blocks previously diagnosed as colorectal polyps were used in this study 14(35.0%) samples were juvenile polyps, 14(35.0%) samples were adenomas polyps and 12(30.0%) samples were hyper plastic polyps (table 4.1). The patient ages ranged between 3-80 years with mean age 43 years, most of them 22(55.0%) were above 50 years and the remaining 18(45.0%) were less than 50 years (table 4.2). The patient sex revealed that 11(27.5%) patients were female and 29(72.5%) patients were male (table 4.3). Positive expression of laminin -5 among study population was found in 16/ 40 samples. Positive expression of laminin- 5 is common among adenomas polyps 7/10 samples, juvenile polyps 7/14 samples and in hyper plastic polyps 2/12 samples, negative expression of laminin -5 among study population was 24/40 samples, the most negative expression of laminin-5 was seen in hyper plastic polyps 10/12 samples, adenomas polyps 7/14 samples and juvenile polyps 7/14 samples with significant correlation between Laminin-5 and polyps types (P. value 0.047), (table 4.4).

**Table (4.1): Distribution of histopathological diagnosis among study population:**

<b>Histopathological diagnosis</b>	<b>Frequency</b>	<b>Percent</b>
Juvenile polyps	14	35%
Adenomas polyps	14	35%
Hyperplastic polyps	12	30%
Total	40	100%

**Table (4.2): Distribution of age groups among study population:**

<b>Age group (years)</b>	<b>Frequency</b>	<b>Percent</b>
50>	22	45%
50<	18	55%
Total	40	100%

**Table (4.3): Distribution of sex among study population:**

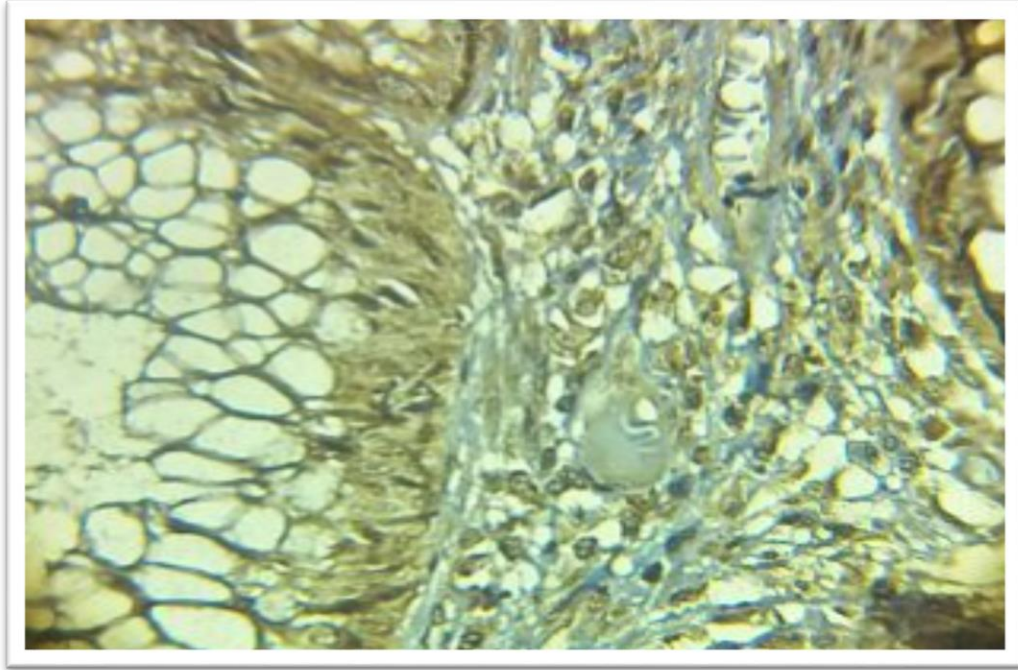
<b>Sex</b>	<b>Frequency</b>	<b>Percent</b>
Male	29	72.5%
Female	11	27.5%
Total	40	100%

**Table (4.4): Expression of laminin-5 among study samples:**

<b>Expression</b>	<b>Frequency</b>	<b>Percent</b>
Positive	16	40.0%
Negative	24	60.0%
Total	40	100%

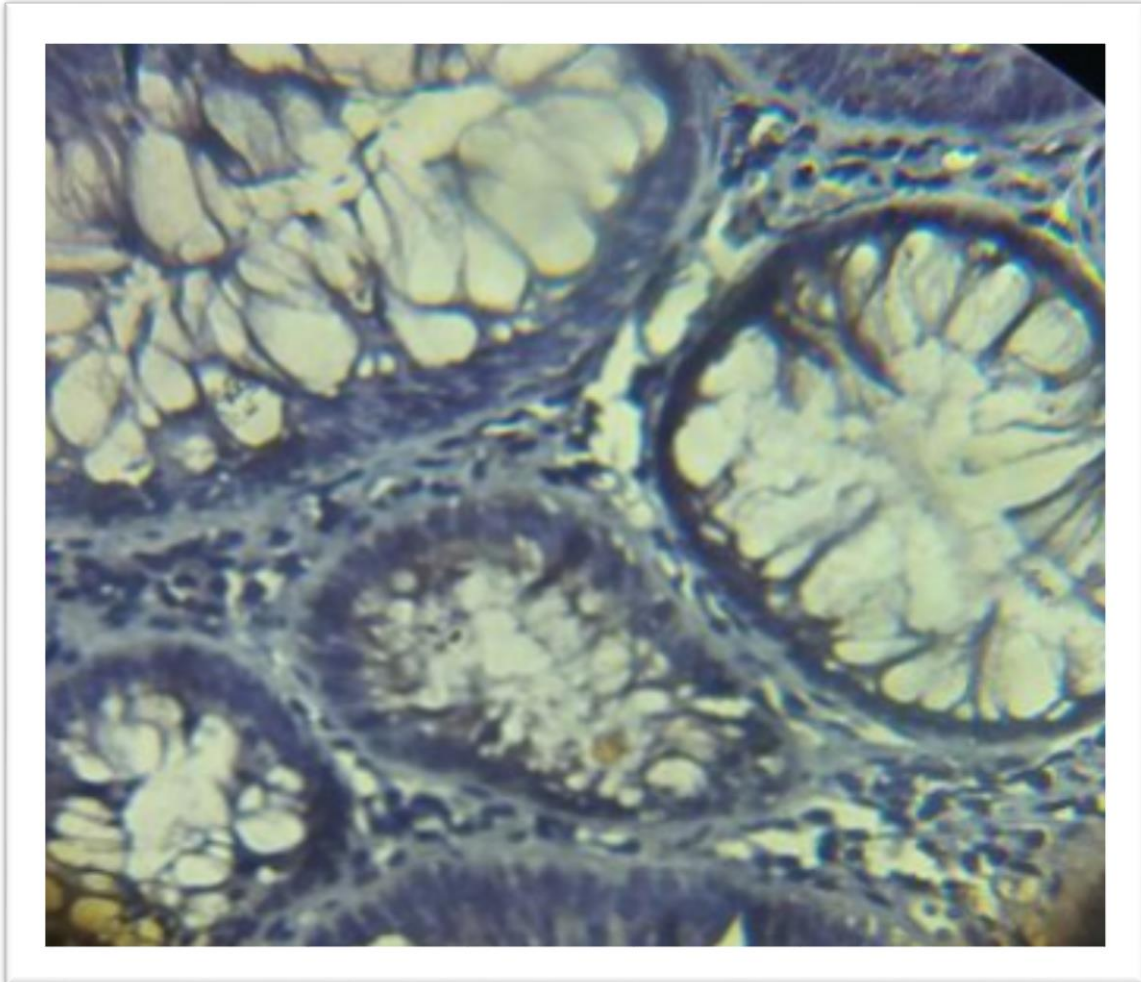
**Table (4.5): Relation between laminin -5 expression and histopathological diagnosis:**

<b>Expression of laminin-5</b>	<b>Histopathological diagnosis</b>			<b>Total</b>	<b>P. value</b>
	<b>Hyper plastic polyps N (%)</b>	<b>Adenomatous polyps N (%)</b>	<b>Juvenile polyps N (%)</b>		
Positive	2 (5.0 %)	7(17.5%)	7(17.5%)	16(40%)	0.047
Negative	10(25.0%)	7(17.5%)	7(17.5%)	24(60%)	
Total	12(30.0%)	14(35.0%)	14(35.0%)	40(100%)	



**Photograph (4.1): Adenomatous colorectal polyp of shows positive cytoplasmic expression of laminin5 (40x).**





**Photograph (4.2): Hyperplastic colorectal polyp of shows negative cytoplasmic expression of laminin5 (40x).**

## Chapter Five

### Discussion

#### 5. Discussion:

The present study involves forty cases of colorectal polyps for immunohistochemical staining by laminin-5.

Regarding the age of the population, the study revealed that most of patients were more than 50 years due to most people with one or more bowel polyps do not have any symptoms. So, most affected people never know that they have a bowel polyp. This result compatible with Huan *et al.* (2012), who reported that number of patient was increased with age 50 and reached its maximum higher in age group 75-84.

The study revealed that most of patients are men, female/male ratio was 1:2, and differences in sex hormones might explain the lower female/male ratio and overweight or obese increases men's risk of colon polyps more than it does women's. This result agrees with Murphy *et al.* (2010), they reported that colorectal cancer incidence and mortality rates are about 30% to 40% higher in men than in women. Also agree with Sarah and Madhulika, (2008), they reported that men are more likely to have colonic polyps and twice as likely to have advanced lesions.

The positive expression of laminin was in adenomatous polyps and juvenile polyps (17.5%). This result showed significant relation between laminin 5 expressions and histopathological diagnosis of polyps (P. value 0.047). That means the adenomatous polyps and juvenile polyps are more suspect to transform to adenocarcinoma. This result compatible with Conteduca *et al.* (2013), they reported that adenoma (adenomatous polyps and juvenile polyps) is the most frequent precancerous lesion. Also agree with Lenander *et al.* (2003), they reported laminin 5  $\gamma$ 2 chain expression was found to increase progressively towards a more atypical phenotype of adenoma.

The study revealed there is a role of laminin -5 as marker of potential invasiveness of colorectal polyps and laminin 5 expressions is associated with adenomatous polyps and juvenile polyps which they are more common pre-cancerous lesions of colorectal cancer.

## **Chapter Six**

### **Conclusion and recommendation**

#### **6. Conclusion and recommendation:**

##### **6.1 Conclusion:**

On basis of this study we conclude:

- The age of the colorectal cancer among study population is commonly more than 50 years.
- Most histological type of colorectal polyp – in the study samples- is adenomas and juvenile polyps.
- Laminin- 5 expression is associated with adenomatous polyps and juvenile polyps; they are more common pre-cancerous lesions of colorectal cancer.

##### **6.2 Recommendation:**

On basis of this study we recommend:

- Further study should be done on expression of laminin 5 in colorectal polyps with large sample size.
- Laminin- 5 should be used to detect the possibility of transformation of colorectal polyps

## References

Bancroft, J. D., and Marilyn, G., (2008). theory and practice of histological techniques, 6<sup>th</sup> edition, London, New York, Oxford Philadelphia, St Louis Sydney Toronto, PP.423-538.

Bond, J.H., (2000). Polyp guideline: diagnosis, treatment, and surveillance for patients with colorectal polyps. Practice Parameters Committee of the American College of Gastroenterology, *American Journal Gastroenterology*, **95**(11):3053-63.

Carlos, E., Daniele, M., Tiago, S. C., César, V.L. and Júlio, C. (2014). Malignancy in Large Colorectal Lesions, *Arquivos de Gastroenterologia*, **51**(3):235-237.

Carolyn,C. and Fredreick,L.G.,(2004) The Staging of Colorectal Cancer 2004 and Beyond, *Cancer Journal for Clinicians*, **54**(6): 295–308.

Chattopadhyay, G., Ray, D., Chakravartty,S., and Mandal,S., (2008). Leiomyosarcoma of rectum and anal canal -a diagnostic challenge, *World Journal of Colorectal Surgery*, **1**(1):1-14.

Christina, E. B., Chung.Y. H., Nancy, Y. Y., Harmeet, K., Randy, D. E., and George, J.C., (2015). Variation in Positron Emission Tomography Use after Colon Cancer Resection, *Journal of Oncology Practice*, **11**(3): 363-372.

Conteduca, V., Sansonno, D., Russi, S., and Dammacco, F., (2013). Precancerous colorectal lesions (Review), *International Journal of Oncology*, **43**(4):973-84.

Cosnes, J., (2004). Tobacco and IBD relevance in the understanding of disease mechanisms and clinical practice, *Best Practical Research Clinical Gastroenterol*, **18**(3):481-96.

Domenico, R., Rossana, P., Margherita, L., Francesco, C., Domenico, A., *et al* (2014). Diffuse large B-cell lymphoma of the colon with synchronous liver metastasis: a rare case report mimicking metastatic colorectal adenocarcinoma, *biomedical central Surgery*, **14**(75): 1471-2482.

Domogatskaya, A., Rodin, S. and Tryggvason, D. (2012). Functional diversity of laminins, *Annual Review*, **28**:523-53.

Farin, A., Michelle, A., and Clifford, Y., (2005). Colorectal Cancer Epidemiology, Risk Factors, and Health Services, *Clinics in Colon and Rectal Surgery*, **18**(3): 133–140.

Gray, H. and Lewis, W.H., (2000). The Large Intestine, Gray's Anatomy of the Human Body, 20<sup>th</sup> editions, New York, NY, Bartleby, pp. 1821–1865.

Greg, H., (2000). Trends and risk factors for colorectal cancer, *British Cancer Medical Journal*, **42**(3): 131-135.

Halligan, S., Wooldrage, K., Dadswell, E., Kralj-Hans, I., Von Wagner, C., Edwards, R., *et al* (2013). Computed tomographic colonography versus barium enema for diagnosis of colorectal cancer or large polyps in symptomatic patients (SIGGAR): a multicenter randomized trial, *the Lancet Journal*, **381**(9873):1185-93.

Harmeet, K., Haesun, C., Nancy You, Y., Gaiane, M. R., Corey, T. J., Ping Hou, *et al.* (2011). MR imaging for preoperative evaluation of primary rectal cancer practical considerations, *Radio graphics*, **32**(2): 389–409.

Huan, C., Jorng-Tzong, H., Wen-Chu, L., Hsin-Wen, L., Cheng-Wei, C., *et al* (2012). Evaluation of the Appropriate Age Range of Colorectal Cancer Screening Based on the Changing Epidemiology in the Past 20 Years in Taiwan, *International Scholarly Research Notices*, **2012**:1-5.

Hugen, N., Brown, G., Glynn-Jones, R., de Wilt, J.H. and Nagtegaal, I.D., (2015). Advances in the care of patients with mucinous colorectal cancer. *Nature Reviews Clinical Oncology*, **13** (6):333–339.

Jasperson, K.W., Tuohy, T.M., Neklason, D.W., and Burt, R.W., (2010). Hereditary and Familial Colon Cancer, *Gastroenterology*, **138**(6): 2044–2058.

Jun, C., Liufang, J., Christopher, L. G., William, J. R., Robert, D. F., and Lori, A. S., (2009). Expression of Laminin Isoforms,

Receptors and Binding Proteins Unique to Nucleus Pulposus Cells of Immature Intervertebral Disc, *Connective Tissue Research*, **50**(5): 294–306.

Labianca, R., Nordlinger, B., Beretta, G. D., Brouquet, A. and Cervantes, A., (2010). Primary colon cancer: ESMO Clinical Practice Guidelines for diagnosis, adjuvant treatment and follow-up, *Oxford Journals*, **21** (5): 70-77.

Lenander, C., Roblick, U. J., Habermann, J. K., Tryggvason, K., and Auer, G., (2003). Laminin 5  $\gamma$ 2 chain expression: a marker of early invasiveness in colorectal adenomas, *Molecular Pathology*, **56**(6): 342–346.

Maka, K., Luigia, D. E., Michele, P., Anthony, T., and Joachim, H., (2013). Colorectal cancer Current imaging methods and future perspectives for the diagnosis, Staging and Therapeutic Response Evaluation, *World Journal of Surgical Oncology*, **19**(46): 8502–8514.

Miguel, A.R., Edward, H. L., and Christopher, H. C., (2003). Surgical Anatomy Holland-Frei Cancer Medicine, 6<sup>th</sup> edition, Hamilton, BC Decker, pp 230-8.

Mohamed, O.A. T., Abd Elrahman, A. A and Mohamed, R.S., (2015). Pattern & presentation of colorectal cancer in central Sudan, a retrospective descriptive study, *Africa Health Sciences*, **15**(2): 576–580.



Murphy, G., Devesa, S.S., Cross, A.J., Inskip, P.D., McGlynn, K.A., Cook, M.B., (2010). Sex disparities in colorectal cancer incidence by anatomic subsite, race and age, *International Journal Cancer*. **128**: 1668-1675.

Niek, H., Gina, B., Robert, G., Johannes, H. W. and Iris, D. N., (2015). Advances in the care of patients with mucinous colorectal cancer, *Nature Reviews Clinical Oncology*, **13**(2016):361–369.

Numata, M., Shiozawa, M., Watanabe, T., Tamagawa, H., Yamamoto, N., Morinaga, S., *et al*, (2012). The clinicopathological features of colorectal mucinous adenocarcinoma and a therapeutic strategy for the disease, *World Journal of Surgical Oncology*, **10**(109):2-8.

Philip C. T., Steven, R. H., (2006). Carcinoid and Neuroendocrine Tumors of the Colon and Rectum, *Clinics in Colon and Rectal Surgery*, **19**(2): 45–48.

Quayle, F.G. and Lowney, G.K., (2006). Colorectal Lymphoma, *Clinics of colon and rectal surgery*, **19**(2): 49–53.

Rama, A. R., Aguilera, A., Melguizo, C., Caba, O., Prados, J., (2015) Tissue Specific Promoters in Colorectal Cancer, *Disease Markers*, **2015**(2015):1-8.

Ramos V.J.A., and Miller, M.A., (2014). When Tissue Antigens and Antibodies Get Along Revisiting the Technical Aspects of

Immunohistochemistry The Red, Brown, and Blue Technique, *Veterinary Pathology Journal*, **51**(1):42-87.

Robert, H. F., (2009). The diagnosis of colorectal cancer in patients with symptoms, *Biomed Central Medicine*, **1**(115):7-18.

Sandro, N. A., Gustavo, J. L., Daniéla, O. M., Helvia, N., Rogério, A., Oliveira, *et al*, (2015). Dietary risk factors for colorectal cancer in Brazil: a case control study, *Nutrition Journal*, **15**(20):1-4.

Sarah, W. G. and Madhulika, G. V., (2008). Factors that Increase Risk of Colon Polyps, *Clinics of colon and rectal surgery*, **21**(4): 247–255.

Saunders, T. H., Mendes, R. H. K., and Gleeson, F. V., (2002). New techniques for imaging colorectal cancer: the use of MRI, PET and radioimmunosintigraphy for primary staging and follow-up, *Oxford Journals*, **64** (1): 81-99.

Sebastian, S., (2014). Management of colorectal cancer, *F1000Prime Report*, **6**(108): 6-108.

Steward, M. J., and Murray, D., (2013). Staging of colorectal cancer, *British Institute of Radiology*, **22** (1):1-3.

Tom, V.W, Anneke, M., Juul, T.W. and Hans, M., (2012). A review of the genetic background and tumour profiling in familial colorectal cancer, *Oxford Journals*, **27** (2): 239-245.

Van, S., Ernst, H.A. M., and Bosscha, K., (2008). Melanoma of the rectum a rare entity, *World Journal Gastroenterology*, **14**(10): 1633–1635.

Vincenza, C., Domenico, S., Sabino, R., and Franco, D., (2013). Precancerous colorectal lesions (Review), *International Journal of Oncology* **43**: 973-984.

Wong, H.H. and Chu, P., (2012). Immunohistochemical features of the gastrointestinal tract tumors, *Journal of Gastrointestinal Oncology*, **3**(3): 262–284.

Zuccari, D.A.P.C., CastroI, R., Jardim, B.V., Mancini, U.M., Polachini, G.M., (2011). Immunohistochemical and molecular expression of laminin-332 gamma-2 chain in canine mammary tumors, *Arquivo Brasileiro de Medicina Veterinária e Zootecnia*, **63**(1):29-35.

## Appendices

### **Instrument and Material:**

#### **Instrument:**

Disposable gloves.

Rotary microtome.

Microtome knives.

Coplin jars.

Oven.

Staining racks.

Coated slides.

Water path.

Cover glass.

Dako pen.

Humidity chamber.

#### **Materials:**

Mayer`s haematoxylin.

Xylene.

Ethyl alcohol (absolute, 90%, 70%, 50%).

Distill water.

Peroxidase blocker.

Primary antibody (laminin 5) .

Secondary antibodies (biotinylated secondary antibody).

3.3 di amino benzidine tetra hydrochloride in substrate buffer.

DPX mounting media.

#### **Phosphate (PH7.4) component:**

**Solution A** (0.2 M sodium di hydrogen orthophosphate, 3.12g di sodium hydrogen orthophosphate, 100ml DW).

**Solution B** (0.2 M sodium di hydrogen orthophosphate, 2.83g di sodium hydrogen orthophosphate, 100ml DW) (9.5ml from solution A + 40.5ml solution B).

**Citrate buffer(PH6.8) component:**

**Solution A** (0.2 M sodium di hydrogen orthophosphate, 2.83g di sodium hydrogen orthophosphate, 100ml DW).

**Solution B** (2.1g citric acid, 100ml DW) (72.7ml from solution A +22.8ml from solution B).

**Mayer`s haematoxylin component:**

Haematoxylin powder	1gm
Potassium alum or ammonium alum	50gm
Sodium iodate	0.2gm
Citric acid	1gm
Chloral hydrate	50gm
Distilled water	1000ml
Ammoniated water:	
Concentrated ammonia	0.05ml
Tap water	99.95ml