

Sudan University of Science and Technology

College of Graduate studies

Evaluation of Placenta in Pregnant Ladies at
Omdurman Maternity Hospital Using Ultrasound

تقييم المشيمة لدى النساء الحوامل بمستشفى الولادة بامدرمان
باستخدام الموجات فوق الصوتية

Thesis submitted for partial fulfillment of the Requirement of M.Sc. Degree in medical
diagnostic ultrasound

by:

Mohamed Babikir Sir El Khatim

Supervisor :

Dr. Afraa Siddig Hassan Omer

2016

بِسْمِ اللّٰهِ الرَّحْمٰنِ الرَّحِیْمِ

قال تعالى:

يَا يَحْيَى خُذِ الْكِتَابَ بِقُوَّةٍ وَآتِنَاهُ الْحُكْمَ صَبِيًّا ﴿12﴾ وَحَدَانَا مَنْ لُدْنَا وَكَانَ تَقِيًّا
﴿13﴾ وَوَأَبَاؤَهُ وَلَمْ يَكُن جَبَّارًا عَصِيًّا ﴿14﴾ وَسَلَامٌ عَلَيْهِ يَوْمَ وُلِدَ وَيَوْمَ يَمُوتُ
وَيَوْمَ يُبْعَثُ حَيًّا ﴿15﴾

سورة مريم الايات من ﴿12-15﴾

Dedication

To

My Mother....

My Father....

&

My wife and her kids

Acknowledgement

I would like to express my deepest gratitude and sincere appreciation to my faithful supervisor Dr Afraa Siddig Hassan for her continuous help, support, guidance and encouragement to complete this work. Without her supervision and constant help this dissertation would not have been possible.

My gratitude and appreciation extend to my college Alabbas Osman, the sonologist in Omdurman Maternity Hospital, for his patience and greater help during the practical part of this study.

ABSTRACT

This is a descriptive cross-sectional study conducted in Omdurman Maternal hospital. Abnormal placental development may cause major maternal and fetal complications. Therefore, the normal placenta features should be well evaluated so as to discover the abnormalities and correlate with fetal condition.

The duration of the study was from June 2016 to November 2016 on 50 pregnant women in the second and third trimesters in a group of age between 15 to 40 years old who chose to participate in this study. The main aim of this study is to evaluate placenta development in pregnant Sudanese ladies using Ultrasonography.

After ultrasound scan and analyzed using Statistical Package for social sciences we found that about 96% of them have normal placenta site and only 4% are abnormal, 2% of them are placenta previa and 2% are low lying placenta, and also the study showed the texture of placenta in this indicate that 62% are homogeneous texture while the other are heterogeneous, also the study characterized the four grading of placenta (0, 1, 2, 3), and the thickness of placenta, the study reveal that about 78% have normal placenta thickness and 22% abnormal thickness (more than 4cm) but the abnormal placenta doesn't lead to any abnormality of maternal fetus which need more researches and studies to understand this characterize in Sudanese women.

Beside the study results connected with placenta thickness and the fetus's age and the comparative between amniotic fluid index and the placenta grading

From the study was clearly there is strong relationship and close association between the fetus weight and placenta thickness and grading and also ultrasound is very informative investigation method in evaluation and diagnosis of various placenta situations and disorders. In this study we found that the abnormal placenta thickness doesn't lead to any abnormality on maternal or her fetus in Sudanese pregnant ladies, so the study recommended that further studies should be done .

ملخص الدراسة

هذه دراسة وصفية أجريت في مستشفى أم درمان للولادة وسبب هذه الدراسة أن النمو الغير طبيعي للمشيمة وظهور تشوهات عليها ربما تؤدي إلي مضاعفات على الأم والجنين لذا

لا بد من دراسة نمو وتطور المشيمة الطبيعي لاكتشاف هذه التشوهات مبكرا وإجراء اللازم نحوها وكانت في الفترة ما بين يونيو 2016 إلى نوفمبر 2016 الهدف الأساسي من هذه الدراسة هو دراسة وتقييم المشيمة للنساء الحوامل في السودان باستخدام الموجات فوق الصوتية.

وقد اختير عدد 50 حالة من النساء الحوامل في الثلثين الثاني والثالث من الحمل وكانت أعمارهن تتراوح ما بين 15 سنة و40 سنة. وبعد عمل الموجات فوق الصوتية لتأكيد سلامه الجنين و المشيمة وتم التحليل بواسطة برنامج التحليلات الاحصائية للعلوم الانسانية (spss)، اتضح أن 96% من مواقع المشيمة طبيعيه ماعدا 4% فقط غير طبيعيه منها 2% مشيمة متقدمه و2% أخرى منخفضة الوضع، كذلك تم دراسة مظهر المشيمة من حيث تجانس البياض والسواد وقد كان التجانس بنسبة 62% بينما البقية الأخرى غير متجانسة، كما تم وصف تدرجات المشيمة الاربعه وهي (0. 1. 2. 3.)، كما تمت دراسة سمك المشيمة وكانت 78% من الحالات ذات سمك طبيعي ولكن البقية ذات سمك غير طبيعي (اكبر من 4سم) والتي كان يفترض أن يكون هنالك خلل ما على الجنين أو الأم بيد أننا لاحظنا انه لم يترتب على ذلك اي خلل مما يستوجب تكثيف الدراسات والبحوث لإلقاء المزيد من الضوء على هذه الميزة لدى النساء السودانيات. كما ربطت الدراسة بين سمك المشيمة وعمر الجنين والمقارنة بين مؤشر قياس السائل المحيط بالجنين وتدرجات المشيمة. ومن خلال هذه النتائج اتضح أن هناك علاقه وثيقة بين وزن الجنين وسمك المشيمة وتدرجها واتضح أيضاً أن الموجات فوق الصوتية من الفحوصات المهمة لتقييم حالات المشيمة. بالإضافة لسمك المشيمة أكثر من 4سم أو صينا بزيادة عدد الحالات في الدراسات القادمة .

Table of Contents

Number	Address	bage
Chapter1	Introduction	1
1-1	General introduction	1
1-2	Problem of the Study	2
1-3	Objectives	2
1-3-1	General objective	2

1-3-2	Specific objective	3
1-4	Methodology	3
1-4-1	Study area	3
1-4-2	Study population	3
1-4-3	Study sample size	3
1-4-4	Method of the study	3
1-4-5	Data collection	3
1-4-6	Data storage	4
1-4-7	Data analysis	4
1-4-8	Ethical consideration	4
1-5	Thesis layout	4
Chapter 2	Litterateur Review	5
2-1	Anatomy of placenta	5
2-1-1	Development of placenta	5
2-1-2	Structure of the Placenta	7
2-1-3	Full Term Placenta	8
2-1-4	Circulation of the Placenta	9
2-1-5	Placental Grading	11
2-1-6	Umbilical Cord	14
2-2	Physiology of Placenta	15
2-2-1	Nutrition	15
2-2-2	Excretion	16
2-2-3	Protection	16
2-2-4	Production of Hormones	16
2-2-5	Ultrasound	18
2-2-6	Location	20
2-3	Pathology of Placenta	20
2-3-1	Hydatidiform Mole	20
2-3-2	Choriocarcinoma	21
2-3-3	Intervillous Thrombosis	21
2-3-4	Placental Infarcts	22
2-3-5	Placental Abruption	22
2-3-6	Developmental Variations	23
2-3-7	Placenta Annularis	26
2-3-8	Fenestrate Placenta	26
2-3-9	Circumvallate Placenta	26
2-3-10	Placenta Previa	28
2-3-11	Low-Lying Placenta	29
2-3-12	Ultrasound of placenta previa	31
2-3-13	Placenta Accreta	34
2-3-14	Villitis	36
2-3-15	Chorioamnionitis	38

2-4	Placental Size and Growth	38
2-5	Previous Studies	40
Chapter3	Materials and Method	42
3	Population of the Study	42
3.1	Area and duration of the Study	42
3.2	Equipments	42
3.4	Method of Data Collection	42
3.5	Data Analysis	42
Chapter4	Results	43
Chapter5	Discussion, conclusion and Recommendation	57
5.1	Discussion	57
5.2	Conclusion	60
5.3	Recommendations	61
5.4	References	62
	Appendix1	
	Appendix2	

List of Tables:

Table (4.1) frequency distribution of age groups

Table (4.2) frequency distribution of site of placenta

Table (4.3) frequency distribution of echogenecity of placenta

Table (4.4) frequency distribution of grading of placenta

Table (4.5) a- frequency distribution of range of placenta thickness by mm

Table (4.5) b- frequency distribution of placenta thickness (normal or abnormal)

Table (4.6) frequency distribution of gestational age per weeks

Table (4.7) mean , minimum ,maximum and Std for AFI & fetal weight

Table (4.8) Frequency distribution of fetal status

Table (4.9) a. crosstabulation echogenicity and gestational age

Table (4.9) b. chi square echogenicity and gestational age

Table (4.10) a. crosstabulation echogenicity and grading of placenta

Table (4.10) b. chi square echogenicity and grading

Table (4.11) a. cross tabulation gestational age and thickness of placenta

Table (4.11) b. chi square gestational age and thickness of placenta

Table (4.12) Correlations thickness and fetal weight

Table (4.13) Correlations grading and fetal weight

Table (4.14) Correlations grading and AFI

Table (4.15) correlation between thickness mm and gestational age

List of Figures :

Figure	Address
2-1	structure of the placenta Figure (4.1) frequency distribution of age groups
2-2	the full-term placenta
2-3	placental circulation
2-4	placental grading
2-5	Grade 1 Placenta
2-6	Grade 2 Placenta
2-7	Grade 3 Placenta
2-8	Normal Cord Insertion:
2-9	Placental abruption
2-10	Succenturiate Lobe
2-11	Membranacea
2-12	Circumvallate Placenta
2-13	marginal Placenta Previa
2-14	Low-Lying Placenta
2-15	placental migration
2-16	Effects of FMC on the Cervix
2-17	Placenta accrete
2-18	Placenta accrete
2-19	Placenta increta
2-20	Placenta Previa and Percreta
(4.2)	frequency distribution of site of placenta
(4.3)	frequency distribution of echogenecity of placenta
(4.4)	frequency distribution of grading of placenta
(4.5)a	frequency distribution of range of placenta thickness by mm
(4.5) b	frequency distribution of placenta thickness (normal or abnormal)
(4.6)	frequency distribution of gestational age per weeks
(4.7)	Frequency distribution of fetal status
(4.8) a-	regression equation between placenta per mm thickness and GA per week
(4.8) b-	regression equation between placenta per mm thickness and GA per week

List of abbreviations

ACAbdominal circumference
AD Abdmninal diameter
APHAntepartum hemorrhage
AF.....Amniotic fluid index
BPDBiparietal diameter
CSCesarean section
EVS Endovaginal scan
FLFemouer length
FMCFocal myometreium contraction
GAGestational age
GTD Gestational trophoblast disease
HCHead circumferece
HCGHuman chorionic gonadotropin
HPLHuman placental lactogen
IUGRIntrauterine growth retardation
LMP Last menstrual period
SCHSub chorionic hematoma
SPSSStatistical package for social sciences
TASTrans abdominal scan
TPSTrans perineal scan
US.....Ultrasound

Chapter One

Introduction

1-1 General introduction:

The placenta and fetus both arise from the same single cell- zygote which is the fertilized ovum , hence, the placenta and the umbilical cord and the blood flowing in them are of embryonic or fetal origin . After the blastocyst attaches the endometrial surface ,it begin the process of implantation. In the early stage of implantation the trophoblast begin to differentiate in two cell layers – inner and outer (Devin 2005). The placenta is a vascular structure by which an unborn child is attached to its mother's uterine wall and through which respiratory gas and metabolic exchange occurs. The placenta is formed in part from maternal tissue and in part from embryonic tissue. The embryonic portion of the placenta consists of the chorionfrondosum, whereas the maternal portion is composed of the area of the uterine wall called the decidua basalis, into which the chorionic villi penetrate. Blood does not flow directly between these two portions, but because their membranes are in close proximity, certain substances diffuse readily. When fully formed, the placenta is a reddish brown oval disc with a diameter of 15 to 20 cm and a thickness of 2.5 cm, It weighs between 500 and 600 g, about one sixth as much as the fetus(Graaff 2001).

As a result of the continuous growth of the fetus and expansion of the uterus, the placenta also enlarges. Its increase in surface area roughly parallels that of the expanding uterus and throughout pregnancy it covers approximately 15 to 30% of the internal surface of the uterus. The increase in thickness of the placenta results from arborization of existing

villi and is not caused by further penetration into maternal tissues.(Sadler 2004)

The use of ultrasound to evaluate the placenta is routine among the majority of pregnant women. A wide range of pregnancy complications result from abnormal placental development, including preeclampsia, intrauterine growth retardation 2 (IUGR) and abruption. Other placental abnormalities, such as placenta previa, percreta or vasa previa, may cause major maternal and fetal complications. Timely recognition of these abnormalities can lead to improve management of pregnancy and delivery. Thus, careful examinations of the placenta by ultrasound can contribute directly to enhance patient care and improve outcomes.(Rumack 2011)

ultrasound, manual examination of the maternal abdomen was the only approach that could be used to estimate Placental abnormalities.

General evaluation of the placenta should routine part of every second and third trimester . Ultrasound study as indicate in the American institute of ultrasound in medicine ant partum obstrical ultrasound examination guidness (the placental location – appearance and it is relationship to the internal cervical os should be recorded). (Devin 2005)

There is no special equipment or transducer consideration ,the equipment and transducer deemed mass appropriate for the obstetrical ultrasound study may be used. If the system has electric beam focusing the focal zone should be adjusted to optically visualize the placenta. (Devin 2005)

The attenuation and shadowing from over lying fetus causing difficulty in visualizing the posterior placenta.

Positioning of the patient in the left or right oblique position may be helpful in better visualizing a posterior placenta.

For standard trans abdominal study(TAS) the bladder should be adequately distended to optimize visualization of the cervix and lower uterine segment and show the relationship between the placenta and the internal os. (Devin 2005)

Routine evaluation of the placenta with the color Doppler is now favored to rapidly find the placental orientation site and detect vascular abnormalities.

Ultrasound has become one of the primary diagnostic aids to evaluate placental growth ,location, measurement ,abruption , grade and abnormalities during pregnancy. (Devin 2005)

Placental abnormalities such as placenta accreta ,increta. Percreta placental previa, succenturiate placenta, circumvalate placenta , circummagnate placenta and fibrin deposition ...etc.

1-2 Problem of the Study

Abnormal placental development may causes major maternal and fetal complications, there for the normal placenta feature shoud be well evaluated so as to discovered the abnormal and correlate with fetal condition .

1.3 Objectives:

1.3.1 General objective:

Evaluation of placenta in pregnant ladies at Omdurman Maternity Hospital using ultrasound.

1.3.2 Specific objective:

- To Evaluate the placenta in the pregnant women in the second and third trimester
- To Evaluate the normal and abnormal placenta.
- To Evaluate the placenta site, ,grade and thickness .
- _ To correlate the placenta thicknesst with gestational age and fetal weight.
- _ To evaluate the amniotic fluid index.

1.4 Thesis layout:

Chapter one: Introduction

Chapter two: literature review.

Chapter three: Materials and methods.

Chapter four: the results.

Chapter five: discussion. recommendation, conclusion , references and appendix.

Chapter Two

Litterateur Review

2.1 Anatomy of placenta

2.1.1 Development of placenta

As the fetus grows, its demands for nutritional and other factors increase, causing major changes in the placenta. Foremost among these is an increase in surface area between maternal and fetal components to facilitate exchange. (Sadler 2004).

a. Changes in the Trophoblast

By the beginning of the second month, the trophoblast is characterized by a great number of secondary and tertiary villi that give it a radial appearance. The villi are anchored in the mesoderm of the chorionic plate and are attached peripherally to the maternal decidua by way of the outer cytotrophoblast shell. The surface of the villi is formed by the syncytium, resting on a layer of cytotrophoblastic cells that in turn cover a core of vascular mesoderm. The capillary system developing in the core of the villous stems soon comes in contact with capillaries of the chorionic plate and connecting stalk, thus giving rise to the extra embryonic vascular system. (Sadler 2004)

During the following months, numerous small extensions sprout from existing villous stems into the surrounding lacunar or intervillous spaces. Initially these newly formed villi are primitive, but by the beginning of the fourth month, cytotrophoblastic cells and some connective tissue cells disappear. The syncytium and endothelial wall of the blood vessels are then the only layers that separate the maternal and fetal circulations. Frequently the syncytium becomes very thin, and large pieces containing

several nuclei may break off and drop into the intervillous blood lakes. These pieces, known as syncytial knots, enter the maternal circulation and usually degenerate without causing any symptoms. Disappearance of cytotrophoblastic cells progresses from the smaller to larger villi, and although some always persist in large villi, they do not participate in the exchange between the two circulations.(Sadler 2004).

b. Chorion Frondosum and Decidua Basalis

In the early weeks of development, villi cover the entire surface of the chorion. As pregnancy advances, villi on the embryonic pole continue to grow and expand, giving rise to the chorion frondosum (bushy chorion). Villi on the abembryonic pole degenerate and by the third month this side of the chorion, now known as the chorion laeve, is smooth. (Sadler 2004).

The difference between the embryonic and abembryonic poles of the chorion is also reflected in the structure of the decidua, the functional layer of the endometrium, which is shed during parturition. The decidua over the chorion frondosum, the decidua basalis, consists of a compact layer of large cells, decidual cells, with abundant amounts of lipids and glycogen. This layer, the decidual plate, is tightly connected to the chorion. The decidual layer over the abembryonic pole is the decidua capsularis. With growth of the chorionic vesicle, this layer becomes stretched and degenerates. Subsequently, the chorion laeve comes into contact with the uterine wall (decidua parietalis) on the opposite side of the uterus and the two fuses, obliterating the uterine lumen. Hence the only portion of the chorion participating in the exchange process is the chorion frondosum, which, together with the decidua basalis, makes up the placenta. Similarly, fusion of the amnion and chorion to form the

amniochorionic membrane obliterates the chorionic cavity. It is this membrane that ruptures during labor (breaking of the water). (Sadler 2004).

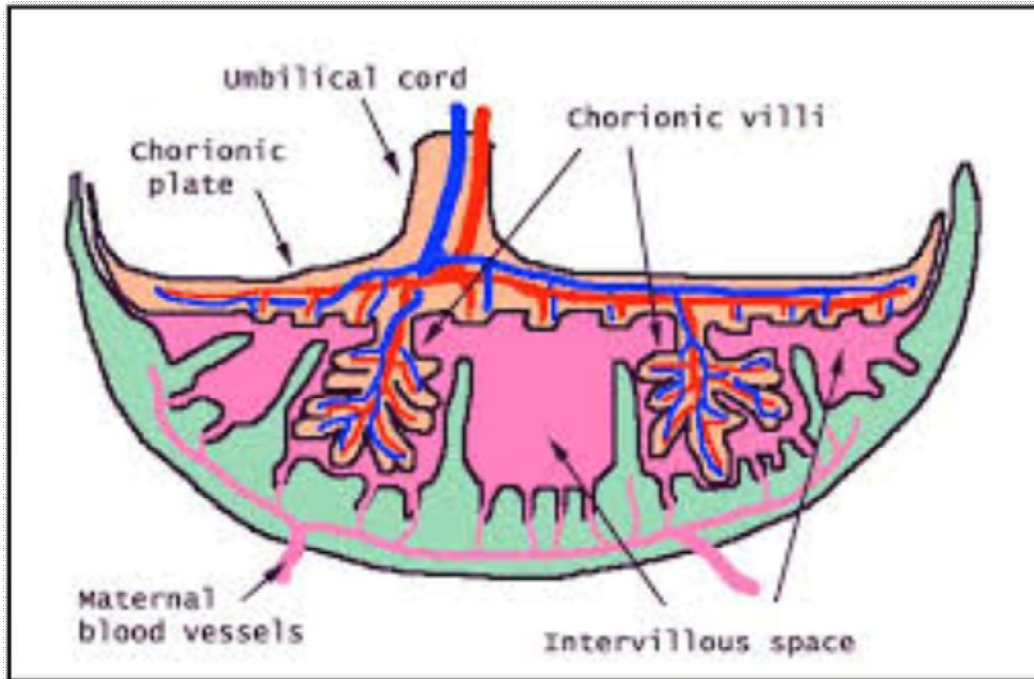


Figure 2-1: structure of the placenta:

(<http://www.siumed.edu/~dking2/erg/placenta.htm>)

2.1.2 Structure of the Placenta

By the beginning of the fourth month, the placenta has two components: (a) a fetal portion, formed by the chorion frondosum; and (b) a maternal portion, formed by the decidua basalis. On the fetal side, the placenta is bordered by the chorionic plate; on its maternal side, it is bordered by the decidua basalis, of which the decidual plate is most intimately incorporated into the placenta. In the junctional zone, trophoblast and decidua cells intermingle. This zone, characterized by decidual and syncytial giant cells, is rich in amorphous extracellular

material. By this time most cytotrophoblast cells have degenerated. Between the chorionic and decidua are the intervillous spaces, which are filled with maternal blood. They are derived from lacunae in the syncytiotrophoblast and are lined with syncytium of fetal origin. The villous trees grow into the intervillous blood lakes. During the fourth and fifth months the decidua forms a number of decidua septa, which project into intervillous spaces but do not reach the chorionic plate. These septa have a core of maternal tissue, but their surface is covered by a layer of syncytial cells, so that at all times a syncytial layer separates maternal blood in intervillous lakes from fetal tissue of the villi. As a result of this septum formation, the placenta is divided into a number of compartments, or cotyledons. Since the decidua septa do not reach the chorionic plate, contact between intervillous spaces in the various cotyledons is maintained. (Sadler 2004)

As a result of the continuous growth of the fetus and expansion of the uterus, the placenta also enlarges. Its increase in surface area roughly parallels that of the expanding uterus and throughout pregnancy it covers approximately 15 to 30% of the internal surface of the uterus. The increase in thickness of the placenta results from arborization of existing villi and is not caused by further penetration into

maternal tissues. (Sadler 2004).

2.1.3 Full Term Placenta

At full term, the placenta is discoid with a diameter of 15 to 25 cm, is approximately 3 cm thick, and weighs about 500 to 600 g. At birth, it is torn from the uterine wall and, approximately 30 minutes after birth of the child, is expelled from the uterine cavity. After birth, when the placenta is viewed from the maternal side, 15 to 20 slightly bulging areas,

the cotyledons, covered by a thin layer of decidua basalis, are clearly recognizable. Grooves between the cotyledons are formed by decidual septa. (Sadler 2004)

The fetal surface of the placenta is covered entirely by the chorionic plate. A number of large arteries and veins, the chorionic vessels, converge toward the umbilical cord. The chorion, in turn, is covered by the amnion. Attachment of the umbilical cord is usually eccentric and occasionally even marginal. Rarely, however, does it insert into the chorionic membranes outside the placenta (velamentous insertion). (Sadler 2004).

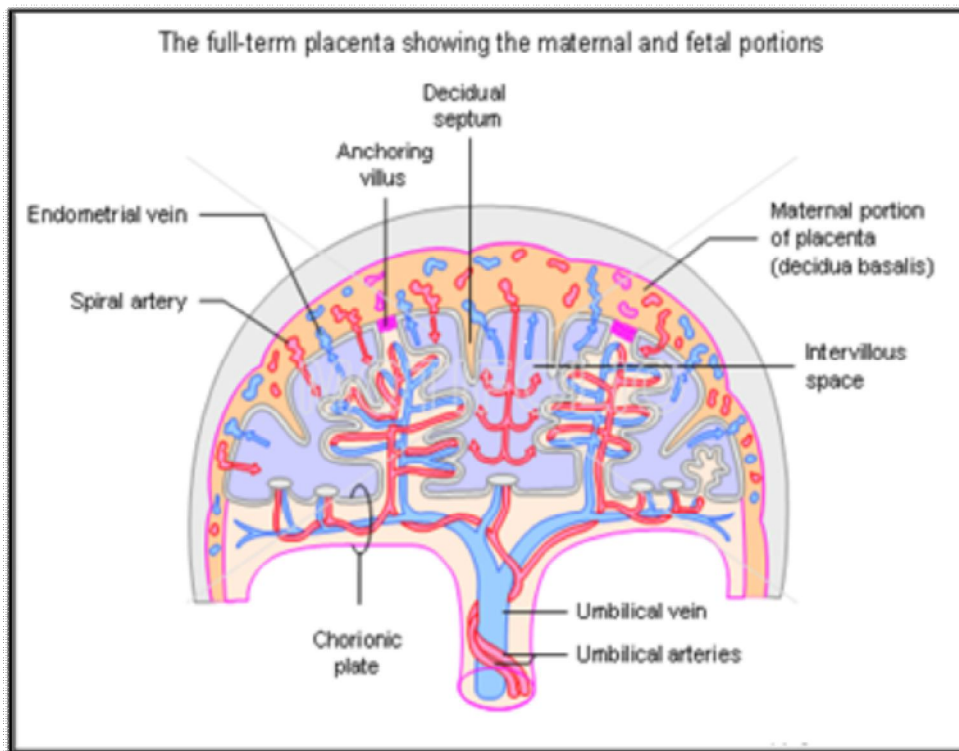


Figure 2-2 The full-term placenta

(<http://www.inharmonybirth.com/placenta-eparation>)

2.1.4 Circulation of the Placenta

Cotyledons receive their blood through 80 to 100 spiral arteries that pierce the decidual plate and enter the intervillous spaces at more or less regular intervals. The lumen of the spiral artery is narrow, so blood pressure in the intervillous space is high. This pressure forces the blood deep into the intervillous spaces and bathes the numerous small villi of the villous tree in oxygenated blood. As the pressure decreases, blood flows back from the chorionic plate toward the decidua, where it enters the endometrial veins. Hence, blood from the intervillous lakes drains back into the maternal circulation through the endometrial veins. (Sadler 2004).

Collectively, the intervillous spaces of a mature placenta contain approximately 150 ml of blood, which is replenished about 3 or 4 times per minute. This blood moves along the chorionic villi, which have a surface area of 4 to 14 m². However; placental exchange does not take place in all villi, only in those whose fetal vessels are in intimate contact with the covering syncytial membrane. In these villi, the syncytium often has a brush border consisting of numerous micro villi, which greatly increases the surface area and consequently the exchange rate between maternal and fetal circulations. The placental membrane, which separates maternal and fetal blood, is initially composed of four layers: (a) the endothelial lining of fetal vessels; (b) the connective tissue in the villus core; (c) the cytotrophoblastic layer; and (d) the syncytium. From the fourth month on, however, the placental membrane thins, since the endothelial lining of the vessels comes in intimate contact with the syncytial membrane, greatly increasing the rate of exchange. Sometimes called the placental barrier, the placental membrane is not a true barrier, since many substances pass through it freely. Because the maternal blood

in the intervillous spaces is separated from the fetal blood by a chorionic derivative, the human placenta is considered to be of the hemochorial type. (Sadler 2004).

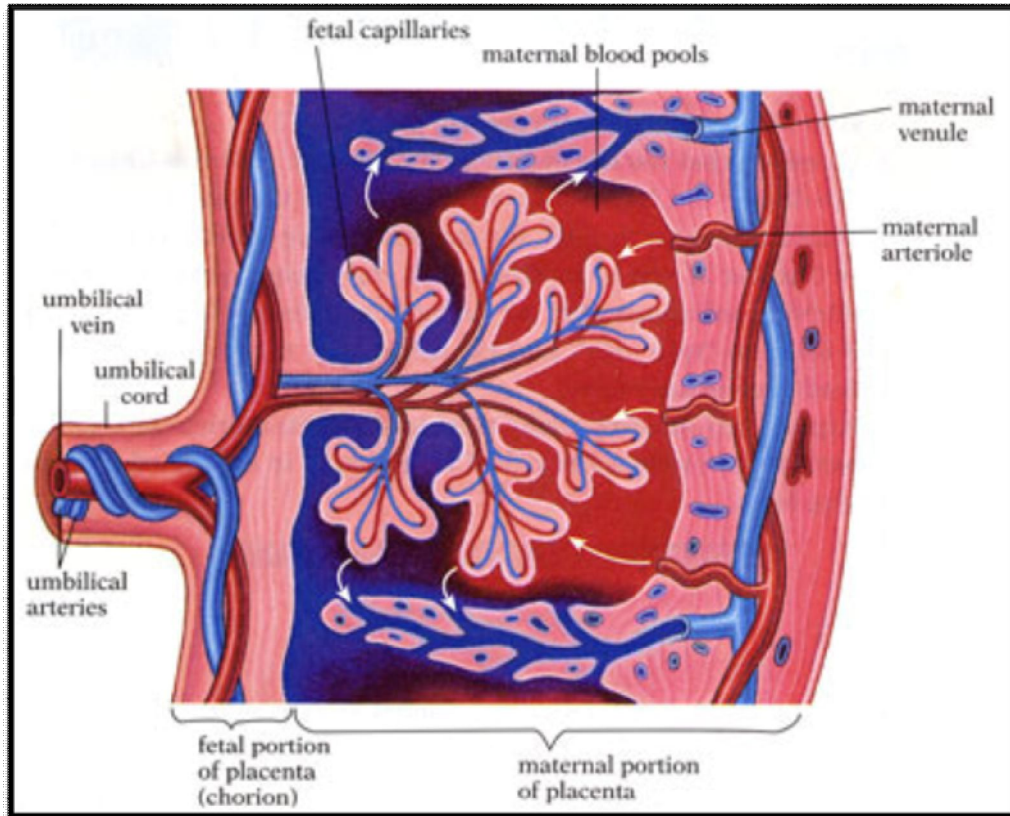


Figure 2-3: placental circulation:.

(<http://www.biog1445.org/demo/07/ovaryplacenta.html>).

2.1.5 Placental Grading

Calcium deposition in the placenta is a normal process of placental aging or maturation which occurs at different rates in normal pregnancies. Sonographically, macroscopic areas of placental calcifications appear as hyperechoic densities in different areas of the placenta. Calcium is deposited primarily along the basal surface and placental septa. Macroscopic and sonographic evidence of placental calcification is not evident until the third trimester. Previously, investigators found it useful

to assign placentas numerical grade (0 to 3) based on the degree of calcification however such grading schemes have proven to be of limited value in clinical practice in predicting fetal maturity, fetal well being, or perinatal outcome. These placentas show an irregular amniochorionic surface (chorionic plate) with calcification extending along the cotyledenal division from the chorionic plate to the basal surface. The grade 3 placenta may also have larger areas of calcification that produce shadowing and the placental parenchyma may contain hypoechoic or anechoic areas. Grade 3 placentas are the most heavily calcified and are not seen before 36 weeks gestation in normal pregnancies.(Burwin Institute Notes2005).

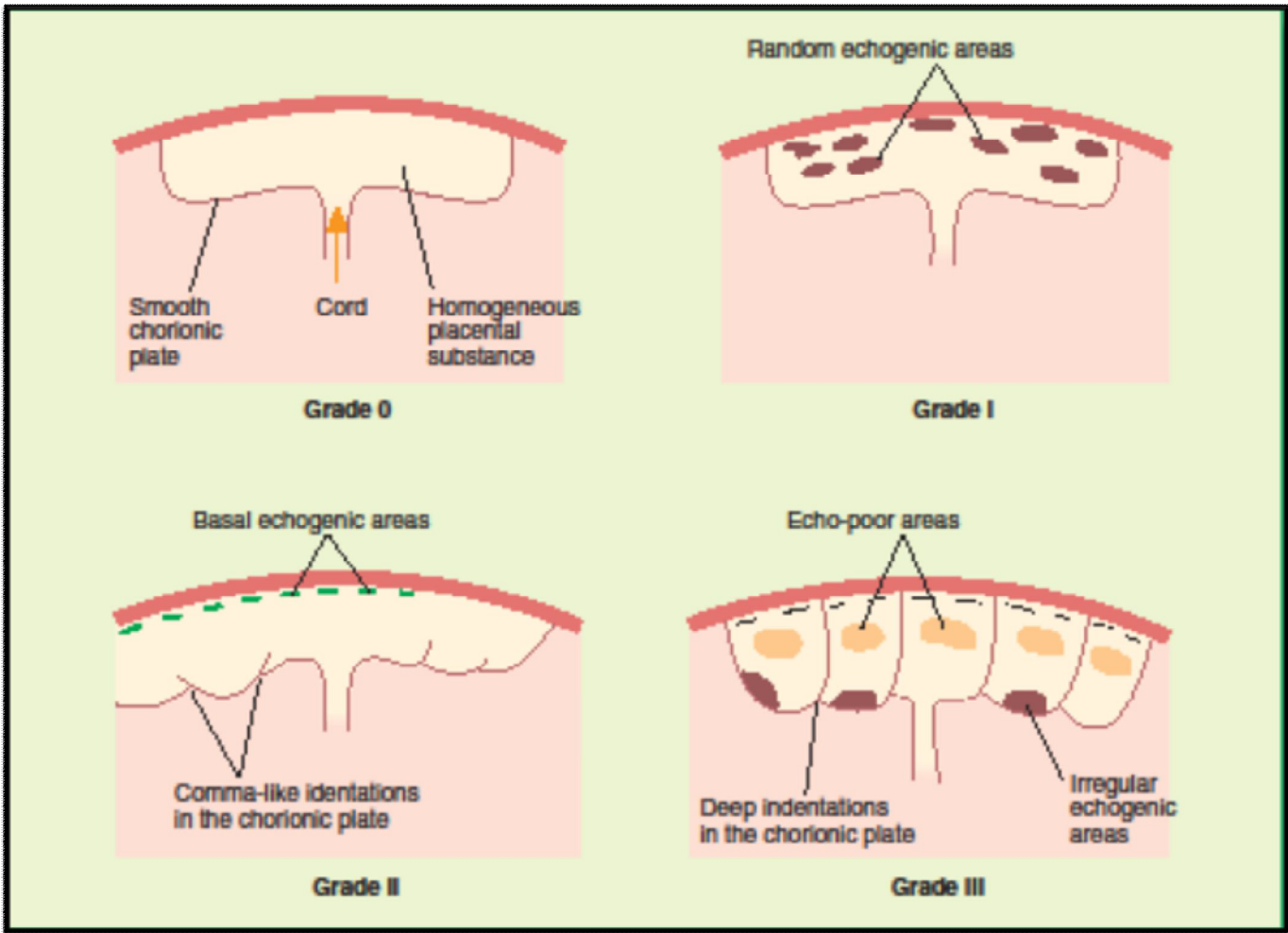
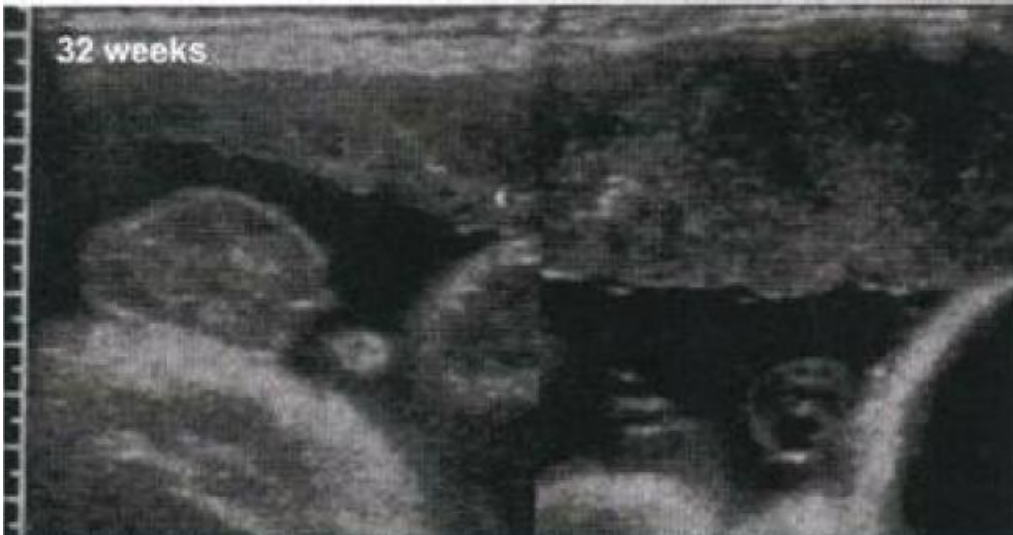

Figure 2-4: placental grading

(Chudleigh & Thilaganathan., 2004)



Grade 0 Placenta Linear array image of an anterior placenta at 32 weeks gestation shows no evidence of placental calcification

(Burwin Institute Notes 2005).

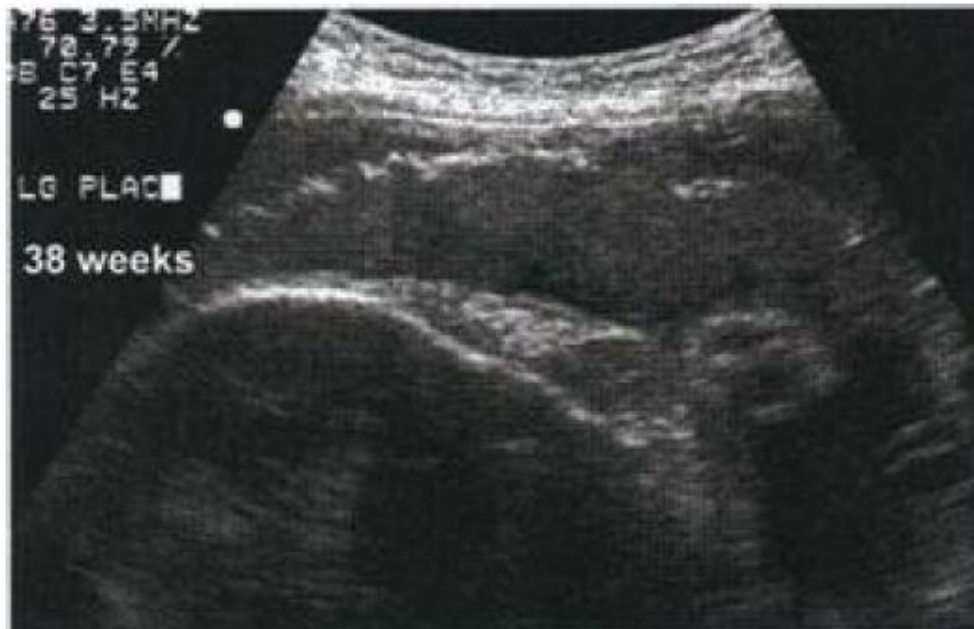

Figure2-5 Grade 1 Placenta anteriorplacenta at 32 weeks gestation

(Burwin Institute Notes 2005)..

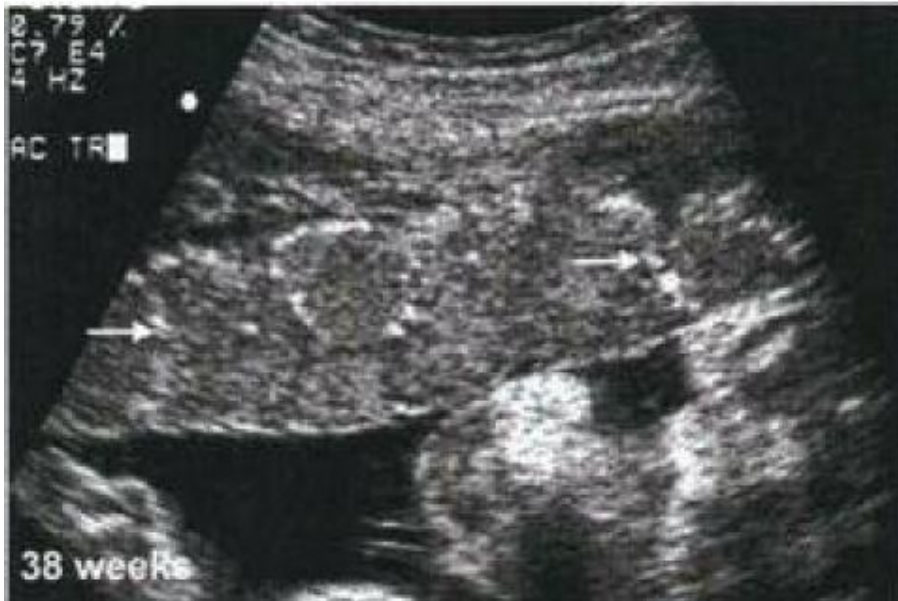

Figure 2-6 Grade 2 Placenta Anterior placenta at 38 weeks gestation
(Burwin Institute Notes 2005).

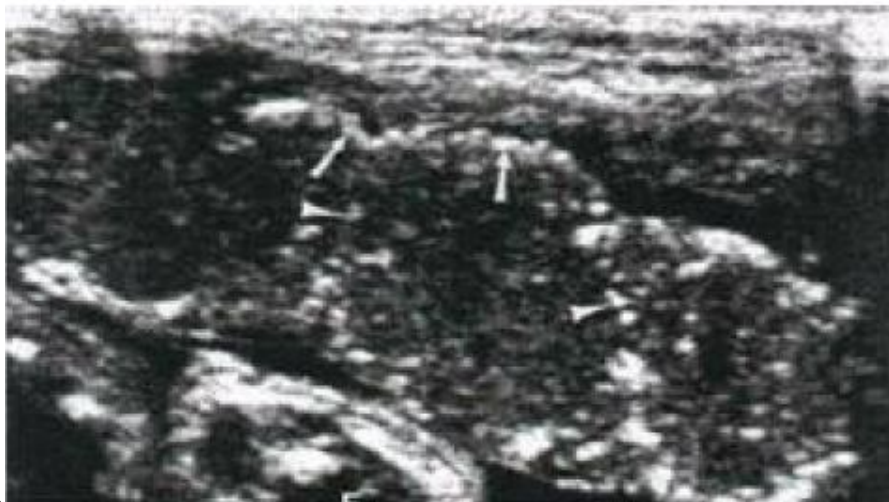

Figure 2-7 Grade 3 Placenta an anterior placenta
(Burwin Institute Notes 2005)

2.1.6 Umbilical Cord

The umbilical cord connects the fetus to the placenta. Within the cord are two umbilical arteries that carry blood from the fetus to the placenta and one umbilical vein that returns blood from the placenta to the fetus. When blood in the umbilical arteries enters the placenta, CO₂ and waste products in the fetal capillaries diffuse into the maternal blood sinuses. Oxygen diffuses from the maternal blood sinuses into the fetal capillaries; nutrients enter the fetal blood by diffusion and active transport mechanisms. This oxygen- and nutrient-rich blood then flows through the umbilical vein back to the fetus. (Scanlon and Sanders 2007).

When the baby is delivered at the end of gestation, the umbilical cord is cut. The placenta then detaches from the uterine wall and is delivered, with the rest of the umbilical cord, as the afterbirth. (Scanlon and Sanders 2007).

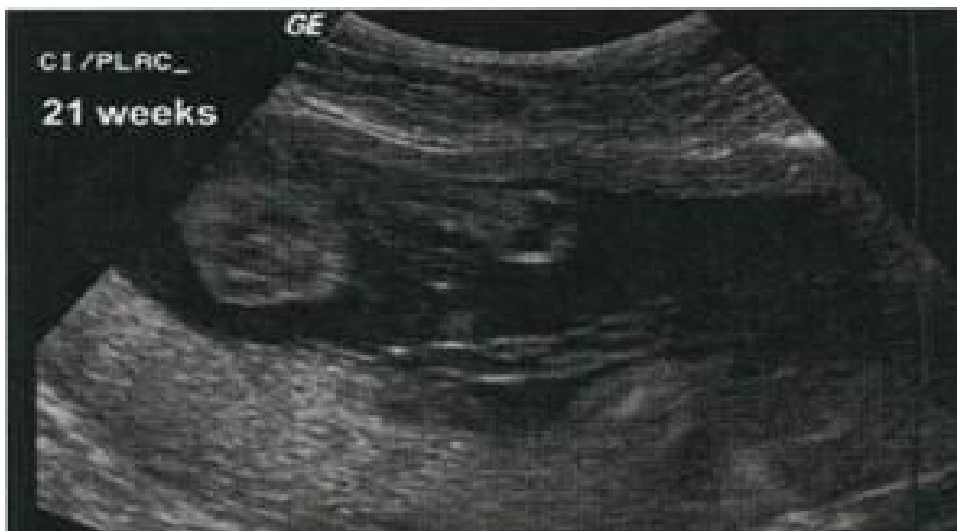

Figure 2-8: Normal Cord Insertion:. (Burwin Institute Notes 2005).

2.2 Physiology of Placenta

Main functions of the placenta are nutrition, excretion, protection and production of hormones (<http://en.wikipedia.org/wiki/Placenta>).

2.2.1 Nutrition

The perfusion of the intervillous spaces of the placenta with maternal blood allows the transfer of nutrients and oxygen from the mother to the fetus and the transfer of waste products and carbon dioxide back from the fetus to the maternal blood supply. Nutrient transfer to the fetus occurs via both active and passive transport. Active transport systems allow significantly different plasma concentrations of various large molecules to be maintained on the maternal and fetal sides of the placental barrier. Adverse pregnancy situations, such as those involving maternal diabetes or obesity can increase or decrease levels of nutrient transporters in the placenta resulting in overgrowth or restricted growth of the fetus. (<http://en.wikipedia.org/wiki/Placenta>).

2.2.2 Excretion

Waste products excreted from the fetus such as urea, uric acid, and creatinine are transferred to the maternal blood by diffusion across the placenta. (<http://en.wikipedia.org/wiki/Placenta>).

2.2.3 Protection

IgM antibodies can pass through the human placenta, thereby providing protection to the fetus *in utero*. This transfer of antibodies begins as early as the 20th week of gestational age, and certainly by the 24th week. This passive immunity lingers for several months after birth, thus providing the newborn with a carbon copy of the mother's long-term

humoral immunity to see the infant through the crucial first months of extra uterine life. IgM, however, cannot cross the placenta, which is why some infections acquired *during* pregnancy can be hazardous for the fetus. (<http://en.wikipedia.org/wiki/Placenta>).

Furthermore, the placenta functions as a selective maternal-fetal barrier against transmission of microbes. However, insufficiency in this function may still cause mother-to-child transmission of infectious diseases. (<http://en.wikipedia.org/wiki/Placenta>).

2.2.4 Production of Hormones

In humans, aside from serving as the conduit for oxygen and nutrients for fetus, the placenta secretes, from the syncytial layer of chorionic villi, the following hormones that are important during pregnancy (<http://en.wikipedia.org/wiki/Placenta>):

- a- Human Chorionic Gonadotropin (HCG) can be found in maternal blood and urine as shortly after implantation has occurred, and increases through to the 10-12th week of pregnancy, decreasing to a stable level around the 16-18th week. HCG also ensures that the corpus luteum continues to secrete progesterone and estrogen, which is important in sustaining the pregnancy until sufficient estrogen and progesterone can be secreted by the placenta itself. HCG suppresses the maternal immunologic response so that placenta is not rejected. This is the hormone analyzed by pregnancy test; a false-negative result from a pregnancy test may be obtained before or after this period. Women's blood serum will be completely negative for HCG by one to two weeks after birth. HCG testing is proof that all placental tissue is delivered. HCG is

present only during pregnancy because it is secreted by the placenta (<http://en.wikipedia.org/wiki/Placenta>).

- b- Human Placental Lactogen (HPL) promotes mammary gland growth in preparation for lactation in the mother. It also regulates maternal glucose, protein, and fat levels so that this is always available to the fetus. HPL levels increase proportional to placenta size (<http://en.wikipedia.org/wiki/Placenta>).
- c- Estrogen is secreted in levels up to thirty times those in non-pregnant women. Estrogen causes the mother's breasts, uterus and external genitalia to enlarge. Breast enlargement and glandular development is in preparation for lactation and uterine growth to accommodate growing fetus. Estrogen also causes relaxation of ligaments, including the sacroiliac joints and symphysis pubis, which will ease a vaginal birth (<http://en.wikipedia.org/wiki/Placenta>).
- d- Progesterone is necessary to maintain endometrial lining of the uterus during pregnancy. This hormone prevents preterm labor by reducing myometrial contraction. Levels of progesterone are high during pregnancy. (<http://en.wikipedia.org/wiki/Placenta>).

2.2.5 Ultrasound :

a. Technique

Diagnostic ultrasound use high frequency (3-10) MHz, low intensity sound waves which are transmitted through the tissue by the transducer .transducers consist of piezoelectric crystals which emit u\s beam and received the reflected signals then these signals are transformed into pictures on a cathode ray tube or video screen.u\s for pregnancy can be applied transabdomen scanning (traditional) or endovaginal scanning

(modern).Ultrasound has become one of the the primary diagnostic aids to evaluate placental growth, location, measurement, abruption, grade and abnormalities during pregnancy.

In general, there is no special equipment or transducer considerations (the equipment and transducer deemed most appropriate for the obstetrical ultrasound study may be used). If the system has electronic beam focussing, the focal zone should be adjusted to optimally visualize the placenta.

A posterior placenta is more difficult to visualize in its entirety due to attenuation and shadowing from the overlying fetus. If indicated, positioning the patient in a left or right posterior oblique position may be helpful in better visualizing a posterior placenta.

For the standard transabdominal study (TAS), the bladder should be adequately distended to optimize visualization of the cervix and lower uterine segment and to show the relationship of the placenta to the internal os. Overdistention of the bladder distorts the appearance of the cervix and lower uterine segment and may lead to the false positive diagnosis of placenta previa.

Endovaginal (EVS) or transperineal (TPS) techniques should be performed whenever TAS does not adequately show the relationship of the placenta to the internal os (e.g. due to attenuation by fetal parts or the patient presents with an empty bladder) and there is a high index of suspicion of placenta previa (e.g. patient presents with third trimester bleeding).

Routine evaluation of the placenta with colour Doppler is now favoured to rapidly find the placental cord insertion site and to detect vascular abnormalities in the placenta and the retroplacental uterine wall. This is especially important if the placenta is anterior and appears to be low-lying or previa since the risk of placenta creta is highest in this

situation. An important view is the median lower segment and cervix image which may identify vasa previa associated with velamentous insertion of the cord or succenturiate lobe. Pulsed Doppler spectral waveform analysis of the placenta may be helpful to characterize flow in masses or abnormal appearing vessels. (Burwin Institute Notes2005.)

b .Fetal weight Measurement:

Before the availability of the ultrasound, manual examination of the maternal abdomen was the only approach that could be used to estimate fetal size. The physical examination, however, provides only a general approximation of fetal weight because the palpated dimensions of the uterus are affected by several factors other than fetal size, including amniotic fluid volume, placental bulk, presence of fibroids and maternal obesity. Sonographic measurements of the fetus provide information about fetal age and growth. These data are used to assign gestational age, estimated fetal weight and diagnose growth disturbance. The measurements of fetal body parts provide a direct way of assessing fetal size. Numerous formulas have been published for estimating fetal weight from one or more of these fetal body measurements: head (biparietal diameter BPD or head circumference HC), abdomen (abdominal diameter AD or abdomen circumferenceAC), and femur length (FL). (Rumack et al 2011).

c. Amniotic fluid index:

This is a semiquantitative technique for assessing amniotic fluid volume. Using the maternal umbilicus as a reference point, the abdomen is divided into four quarters. With the ultrasound probe held in the longitudinal axis of the mother and perpendicular to the floor, the largest vertical pool

depth in each quadrant is recorded. The sum of these measurements represents the amniotic fluid index (AFI). Although the AFI is known to vary with gestational age, an AFI < 5 cm is classified as oligohydramnios and an AFI > 25 cm is classified as polyhydramnios. Even though this method is accepted as superior to the single deepest pool technique, considerable intra- and interobserver variation exists. Although the importance of quantifying the amniotic fluid volume is unquestionable, a practical and reproducible technique for the accurate assessment of amniotic fluid volume has yet to be introduced into clinical practice.(Chudleigh et al 2004).

2.2.6 Location

Placental location is described with respect to its relative position on the uterine wall and its relationship to the internal os. The placenta may be sleft lateral. A placenta that is distant from the internal os may be described as being in a normal location, central, or non previa. A low-lying placenta describes a placenta which appears to extend into the lower uterine segment and is within 1-2 cm of the internal os. A placenta previa describes a placenta which appears to partly or completely cover the internal os. Documentation should include an image showing placental location and the relationship to the internal os. (Burwin Institute Notes2005.)

2.3 Pathology of Placenta

2.3.1 Hydatidiform Mole

a. Total Hydatidiform Mole

It is abnormal pregnancy, where all placental villi change to molar vesicles and fill uterine cavity, while there is no embryo, fetus, nor umbilical cord. Amnion is, however, found in some cases. No capillary vessel is noted in the molar cyst which is covered by proliferated trophoblast. Microscopically found molar cyst of diameter less than 2 mm is called microscopic mole. Trophoblast are scattered in the decidua and myometrium, and called syncytial endometritis. Molar cysts may spread into blood vessel, which is the intravascular mole, and rarely metastasis appears in distant organ.(Kurjak et al 2006).

b. Partial Hydatidiform Mole

It is partial change of placental villi into the mole, which is associated with embryo, fetus or fetal parts. Fetal anomalies are common. Capillary vessels are found in molar interstitium. (Kurjak et al 2006).

c. Invasive Hydatidiform Mole

It is the invasion of molar cysts into myometrium with destruction and hemorrhage. Intravascular mole and placental polyp are excluded from the invasive mole. The lesion is formed either in total or partial mole, usually after the molar evacuation, although the invasion may develop before the termination. The change is visually noted in surgical specimen and microscopically confirmed, where the trophoblasts proliferate, hemorrhage and necrosis are found in the myometrium. (Kurjak et al 2006).

2.3.2 Choriocarcinoma

It is solid trophoblastic tumor developed primarily in myometrium, or in distant organs and tissues, usually after the removal of total or partial hydatidiform mole, and also infrequently after the abortion or deliveries. They are gestational choriocarcinoma or gestational trophoblastic disease (GTD). Non-gestationalchoriocarcinoma develops from germ cells or other cancer cells in children. Choriocarcioma is constructed of syncytio- and cyto-trophoblasts, and shows no villus pattern at all. Since villus pattern is characteristic sign of invasive mole, and its outcome is less ominous than choriocarcinoma, microscopic studies should be detailed on whole specimen after hysterectomy. Wide spread distant metastases of choriocarcinoma were common before the introduction of effective chemotherapy in this field. The interval of its diagnosis and metastases was about half to one year. Subsequent frequent spread was the lung. Any organs or tissues were affected after pulmonary metastasis, e.g. skin, subcutaneous tissue, intestine, liver, spleen, kidney, heart, and finally brain. Tumor cells were found also in blood vessels. Every organ is damaged by the trophoblasts and hemorrhage. Patients died from brain metastasis and multiple metastases due to the damage and dysfunction. (Kurjak et al 2006).

2.3.3 Intervillous Thrombosis

Intervillous thrombosis represents bleeding from fetal vessels. It is characterized as intraplacental areas of hemorrhage with variable appearance dependant on the age of lesion. Fresh lesions are dark red, with aging become brown, yellow and finally white. Intervillous thrombosis may be found in up to 50% of the term placentas. Ultrasound appearance of intervillous thrombosis is anechogenic or hypoechogenic

areas in the placenta of variable size. They can be as small as few millimeters up to few centimeters in size and they may extend to subchorionic space or basal plate. The clinical significance of intervillous thrombosis is in the possible presence of fetal maternal hemorrhage. Microscopically, fetal and maternal red blood cells may be present and the incidence is increased in the Rh isoimmunisation. (Kurjak et al 2006).

2.3.4 Placental Infarcts

Placental infarction results from disruption of blood supply to the placenta. As placenta is completely dependent on the maternal blood supply, there is underlying problem in maternal blood supply resulting in coagulation necrosis of villi. In the most circumstances infarcts are present on the placental basis, in the close proximity to the basal plate and they are variable in size. Small infarcts can be found in ¼ of the placenta without clinical significance, but they are frequently related to preeclampsia and essential hypertension. (Kurjak et al 2006).

2.3.5 Placental Abruption

Placental abruption is the acute separation of the placenta from the uterus prior to delivery of the fetus. The symptoms include pain, uterine tenderness and abdominal pain and it is usually accompanied with vaginal bleeding. Such bleeding, if excessive may cause maternal hypovolemia and shock, while severe forms of abruption result in diminished fetoplacental transfer and consequently may cause fetal death *in utero*. (Kurjak et al 2006).

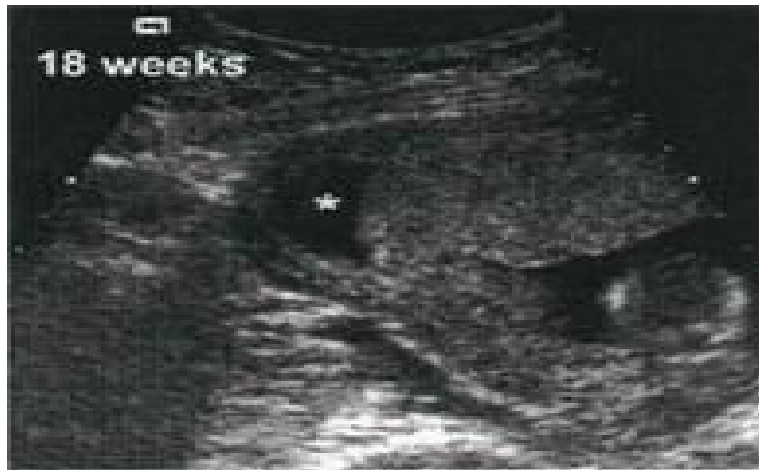

Figure 2-9: Placental abruption: Sonogram of the placenta shows a cystic area behind the placenta (*) which is the Retroplacental Hematoma (Devin 2005)

2.3.6 Developmental Variations

Variations in the configuration of the placenta is very uncommon however the sonographer should be aware of the most common variants and understand their clinical significance. Only the most commonly encountered forms (succenturiate lobe and placenta circumvallate) will be considered in detail. Other less frequent forms include placenta annularis, placenta membranacea, fenestrated placenta, and placenta spuria.

a. Succenturiate Lobe

A succenturiate lobe or succenturiate placenta is defined as one or more accessory lobes connected to the main body of the placenta by velamentous connection of the umbilical vessels (vessels traversing the membranes). The pathogenesis of succenturiate lobe is uncertain but it is likely due to a failure of the normal chorionic villi associated with part of the decidua capsularis to atrophy. Succenturiate placenta has a reported incidence of about 2.5 per 1,000 deliveries. Potential associated symptoms and complications include antepartum hemorrhage (if the

velamentous vessels rupture before delivery), vasa previa (velamentous vessels cross the internal os), postpartum hemorrhage and infection (due to retention of the accessory lobe), and perinatal morbidity and mortality (fetal anemia and shock due to rupture of velamentous vessels).

A succenturiate lobe appears as a smaller mass of placental tissue at variable distance from the main placental body (typically very close). The diagnosis can be made accurately when the connecting velamentous vessels are seen between the two islands of placental tissue.

Colour Doppler is very helpful to localize the connecting vessels which will show typical fetal umbilical flow. Focal myometrial contractions (FMC) and subchorionic hematomas (SCH) have sonographic characteristics that may mimic a succenturiate placenta with SCH being more challenging to distinguish. A FMC is a transient event which changes appearance Placenta Membranacea. The entire surface of the gestational sac is covered with a thin layer of chorionic villi (A).

Sagittal plane of section shows villous tissue around the entire surface of the gestational sac (B). Line indicates plane of section for the axial image (C) which also shows villi around the entire perimeter of the sac. during the study period and is easily recognized; SCH will lack connecting vessels and changes appearance over the course of serial studies. Colour Doppler should demonstrate normal intraplacental flow in the succenturiate lobe (colour flow similar to the main placental body) whereas SCH will lack normal colour flow signals. (Devin 2005)

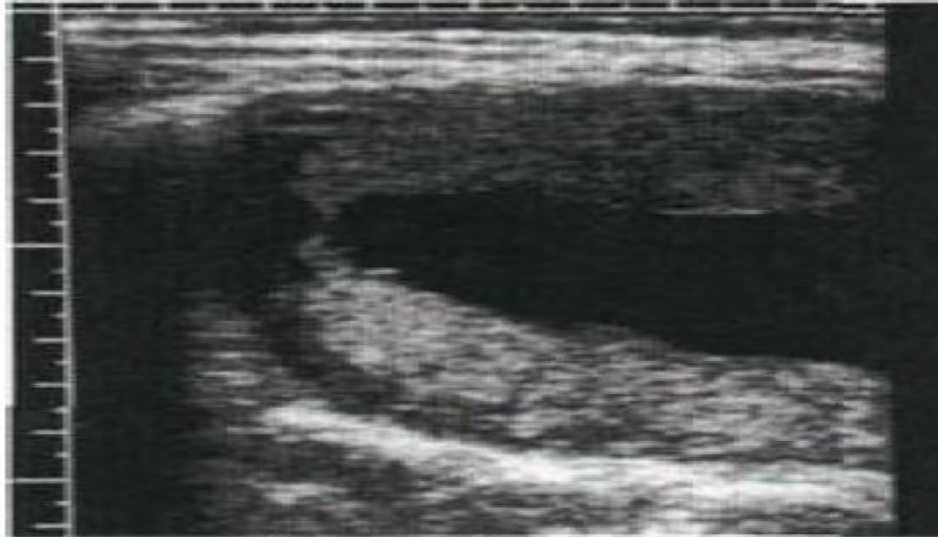

Figure 2-10 Succenturiate Lobe

Transverse TAS image showing a main placental lobe anteriorly and a smaller communicating placental lobe posteriorly((Devin 2005)

B .Placenta Membranacea

Also known as placenta diffusa. Classically, this term describes a thin membranous placenta covering the entire or greater part of the chorioamniotic membrane. The expression membranacea is somewhat misleading, for this form of placenta is not necessarily either thin or membranous. The essential feature of the anomaly is that all, or most of the chorioamniotic membranes are covered on their outer (endometrial) aspect by functioning chorionic villi. Exceptionally, there may be a focal thickening to form a placental disc, but more commonly the gestational sac is diffusely covered by villous tissue, albeit of varying thickness.

In nearly all instances there is recurrent vaginal bleeding in the late first and second trimesters the consequence of which is either spontaneous abortion or premature labor. The bleeding is due to the fact that the placenta membranacea must also, of necessity, be placenta previa. Fetal survival is usually hampered by prematurity and IUGR. (Devin 2005)

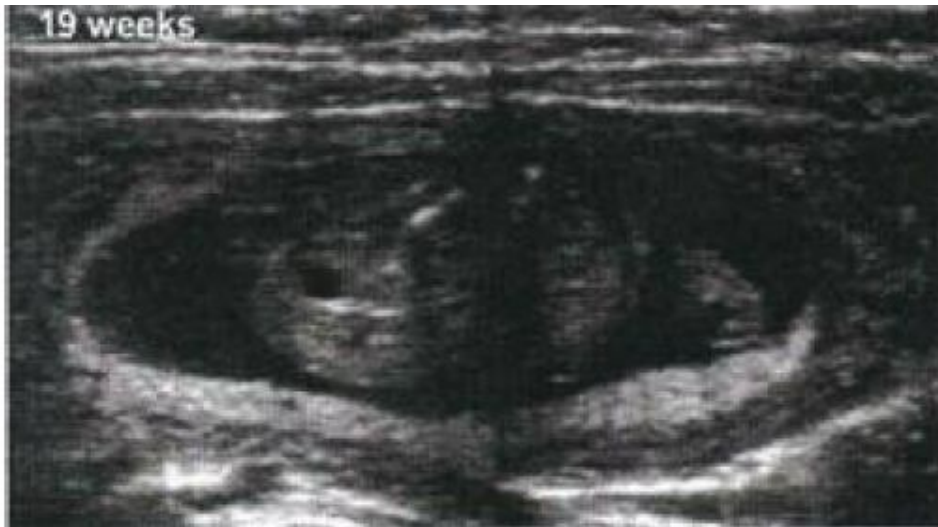

Figure 2-11 Membranacea Transverse TAS image of the uterus at 19 weeks gestation shows a thin posterior placenta that covers 60 - 60% of the perimeter of the uterus. (Devin 2005)

C .Extrachorial Placenta.

A. Normal placenta. The transition of membranous to villous chorion is at the placental edge . B Circummarginate placenta. The transition of membranous to villous chorion occurs central to the edge of the placenta, but the chorionic surface remains smooth. C. Circumvallate placenta. Appearance is as in B except for folding of the chorionic membrane. (From Callen 3rd Edition, fig. 20-12, pg. 446)

Antenatal diagnosis of this condition is exceedingly rare but the routine and extensive use of ultrasound in obstetrics will undoubtedly result in more cases being diagnosed prenatally. A review of the ultrasound literature reveals three reported cases since 1976. The diagnosis is established by noting placenta surrounding the entire gestational sac or uterine cavity. (Devin 2005)

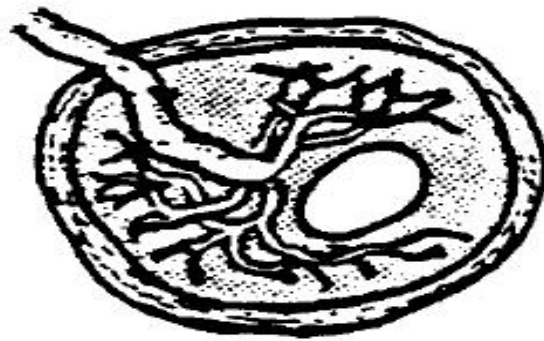
2.3.7 Placenta Annularis

Defines a ring-shaped placenta which surrounds the gestational sac. This type of placenta is considered by some investigators to be a variant

of placenta membranacea. It is associated with an increased risk of ante- and postpartum bleeding and IUGR. (Devin 2005)

2.3.8 Fenestrate Placenta

This is an exceptionally rare variant of placental development in which the central portion of a discoidal placenta fails to develop creating a large gap. Does not appearance to be of significance.



Figur 3-12 Fenestrate -Placenta

2.3.9 Circumvallate Placenta

The shape of a circumvallate placenta and the resultant sonographic appearance can be difficult to conceptualize. In this condition, the membranes, decidua, and at the periphery of the placenta lift away from the endometrium, becoming raised and folded back toward the center of the placenta along the fetal surface.

The shape is closely analogous to a mushroom cap (with the top of the cap against the endometrium and the stem side representing the chorionic surface). The circumvallate configuration may affect the entire circumference of

the placenta or only a portion of it. Little clinical significance has been related to the presence of a circumvallate placenta. Scans oriented radially to the placenta show a triangular tissue fold, thickest at the placental edge, tapering to an apex that points into the amniotic space and back toward the center of the placenta. Scans that intersect a peripheral arc of the placenta may show a continuous linear band just deep to the placenta, with both its surfaces outlined by amniotic fluid. Although this superficially may simulate a synechia, the fact that the free edge is curvilinear, following the contour of the placenta, as well as the triangular cross-section of the circumvallate placental fold, allow easy differentiation of these two conditions. (Devin 2005)

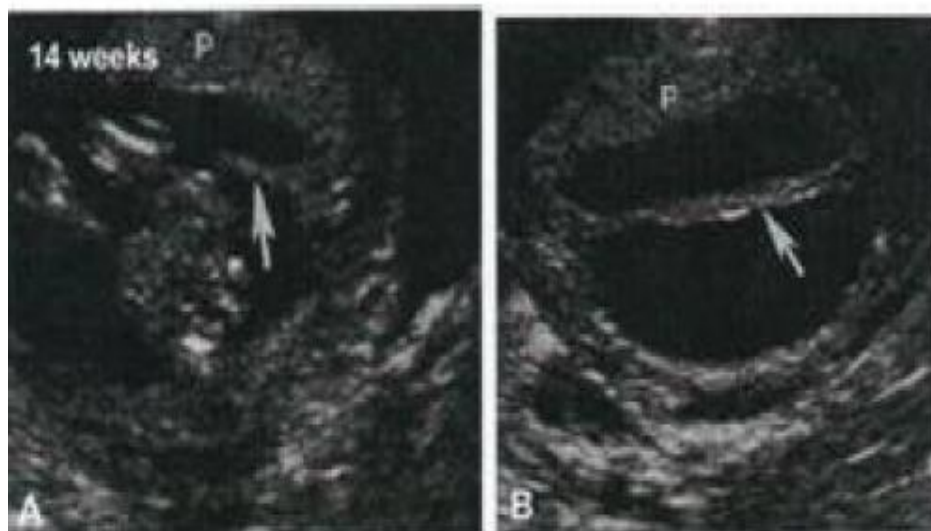


Figure 2-12 Circumvallate Placenta Sagittal (A) and transverse (B) scans @ 14 weeks show a thick membranous fold (arrows) involving the edge of the placenta. (Devin 2005)

2.3.10 Placenta Previa

Placenta previa describes a placenta that partially or completely covers the internal os. Three degrees of placenta previa are generally the internal os is completely covered by the placenta. Complete placenta

placenta may be either symmetric or asymmetric. Asymmetric placenta previa is indicated when the central portion of the placenta is over the os and equal portions of the placenta appears to be attached to the anterior and posterior walls of the lower uterine segment. With asymmetric, complete placenta previa, the placenta is anterior or posterior in relation to the internal os. The internal os is only partially covered by placenta (Devin 2005)

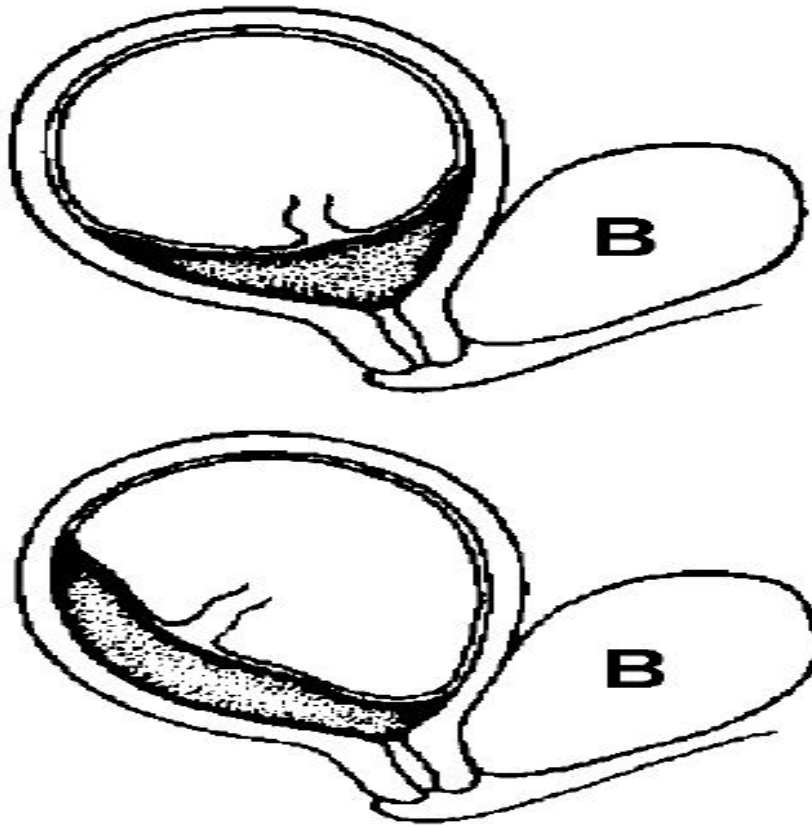


Figure 2-13 Marginal and complete placenta (Devin 2005)

2.2.11 . Low-Lying Placenta

The placenta is close to the edge of the internal os but does not extend over it. Lowlying placentas generally convert to higher positions by 34 weeks gestation. The incidence of placenta previa at the time of delivery is reported to be about 1%. Three factors which increase the relative risk of placenta previa are advanced maternal age, parity, and smoking. Multiparous women are twice as likely to have placenta previa than women delivering for the first time. A possible reason for this association is endometrial scarring which occurs with increasing age or repeated pregnancies. The scarring is thought to cause inadequate placental blood supply, for which the placenta compensates by becoming thinner and occupying a greater surface area of the endometrium. A consequence of greater placental surface area attachment is an increased chance for encroachment over the internal os. (Devin 2005)

The majority of patients with placenta previa present with painless vaginal bleeding near the end of the second trimester or early in the third trimester (antepartum hemorrhaging or APH) however placenta previa may remain asymptomatic until the onset of labour. The clinical course and management of placenta previa depends on several factors including the onset and severity of APH, the maturity of the fetus, and the degree of placenta previa. (Devin 2005)

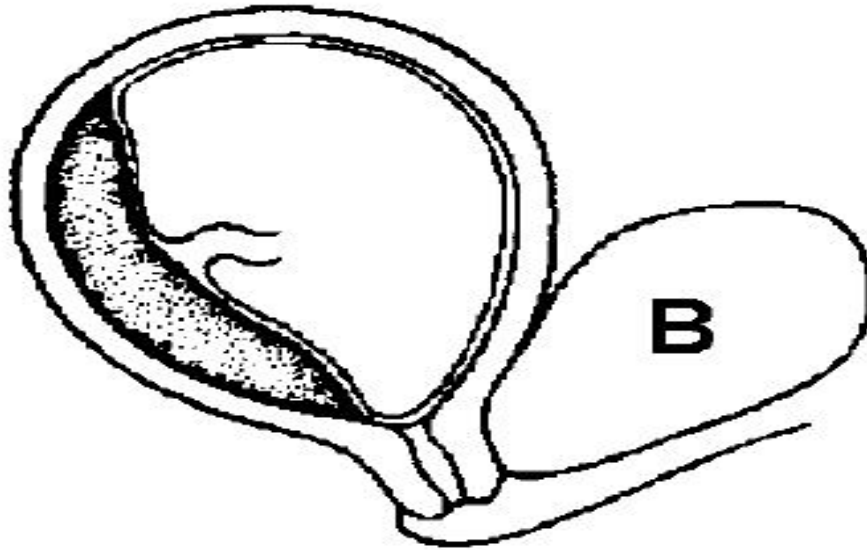


Figure 2-14 Low-lying posterior placenta (Devin 2005)

2.3.12 Ultrasound of placenta previa

Ultrasound is the imaging modality of choice for the prenatal diagnosis of placenta previa however the sonographer must be aware of technical limitations and common interpretation pitfalls leading to false positive and false negative diagnosis. The false negative rate for the detection of placenta previa is very low (U/S misses the diagnosis of placenta previa), and makes ultrasound a good screening tool to rule out the diagnosis. The most significant factors contributing to a relatively high false positive rate (U/S falsely indicates the diagnosis of placenta previa) include distortion of the lower segment by an overdistended bladder and focal myometrial contractions, and early diagnosis. (Devin 2005)

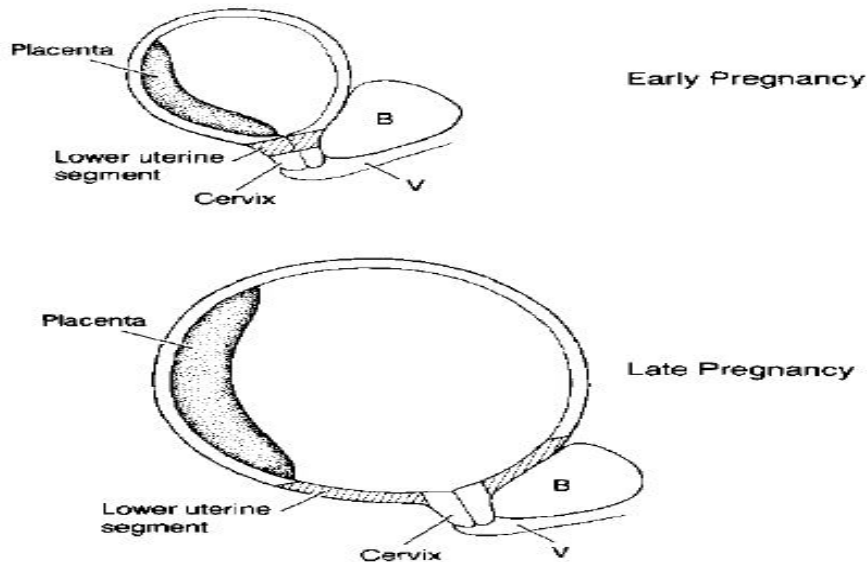


Figure 2-15 placental migration. (Devin 2005)

a. Bladder distention

Pushes the anterior wall of the uterus posteriorly towards the posterior wall with the net effect of bringing an anterior lower segment placenta artificially closer to the cervix and also compressing the anterior and posterior lower segment walls together and masking the true location of the internal os. For these reasons, when evaluating a placenta that reaches the lower segment of the uterus and appears to be low-lying or previa, the sonographer should re-evaluate the patient after she has voided (postvoid scans). In the majority of cases, the postvoid study will resolve the situation, with most placentas changing in appearance from previa or lowlying to normal (cases that remain suspicious should be evaluated with endovaginal (EVS) or transperineal (TPS) techniques). (Devin 2005)

b. Focal myometrial contractions

(FMC) can occur at anytime and in any part of the uterus, including the lower segment. The placenta - internal os relationship

should not be assessed in the presence of a FMC on the placental wall or lower uterine segment. Simultaneous contraction of the anterior and posterior lower segment walls (referred to as circumferential or symmetric lower uterine segment contractions) is a little more problematic since it may be more difficult to recognize by the inexperienced sonographer. Keep in mind that the true length of the cervix (internal to external os) should measure approximately 3 cm. If the cervix appears to be significantly longer than 3 cm, the sonographer should question the true location of the internal os since both bladder filling and lower segment contractions can artificially distort the location of the Focal myometrial contraction masks the true location of the internal os. B) Fifteen minutes later, the contraction is gone and the location of the internal os can be appreciated. (Devin 2005)

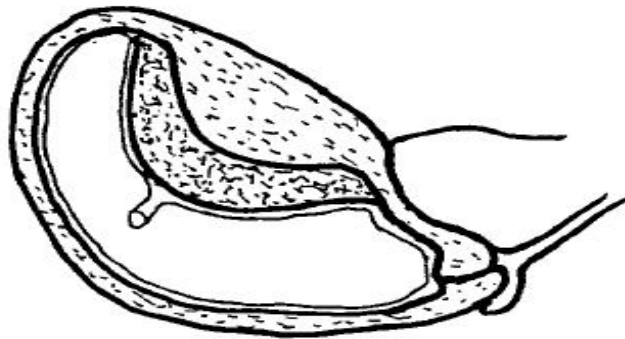


Figure 2-16 FMC. (Devin 2005)

2.3.13 Placenta Accreta

Placenta accrete is defined as the abnormal adherence of part or all of the placenta to the underlying uterine wall. A deficiency of decidua at the implantation site may result from implantation of the placenta close to or cover the cervix (placenta previa). A similar situation may arise when implantation occurs on scars from a previous cesarean section. Owing to the absence of decidua, the placenta does not separate normally from the underlying uterine wall following parturition, an event that can result in life-threatening bleeding. (Rubin 1999).

Placenta accreta is sub classified according to the depth that the villi invade into the myometrium:

- a. Placenta accretes: refers to the attachment of villi to the myometrium without further invasion.
- b. Placenta increta: defines villi invading the underlying myometrium.
- c. Placenta percreta: is a condition in which the villi penetrate the full thickness of the uterine wall. (Rubin & Farber 1999).

The placental villi in all these placental disorders are normal and show no evidence of trophoblastic proliferation. (Rubin & Farber 1999).

Most patients with placenta accreta have a normal pregnancy and delivery. However complications may occur during pregnancy, delivery, or especially in the immediate postpartum state. Bleeding in the third trimester is the most common presenting sign before delivery.

Uterine rupture, before, during, or after labor, occurs in 15% of patients with placenta accrete. Substantial fragments of placenta may remain adherent following delivery and are a source of postpartum

hemorrhage. Placenta accreta is a serious complication and is associated with a maternal death. (Rubin 1999).

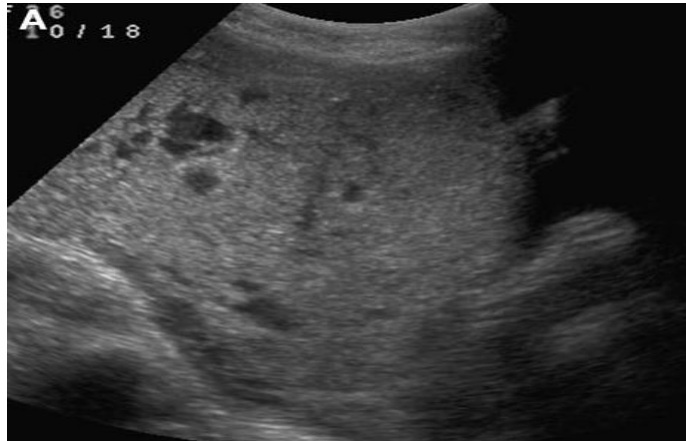


Figure 2-17: Placenta accreta at 26 weeks gestational age. A transabdominal sagittal image shows a thickened placenta with cystic spaces. There is loss of the normal myometrium anteriorly..(Chie 2006)

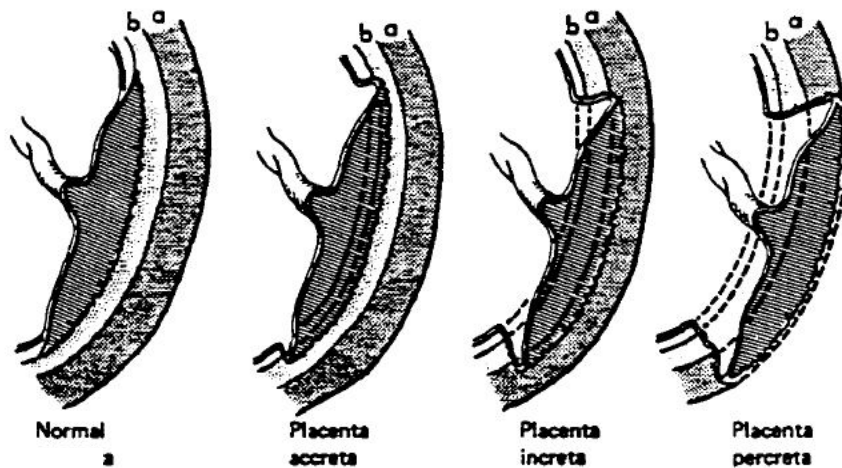


Figure 2-18 Abnormal placental attachment

2.3.14 Villitis

Is the inflammation of the villi. Infection of the villi results from endometritis or transeplacental passage of organisms delivered by way of the maternal circulation. The process is frequently focal. While the infection cannot be demonstrated in most cases, the microorganisms causing this type of infection include: bacteria, viruses, parasites and protozoa and fungi. The most important consequence of hematogenous placental infection is the establishment of an inflammatory focus, which can then secondarily infect the fetus. Approximately 30% of the villi must be destroyed before perinatal mortality is significantly increased. (Rubin & Farber 1999). Placenta Creta

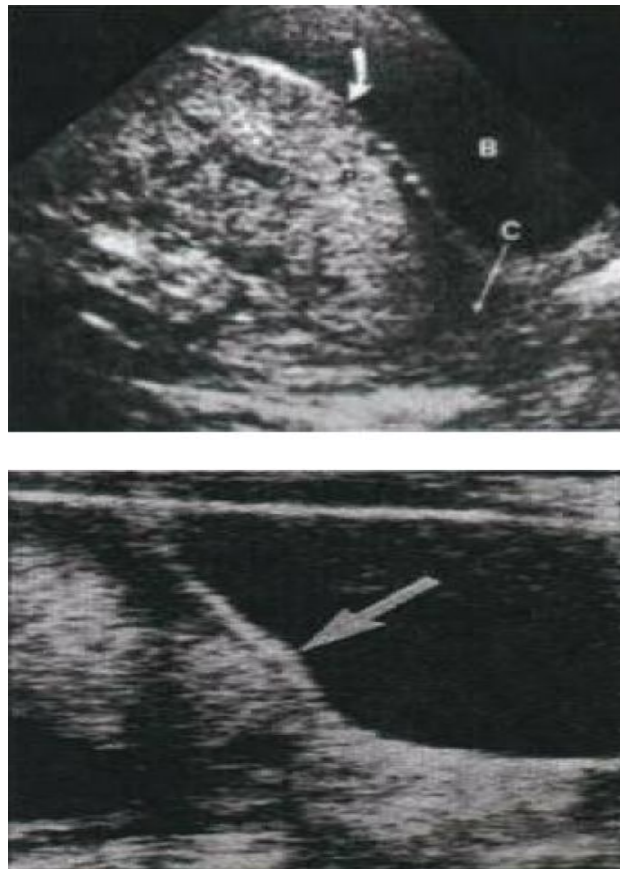


Figure 2-19 Placenta increta. The normal placenta - uterine wall interface is absent(Devin 2005)

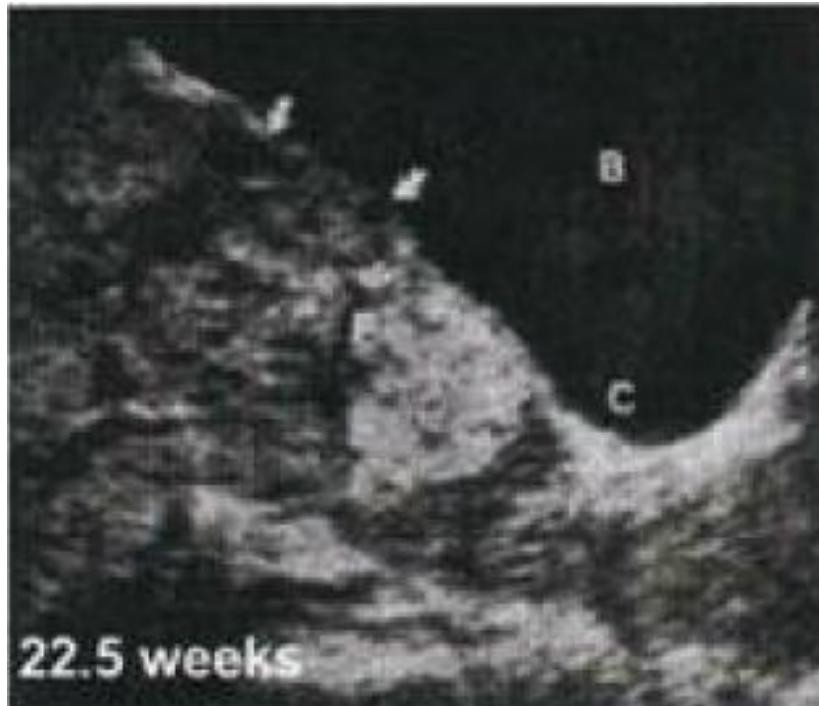

Figure 2-20 Placenta Previa and Percreta (Devin 2005)

Ultrasound/Doppler: -

Prenatal sonographic diagnosis of placenta accreta is usually in the late second or third trimester based on the appearance of the placental interface with the anterior uterine wall and distended bladder. In patients with previous C-S delivery, a low-lying gestational sac on a scan at 10 weeks or earlier suggests the possibility of placenta accreta. A low position of the gestational sac can occur in other clinical situations including abortion in progress, cervical pregnancy, and normal pregnancy. (Burwin Institute Notes.)

2.3.15 Chorioamnionitis

Chorioamnionitis refers to inflammation of the placental amnion and chorion and the extraplacental membrane. It is usually the result of an ascending infection from the maternal birth canal, commonly owing to premature rupture of the membranes. In this type of infection, the

inflammatory process affects primarily the membranes (chorioamnionitis) rather than the chorionic villi. Acute chorioamnionitis is important because of its occurrence in 20% of placentas and its clear association with preterm labor, fetal and neonatal infections, and intrauterine hypoxia. The risks of chorioamnionitis to the fetus include:

- a. Pneumonia after inhalation of infected amniotic fluid.
- b. Skin or eye infections from direct contact with organisms in the fluid.
- c. Neonatal gastritis, enteritis, or peritonitis from ingestion of infected fluid.

Major risks to the mother are intrapartum fever, postpartum endometritis, and pelvic sepsis with venous thrombosis. (Rubin & Farber 1999).

2.4 Placental Size and Growth

There is less emphasis nowadays in measurements of the placenta largely because the information is of limited diagnostic value. Thus, the placenta is not routinely measured. The most popular measurement is placental thickness (data on placental area, volume, and weight estimates have all been studied and reported in the literature). As a guideline, placental thickness should be measured if the placenta appears to be either thick or thin. Placental thickness measurements should be made near the mid portion or center of the placenta with one caliper placed at the amniochorionic surface (chorionic plate) and the second caliper placed at the basal surface perpendicular to the amniochorionic surface. The measurement should exclude retroplacental veins, myometrium, fibroids, and contractions of the uterus that might incorrectly increase the measurement. In a normal pregnancy, placental thickness is measured with one caliper placed at the amniochorionic surface (chorionic plate) and the second caliper

placed at the basal surface perpendicular to the amniochorionic surface. The measurement should exclude retroplacental veins, myometrium, fibroids, and contractions of the uterus that might incorrectly increase the measurement. In a normal pregnancy, placental The graph shows there is significant variance in normal placental thickness at different gestational ages. This graph indicates the placenta appears to grow until term but at a slower rate in the third trimester. A placental thickness greater than 4 cm is considered abnormal at any gestational age. Less than 2.5 cm at or greater than 35 weeks is considered too thin The four conditions most commonly associated with placental thickening are:

- a) Diabetes mellitus, especially gestational diabetes and class A, B, and C.
- b) Immune and nonimmune fetal hydrops
- c) Fetal infections (e.g. cytomegalovirus)
- d) Chromosomal abnormalities, especially triploidy

Small or thin placentas are most commonly associated with maternal hypertensive disease, severe IUGR, and severe diabetes mellitus (class D, E, R). Rarely, a thin placenta may be due to a membranous placenta (placenta membranacea or diffusa) which is a thin, poorly functional placenta that covers the entire surface of the chorionic sac. The placenta may also appear unusually thin with severe polyhydramnios as it is

stretched over a large surface area of the uterine wall (Devin 2005).

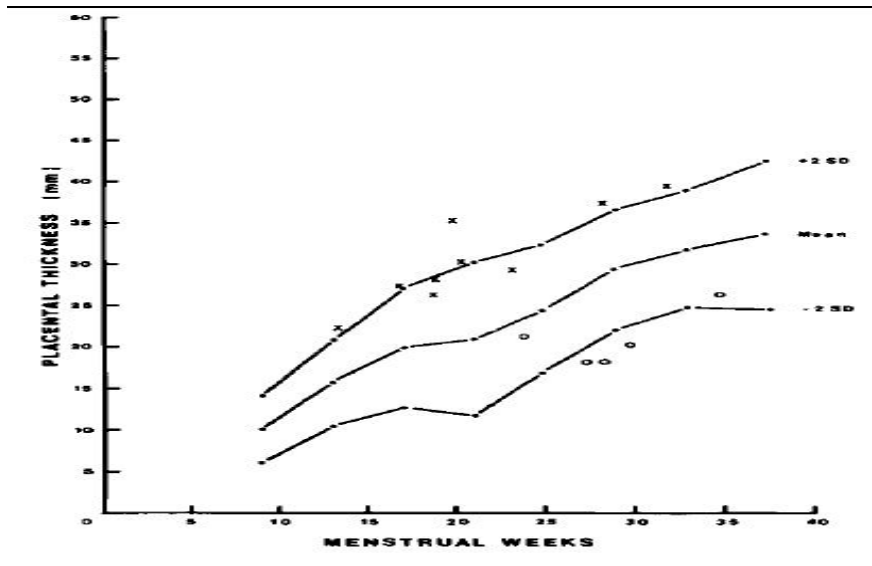


Figure 2-20 Relationship of Placental thickness to menstrual

(Devin 2005)

2.5 Previous Study

Abu et al (2009) performed a study to investigate the relationship between placental thickness and estimated fetal weight in normal pregnant Nigerian women. They scan six hundred and forty five Nigerian women with singleton pregnancies in the second and third trimesters by ultrasound. Their results showed that both placental thickness and estimated fetal weight increased in fairly linear manner with gestational age. They found a significant positive correlation between placental thickness and estimated fetal weight in the second and third trimesters ($p < 0.05$). Regression analysis yielded linear mathematical relationships between estimated fetal weight and placental thickness in the second and third trimesters, but the marked variations in fetal weights corresponding to particular placental thickness limit the usefulness of this relationship

Ohagwu et al (2009) investigated the relationship between placental thickness and fetal growth parameters in normal singleton Nigerian fetuses. The pregnancies were in the second and third trimesters, and were not complicated by either maternal or fetal disease. Their study shows that there was a fairly linear increase in placental thickness with gestational age. There was significant positive correlation between placental thickness and, biparietal diameter (BPD) and abdomen circumference (AC) in the second and third trimesters with both parameters having identical relationship with placental thickness. Placental thickness has a strong positive correlation with BPD and AC

Hammad(2008) performed a study to evaluate Placental thickness in the third trimester, his results showed linear relationship between Placental thickness in mm and gestational age in weeks. He found that Placental thickness increase with the 28 fetal age. He concluded that the

measurement of the placental thickness is an important parameter for estimating gestational age in normal singleton pregnancies along with other parameters.

Elamin (2012) studied the relationship between Placental thickness and fetal age in Sudanese women, she found that the placental thickness increase with gestational age. She also found that there is significant positive correlation between Placental thickness and LMP, biparietal diameter (BPD), AC and femur length (FL). Her study showed linear regression between Placental thickness and LMP, biparietal diameter (BPD), abdomen circumference (AC) and femur length (FL).

Chapter Three

Materials and Method

3.1 Population of the Study

This descriptive study includes fifty Sudanese pregnant women in second and third trimesters came to the ultrasound department for regular checkup. The selected women were attending with viable singleton and uncomplicated pregnancies.

3.2 Area and duration of the Study

The study is held in ultrasound department in Omdurman Maternity Hospital in Sudan, from June to November 2016 .

3.3 Study sample size:

50 pregnant women present to ultrasound department by single random sampling.

3.4 Equipments

Sonography was carried out on each patient included in the study using ultrasound machine Toshiba-power vision-6000, transabdominal convex transducer with frequency of 3.5 MHz and ultrasound gel

3.5 Method of the study:

Each patient will be scanned twice in an international scanning guidelines and protocols. first by student and then by qualified sonologist to confirm the finding and diagnosis.

3.6 Data collection:

Direct ultrasound scanning for the study sample and by data collection sheet (questionnaire).

3.7 Data storage:

The storage of data will be in different types of data means such as data collection sheet , ultrasound image ,CD and diskette.

3.8 Method of Data Collection

In this study, fifty Sudanese pregnant women scanned by Transabdominal probe in second and third trimesters. The fetal weight was estimated by measuring the biparietal diameter (BPD) , abdomen circumference (AC). The placental thickness was measured in longitudinal section at the point of umbilical cord insertion. Other variables including maternity age, gravidity, were also included in the data collecting sheet.

3.9 Data Analysis

After measurements and data collection, the data is analyzed by using Statistical Package for Social Sciences (SPSS).

3.10 Ethical consideration:

The study proposal was reviewed and ethically approved by the scientific and ethical committee of sudan university of sciences and technology and ethical committee of hospitals.

Chapter Four

Results

Table (4.1) frequency distribution of age groups

Age group	Frequency	Percent	Valid Percent	Cumulative Percent
15-20 years	3	6.0	6.0	6.0
21-25 years	8	16.0	16.0	22.0
26- 30 years	14	28.0	28.0	50.0
31- 40 years	23	46.0	46.0	96.0
more than 40 years	2	4.0	4.0	100.0
Total	50	100.0	100.0	
Minimum = 19 , maximum = 50 , means= 30.46				

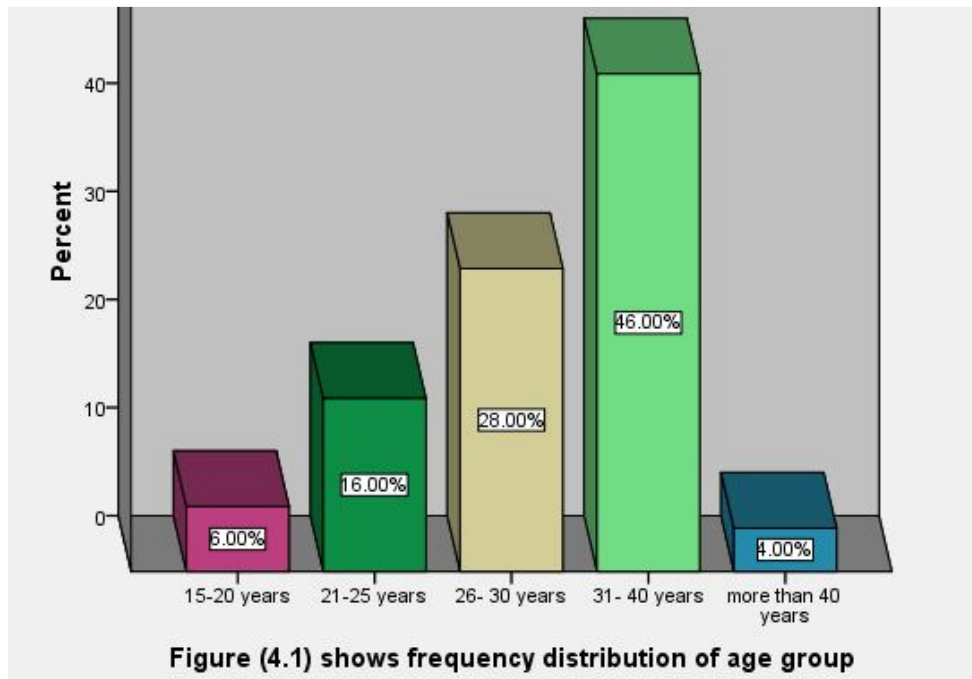


Table (4.2) frequency distribution of site of placenta

Site of placenta	Frequency	Percent	Valid Percent	Cumulative Percent
Abnormal	2	4.0	4.0	4.0
Normal	48	96.0	96.0	100.0
Total	50	100.0	100.0	

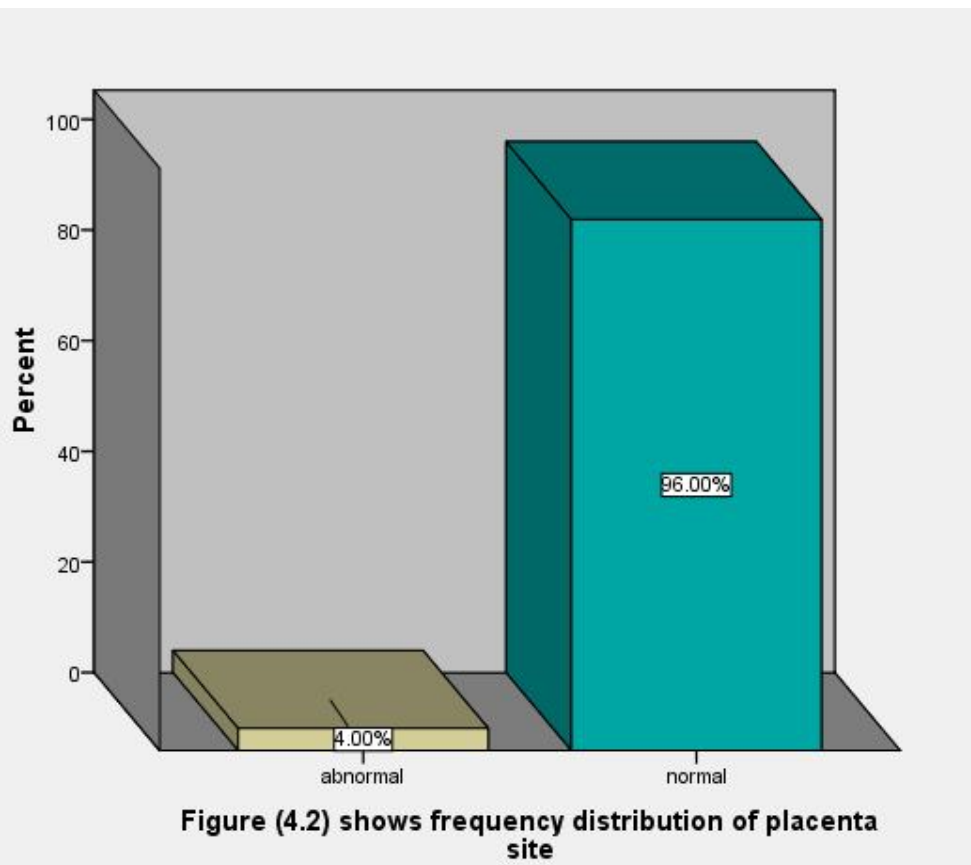


Table (4.3) frequency distribution of echogenicity of placenta

Echogenicity	Frequency	Percent	Valid Percent	Cumulative Percent
Heterogeneous	19	38.0	38.0	38.0
Homogeneous	31	62.0	62.0	100.0
Total	50	100.0	100.0	

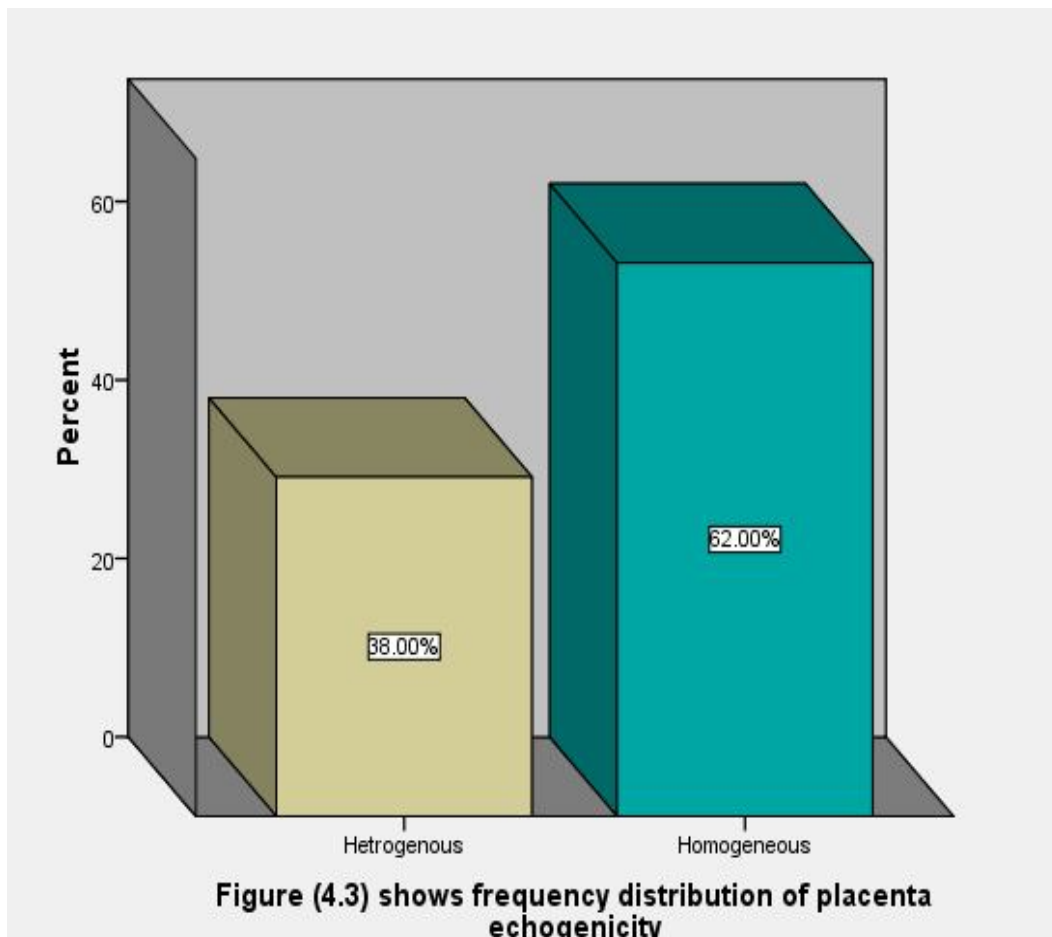
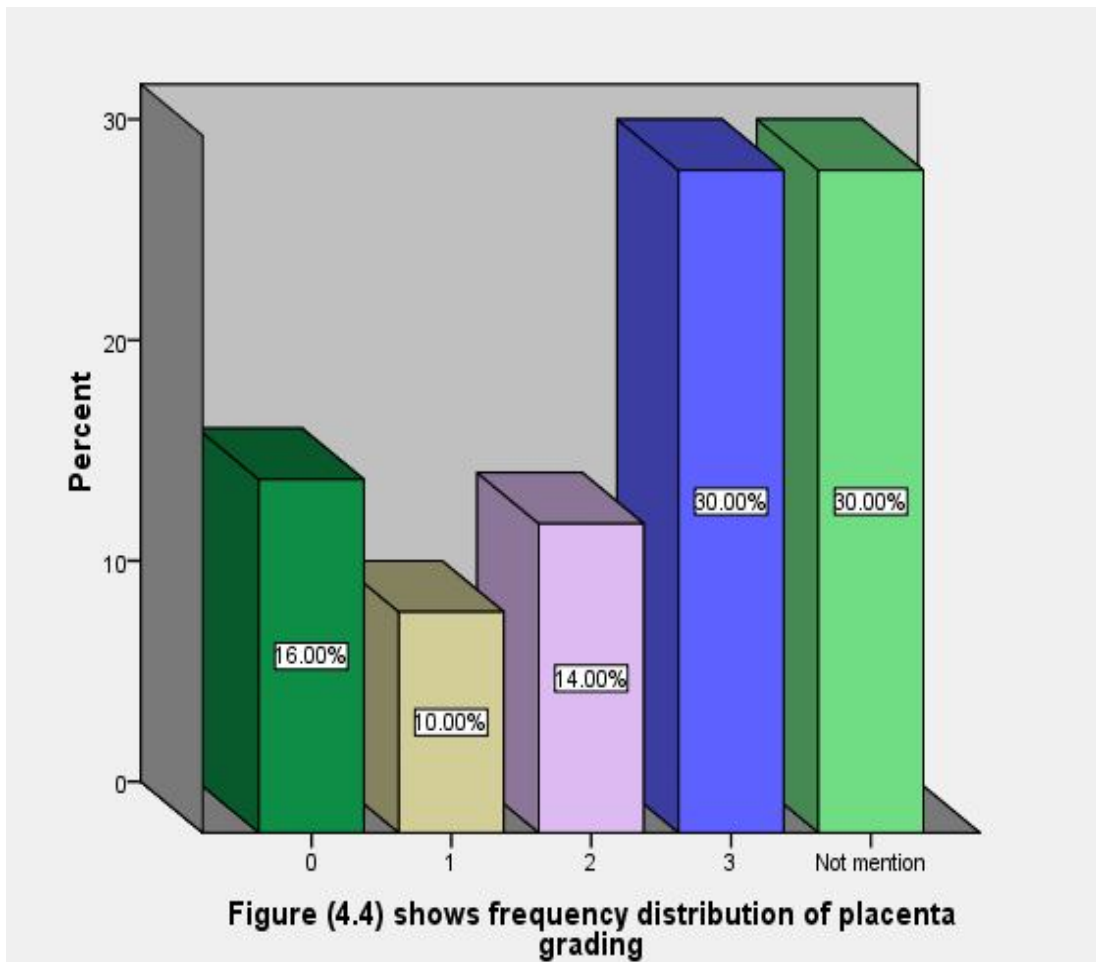


Table (4.4) frequency distribution of grading of placenta

Placenta grading	Frequency	Percent	Valid Percent	Cumulative Percent
0	8	16.0	16.0	16.0
1	5	10.0	10.0	26.0
2	7	14.0	14.0	40.0
3	15	30.0	30.0	70.0
Not mention	15	30.0	30.0	100.0
Total	50	100.0	100.0	



Tabal (4.5) a- frequency distribution of placenta Thickness by mm

Placenta thickness range	Frequency	Percent	Valid Percent	Cumulative Percent
15-20 mm	4	8.0	8.0	8.0
21-25 mm	6	12.0	12.0	20.0
26- 30 mm	13	26.0	26.0	46.0
31- 40 mm	16	32.0	32.0	78.0
more than 40 mm	11	22.0	22.0	100.0
Total	50	100.0	100.0	
Minimum = 19 ,maximum = 50 , means = 33.74 , STD= 9.33				

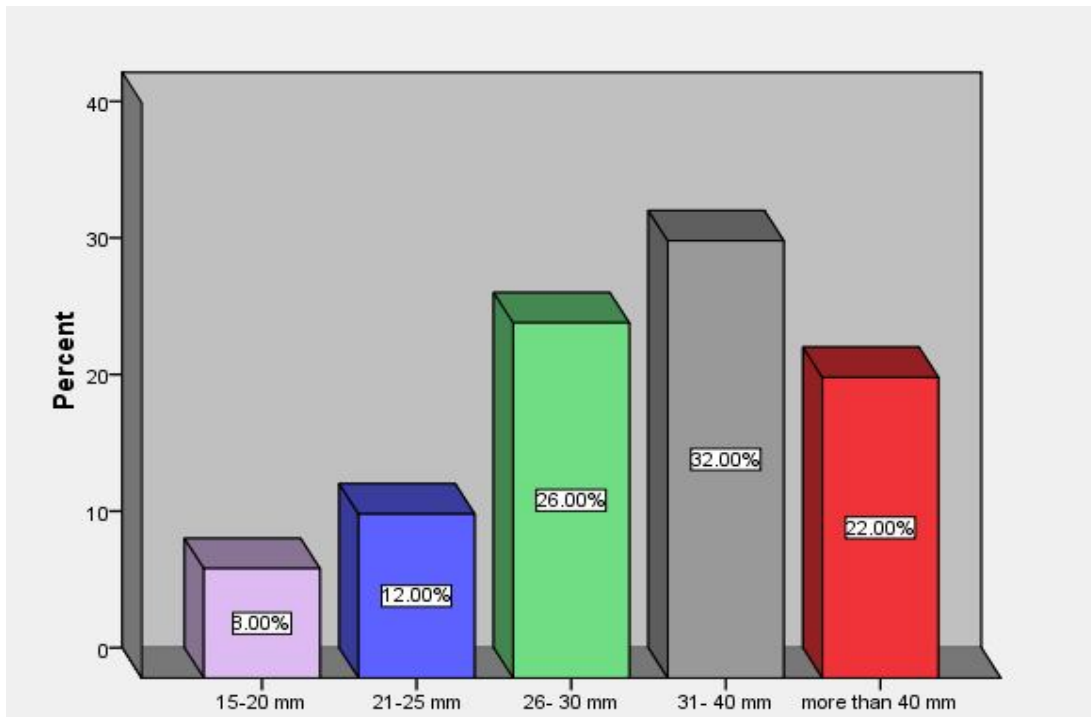


Figure (4.5) a- shows frequency distribution of placenta thickness by mm

Table (4.5) b- frequency distribution of placenta thickness (normal or abnormal)

Thickness of placenta	Frequency	Percent	Valid Percent	Cumulative Percent
Normal	39	78.0	78.0	78.0
abnormal	11	22.0	22.0	100.0
Total	50	100.0	100.0	

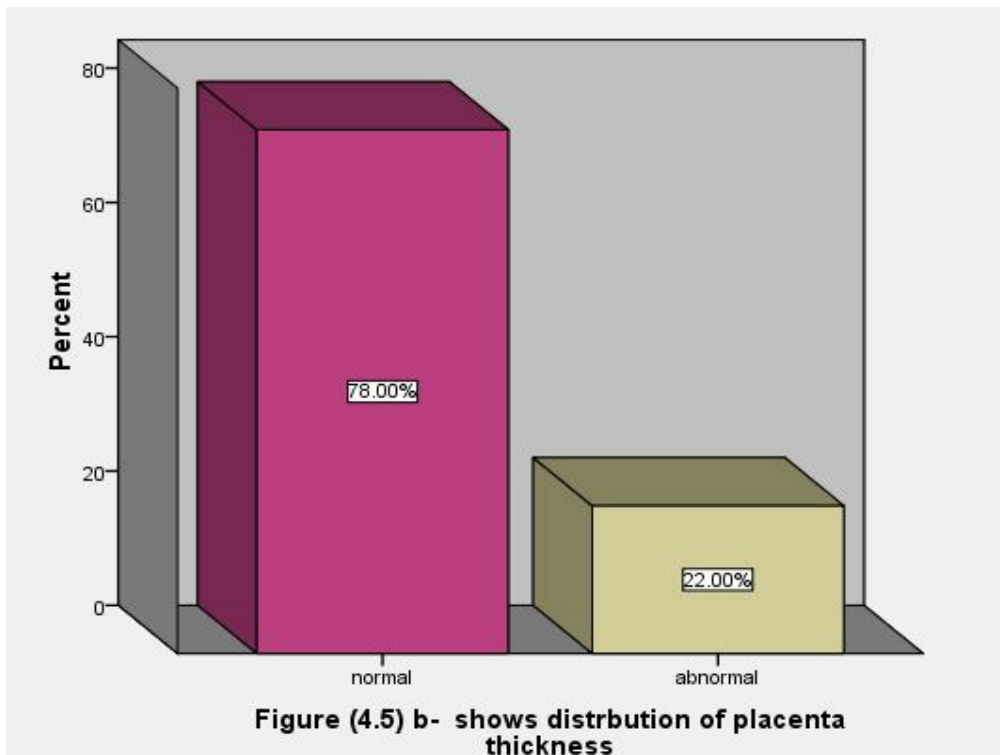


Table (4.6) frequency distribution of gestational age per weeks

Gestational age per weeks	Frequency	Percent	Valid Percent	Cumulative Percent
15-20 weeks	13	26.0	26.0	26.0
21-25 weeks	8	16.0	16.0	42.0
26- 30 weeks	12	24.0	24.0	66.0
31- 40 weeks	17	34.0	34.0	100.0
Total	50	100.0	100.0	
Minimum = 15, maximum =40 ,mean= 27.92, std= 8.285				

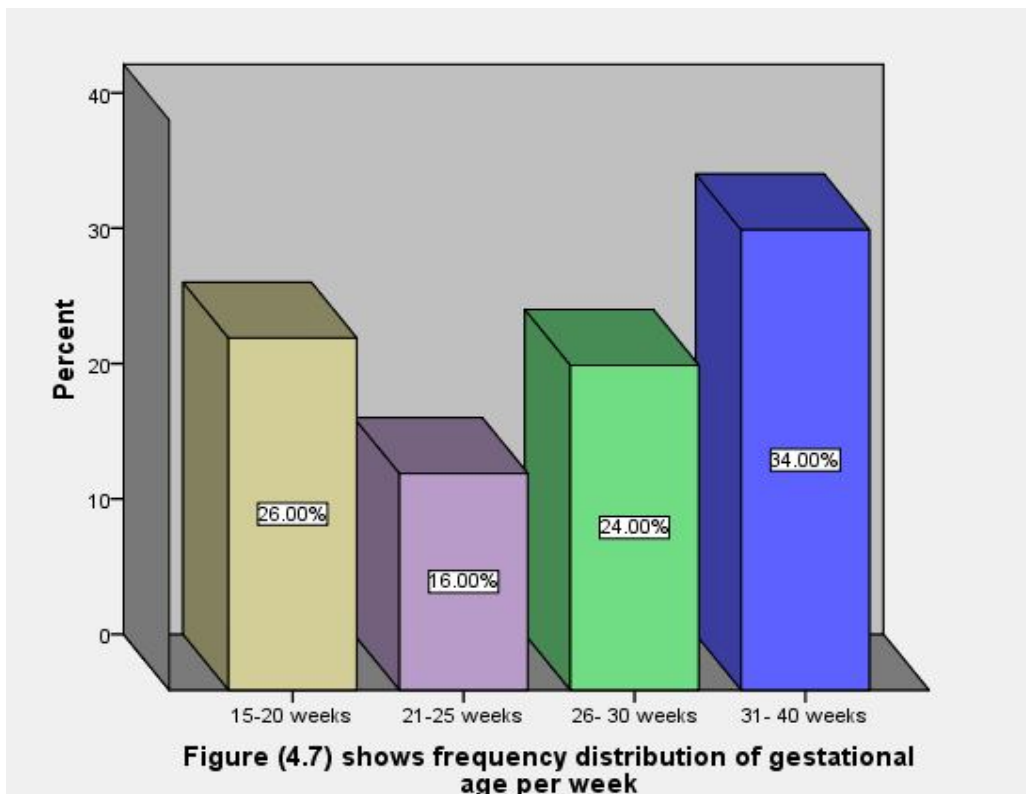


Table (4.7) mean , minimum ,maximum and Std for AFI & fetal weight

	N	Minimum	Maximum	Mean	Std. Deviation
AFI	50	13.00	27.00	19.1200	3.58364
Weight	50	.07	4.50	1.6954	1.45050
Valid N (listwise)	50				

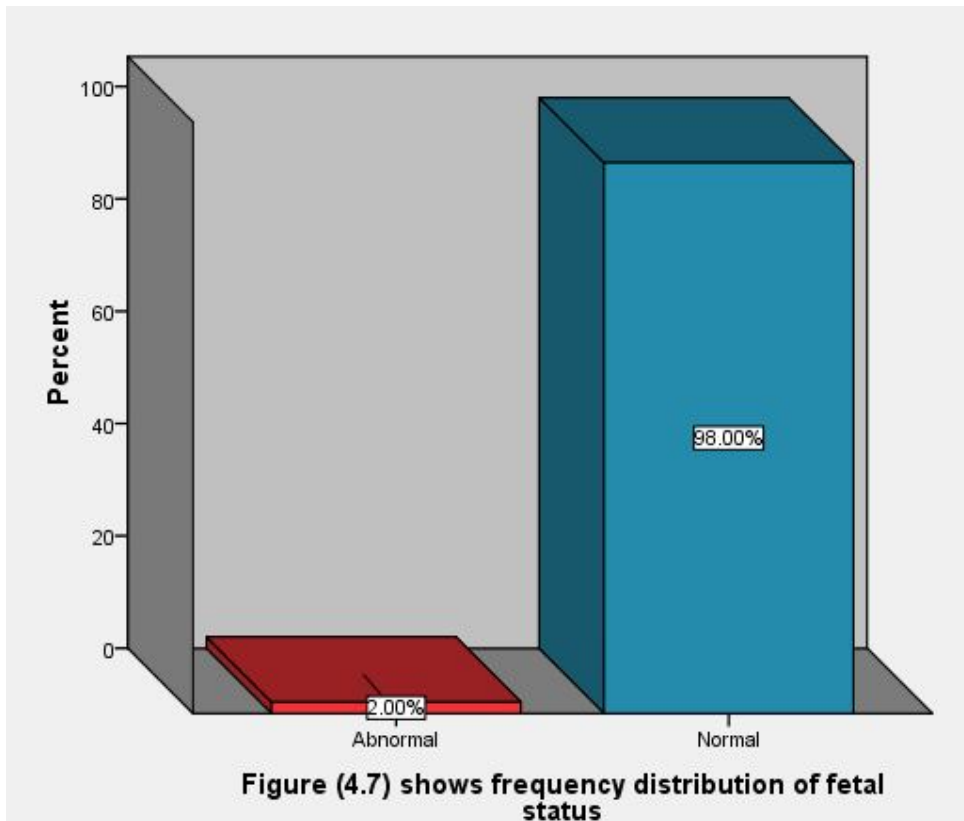


Table (4.8) Frequency distribution of fetal status

Status	Frequency	Percent	Valid Percent	Cumulative Percent
Abnormal	1	2.0	2.0	2.0
Normal	49	98.0	98.0	100.0
Total	50	100.0	100.0	

Table (4.9) a. crosstabulation echogenicity and gestational age

Echogenicity	Gestational age				Total
	15-20 weeks	21-25 weeks	26- 30 weeks	31- 40 weeks	
Hetrogenous	0	0	3	16	19
Homogeneous	13	8	9	1	31
	13	8	12	17	50

Table (4.9) b. chi square echogenicity and gestational age

	Value	df	Asymp. Sig. (2-sided)
Pearson Chi-Square	36.455 ^a	3	.000
Likelihood Ratio	45.304	3	.000
N of Valid Cases	50		
a. 4 cells (50.0%) have expected count less than 5. The minimum expected count is 3.04.			

Table (4.10) a. crosstabulation echogenicity and grading of placenta

Echogenicity	Grading					Total
	0	1	2	3	Not mention	
Hetrogenous	0	2	5	12	0	19
Homogeneous	8	3	2	3	15	31
	8	5	7	15	15	50

Table (4.10) b. Chi square echogenicity and grading

	Value	Df	Asymp. Sig. (2-sided)
Pearson Chi-Square	28.656 ^a	4	.000
Likelihood Ratio	36.288	4	.000
N of Valid Cases	50		
a. 6 cells (60.0%) have expected count less than 5. The minimum expected count is 1.90.			

Table (4.11) a. cross tabulation gestational age and thickness of placenta

Thickness	Gestational age				Total
	15-20 weeks	21-25 weeks	26- 30 weeks	31- 40 weeks	
15-20 mm	4	0	0	0	4
21-25 mm	5	1	0	0	6
26- 30 mm	4	6	3	0	13
31- 40 mm	0	1	7	8	16
more than 40 mm	0	0	2	9	11
	13	8	12	17	50

Table (4.11) b. chi square echogenicity and grading

	Value	Df	Asymp. Sig. (2-sided)
Pearson Chi-Square	55.467 ^a	12	.000
Likelihood Ratio	63.723	12	.000
Linear-by-Linear Association	35.330	1	.000
N of Valid Cases	50		

a. 19 cells (95.0%) have expected count less than 5. The minimum expected count is .64.

Table (4.12) Correlations thickness and fetal weight

		Thickness	Wight
thickness	Pearson Correlation	1	.855**
	Sig. (2-tailed)		.000
	N	50	50
Weight	Pearson Correlation	.855**	1
	Sig. (2-tailed)	.000	
	N	50	50

** . Correlation is significant at the 0.01 level (2-tailed).

Table (4.13) Correlations grading and fetal weight

		Weight	Grade
Wight	Pearson Correlation	1	-.102
	Sig. (2-tailed)		.482
	N	50	50
Grade	Pearson Correlation	-.102	1
	Sig. (2-tailed)	.482	
	N	50	50

Table (4.14) Correlations grading and AFI

		Thickness	AFI
Thickness	Pearson Correlation	1	.406**
	Sig. (2-tailed)		.003
	N	50	50
AFI	Pearson Correlation	.406**	1
	Sig. (2-tailed)	.003	
	N	50	50

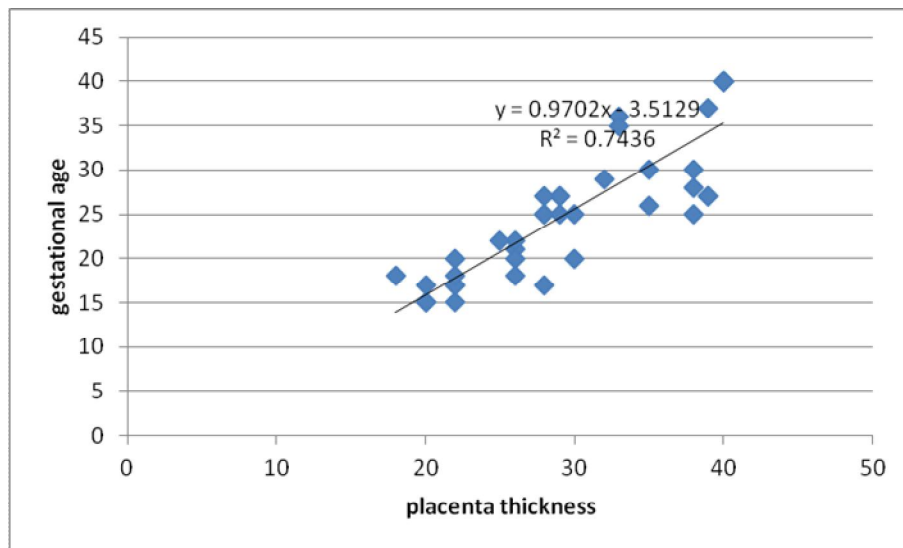
** . Correlation is significant at the 0.01 level (2-tailed).

Table (4.15) correlation between thickness mm and gestational age

Correlations			
		thickness	GA
Thickness	Pearson Correlation	1	.870**
	Sig. (2-tailed)		.000
	N	50	50
GA	Pearson Correlation	.870**	1
	Sig. (2-tailed)	.000	
	N	50	50

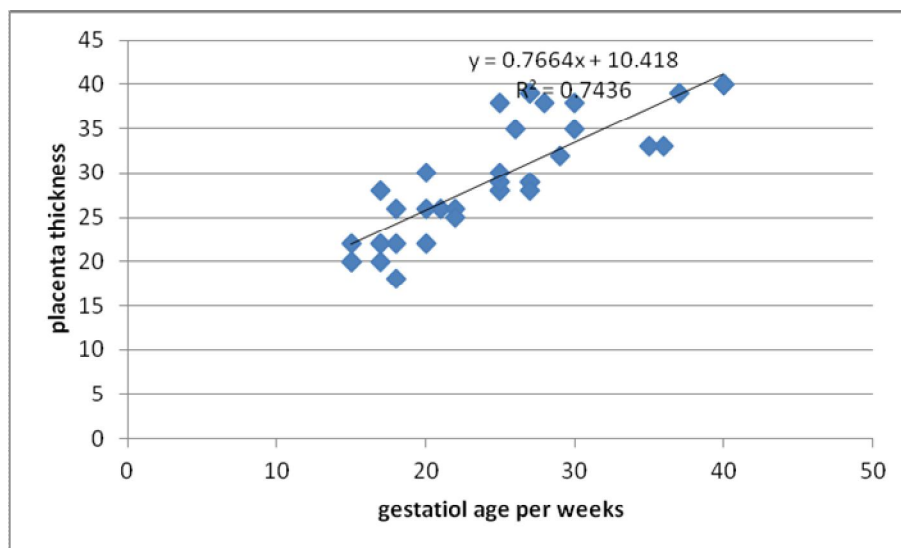
** . Correlation is significant at the 0.01 level (2-tailed).

Figure (4.8) a- shows regression equation between placenta per mm thickness and GA per week



****Gestational age per weeks = placenta thickness by mm X 0.9702x-3.5129**

Figure (4.8) b- shows regression equation between placenta per mm thickness and GA per week



**** Placenta thickness per mm= gestational age per week 0.7664x+ 10.418****

Chapter five

Discussion, conclusion and Recommendations

5.1 Discussion:

Evaluation of Placenta in pregnant ladies is very crucial because it's associated with considerable maternal & fetal morbidity and mortality.

The research include 50 pregnant woman were selected to be the sample unit in this study and the results of sonographic finding were documented and analyzed as follow:

The study found that the frequency distribution of age group between 12-20 years old and the group of age more than 40, majority of sample in this study is in age group of 31-40 years by percent (46%) and the little group is more than 40 years old by percentage (4%). figure (4.1).

The study found that the frequency distribution of placenta site which it indicates that the patients majority of site is normal, (96%), and the abnormal site is only (4%) had. in figure (4.2).

The study found that the frequency distribution of echogenicity of placenta which explained that the large group present homogenous texture (62%) and the rest is heterogamous (38%) texture of placenta echogenicity. in figure (4.3).

The study found that the frequency distribution of placenta grading, which indicate that the percentage of grade 0 was (16%), grade I was (10%), grade II was (14%) and grade III was(30% in figure (4.4).

The study found that the frequency distribution of range of placenta thickness by mm in the total of 50 patients (100%), when the thickness of placenta is (21-25 mm) the percentage is (8%). And(21-25 mm), (26-30 mm), (31- 40 mm) and (more than 40 mm) was 12%, 26%, 32% and

22% is respectively, and the results in figure (4-1) indicate that the most frequency was in thickness of placenta (31- 40 mm). figure (4.5 a).

We found that the frequency distribution of normal and abnormal placenta thickness, which represent that the normal placenta thickness was (78%) while the rest is abnormal, but the abnormal placenta doesn't lead to any abnormality of maternal or fetus which need more researches and studies to understand this characterize in Sudanese women. figure (4.5 b).

The study found that the frequency distribution of gestational age per weeks, in the group of gestational age (15-20 weeks) percent is 26% and in groups (21-25 weeks), (26- 30 weeks) and (31- 40 weeks) are 16%, 24% and 34% respectively, the majority is occur in gestational age (15- 20 weeks) in figure (4.6).

The study found that the comparative between fetus weight and amniotic fluid index which indicate that that patients have normal amniotic fluid index if we compare with fetus weight by mean about (19.12) because if it less than 5 that mean oliguhydrominous and if it more than 25 it considered as polyhydromnious. Table (4.7).

The study found that the frequency distributions of fetal status which indicate that there is 98% are normal status while the a few rest are abnormal. Table (4.8).

The study found that the indicates the crosstabulation of echogenicity and gestational age which proved that heterogeneous echogenicity of placenta are increased with increasing gestational age Table. (4.9 a).

The study found that the chi square echogenicity and gestational age which shows that there is significant change in placenta echogenicity with gestational age. Table (4.9 b).

The study found that the crosstabulation echogenicity and grading of placenta which show that the heterogeneous echogenicity increase while the placenta grading increased also Table. (4 .10 a) .

The study found that the chi square echogenicity and placenta grading which shows that there is significant change in placenta echogenicity with increase placenta grading. Table (4.10 b) .

The study found that the cross tabulation gestational age and thickness of placenta which indicate that the placenta thickness increase with through the increasing of the fetal age and chi square test in table (4.11 b.) indicate that this done by χ^2 test. Table (4.11 a).

The study found that the correlations between thickness of placenta and fetal weight which show that the placenta thickness increase with increasing of fetus weight this result is similar to Nigerian study done by Abo et al (2009) in Nigeria .Both studies found positive significant correlation between placental thickness and estimated fetal weight. Table (4.12)

The study found that the Table (4.13) Correlation placenta grading and fetal weight which show the placenta grading progress while the fetal age increase. Table (4.13).

The study found that the Correlations placenta grading and Amniotic Fluid Index, from the statistical study and analysis that done , it was found that there is a relationship between placenta grading and Amniotic Fluid Index other side. Table (4.14) .

The study found that the cross tabulation thickness of placenta and gestational age which indicate that the placenta thickness increase through the increasing of the fetal age and χ^2 square test in.which

typically go with those studies where done by Ohagwu et al 2009 , Hammad 2008 and Elamin 2012 , all studies concurred in that the placental thickness increase with the increase do fetal age Table (4.15) .

The study found that the regression equation between placenta thickness per mm and gestational age per week, and the scatter plots indicate that there is linear equation show that when the is increase of placenta thickness 1mm the gestational age increase with rate equal .0.74 for each week . figure (4.8 a)

The study found that the regression equation between gestational age per week placenta thickness per mm and the scatter plots indicate that when the gestational age increased one week the placenta thickness increase with rate equal .0.74 for mm also. There is linear association between gestational age and placental thickness with rate equal 0.74,36 .gestational age per week equal 0.97,2 and placental thickness equal +3.5129. figure (4.8 b).

5.2 Conclusion:

The placenta is an important organ that connects the developing fetus to the uterine wall to allow nutrients uptake, waste elimination and gas exchange via the mother blood.

This study concluded that ultrasound has an important role in diagnosing and evaluate the placental development.

The study found that there is positive significant correlation between placental thickness and fetal age. Also the study showed that there is positive significant correlation and close association between the fetal weight and placental thickness and grading

From the analysis of data obtained it is found that the ultrasound scans can be serve as a monitor of detection of placental disorders and indicator for prognosis during the pregnancy period. And identification and early diagnosis of risk factor such as placenta previa.

The study reveal that about 78% have normal placenta thickness and 22% abnormal thickness (more than 4cm)but the abnormal placenta doesn't lead to any abnormality of maternal fetus which need more researches and studies to understand this characterize in Sudanese women.

5.3 Recommendation:

- 1- Ultrasound scanning should be used in every pregnant woman to evaluate the placental development and detect any abnormalities early if found.
- 2- The hospitals and clinical centers should be equipped by qualitative machines.
- 3- Further studies will be recommended to evaluate the ultrasound finding of placental thickness measurement on Sudanese
- 4- In next studies will be recommended to increase sample size to increase chance for study more patients.

References :-

Abo,po, 2009 ,Correlation Between Placental Thickness and Estimated Fetal Weight in Nigerian Women, *Ibnosina Journal of Medicine and Biomedical Science*, 3: 80 – 85

Chie.L and Levine.D, 2006, *Ultrasound Clinics*, Elsevier Saunders, USA, 303-319.

Devin Dean,Obstetric Ultrasound.The Buruwin Institute of Diagnostic Medical Ultrasound,Lunenburg , Canada .2005.

Elamin, M.Y.A, 2012, Relationship between Placental Thickness and Fetal Age, Sudan University of Science and Technology, Khartoum.

Graaff.v.d, 2001, *Human Anatomy*.6 ed, The McGraw–Hill Companies. U.S.A, 754-790.

Hammad, Y H, 2008, Measurements of Placental Thickness by Ultrasound in Third Trimester, Sudan University of Science and Technology. Khartoum.

<http://en.wikipedia.org/wiki/Placenta>

<http://www.biog1445.org/demo/07/ovaryplacenta.html>

<http://www.inharmonybirth.com/placenta-preparation>

<http://www.siumed.edu/~dking2/erg/placenta.htm>

Kurjak.A, Chervenak.F.A, 2006, *Donald School Textbook of Ultrasound in Obstetrics and Gynecology*, Taylor & Francis e-Library, London, 259-268.

Ohagwu c c, 2009, Relationship between Placental Thickness and Growth Parameters in Normal Nigerian Fetuses, *African Journal of Biotechnology*, 8: 133 – 138.

Rubin. E and Farber.J.L, 1999, *Pathology*,3d ed, Lippencott-Raven publisher, Philadelphia, 1016-1024.

Rumack.Carol.M et al, 2011, *Diagnostic Ultrasound*, 4th ed, Elsevier Mosby, Philadelphia, 1502.

Sadler.T.W. 2004, Medical Embryology Langman, 9th ed, Lippincott William & Wikins, 117-147.

Scanlon. Valerie C.and Sanders.T, 2007, Essentials of anatomy and physiology, 5th ed.F. A. Davis Company, Philadelphia, 480.

Appendix(I) :-

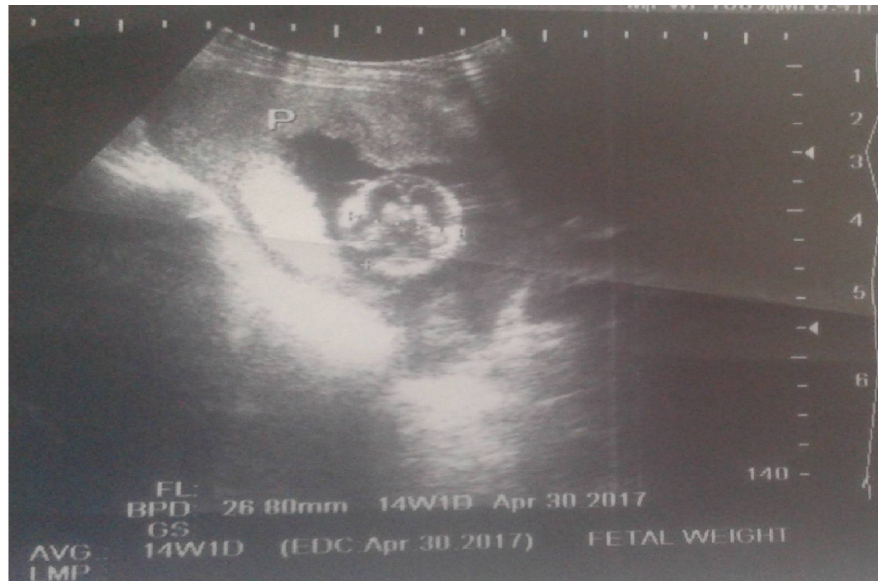

Image 1: Transabdominal ultrasound image for 24 years pregnant woman shows normal placental gestational age 14 weeks

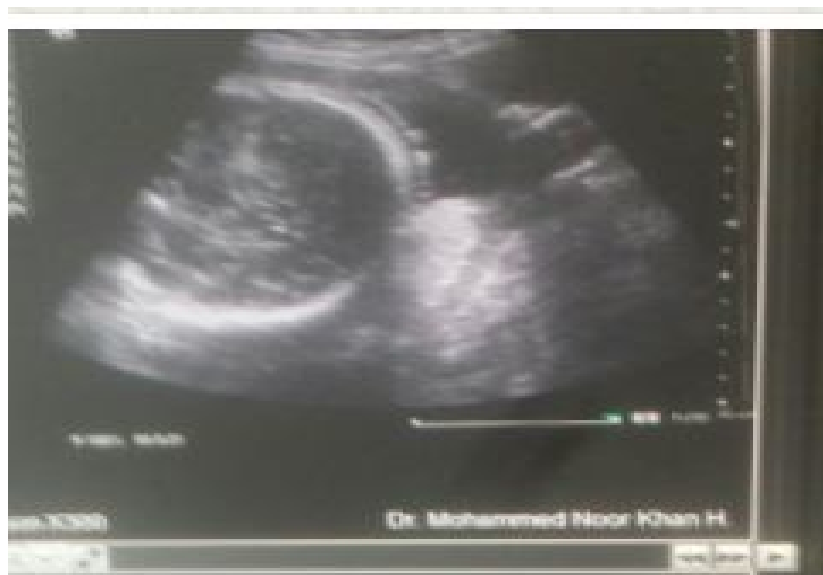

Image 2: Transabdominal ultrasound image for 27 years pregnant woman shows posterior placental previa , gestational age 29 weeks

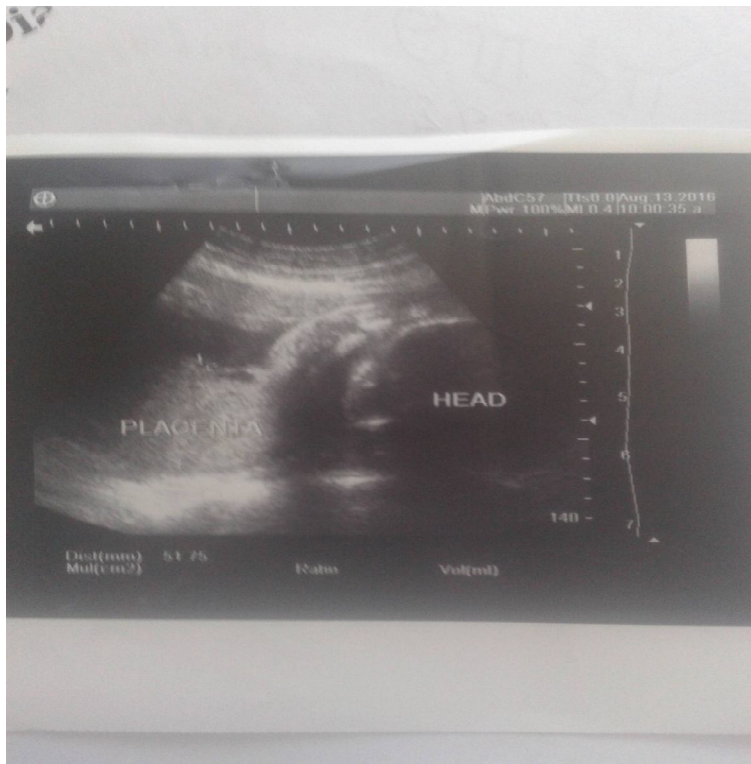

Image 3:Transabdominal ultrasound image for pregnant woman shows normal posterior upper placenta

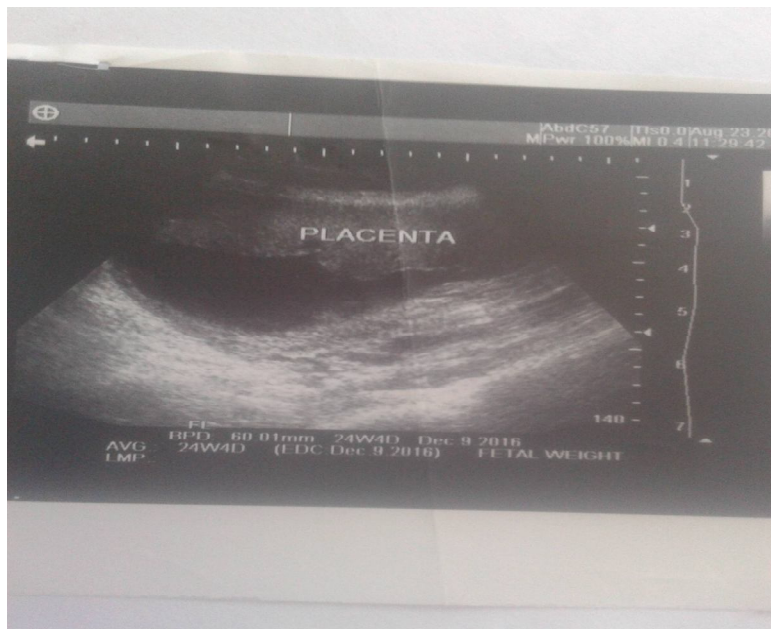


Image 4:Transabdominal ultrasound image for pregnant woman shows Normal anterior upper placenta

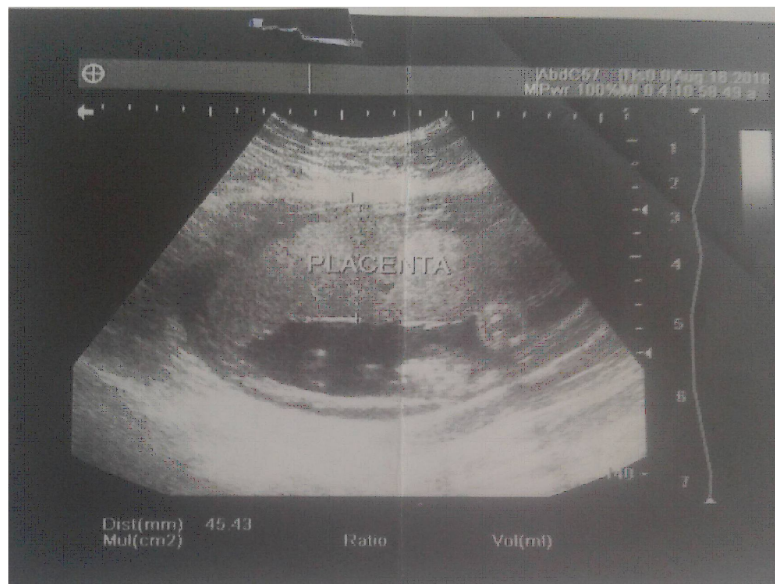


Image 5: Transabdominal ultrasound image for pregnant woman shows Normal anterior upper placenta

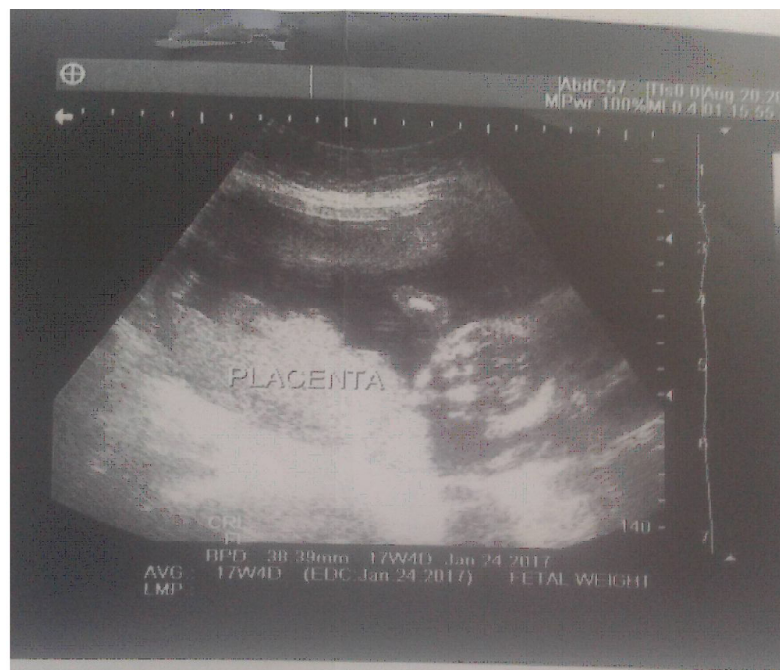

Image 6: Transabdominal ultrasound image for pregnant woman shows Normal posterior upper placenta

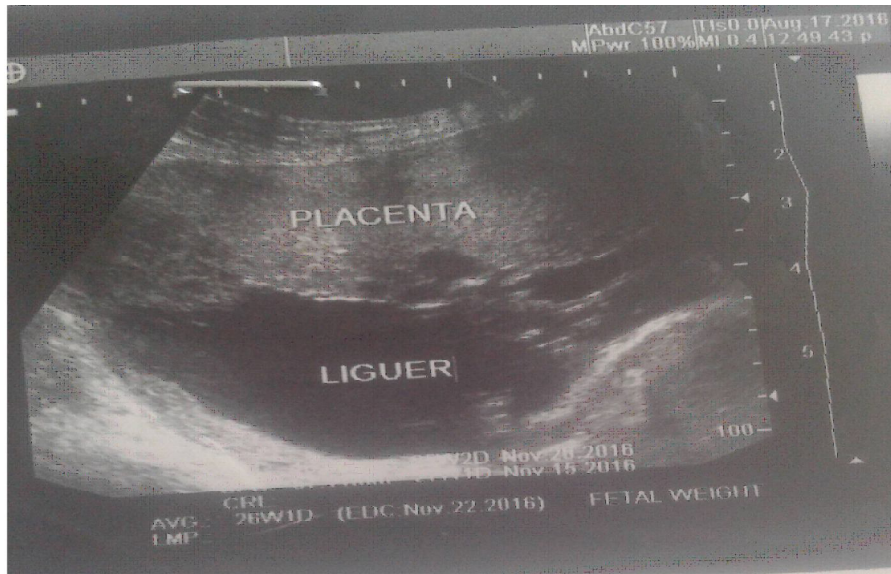

Image7:Transabdominal ultrasound image for pregnant woman shows Increased amniotic fluid index

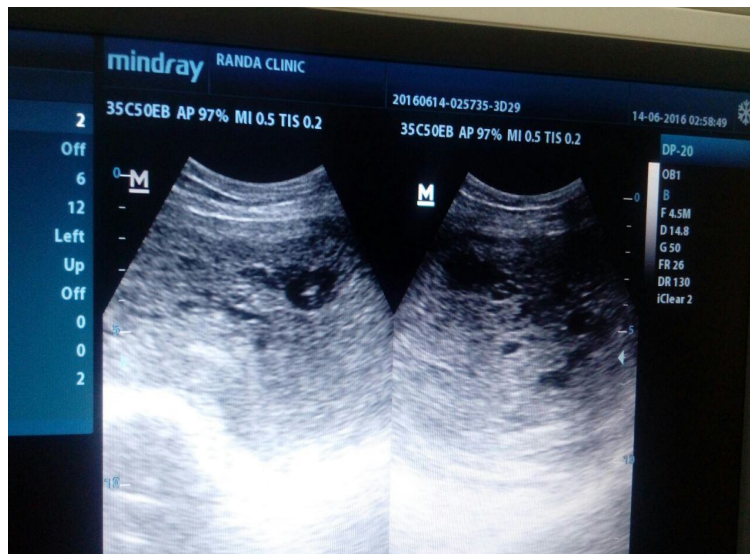


Image 8:Transabdominal ultrasound image shows molar pregnancy

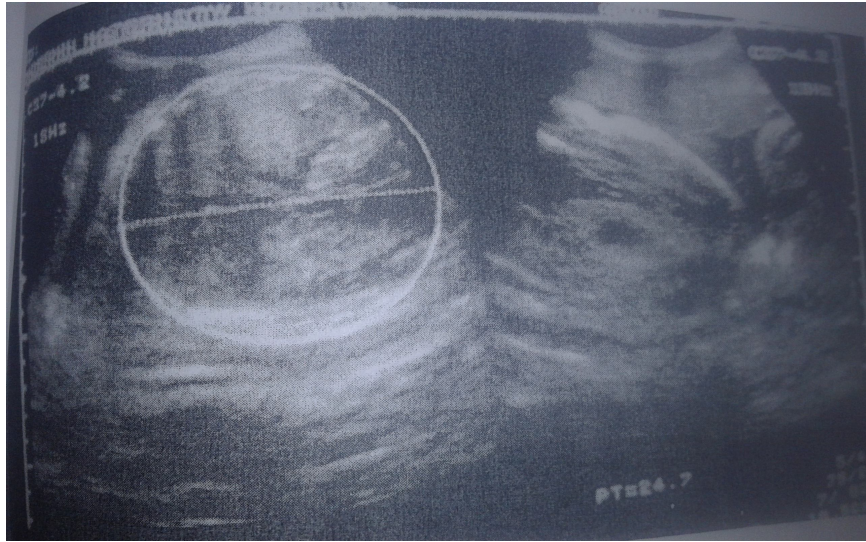


Image 9: Transabdominal ultrasound image for 27 years pregnant woman shows placental thickness=24.7mn gestational age 24 weeks+ 4 days

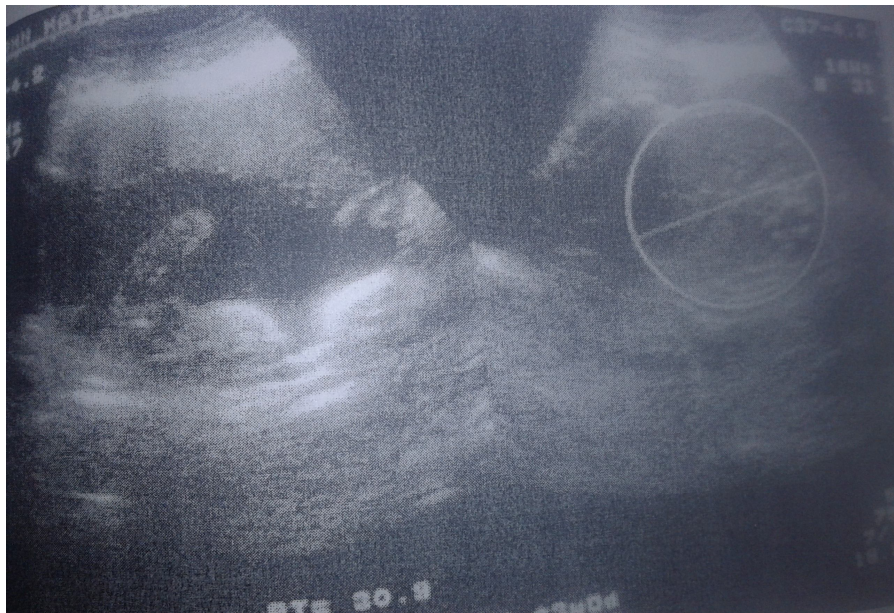

Image 10: Transabdominal ultrasound image for 19years pregnant woman shows placental thickness=30.9mn gestational age 31 weeks+ 3 days

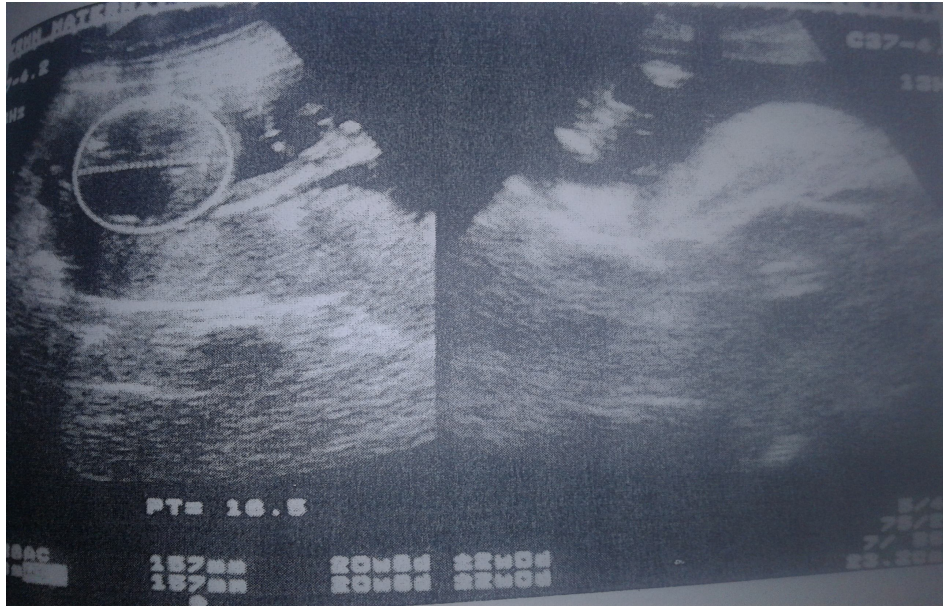


Image 11: Transabdominal ultrasound image for 24 years pregnant woman shows placental thickness=18.5mm gestational age 20 weeks

Appendix(II) :-

Sudan University of Technology and Science

College of Graduate Studies

Data Collection Sheet

Evaluation of Placental Development in pregnant ladies in Omdurman
Maternity Hospital

*Clinic.....

*Date...../...../2016.

*Patient Number (.....)

*Age (.....years)

***Placental characterization :-.....**

-Site : -low lying () Marginal () Previa () Normal ()

Echogenicity :- Homogenous () Hetrogenous ()

Grade :-grade 0 () grade 1 () grade 2 () grade 3()-

Thickness :- (mm)-

Gestational age ;-(weeks)-

Fetal weight :- (kg)

Amniotic fluid index:-..... (mm) -

Fetal abnormalities :-.....Normal ().....Abnormal () -