

Chapter one

1.1 .introduction:-

Headach is an almost universal experience and one of the most common symptoms in medical practice . It varies form an infrequent and trivial nuisance to a pointer to a pointer to serious disease.(Clarke , 2005).

Population based estimates suggest that about 4% of adults have daily or nerdialy headach.(GOADY,RASKIN,2008) Although majority of the patient who present with chronic or recurrent heachache have no neurologic abnormality ,many patient undergo evaluation with computed tomography (CT) and more recently , magnetic resonance (MRI) to exclude import abnormalities. (Tsushimay,Endok 2005).

Yet patient's demand for thorough and high-tech evaluation coupled with the low threshold among doctors for requesting these investigations has accelerated the use of CT and MRI despite the evidences against their use.

Headache, also known as cephalalgia, is the symptom of pain any where in the region of the head or neck. It occurs in migraines, tension-type headaches, and cluster headaches. Frequent headaches can affect relationships and employment. There is also an increased risk of depression in those with severe headaches.(headache disorder,2012).

Headaches can occur as a result of many conditions whether serious or not. There are a number of different classification systems for headaches. The most well-recognized is that of the International Headache Society. Causes of headaches may include fatigue, sleep deprivation, stress, the effects of medications, the effects of recreational drugs, viral infections, common colds, head injury, rapid ingestion of a very cold food or beverage, and dental or sinus issues . (Margreth William maagambo,2012).

1.1.1. Classification of headache:

Headache can further be classified as primary or secondary headache (Ramadan, Olesen.2006). Primary headache is the headache that has no associated cause and secondary headache is the one that has an organic origin. Examples of primary headache include migraine, cluster and tension headache. Primary headache is more common than secondary.

1.1.1.1. Primaryheadach:

1.1.1.1.1. Tension headache:

Tension headaches are often related to stress, depression or anxiety. Approximately 90 percent of all headaches are classified as tension-type headache. The estimated prevalence is said to be 40% in males and 42% in females. The pain is typically generalized all over the head. There appears to be a slightly higher incidence of this type of headache among women, because more females than males seek treatment. This type of headache is not associated with nausea or aggravation by physical activity. This can be further classified into episodic or chronic tension headache. ETH is where by it has a certain frequency which is not systematically known and CTH is when there are 15 episodes in a month for more than three months in a year. CTH emphasize the possible role of central nociceptive pathway sensitization in addition to peripheral myogenic factors(Mathew,2006).

1.1.1.1.2. Cluster headache:

There are an estimated one million cluster headache sufferers in the United States, of whom 10 percent are afflicted with chronic cluster. Cluster headaches are sharp, extremely painful headaches that tend to occur several times per day for months and then go away for a similar period of time.

1.1.1.1.3.HORMONALHEADACHE:

Women suffer migraines three times more frequently than do men, and,menstrual migraines affect 70 percent of these women. The estimated prevalence is said to be 10% in males and 22% in females. They occur before, during or immediately after the period, or during ovulation. Menstrual migraines are primarily caused by estrogen, the female hormones that specifically regulates the menstrual cycle fluctuations throughout the cycle. When the levels of estrogen and progesterone change, women will be more vulnerable to headaches. Because oral contraceptives influence estrogen levels, women on birth control pills may experience more menstrual migraines(Arjona A,etal,2007).Although the exact cause is not known, many experts consider migraine to be an inherited condition where the brain and its serotonin-controlled blood vessels are involved. These headaches can often be triggered by many factors, including stress, certain foods, glaring lights, physical exercise and changes in hormone levels.

1..1.1.1.4. Migraine headache:

Migraine headache is a form of primary headache. It also more common in females and the study by Bahou et al estimated a prevalence of 38.2% (Khu JV,etal,2008). It affects more females than males (Tepper,etal,2004).It has been demonstrated that WMLs are more often found in migraineurs but most migraineurs will not have them and even when found the association with migraine is not understood .

1.1.1.2. Secondary Headache:

Secondary headache can result from a tumor and bleeding in the brain. Risk factors documented include age, about 40 years and the gender whereby more females are more affected than men (Clinch CR.2001). Among illnesses associated with headache hypertension is the most prevalent. This can result into cerebral hemorrhage. Cerebral hemorrhage can be classified as epidural,

subdural or subarachnoid (Ramadan Olesen.2006). In all these types of cerebral hemorrhage, headache may present as acute severe headache that is accompanied with abnormal neurological symptoms(Lledo,etal,1994). Subarachnoid hemorrhage (SAH) presents with severe headache and is treated as an emergency. Imaging techniques are of use when done within the first 24 hours upon the acute onset of severe headache. This can be followed by a lumbar puncture within 72 hours to rule out meningitis. This was found in the study by Lledo et al (Lledo,etal,1994). The headache presents differently depending on the site where the lesion is located. For cerebellar lesion, frontal headache is prominent, for the cases where there is papillo-edema full blown headache is observed. The middle cranial fossa lesions are mostly associated with occipital headache.

1.1.2. Characteristics of headache by IHS:

The IHS have put the following warning signs and termed them as red flags for potential secondary headaches that need further investigation. New onset of headache in patients more than 50 years of age, focal neurological symptoms, non focal neurological symptoms. Others include new onset of headache in a cancer patient, new onset of headache in a patient with HIV infection, patients with risk of cerebral venous sinus thrombosis. Also headache with abnormal neurological examination, headache with fever and neck stiffness, Headache that changes with posture and headache precipitated by physical activity.

Treatment of a headache depends on the underlying cause, but commonly involves pain medication. Some form of headache is one of the most commonly experienced of all physical discomfort.

1.2 problem of study:-

Due to unavailability and higher cost of MRI ,CT is requested more frequently in our setup .

However no data exist in our country about the use of CT for evaluation of chronic headache and normal neurological findings .Thus, the purpose of the study was to evaluation the ability of CT in evaluation of chronic headache without neurological abnormality.

1.3 study objective :-

1.3.1 General objective:-

To find out the proportion of intracranial abnormalities in patient with chronic headache without neurologic abnormality with the use of computed tomography.

1.3.2 Specific objective:-

- To detect the ability of computer tomography detection of headache.
- To determine the intracranial abnormality.
- To evaluate this study with previous one.

1.4 over view of the study:-

this study was consist of five chapters ,chapter one will be an introduce briefly this thesis, chapter two is general introduction and literature review about previous study of evaluation of chronic headache by using computed tomography. Chapter three will describe the methodology (material, method).

Chapter four will include result of presentation of final finding of study; chapter five will include discussion conclusion and recommendations for future scope in addition to reference and appendices.

Chapter two

Literature review

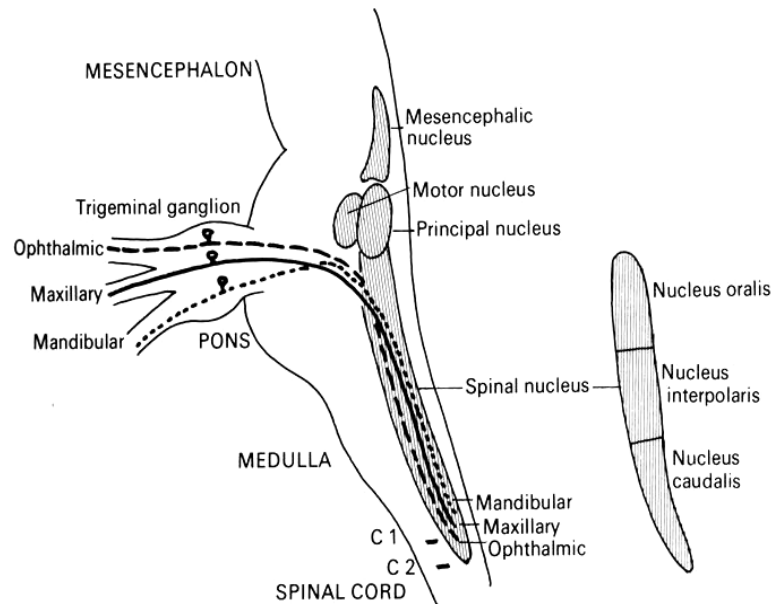
2.1. neuroanatomy of headache:

In the brainstem, the grey matter constituting the pars caudalis of the spinal nucleus of the trigeminal nerve extends caudally without interruption to become continuous with the grey matter of the dorsal horn of the spinal cord. Within this column of grey matter one can discern what is effectively nucleus - the trigeminocervical nucleus (fig 2.1).

This nucleus is not a nucleus in the classical sense for it does not have distinct rostral and caudal boundaries - it is directly continuous with the remainder of the spinal nucleus above and with the grey matter of the dorsal horn of the spinal cord below; nor does it have a unique cyto-architecture- the cells in the pars caudalis resemble those of the spinal grey matter and arranged in laminae that correspond to laminae I to V of the dorsal horn (Olszewski, 1950). Rather, the "nucleus" is defined by its afferent fibers.

The trigeminocervical nucleus is that region of grey matter that receives afferents from the trigeminal nerve and from the upper three cervical spinal nerves, together with additional fibres from the VII, IX and X cranial nerves. Trigeminal afferents ramify in the pars caudalis and as far caudally as the third cervical spinal cord segment, perhaps even as far as C4 (Humphrey, 1952, Torvik, 1956). Afferents from the first three spinal cord segments ramify at the segment at which they enter the spinal cord and also send collateral branches to more rostral and caudal segments. In particular, afferents from C2 ramify within the C2 grey matter but also ascend to C1 and descend to C3, and afferents from C1 ascend as far as C2 and C3. (Kerr, 1961).

Trigeminal Pain Pathway



Fig(2.1) Trigeminal nucleus. (Slide player.com, 2012).

The significance of the trigeminocervical nucleus is that it is the essential nociceptive nucleus of the head, throat and upper neck. All nociceptive afferents from the trigeminal, facial, gloss pharyngeal and vague nerves and the C 1-3 spinal nerves ramify in this single column of grey matter. Moreover, because of the overlapping pattern of ramification of primary afferent fibers, fibres from different peripheral nerves terminate on common, second-order neurones in the trigeminocervical nucleus. Although not formally demonstrated anatomically, this convergence has been demonstrated physiologically. Neuron's in the C1 and C2 segments respond to stimulation of afferents in both the upper cervical spinal nerves and the trigeminal nerve (Kerr, 1961).

This convergence constitutes the basis of referred pain in the head and upper neck. Stimulation of cervical afferents to a second-order neurone that also receives a trigeminal input may result in the source of stimulation being interpreted as arising in the cervical receptive field, the trigeminal receptive field or both. By the same token, if a neurone receives afferents from two different cervical receptive fields, stimulation of one may result in the perception of pain in the other cervical receptive field. This mechanism underlies the variety of patterns of pain perceived in the head and their sources. Pain in the forehead can arise as a result of stimulation of trigeminal forehead afferents (e.g. in frontal sinusitis) but it can also arise as a result of stimulation by the cervical afferents of second-order neurones in the trigeminocervical nucleus that happen also to receive forehead afferents. Similarly, pain in the occipital region (innervated largely by C2) does not necessarily imply an origin in the occiput, but may arise as a result of stimulation of trigeminal or cervical afferents from other sites but which relay to second-order neurones that receive a convergent input from occipital afferents.

Referred pain following cervical stimulation is most commonly perceived in the occipital and fronto-orbital regions of the head; less commonly in fields innervated by the maxillary and mandibular divisions of the trigeminal nerve. This correlates with the fact that maxillary and mandibular afferents in the spinal tract of the trigeminal nerve do not extend as far caudally into cervical segments as do ophthalmic afferents, or at least, do so less densely. Consequently, cervical

afferents are more likely to converge on second order neurones that receive ophthalmic afferents than ones that receive maxillary or mandibular afferents.

On anatomical grounds, the differential diagnosis of headache can be summarized comprehensively as any primary cause of pain that activates the

trigemincervical nucleus. In turn, the possible locations of peripheral causes of headache are dictated by the receptive field of the trigemincervical nucleus, namely any of the structures innervated by the trigeminal, VII, IX, X cranial nerves and the upper three cervical spinal nerves. Given the appropriate stimulus and given the appropriate convergent connections in the central nervous system, any structure innervated by these nerves is capable of causing headache.

2.2. Phyology:

here are three basic mechanism by which pain may be generated. Nociceptive pain arises when the terminals of peripheral nociceptive afferents are stimulated. Neurogenic pain arises when the axons or cell bodies of a peripheral nerve are stimulated. Central pain does not involve peripheral nerves and is caused by activation of second or third order pathways within the central nervous system.

Nociceptive pain requires some form of pathology or disturbance in the periphery that can activate nerve endings. In this regard only two mechanisms obtain - mechanical or chemical stimulation. Archetypically, mechanical nociception involves distortion of a network of collagen. In the appendicle skeleton the classical example is ligament strain; in the context of headache the example is strain of the dura mater. Chemical nociception requires the liberation of an algogenic chemical; inflammation is one source but others include potassium ions liberated from injured cells, e.g. blood.

Neurogenic pain requires the ectopic generation of action potentials long the course of a peripheral nerve. The causative lesion does not lie in peripheral territory supplied by the nerve but may be as far proximal as the roots of that nerve. The pain produced however, is perceived in the territory of that nerve.

Hence the location of the pain belies the location of the lesion. This type of pain has to be recognized in order that its source be accurately explored. Central pain is a mysterious phenomenon. It involves the activation of second or third order pathways by mechanisms other than stimulation by peripheral nerves. The pain evoked, however, is nonetheless perceived in the territory of the nerves that relay to the pathways involved; yet there is no pathology in the periphery to explain the pain. Archetypically, central pain occurs after peripheral nerve injury and involves differentiation super sensitivity of second order neurons of the spinal cord. Another model is demodulation, in which the descending inhibitory pathways that control pain perception are somehow themselves inhibited resulting effectively in an illusion of pain but pain that is nonetheless real in terms of the suffering it produces; the illusion pertains only to the lack of tissue damage in the territory in which the pain is perceived. When each of these three basic mechanisms is matched to the anatomy of headache the differential diagnosis of headache systematically emerges. (Biomed &Pharmarothrr , 1995).

2.3. Pathophysiology:

Primary headaches are more difficult to understand than secondary headaches. The exact mechanisms which cause migraines, tension headaches and cluster headaches are not known. There have been different theories over time which attempt to explain what happens in the brain to cause these headaches. Migraines are currently thought to be caused by dysfunction of the nerves in the brain.(Cutrer.etal,2014) Previously, migraines were thought to be caused by a primary problem with the blood vessels in the brain(Goadsby,,2009) This vascular theory, which was developed in the 20th century by Wolff, suggested that the aura in migraines is caused by constriction of intracranial vessels (vessels inside the brain), and the headache itself is caused by rebound dilation of extra cranial vessels (vessels

just outside the brain). Dilation of these extra cranial blood vessels activates the pain receptors in the surrounding nerves, causing a headache. The vascular theory is no longer accepted.(Cutrer,etal.2014\Charles,2013.) Studies have shown migraine head pain is not accompanied by extra cranial vasodilatation, but rather only has some mild intracranial vasodilatation.(Amin,2013)Currently, most specialists think migraines are due to a primary problem with the nerves in the brain.(Cutrer.etal,2014) Auras are thought to be caused by a wave of increased activity of neurons in the cerebral cortex (a part of the brain) known as cortical spreading depression(HADJIKHANI,2001)followed by a period of depressed activity.(Buzzi,etal.2005|) Some people think headaches are caused by the activation of sensory nerves which release peptides, such as serotonin, causing inflammation in arteries, Dura and meninges and also cause some vasodilatation. Triptans, medications which treat migraines, block serotonin receptors and constrict blood vessels.(Denny , Schull .2011).

People who are more susceptible to experience migraines without headache are those who have a family history of migraines, women, and women who are experiencing hormonal changes or are taking birth control pills or are prescribed hormone replacement therapy.

2.4. Diagnosis:

Most headaches can be diagnosed by the clinical history alone. (Buzzi,atel.2005).If the symptoms described by the person sound dangerous, further testing with neuroimaging and/or lumbar puncture may be necessary. Electroencephalography (EEG) is not useful for headache diagnosis.(Gronseth,2005).

The first step to diagnosing a headache is to determine if the headache is old or new. A "new headache" can be a headache that has started

recently, or a chronic headache that has changed character.(Smetana,2012). For example, if a person has chronic weekly headaches with pressure on both sides of his head, and then develops a sudden severe throbbing headache on one side of his head, he has a new headache.

2.5. Previous studies:

Of the 56 patients, 50 had normal CT (89.28 %), four had minor abnormality (7.14%) that did not alter patient management and two had significant lesions (3.57%). Contrast enhanced CT did not improve lesion detection. The minor findings detected were sub-ependymal calcifications of Tuberous sclerosis, calcified neurocysticercosis and old lacunars infarctions in external capsule. Clinically significant lesions detected were small ring enhancing lesion (neurocysticercosis or tuberculoma) and pineal cyst. Results of this study were compared with previous study with similar study design. The Z test showed that the difference in proportions in these studies was not statistically significant. (Anish Subede,2012).

The data reviewed demonstrate that 11% to 21% of patients presenting with new-onset headache have serious intracranial pathology (moderate and limited evidence)CT examination has been the standard of care for the initial evaluation of new-onset headache because CT is faster, more readily available.(L. Santiago Medina, etal,2012).

Most of the available literature (moderate and limited evidence) suggests that there is no need for neuroimaging in patients with migraine and normal neurologic examination. Neuroimaging is indicated in patients with no acute headache and unexplained abnormal neurologic examination; or in patients with atypical features or headache that does not fulfill the definition of migraine. .(L. Santiago Medina, etal,2012).

This cross sectional study included a total of 85 participants. There were more female candidates (47) than male candidates (38).From the study it is well established that CT imaging plays a major role in detecting the cause of secondary headache. When used properly it does confirm and give an alternate diagnosis. Most cases had primary type of headache. The

commonest cause that was found among patients with suspected secondary headache was sinusitis located in the maxillary sinus. Majority (68.2%) had no any significant findings. Many patients presented with hypertension as an existing morbidity and the frequent encountered neurological manifestation as loss of consciousness. (Margreth William Magambo ,2012).

Chapter three

Materials and Methods

3.1. Materials:

3.1.1. Study sample:

51 patients with chronic/recurrent headache and normal neurological findings.

3.1.2. Study area and population and duration:

In Khartoum state hospitals with Sudanese people have chronic headache from February 2016 until August 2016.

3.1.3. Machine used:

Multislice CT scan (Toshiba).

3.1.4. Study design:

A descriptive computed tomography image design.

3.1.5. Inclusion criteria:

- All the patients with the chief complaint of chronic recurrent long standing headache were included in the study.

3.1.6. Exclusion criteria:

- Abnormal neurological finding in clinical examination.
- Patients with diagnosed CNS abnormality.

3.1.7. Accessory instrumentation:

- Automatic injector (3-4 ml/s).
- Contrast media (omipaque 1 ml/kg).

3.2. Methods:

3.2.1. Technique:

The scans were performed with patients in supine position laying on the table of computed tomography machine, putted the head over head holder of the table and grip it by the strap in order to stability, the machine justed on spiral scan with 120 kvp, 300 MA, head first and 5mm thicken cut. Administrated the contrast media if need it, the tube of machine rotate with different angle to produce image in two dimension and receive to radiologist to diagnosis it.

3.2.2. Data collection:

The clinical data and the CT images of the patient undergoing cranial CT scan for the evaluation of chronic headache were reviewed. Clinical information was collected from the requisition form supplied by the referring doctor. CT images were reviewed from the digital archive of the department.

3.2.3. Data analysis:

Data was analyzed using SPSS version 15.0. Descriptive statistic program.

Chapter four

Results

This chapter aimed to description the statistical of the data among 51 patients complain of headache or chronic headache without neurological defect by using computed tomography.

The area of the study was scoped in the Khartoum hospitals with radiological diagnostic department.

Table (4.1) show that the mean age of patients was 31.41years, with Stander deviationof13.650 between age range (2 to 74) years

Table(4.1) Age distribution.

	N	Minimu m	Maximu m	Mean	Std. Deviation
Age	51	2	74	31.41	13.650

Table (4.2) Gender distribution.

Gender	Frequency	Percent
Male	22	43.1
Female	29	56.9
Total	51	100.0

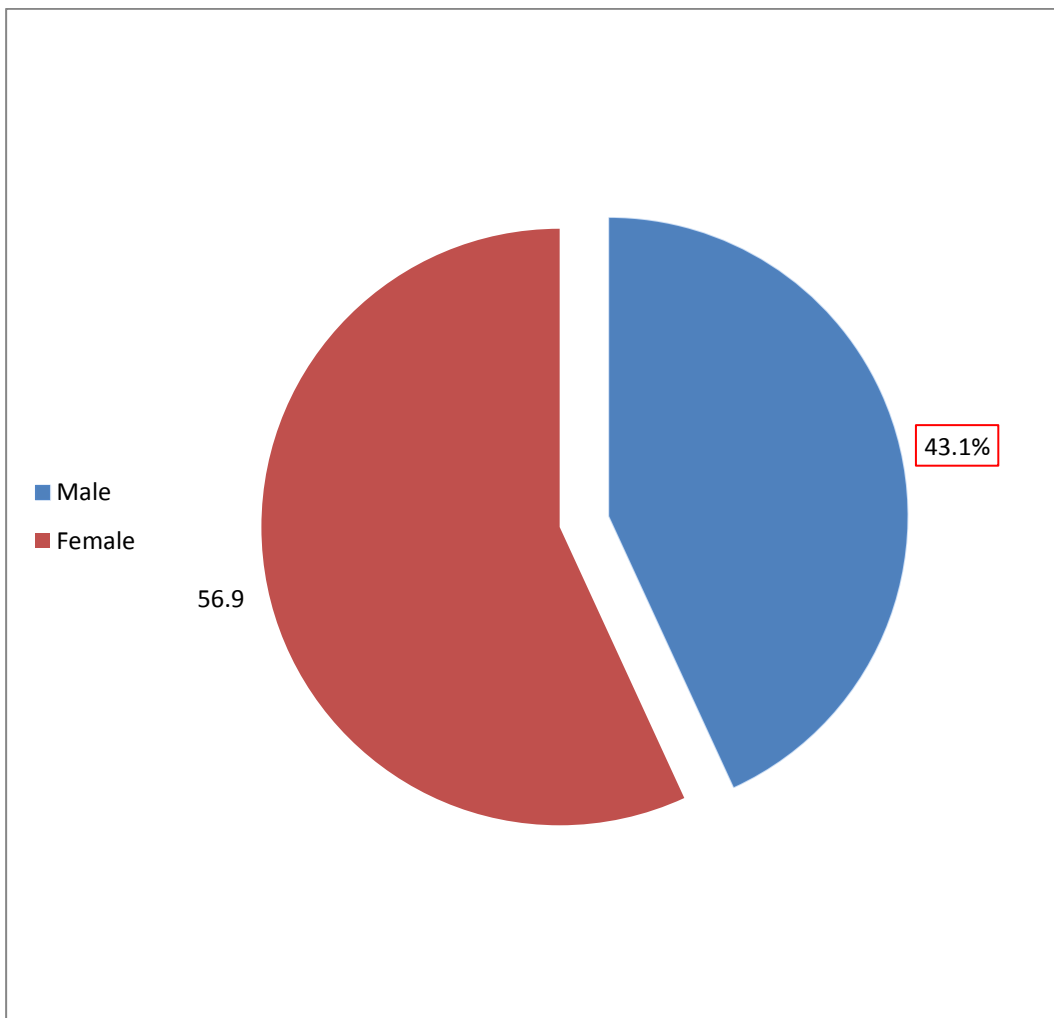


Fig (4.1) Gender distribution.

Table (4.3) CT findings distribution.

CT finding	Frequency	Percent
normal	40	78.4
sinusitis	2	3.9
epidural hematoma	1	2.0
hydrocephalus	1	2.0
malignant feature	2	3.9
brain atrophy	4	7.8
dandy walker syndrome	1	2.0
Total	51	100.0

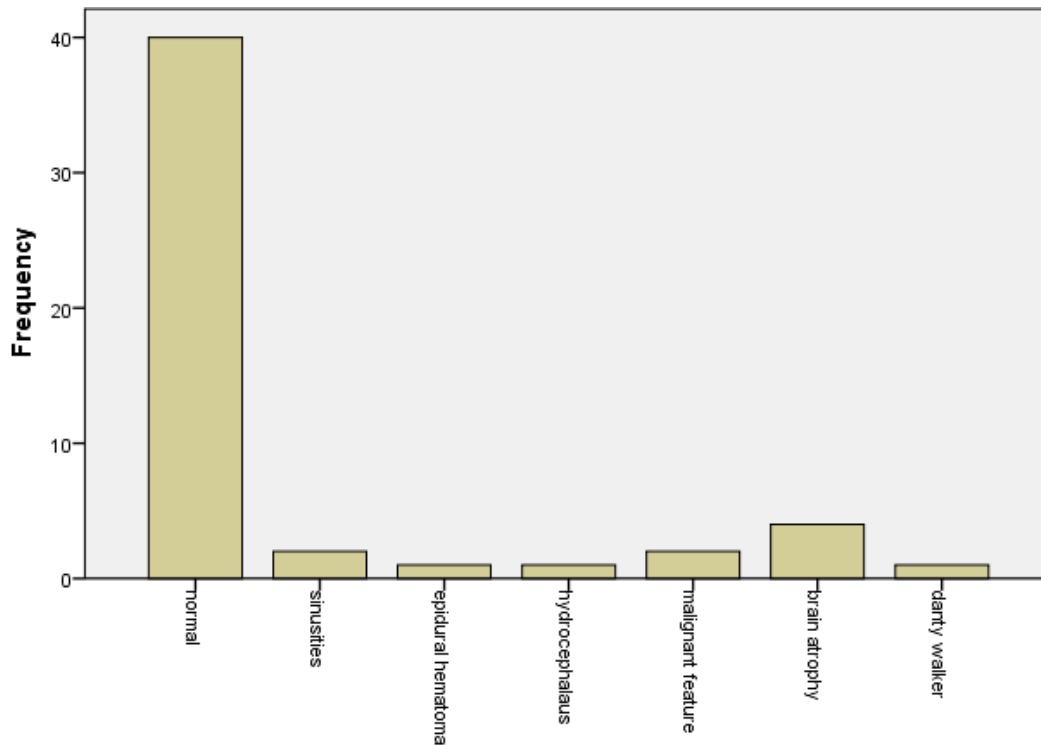
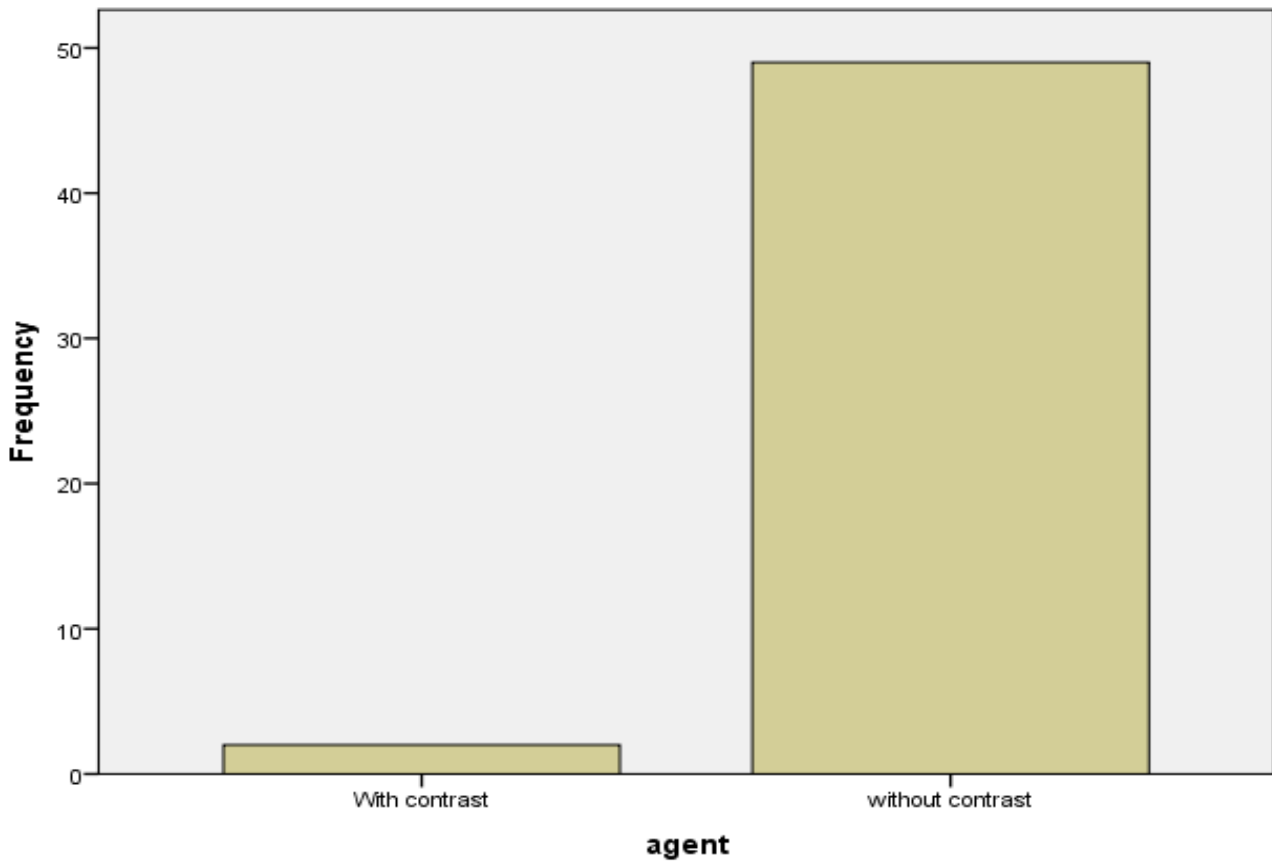


Fig (4.2) CT findings distribution.

Table (4.4) Contrast agent distribution.

Contrast	Frequency	Percent
With contrast	2	3.9
without contrast	49	96.1
Total	51	100.0



Fig(4.3) Contrast agent distribution.

Table (4.5): Age groups according to gender distribution.

		gender		Total
		male	female	
Age	0-9	1	1	2
	10-19	2	3	5
	20-29	9	9	18
	30-39	6	10	16
	40-49	2	3	5
	50-59	1	2	3
	70-79	1	1	2
Total		22	29	51

Correlation is significant at $p < 0.05$, $p = 0.992$

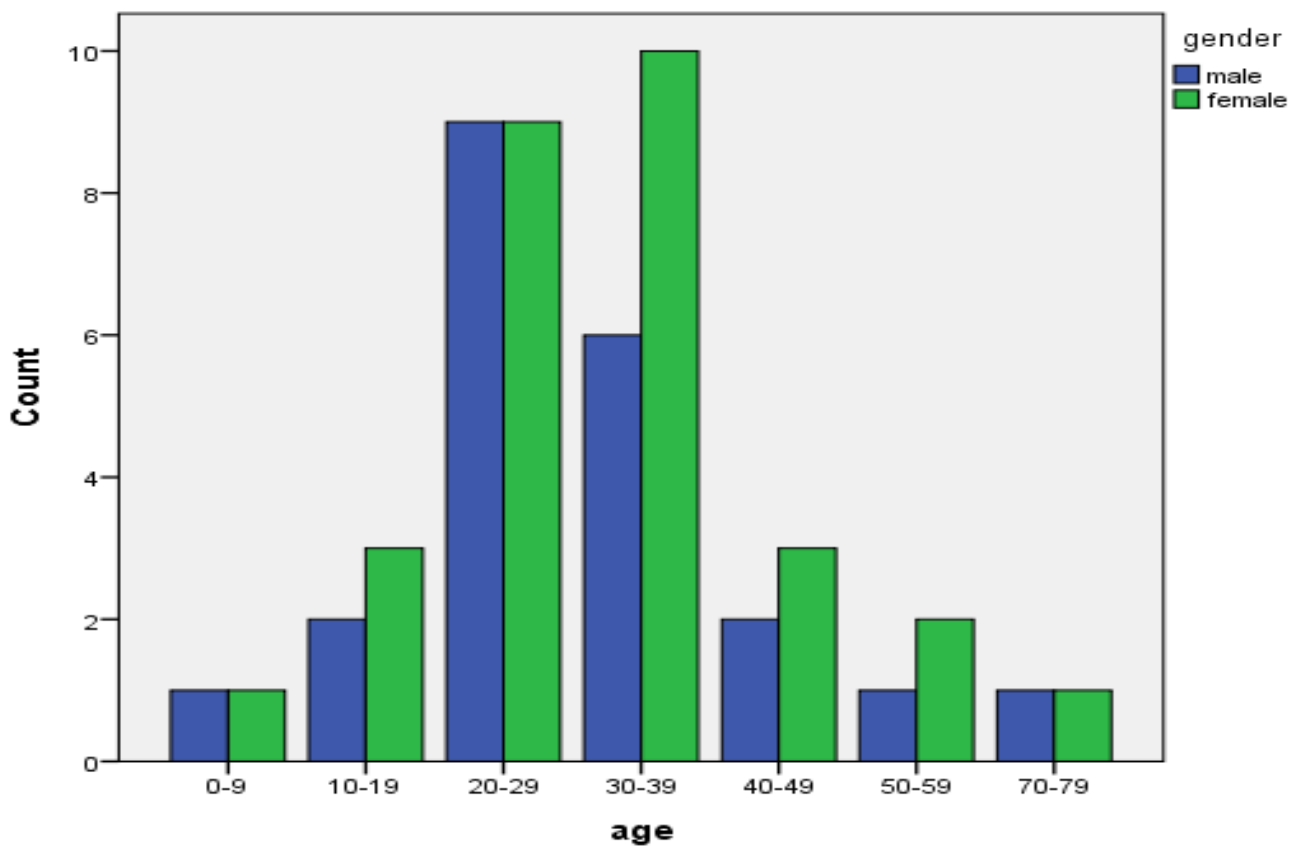


Fig (4.4) Age groups according to gender distribution.

Table (4.6) Age groups according to contrast agent.

		agent		Total
		With contrast	without contrast	
Age	0-9	0	2	2
	10-19	1	4	5
	20-29	0	18	18
	30-39	1	15	16
	40-49	0	5	5
	50-59	0	3	3
	70-79	0	2	2
Total		2	49	51
Correlation is significant at $p < 0.05$, $p = 0.559$				

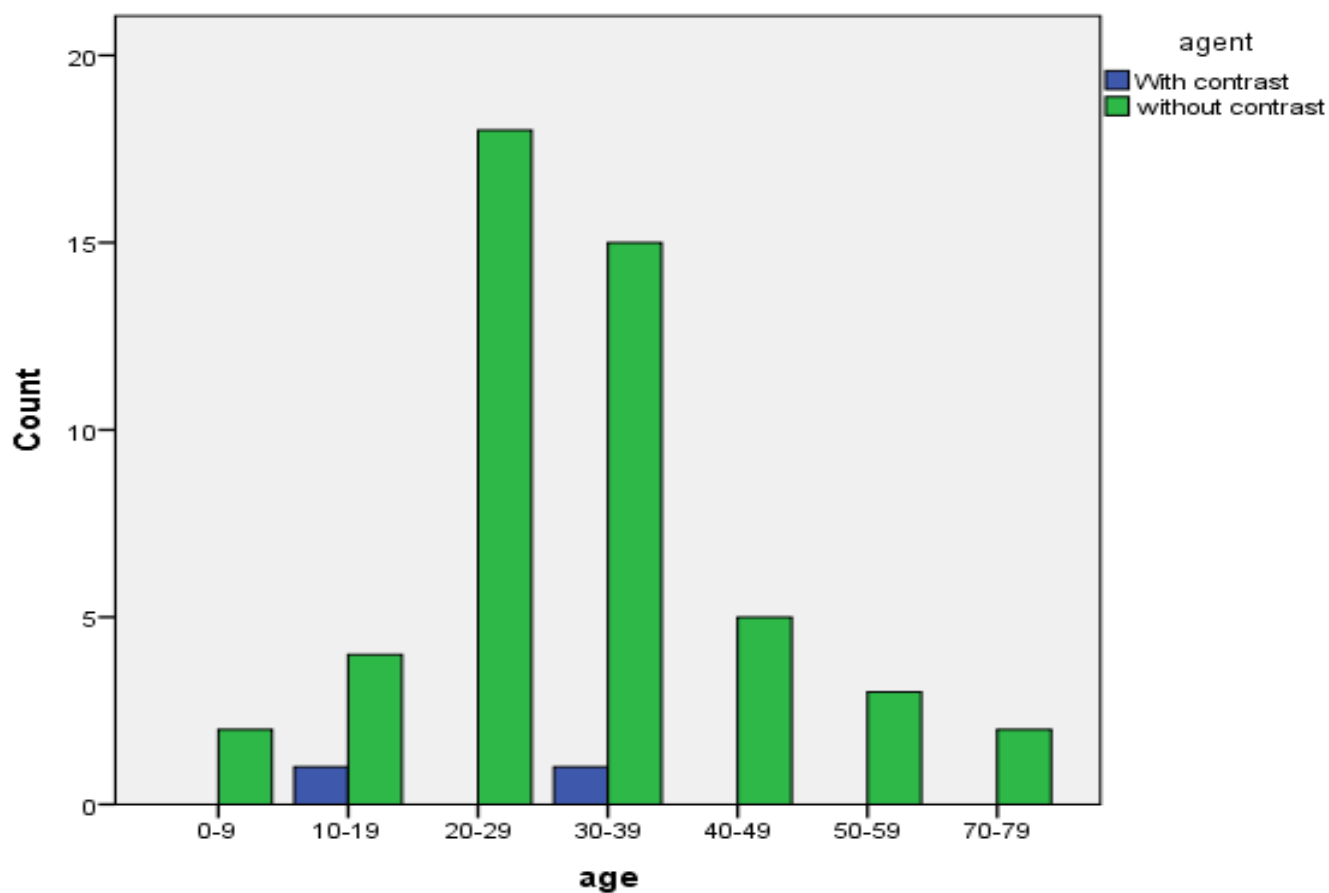


Fig (4.5) Age groups according to contrast agent.

Table (4.7) Age groups according to CT findings.

		finding						Dandy walker	Total
		normal	sinusitis	epidural hematoma	hydrocephalus	malignant feature	brain atrophy		
age	0-9	1	0	0	0	0	0	1	2
	10-19	5	0	0	0	0	0	0	5
	20-29	15	0	0	0	1	2	0	18
	30-39	12	1	1	1	0	1	0	18
	40-49	4	1	0	0	0	0	0	5
	50-59	2	0	0	0	0	1	0	3
	70-79	1	0	0	0	1	0	0	2
Total		40	2	1	1	2	4	1	51

Correlation is significant at $p < 0.05$, $p = 0.055$

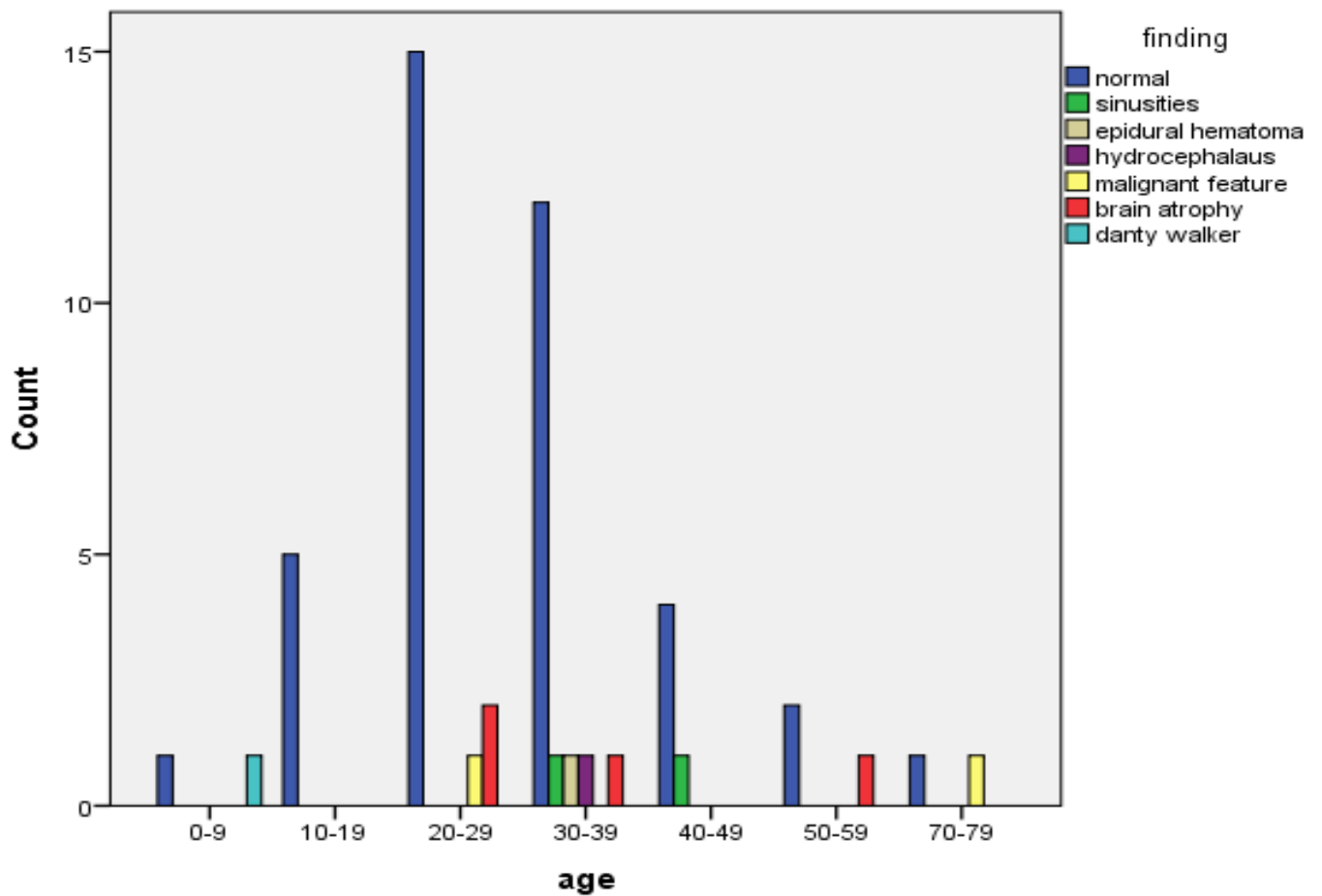


Figure (4.6) Age groups according to CT findings.

Chapter five

Discussion

The descriptive image of computed tomography of the brain study was conducted among 51 patients in Khartoum hospitals during the period from February 2016 until Augustus 2016.

These patients suffered with chronic headache without neurological defect and came to doctor and referred to diagnostic department in order to scan.

The findings of the study resulted that; the main age of the patient was 31 years with stander deviation 13.650 between age (2to74) years.

Also the study indicated the majority patients gender were females more than males 29(%56.9), 22(%43.1) respectively. This indicated is similar to study that was done by (Margreth William maagambo,2012) was showed the females are more than males 47(%55.3),38(%44.7) respectively, with patients range (18to81)years, (n=85).

The study was finding in both male and female according to CTscan findings the majority of normal scan is maximum one related to another findings however the resulted as 40 (%78.4) with total number 51 that it is agreewith (anish subedee,2012) was founded the majority of the CTfindings for the the patient suffered chronic headache is normal 50(%89.28) with total number of patient is 56.

Also the study was showed with CTfindings of pathologies resulted that the sinusitis 2(%3.9), epidural hematoma 1(%2), hydrocephalus 1(%2)

Malignant feature 2(%3.9), brain atrophy 4(%7.8), dandy walker syndrome 1(%2), and this is most pathological finding with headache.

The study was the contrast media injected for two patients only and forty nine patients without injected, did not improve it is yield.

The study was revealed association between age range and gender is no significant ($P = 0.992$), and the more prevalent age range was effected by chronic headache is 34 (20-39) years, that result is full similarity with study of (anish subedee,2012) that resulted of more age range effected by chronic headache 29(20-39). (n=56).

Also the are no association between age range and contrast media administration the correlation value is ($P=0.59$), the reason aback to the a few number of the patients administrated contrast just 2 patients,1(10-19)year.1(30-39)year.

The study was findings also the association between CTfindings and age range are proximately significant ($P=0.055$).

Also the prevalent of majority are normal 15 patients within age range (20-29), sinusitis 2(30-49), epidural heamatoma 1(30-39),hydrocephalus 1(30-39),malignant feature 1(50-59),brain atrophy 2(20-29),dandy walker syndrome 1(0-9).

Conclusions

The study concluded the following:

The study it is well established that CT imaging plays major role in detecting cause of secondary headache (%21.6),the commonest causes that was founded among patient with suspected secondary headache was brain atrophy(%7.8).

The study demonstrated also that mean age of patient was young 31.41 years with SD=13.650 and prevalent of females more than males(%56.9), (%43.1)respectively and majority (%78.4) had no any significant CT findings(normal) and these is agreement with previous studies.

The study illustrated That were no correlation between age and contrast media administration $P=(0.559)$, age and gender $p= (0.992)$, but also it is founded significant correlation between age and CTfindings $p=(0.055)$.

Recommendations

- The computed tomography have inferiorly detected of intracranial abnormalities with primary headache than MRI but also is superiorly detected of secondary headach.
- The doctors should be choice wisely the best modalities to detected headache.
- To improve this study comparison study between CT and MRI should be do .
- Cancer patients should undergo CT scan when presenting with first time headache due to high likelihood having brain metastasis.
- Usage contrast media agent cannot taking yield to detected abnormality unless the patient knower with vascular disorder or malignant feature.

REFERENCES

Amin FM, Asghar MS, Anders H; et al. (2013). "Magnetic resonance angiography of intracranial and extracranial arteries in patients with spontaneous migraine without aura: a cross sectional study". Lancet Neurol.

Arjona A, Rubi-Callejon J, Guardado-Santervas P, Serrano-Castro P, Olivares J. Menstrual tension-type headache: evidence for its existence. *Headache.* 2007Jan;47(1):100-3.

Buzzi, M.G.; Moskowitz, M (2005). "The pathophysiology of migraine: year 2005". J Headache Pain.6 (3): 105–11.

Buzzi, M.G.; Moskowitz, M (2005). "The pathophysiology of migraine: year 2005". J Headache Pain. 6 (3): 105–11.

Charles A (2013). "Vasodilation out of the picture as a cause of migraine headache". Lancet Neurol. 12 (5): 419–420.

Clarke CRA. Neurological Disease. In: Kumar P, Clark M, editors. *Clinical Medicine.* Sixth ed. Elsevier Limited; 2005.p. 1174.

Clinch CR. Evaluation of acute headaches in adults. *Am Fam Physician.* 2001 Feb15;63(4):685-92.

Cutrer, FM, Bajwa A, Sabhat M. Pathophysiology, clinical manifestations and diagnosis of migraine in adults. In: UpToDate, Post TW (Ed), UpToDate, San Francisco, CA. (Accessed on April 23, 2014).

Cutrer, FM, Bajwa A, Sabhat M. Pathophysiology, clinical manifestations and diagnosis of migraine in adults. In: UpToDate, Post TW (Ed), UpToDate, San Francisco, CA. (Accessed on April 23, 2014).

Denny CJ, Schull MJ. Chapter 159. Headache and Facial Pain. In: Tintinalli JE, Stapczynski J, Ma O, Cline DM, Cydulka RK, Meckler GD, T. eds. *Tintinalli's Emergency Medicine: A Comprehensive Study Guide, 7e.* New York, NY: McGraw-Hill; 2011".

Goadsby PJ, Raskin NH. Headache. In: Fauci AS, Braunwald EB, Casper DL et al, editors. *Harrison's Principles of Internal Medicine.* 17th ed. McGraw Hill Medical; 2008.p. 103.

HADJIKHANI, N; SANCHEZ DEL RIO, M; WU, O; Bakker, Dick; Fischl, Bruce; Kwong, Kenneth K.; Cutrer, F. Michael; Rosen, Bruce R.; Tootell, Roger B. H.; Sorensen, A. Gregory; Moskowitz, Michael A.; et al.

(2001). "Mechanisms of migraine aura revealed by functional MRI in human visual cortex".

Humphrey T. The spinal tract of the trigeminal nerve in human embryos between 7 1/2 and 8 1/2 weeks of menatrualage and its relation to early feetalbehaviour. *J CampNeuml* 1952.

Kerr FWL. Olafson RA. Trigeminal and cervical volleys. *Arch Neural* 1961;5:171-8.

Kerr FWL. Structural relation of the trigeminal spinal tract to upper cervical roots and the solitary nucleus in the cat. *Exp'heuro* 1961;4:134-48

Khu JV, Siow HC, Ho KH. Headache diagnosis, management and morbidity in the Singapore primary care setting: findings from a general practice survey. *Singapore Med J.* 2008 Oct;49(10):774-9.

Lledo A, Calandre L, Martinez-Menendez B, Perez-Sempere A, Portera-Sanchez A. Acute headache of recent onset and subarachnoid hemorrhage: a prospective study. *Headache.* 1994 Mar;34(3):172-4.

Mathew NT. Tension-type headache. *CurrNeuroNeurosci Rep.* 2006 Mar;6(2):100-5.

Olszewski J. On the anatomical and functional organization of the spinal trigeminal nucleus. *J Camp Neural* 1950;92:401-13 Ouaknine G, Nathan.

Ramadan NM, Olesen J. Classification of headache disorders. *Semin Neurol.* 2006 Apr;26(2):157-62.

Smetana GW. Chapter 9. "Headache." In: Henderson MC, Tierney LM, Jr., Smetana GW. eds. *The Patient History: An Evidence-Based Approach to Differential Diagnosis.* New York, NY: McGraw-Hill; 2012.

Tepper, S.J. PrDahlof, C. G, Dowson, A, Newman, L, Mansbach, H, Jones, M. Pham, B, Webster, C. Salonen, R. Prevalence and diagnosis of migraine in patients consulting their physician with a complaint of headache: data from the Landmark Study. *Headache,* 2004. **44**(9): p. 856-64.

Torvik A. Afferent connections to the sensory trigeminal nuclei, the nucleus of the solitary tract and adjacent structures. *J Camp Neural* 1956;106:51-141 Travel] JG, Simons DG. Mvofascial Pain.

Tsushima Y, Endo K. MR imaging in the evaluation of chronic or recurrent headache. *Radiology* 2005; 235:575-579.

Gronseth, G.S.; Greenberg, M.K. (July 1995). "The utility of the electroencephalogram in the evaluation of patients presenting with headache: A review of the literature". Neurology.

Goadsby, P.J. (January 2009). "The vascular theory of migraine--A great story wrecked by the facts.

Headache disorders Fact sheet N°277". October 2012. Retrieved 15 February 2016.

Migraine Without Headache". Neurobalance. Retrieved 16 July 2014.

APPENDEX (A)

N	AGE	Gender	CLINICAL INDICATION	CONTRAST AGENT		PATIENT HISTORY	CT FINDING
				WITH	WITHOUT		

DATA SHEET COLLECTION

Reporting example

Patient id: 187033	Patient name: xxxxxxxxxx
Study Date: 5/9/2016	ref. phy.: -

Procedure:

NON -CONTRAST MULTISLICE C.T AXIAL & CORONAL SCANS OF NOSE, PARANASAL SINUSES & NASOPHARYNX

C.T OF THE BRAIN IS ALSO INCLUDED

Morphology:

- Significant opacification of left sided maxillary sinuses associated with mild right sided maxillary sinus mucosal thickening of sinusitis.
- Clear bilateral frontal sinuses, bilateral ethmoidal air cells & bilateral sphenoidal sinuses.
- Right sided hypertrophy of nasal turbinate particularly the right inferior one mostly of Polypoidal rhinitis.
- Significant obliteration of bilateral osteomeatal complexes
- Rightward deviated bony nasal septum
- Normal study of the brain with evidence of localized brain parenchymal focal lesions, midline shift or ventricular dilatations.

Impression:

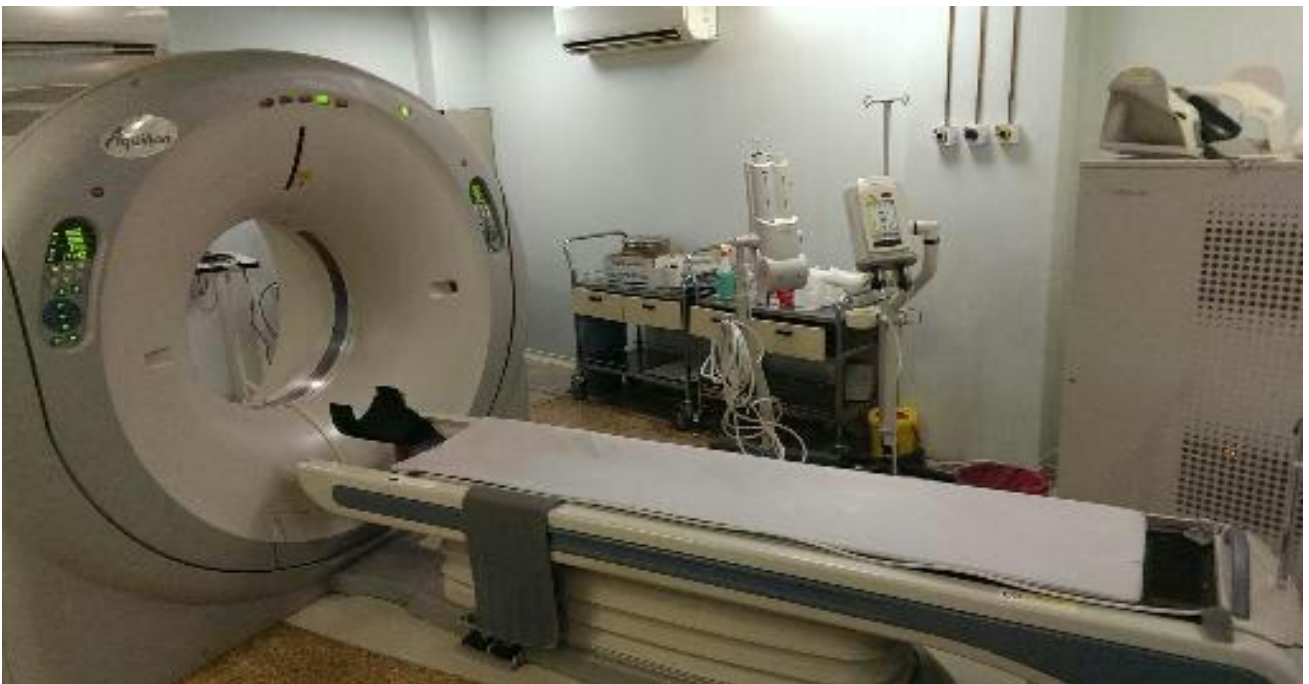-
- *C.T findings are impressive of partial sinusitis; right sided polypoidal rhinitis & rightward deviated bony nasal septum as described above.*
 - *Normal c.t of the brain.*
-

Thanks

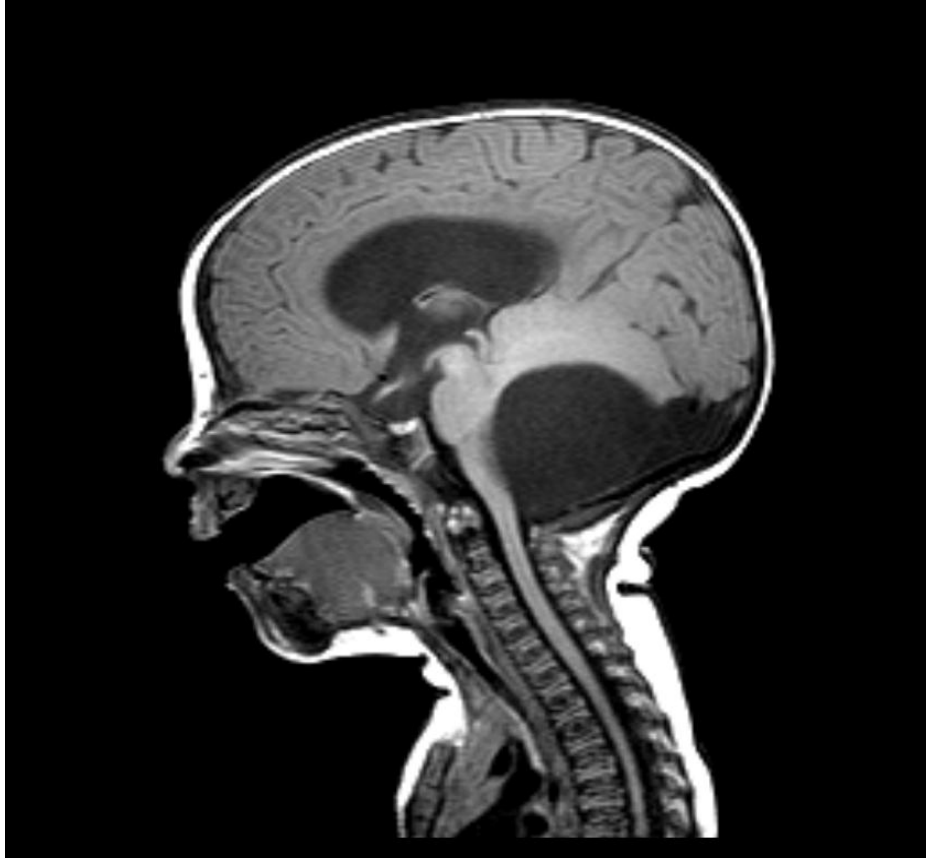
PROF AYMAN SLEM

Consultant Radiologist

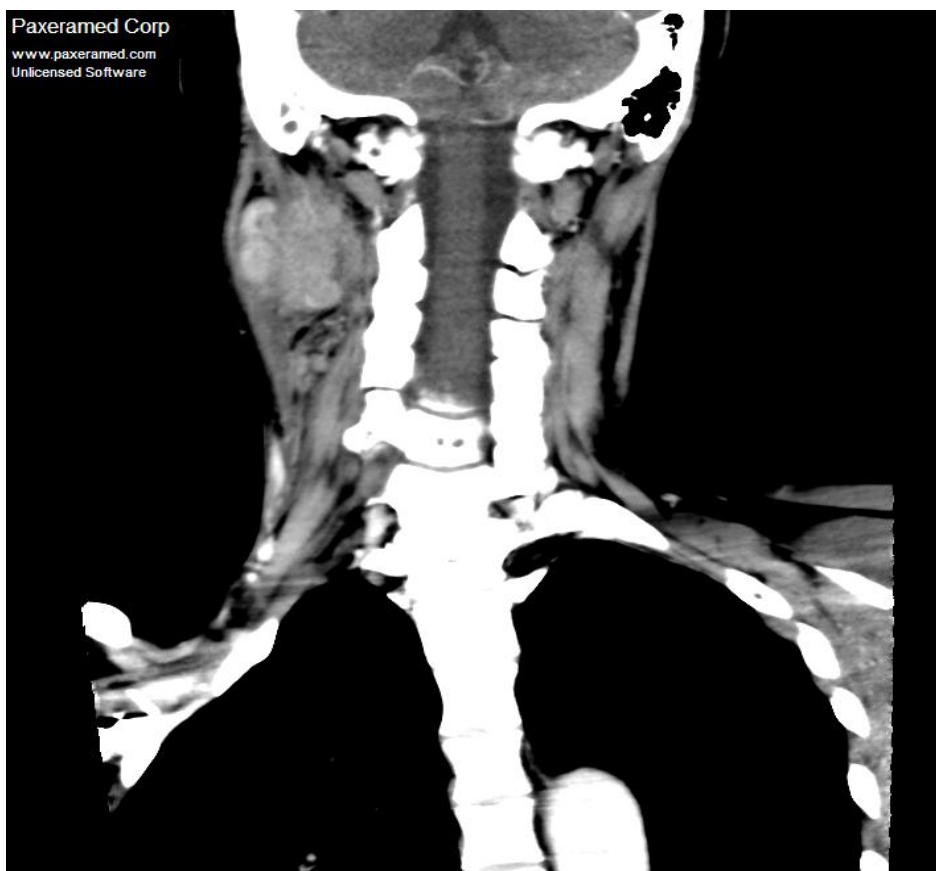
APPENDIX(B)



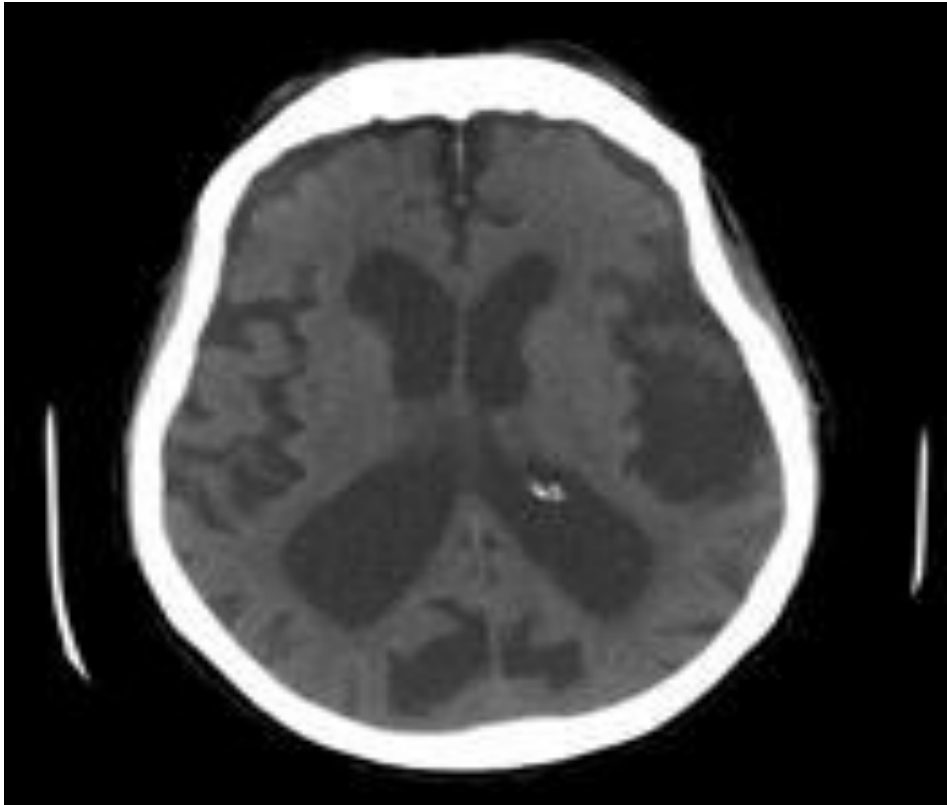
Toshiba CT scan with two automatic injectors



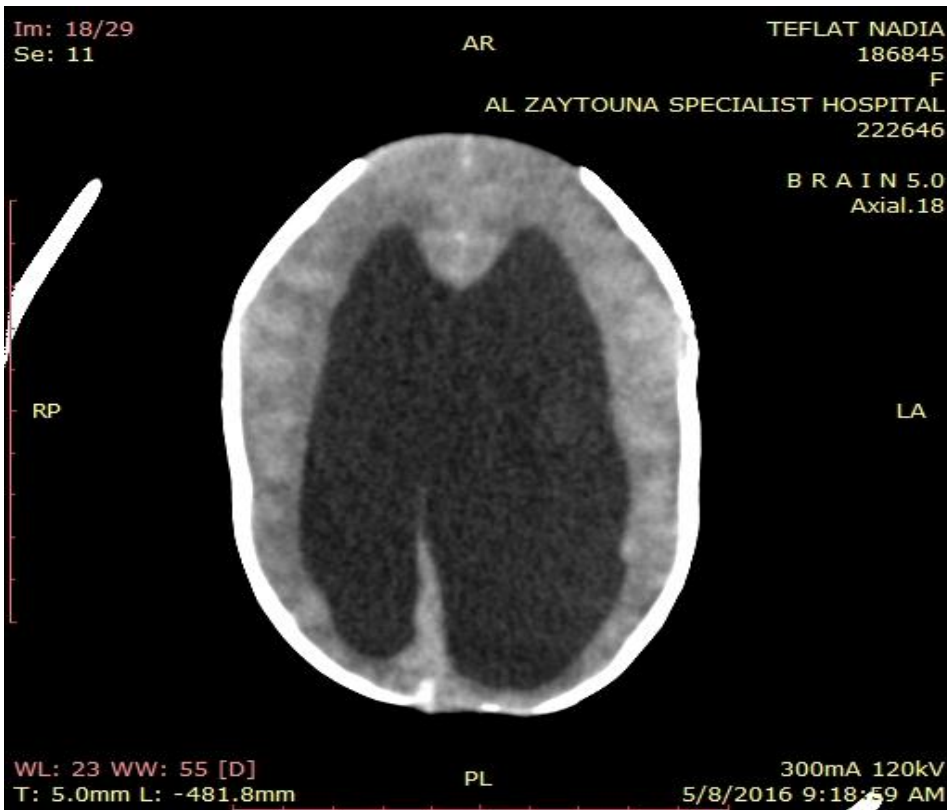
Sagittal plain of brain MRI for 2-year-old male child with Dandy-Walker syndrome.



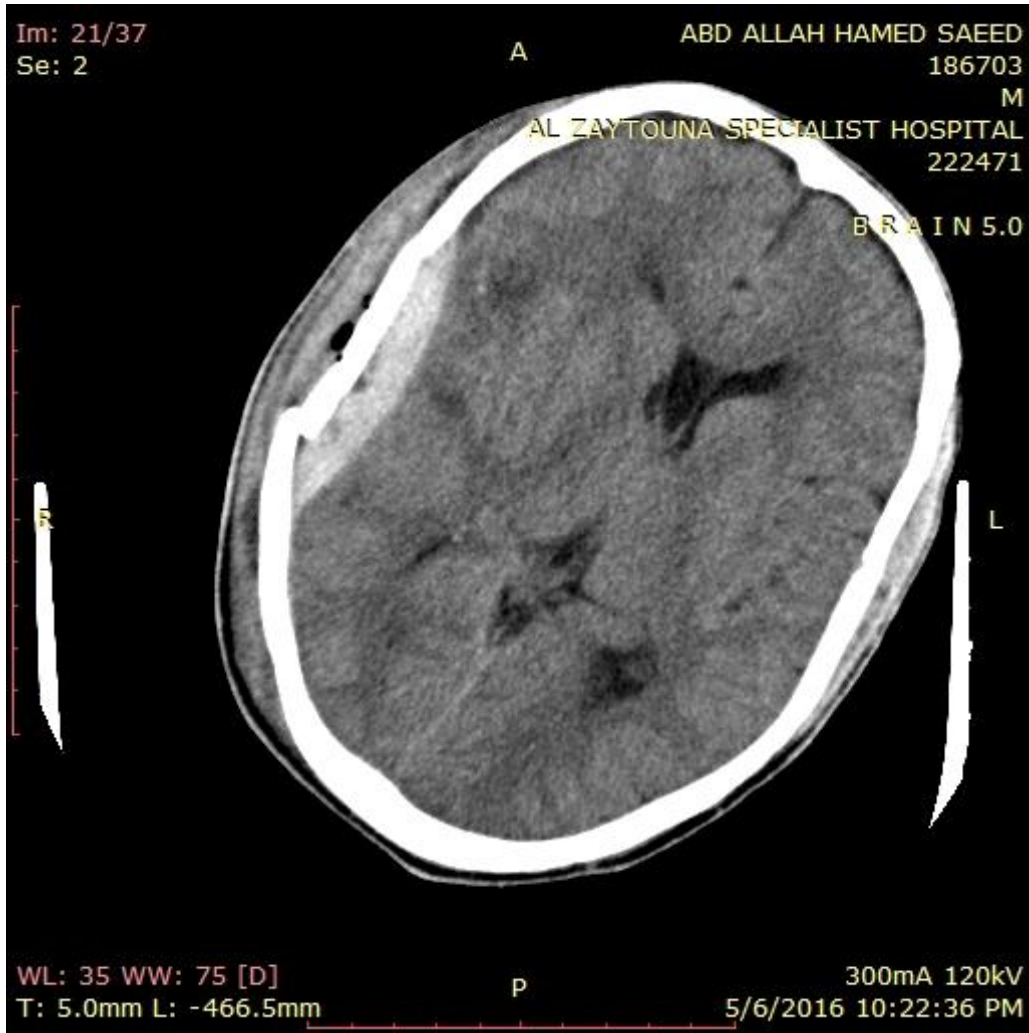Coronal plain of reconstruction computed tomography of malignant featuring considerable sized right-sided nasopharyngeal mass lesion for 40-year-old male.



Axial computed tomography image for atrophied brain with 70years male.



Axial computed tomography for brain with hydrocephalus patient 2years male.



Axial computed tomography for brain with epidural hematoma for 30 years male.